

World Journal of *Clinical Cases*

World J Clin Cases 2020 May 26; 8(10): 1756-2065



**GUIDELINES**

- 1756** French Spine Surgery Society guidelines for management of spinal surgeries during COVID-19 pandemic
Prost S, Charles YP, Allain J, Barat JL, d'Astorg H, Delhaye M, Eap C, Zairi F, Guigui P, Ilharreborde B, Meyblum J, Le Huec JC, Lonjon N, Lot G, Hamel O, Riouallon G, Litrico S, Tropiano P, Blondel B, the French Spine Surgery Society

OPINION REVIEW

- 1763** Needs and concerns of patients in isolation care units - learnings from COVID-19: A reflection
Fan PEM, Aloweni F, Lim SH, Ang SY, Perera K, Quek AH, Quek HKS, Ayre TC

REVIEW

- 1767** Prophylactic and therapeutic roles of oleanolic acid and its derivatives in several diseases
Sen A
- 1793** Macrophage regulation of graft-vs-host disease
Hong YQ, Wan B, Li XF

MINIREVIEWS

- 1806** Antiphospholipid syndrome and its role in pediatric cerebrovascular diseases: A literature review
Sarecka-Hujar B, Kopyta I
- 1818** Remotely monitored telerehabilitation for cardiac patients: A review of the current situation
Batalik L, Filakova K, Batalikova K, Dosbaba F
- 1832** Keystone design perforator island flap in facial defect reconstruction
Lim SY, Yoon CS, Lee HG, Kim KN

ORIGINAL ARTICLE**Clinical and Translational Research**

- 1848** Cross electro-nape-acupuncture ameliorates cerebral hemorrhage-induced brain damage by inhibiting necroptosis
Cai GF, Sun ZR, Zhuang Z, Zhou HC, Gao S, Liu K, Shang LL, Jia KP, Wang XZ, Zhao H, Cai GL, Song WL, Xu SN

Retrospective Study

- 1859** Evaluation of ischemic lesions after carotid artery stenting with diffusion-weighted imaging
Beyhan M, Acu B, Gökçe E, Fırat MM
- 1871** Transjugular intrahepatic portosystemic shunt and splenectomy are more effective than endoscopic therapy for recurrent variceal bleeding in patients with idiopathic noncirrhotic portal hypertension
He FL, Qi RZ, Zhang YN, Zhang K, Zhu-Ge YZ, Wang M, Wang Y, Jia JD, Liu FQ

- 1878** Liglipatin for treatment of type 2 diabetes mellitus with early renal injury: Efficacy and impact on endogenous hydrogen sulfide and endothelial function
Zhang J, Du YL, Zhang H, Sui H, Hou WK
- 1887** Outcomes of patients with pelvic leiomyosarcoma treated by surgery and relevant auxiliary diagnosis
Sun Q, Yang X, Zeng Z, Wei X, Li KZ, Xu XY
- 1897** Defecation function and quality of life in patients with slow-transit constipation after colectomy
Tian Y, Wang L, Ye JW, Zhang Y, Zheng HC, Shen HD, Li F, Liu BH, Tong WD
- 1908** Risk factors, incidence, and morbidity associated with antibiotic-associated diarrhea in intensive care unit patients receiving antibiotic monotherapy
Zhou H, Xu Q, Liu Y, Guo LT
- Observational Study**
- 1916** Serum von Willebrand factor for early diagnosis of lung adenocarcinoma in patients with type 2 diabetes mellitus
Zhou YY, Du X, Tang JL, Wang QP, Chen K, Shi BM
- 1923** Four-microRNA signature for detection of type 2 diabetes
Yan LN, Zhang X, Xu F, Fan YY, Ge B, Guo H, Li ZL

CASE REPORT

- 1932** Isolated colonic neurofibroma, a rare tumor: A case report and review of literature
Ghoneim S, Sandhu S, Sandhu D
- 1939** Helmet-based noninvasive ventilation for acute exacerbation of chronic obstructive pulmonary disease: A case report
Park MH, Kim MJ, Kim AJ, Lee MJ, Kim JS
- 1944** Appendectomy in patient with suspected COVID-19 with negative COVID-19 results: A case report
Kim C, Kim JK, Yeo IH, Choe JY, Lee JE, Kang SJ, Park CS, Kwon KT, Hwang S
- 1950** T4 cervical esophageal cancer cured with modern chemoradiotherapy: A case report
Lee CC, Yeo CM, Ng WK, Verma A, Tey JC
- 1958** Lumbar disc rehydration in the bridged segment using the BioFlex dynamic stabilization system: A case report and literature review
Li YC, Feng XF, Pang XD, Tan J, Peng BG
- 1966** Traditional investigation and management for recurrent hemarthrosis after total knee arthroplasty: A case report
Geng X, Li Y, He X, Tian H

- 1973** Positron emission tomography/computed tomography findings of multiple cystic lymphangiomas in an adult: A case report
Sun MM, Shen J
- 1979** Heterotopic pancreas adenocarcinoma in the stomach: A case report and literature review
Xiong Y, Xie Y, Jin DD, Wang XY
- 1988** Early-onset refractory diarrhea due to immune dysregulation, polyendocrinopathy, enteropathy, X-linked syndrome associated with a novel mutation in the *FOXP3* gene: A case report
Su N, Chen C, Zhou X, Ma GD, Chen RL, Tian C
- 1995** Tuberous sclerosis complex presenting as primary intestinal lymphangiectasia: A case report
Lin WH, Zhang ZH, Wang HL, Ren L, Geng LL
- 2001** Gilbert's syndrome coexisting with hereditary spherocytosis might not be rare: Six case reports
Kang LL, Liu ZL, Zhang HD
- 2009** Effective combined therapy for pulmonary epithelioid hemangioendothelioma: A case report
Zhang XQ, Chen H, Song S, Qin Y, Cai LM, Zhang F
- 2016** Unexplained huge liver infarction presenting as a tumor with bleeding: A case report
Wang FH, Yang NN, Liu F, Tian H
- 2023** Rare recurrent gallstone ileus: A case report
Jiang H, Jin C, Mo JG, Wang LZ, Ma L, Wang KP
- 2028** Treating severe periodontitis with staged load applied implant restoration: A case report
Wang SH, Ni WC, Wang RF
- 2038** Cryptococcal pneumonia in a human immunodeficiency virus-negative patient: A case report
Jiang XQ, Zhang YB
- 2044** Ileocecal intussusception caused by two different tumors - which is the culprit lesion? A case report
Fan WF, Ma G, Li GC, Long J, Xu YH, Guo KJ, Liu Z
- 2050** Robot-assisted retroperitoneal laparoscopic excision of perirenal vascular tumor: A case report
Zhang C, Fu B, Xu S, Zhou XC, Cheng XF, Fu WQ, Wang GX
- 2056** Successful use of plasma exchange in fulminant lupus myocarditis coexisting with pneumonia: A case report
Xing ZX, Yu K, Yang H, Liu GY, Chen N, Wang Y, Chen M

ABOUT COVER

Editorial Board Member of *World Journal of Clinical Cases*, Preet M Chaudhary, MD, PhD, Professor, Department of Medicine, Jane Anne Nohl Division of Hematology and Center for the Study of Blood Diseases, University of Southern California, Los Angeles, CA 90033, United States

AIMS AND SCOPE

The primary aim of *World Journal of Clinical Cases* (WJCC, *World J Clin Cases*) is to provide scholars and readers from various fields of clinical medicine with a platform to publish high-quality clinical research articles and communicate their research findings online.

WJCC mainly publishes articles reporting research results and findings obtained in the field of clinical medicine and covering a wide range of topics, including case control studies, retrospective cohort studies, retrospective studies, clinical trials studies, observational studies, prospective studies, randomized controlled trials, randomized clinical trials, systematic reviews, meta-analysis, and case reports.

INDEXING/ABSTRACTING

The WJCC is now indexed in PubMed, PubMed Central, Science Citation Index Expanded (also known as SciSearch®), and Journal Citation Reports/Science Edition. The 2019 Edition of Journal Citation Reports cites the 2018 impact factor for WJCC as 1.153 (5-year impact factor: N/A), ranking WJCC as 99 among 160 journals in Medicine, General and Internal (quartile in category Q3).

RESPONSIBLE EDITORS FOR THIS ISSUE

Responsible Electronic Editor: Ji-Hong Liu

Proofing Production Department Director: Xiang Li

Responsible Editorial Office Director: Jin-Lai Wang

NAME OF JOURNAL

World Journal of Clinical Cases

ISSN

ISSN 2307-8960 (online)

LAUNCH DATE

April 16, 2013

FREQUENCY

Semimonthly

EDITORS-IN-CHIEF

Dennis A Bloomfield, Bao-Gan Peng, Sandro Vento

EDITORIAL BOARD MEMBERS

<https://www.wjgnet.com/2307-8960/editorialboard.htm>

PUBLICATION DATE

May 26, 2020

COPYRIGHT

© 2020 Baishideng Publishing Group Inc

INSTRUCTIONS TO AUTHORS

<https://www.wjgnet.com/bpg/gerinfo/204>

GUIDELINES FOR ETHICS DOCUMENTS

<https://www.wjgnet.com/bpg/GerInfo/287>

GUIDELINES FOR NON-NATIVE SPEAKERS OF ENGLISH

<https://www.wjgnet.com/bpg/gerinfo/240>

PUBLICATION ETHICS

<https://www.wjgnet.com/bpg/GerInfo/288>

PUBLICATION MISCONDUCT

<https://www.wjgnet.com/bpg/gerinfo/208>

ARTICLE PROCESSING CHARGE

<https://www.wjgnet.com/bpg/gerinfo/242>

STEPS FOR SUBMITTING MANUSCRIPTS

<https://www.wjgnet.com/bpg/GerInfo/239>

ONLINE SUBMISSION

<https://www.f6publishing.com>

Traditional investigation and management for recurrent hemarthrosis after total knee arthroplasty: A case report

Xiao Geng, Yang Li, Xuan He, Hua Tian

ORCID number: Xiao Geng (0000-0003-0502-6237); Yang Li (0000-0002-4799-5397); Xuan He (0000-0002-1673-5939); Hua Tian (0000-0001-7139-3372).

Author contributions: Geng X and Li Y contributed equally to the work, as co-first authors; Geng X, Li Y and He X reviewed the literature and contributed to manuscript drafting; Tian H revised the manuscript for important intellectual content; all authors issued final approval for the version to be submitted.

Informed consent statement: Informed written consent was obtained from the patient.

Conflict-of-interest statement: The authors declare that they have no conflict of interest.

CARE Checklist (2016) statement: The authors have read the CARE Checklist (2016), and the manuscript was prepared and revised according to the CARE Checklist (2016).

Open-Access: This article is an open-access article that was selected by an in-house editor and fully peer-reviewed by external reviewers. It is distributed in accordance with the Creative Commons Attribution NonCommercial (CC BY-NC 4.0) license, which permits others to distribute, remix, adapt, build upon this work non-commercially, and license their derivative works on different terms, provided the original work is properly cited and the use is non-commercial. See: <http://creativecommons.org/licenses/by-nc/4.0/>

Xiao Geng, Yang Li, Xuan He, Hua Tian, Orthopedic Department, Peking University Third Hospital, Beijing 100191, China

Corresponding author: Hua Tian, MD, Professor, Orthopedic Department, Peking University Third Hospital, No. 49 North Garden Rd, Haidian District, Beijing 100191, China. tianhua@bjmu.edu.cn

Abstract

BACKGROUND

Recurrent hemarthrosis is a rare complication of total knee arthroplasty, and only a few cases have been reported; hence, it is hard to establish comprehensive diagnosis and treatment guidelines. We here report a case of recurrent hemarthrosis after total knee arthroplasty, and briefly review the literature.

CASE SUMMARY

A 50-year-old man, with a history of hypertension, presented to the Orthopedic Department of our hospital for non-traumatic acute left knee pain and swelling associated with a warmth sensation 14 mo after total knee arthroplasty. Investigations (ultrasound, aspiration, and arthroscopy) and managements (non-surgical, arthroscopy and open exploration) were performed, and the clinical effects of these interventions were analyzed separately. Clinical evidence indicates that the cause of this case was rupture of a pseudoaneurysm of the medial superior genicular artery.

CONCLUSION

The present case indicated that angiography is essential in cases of hemarthrosis after TKA; arthroscopy may not always be adequate as it may not provide a clear view; and traditional open exploration is still effective and sometimes necessary.

Key words: Total knee arthroplasty; Recurrent hemarthrosis; Arthroscopy; Open exploration; Case report

©The Author(s) 2020. Published by Baishideng Publishing Group Inc. All rights reserved.

Core tip: Recurrent hemarthrosis is a rare complication of total knee arthroplasty, and only a few cases have been reported; hence, it is hard to establish comprehensive diagnosis and treatment guidelines. We present herein a rare case of recurrent hemarthrosis which occurred 14 mo after total knee arthroplasty. The patient underwent traditional investigations (ultrasound, aspiration, and arthroscopy) and managements

ses/by-nc/4.0/

Manuscript source: Unsolicited manuscript**Received:** February 10, 2020**Peer-review started:** February 10, 2020**First decision:** April 1, 2020**Revised:** April 8, 2020**Accepted:** April 17, 2020**Article in press:** April 17, 2020**Published online:** May 26, 2020**P-Reviewer:** De Martino I**S-Editor:** Wang JL**L-Editor:** Med-E Ma JY**E-Editor:** Liu JH

(non-surgical, arthroscopy and open exploration), and the clinical effects of these interventions were analyzed separately. Clinical evidence indicated that the cause of recurrent hemarthrosis in this case was rupture of a pseudoaneurysm of the medial superior genicular artery.

Citation: Geng X, Li Y, He X, Tian H. Traditional investigation and management for recurrent hemarthrosis after total knee arthroplasty: A case report. *World J Clin Cases* 2020; 8(10): 1966-1972

URL: <https://www.wjgnet.com/2307-8960/full/v8/i10/1966.htm>

DOI: <https://dx.doi.org/10.12998/wjcc.v8.i10.1966>

INTRODUCTION

Recurrent hemarthrosis is a complication of total knee arthroplasty (TKA)^[1], with an incidence of 0.3% to 1.6%, and appropriate management should be implemented as early as possible to minimize the risk of severe consequences^[2-5]. No consensus is available on the criteria for diagnosis or treatment of this disease^[6]. Kindsfater *et al*^[7] described a case series of 30 patients and their findings were broadly reflective of the subsequent literature. In the present case, various investigations and managements were performed, and the clinical effects of these interventions were analyzed separately.

CASE PRESENTATION

Chief complaints

A 50-year-old man, with a history of hypertension, presented to the Orthopedic Department of our hospital for non-traumatic acute left knee pain and swelling associated with a warmth sensation 14 mo after TKA.

History of past illness

He had a history of hypertension, but was not regularly taking any anticoagulant or antiplatelet medication.

History of present illness

He had a bilateral knee pain due to end-stage primary knee osteoarthritis for over 10 years and underwent TKA of the left knee in 2013 after failure of conservative treatment. There were no complications intraoperatively. A pneumatic tourniquet was used during surgery at a pressure of 300 mmHg after exsanguination. The implant used was a Press Fit Condylar prosthesis P.F.C.® SIGMA® (DePuy Synthes, West Chester, United States). A single intra-articular drainage without blood recovery system was used, and was removed 24 h postoperatively. The drainage volume was 300 mL. Postoperative rehabilitation was uneventful, and the outcome was satisfactory. Thromboprophylaxis was administered with sodium enoxaparin (6100 IU per day), starting on the day of surgery and lasting 2 wk. The patient was discharged on postoperative day 7. Clinical tests and radiographs were normal 3 mo after TKA. The range of motion of the left knee was 0° extension to 125° flexion, and the femorotibial angle was 178°. The Hospital for Special Surgery Scoring System (HSS) score improved from 50 points to 96 points (with 30 points of pain, 20 points of function, 16 points of mobility, 10 points of force, 10 points of deformity and 10 points of stability). The Western Ontario and McMaster Universities Osteoarthritis Index (WOMAC) score reduced from 62 points to 7 points. However, 14 mo postoperatively, the patient experienced acute pain in the left knee while he was sleeping. This onset of pain was associated with immediate swelling of the knee and a sensation of warmth in the area of pain.

Physical examination

Local findings in the left knee showed that the range of motion was limited to 0° extension and 80° flexion, with positive patellar ballottement and no knee instability. The HSS score had decreased to 71 points and the WOMAC score was 55 points.

Laboratory examinations

Aspiration of the knee joint yielded 40 mL of dark, bloody fluid (Figure 1). No organisms were isolated, and culture was negative for bacteria over a 72-h period. Culture was sent only once to microbiology because the patient's symptoms were disappeared 10 h after non-surgical treatment was implemented.

Imaging examinations

Radiography showed excellent alignment and no prosthetic loosening (Figures 2A and B). Ultrasonography revealed hydarthrosis of the left knee.

FINAL DIAGNOSIS

The diagnosis of the presented case is hemarthrosis after TKA.

TREATMENT

At the beginning, the patient received non-surgical treatment including compression, cryotherapy and immobilization was. The symptoms resolved 10 h later and he could walk home. But repeated similar episodes occurred in the following 2 mo. The patient was finally diagnosed with recurrent hemarthrosis after TKA. The patient presented to our department for definitive diagnosis and treatment, and arthroscopic exploration was performed. A tourniquet was initially used. After thorough lavage of the joint, there was no visible bleeding (Figure 3A). However, progressive hemorrhage blurred the view soon after releasing the tourniquet, and it was difficult to determine the source of the bleeding (Figure 3B). Therefore, open exploration was performed. Pulsatile bleeding was discovered in the medial sulcus close to the upper pole of the patella (Figure 4). The bleeding artery was about 1–1.5 mm in diameter. According to the anatomy of the knee and the structure of the blood vessel, the bleeding source was identified as the medial superior genicular artery. The artery was ligated with three sutures. There was no sign of bleeding during intraoperative flexion and extension of the knee.

OUTCOME AND FOLLOW-UP

The patient was symptom-free in the 15 mo after surgery. The left knee had a range of motion of 0° extension to 120° flexion, and the standing femorotibial angle was 177°. The HSS score returned to 92 points and the WOMAC score was 5 points in 24 mo after surgery. We also followed up the patient at 48 mo after surgery through video communication since he could not come back to our hospital. At that time, the WOMAC sore remained 5 points and knee function were perfect (Figure 5).

DISCUSSION

More recently, Ravi *et al*^[6] reviewed previous literatures and suggested that the potential causes of recurrent hemarthrosis after TKA varied and involved systemic, local and iatrogenic etiologies. They also described an algorithm for the diagnosis and treatment of recurrent hemarthrosis after TKA. It was reported previously that the blood vessel could be directly injured during procedures such as resection of the proximal tibia or posterior femoral condyles, posterior capsule release, posterior cruciate ligament removal, and screw insertion^[8]. In addition, a low power injury can cause the formation of an arteriovenous fistula, arterial aneurysm, or pseudoaneurysm, creating the potential for future blood vessel rupture^[8-11]. Drexler *et al*^[12] reported an atypical tibial defect in open surgery and biopsy results revealed high-grade epithelioid angiosarcoma, which was treated by amputation above the level of the knee. In addition, hemarthrosis may be caused by anticoagulation medication such as warfarin, aspirin, rivaroxaban, or clopidogrel^[13]. Some rare causes like hemophilia, an inherited disease with a deficiency of factor VIII (hemophilia A) or factor IX (hemophilia B)^[14,15], and PVNS, a proliferative tumor of synovial tissue, may also induce hemarthrosis^[16-18]. Routine blood tests including inflammatory markers and a coagulation profile are essential in cases of swollen and painful knees after TKA^[5]. In 1996, Worland *et al*^[3] emphasized the necessity of aspiration as an important way to differentiate the cause of knee swelling after TKA. Ultrasound can present a luminal turbulence with a “Yin-Yang” sign which can easily detect arterial aneurysms, pseudoaneurysms, and arteriovenous fistulae^[5]. Radiography can

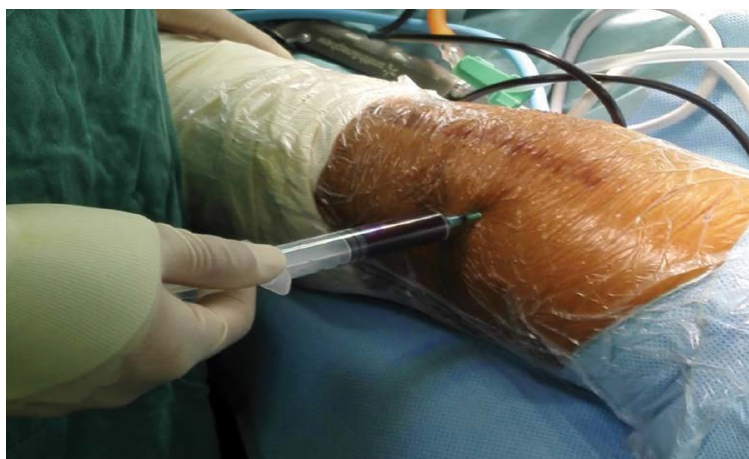


Figure 1 Aspiration of the knee joint resulted in 40 mL of dark, bloody fluid.

evaluate the position of components and determine whether the components are loose. Magnetic resonance imaging is valuable for detecting pathological changes of the synovium^[19]. Angiography is a very useful method for diagnosing and treating recurrent hemarthrosis in both early and late cases. Vascularized synovium could present as a “tumor blush” sign in angiography^[20]. All anticoagulant medication should be stopped after consultation with related experts. Cryotherapy, aspiration, and immobilization can resolve the symptoms and stop the bleeding temporarily or definitively^[4,7]. Although some cases will fail in conservative therapy and require surgical therapy, non-surgical therapy should be given first^[6]. Open surgical repair such as synovectomy is a direct approach to explore the bleeding area and ligate the blood vessel or remove the hypertrophic synovium^[2,3]. However, open surgery is associated with operation-related complications such as iatrogenic injury, more blood loss, and longer rehabilitation. Arthroscopic synovectomy is a minimally invasive approach that allows dissection of hypertrophic synovium with less bleeding and trauma than open surgery. However, arthroscopic synovectomy is not always successful. Suzuki *et al*^[21] reported a case of recurrent hemarthrosis in which the source of bleeding could not be determined in an unclear arthroscopic view, and was treated with open exploration, which was same as in our case. Therefore, angiographic embolization has been regarded as a more optimal choice in cases of vascular injury and of synovial impingement. Compared with open exploration and arthroscopic surgery, angiographic treatment is a less invasive therapy with lower risk of complications and easier rehabilitation^[19,20]. In the present case, the patient did not undergo angiography, and the cause of the bleeding could not be determined preoperatively. In fact, the source of bleeding was suspected to be synovium impingement according to recently reported cases^[5,7], and the ultrasound examination. However, open exploration revealed a bleeding artery, which strongly suggested that the cause of hemarthrosis was rupture of a pseudoaneurysm of the medial superior genicular artery. Arthroscopy was initially performed and was found to be inadequate compared with angiography. A clear scope is essential to determine the source of bleeding, unfortunately, it was difficult to visualize the effusion or jet point before the view became bloody.

CONCLUSION

The present case indicated the following perspectives. Firstly, angiography is essential in cases of hemarthrosis after TKA. Secondly, arthroscopy may not always be adequate as it may not provide a clear view. Lastly, traditional open exploration is still effective and sometimes necessary.

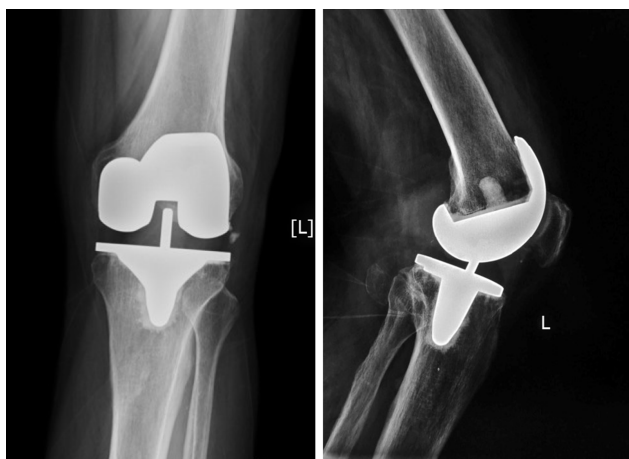

Figure 2 Radiography showed excellent alignment and no prosthetic loosening.

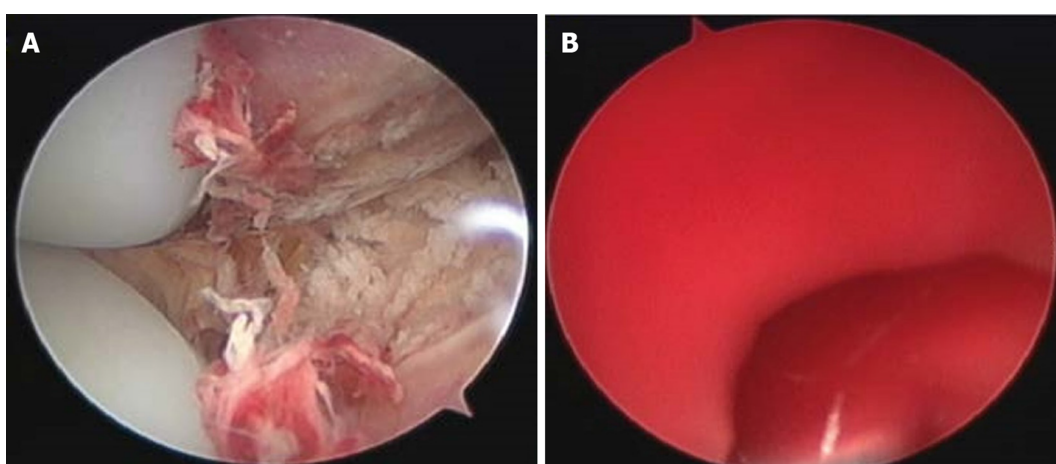


Figure 3 Arthroscopic explorations. A: After thorough lavage of the joint, there was no visible bleeding; B: It was difficult to determine the source of the bleeding after releasing the tourniquet.

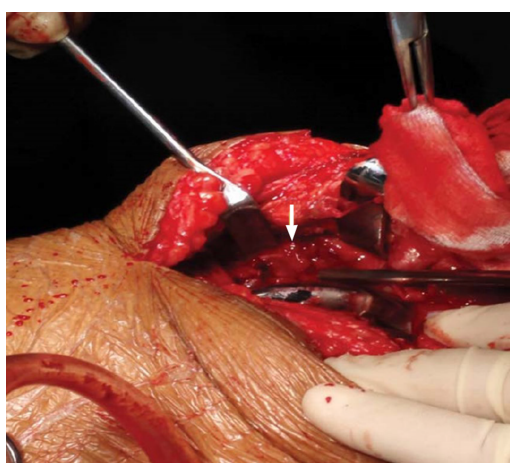


Figure 4 Pulsatile bleeding was discovered in the medial sulcus close to the upper pole of the patella.

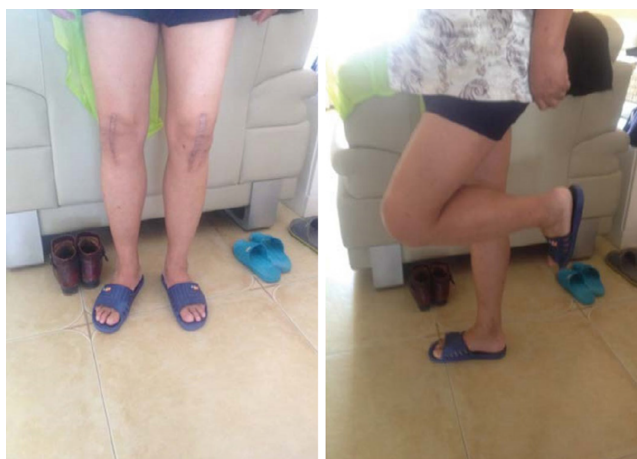

Figure 5 The Western Ontario and McMaster Universities Osteoarthritis Index score was 5 points and knee function was perfect.

REFERENCES

- 1 **Insall J**, Scott WN, Ranawat CS. The total condylar knee prosthesis. A report of two hundred and twenty cases. *J Bone Joint Surg Am* 1979; **61**: 173-180 [PMID: [422602](#) DOI: [10.2106/00004623-197961020-00003](#)]
- 2 **Oishi CS**, Elliott ML, Colwell CW. Recurrent hemarthrosis following a total knee arthroplasty. *J Arthroplasty* 1995; **10** Suppl: S56-S58 [PMID: [8776057](#) DOI: [10.1016/s0883-5403\(05\)80232-3](#)]
- 3 **Worland RL**, Jessup DE. Recurrent hemarthrosis after total knee arthroplasty. *J Arthroplasty* 1996; **11**: 977-978 [PMID: [8986579](#) DOI: [10.1016/S0883-5403\(96\)80144-6](#)]
- 4 **Ohdera T**, Tokunaga M, Hiroshima S, Yoshimoto E, Matsuda S. Recurrent hemarthrosis after knee joint arthroplasty: etiology and treatment. *J Arthroplasty* 2004; **19**: 157-161 [PMID: [14973857](#) DOI: [10.1016/j.arth.2003.09.009](#)]
- 5 **Saksena J**, Platts AD, Dowd GS. Recurrent haemarthrosis following total knee replacement. *Knee* 2010; **17**: 7-14 [PMID: [19616438](#) DOI: [10.1016/j.knee.2009.06.008](#)]
- 6 **Ravi B**, Hosack L, Backstein D, Spangehl M. Recurrent Hemarthrosis After Total Knee Arthroplasty: Evaluation and Treatment. *J Am Acad Orthop Surg* 2019; **27**: 652-658 [PMID: [30720569](#) DOI: [10.5435/JAAOS-D-18-00182](#)]
- 7 **Kindsfater K**, Scott R. Recurrent hemarthrosis after total knee arthroplasty. *J Arthroplasty* 1995; **10** Suppl: S52-S55 [PMID: [8776056](#) DOI: [10.1016/s0883-5403\(05\)80231-1](#)]
- 8 **Ibrahim M**, Booth RE, Clark TW. Embolization of traumatic pseudoaneurysms after total knee arthroplasty. *J Arthroplasty* 2004; **19**: 123-128 [PMID: [14716660](#) DOI: [10.1016/j.arth.2003.08.007](#)]
- 9 **Sharma H**, Singh GK, Cavanagh SP, Kay D. Pseudoaneurysm of the inferior medial geniculate artery following primary total knee arthroplasty: delayed presentation with recurrent haemorrhagic episodes. *Knee Surg Sports Traumatol Arthrosc* 2006; **14**: 153-155 [PMID: [16028055](#) DOI: [10.1007/s00167-005-0639-4](#)]
- 10 **Cunningham RB**, Mariani EM. Spontaneous hemarthrosis 6 years after total knee arthroplasty. *J Arthroplasty* 2001; **16**: 133-135 [PMID: [11172285](#) DOI: [10.1054/arth.2001.9050](#)]
- 11 **Huang CH**, Ho FY, Cheng CT, Ma HM. Hemarthrosis associated with failure of a mobile meniscal-bearing total knee arthroplasty. A case report. *J Bone Joint Surg Am* 2003; **85**: 2445-2448 [PMID: [14668519](#) DOI: [10.2106/00004623-200312000-00027](#)]
- 12 **Drexler M**, Dolkart O, Amar E, Pritsch T, Dekel S. Late recurrent hemarthrosis following knee arthroplasty associated with epithelioid angiosarcoma of bone. *Knee* 2010; **17**: 365-367 [PMID: [19945286](#) DOI: [10.1016/j.knee.2009.10.010](#)]
- 13 **Takezawa Y**, Arai Y, Fujita S, Yamagami T, Tanaka O, Kubo T. A case of selective arterial embolization for recurrent hemarthrosis after total knee arthroplasty. *J Orthop Sci* 2013; **18**: 679-682 [PMID: [22237971](#) DOI: [10.1007/s00776-011-0192-6](#)]
- 14 **Silva M**, Luck JV. Radial head excision and synovectomy in patients with hemophilia. Surgical technique. *J Bone Joint Surg Am* 2008; **90** Suppl 2 Pt 2: 254-261 [PMID: [18829938](#) DOI: [10.2106/JBJS.H.00577](#)]
- 15 **Chin KR**, Barr SJ, Winalski C, Zurakowski D, Brick GW. Treatment of advanced primary and recurrent diffuse pigmented villonodular synovitis of the knee. *J Bone Joint Surg Am* 2002; **84**: 2192-2202 [PMID: [12473708](#) DOI: [10.2106/00004623-200212000-00011](#)]
- 16 **Hamlin BR**, Duffy GP, Trousdale RT, Morrey BF. Total knee arthroplasty in patients who have pigmented villonodular synovitis. *J Bone Joint Surg Am* 1998; **80**: 76-82 [PMID: [9469312](#) DOI: [10.2106/00004623-199801000-00013](#)]
- 17 **Rukavina A**, Kerkhoffs GM, Schneider P, Kuster MS. Recurrent hemarthrosis after total knee arthroplasty. *Knee Surg Sports Traumatol Arthrosc* 2010; **18**: 898-900 [PMID: [20076944](#) DOI: [10.1007/s00167-009-1031-6](#)]
- 18 **Weidner ZD**, Hamilton WG, Smirniotopoulos J, Bagla S. Recurrent Hemarthrosis Following Knee Arthroplasty Treated with Arterial Embolization. *J Arthroplasty* 2015; **30**: 2004-2007 [PMID: [26092252](#) DOI: [10.1016/j.arth.2015.05.028](#)]
- 19 **Bagla S**, Rholl KS, van Breda A, Sterling KM, van Breda A. Geniculate artery embolization in the management of spontaneous recurrent hemarthrosis of the knee: case series. *J Vasc Interv Radiol* 2013; **24**: 439-442 [PMID: [23433418](#) DOI: [10.1016/j.jvir.2012.11.011](#)]
- 20 **Karataglis D**, Marlow D, Learmonth DJ. Atraumatic haemarthrosis following total knee replacement treated with selective embolisation. *Acta Orthop Belg* 2006; **72**: 375-377 [PMID: [16889156](#)]

- 21 **Suzuki M**, Kakizaki J, Tsukeoka T, Tsuneizumi Y, Miyagi J, Moriya H. A case of spontaneous hemoarthrosis after a total knee arthroplasty. *Mod Rheumatol* 2006; **16**: 248-250 [PMID: [16906377](#) DOI: [10.1007/s10165-006-0489-z](#)]



Published by Baishideng Publishing Group Inc
7041 Koll Center Parkway, Suite 160, Pleasanton, CA 94566, USA
Telephone: +1-925-3991568
E-mail: bpgoffice@wjgnet.com
Help Desk: <https://www.f6publishing.com/helpdesk>
<https://www.wjgnet.com>

