

# World Journal of *Clinical Cases*

*World J Clin Cases* 2020 May 26; 8(10): 1756-2065



**GUIDELINES**

- 1756** French Spine Surgery Society guidelines for management of spinal surgeries during COVID-19 pandemic  
*Prost S, Charles YP, Allain J, Barat JL, d'Astorg H, Delhaye M, Eap C, Zairi F, Guigui P, Ilharreborde B, Meyblum J, Le Huec JC, Lonjon N, Lot G, Hamel O, Riouallon G, Litrico S, Tropiano P, Blondel B, the French Spine Surgery Society*

**OPINION REVIEW**

- 1763** Needs and concerns of patients in isolation care units - learnings from COVID-19: A reflection  
*Fan PEM, Aloweni F, Lim SH, Ang SY, Perera K, Quek AH, Quek HKS, Ayre TC*

**REVIEW**

- 1767** Prophylactic and therapeutic roles of oleanolic acid and its derivatives in several diseases  
*Sen A*
- 1793** Macrophage regulation of graft-vs-host disease  
*Hong YQ, Wan B, Li XF*

**MINIREVIEWS**

- 1806** Antiphospholipid syndrome and its role in pediatric cerebrovascular diseases: A literature review  
*Sarecka-Hujar B, Kopyta I*
- 1818** Remotely monitored telerehabilitation for cardiac patients: A review of the current situation  
*Batalik L, Filakova K, Batalikova K, Dosbaba F*
- 1832** Keystone design perforator island flap in facial defect reconstruction  
*Lim SY, Yoon CS, Lee HG, Kim KN*

**ORIGINAL ARTICLE****Clinical and Translational Research**

- 1848** Cross electro-nape-acupuncture ameliorates cerebral hemorrhage-induced brain damage by inhibiting necroptosis  
*Cai GF, Sun ZR, Zhuang Z, Zhou HC, Gao S, Liu K, Shang LL, Jia KP, Wang XZ, Zhao H, Cai GL, Song WL, Xu SN*

**Retrospective Study**

- 1859** Evaluation of ischemic lesions after carotid artery stenting with diffusion-weighted imaging  
*Beyhan M, Acu B, Gökçe E, Fırat MM*
- 1871** Transjugular intrahepatic portosystemic shunt and splenectomy are more effective than endoscopic therapy for recurrent variceal bleeding in patients with idiopathic noncirrhotic portal hypertension  
*He FL, Qi RZ, Zhang YN, Zhang K, Zhu-Ge YZ, Wang M, Wang Y, Jia JD, Liu FQ*

- 1878** Liglipatin for treatment of type 2 diabetes mellitus with early renal injury: Efficacy and impact on endogenous hydrogen sulfide and endothelial function  
*Zhang J, Du YL, Zhang H, Sui H, Hou WK*
- 1887** Outcomes of patients with pelvic leiomyosarcoma treated by surgery and relevant auxiliary diagnosis  
*Sun Q, Yang X, Zeng Z, Wei X, Li KZ, Xu XY*
- 1897** Defecation function and quality of life in patients with slow-transit constipation after colectomy  
*Tian Y, Wang L, Ye JW, Zhang Y, Zheng HC, Shen HD, Li F, Liu BH, Tong WD*
- 1908** Risk factors, incidence, and morbidity associated with antibiotic-associated diarrhea in intensive care unit patients receiving antibiotic monotherapy  
*Zhou H, Xu Q, Liu Y, Guo LT*
- Observational Study**
- 1916** Serum von Willebrand factor for early diagnosis of lung adenocarcinoma in patients with type 2 diabetes mellitus  
*Zhou YY, Du X, Tang JL, Wang QP, Chen K, Shi BM*
- 1923** Four-microRNA signature for detection of type 2 diabetes  
*Yan LN, Zhang X, Xu F, Fan YY, Ge B, Guo H, Li ZL*

**CASE REPORT**

- 1932** Isolated colonic neurofibroma, a rare tumor: A case report and review of literature  
*Ghoneim S, Sandhu S, Sandhu D*
- 1939** Helmet-based noninvasive ventilation for acute exacerbation of chronic obstructive pulmonary disease: A case report  
*Park MH, Kim MJ, Kim AJ, Lee MJ, Kim JS*
- 1944** Appendectomy in patient with suspected COVID-19 with negative COVID-19 results: A case report  
*Kim C, Kim JK, Yeo IH, Choe JY, Lee JE, Kang SJ, Park CS, Kwon KT, Hwang S*
- 1950** T4 cervical esophageal cancer cured with modern chemoradiotherapy: A case report  
*Lee CC, Yeo CM, Ng WK, Verma A, Tey JC*
- 1958** Lumbar disc rehydration in the bridged segment using the BioFlex dynamic stabilization system: A case report and literature review  
*Li YC, Feng XF, Pang XD, Tan J, Peng BG*
- 1966** Traditional investigation and management for recurrent hemarthrosis after total knee arthroplasty: A case report  
*Geng X, Li Y, He X, Tian H*

- 1973** Positron emission tomography/computed tomography findings of multiple cystic lymphangiomas in an adult: A case report  
*Sun MM, Shen J*
- 1979** Heterotopic pancreas adenocarcinoma in the stomach: A case report and literature review  
*Xiong Y, Xie Y, Jin DD, Wang XY*
- 1988** Early-onset refractory diarrhea due to immune dysregulation, polyendocrinopathy, enteropathy, X-linked syndrome associated with a novel mutation in the *FOXP3* gene: A case report  
*Su N, Chen C, Zhou X, Ma GD, Chen RL, Tian C*
- 1995** Tuberous sclerosis complex presenting as primary intestinal lymphangiectasia: A case report  
*Lin WH, Zhang ZH, Wang HL, Ren L, Geng LL*
- 2001** Gilbert's syndrome coexisting with hereditary spherocytosis might not be rare: Six case reports  
*Kang LL, Liu ZL, Zhang HD*
- 2009** Effective combined therapy for pulmonary epithelioid hemangioendothelioma: A case report  
*Zhang XQ, Chen H, Song S, Qin Y, Cai LM, Zhang F*
- 2016** Unexplained huge liver infarction presenting as a tumor with bleeding: A case report  
*Wang FH, Yang NN, Liu F, Tian H*
- 2023** Rare recurrent gallstone ileus: A case report  
*Jiang H, Jin C, Mo JG, Wang LZ, Ma L, Wang KP*
- 2028** Treating severe periodontitis with staged load applied implant restoration: A case report  
*Wang SH, Ni WC, Wang RF*
- 2038** Cryptococcal pneumonia in a human immunodeficiency virus-negative patient: A case report  
*Jiang XQ, Zhang YB*
- 2044** Ileocecal intussusception caused by two different tumors - which is the culprit lesion? A case report  
*Fan WF, Ma G, Li GC, Long J, Xu YH, Guo KJ, Liu Z*
- 2050** Robot-assisted retroperitoneal laparoscopic excision of perirenal vascular tumor: A case report  
*Zhang C, Fu B, Xu S, Zhou XC, Cheng XF, Fu WQ, Wang GX*
- 2056** Successful use of plasma exchange in fulminant lupus myocarditis coexisting with pneumonia: A case report  
*Xing ZX, Yu K, Yang H, Liu GY, Chen N, Wang Y, Chen M*



**ABOUT COVER**

Editorial Board Member of *World Journal of Clinical Cases*, Preet M Chaudhary, MD, PhD, Professor, Department of Medicine, Jane Anne Nohl Division of Hematology and Center for the Study of Blood Diseases, University of Southern California, Los Angeles, CA 90033, United States

**AIMS AND SCOPE**

The primary aim of *World Journal of Clinical Cases* (WJCC, *World J Clin Cases*) is to provide scholars and readers from various fields of clinical medicine with a platform to publish high-quality clinical research articles and communicate their research findings online.

WJCC mainly publishes articles reporting research results and findings obtained in the field of clinical medicine and covering a wide range of topics, including case control studies, retrospective cohort studies, retrospective studies, clinical trials studies, observational studies, prospective studies, randomized controlled trials, randomized clinical trials, systematic reviews, meta-analysis, and case reports.

**INDEXING/ABSTRACTING**

The WJCC is now indexed in PubMed, PubMed Central, Science Citation Index Expanded (also known as SciSearch®), and Journal Citation Reports/Science Edition. The 2019 Edition of Journal Citation Reports cites the 2018 impact factor for WJCC as 1.153 (5-year impact factor: N/A), ranking WJCC as 99 among 160 journals in Medicine, General and Internal (quartile in category Q3).

**RESPONSIBLE EDITORS FOR THIS ISSUE**

Responsible Electronic Editor: Ji-Hong Liu

Proofing Production Department Director: Xiang Li

Responsible Editorial Office Director: Jin-Lai Wang

**NAME OF JOURNAL**

*World Journal of Clinical Cases*

**ISSN**

ISSN 2307-8960 (online)

**LAUNCH DATE**

April 16, 2013

**FREQUENCY**

Semimonthly

**EDITORS-IN-CHIEF**

Dennis A Bloomfield, Bao-Gan Peng, Sandro Vento

**EDITORIAL BOARD MEMBERS**

<https://www.wjgnet.com/2307-8960/editorialboard.htm>

**PUBLICATION DATE**

May 26, 2020

**COPYRIGHT**

© 2020 Baishideng Publishing Group Inc

**INSTRUCTIONS TO AUTHORS**

<https://www.wjgnet.com/bpg/gerinfo/204>

**GUIDELINES FOR ETHICS DOCUMENTS**

<https://www.wjgnet.com/bpg/GerInfo/287>

**GUIDELINES FOR NON-NATIVE SPEAKERS OF ENGLISH**

<https://www.wjgnet.com/bpg/gerinfo/240>

**PUBLICATION ETHICS**

<https://www.wjgnet.com/bpg/GerInfo/288>

**PUBLICATION MISCONDUCT**

<https://www.wjgnet.com/bpg/gerinfo/208>

**ARTICLE PROCESSING CHARGE**

<https://www.wjgnet.com/bpg/gerinfo/242>

**STEPS FOR SUBMITTING MANUSCRIPTS**

<https://www.wjgnet.com/bpg/GerInfo/239>

**ONLINE SUBMISSION**

<https://www.f6publishing.com>

# Early-onset refractory diarrhea due to immune dysregulation, polyendocrinopathy, enteropathy, X-linked syndrome associated with a novel mutation in the *FOXP3* gene: A case report

Na Su, Cheng Chen, Xia Zhou, Guo-Da Ma, Ri-Ling Chen, Chuan Tian

**ORCID number:** Na Su (0000-0002-3824-345X); Cheng Chen (0000-0003-4676-2919); Xia Zhou (0000-0003-3798-4552); Guo-Da Ma (0000-0001-8962-6007); Ri-Ling Chen (0000-0001-5988-032X); Chuan Tian (0000-0002-0635-8666).

**Author contributions:** Su N, Ma GD, and Zhou X reviewed the literature, contributed to drafting of the manuscript, and prepared the figures and table; Chen C, Chen RL, and Tian C discussed the diagnosis and treatment; all authors issued final approval for the version to be submitted.

**Informed consent statement:** Informed written consent was obtained from the patient for publication of this report and any accompanying images.

**Conflict-of-interest statement:** The authors declare that they have no conflict of interest.

**CARE Checklist (2016) statement:** The authors have read the CARE Checklist (2016), and the manuscript was prepared and revised according to the CARE Checklist (2016).

**Open-Access:** This article is an open-access article that was selected by an in-house editor and fully peer-reviewed by external reviewers. It is distributed in accordance with the Creative Commons Attribution NonCommercial (CC BY-NC 4.0) license, which permits others to distribute, remix, adapt, build upon this work non-commercially,

**Na Su,** Department of Pediatrics, Shunde Women and Children's Hospital, Guangdong Medical University, Foshan 528300, Guangdong Province, China

**Na Su,** Department of Pediatrics, Guangdong Medical University, Zhanjiang 524000, Guangdong Province, China

**Cheng Chen, Ri-Ling Chen,** Department of Pediatric Internal Medicine, Shunde Women and Children's Hospital, Guangdong Medical University, Foshan 528300, Guangdong Province, China

**Xia Zhou,** Department of Neurology, Guangdong Medical University, Zhanjiang 524000, Guangdong Province, China

**Guo-Da Ma,** Maternal and Child Research Institute, Shunde Women and Children's Hospital, Guangdong Medical University, Foshan 528300, Guangdong Province, China

**Chuan Tian,** Department of Pediatric Hematology, Affiliated Hospital of Guangdong Medical University, Zhanjiang 524000, Guangdong Province, China

**Corresponding author:** Ri-Ling Chen, MD, Professor, Department of Pediatric Internal Medicine, Shunde Women and Children's Hospital, Guangdong Medical University, No. 3, Baojian Road, Foshan 528300, Guangdong Province, China. [chenrl319@163.com](mailto:chenrl319@163.com)

## Abstract

### BACKGROUND

Immune dysregulation, polyendocrinopathy, enteropathy, X-linked (IPEX) syndrome is a rare X-linked recessive disease caused by mutations in the forkhead box protein 3 (*FOXP3*) gene, which is a master transcriptional regulator for the development and function of CD4<sup>+</sup>CD25<sup>+</sup> regulatory T (Treg) cells. The dysfunction of these cells leads to multiple system autoimmune diseases. We present a case of IPEX due to a mutation not reported in the literature before.

### CASE SUMMARY

We report a male patient with IPEX syndrome who presented with refractory diarrhea and malabsorption leading to failure to thrive, as well as with hypothyroidism and nephrotic syndrome. Laboratory investigation showed increased total IgE and Treg cells, decreased free triiodothyronine (FT3) and free thyroxine (FT4), and proteinuria. Multiple dietary and supportive treatments were introduced but did not improve the diarrhea during his hospital stay. Ultimately, whole exome sequencing revealed that the patient was hemizygous

and license their derivative works on different terms, provided the original work is properly cited and the use is non-commercial. See:

<http://creativecommons.org/licenses/by-nc/4.0/>

**Manuscript source:** Unsolicited manuscript

**Received:** January 16, 2020

**Peer-review started:** January 16, 2020

**First decision:** March 5, 2020

**Revised:** April 1, 2020

**Accepted:** April 21, 2020

**Article in press:** April 21, 2020

**Published online:** May 26, 2020

**P-Reviewer:** Ishizawa K

**S-Editor:** Ma YJ

**L-Editor:** Wang TQ

**E-Editor:** Xing YX



for the exon 5, c.542G>A (p.Ser181Asn) mutation of the *FOXP3* gene, which has not been previously reported. The patient remains on prednisone and euthyrox while awaiting hematopoietic stem cell transplantation at the time of the compilation of this case report.

## CONCLUSION

We report a novel *FOXP3* gene mutation involved in IPEX. A high level of suspicion should be maintained in an early-onset refractory diarrhea patient.

**Key words:** Immune dysregulation, polyendocrinopathy, enteropathy, X-linked syndrome; Forkhead box protein 3; Mutation; Refractory diarrhea; Regulatory T cells; Case report

©The Author(s) 2020. Published by Baishideng Publishing Group Inc. All rights reserved.

**Core tip:** Immune dysregulation, polyendocrinopathy, enteropathy, X-linked syndrome is a rare X-linked recessive disease caused by mutations in the *FOXP3* gene. Patients most commonly present symptoms with refractory diarrhea, type 1 diabetes mellitus, eczema, and rarely, symptoms of nephrotic syndrome, hypothyroidism, and thrombocytopenia. Herein, we present a patient with refractory diarrhea, failure to thrive, hypothyroidism, and nephrotic syndrome who was subsequently found to have a novel mutation in the *FOXP3* gene [c.542G>A (p.Ser181Asn)]. Patients with immune dysregulation, polyendocrinopathy, enteropathy, X-linked generally require supportive treatments and replacement therapy, such as steroids, immunosuppressors, or hematopoietic stem cell transplantation.

**Citation:** Su N, Chen C, Zhou X, Ma GD, Chen RL, Tian C. Early-onset refractory diarrhea due to immune dysregulation, polyendocrinopathy, enteropathy, X-linked syndrome associated with a novel mutation in the *FOXP3* gene: A case report. *World J Clin Cases* 2020; 8(10): 1988-1994

**URL:** <https://www.wjgnet.com/2307-8960/full/v8/i10/1988.htm>

**DOI:** <https://dx.doi.org/10.12998/wjcc.v8.i10.1988>

## INTRODUCTION

Immune dysregulation, polyendocrinopathy, enteropathy, X-linked (IPEX) syndrome is a rare disorder of genetic autoimmunity caused by mutations in the forkhead box protein 3 (*FOXP3*) gene<sup>[1]</sup>. *FOXP3* is an important transcription regulator in the development of CD4<sup>+</sup>CD25<sup>+</sup> regulatory T (Treg) cells. *FOXP3* gene mutations lead to developmental defects, differentiation disorders, and dysfunction of Tregs, which lead to serious autoimmune phenomena in multiple systems<sup>[2]</sup>. The disease mainly influences the intestine, endocrine system, and skin<sup>[2]</sup>, whereas the thyroid glands, kidneys, blood cells, liver, and joints may also be influenced<sup>[3]</sup>. IPEX is an X-linked recessive disorder, and patients who have not been treated effectively in the early stage mostly die within 2 years of age<sup>[4]</sup>. The main treatment measures for patients with IPEX include supportive care, immunosuppressive treatments, and hematopoietic stem cell transplantation. The clinical manifestations of the disease were first reported in 1982 by Powell *et al*<sup>[5]</sup>, and an increasing number of cases were subsequently reported. Here, we report a male patient with IPEX syndrome who had refractory diarrhea, failure to thrive, hypothyroidism, and nephrotic syndrome and who was hemizygous in the *FOXP3* gene [c.542G>A (p.Ser181Asn)].

## CASE PRESENTATION

### Chief complaints

A 13-month-old male patient was admitted to the hospital in June 2019 due to chronic diarrhea and malnutrition.

### History of present illness

The patient's symptoms started a year ago with recurrent diarrhea and malnutrition. His diarrhea had been worsened the last 4 h (10 watery bowel movements).

### Personal and family history

The patient is the second live-born child of nonconsanguineous and healthy parents (Figure 1) and was born at 35 wk of gestation by spontaneous vaginal delivery. The newborn had a birth weight of 2.15 kg and was hospitalized as a premature infant. The family history was negative for inherent diseases.

### History of past illness

At the age of 1 mo, the patient had refractory diarrhea (up to 10–15 watery bowel movements per day) and scattered eczema. Therefore, he was hospitalized on several occasions at a local hospital and given hydrolyzing protein formula milk and supportive care to improve gastrointestinal symptoms. The eczema gradually disappeared in May after birth, but diarrhea did not significantly improve.

### Physical examination

Upon admission to the hospital, the patient had a weight of 6.4 kg, head circumference of 40.5 cm, and length 70 cm, failure to thrive, and moderate-severe dehydration. Abdominal subcutaneous fat thickness was less than 4 mm, and bowel sounds were active, approximately 7 per minute.

### Laboratory examinations

The laboratory results showed a normal eosinophil count and hemoglobin concentration; a high white blood cell count ( $23.25 \times 10^9/L$ ); normal immunoglobulin A, IgG, and IgM levels but markedly elevated IgE levels (1970 IU/mL); high triglyceride (3.74 mmol/L); and decreased complement C3 (0.25 g/L), complement C4 (0.1 g/L), and albumin (29.1 g/L). The endocrine test showed normal antithyroid peroxidase (aTPO), antithyroglobulin (aTG), and thyroid stimulating hormone (TSH), and high free triiodothyronine (FT3, 2.20 pmol/L) and free thyroxine (FT4, 10.49 pmol/L) (Table 1). Multiple urinalyses indicated proteinuria (+ to +++). Multiple stool analyses were unremarkable. The patient was allergic to eggs, peanuts, and milk. Endoscopy (gastroscope and colonoscopy) found duodenal anterior wall erosion, and the immunohistochemical staining for cytomegalovirus (CMV) and *in situ* hybridization for EBV-encoded small RNA (EBER) were negative. Flow cytometry showed a slightly higher proportion of CD25<sup>+</sup>FOXP3<sup>+</sup> Tregs in CD4<sup>+</sup> T cells (13.0%) (Figure 2).

### Further diagnostic work-up

The patient had early refractory diarrhea, malabsorption, high immunoglobulin E, hypothyroidism, and nephrotic syndrome. The diagnosis of IPEX was confirmed by whole exome sequencing, which revealed a pathogenic site in exon 5, c.542G>A (p.Ser181Asn) mutation of the *FOXP3* gene. Subsequently, the same heterozygous mutation was found in the mother, who was a carrier, but his father and older brother were normal (Figure 3). The family pedigree of the patient is shown in Figure 1.

## FINAL DIAGNOSIS

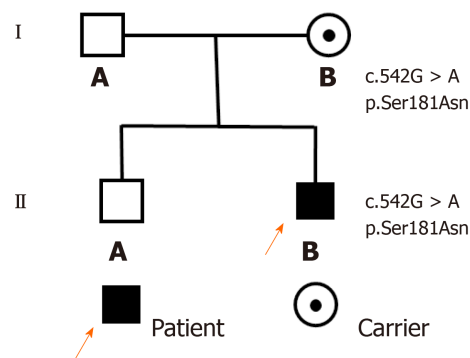
The final diagnosis of the presented case was IPEX syndrome, hypothyroidism, and nephrotic syndrome.

## TREATMENT

The patient was initially diagnosed with refractory diarrhea, malabsorption, hypothyroidism, and nephrotic syndrome. He was treated with anti-infection medications, total parenteral nutrition, prednisone (5 mg/d), and euthyrox (37.5 µg/d). After 10 d of this treatment, he had 4–6 watery bowel movements per day but was not significantly gaining weight. Subsequently, the diagnosis of IPEX was confirmed by whole exome sequencing, and a scheduled immunosuppressor treatment was started. However, the family thought that these drugs had severe side effects and refused this type of treatment. Therefore, the patient was treated with prednisone, euthyrox, and other supportive cares.

## OUTCOME AND FOLLOW-UP

Since the diagnosis of IPEX syndrome, the patient has been regularly treated with prednisone and euthyrox. Instead of getting better, his condition is slightly worse. He



**Figure 1 Family pedigree.** The black square and arrow indicate the patient, the point inside the circle indicates a heterozygous carrier of the gene, and white squares represent normal members in the family.

was hospitalized for refractory diarrhea (up to 15-20 watery bowel movements per day) and anasarca, and was discharged after correction of electrolyte disorder and dehydration therapy. At present, he is awaiting hematopoietic stem cell transplantation.

## DISCUSSION

The typical symptoms of IPEX syndrome present as early refractory diarrhea, type 1 diabetes mellitus, and eczema<sup>[2]</sup>. The enteropathy of IPEX syndrome is present in virtually all affected individuals. The main manifestation of the patients was watery diarrhea and sometimes mucoid or bloody diarrhea<sup>[2]</sup>. Dermatitis is most frequently eczematous<sup>[6]</sup> and can also be psoriasiform<sup>[7]</sup> and ichthyosiform<sup>[8]</sup>. Endocrine diseases are common in type 1 diabetes mellitus, most of which are newborn<sup>[9]</sup>, but hypothyroidism has also been reported<sup>[3]</sup>. Rare symptoms such as thrombocytopenia, hepatitis, pneumonia, and nephrotic syndrome have also been reported<sup>[3,10]</sup>. In this report, we present an early-onset IPEX syndrome case with chronic diarrhea as the first symptom at the age of 1 mo, as well as hypothyroidism and nephrotic syndrome. The patient received anti-infection therapy, total parenteral nutrition, and other supportive care more than five times after admission in 1 year. However, diarrhea was not well controlled. Finally, the patient was diagnosed with IPEX syndrome associated with a novel *FOXP3* gene mutation [c.542G>A (p.Ser181Asn)] by whole exome sequencing.

The human *FOXP3* gene is located on the X chromosome (Xq11.23-Xq13.3) and consists of 11 coding exons plus one upstream non-coding exon<sup>[11]</sup>. The gene encodes a protein of 431 amino acids, which contains a repressor domain, a zinc-finger (ZF) domain, a leucine zipper (LZ) domain, and a forkhead (FKH) domain (Figure 4). Ziegler *et al*<sup>[12]</sup> found that there were two functional domains within the N-terminal of *FOXP3*, one between amino acids 67 and 132 and the other between amino acids 135 and 198, which are functional as transcriptional repressors; the latter is especially required for inhibition of nuclear factor of activated T cells (NFAT)-mediated transcription. NFAT is an important transcription factor of cytokine gene expression. In the promoters of cytokine genes, it was found that the NFAT site potentially overlapped or was adjacent to the FKH-binding site<sup>[12]</sup>. Therefore, *FOXP3* may play an immunosuppressive function by competing for the DNA-binding sites of NFAT or directly inhibiting the negative feedback of NFAT activity to regulate the expression of cytokine genes<sup>[13,14]</sup>. Therefore, this mutation leads to impaired NFAT transcriptional regulatory activity by altering the binding sites to DNA or inhibiting cytokine gene expression and eventually is responsible for this disease.

The *FOXP3* gene is a master regulator of Tregs<sup>[2]</sup>. If *FOXP3* mutation leads to this protein being functionally defective, it is unable to sustain Treg development<sup>[15]</sup>. Therefore, most IPEX patients had decreased percentages of CD25<sup>+</sup>*FOXP3*<sup>+</sup> Tregs in CD4<sup>+</sup> T cells. However, the patient had increased percentages in this study. In previous reports, in addition to the natural Treg cells in the thymus, peripheral CD4<sup>+</sup>CD25<sup>+</sup> cells can also develop into Tregs with inhibitory function by stimulation of anti-CD3 and anti-CD28<sup>[16]</sup> or by retroviral vector or transgene expression. Bacchetta *et al*<sup>[17]</sup> found that the ratio of CD4<sup>+</sup>CD25<sup>+</sup> Tregs in peripheral blood mononuclear cells (PBMCs) can appear normal, but their capacity to suppress was impaired, which indicates that the *Foxp3* mutation could not affect Treg development but affected

**Table 1** Hematologic and immunologic data of the immune dysregulation, polyendocrinopathy, enteropathy, X-linked patient

Blood index	Admission	Reference range
WBC ( $\times 10^9/L$ )	23.25	3.5-9.5
Eosinophils ( $\times 10^9/L$ )	0.13	0.02-0.52
HGB (g/L)	112	110-160
ALB (g/L)	29.1	40-55
IgA (g/L)	0.61	0.14-1.14
IgG (g/L)	9.12	3.82-10.58
IgM (g/L)	0.67	0.4-1.28
IgE (IU/mL)	1.970	0-60
Triglyceride (mmol/L)	3.74	0.56-1.70
Complement C3 (g/L)	0.25	0.8-1.5
Complement C4 (g/L)	0.1	0.12-0.4
TSH (mIU/L)	0.931	0.38-7.31
FT3 (pmol/L)	2.20	4.1-7.42
FT4 (pmol/L)	10.49	14.45-22.74
aTPO (U/mL)	30.90	< 60
aTG (U/mL)	20.50	< 60

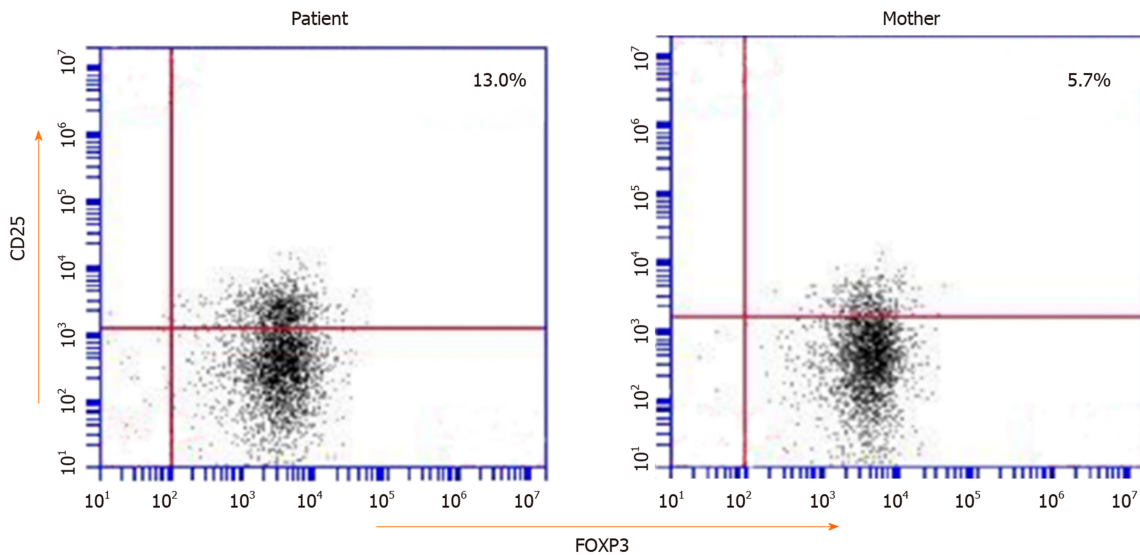
Abnormal values are shown in bold. WBC: White blood cells; HGB: Hemoglobin concentration; ALB: Albumin; TSH: Thyroid-stimulating hormone; FT3: Free triiodothyronine; FT4: Free thyroxine; aTPO: Antithyroid peroxidase; aTG: Antithyroglobulin.

suppression function. Therefore, the function of *FOXP3* is not restricted to Tregs but it could also play a role outside the Treg subset. It has been reported in the literature that the percentage of CD4<sup>+</sup>CD25<sup>+</sup> FOXP3<sup>+</sup> Tregs in CD4<sup>+</sup> T cells or the percentage of FOXP3 expressing CD4<sup>+</sup> cells in children with IPEX is high (for example, mutation sites were p.M370I<sup>[18]</sup>, p.E323K<sup>[19]</sup>, and p.S390N<sup>[19]</sup>). Therefore, we speculate that the high ratio of CD25<sup>+</sup> Tregs in our patient may be related to other regulatory factors.

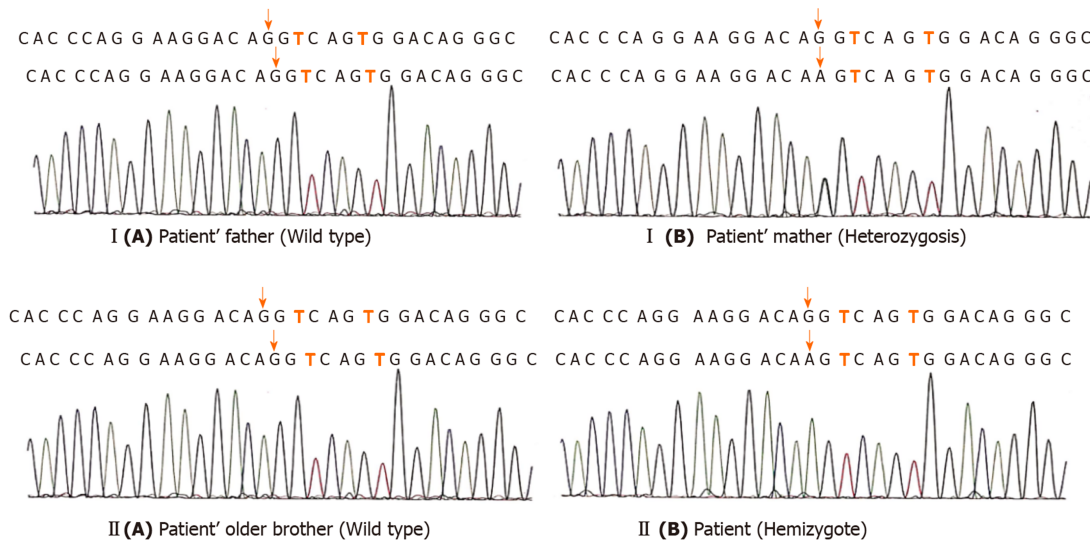
## CONCLUSION

IPEX is a rare X-linked recessive disease with multiple system involvement, especially enteropathy and refractory diarrhea, caused by mutations in the *FOXP3* gene. The onset of symptoms is as early as the first few months of life, and patients usually require supportive and alternative treatments. In the differential diagnosis of any patient with unexplained and intractable diarrhea, the disease should be considered and eventually confirmed by gene testing.

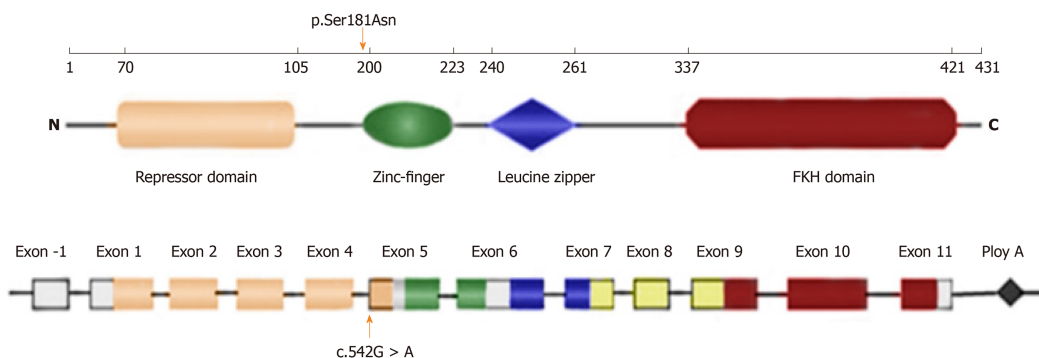




**Figure 2** Flow cytometry showing CD25<sup>+</sup>FOXP3<sup>+</sup> regulatory cells in the CD4<sup>+</sup>T cell population in peripheral blood. The red number in each quadrant indicates the percentage of the individual. The percentages of CD25<sup>+</sup>FOXP3<sup>+</sup>T cells of the patient and his mother were not reducing (reference range 5.1%-12.7%).



**Figure 3** The gene sequencing peaks of the two-generation family. I (A) and II (A) indicate that no mutation was found; I (B) and II (B) indicate that the mutation site is c.542G>A.



**Figure 4** Schematic representation of the *FOXP3* gene and protein. Numbers along the top line indicate amino acid number (1–431). The latter two lines refer to the gene structure, the coding and non-coding regions: N-terminal domain (orange), zinc-finger (ZF) domain (green), leucine-zipper (LZ) domain (blue), LZ-FKH loop (yellow), and FKH domain (red). The orange arrows indicate the mutation site identified in this study.

## REFERENCES

- 1 **Bennett CL**, Christie J, Ramsdell F, Brunkow ME, Ferguson PJ, Whitesell L, Kelly TE, Saulsbury FT, Chance PF, Ochs HD. The immune dysregulation, polyendocrinopathy, enteropathy, X-linked syndrome (IPEX) is caused by mutations of FOXP3. *Nat Genet* 2001; **27**: 20-21 [PMID: [11137993](#) DOI: [10.1038/83713](#)]
- 2 **Barzaghi F**, Passerini L, Bacchetta R. Immune dysregulation, polyendocrinopathy, enteropathy, x-linked syndrome: a paradigm of immunodeficiency with autoimmunity. *Front Immunol* 2012; **3**: 211 [PMID: [23060872](#) DOI: [10.3389/fimmu.2012.00211](#)]
- 3 **Pogoriler J**, Kamin D, Goldsmith JD. Pediatric non-Helicobacter pylori atrophic gastritis: a case series. *Am J Surg Pathol* 2015; **39**: 786-792 [PMID: [25602795](#) DOI: [10.1097/PAS.0000000000000378](#)]
- 4 **Chen CA**, Chung WC, Chiou YY, Yang YJ, Lin YC, Ochs HD, Shieh CC. Quantitative analysis of tissue inflammation and responses to treatment in immune dysregulation, polyendocrinopathy, enteropathy, X-linked syndrome, and review of literature. *J Microbiol Immunol Infect* 2016; **49**: 775-782 [PMID: [26748735](#) DOI: [10.1016/j.jmii.2015.10.015](#)]
- 5 **Powell BR**, Buist NR, Stenzel P. An X-linked syndrome of diarrhea, polyendocrinopathy, and fatal infection in infancy. *J Pediatr* 1982; **100**: 731-737 [PMID: [7040622](#) DOI: [10.1016/s0022-3476\(82\)80573-8](#)]
- 6 **Owen CJ**, Jennings CE, Imrie H, Lachaux A, Bridges NA, Cheetham TD, Pearce SH. Mutational analysis of the FOXP3 gene and evidence for genetic heterogeneity in the immunodysregulation, polyendocrinopathy, enteropathy syndrome. *J Clin Endocrinol Metab* 2003; **88**: 6034-6039 [PMID: [14671208](#) DOI: [10.1210/jc.2003-031080](#)]
- 7 **Nieves DS**, Phipps RP, Pollock SJ, Ochs HD, Zhu Q, Scott GA, Ryan CK, Kobayashi I, Rossi TM, Goldsmith LA. Dermatologic and immunologic findings in the immune dysregulation, polyendocrinopathy, enteropathy, X-linked syndrome. *Arch Dermatol* 2004; **140**: 466-472 [PMID: [15096376](#) DOI: [10.1001/archderm.140.4.466](#)]
- 8 **Baud O**, Goulet O, Canioni D, Le Deist F, Radford I, Rieu D, Dupuis-Girod S, Cerf-Bensussan N, Cavazzana-Calvo M, Brousse N, Fischer A, Casanova JL. Treatment of the immune dysregulation, polyendocrinopathy, enteropathy, X-linked syndrome (IPEX) by allogeneic bone marrow transplantation. *N Engl J Med* 2001; **344**: 1758-1762 [PMID: [11396442](#) DOI: [10.1056/NEJM200106073442304](#)]
- 9 **Chatila TA**, Blaeser F, Ho N, Lederman HM, Voulgaropoulos C, Helms C, Bowcock AM. JM2, encoding a fork head-related protein, is mutated in X-linked autoimmunity-allergic dysregulation syndrome. *J Clin Invest* 2000; **106**: R75-R81 [PMID: [11120765](#) DOI: [10.1172/JCI11679](#)]
- 10 **Park E**, Chang HJ, Shin JI, Lim BJ, Jeong HJ, Lee KB, Moon KC, Kang HG, Ha IS, Cheong HI. Familial IPEX syndrome: different glomerulopathy in two siblings. *Pediatr Int* 2015; **57**: e59-e61 [PMID: [25712815](#) DOI: [10.1111/ped.12570](#)]
- 11 **Wildin RS**, Ramsdell F, Peake J, Faravelli F, Casanova JL, Buist N, Levy-Lahad E, Mazzella M, Goulet O, Perroni L, Bricarelli FD, Byrne G, McEuen M, Proll S, Appleby M, Brunkow ME. X-linked neonatal diabetes mellitus, enteropathy and endocrinopathy syndrome is the human equivalent of mouse scurfy. *Nat Genet* 2001; **27**: 18-20 [PMID: [11137992](#) DOI: [10.1038/83707](#)]
- 12 **Ziegler SF**. FOXP3: of mice and men. *Annu Rev Immunol* 2006; **24**: 209-226 [PMID: [16551248](#) DOI: [10.1146/annurev.immunol.24.021605.090547](#)]
- 13 **Schubert LA**, Jeffery E, Zhang Y, Ramsdell F, Ziegler SF. Scurfin (FOXP3) acts as a repressor of transcription and regulates T cell activation. *J Biol Chem* 2001; **276**: 37672-37679 [PMID: [11483607](#) DOI: [10.1074/jbc.M104521200](#)]
- 14 **Bettelli E**, Dastrange M, Oukka M. Foxp3 interacts with nuclear factor of activated T cells and NF-kappa B to repress cytokine gene expression and effector functions of T helper cells. *Proc Natl Acad Sci USA* 2005; **102**: 5138-5143 [PMID: [15790681](#) DOI: [10.1073/pnas.0501675102](#)]
- 15 **Benoist C**, Mathis D. Treg cells, life history, and diversity. *Cold Spring Harb Perspect Biol* 2012; **4**: a007021 [PMID: [22952391](#) DOI: [10.1101/cshperspect.a007021](#)]
- 16 **Walker MR**, Kasprovicz DJ, Gersuk VH, Benard A, Van Landeghen M, Buckner JH, Ziegler SF. Induction of FoxP3 and acquisition of T regulatory activity by stimulated human CD4+CD25- T cells. *J Clin Invest* 2003; **112**: 1437-1443 [PMID: [14597769](#) DOI: [10.1172/JCI19441](#)]
- 17 **Bacchetta R**, Passerini L, Gambineri E, Dai M, Allan SE, Perroni L, Dagna-Bricarelli F, Sartirana C, Matthes-Martin S, Lawitschka A, Azzari C, Ziegler SF, Levings MK, Roncarolo MG. Defective regulatory and effector T cell functions in patients with FOXP3 mutations. *J Clin Invest* 2006; **116**: 1713-1722 [PMID: [16741580](#) DOI: [10.1172/JCI25112](#)]
- 18 **An YF**, Zhao XD, Xu F, Yang XQ. A novel missense mutation of FoxP3 causes immune dysregulation, polyendocrinopathy, enteropathy, X-linked syndrome in a Chinese child. *Zhonghua Erke Zazhi* 2009; **47**: 824-828 [DOI: [10.3760/cma.j.issn.0578-1310.2009.11.007](#)]
- 19 **Gambineri E**, Ciullini Mannurita S, Hagin D, Vignoli M, Anover-Sombke S, DeBoer S, Segundo GRS, Allenspach EJ, Favre C, Ochs HD, Torgerson TR. Clinical, Immunological, and Molecular Heterogeneity of 173 Patients With the Phenotype of Immune Dysregulation, Polyendocrinopathy, Enteropathy, X-Linked (IPEX) Syndrome. *Front Immunol* 2018; **9**: 2411 [PMID: [30443250](#) DOI: [10.3389/fimmu.2018.02411](#)]



Published by Baishideng Publishing Group Inc  
7041 Koll Center Parkway, Suite 160, Pleasanton, CA 94566, USA  
Telephone: +1-925-3991568  
E-mail: [bpgoffice@wjgnet.com](mailto:bpgoffice@wjgnet.com)  
Help Desk: <https://www.f6publishing.com/helpdesk>  
<https://www.wjgnet.com>

