

# World Journal of *Clinical Cases*

*World J Clin Cases* 2020 June 6; 8(11): 2066-2407



**REVIEW**

- 2066** Tumor circulome in the liquid biopsies for digestive tract cancer diagnosis and prognosis  
*Chen L, Chen Y, Feng YL, Zhu Y, Wang LQ, Hu S, Cheng P*
- 2081** Isoflavones and inflammatory bowel disease  
*Wu ZY, Sang LX, Chang B*

**MINIREVIEWS**

- 2092** Cytapheresis for pyoderma gangrenosum associated with inflammatory bowel disease: A review of current status  
*Tominaga K, Kamimura K, Sato H, Ko M, Kawata Y, Mizusawa T, Yokoyama J, Terai S*
- 2102** Altered physiology of mesenchymal stem cells in the pathogenesis of adolescent idiopathic scoliosis  
*Ko DS, Kim YH, Goh TS, Lee JS*
- 2111** Association between liver targeted antiviral therapy in colorectal cancer and survival benefits: An appraisal  
*Wang Q, Yu CR*
- 2116** Peroral endoscopic myotomy for management of gastrointestinal motility disorder  
*Feng Z, Liu ZM, Yuan XL, Ye LS, Wu CC, Tan QH, Hu B*

**ORIGINAL ARTICLE****Case Control Study**

- 2127** Clinical prediction of complicated appendicitis: A case-control study utilizing logistic regression  
*Sasaki Y, Komatsu F, Kashima N, Suzuki T, Takemoto I, Kijima S, Maeda T, Miyazaki T, Honda Y, Zai H, Shimada N, Funahashi K, Urita Y*
- 2137** Clinical application of ultrasound-guided selective proximal and distal brachial plexus block in rapid rehabilitation surgery for hand trauma  
*Zhang J, Li M, Jia HB, Zhang L*
- 2144** High flux hemodialysis in elderly patients with chronic kidney failure  
*Xue HY, Duan B, Li ZJ, Du P*
- 2150** Determination of vitamin D and analysis of risk factors for osteoporosis in patients with chronic pain  
*Duan BL, Mao YR, Xue LQ, Yu QY, Liu MY*

**Retrospective Study**

- 2162** Differences in parents of pediatric liver transplantation and chronic liver disease patients  
*Akbulut S, Gunes G, Saritas H, Aslan B, Karipkiz Y, Demyati K, Gungor S, Yilmaz S*
- 2173** Epidemiological investigation of *Helicobacter pylori* infection in elderly people in Beijing  
*Zhu HM, Li BY, Tang Z, She J, Liang XY, Dong LK, Zhang M*
- 2181** Application of a pre-filled tissue expander for preventing soft tissue incarceration during tibial distraction osteogenesis  
*Chen H, Teng X, Hu XH, Cheng L, Du WL, Shen YM*
- 2190** Evaluation of clinical significance of claudin 7 and construction of prognostic grading system for stage II colorectal cancer  
*Quan JC, Peng J, Guan X, Liu Z, Jiang Z, Chen HP, Zhuang M, Wang S, Sun P, Wang HY, Zou SM, Wang XS*
- 2201** Choice and management of negative pressure drainage in anterior cervical surgery  
*Su QH, Zhu K, Li YC, Chen T, Zhang Y, Tan J, Guo S*
- 2210** Risk scores, prevention, and treatment of maternal venous thromboembolism  
*Zhang W, Shen J, Sun JL*
- 2219** Role of Hiraoka's transurethral detachment of the prostate combined with biopsy of the peripheral zone during the same session in patients with repeated negative biopsies in the diagnosis of prostate cancer  
*Pan CY, Wu B, Yao ZC, Zhu XQ, Jiang YZ, Bai S*
- 2227** Efficacy of thoracoscopic anatomical segmentectomy for small pulmonary nodules  
*Li H, Liu Y, Ling BC, Hu B*

**Observational Study**

- 2235** Attitudes, awareness, and knowledge levels of the Turkish adult population toward organ donation: Study of a nationwide survey  
*Akbulut S, Ozer A, Gokce A, Demyati K, Saritas H, Yilmaz S*
- 2246** Metabolic biomarkers and long-term blood pressure variability in military young male adults  
*Lin YK, Liu PY, Fan CH, Tsai KZ, Lin YP, Lee JM, Lee JT, Lin GM*
- 2255** Cytokines predict virological response in chronic hepatitis B patients receiving peginterferon alfa-2a therapy  
*Fu WK, Cao J, Mi NN, Huang CF, Gao L, Zhang JD, Yue P, Bai B, Lin YY, Meng WB*

**SYSTEMATIC REVIEWS**

- 2266** Utilising digital health to improve medication-related quality of care for hypertensive patients: An integrative literature review  
*Wechkunanukul K, Parajuli DR, Hamiduzzaman M*

**META-ANALYSIS**

- 2280** Role of *IL-17* gene polymorphisms in osteoarthritis: A meta-analysis based on observational studies  
*Yang HY, Liu YZ, Zhou XD, Huang Y, Xu NW*

**CASE REPORT**

- 2294** Various diagnostic possibilities for zygomatic arch pain: Seven case reports and review of literature  
*Park S, Park JW*
- 2305** Extensive multifocal and pleomorphic pulmonary lesions in Waldenström macroglobulinemia: A case report  
*Zhao DF, Ning HY, Cen J, Liu Y, Qian LR, Han ZH, Shen JL*
- 2312** Lung cancer from a focal bulla into thin-walled adenocarcinoma with ground glass opacity – an observation for more than 10 years: A case report  
*Meng SS, Wang SD, Zhang YY, Wang J*
- 2318** Pyogenic discitis with an epidural abscess after cervical analgesic discography: A case report  
*Wu B, He X, Peng BG*
- 2325** Clinical characteristics, diagnosis, and treatment of COVID-19: A case report  
*He YF, Lian SJ, Dong YC*
- 2332** Paraplegia after transcatheter artery chemoembolization in a child with clear cell sarcoma of the kidney: A case report  
*Cai JB, He M, Wang FL, Xiong JN, Mao JQ, Guan ZH, Li LJ, Wang JH*
- 2339** Macrophage activation syndrome as a complication of dermatomyositis: A case report  
*Zhu DX, Qiao JJ, Fang H*
- 2345** Serial computed tomographic findings and specific clinical features of pediatric COVID-19 pneumonia: A case report  
*Chen X, Zou XJ, Xu Z*
- 2350** Myxofibrosarcoma of the scalp with difficult preoperative diagnosis: A case report and review of the literature  
*Ke XT, Yu XF, Liu JY, Huang F, Chen MG, Lai QQ*
- 2359** Endoscopic pedicle flap grafting in the treatment of esophageal fistulas: A case report  
*Zhang YH, Du J, Li CH, Hu B*
- 2364** Hemophagocytic syndrome as a complication of acute pancreatitis: A case report  
*Han CQ, Xie XR, Zhang Q, Ding Z, Hou XH*
- 2374** Reduced delay in diagnosis of odontogenic keratocysts with malignant transformation: A case report  
*Luo XJ, Cheng ML, Huang CM, Zhao XP*

- 2380** Gastric pyloric gland adenoma resembling a submucosal tumor: A case report  
*Min CC, Wu J, Hou F, Mao T, Li XY, Ding XL, Liu H*
- 2387** Ataxia-telangiectasia complicated with Hodgkin's lymphoma: A case report  
*Li XL, Wang YL*
- 2392** Uterine incision dehiscence 3 mo after cesarean section causing massive bleeding: A case report  
*Zhang Y, Ma NY, Pang XA*
- 2399** Optical coherence tomography guided treatment avoids stenting in an antiphospholipid syndrome patient: A case report  
*Du BB, Wang XT, Tong YL, Liu K, Li PP, Li XD, Yang P, Wang Y*

**LETTER TO THE EDITOR**

- 2406** Macrophage activation syndrome as an initial presentation of systemic lupus erythematosus  
*Shi LJ, Guo Q, Li SG*

**ABOUT COVER**

Editorial Board Member of *World Journal of Clinical Cases*, Consolato M Sergi, FRCP (C), MD, PhD, Professor, Department of Lab. Medicine and Pathology, University of Alberta, Edmonton T6G 2B7, Canada

**AIMS AND SCOPE**

The primary aim of *World Journal of Clinical Cases* (WJCC, *World J Clin Cases*) is to provide scholars and readers from various fields of clinical medicine with a platform to publish high-quality clinical research articles and communicate their research findings online.

WJCC mainly publishes articles reporting research results and findings obtained in the field of clinical medicine and covering a wide range of topics, including case control studies, retrospective cohort studies, retrospective studies, clinical trials studies, observational studies, prospective studies, randomized controlled trials, randomized clinical trials, systematic reviews, meta-analysis, and case reports.

**INDEXING/ABSTRACTING**

The WJCC is now indexed in PubMed, PubMed Central, Science Citation Index Expanded (also known as SciSearch®), and Journal Citation Reports/Science Edition. The 2019 Edition of Journal Citation Reports cites the 2018 impact factor for WJCC as 1.153 (5-year impact factor: N/A), ranking WJCC as 99 among 160 journals in Medicine, General and Internal (quartile in category Q3).

**RESPONSIBLE EDITORS FOR THIS ISSUE**

Responsible Electronic Editor: *Yan-Xia Xing*

Proofing Production Department Director: *Yun-Xiaojian Wu*

Responsible Editorial Office Director: *Jim-Lei Wang*

**NAME OF JOURNAL**

*World Journal of Clinical Cases*

**ISSN**

ISSN 2307-8960 (online)

**LAUNCH DATE**

April 16, 2013

**FREQUENCY**

Semimonthly

**EDITORS-IN-CHIEF**

Dennis A Bloomfield, Bao-Gan Peng, Sandro Vento

**EDITORIAL BOARD MEMBERS**

<https://www.wjgnet.com/2307-8960/editorialboard.htm>

**PUBLICATION DATE**

June 6, 2020

**COPYRIGHT**

© 2020 Baishideng Publishing Group Inc

**INSTRUCTIONS TO AUTHORS**

<https://www.wjgnet.com/bpg/gerinfo/204>

**GUIDELINES FOR ETHICS DOCUMENTS**

<https://www.wjgnet.com/bpg/GerInfo/287>

**GUIDELINES FOR NON-NATIVE SPEAKERS OF ENGLISH**

<https://www.wjgnet.com/bpg/gerinfo/240>

**PUBLICATION ETHICS**

<https://www.wjgnet.com/bpg/GerInfo/288>

**PUBLICATION MISCONDUCT**

<https://www.wjgnet.com/bpg/gerinfo/208>

**ARTICLE PROCESSING CHARGE**

<https://www.wjgnet.com/bpg/gerinfo/242>

**STEPS FOR SUBMITTING MANUSCRIPTS**

<https://www.wjgnet.com/bpg/GerInfo/239>

**ONLINE SUBMISSION**

<https://www.f6publishing.com>

## Retrospective Study

**Role of Hiraoka's transurethral detachment of the prostate combined with biopsy of the peripheral zone during the same session in patients with repeated negative biopsies in the diagnosis of prostate cancer**

Chun-Yu Pan, Bin Wu, Zi-Chuan Yao, Xian-Qing Zhu, Yun-Zhong Jiang, Song Bai

**ORCID number:** Chun-Yu Pan (0000-0002-2605-8337); Bin Wu (0000-0003-2197-7294); Zi-Chuan Yao (0000-0003-0512-4136); Xian-Qing Zhu (0000-0002-5781-297X); Yun-Zhong Jiang (0000-0001-8127-633X); Song Bai (0000-0002-4197-9054).

**Author contributions:** Bai S had full access to all the data in the study and is responsible for the integrity of the data and the accuracy of the data analysis; Bai S conceived and designed the study, obtained funding and other figures; Pan CY, Yao ZC and Zhu XQ contributed to acquisition of data, analysis and interpretation of data; Pan CY drafted the manuscript, critically revised the manuscript for important intellectual content, and analyzed the data.

**Supported by** Shengjing Hospital Science and Technology Program, No. MC05.

**Institutional review board**

**statement:** Ethical approval (Ethics Committee No. 2018PS496k) was provided by the Institutional Research and Ethics Committee of the Shengjing Hospital Affiliated China Medical University in Shenyang, China.

**Informed consent statement:**

Informed consent was obtained from all eligible patients.

**Conflict-of-interest statement:** We have no financial relationships to

Chun-Yu Pan, Bin Wu, Zi-Chuan Yao, Xian-Qing Zhu, Yun-Zhong Jiang, Song Bai, Department of Urology, Shengjing Hospital of China Medical University, Shenyang 110004, Liaoning Province, China

**Corresponding author:** Song Bai, MD, PhD, Assistant Professor, Doctor, Department of Urology, Shengjing Hospital of China Medical University, 36 Sanhao Street, Shenyang 110004, Liaoning Province, China. [bais@sj-hospital.org](mailto:bais@sj-hospital.org)

**Abstract****BACKGROUND**

Persistent suspicion of prostate cancer (PCa) due to a rising prostate-specific antigen (PSA) level after repeated negative biopsies is a serious challenge in clinical practice.

**AIM**

To determine the role of Hiraoka's transurethral detachment of the prostate (TUDP) combined with biopsy of the peripheral zone during the same session in patients with repeated negative biopsies in the diagnosis of PCa.

**METHODS**

We retrospectively evaluated the records of 10 patients who were eligible for inclusion in our hospital between December 2012 and August 2017. Patient demographics, a family history of PCa, the number of biopsies, prostate volume, pathological examination, and perioperative PSA level were obtained.

**RESULTS**

Two of 10 patients were pathologically diagnosed with PCa after surgery; the Gleason scores were 4 + 4 and 4 + 3, respectively. Both patients subsequently underwent laparoscopic radical prostatectomy. The median PSA levels preoperatively, and 3 mo and 1 year postoperatively in the other eight patients who were diagnosed with benign prostate hyperplasia after surgery were 19.10 ng/mL, 1.10 ng/mL, and 1.15 ng/mL, respectively. The adjusted *P* values of the 3-mo and 1-year post-operative PSA level *vs* pre-operative PSA level were 0.003 and 0.026, respectively. None of the patients had increased PSA levels or PCa detected after a median 35 mo of follow-up.



disclose.

**Data sharing statement:** No additional data are available.

**Open-Access:** This article is an open-access article that was selected by an in-house editor and fully peer-reviewed by external reviewers. It is distributed in accordance with the Creative Commons Attribution NonCommercial (CC BY-NC 4.0) license, which permits others to distribute, remix, adapt, build upon this work non-commercially, and license their derivative works on different terms, provided the original work is properly cited and the use is non-commercial. See: <http://creativecommons.org/licenses/by-nc/4.0/>

**Manuscript source:** Unsolicited manuscript

**Received:** January 2, 2020

**Peer-review started:** January 2, 2020

**First decision:** February 26, 2020

**Revised:** March 26, 2020

**Accepted:** April 24, 2020

**Article in press:** April 24, 2020

**Published online:** June 6, 2020

**P-Reviewer:** Bugaj AM, Markic D, Sugimura H

**S-Editor:** Dou Y

**L-Editor:** Webster JR

**E-Editor:** Qi LL



## CONCLUSION

TUDP combined with peripheral zone biopsy may improve the detection rate of PCa in patients with repeated negative biopsies. The PSA level declined rapidly in patients who had negative pathological examinations after TUDP, which remained stable 1 year after surgery.

**Key words:** Prostate cancer; Biopsy; Transurethral detachment of prostate; Transurethral resection of the prostate; Prostate-specific antigen; Hiraoka's transurethral detachment of the prostate

©The Author(s) 2020. Published by Baishideng Publishing Group Inc. All rights reserved.

**Core tip:** This retrospective study demonstrated that transurethral detachment of the prostate combined with peripheral zone biopsy may improve prostate cancer detection rate in patients with repeated negative biopsies, and abnormal prostate-specific antigen level. The prostate-specific antigen level declined rapidly 3 mo postoperatively in patients with negative pathological examinations and remained stable 1 year after surgery.

**Citation:** Pan CY, Wu B, Yao ZC, Zhu XQ, Jiang YZ, Bai S. Role of Hiraoka's transurethral detachment of the prostate combined with biopsy of the peripheral zone during the same session in patients with repeated negative biopsies in the diagnosis of prostate cancer. *World J Clin Cases* 2020; 8(11): 2219-2226

**URL:** <https://www.wjgnet.com/2307-8960/full/v8/i11/2219.htm>

**DOI:** <https://dx.doi.org/10.12998/wjcc.v8.i11.2219>

## INTRODUCTION

Prostate cancer (PCa) is the most commonly diagnosed cancer in men > 65 years of age, with an estimated 1.1 million diagnosed worldwide in 2012 and accounting for 15% of all cancers diagnosed<sup>[1]</sup>. The prevalence of PCa varies widely in different geographic regions and races, and is higher in western Europe and North America, with age-standardized rates of 94.7/100000 and 97.2/100000, respectively, and lower in Asia, with an age-standardized rate of 4.5/100000<sup>[2]</sup>. PCa is the main cause of mortality for men in developed countries.

Prostate biopsy is the main strategy for diagnosing PCa; however, 25%-35% of PCas are missed at the time of the first biopsy and 10% are missed at the time of the second biopsy, even if additional transition zone and saturation biopsies are obtained<sup>[3]</sup>. The incidence of identifying cancer at the time of the third or fourth biopsies decreases to < 14%<sup>[4]</sup>. Persistent suspicion of PCa due to a rising prostate-specific antigen (PSA) level after repeated negative biopsies is common in clinical practice<sup>[5]</sup>. Although many strategies have been developed to overcome this problem, such as increasing the number of biopsy cores and biopsy of transitional or anterior zones of the gland<sup>[6-8]</sup>, none of the existing strategies can resolve this problem.

Transurethral resection of the prostate (TURP) is a common treatment option for patients with lower urinary tract symptoms (LUTS) caused by bladder outlet obstruction, which allows improvement in voiding symptoms and extends the histologic examination in the transition zone, which accounts for 20%-25% of PCas<sup>[9]</sup>. Due to a lower histological positive rate compared with repeated prostate biopsies, TURP is not a reasonable approach to diagnose PCa in patients without voiding symptoms<sup>[10]</sup>. Moreover, there are several disadvantages of TURP; specifically, TURP cannot reach the prostate peripheral zone tissues and may lead to an increased surgical risk due to tissue adhesions caused by thermal injury, which necessitate postponing radical prostatectomy to avoid morbidity. Hence, either repeated biopsies or TURP cannot reliably exclude the presence of PCa.

Hiraoka's transurethral detachment of the prostate (TUDP) was first introduced in 1989 by Hiraoka *et al.*<sup>[11]</sup>. TUDP is a mature technique in enucleation of the prostate for treatment of benign prostate hyperplasia<sup>[12,13]</sup>. TUDP combined with biopsy of the peripheral zone during the same session is a method which may improve the PCa detection rate by obtaining a complete sample which simultaneously includes the entire transition, peripheral, and anterior fibrous zones. The purpose of this study was



to determine the role of TUDP combined with biopsy of the peripheral zone during the same session in patients with repeated negative biopsies, rising PSA levels, and voiding symptoms in the diagnosis of PCa.

## MATERIALS AND METHODS

### *Study design and patients*

We retrospectively evaluated the records of 10 patients who underwent Hiraoka's TUDP combined with biopsy of the peripheral zone during the same session and had repeated negative biopsies in the diagnosis of PCa in our hospital between December 2012 and August 2017. The inclusion criteria were as follows: had rising PSA level and negative prostate biopsies (at least twice); underwent TUDP due to bladder outlet obstruction.

Patient demographics (age and body mass index), family history of PCa, number of biopsies, prostate volume (examined by transrectal ultrasound), pathological examination, and peri-operative PSA level (preoperatively, and 3 mo and 1 year postoperatively) were obtained. The follow-up period was calculated from the date of surgery to the date of the final visit.

### *TUDP surgical techniques combined with biopsy of the peripheral zone*

The surgical instruments include Hiraoka's Prostate Detaching Blade (Olympus, Tokyo, Japan), Needle Electrode and Cutting Loop Electrode (Olympus, Tokyo, Japan), 26 Fr Continuous Irrigation Sheath and Resectoscope (Olympus, Tokyo, Japan; [Figure 1A and B](#)), and 26 Fr Storz Nephroscope and Lumenis Versa Tissue Morcellator (Israel).

Patients underwent surgery in the lithotomy position after anesthesia. First, we used a cutting loop electrode to mark the junction between the distal prostate gland and the proximal edge of the urethral external sphincter (Nesbit sign) using the electrocoagulation mode. The needle electrode was then used to incise the urethral mucosa in a circular incision along the marker. The depth of the circular incision was 3–4 mm and was anterior oblique (parallel to the sphincter to avoid injury). Second, Hiraoka's Prostate Detaching Blade was used to locate and enter the surgical capsule plane at 5–7 o'clock of the circular incision, then extended forward and laterally along the surgical plane by blunt separation. A hyperplastic prostate gland is white with a dense fibrous structure, and the surgical capsule is spongy with soft and transverse vessels when viewed with a resectoscope. There is little bleeding during the detaching process, which generally does not affect the visual field. We used a cutting loop electrode to stop bleeding as needed. Third, when detaching the bladder neck, Hiraoka's Prostate Detaching Blade was used to enucleate the anterior fibrous area in the 12 o'clock direction, then extended to both sides and stopping at 5 o'clock and 7 o'clock. The bladder neck was then cut off between 5 o'clock and 7 o'clock using a cutting loop electrode. Finally, the enucleated prostate hyperplastic gland was pushed into the bladder, which was morcellated and removed using a tissue morcellator ([Figure 1C–F](#)). A cutting loop electrode was used to biopsy the peripheral zone, which included three locations (left peripheral zone, right peripheral zone, and anterior fibrous area; [Figure 1G and H](#)).

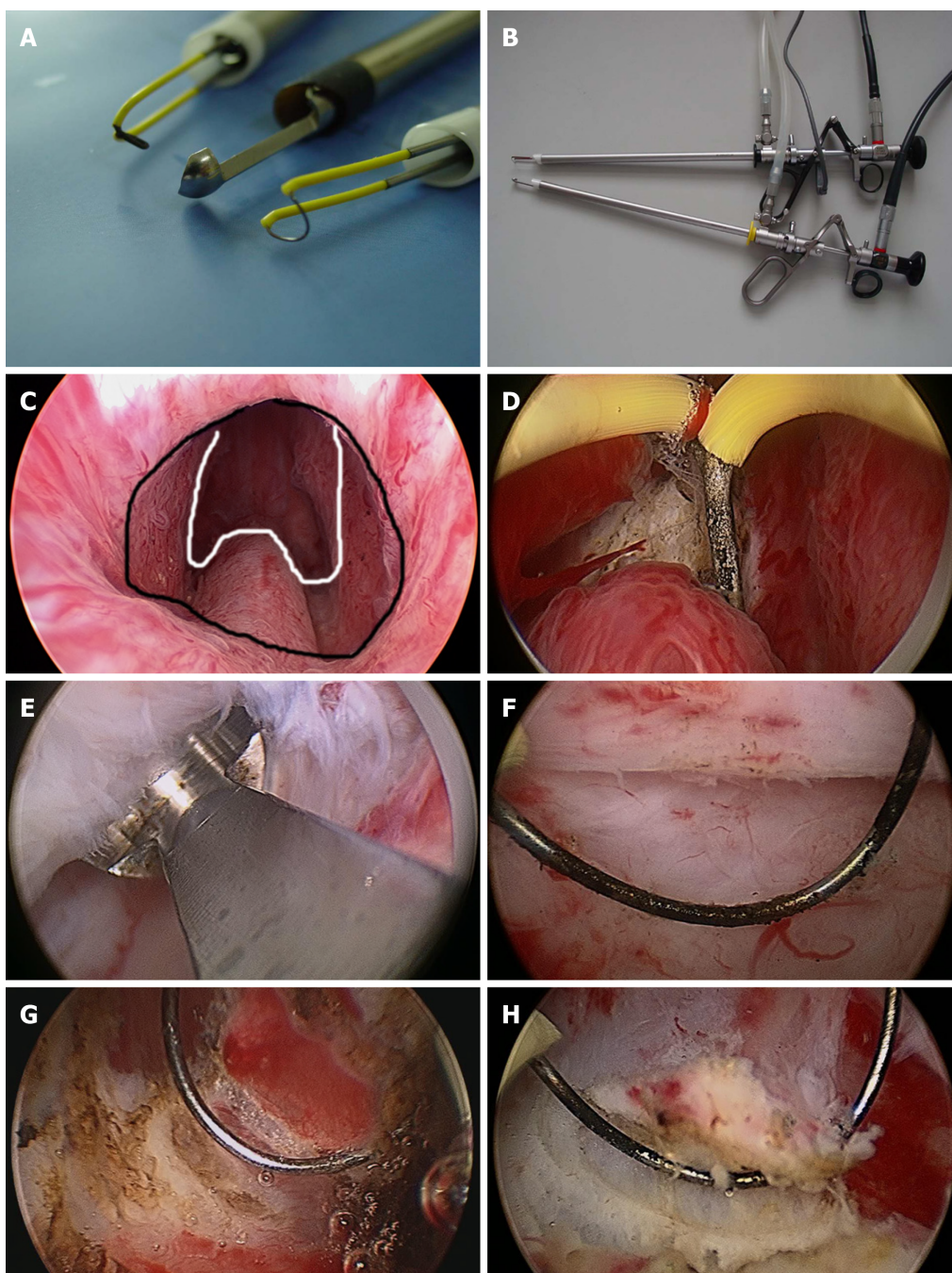
### *Statistical analysis*

Continuous variables with non-normal variables were reported as the median (interquartile range). Categorical data are presented as a frequency and percentage. The mean of multiple repeated continuous non-normally distributed variables was compared using the Friedman test. Statistical analyses were performed using SPSS 22.0 for Windows (SPSS, Inc., Chicago, IL, United States). A *P* value < 0.05 was considered statistically significant.

## RESULTS

Ten patients underwent Hiraoka's TUDP combined with biopsy of the peripheral zone with a long-term follow-up (median, 35 mo; range, 12–40 mo). The median age and body mass index were 66.0 years and 26.0 kg/m<sup>2</sup>, respectively. None of the patients had a family history of PCa. The median prostate volume was 55 mL (range, 40–60 mL).

Two of 10 patients were pathologically diagnosed with PCa after surgery. One patient had PCa, which was detected in the transition and peripheral zones. The other patient had PCa, which was only detected in the anterior fibrous zone. The Gleason



**Figure 1** Instruments and procedure of Hiraoka's transurethral detachment of prostate combined with biopsy of the peripheral zone. A: Surgical instruments (from top-to-bottom): Needle electrode, Hiraoka's Prostate Detaching Blade (the tip of the detaching blade is a shallow, sharp-edged scoop with two longitudinal apertures to enhance the flow of irrigation fluid) and a cutting loop electrode; B: Hiraoka's Prostate Detaching Blade can be connected with a 26 Fr continuous irrigation sheath and resectoscope; C: Nesbit sign: the white solid line indicates the distal part of the prostate adenoma; the black solid line indicates the proximal part of the urethral external sphincter; D: A needle electrode was used to incise the urethral mucosa in a circular incision along the marker, then Hiraoka's Prostate Detaching Blade was used to locate and enter the surgical capsule plane at the 5-7 o'clock position of the circular incision; E: The hyperplastic prostate gland is white with a dense fibrous structure, and the surgical capsule is spongy with soft and transverse vessels when visualized with a resectoscope; F: There was little bleeding during the detaching process, which generally does not affect the visual field. If necessary, we could use a cutting loop electrode to stop bleeding; G and H: Biopsy of the lateral peripheral zone with a cutting loop electrode.

scores were 4 + 4 and 4 + 3, respectively. Both patients subsequently underwent a laparoscopic radical prostatectomy.

The median preoperative, and 3-mo and 1-year postoperative PSA levels of the other 8 patients who were diagnosed with benign prostate hyperplasia were 19.10 ng/mL, 1.10 ng/mL, and 1.15 ng/mL, respectively. The adjusted *P* values for the 3-mo and 1-year post-operative PSA level *vs* preoperative PSA level were 0.003 and 0.026, respectively. The PSA levels of these patients declined rapidly 3 mo postoperatively and remained stable 1 year after surgery. Moreover, none of the patients had rising PSA levels and PCa detected after a median of 35 mo follow-up

(Table 1).

## DISCUSSION

Prostate biopsy is the main strategy used in diagnosing PCa. In the largest PCa screening program, 91% of PCas were detected at the time of the first or second biopsy, but < 14% of PCas were detected at the time of the third or fourth biopsy<sup>[4]</sup>. There are many methods for improving the PCa detection rate, such as increasing the number of biopsy cores and extending the transitional and anterior fibrous zones of the prostate. Nevertheless, a portion of PCas remain undetected after multiple biopsies. According to the 2018 EAU guidelines, third and fourth biopsies are not recommended because of lower sensitivities<sup>[10]</sup>. TURP is an option for patients with voiding problems, rising PSA levels, and repeated negative biopsies, which would improve voiding symptoms, normalize PSA levels, and extend the histological examination in the transition zone of the prostate<sup>[6]</sup>; however, TURP does not reach the peripheral zone, thus part of a PCa may be missed by surgery. However, this is a common issue in clinical practice for which there is currently no solution. In addition, patients with abnormal PSA levels and repeated negative biopsies can also be terrified. Katz *et al*<sup>[14]</sup> reported that such patients have increased cancer-related anxiety and exhibit increased sexual problems. In this study we evaluated the role of TUDP combined with peripheral zone biopsy during the same session in patients with voiding problems, rising PSA levels, and repeated negative biopsies in the diagnosis of PCa.

The most important advantage of TUDP is the nearly complete prostate tissue biopsy, which includes the entire transition zone, and parts of the peripheral and anterior fibrous zones of the prostate that can be biopsied simultaneously. It is noteworthy that the peripheral zone biopsy tissue which is resected by TURP is much more than a puncture biopsy.

Based on the literature, the PCa detection rate in TURP ranges from 1.4%-16.7%<sup>[15-19]</sup>, which is less than our results (20.0%). The reason for this difference may be that more adenoma tissues are removed in TUDP than TURP, and when simultaneously combined with a peripheral zone resection biopsy, a nearly complete sampling would be obtained and the cancer detection rate would be increased.

Puppo *et al*<sup>[5]</sup> reported a similar technique to TURP combined with a peripheral zone biopsy in the diagnosis of PCa for patients with repeated negative biopsies, a persistently abnormal PSA level, and no voiding problems. Eight of 14 patients had PCa, which was higher than repeated biopsies. Therefore, Puppo *et al*<sup>[5]</sup> concluded that this technique had high diagnostic power for such patients. In contrast, many studies suggest that TURP should be performed only in patients with voiding symptoms due to lower sensitivity than repeated biopsies<sup>[10,20]</sup>. In this study all of the patients had moderate-to-severe LUTS and an impaired quality of life.

Puppo *et al*<sup>[5]</sup> stated that radical prostatectomy is more difficult in patients after TURP than routine cases, with good continence and poor erection function. In this study there were two patients with positive biopsies, both of whom had aggressive PCa. The patients underwent laparoscopic radical prostatectomies within 1 mo after TUDP, did not have severe morbidities perioperatively, and had good continence and erection function.

Postoperative follow-up is also important. Zigeuner *et al*<sup>[10]</sup> reported that every fourth cancer is missed by previous biopsies and surgery, which were detected during follow-up. Kitamura *et al*<sup>[20]</sup> reported that four of 139 patients who underwent TURP with repeated negative biopsies were shown to have PCa during the follow-up period. In a retrospective study, Radhakrishnan *et al*<sup>[21]</sup> reported that three of 14 patients had PCa during the follow-up period. Philip *et al*<sup>[7]</sup> also described five patients who had PCa and underwent radical prostatectomy and emphasized that PCa was mainly located in the anterior fibrous zone. In our study none of the patients had rising PSA levels and PCa detected after a median of 35 mo follow-up, possibly because the anterior and peripheral zones were both examined during surgery.

van Renterghem *et al*<sup>[6]</sup> reported that TURP could improve voiding symptoms, quality of life, and normalize the PSA level. The average PSA level decreased from 8.2 ng/mL to 0.9 ng/mL 1 year after surgery and 97.2% of patients (35/36) had a permanently normal PSA. Cho *et al*<sup>[22]</sup> stated that 95.5% of patients (106/112) had normalized PSA 3 mo after TURP that persisted in 97.2% of patients 3 years after surgery. In agreement with this finding, we demonstrated that 100% of patients (8/8) with negative biopsies had normalized PSA levels 3 mo after TUDP that persisted for at least 1 year. The reason for this finding could be that the prostate volume and voiding symptoms are closely related to the PSA level.



**Table 1** Data of the cohort

Characteristics	Results
Follow-up period (mo)	35.0 (12.0–40.0)
No. of cases	10
Age (yr)	66.0 (62.0–67.0)
BMI (kg/m <sup>2</sup> )	26.0 (24.0–27.0)
Familial history of PCa	0 (0)
Number of negative biopsy (times)	2 (2–3)
Prostate volume (mL)	55.0 (40.0–60.0)
Pathological examination (PCa)	2 (0.2)
PSA pre-operation (ng/mL)	19.10 (16.00 to 23.00)
PSA 3 mo postoperation	1.00 (1.05–1.20)
PSA 1 year postoperation	1.15 (1.10–1.20)

Data are presented as the median (IQRs) or number (percentages). BMI: Body mass index; PCa: Prostate cancer; IQR: Interquartile range.

TUDP resects the entire hyperplastic prostate adenoma. In contrast, TURP only removes one-half of the adenoma on average<sup>[23]</sup>. Helfand *et al*<sup>[16]</sup> reported a 93.0% decrease in the PSA level from baseline in patients undergoing open prostatectomy and a 60% decrease in the PSA level in patients undergoing TURP, which presumably reflects the completeness of the resection. We noted a 94.0% decrease in the PSA level in our study.

We are of the opinion that the other types of transurethral enucleation of the prostate, such as Holmium laser enucleation of the prostate, could also be combined with peripheral zone biopsies in diagnosing PCa; however, we would not recommend vaporization in these patients as vaporization does not allow pathological examination<sup>[24]</sup>.

There were several limitations in this study that should be noted. First, this was a retrospective study with inherent flaws. Second, relatively few patients were included in one center. A large multi-center study is required to support the advantages of this technique. In addition, other surgeons are needed to confirm the repeatability before widespread acceptance. Nevertheless, this type of technique is demanding compared with other kinds of techniques.

In conclusion, TUDP combined with peripheral zone biopsy may improve the detection rate of PCa in patients with repeated negative biopsies. The PSA level declined rapidly in patients who had negative pathological examinations after TUDP, which remained stable 1 year after surgery.

## ARTICLE HIGHLIGHTS

### Research background

After repeated negative biopsies, persistent suspicion of prostate cancer (PCa) due to a rising prostate-specific antigen (PSA) level is a serious challenge in clinical practice.

### Research motivation

Transurethral detachment of the prostate (TUDP) combined with biopsy of the peripheral zone during the same session is a method which may improve the PCa detection rate by obtaining a complete sample which simultaneously includes the entire transition, peripheral, and anterior fibrous zones.

### Research objectives

Our aim was to determine the role of Hiraoka's TUDP combined with biopsy of the peripheral zone during the same session in patients with repeated negative biopsies in the diagnosis of PCa.

### Research methods

We retrospectively evaluated the records of 10 patients who were eligible for inclusion in our hospital between December 2012 and August 2017. Patient demographics, a family history of PCa, the number of biopsies, prostate volume, pathological examination, and perioperative PSA level were obtained.

### Research results

Two of 10 patients were pathologically diagnosed with PCa after surgery; the Gleason scores

were 4 + 4 and 4 + 3, respectively. Both of the patients subsequently underwent laparoscopic radical prostatectomy. The median PSA levels preoperatively, and 3 mo and 1 year postoperatively in the other eight patients who were diagnosed with benign prostate hyperplasia after surgery were 19.10 ng/mL, 1.10 ng/mL, and 1.15 ng/mL, respectively. The adjusted *P* values of the 3-mo and 1-year post-operative PSA level *vs* pre-operative PSA level were 0.003 and 0.026, respectively. None of the patients had rising PSA levels or PCa detected after a median 35 mo of follow-up.

### Research conclusions

TUDP combined with peripheral zone biopsy may improve the PCa detection rate in patients with repeated negative biopsies.

### Research perspectives

The PSA level declined rapidly in patients who had negative pathological examinations after TUDP, which remained stable 1 year after surgery.

## ACKNOWLEDGEMENTS

We give special thanks to all the teachers at the Department of Urology of Shengjing Hospital for their help and support.

## REFERENCES

- 1 Ferlay J, Soerjomataram I, Dikshit R, Eser S, Mathers C, Rebelo M, Parkin DM, Forman D, Bray F. Cancer incidence and mortality worldwide: sources, methods and major patterns in GLOBOCAN 2012. *Int J Cancer* 2015; **136**: E359-E386 [PMID: 25220842 DOI: 10.1002/ijc.29210]
- 2 Haas GP, Delongchamps N, Brawley OW, Wang CY, de la Roza G. The worldwide epidemiology of prostate cancer: perspectives from autopsy studies. *Can J Urol* 2008; **15**: 3866-3871 [PMID: 18304396 DOI: 10.1111/j.1464-410X.2007.07285.x]
- 3 Abedi AR, Fallah-Karkan M, Allameh F, Ranjbar A, Shadmehr A. Incidental prostate cancer: a 10-year review of a tertiary center, Tehran, Iran. *Res Rep Urol* 2018; **10**: 1-6 [PMID: 29392121 DOI: 10.2147/RRU.S146159]
- 4 Roehl KA, Antenor JA, Catalona WJ. Serial biopsy results in prostate cancer screening study. *J Urol* 2002; **167**: 2435-2439 [PMID: 11992052 DOI: 10.1016/S0022-5347(05)64999-3]
- 5 Puppo P, Introini C, Calvi P, Naselli A. Role of transurethral resection of the prostate and biopsy of the peripheral zone in the same session after repeated negative biopsies in the diagnosis of prostate cancer. *Eur Urol* 2006; **49**: 873-878 [PMID: 16439052 DOI: 10.1016/j.eururo.2005.12.064]
- 6 van Renterghem K, Van Koeveringe G, Achten R, van Kerrebroeck P. A new algorithm in patients with elevated and/or rising prostate-specific antigen level, minor lower urinary tract symptoms, and negative multisite prostate biopsies. *Int Urol Nephrol* 2010; **42**: 29-38 [PMID: 19496018 DOI: 10.1007/s11255-009-9596-z]
- 7 Philip J, Dutta Roy S, Scally J, Foster CS, Javle P. Importance of TURP in diagnosing prostate cancer in men with multiple negative biopsies. *Prostate* 2005; **64**: 200-202 [PMID: 15712218 DOI: 10.1002/pros.20239]
- 8 Chon CH, Lai FC, McNeal JE, Presti JC. Use of extended systematic sampling in patients with a prior negative prostate needle biopsy. *J Urol* 2002; **167**: 2457-2460 [PMID: 11992057 DOI: 10.1016/S0022-5347(05)65004-5]
- 9 Onder AU, Yalcin V, Arar O, Yaycioglu O, Citci A, Solok V. Impact of transition zone biopsies in detection and evaluation of prostate cancer. *Eur Urol* 1998; **33**: 542-548 [PMID: 9743695 DOI: 10.1159/000019653]
- 10 Zigeuner R, Schips L, Lipsky K, Auprich M, Salfellner M, Rehak P, Pummer K, Hubner G. Detection of prostate cancer by TURP or open surgery in patients with previously negative transrectal prostate biopsies. *Urology* 2003; **62**: 883-887 [PMID: 14624913 DOI: 10.1016/S0090-4295(03)00663-0]
- 11 Hiraoka Y, Akimoto M. Transurethral enucleation of benign prostatic hyperplasia. *J Urol* 1989; **142**: 1247-1250 [PMID: 2478727 DOI: 10.1016/S0022-5347(17)39047-x]
- 12 Iwamoto K, Hiraoka Y, Shimizu Y. Transurethral detachment prostatectomy using a tissue morcellator for large benign prostatic hyperplasia. *J Nippon Med Sch* 2008; **75**: 77-84 [PMID: 18475027 DOI: 10.1272/jnms.75.77]
- 13 Hiraoka Y, Shimizu Y, Iwamoto K, Takahashi H, Abe H. Trial of complete detachment of the whole prostate lobes in benign prostate hyperplasia by transurethral enucleation of the prostate. *Urol Int* 2007; **79**: 50-54 [PMID: 17627169 DOI: 10.1159/000102914]
- 14 Katz DA, Jarrard DF, McHorney CA, Hillis SL, Wiebe DA, Fryback DG. Health perceptions in patients who undergo screening and workup for prostate cancer. *Urology* 2007; **69**: 215-220 [PMID: 17320653 DOI: 10.1016/j.urol.2006.09.059]
- 15 Voigt S, Hüttig F, Koch R, Propping S, Propping C, Grimm MO, Wirth M. Risk factors for incidental prostate cancer-who should not undergo vaporization of the prostate for benign prostate hyperplasia? *Prostate* 2011; **71**: 1325-1331 [PMID: 21308716 DOI: 10.1002/pros.21349]
- 16 Helfand BT, Anderson CB, Fought A, Kim DY, Vyas A, McVary KT. Postoperative PSA and PSA velocity identify presence of prostate cancer after various surgical interventions for benign prostatic hyperplasia. *Urology* 2009; **74**: 177-183 [PMID: 19428074 DOI: 10.1016/j.urol.2008.10.062]
- 17 Yoo C, Oh CY, Kim SJ, Kim SI, Kim YS, Park JY, Seong do H, Song YS, Yang WJ, Chung HC, Cho IR, Cho SY, Cheon SH, Hong S, Cho JS. Preoperative clinical factors for diagnosis of incidental prostate cancer in the era of tissue-ablative surgery for benign prostatic hyperplasia: a Korean multi-center review. *Korean J Urol* 2012; **53**: 391-395 [PMID: 22741046 DOI: 10.4111/kju.2012.53.6.391]
- 18 Trpkov K, Thompson J, Kulaga A, Yilmaz A. How much tissue sampling is required when unsuspected

- minimal prostate carcinoma is identified on transurethral resection? *Arch Pathol Lab Med* 2008; **132**: 1313-1316 [PMID: 18684032 DOI: 10.1043/1543-2165(2008)132[1313:HMTSIR]2.0.CO;2]
- 19 **Otto B**, Barbieri C, Lee R, Te AE, Kaplan SA, Robinson B, Chughtai B. Incidental prostate cancer in transurethral resection of the prostate specimens in the modern era. *Adv Urol* 2014; **2014**: 627290 [PMID: 24876835 DOI: 10.1155/2014/627290]
- 20 **Kitamura H**, Masumori N, Tanuma Y, Yanase M, Itoh N, Takahashi A, Tsukamoto T, Adachi H, Hotta H. Does transurethral resection of the prostate facilitate detection of clinically significant prostate cancer that is missed with systematic sextant and transition zone biopsies? *Int J Urol* 2002; **9**: 95-99 [PMID: 12028299 DOI: 10.1046/j.1442-2042.2002.00428.x]
- 21 **Radhakrishnan S**, Dorkin TJ, Sheikh N, Greene DR. Role of transition zone sampling by TURP in patients with raised PSA and multiple negative transrectal ultrasound-guided prostatic biopsies. *Prostate Cancer Prostatic Dis* 2004; **7**: 338-342 [PMID: 15365579 DOI: 10.1038/sj.pcan.4500756]
- 22 **Cho HJ**, Shin SC, Cho JM, Kang JY, Yoo TK. The role of transurethral resection of the prostate for patients with an elevated prostate-specific antigen. *Prostate Int* 2014; **2**: 196-202 [PMID: 25599076 DOI: 10.12954/PI.14060]
- 23 **Shimizu Y**, Hiraoka Y, Iwamoto K, Takahashi H, Abe H. Measurement of residual adenoma after transurethral resection of the prostate by transurethral enucleation technique. *Urol Int* 2005; **74**: 102-107 [PMID: 15756059 DOI: 10.1159/000083278]
- 24 **van Renterghem K**, Van Koeveringe G, Achten R, van Kerrebroeck P. Prospective study of the role of transurethral resection of the prostate in patients with an elevated prostate-specific antigen level, minor lower urinary tract symptoms, and proven bladder outlet obstruction. *Eur Urol* 2008; **54**: 1385-1392 [PMID: 18599187 DOI: 10.1016/j.eururo.2008.06.069]





Published by Baishideng Publishing Group Inc  
7041 Koll Center Parkway, Suite 160, Pleasanton, CA 94566, USA  
Telephone: +1-925-3991568  
E-mail: [bpgoffice@wjgnet.com](mailto:bpgoffice@wjgnet.com)  
Help Desk: <https://www.f6publishing.com/helpdesk>  
<https://www.wjgnet.com>

