

World Journal of *Clinical Cases*

World J Clin Cases 2020 June 6; 8(11): 2066-2407



**REVIEW**

- 2066** Tumor circulome in the liquid biopsies for digestive tract cancer diagnosis and prognosis
Chen L, Chen Y, Feng YL, Zhu Y, Wang LQ, Hu S, Cheng P
- 2081** Isoflavones and inflammatory bowel disease
Wu ZY, Sang LX, Chang B

MINIREVIEWS

- 2092** Cytapheresis for pyoderma gangrenosum associated with inflammatory bowel disease: A review of current status
Tominaga K, Kamimura K, Sato H, Ko M, Kawata Y, Mizusawa T, Yokoyama J, Terai S
- 2102** Altered physiology of mesenchymal stem cells in the pathogenesis of adolescent idiopathic scoliosis
Ko DS, Kim YH, Goh TS, Lee JS
- 2111** Association between liver targeted antiviral therapy in colorectal cancer and survival benefits: An appraisal
Wang Q, Yu CR
- 2116** Peroral endoscopic myotomy for management of gastrointestinal motility disorder
Feng Z, Liu ZM, Yuan XL, Ye LS, Wu CC, Tan QH, Hu B

ORIGINAL ARTICLE**Case Control Study**

- 2127** Clinical prediction of complicated appendicitis: A case-control study utilizing logistic regression
Sasaki Y, Komatsu F, Kashima N, Suzuki T, Takemoto I, Kijima S, Maeda T, Miyazaki T, Honda Y, Zai H, Shimada N, Funahashi K, Urita Y
- 2137** Clinical application of ultrasound-guided selective proximal and distal brachial plexus block in rapid rehabilitation surgery for hand trauma
Zhang J, Li M, Jia HB, Zhang L
- 2144** High flux hemodialysis in elderly patients with chronic kidney failure
Xue HY, Duan B, Li ZJ, Du P
- 2150** Determination of vitamin D and analysis of risk factors for osteoporosis in patients with chronic pain
Duan BL, Mao YR, Xue LQ, Yu QY, Liu MY

Retrospective Study

- 2162** Differences in parents of pediatric liver transplantation and chronic liver disease patients
Akbulut S, Gunes G, Saritas H, Aslan B, Karipkiz Y, Demyati K, Gungor S, Yilmaz S
- 2173** Epidemiological investigation of *Helicobacter pylori* infection in elderly people in Beijing
Zhu HM, Li BY, Tang Z, She J, Liang XY, Dong LK, Zhang M
- 2181** Application of a pre-filled tissue expander for preventing soft tissue incarceration during tibial distraction osteogenesis
Chen H, Teng X, Hu XH, Cheng L, Du WL, Shen YM
- 2190** Evaluation of clinical significance of claudin 7 and construction of prognostic grading system for stage II colorectal cancer
Quan JC, Peng J, Guan X, Liu Z, Jiang Z, Chen HP, Zhuang M, Wang S, Sun P, Wang HY, Zou SM, Wang XS
- 2201** Choice and management of negative pressure drainage in anterior cervical surgery
Su QH, Zhu K, Li YC, Chen T, Zhang Y, Tan J, Guo S
- 2210** Risk scores, prevention, and treatment of maternal venous thromboembolism
Zhang W, Shen J, Sun JL
- 2219** Role of Hiraoka's transurethral detachment of the prostate combined with biopsy of the peripheral zone during the same session in patients with repeated negative biopsies in the diagnosis of prostate cancer
Pan CY, Wu B, Yao ZC, Zhu XQ, Jiang YZ, Bai S
- 2227** Efficacy of thoracoscopic anatomical segmentectomy for small pulmonary nodules
Li H, Liu Y, Ling BC, Hu B

Observational Study

- 2235** Attitudes, awareness, and knowledge levels of the Turkish adult population toward organ donation: Study of a nationwide survey
Akbulut S, Ozer A, Gokce A, Demyati K, Saritas H, Yilmaz S
- 2246** Metabolic biomarkers and long-term blood pressure variability in military young male adults
Lin YK, Liu PY, Fan CH, Tsai KZ, Lin YP, Lee JM, Lee JT, Lin GM
- 2255** Cytokines predict virological response in chronic hepatitis B patients receiving peginterferon alfa-2a therapy
Fu WK, Cao J, Mi NN, Huang CF, Gao L, Zhang JD, Yue P, Bai B, Lin YY, Meng WB

SYSTEMATIC REVIEWS

- 2266** Utilising digital health to improve medication-related quality of care for hypertensive patients: An integrative literature review
Wechkunanukul K, Parajuli DR, Hamiduzzaman M

META-ANALYSIS

- 2280** Role of *IL-17* gene polymorphisms in osteoarthritis: A meta-analysis based on observational studies
Yang HY, Liu YZ, Zhou XD, Huang Y, Xu NW

CASE REPORT

- 2294** Various diagnostic possibilities for zygomatic arch pain: Seven case reports and review of literature
Park S, Park JW
- 2305** Extensive multifocal and pleomorphic pulmonary lesions in Waldenström macroglobulinemia: A case report
Zhao DF, Ning HY, Cen J, Liu Y, Qian LR, Han ZH, Shen JL
- 2312** Lung cancer from a focal bulla into thin-walled adenocarcinoma with ground glass opacity – an observation for more than 10 years: A case report
Meng SS, Wang SD, Zhang YY, Wang J
- 2318** Pyogenic discitis with an epidural abscess after cervical analgesic discography: A case report
Wu B, He X, Peng BG
- 2325** Clinical characteristics, diagnosis, and treatment of COVID-19: A case report
He YF, Lian SJ, Dong YC
- 2332** Paraplegia after transcatheter artery chemoembolization in a child with clear cell sarcoma of the kidney: A case report
Cai JB, He M, Wang FL, Xiong JN, Mao JQ, Guan ZH, Li LJ, Wang JH
- 2339** Macrophage activation syndrome as a complication of dermatomyositis: A case report
Zhu DX, Qiao JJ, Fang H
- 2345** Serial computed tomographic findings and specific clinical features of pediatric COVID-19 pneumonia: A case report
Chen X, Zou XJ, Xu Z
- 2350** Myxofibrosarcoma of the scalp with difficult preoperative diagnosis: A case report and review of the literature
Ke XT, Yu XF, Liu JY, Huang F, Chen MG, Lai QQ
- 2359** Endoscopic pedicle flap grafting in the treatment of esophageal fistulas: A case report
Zhang YH, Du J, Li CH, Hu B
- 2364** Hemophagocytic syndrome as a complication of acute pancreatitis: A case report
Han CQ, Xie XR, Zhang Q, Ding Z, Hou XH
- 2374** Reduced delay in diagnosis of odontogenic keratocysts with malignant transformation: A case report
Luo XJ, Cheng ML, Huang CM, Zhao XP

- 2380** Gastric pyloric gland adenoma resembling a submucosal tumor: A case report
Min CC, Wu J, Hou F, Mao T, Li XY, Ding XL, Liu H
- 2387** Ataxia-telangiectasia complicated with Hodgkin's lymphoma: A case report
Li XL, Wang YL
- 2392** Uterine incision dehiscence 3 mo after cesarean section causing massive bleeding: A case report
Zhang Y, Ma NY, Pang XA
- 2399** Optical coherence tomography guided treatment avoids stenting in an antiphospholipid syndrome patient: A case report
Du BB, Wang XT, Tong YL, Liu K, Li PP, Li XD, Yang P, Wang Y

LETTER TO THE EDITOR

- 2406** Macrophage activation syndrome as an initial presentation of systemic lupus erythematosus
Shi LJ, Guo Q, Li SG

ABOUT COVER

Editorial Board Member of *World Journal of Clinical Cases*, Consolato M Sergi, FRCP (C), MD, PhD, Professor, Department of Lab. Medicine and Pathology, University of Alberta, Edmonton T6G 2B7, Canada

AIMS AND SCOPE

The primary aim of *World Journal of Clinical Cases* (WJCC, *World J Clin Cases*) is to provide scholars and readers from various fields of clinical medicine with a platform to publish high-quality clinical research articles and communicate their research findings online.

WJCC mainly publishes articles reporting research results and findings obtained in the field of clinical medicine and covering a wide range of topics, including case control studies, retrospective cohort studies, retrospective studies, clinical trials studies, observational studies, prospective studies, randomized controlled trials, randomized clinical trials, systematic reviews, meta-analysis, and case reports.

INDEXING/ABSTRACTING

The WJCC is now indexed in PubMed, PubMed Central, Science Citation Index Expanded (also known as SciSearch®), and Journal Citation Reports/Science Edition. The 2019 Edition of Journal Citation Reports cites the 2018 impact factor for WJCC as 1.153 (5-year impact factor: N/A), ranking WJCC as 99 among 160 journals in Medicine, General and Internal (quartile in category Q3).

RESPONSIBLE EDITORS FOR THIS ISSUE

Responsible Electronic Editor: *Yan-Xia Xing*

Proofing Production Department Director: *Yun-Xiaojian Wu*

Responsible Editorial Office Director: *Jim-Lei Wang*

NAME OF JOURNAL

World Journal of Clinical Cases

ISSN

ISSN 2307-8960 (online)

LAUNCH DATE

April 16, 2013

FREQUENCY

Semimonthly

EDITORS-IN-CHIEF

Dennis A Bloomfield, Bao-Gan Peng, Sandro Vento

EDITORIAL BOARD MEMBERS

<https://www.wjgnet.com/2307-8960/editorialboard.htm>

PUBLICATION DATE

June 6, 2020

COPYRIGHT

© 2020 Baishideng Publishing Group Inc

INSTRUCTIONS TO AUTHORS

<https://www.wjgnet.com/bpg/gerinfo/204>

GUIDELINES FOR ETHICS DOCUMENTS

<https://www.wjgnet.com/bpg/GerInfo/287>

GUIDELINES FOR NON-NATIVE SPEAKERS OF ENGLISH

<https://www.wjgnet.com/bpg/gerinfo/240>

PUBLICATION ETHICS

<https://www.wjgnet.com/bpg/GerInfo/288>

PUBLICATION MISCONDUCT

<https://www.wjgnet.com/bpg/gerinfo/208>

ARTICLE PROCESSING CHARGE

<https://www.wjgnet.com/bpg/gerinfo/242>

STEPS FOR SUBMITTING MANUSCRIPTS

<https://www.wjgnet.com/bpg/GerInfo/239>

ONLINE SUBMISSION

<https://www.f6publishing.com>

Myxofibrosarcoma of the scalp with difficult preoperative diagnosis: A case report and review of the literature

Xiao-Ting Ke, Xiong-Feng Yu, Ji-Yang Liu, Fang Huang, Mei-Gui Chen, Qing-Quan Lai

ORCID number: Xiao-Ting Ke (0000-0002-3323-3260); Xiong-Feng Yu (0000-0001-5055-0287); Ji-Yang Liu (0000-0002-9858-0060); Fang Huang (0000-0002-3654-0725); Mei-Gui Chen (0000-0001-8903-4327); Qing-Quan Lai (0000-0001-5393-9503).

Author contributions: Ke XT participated in the design of the report, analyzed the data, and wrote the paper; Yu XF, Liu JY and Huang F collected the medical imaging materials; Chen MG and Lai QQ designed the report and performed the preliminary revision of the article.

Informed consent statement: Consent was obtained from the patient for publication of this report and any accompanying images.

Conflict-of-interest statement: The authors have no conflicts of interest to declare.

CARE Checklist (2016) statement: The authors have read the CARE Checklist (2016), and the manuscript was prepared and revised according to the CARE Checklist (2016).

Open-Access: This article is an open-access article that was selected by an in-house editor and fully peer-reviewed by external reviewers. It is distributed in accordance with the Creative Commons Attribution NonCommercial (CC BY-NC 4.0) license, which permits others to distribute, remix, adapt, build upon this work non-commercially, and license their derivative works

Xiao-Ting Ke, Xiong-Feng Yu, Ji-Yang Liu, Fang Huang, Mei-Gui Chen, Qing-Quan Lai, Department of CT/MRI, The Second Affiliated Hospital of Fujian Medical University, Quanzhou 362000, Fujian Province, China

Corresponding author: Qing-Quan Lai, MA, Associate Professor, Chief Physician, Department of CT/MRI, The Second Affiliated Hospital of Fujian Medical University, No. 34 Zhongshanbei Road, Licheng District, Quanzhou 362000, Fujian Province, China. laiqingquan888@163.com

Abstract

BACKGROUND

A myxofibrosarcoma (MFS) is a malignant fibroblastic tumor that tends to occur in the lower and upper extremities. The reported incidence of head and neck MFSs is extremely rare. We report a 46-year-old male with “a neoplasm in the scalp” who was hospitalized and diagnosed with an MFS (highly malignant with massive necrotic lesions) based on histologic and immunohistochemistry evaluations. The magnetic resonance imaging manifestations did not demonstrate the “tail sign” mentioned in several studies, which resulted in a great challenge to establish an imaging diagnosis. The treatment plan is closely associated with the anatomic location and histologic grade, and more importantly, aggressive surgery and adjuvant radiotherapy may be helpful. Hence, we report the case and share some valuable information about the disease.

CASE SUMMARY

A 46-year-old male with “a neoplasm in the scalp for 6 mo” was hospitalized. Initially, the tumor was about the size of a soybean, without algesia or ulceration. The patient ignored the growth, did not seek treatment, and thus, did not receive treatment. Recently, the tumor increased to the size of an egg; there was no bleeding or algesia. His family history was unremarkable. No abnormalities were found upon laboratory testing, including routine hematologic, biochemistry, and tumor markers. Computed tomography showed an ovoid mass (6.25 cm × 3.29 cm × 3.09 cm in size) in the left frontal scalp with low density intermingled with equidense strips in adjacent areas of the scalp. Magnetic resonance imaging revealed a lesion with an irregular surface and an approximate size of 3.55 cm × 6.34 cm in the left frontal region, with clear boundaries and visible separation. Adjacent areas of the skull were damaged and the dura mater was involved. Contrast enhancement showed an uneven enhancement pattern. Surgery was performed and postoperative adjuvant radiotherapy was administered to avoid recurrence or metastasis. The post-operative pathologic diagnosis confirmed an

on different terms, provided the original work is properly cited and the use is non-commercial. See: <http://creativecommons.org/licenses/by-nc/4.0/>

Manuscript source: Unsolicited manuscript.

Received: January 21, 2020

Peer-review started: January 21, 2020

First decision: April 14, 2020

Revised: April 17, 2020

Accepted: April 29, 2020

Article in press: April 29, 2020

Published online: June 6, 2020

P-Reviewer: El-Razek AA, Sawazaki H

S-Editor: Zhang L

L-Editor: Webster JR

E-Editor: Xing YX



MFS. A repeat computed tomography scan showed no local recurrence or distant metastasis 19 mo post-operatively.

CONCLUSION

The case reported herein of MFS was demonstrated in an extremely rare location on the scalp and had atypical magnetic resonance imaging findings, which serves as a reminder to radiologists of the possibility of this diagnosis to assist in clinical treatment. Given the special anatomic location and the high malignant potential of this rare tumor, combined surgical and adjuvant radiotherapy should be considered to avoid local recurrence and distant metastasis. The significance of regular follow-up is strongly recommended to improve the long-term survival rate.

Key words: Malignant fibrous histiocytoma; Myxofibrosarcoma; Scalp; Magnetic resonance imaging; Treatment; Case report

©The Author(s) 2020. Published by Baishideng Publishing Group Inc. All rights reserved.

Core tip: Myxofibrosarcoma (MFS) is a malignant fibroblastic tumor that has a predilection for lower and upper extremities. Rare occurrences have been reported in the scalp. We describe a 46-year-old male diagnosed with a MFS of the scalp (highly malignant with massive necrotic lesions) by histologic examination and immunohistochemistry testing. The magnetic resonance imaging findings did not conform to the reported typical “tail sign”, which may be confused with other tumors and lead to the correct diagnosis being missed. The definitive diagnosis of MFS is based on immunohistologic features. Considering the location and non-specific imaging manifestations of this case, the treatment is also worthy of discussion. Surgical excision combined with postoperative adjuvant radiotherapy was effective in our case.

Citation: Ke XT, Yu XF, Liu JY, Huang F, Chen MG, Lai QQ. Myxofibrosarcoma of the scalp with difficult preoperative diagnosis: A case report and review of the literature. *World J Clin Cases* 2020; 8(11): 2350-2358

URL: <https://www.wjnet.com/2307-8960/full/v8/i11/2350.htm>

DOI: <https://dx.doi.org/10.12998/wjcc.v8.i11.2350>

INTRODUCTION

Myxofibrosarcoma (MFS) is a fibroblast malignant tumor with a matrix of myxoid, visible arc-like vessels, and tumor cells showing varying degrees of atypia. A MFS is the most common soft tissue sarcoma that appears in late adult life, is mainly a low-grade malignancy, and occurs primarily in the lower extremities (77%), followed by the trunk (12%), and retroperitoneum or mediastinum (8%)^[1]. Rare occurrences have been reported in the cranial cavity^[2], orbit^[3], maxilla^[4], parotid gland^[5], hypopharynx^[6], sinus piriformis^[7], vocal folds^[8], thyroid gland^[9], esophagus^[10], breast^[2], heart^[11], aorta^[2], scapular region^[12], buttock^[13], scrotum^[14], pterygopalatine fossa^[1,2], liver^[2], and scalp. MFS of the scalp is extremely rare. We report a case of MFS of the scalp. A 46-year-old male with “a neoplasm in the scalp” was hospitalized and diagnosed with an MFS (highly malignant with massive necrotic lesions) by histologic evaluation and immunohistochemistry testing. A computed tomography (CT) scan and magnetic resonance imaging (MRI) indicated a mass in the scalp, but no typical “tail sign” was observed. Due to the lack of characteristic imaging features and the extremely unusual location, the diagnosis was missed. Lefkowitz *et al*^[15] reported that the “tail sign” cannot be considered of diagnostic value for MFS as the sensitivity and specificity were approximately 80%. This case had unusual imaging findings. Moreover, the treatment for MFS is a matter of international discussion. In our case, aggressive surgery and adjuvant radiotherapy was effective. Therefore, we describe a 46-year-old male with a rare case of MFS originating from the scalp and report the unusual imaging findings to offer some reference for researchers. We discuss the MRI findings, treatment, and histologic evaluation and immunohistochemical testing in this rare case.

CASE PRESENTATION

Chief complaints

A 46-year-old male with “a neoplasm in the scalp for 6 mo” was hospitalized.

History of past illness

His medical history was unremarkable.

Personal and family histories

His family history was unremarkable.

Physical examination upon admission

On physical examination, a mass on the left forehead was palpated and measured approximately 6 cm × 3 cm. The tumor was hard without algesia or ulcerations.

Laboratory examinations

No abnormalities were found on laboratory examinations, including routine hematologic, biochemistry, and tumor markers.

Imaging examinations

A CT scan (Figure 1) showed an ovoid mass approximately 6.25 cm × 3.29 cm × 3.09 cm in the left frontal scalp with low density intermingled with equidense strips involving adjacent areas of the scalp. Contrast enhancement showed an uneven enhancement pattern. MRI (Figure 2) revealed a lesion in the left frontal region with an irregular surface, approximately 3.55 cm × 6.34 cm in size, and clear boundaries and visible separation. The adjacent skull was damaged and the dura mater was involved. The images of different sequences are as follows: T1, complex signal with dramatic low signal; T2, complex signal with dramatic high signal; T2 FLAIR, high marginal and low central signals; and DWI, high marginal and low central signals. The specimen (Figure 3) was visible to the naked eye as a mass in the scalp involving the skull and approximately 7.5 cm × 6.0 cm × 3.0 cm in size. Histologically (Figure 4), there were abundant heteromorphic spindle cells and partial nodular mucus arranged in a woven pattern with rare nuclear fission and abundant blood vessels in the interstitium. Immunohistochemical stains demonstrated the following: Vim (+); SMA (+); S-100 (-); GFAP (-); CD34 (+); and Ki-67 (+).

FINAL DIAGNOSIS

Myxofibrosarcoma of the scalp.

TREATMENT

A tumor resection (superficial) and cranioplasty were performed under general anesthesia. A horseshoe incision was made, approximately 24 cm in length, in the left frontotemporal parietal. The scalp was incised to the periosteum and the subcutaneous tumor was separated along the tumor margin. The tumor boundaries were clear and approximately 6.5 cm × 4.0 cm × 4.5 cm in size. Following surgery, the patient was returned to the ward in a stable condition. Subsequently, the patient underwent appropriate radiotherapy.

OUTCOME AND FOLLOW-UP

After surgery and subsequent radiotherapy, the patient recovered uneventfully without local recurrence or distant metastasis during a 19-mo follow-up period.

DISCUSSION

MFS is a type of malignant tumor with an unknown etiology that occurs in late adult life and mainly affects the lower and upper extremities, followed by the trunk, and retroperitoneum or mediastinum. The occurrence of head and neck MFS is rare, with a reported incidence of 2%-4%^[16]. Only 21 cases of MFS in the head and neck have been reported in the literature, the clinical features of which (including our case) are summarized in Table 1.

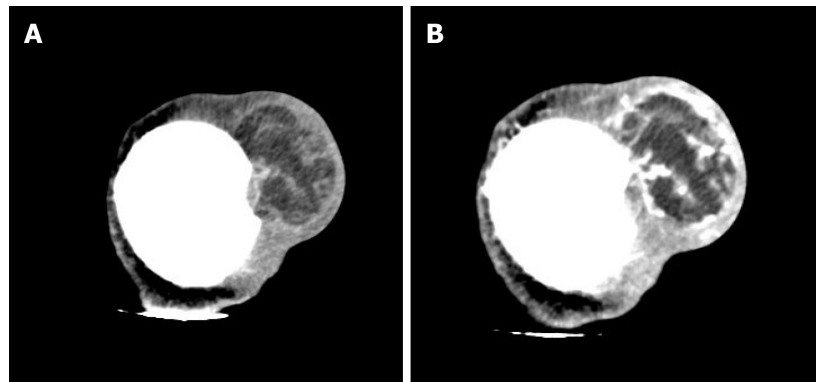


Figure 1 Computed tomography image of the patient. A: Computed tomography scan revealed that an ovoid mass with mixed density 6.25 cm × 3.29 cm × 3.09 cm in size was detected in the left frontal scalp, with low density intermingled with equidense strips involving the adjacent skull; B: Contrast enhanced computed tomography scan showed an uneven enhancement pattern.

It as shown in Table 1^[17-30], there was no significant difference in the incidence of MFS in the head and neck between men and women. The age ranged from 23-87 years, and the median age was 52 years. The prognosis varied greatly depending on the time of discovery and the degree of malignancy. MFS of the scalp has not been reported; thus, the diagnosis of MFS by radiologists is difficult.

To our knowledge, a large volume, extracompartmental extension, broad interface with the underlying fascia, inhomogeneous MR signal intensity, high signal intensity on T2-weighted MR images, invasion of bone or neurovascular structures, intratumoral necrosis, and marked, primarily peripheral enhancement have been reported in the literature as malignant imaging features of soft tissue tumors^[31]. The mucous component of MFS, including more water molecules, shows a higher signal at T2. The degree of high signals in T2 varies with the proportion of the mucinous component in the tumor. MRI findings of MSF contribute to establishing a diagnosis. In T2-weighted MRI, the infiltrative spread of the tumor along the fascial plane is manifested by a curvilinear shape, commonly defined as a “tail,” which extends from the primary mass of the MFS^[32]; however, in several studies, MFS with a “tail-like” pattern is significantly related to a superficial (subcutaneous) origin^[15]. In our case, MRI revealed a lesion with an irregular surface and a size of approximately 3.55 cm × 6.34 cm in the left frontal region, with clear boundaries and visible separation. The adjacent skull was damaged and the dura mater was involved. The MFS of the scalp of this case was a tumor of superficial (subcutaneous) origin, but the relevant MRI findings did not conform to the so-called “tail-like” pattern. Such atypical imaging findings, combined with the uncommon location, may lead radiologists to miss the correct diagnosis. Therefore, it is crucial to differentiate a MFS from other tumors with similar MRI findings, such as a low-grade fibromyxoid sarcoma (LGFS). MFS shares similar characteristics with LGFS on T1 low signals, T2 mixed signals, and an enhancing pattern; thus, the histopathologic features are required to identify a MFS^[33]. In addition, compared with the apparent diffusion coefficient (ADC) value of non-myxoid tumors, that of mucinous tumors is obviously high, and DWI MR imaging has been testified as a helpful way to assess the composition of tumor cells in soft tissue sarcomas^[34]. Surov *et al*^[35] indicated that sarcomas require further study using a standardized MR program to compare the ADC values of various types of sarcomas. This idea may provide a new way for researchers to study MR of MFS in the future.

MFS can be diagnosed accurately based on immunohistologic and ultrastructural studies^[16]. Histologically, myxoid cells are mixed with spindle cells. The spindle cell area is characterized by large atypical cells and more mitotic features. Mononuclear or multinucleate giant cells, curved blood vessels, spoke-like structures, and inflammatory cells are observed^[32]. MFS is classified into low-grade tumors with low metastatic potential and high-grade tumors^[16]. The specimen in our case was visible to the naked eye as a mass on the scalp involving the skull and approximately 7.5 cm × 6.0 cm × 3.0 cm in size. Histologically, there were abundant heteromorphic spindle cells and partial nodular mucus arranged in a woven pattern with rare nuclear fission and abundant blood vessels in the interstitium. Immunohistochemical staining demonstrated the following: Vim (+); SMA (+); S-100 (-); GFAP (-); CD34 (+); and Ki-67 (+). The histologic features combined with immunohistochemical findings in our case were consistent with mucinous fibrosarcoma (highly malignant with massive necrotic lesions). Based on the FNCLCC system, this MFS in the scalp was grade 3. In

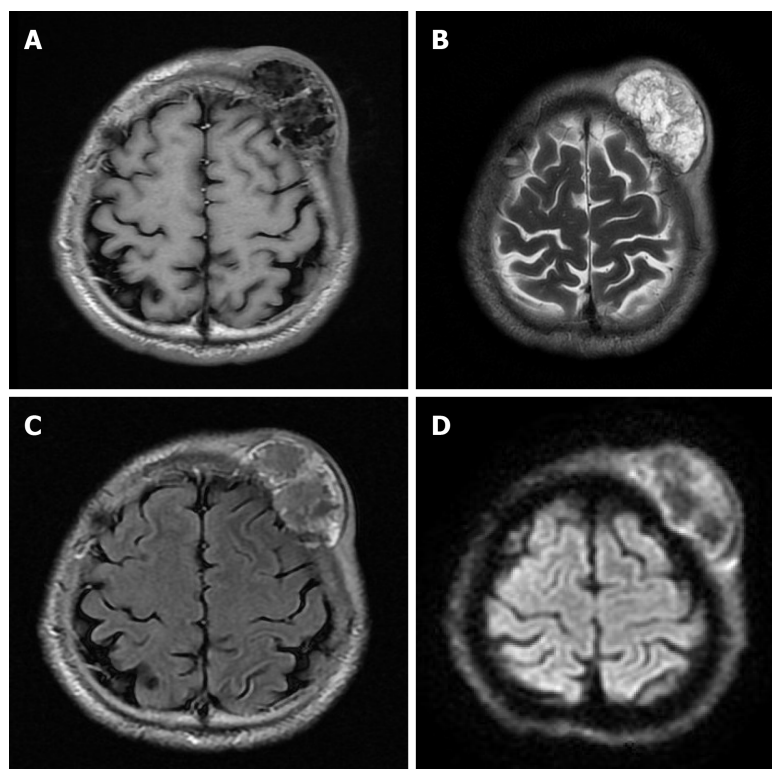


Figure 2 The magnetic resonance imaging revealed an irregular lesion, approximately 3.55 cm × 6.34 cm in size, in the left frontal region with clear boundaries and visible separation. The adjacent skull was damaged and the dura mater was involved. A: T1 showed complex signal with a dramatic low signal; B: T2 showed complex signal with a dramatic high signal; C: T2 FLAIR showed high marginal and low central signals; D: DWI showed high marginal and low central signals.

addition, the histologic findings and evaluation provided several options for the differential diagnosis, such as neurilemoma, dedifferentiated liposarcoma, and fibromatosis^[16]. A MFS of grade 2-3 can be differentiated from dedifferentiated liposarcoma by immunohistochemical staining; the latter has distinctive immunohistochemical stains that are strongly positive for CKD4 and MDM2^[36]. The characteristic histopathologic features of neurilemoma are the presence of abundant Wagner-Meissner corpuscle-like structures and a lack of neoplastic spindle cell nests, as seen in conventional neurofibroma and diffusely positive for S-100 by immunohistochemical analysis^[37].

Based on a literature review, there has been no internationally uniform conclusion on the treatment of MFS. As far as malignant tumors are concerned, intact mass excision is advised. Additionally, the value of pre- and post-operative chemotherapy and radiotherapy is still being discussed^[38]. Over the past several decades, progress in understanding sarcoma management has promoted the application of combined modality therapies to improve survival. FNCLCC grade plays a significant role in the treatment and prognosis. Therefore, the grade should be an important reference basis for clinical treatment. Some researchers have suggested that local radiotherapy of the mass for patients with FNCLCC grade 1-2 and grade 3 may be supplemented by appropriate chemotherapy and other treatments. Several studies have proposed significant reference factors for local recurrence and metastases, including tumor size, depth, extent of histologic myxoid areas, mitotic rate, and grade^[15,32]. It is reported that the high rates of local recurrence of MFS are 50%-60% and distal metastases are significantly more common with high-grade MFS at a rate of 33%^[16]. Given the highly malignant MFS in our case, combined with the anatomic location, size, and other factors, surgery was performed and adjuvant radiotherapy was delivered to avoid local and distant recurrences. Importantly, follow-up should be encouraged. The patient recovered without complications, without local recurrence and distant metastases after a follow-up period of 19 mo. Although there is no gold standard of treatment, a complete tumor resection with sufficient resection margins, assisted by adjuvant radiotherapy, may be effective. Dell'Aversana Orabona *et al*^[1] has proposed that a possible re-excision of recurrent lesions is a way to enhance survival. Additionally, the recognition of the “tail” on MRI may be valuable in pre-operative planning to ameliorate the quality of the excision, thus, reducing the risk of local

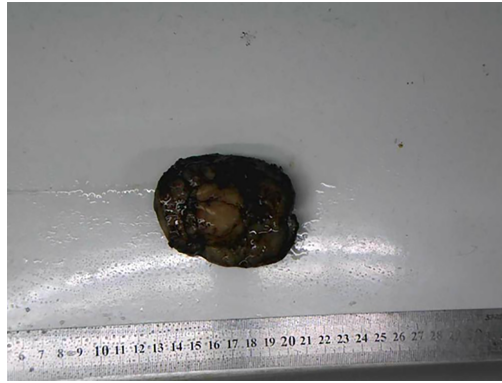

Figure 3 A mass of the scalp involving the skull approximately 7.5 cm × 6.0 cm × 3.0 cm in size.

recurrence^[15,32]. The treatment for MSF of the scalp (highly malignant) without a “tail sign” reported in this case may provide a reference for subsequent cases that are equally atypical.

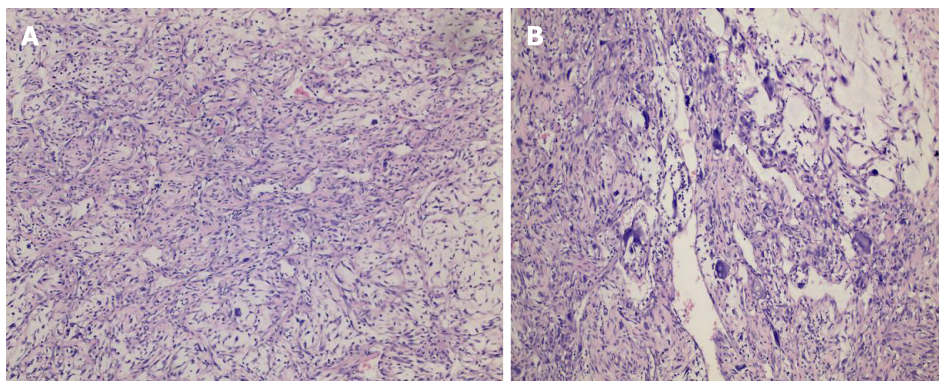
CONCLUSION

The case reported herein of MFS occurred in an extremely rare location on the scalp and had atypical MRI findings, which serves as a reminder to radiologists of the possibility of this diagnosis to assist in clinical treatment. Although there is no gold standard of treatment, a complete tumor resection with clear resection margins, assisted by adjuvant radiotherapy, may be effective.

Table 1 Clinical features of head and neck myxofibrosarcoma

Patient	Ref.	Sex/age	Location	Treatment	Results
1	Blitzer <i>et al</i> ^[17] , 1981	Male/66	Sphenoid sinus	Radiotherapy	Died after 3 mo
2	Pomerantz <i>et al</i> ^[18] , 1982	Male/58	Maxillary sinus	Surgery	Unknown
3	Barnes and Kanbour ^[19] , 1988	Female/67	Sphenoid sinus-cavernous sinus	Surgery, adjuvant radiotherapy	Alive after 8 mo
4	Imai <i>et al</i> ^[20] , 2000	Female/52	Orbit	Surgery	NA
5	Iguchi <i>et al</i> ^[21] , 2002	Male/NA	Maxillary	NA	NA
6	Song and Miller ^[10] , 2002	Male/40	Esophagus	Surgery	NA
7	Nishimura <i>et al</i> ^[6] , 2006	Male/69	Hypopharynx	Surgery	Alive after 16 mo
8	Udaka <i>et al</i> ^[22] , 2006	Male/55	Neck	Surgery	Alive after 27 mo
9	Enoz and Suoglu ^[23] , 2007	Female/36	Maxillary sinus	Surgery	Alive after 2 yr
10	Gugatschka <i>et al</i> ^[8] , 2010	Male/79	Vocal folds	Surgery	NA
11	Li <i>et al</i> ^[5] , 2010	Female/37	Parotid	Surgery, radiotherapy	Alive after 8 mo
12	Zhang <i>et al</i> ^[24] , 2010	Female/27	Orbit	Surgery, radiotherapy	Alive after 6 mo
13	Zouloumis <i>et al</i> ^[25] , 2010	Male/23	Mandible	Surgery, radiotherapy	Alive 39 mo
14	Norval <i>et al</i> ^[26] , 2011	Male/69	Maxillary sinus	Radiotherapy, chemotherapy	Died after 1 yr
15	Srinivasan <i>et al</i> ^[27] , 2011	Female/78	Parotid	Surgery, radiotherapy	Died after 24 mo
16	Krishnamurthy <i>et al</i> ^[28] , 2011	Female/42	Infratemporal space	Surgery, radiotherapy	Alive after 26 mo
17	Nakahara <i>et al</i> ^[4] , 2012	Male/52	Maxilla	Surgery, radiotherapy	Alive after 20 mo
18	Qiubei <i>et al</i> ^[7] , 2012	Male/42	Hypopharynx	Surgery	NA
19	Dell'Aversana Orabona <i>et al</i> ^[30] , 2014	Male/35	Pterygopalatine fossa	Surgery, radiotherapy	Alive after 27 mo
20	Wong <i>et al</i> ^[29] , 2017	Female/61	Maxillary sinus	Surgery, radiotherapy	NA
21	Clair <i>et al</i> ^[30] , 2018	Female/87	Orbit	Surgery, radiotherapy	Alive after 48 mo
22	Present case	Male/46	Scalp	Surgery, radiotherapy	Alive after 19 mo

NA: Not available.

**Figure 4** Pathologic images of the mass. Histologic evaluation showed that there were abundant heteromorphous spindle cells and partial nodular mucus, arranged in a woven pattern, with rare nuclear fission and abundant blood vessels in the interstitium (A: Hematoxylin-eosin staining, × 100, B: Hematoxylin-eosin staining, × 200).

REFERENCES

- 1 Dell'Aversana Orabona G, Iaconetta G, Abbate V, Piombino P, Romano A, Maglito F, Salzano G, Califano L. Head and neck myxofibrosarcoma: a case report and review of the literature. *J Med Case Rep* 2014; **8**: 468 [PMID: 25547541 DOI: 10.1186/1752-1947-8-468]
- 2 Shao Z, Jiao B, Yu J, Liu H. Primary low grade myxofibrosarcoma of the liver with benign presentation but malignant outcome: a case report. *BMC Cancer* 2019; **19**: 1098 [PMID: 31718576 DOI: 10.1186/s12885-019-6282-0]
- 3 Pujari A, Ali MJ, Honavar SG, Mittal R, Naik M. Orbital myxofibrosarcoma: a clinicopathologic correlation of an extremely rare tumor. *Ophthalmic Plast Reconstr Surg* 2014; **30**: e111-e113 [PMID: 24833459 DOI: 10.1097/IOP.0b013e3182a230cc]
- 4 Nakahara S, Uemura H, Kurita T, Suzuki M, Fujii T, Tomita Y, Yoshino K. A case of myxofibrosarcoma of the maxilla with difficulty in preoperative diagnosis. *Int J Clin Oncol* 2012; **17**: 390-394 [PMID: 21830085 DOI: 10.1007/s10147-011-0302-7]

- 5 **Li X**, Chen X, Shi ZH, Chen Y, Ye J, Qiao L, Qiu JH. Primary myxofibrosarcoma of the parotid: case report. *BMC Cancer* 2010; **10**: 246 [PMID: [20513245](#) DOI: [10.1186/1471-2407-10-246](#)]
- 6 **Nishimura G**, Sano D, Hanashi M, Yamanaka S, Tanigaki Y, Taguchi T, Horiuchi C, Matsuda H, Mikami Y, Tsukuda M. Myxofibrosarcoma of the hypopharynx. *Auris Nasus Larynx* 2006; **33**: 93-96 [PMID: [16183234](#) DOI: [10.1016/j.anl.2005.07.004](#)]
- 7 **Qiubei Z**, Cheng L, Yaping X, Shunzhang L, Jingping F. Myxofibrosarcoma of the sinus piriformis: case report and literature review. *World J Surg Oncol* 2012; **10**: 245 [PMID: [23152982](#) DOI: [10.1186/1477-7819-10-245](#)]
- 8 **Gugatschka M**, Beham A, Stammberger H, Schmid C, Friedrich G. First case of a myxofibrosarcoma of the vocal folds: case report and review of the literature. *J Voice* 2010; **24**: 374-376 [PMID: [19664897](#) DOI: [10.1016/j.jvoice.2008.10.008](#)]
- 9 **Darouassi Y**, Attifi H, Zalagh M, Rharrassi I, Benariba F. Myxofibrosarcoma of the thyroid gland. *Eur Ann Otorhinolaryngol Head Neck Dis* 2014; **131**: 385-387 [PMID: [24702999](#) DOI: [10.1016/j.anorl.2013.09.004](#)]
- 10 **Song HK**, Miller JI. Primary myxofibrosarcoma of the esophagus. *J Thorac Cardiovasc Surg* 2002; **124**: 196-197 [PMID: [12091833](#) DOI: [10.1067/mtc.2002.122818](#)]
- 11 **Sanchez-Urbe M**, Retamero JA, Gomez Leon J, Montoya Perez J, Quiñonez E. Primary intermediate-grade cardiac myxofibrosarcoma with osseous metaplasia: an extremely rare occurrence with a previously unreported feature. *Cardiovasc Pathol* 2014; **23**: 376-378 [PMID: [25246023](#) DOI: [10.1016/j.carpath.2014.07.006](#)]
- 12 **Sakamoto A**, Shiba E, Hisaoka M. Short-term spontaneous regression of myxofibrosarcoma in the scapular region. *Skeletal Radiol* 2014; **43**: 1487-1490 [PMID: [24910124](#) DOI: [10.1007/s00256-014-1914-6](#)]
- 13 **Picardo NE**, Mann B, Whittingham-Jones P, Shaerf D, Skinner JA, Saifuddin A. Bilateral symmetrical metachronous myxofibrosarcoma: a case report and review of the literature. *Skeletal Radiol* 2011; **40**: 1085-1088 [PMID: [21331510](#) DOI: [10.1007/s00256-011-1123-5](#)]
- 14 **Ozkan B**, Özgüroğlu M, Ozkara H, Durak H, Talat Z. Adult paratesticular myxofibrosarcoma: report of a rare entity and review of the literature. *Int Urol Nephrol* 2006; **38**: 5-7 [PMID: [16502045](#) DOI: [10.1007/s11255-005-0255-8](#)]
- 15 **Lefkowitz RA**, Landa J, Hwang S, Zabor EC, Moskowitz CS, Agaram NP, Panicek DM. Myxofibrosarcoma: prevalence and diagnostic value of the "tail sign" on magnetic resonance imaging. *Skeletal Radiol* 2013; **42**: 809-818 [PMID: [23318907](#) DOI: [10.1007/s00256-012-1563-6](#)]
- 16 **Quimby A**, Estelle A, Gopinath A, Fernandes R. Myxofibrosarcoma in Head and Neck: Case Report of Unusually Aggressive Presentation. *J Oral Maxillofac Surg* 2017; **75**: 2709.e1-2709.e12 [PMID: [28893544](#) DOI: [10.1016/j.joms.2017.08.015](#)]
- 17 **Blitzer A**, Lawson W, Zak FG, Biller HF, Som ML. Clinical-pathological determinants in prognosis of fibrous histiocytomas of head and neck. *Laryngoscope* 1981; **91**: 2053-2070 [PMID: [6275219](#) DOI: [10.1288/00005537-198112000-00008](#)]
- 18 **Pomerantz JM**, Sanfacon DG, Dougherty TP, Hanson S. Myxofibrosarcoma of the maxillary sinus. *Del Med J* 1982; **54**: 147-152 [PMID: [7067862](#)]
- 19 **Barnes L**, Kanbour A. Malignant fibrous histiocytoma of the head and neck. A report of 12 cases. *Arch Otolaryngol Head Neck Surg* 1988; **114**: 1149-1156 [PMID: [2843204](#) DOI: [10.1001/archotol.1988.01860220083030](#)]
- 20 **Imai Y**, Sugawara Y, Okazaki M, Harii K. Low grade myxofibrosarcoma in the orbit: a case report. *Japanese J Plastic Reconstructive Surg* 2000; **43**: 401-409
- 21 **Iguchi Y**, Takahashi H, Yao K, Nakayama M, Nagai H, Okamoto M. Malignant fibrous histiocytoma of the nasal cavity and paranasal sinuses: review of the last 30 years. *Acta Otolaryngol Suppl* 2002; **75**: 78 [PMID: [12212601](#) DOI: [10.1080/000164802760057635](#)]
- 22 **Udaka T**, Yamamoto H, Shiomi T, Fujimura T, Suzuki H. Myxofibrosarcoma of the neck. *J Laryngol Otol* 2006; **120**: 872-874 [PMID: [17038234](#) DOI: [10.1017/S0022215106001113](#)]
- 23 **Enoz M**, Suoglu Y. Myxofibrosarcoma of the maxillary sinus. *Int J Head Neck Surg* 2007; **1**: 1-4
- 24 **Zhang Q**, Wojno TH, Yaffe BM, Grossniklaus HE. Myxofibrosarcoma of the orbit: a clinicopathologic case report. *Ophthalmic Plast Reconstr Surg* 2010; **26**: 129-131 [PMID: [20305519](#) DOI: [10.1097/IOP.0b013e3181b8efee](#)]
- 25 **Zouloumis L**, Ntomouchtsis A, Lazaridis N. Giant myxofibrosarcoma of the mandible. *Balkan J Stomatol* 2010; **14**: 41-44
- 26 **Norval EJ**, Raubenheimer EJ. Myxofibrosarcoma arising in the maxillary sinus: a case report with a review of the ultrastructural findings and differential diagnoses. *J Maxillofac Oral Surg* 2011; **10**: 334-339 [PMID: [23204750](#) DOI: [10.1007/s12663-011-0259-0](#)]
- 27 **Srinivasan B**, Ethunandan M, Hussain K, Ilankovan V. Epithelioid myxofibrosarcoma of the parotid gland. *Case Rep Pathol* 2011; **2011**: 641621 [PMID: [22937388](#) DOI: [10.1155/2011/641621](#)]
- 28 **Krishnamurthy A**, Vaidhyanathan A, Majhi U. Myxofibrosarcoma of the infratemporal space. *J Cancer Res Ther* 2011; **7**: 185-188 [PMID: [21768709](#) DOI: [10.4103/0973-1482.82913](#)]
- 29 **Wong A**, Chan Woo Park R, Mirani NM, Eloy JA. Myxofibrosarcoma of the maxillary sinus. *Allergy Rhinol (Providence)* 2017; **8**: 95-99 [PMID: [28583233](#) DOI: [10.2500/ar.2017.8.0200](#)]
- 30 **Clair BC**, Salloum G, Carruth BP, Bersani TA, Hill RH. Orbital Myxofibrosarcoma: Case Report and Review of Literature. *Ophthalmic Plast Reconstr Surg* 2018; **34**: e180-e182 [PMID: [30204636](#) DOI: [10.1097/IOP.0000000000001219](#)]
- 31 **Razek AA**, Huang BY. Soft tissue tumors of the head and neck: imaging-based review of the WHO classification. *Radiographics* 2011; **31**: 1923-1954 [PMID: [22084180](#) DOI: [10.1148/rg.317115095](#)]
- 32 **Sambri A**, Spinnato P, Bazzocchi A, Tuzzato GM, Donati D, Bianchi G. Does pre-operative MRI predict the risk of local recurrence in primary myxofibrosarcoma of the extremities? *Asia Pac J Clin Oncol* 2019; **15**: e181-e186 [PMID: [31111597](#) DOI: [10.1111/ajco.13161](#)]
- 33 **Yue Y**, Liu Y, Song L, Chen X, Wang Y, Wang Z. MRI findings of low-grade fibromyxoid sarcoma: a case report and literature review. *BMC Musculoskelet Disord* 2018; **19**: 65 [PMID: [29482535](#) DOI: [10.1186/s12891-018-1976-z](#)]
- 34 **Razek A**, Nada N, Ghaniem M, Elkhamary S. Assessment of soft tissue tumours of the extremities with diffusion echoplanar MR imaging. *Radiol Med* 2012; **117**: 96-101 [PMID: [21744251](#) DOI: [10.1007/s11547-011-0709-2](#)]
- 35 **Surov A**, Nagata S, Razek AA, Tirumani SH, Wienke A, Kahn T. Comparison of ADC values in different malignancies of the skeletal musculature: a multicentric analysis. *Skeletal Radiol* 2015; **44**: 995-1000

- [PMID: 25916616 DOI: 10.1007/s00256-015-2141-5]
- 36 **Shen J**, Fang Z, Zhang Y, Hou J. In-situ recurrence of the primary cardiac dedifferentiated liposarcoma: To resect or not? *J Card Surg* 2020; **35**: 495-498 [PMID: 31803967 DOI: 10.1111/jocs.14394]
- 37 **Miyasaka C**, Ishida M, Kouchi Y, Morimoto N, Kusumoto K, Okabe H, Tsuta K. Wagner-Meissner neurilemmoma of the lip occurring in a patient with neurofibromatosis type 1: A case report. *Mol Clin Oncol* 2020; **12**: 41-43 [PMID: 31814976 DOI: 10.3892/mco.2019.1944]
- 38 **Look Hong NJ**, Hornicek FJ, Raskin KA, Yoon SS, Szymonifka J, Yeap B, Chen YL, DeLaney TF, Nielsen GP, Mullen JT. Prognostic factors and outcomes of patients with myxofibrosarcoma. *Ann Surg Oncol* 2013; **20**: 80-86 [PMID: 22890594 DOI: 10.1245/s10434-012-2572-3]



Published by Baishideng Publishing Group Inc
7041 Koll Center Parkway, Suite 160, Pleasanton, CA 94566, USA
Telephone: +1-925-3991568
E-mail: bpgoffice@wjgnet.com
Help Desk: <https://www.f6publishing.com/helpdesk>
<https://www.wjgnet.com>

