

World Journal of *Clinical Cases*

World J Clin Cases 2020 June 6; 8(11): 2066-2407



**REVIEW**

- 2066** Tumor circulome in the liquid biopsies for digestive tract cancer diagnosis and prognosis
Chen L, Chen Y, Feng YL, Zhu Y, Wang LQ, Hu S, Cheng P
- 2081** Isoflavones and inflammatory bowel disease
Wu ZY, Sang LX, Chang B

MINIREVIEWS

- 2092** Cytapheresis for pyoderma gangrenosum associated with inflammatory bowel disease: A review of current status
Tominaga K, Kamimura K, Sato H, Ko M, Kawata Y, Mizusawa T, Yokoyama J, Terai S
- 2102** Altered physiology of mesenchymal stem cells in the pathogenesis of adolescent idiopathic scoliosis
Ko DS, Kim YH, Goh TS, Lee JS
- 2111** Association between liver targeted antiviral therapy in colorectal cancer and survival benefits: An appraisal
Wang Q, Yu CR
- 2116** Peroral endoscopic myotomy for management of gastrointestinal motility disorder
Feng Z, Liu ZM, Yuan XL, Ye LS, Wu CC, Tan QH, Hu B

ORIGINAL ARTICLE**Case Control Study**

- 2127** Clinical prediction of complicated appendicitis: A case-control study utilizing logistic regression
Sasaki Y, Komatsu F, Kashima N, Suzuki T, Takemoto I, Kijima S, Maeda T, Miyazaki T, Honda Y, Zai H, Shimada N, Funahashi K, Urita Y
- 2137** Clinical application of ultrasound-guided selective proximal and distal brachial plexus block in rapid rehabilitation surgery for hand trauma
Zhang J, Li M, Jia HB, Zhang L
- 2144** High flux hemodialysis in elderly patients with chronic kidney failure
Xue HY, Duan B, Li ZJ, Du P
- 2150** Determination of vitamin D and analysis of risk factors for osteoporosis in patients with chronic pain
Duan BL, Mao YR, Xue LQ, Yu QY, Liu MY

Retrospective Study

- 2162** Differences in parents of pediatric liver transplantation and chronic liver disease patients
Akbulut S, Gunes G, Saritas H, Aslan B, Karipkiz Y, Demyati K, Gungor S, Yilmaz S
- 2173** Epidemiological investigation of *Helicobacter pylori* infection in elderly people in Beijing
Zhu HM, Li BY, Tang Z, She J, Liang XY, Dong LK, Zhang M
- 2181** Application of a pre-filled tissue expander for preventing soft tissue incarceration during tibial distraction osteogenesis
Chen H, Teng X, Hu XH, Cheng L, Du WL, Shen YM
- 2190** Evaluation of clinical significance of claudin 7 and construction of prognostic grading system for stage II colorectal cancer
Quan JC, Peng J, Guan X, Liu Z, Jiang Z, Chen HP, Zhuang M, Wang S, Sun P, Wang HY, Zou SM, Wang XS
- 2201** Choice and management of negative pressure drainage in anterior cervical surgery
Su QH, Zhu K, Li YC, Chen T, Zhang Y, Tan J, Guo S
- 2210** Risk scores, prevention, and treatment of maternal venous thromboembolism
Zhang W, Shen J, Sun JL
- 2219** Role of Hiraoka's transurethral detachment of the prostate combined with biopsy of the peripheral zone during the same session in patients with repeated negative biopsies in the diagnosis of prostate cancer
Pan CY, Wu B, Yao ZC, Zhu XQ, Jiang YZ, Bai S
- 2227** Efficacy of thoracoscopic anatomical segmentectomy for small pulmonary nodules
Li H, Liu Y, Ling BC, Hu B

Observational Study

- 2235** Attitudes, awareness, and knowledge levels of the Turkish adult population toward organ donation: Study of a nationwide survey
Akbulut S, Ozer A, Gokce A, Demyati K, Saritas H, Yilmaz S
- 2246** Metabolic biomarkers and long-term blood pressure variability in military young male adults
Lin YK, Liu PY, Fan CH, Tsai KZ, Lin YP, Lee JM, Lee JT, Lin GM
- 2255** Cytokines predict virological response in chronic hepatitis B patients receiving peginterferon alfa-2a therapy
Fu WK, Cao J, Mi NN, Huang CF, Gao L, Zhang JD, Yue P, Bai B, Lin YY, Meng WB

SYSTEMATIC REVIEWS

- 2266** Utilising digital health to improve medication-related quality of care for hypertensive patients: An integrative literature review
Wechkunanukul K, Parajuli DR, Hamiduzzaman M

META-ANALYSIS

- 2280** Role of *IL-17* gene polymorphisms in osteoarthritis: A meta-analysis based on observational studies
Yang HY, Liu YZ, Zhou XD, Huang Y, Xu NW

CASE REPORT

- 2294** Various diagnostic possibilities for zygomatic arch pain: Seven case reports and review of literature
Park S, Park JW
- 2305** Extensive multifocal and pleomorphic pulmonary lesions in Waldenström macroglobulinemia: A case report
Zhao DF, Ning HY, Cen J, Liu Y, Qian LR, Han ZH, Shen JL
- 2312** Lung cancer from a focal bulla into thin-walled adenocarcinoma with ground glass opacity – an observation for more than 10 years: A case report
Meng SS, Wang SD, Zhang YY, Wang J
- 2318** Pyogenic discitis with an epidural abscess after cervical analgesic discography: A case report
Wu B, He X, Peng BG
- 2325** Clinical characteristics, diagnosis, and treatment of COVID-19: A case report
He YF, Lian SJ, Dong YC
- 2332** Paraplegia after transcatheter artery chemoembolization in a child with clear cell sarcoma of the kidney: A case report
Cai JB, He M, Wang FL, Xiong JN, Mao JQ, Guan ZH, Li LJ, Wang JH
- 2339** Macrophage activation syndrome as a complication of dermatomyositis: A case report
Zhu DX, Qiao JJ, Fang H
- 2345** Serial computed tomographic findings and specific clinical features of pediatric COVID-19 pneumonia: A case report
Chen X, Zou XJ, Xu Z
- 2350** Myxofibrosarcoma of the scalp with difficult preoperative diagnosis: A case report and review of the literature
Ke XT, Yu XF, Liu JY, Huang F, Chen MG, Lai QQ
- 2359** Endoscopic pedicle flap grafting in the treatment of esophageal fistulas: A case report
Zhang YH, Du J, Li CH, Hu B
- 2364** Hemophagocytic syndrome as a complication of acute pancreatitis: A case report
Han CQ, Xie XR, Zhang Q, Ding Z, Hou XH
- 2374** Reduced delay in diagnosis of odontogenic keratocysts with malignant transformation: A case report
Luo XJ, Cheng ML, Huang CM, Zhao XP

- 2380** Gastric pyloric gland adenoma resembling a submucosal tumor: A case report
Min CC, Wu J, Hou F, Mao T, Li XY, Ding XL, Liu H
- 2387** Ataxia-telangiectasia complicated with Hodgkin's lymphoma: A case report
Li XL, Wang YL
- 2392** Uterine incision dehiscence 3 mo after cesarean section causing massive bleeding: A case report
Zhang Y, Ma NY, Pang XA
- 2399** Optical coherence tomography guided treatment avoids stenting in an antiphospholipid syndrome patient: A case report
Du BB, Wang XT, Tong YL, Liu K, Li PP, Li XD, Yang P, Wang Y

LETTER TO THE EDITOR

- 2406** Macrophage activation syndrome as an initial presentation of systemic lupus erythematosus
Shi LJ, Guo Q, Li SG

ABOUT COVER

Editorial Board Member of *World Journal of Clinical Cases*, Consolato M Sergi, FRCP (C), MD, PhD, Professor, Department of Lab. Medicine and Pathology, University of Alberta, Edmonton T6G 2B7, Canada

AIMS AND SCOPE

The primary aim of *World Journal of Clinical Cases* (WJCC, *World J Clin Cases*) is to provide scholars and readers from various fields of clinical medicine with a platform to publish high-quality clinical research articles and communicate their research findings online.

WJCC mainly publishes articles reporting research results and findings obtained in the field of clinical medicine and covering a wide range of topics, including case control studies, retrospective cohort studies, retrospective studies, clinical trials studies, observational studies, prospective studies, randomized controlled trials, randomized clinical trials, systematic reviews, meta-analysis, and case reports.

INDEXING/ABSTRACTING

The WJCC is now indexed in PubMed, PubMed Central, Science Citation Index Expanded (also known as SciSearch®), and Journal Citation Reports/Science Edition. The 2019 Edition of Journal Citation Reports cites the 2018 impact factor for WJCC as 1.153 (5-year impact factor: N/A), ranking WJCC as 99 among 160 journals in Medicine, General and Internal (quartile in category Q3).

RESPONSIBLE EDITORS FOR THIS ISSUE

Responsible Electronic Editor: *Yan-Xia Xing*

Proofing Production Department Director: *Yun-Xiaojian Wu*

Responsible Editorial Office Director: *Jim-Lei Wang*

NAME OF JOURNAL

World Journal of Clinical Cases

ISSN

ISSN 2307-8960 (online)

LAUNCH DATE

April 16, 2013

FREQUENCY

Semimonthly

EDITORS-IN-CHIEF

Dennis A Bloomfield, Bao-Gan Peng, Sandro Vento

EDITORIAL BOARD MEMBERS

<https://www.wjgnet.com/2307-8960/editorialboard.htm>

PUBLICATION DATE

June 6, 2020

COPYRIGHT

© 2020 Baishideng Publishing Group Inc

INSTRUCTIONS TO AUTHORS

<https://www.wjgnet.com/bpg/gerinfo/204>

GUIDELINES FOR ETHICS DOCUMENTS

<https://www.wjgnet.com/bpg/GerInfo/287>

GUIDELINES FOR NON-NATIVE SPEAKERS OF ENGLISH

<https://www.wjgnet.com/bpg/gerinfo/240>

PUBLICATION ETHICS

<https://www.wjgnet.com/bpg/GerInfo/288>

PUBLICATION MISCONDUCT

<https://www.wjgnet.com/bpg/gerinfo/208>

ARTICLE PROCESSING CHARGE

<https://www.wjgnet.com/bpg/gerinfo/242>

STEPS FOR SUBMITTING MANUSCRIPTS

<https://www.wjgnet.com/bpg/GerInfo/239>

ONLINE SUBMISSION

<https://www.f6publishing.com>

Endoscopic pedicle flap grafting in the treatment of esophageal fistulas: A case report

Yu-Hang Zhang, Jiang Du, Chuan-Hui Li, Bing Hu

ORCID number: Yu-Hang Zhang (0000-0003-2268-6149); Jiang Du (0000-0002-6558-7047); Chuan-Hui Li (0000-0001-7915-5352); Bing Hu (0000-0002-9898-8656).

Author contributions: Hu B contributed to procedure performance and revision of the manuscript; Du J and Li CH contributed to procedure assistance; Zhang YH contributed to drafting of the manuscript; all authors issued final approval for the version to be submitted.

Informed consent statement: Informed written consent was obtained from the patient for publication of this report and any accompanying images.

Conflict-of-interest statement: All the authors disclosed no conflict of interest.

CARE Checklist (2016) statement: The authors have read the CARE Checklist (2016), and the manuscript was prepared according to the CARE Checklist (2016).

Open-Access: This article is an open-access article that was selected by an in-house editor and fully peer-reviewed by external reviewers. It is distributed in accordance with the Creative Commons Attribution NonCommercial (CC BY-NC 4.0) license, which permits others to distribute, remix, adapt, build upon this work non-commercially, and license their derivative works on different terms, provided the original work is properly cited and the use is non-commercial. See: <https://creativecommons.org/licenses/by-nc/4.0/>

Yu-Hang Zhang, Jiang Du, Chuan-Hui Li, Bing Hu, Department of Gastroenterology, West China Hospital, Sichuan University, Chengdu 610041, Sichuan Province, China

Corresponding author: Bing Hu, MD, Chief Doctor, Professor, Department of Gastroenterology, West China Hospital, Sichuan University, No. 37, Guo Xue Alley, Chengdu 610041, Sichuan Province, China. hubingnj@163.com

Abstract

BACKGROUND

Fistulization is a rare complication of esophageal diverticula. Patients with this condition often require surgery, which unfortunately can be invasive and traumatic. Endoscopic therapy is an alternative method for treating esophageal fistula. Hereby we introduce a new endoscopic technique that uses an esophageal pedicle flap to close esophageal fistulas.

CASE SUMMARY

A 49-year-old male patient, complaining of backache and choking, was formerly diagnosed with chronic bronchopneumonia. Chest computed tomography and esophagram confirmed the presence of esophageal diverticulum and mediastinal esophageal fistula. The patient was then treated by covering the fistulas using a pedicled flap that was acquired through endoscopic submucosal dissection of a patch from the proximal esophageal mucosa. Then the pedicle flap was reversed 180° to cover the fistula. Titanium clips were used to fix the flap. The procedure ended with percutaneous endoscopic gastrostomy for enteral nutrition. The patient was followed up to evaluate the size reduction of the fistula. Cough, backache, and fever were alleviated within a week. Forty-five days after the surgery, endoscopic examination showed that the fistulas were reduced in size. The larger one reduced from 0.5 cm to 0.2 cm, while the smaller one was fully closed.

CONCLUSION

Transplantation of a pedicle flap obtained from the esophageal mucosa endoscopically is minimally invasive for the treatment of fistula.

Key words: Diverticulum; Esophageal fistula; Endoscopy; Pedicle grafting; Case report

©The Author(s) 2020. Published by Baishideng Publishing Group Inc. All rights reserved.

Core tip: Transplantation of muscle flaps or omental ones for esophageal leakage or

<http://creativecommons.org/licenses/by-nc/4.0/>

Manuscript source: Unsolicited manuscript

Received: March 11, 2020

Peer-review started: March 11, 2020

First decision: April 14, 2020

Revised: April 27, 2020

Accepted: May 14, 2020

Article in press: May 14, 2020

Published online: June 6, 2020

P-Reviewer: Cho YS, Morales HL

S-Editor: Tang JZ

L-Editor: Filipodia

E-Editor: Xing YX



fistula from outside the wall is reported to be effective. But surgical intervention often has postoperative morbidities and is contraindicated when the patient has poor health conditions. We developed this endoscopic pedicle grafting method based on the hypothesis that a mucosal flap could induce epithelization. Our single case study showed that the flap can heal a small fistula orifice and can reduce large one. It exhibits the potential to cure selected esophageal fistulas when surgery is not viable.

Citation: Zhang YH, Du J, Li CH, Hu B. Endoscopic pedicle flap grafting in the treatment of esophageal fistulas: A case report. *World J Clin Cases* 2020; 8(11): 2359-2363

URL: <https://www.wjnet.com/2307-8960/full/v8/i11/2359.htm>

DOI: <https://dx.doi.org/10.12998/wjcc.v8.i11.2359>

INTRODUCTION

The esophageal diverticulum is a rare disorder, which is usually asymptomatic and does not require treatment. Fistulization is a rare complication of esophageal diverticula^[1], which often requires surgery that can be invasive and traumatic. In addition, because the diverticulum is a cavity protruding outward from the esophageal lumen, it might not be appropriate to use a stent as treatment.

Flap transplantation has been widely used in plastic surgery for treating various skin defects, chronic ulcers, fistulas, or sinus tracts. Pedicle flap is a type of flap attached to the original site that provides blood supply during grafting. Muscle or omental flaps have been reported to be used in surgical repair of esophageal leakage and fistula^[2,3]. Hochberger *et al*^[4] endoscopically transplanted a gastric mucosal flap to prevent esophageal stricture after endoscopic submucosal dissection of early squamous cell carcinoma. Inspired by that study, we hypothesized that the mucosal flap could help induce the closing of esophageal fistula when surgery is contraindicated. Therefore, we improved this mucosal transplantation method by using pedicle esophageal mucosal flap to close mediastinal esophageal fistulas.

CASE PRESENTATION

Chief complaints

A 49-year-old man was admitted to our hospital complaining of reiterative backache, occasional bloody sputum, and choking when eating or drinking.

History of present illness

Symptoms of backache and bloody sputum started 7 years ago. The pain was located in the scapular region. Consequently, the patient was diagnosed with chronic bronchopneumonia and was treated accordingly. Ten months ago, he experienced choking during eating or drinking. Recently, the aforementioned symptoms became aggravated and were followed by a low-grade fever.

History of past illness

The patient had a history of an esophageal diverticulum 10 years ago.

Comorbidity

The patient had concomitant mild depression and was taking Olanzapine 2.5 mg qd.

Physical examination

Upon admission, the patient's temperature was 37.5 °C, pulse rate was 84 bpm, respiratory rate was 19 breaths per minute, and the blood pressure was 102/62 mmHg. Breath sounds at the right lower pulmonary lobe region were reduced, and fine rales could be heard.

Laboratory examinations

Blood analysis revealed that white blood count was $4.49 \times 10^9/L$ with a neutrophil percentage of 79.3%. The biochemistry test and electrocardiogram were normal. Sputum microbiological cultivation revealed no obvious pathogenic bacteria.

Imaging examinations

Chest computed tomography showed dilation of the lower esophagus and air in the adjacent mediastinum (Figure 1A). Esophagram confirmed the presence of mediastinal esophageal fistula around the 9th thoracic vertebra level (Figure 1B). In addition, esophagogastroduodenoscopy revealed a giant diverticulum of 2.0 cm in diameter at the right post wall, 32-34 cm aborally. Two fistulas (0.5 cm and 0.3 cm in diameter respectively; 33 cm aborally) were confirmed in the cavity of the diverticulum (Figure 1C).

FINAL DIAGNOSIS

The final diagnosis suggested an esophageal fistula secondary to spontaneous rupture of the diverticulum.

INTERVENTIONAL STRATEGY

Based on this diagnosis, surgical resection of the diverticulum or repair of the fistulas was not recommended by the surgeon due to possible side effects related to surgery (uncontrolled mediastinitis or nonhealing of suture wounds) of fistula with chronic infection. In addition, the doctor suggested that a stent should not be applied because it could not seal fistula orifices in the outward protruding diverticulum, and the diverticulum cavity might contain pus. Instead, an endoscopic pedicle flap grafting (EPFG) was recommended and accepted by the patient who signed the informed consent.

TREATMENT

Upon admission, the patient was prescribed cefoxitin 2000 mg ivgtt q12h and parenteral nutrition. EPFG was performed under general anesthesia as follows: (1) An area of about 2.0 cm × 1.0 cm cranially to the fistulas was marked; (2) The saline-epinephrine-indigo carmine solution was then injected into the submucosal layer (Figure 1D). Mucosal incision and submucosal dissection were performed (Figure 1E) using a dual knife (Olympus, Tokyo, Japan), leaving the distal edge of the flap (the pedicle, 0.4 cm in diameter) intact; (3) When the pedicle flap was ready (Figure 1F), we applied ablation to the surrounding mucosa of the fistulas using argon plasma coagulation (ERBE, Germany) to make it easier for later attachment (Figure 1G); (4) Rat-tooth forceps were employed to match the free edges of the flap to the ablated mucosa (Figure 1H). Moreover, several titanium clips were used for fixation (Figure 1I) leaving an ulcer area of the original flap (Figure 1J); and (5) Finally, percutaneous endoscopic gastrostomy was performed for future enteral nutrition (Figure 1K).

No procedure-related complications were observed. Ceftriaxone 2000 mg ivgtt qd, esomeprazole 40 mg ivgtt qd, carbazochrome sodium 60 mg ivgtt qd, and enteral nutrition through the percutaneous endoscopic gastrostomy tube were administered after the surgery.

OUTCOME AND FOLLOW-UP

Coughing and backache were relieved, and no fever was observed a week after the surgery. The patient was discharged from the hospital thereafter. Forty-five days after the surgery, endoscopic examination showed that the fistulas were reduced in size. The larger one was reduced from 0.5 cm to 0.2 cm, while the smaller one was fully closed (Figure 1L). We offered the patient a second chance of EPFG, but it was refused. The patient is now considering a surgical option of resecting the diverticulum and is waiting for the clearance of the chronic infection so as to be indicated for surgery by feeding through the percutaneous endoscopic gastrostomy tube.

DISCUSSION

Esophageal fistulization is usually caused by trauma, surgery, neoplasm, radiation, or erosion. In this case, it occurred on the basis of diverticulum. Diverticulum, which causes fistula, is rather rare and is often misdiagnosed as a lung infection, bronchiectasis, or pulmonary abscess^[5]. Surgery or endoscopic techniques are

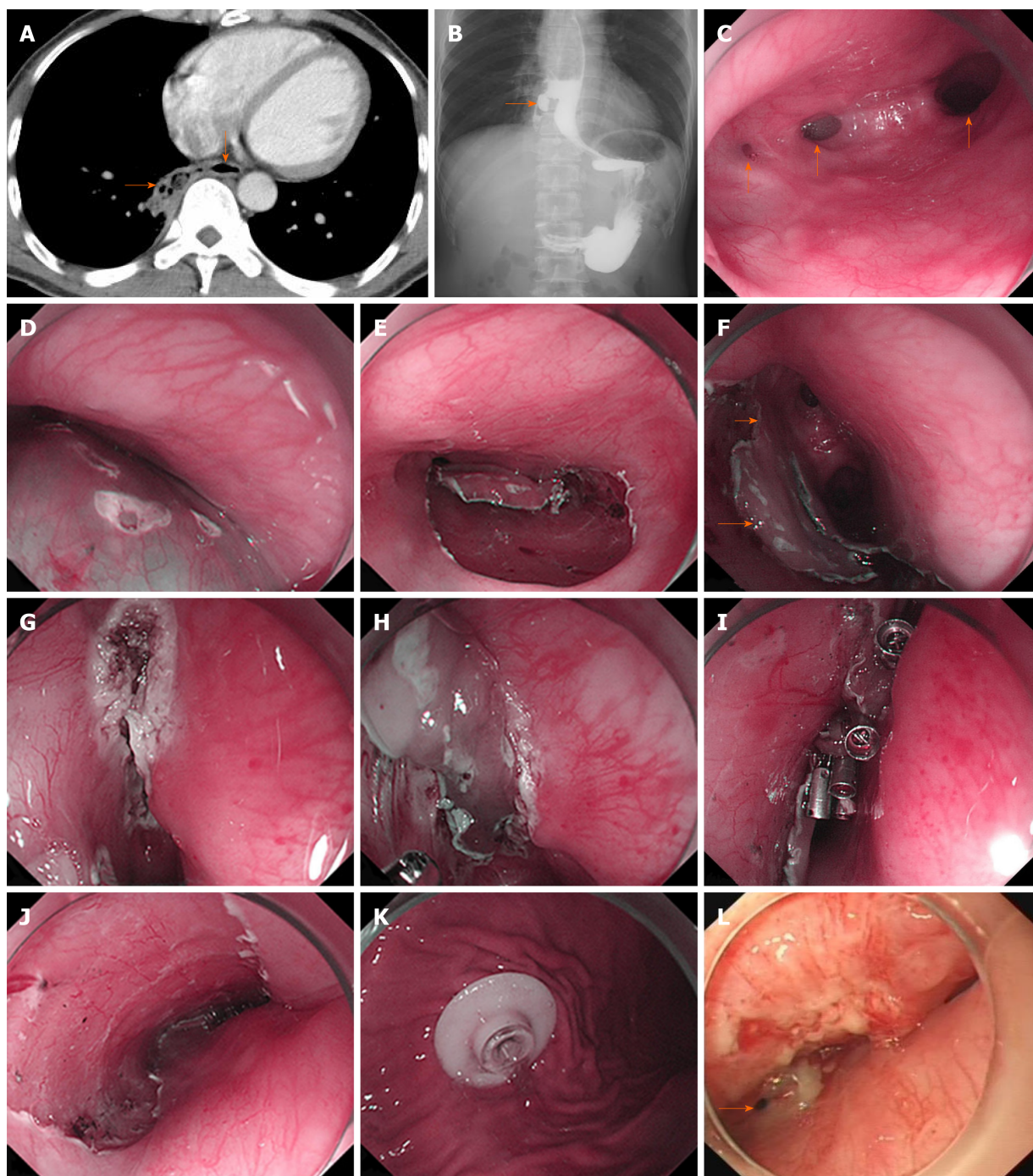


Figure 1 Results of examinations and treatment. A: Computed tomography scan (rightward arrow: Fistula; downward arrow: Esophageal lumen); B: Esophagram revealed the presence of esophageal fistula (arrow) around the 9th vertebra level; C: Endoscopic examination confirmed the presence of two fistulas, which are 0.3 cm (left arrow) and 0.5 cm (middle arrow) in diameter and the esophageal lumen (right arrow); D and E: Submucosal injection was followed by (E) endoscopic submucosal dissection; F: The mucosal flap (lower arrow) with the caudal edge reserved as the pedicle (upper arrow) was made ready after endoscopic submucosal dissection; G and H: Ablation of the surrounding mucosa before (H) covering the fistulas with the flap; I: Several titanium clips were used for fixation; J: Ulcer area left after endoscopic submucosal dissection; K: Percutaneous gastrostomy; L: Forty-five days after the endoscopic surgery, the larger fistula (arrow) reduced from 0.5 cm to 0.2 cm and the smaller one was closed.

required to remove or close fistulas from the esophagus^[6,7]. Yet, surgical closure or resection can be performed only in cases with small defects and without contamination in the mediastinum^[8]. In this case, the patient presented with sputum caused by a local infection in the lung and mediastinum, which excluded surgery.

For benign esophageal fistulas, nonsurgical treatment like endoscopic stent placement has similar outcomes compared with surgical modality^[9]. Nevertheless, this type of treatment has shown to be effective in only 45% of cases and mainly for patients with punctiform orifices (less than approximately 2.5 mm)^[10]. Therefore, the size of the orifices might be slightly larger in our case. In addition, the diverticulum

cavity is protruding outward, which makes it difficult for the stent to cover the orifice. In that case, the cavity would become a container for pus, which might induce further inflammation if surgery was performed.

Endoscopic cell sheets and free mucosal flap transplantation have been reported to prevent strictures secondary to endoscopic submucosal dissection^[11,12]. On this basis, we hypothesized that a pedicle flap with sufficient blood supply than mere free mucosa would endure longer and exhibit greater potential to close the fistula, reserving the integrity of the esophagus. We chose an adjacent esophageal pedicle flap other than skin or previously reported gastric mucosa because skin could not maintain long-term esophageal function and often develops morphological changes, while gastric mucosa has acid-secreting capability^[13].

Although the larger fistula was not completely closed, the reduction in size suggested that this new approach was effective in treating esophageal fistula. Possible reasons for the incomplete closure may be that the course of the disease was too long and that local infection and inflammation impeded epithelization. In view of this, we speculate that selected cases with smaller fistula and little contamination may be better candidates for flap grafting. Nevertheless, future studies with more cases are needed to validate its efficacy and identify best candidates. Comparative studies involving EPFG, stent, and surgical repair using muscle flap are also needed in the future to demonstrate the advantage and disadvantage of each modality. Perhaps a combination of EPFG and stent might also be a choice.

CONCLUSION

Considering the fistula's anatomic and physiologic traits, accessibility, and minimally invasive nature, pedicle flap grafting under endoscopy might be a better choice for esophageal fistula. In addition, it exhibits potential to be applied in esophageal fistulas without diverticulum, and its combination with stent could be considered as well. Future studies are needed to explore its clinical applicability.

REFERENCES

- 1 Wang ZM, Zhang SC, Teng X. Esophageal diverticulum serves as a unique cause of bronchoesophageal fistula in children: A case report. *Medicine (Baltimore)* 2017; **96**: e9492 [PMID: 29390593 DOI: 10.1097/MD.0000000000009492]
- 2 Balakrishnan A, Tapias L, Wright CD, Lanuti MX, Gaissert HA, Mathisen DJ, Muniappan A. Surgical Management of Post-Esophagectomy Tracheo-Bronchial-Esophageal Fistula. *Ann Thorac Surg* 2018; **106**: 1640-1646 [PMID: 30171850 DOI: 10.1016/j.athoracsur.2018.06.076]
- 3 Asaad M, Van Handel A, Akhavan AA, Huang TT, Rajesh A, Allen MA, Shen KR, Sharaf B, Moran SL. Muscle Flap Transposition for the Management of Intrathoracic Fistulas. *Plast Reconstr Surg* 2020 [PMID: 31929454 DOI: 10.1097/PRS.0000000000006670]
- 4 Hochberger J, Koehler P, Wedi E, Gluer S, Rothstein RI, Niemann H, Hilfiker A, Gonzalez S, Kruse E. Transplantation of mucosa from stomach to esophagus to prevent stricture after circumferential endoscopic submucosal dissection of early squamous cell. *Gastroenterology* 2014; **146**: 906-909 [PMID: 24512802 DOI: 10.1053/j.gastro.2014.01.063]
- 5 Zuo CY, Xu ZJ. [Esophageal bronchial fistula secondary to esophageal diverticulum: A case report and literature review]. *Zhonghua Jie He He Hu Xi Za Zhi* 2018; **41**: 622-627 [PMID: 30138972 DOI: 10.3760/cma.j.issn.1001-0939.2018.08.010]
- 6 Onwugbutor MT, Obirieze AC, Ortega G, Allen D, Cornwell EE, Fullum TM. Surgical management of esophageal diverticulum: a review of the Nationwide Inpatient Sample database. *J Surg Res* 2013; **184**: 120-125 [PMID: 23751803 DOI: 10.1016/j.jss.2013.05.036]
- 7 von Renteln D, Denzer UW, Schachschal G, Anders M, Groth S, Röscher T. Endoscopic closure of GI fistulae by using an over-the-scope clip (with videos). *Gastrointest Endosc* 2010; **72**: 1289-1296 [PMID: 20951989 DOI: 10.1016/j.gie.2010.07.033]
- 8 Uno K, Koike T, Takahashi S, Komazawa D, Shimosegawa T. Management of aorto-esophageal fistula secondary after thoracic endovascular aortic repair: a review of literature. *Clin J Gastroenterol* 2017; **10**: 393-402 [PMID: 28766283 DOI: 10.1007/s12328-017-0762-z]
- 9 Lenz CJ, Bick BL, Katzka D, Nichols FC, Depew ZS, Wong Kee Song LM, Baron TH, Buttar NS, Maldonado F, Enders FT, Harmsen WS, Dierkhising RA, Topazian MD. Esophagorespiratory Fistulas: Survival and Outcomes of Treatment. *J Clin Gastroenterol* 2018; **52**: 131-136 [PMID: 27824640 DOI: 10.1097/MCG.0000000000000751]
- 10 Debourdeau A, Gonzalez JM, Dutau H, Benezec A, Barthet M. Endoscopic treatment of nonmalignant tracheoesophageal and bronchoesophageal fistula: results and prognostic factors for its success. *Surg Endosc* 2019; **33**: 549-556 [PMID: 30014327 DOI: 10.1007/s00464-018-6330-x]
- 11 Hürtgen M, Herber SCA. Treatment of malignant tracheoesophageal fistula. *Thorac Surg Clin* 2014; **24**: 117-127 [PMID: 24295667 DOI: 10.1016/j.thorsurg.2013.09.006]
- 12 Leggett CL, Gorospe EC, Lutzke L, Anderson M, Wang KK. A new era: endoscopic tissue transplantation. *Curr Opin Gastroenterol* 2013; **29**: 495-500 [PMID: 23872488 DOI: 10.1097/MOG.0b013e328363e3fd]
- 13 Imaizumi A, Liem AA, Yang CF, Chen W, Chen SH, Chen HC. Long-Term Outcomes of Simultaneous Skin and Bowel Flaps for Esophageal Reconstruction. *Ann Plast Surg* 2015; **75**: 180-185 [PMID: 25003411 DOI: 10.1097/SAP.0000000000000067]



Published by Baishideng Publishing Group Inc
7041 Koll Center Parkway, Suite 160, Pleasanton, CA 94566, USA
Telephone: +1-925-3991568
E-mail: bpgoffice@wjgnet.com
Help Desk: <https://www.f6publishing.com/helpdesk>
<https://www.wjgnet.com>

