

# World Journal of *Clinical Cases*

*World J Clin Cases* 2020 July 6; 8(13): 2674-2892



## Contents

Semimonthly Volume 8 Number 13 July 6, 2020

## OPINION REVIEW

- 2674 Minimizing the risk of community spread of COVID-19 *via* institutional quarantine of high-risk travelers with serial viral RNA testing: A successful experience from Macao SAR, China  
*Lio CF, Cheong HH, Lei CI, Lo IL, Lam C, Leong IH*

## REVIEW

- 2679 Balloon pulmonary angioplasty for chronic thromboembolic pulmonary hypertension: State of the art  
*Jin Q, Zhao ZH, Luo Q, Zhao Q, Yan L, Zhang Y, Li X, Yang T, Zeng QX, Xiong CM, Liu ZH*
- 2703 Advances in para-aortic nodal dissection in gastric cancer surgery: A review of research progress over the last decade  
*Dong YP, Deng JY*
- 2717 Relevance on the diagnosis of malignant lymphoma of the salivary gland  
*Zhang XY, Wang ZM*

## ORIGINAL ARTICLE

## Clinical and Translational Research

- 2727 Role of peripheral eosinophilia in acute exacerbation of chronic obstructive pulmonary disease  
*Wu CW, Lan CC, Hsieh PC, Tzeng IS, Wu YK*

## Case Control Study

- 2738 Effects of prostaglandin E combined with continuous renal replacement therapy on septic acute kidney injury  
*Lei L, Wang MJ, Zhang S, Hu DJ*

## Retrospective Study

- 2749 Modified technique of advanced core decompression for treatment of femoral head osteonecrosis  
*Lin L, Jiao Y, Luo XG, Zhang JZ, Yin HL, Ma L, Chen BR, Kelly DM, Gu WK, Chen H*
- 2758 Initial experience with stereotactic body radiotherapy for intrahepatic hepatocellular carcinoma recurrence after liver transplantation  
*Au KP, Chiang CL, Chan ACY, Cheung TT, Lo CM, Chok KSH*
- 2769 Correlation between age of onset and gastrointestinal stenosis in hospitalized patients with Crohn's disease  
*Yang SB, Du SW, Wang JH*
- 2778 Adjuvant nab-paclitaxel plus gemcitabine *vs* gemcitabine alone for resected pancreatic ductal adenocarcinoma: A single center experience in China  
*Yin ZZ, Zhao ZM, Tang WB, Jiang N, Zhang KD, Song YY, Wang Y, Li CG, Gao YX, Liu R*

**Observational Study**

- 2787 Case studies in psychotherapy training using Austria as an example

*Neidhart E, Löffler-Stastka H*

**Prospective Study**

- 2802 Correlation between crowdedness in emergency departments and anxiety in Chinese patients

*Wang S, Gao JY, Li X, Wu Y, Huo XX, Han CX, Kang MJ, Sun H, Ge BL, Liu Y, Liu YQ, Zhou JP, Wang Z*

**SCIENTOMETRICS**

- 2817 Bibliometric analysis of subject trends and knowledge structures of gut microbiota

*Yue YY, Fan XY, Zhang Q, Lu YP, Wu S, Wang S, Yu M, Cui CW, Sun ZR*

**CASE REPORT**

- 2833 Acute myelomonocytic leukemia during pembrolizumab treatment for non-small cell lung cancer: A case report

*Kim HB, Park SG, Hong R, Kang SH, Na YS*

- 2841 Metallic ureteral stent in restoring kidney function: Nine case reports

*Gao W, Ou TW, Cui X, Wu JT, Cui B*

- 2849 Pheochromocytoma with delayed tumor thrombus detection in renal vein: A case report

*Jia Z, Wang BJ, Li X, Zhang X*

- 2855 Laparoscopic repair of uterine rupture following successful second vaginal birth after caesarean delivery: A case report

*Cai YQ, Liu W, Zhang H, He XQ, Zhang J*

- 2862 Missed diagnosis of femoral deep artery rupture after femoral shaft fracture: A case report

*Ge J, Kong KY, Cheng XQ, Li P, Hu XX, Yang HL, Shen MJ*

- 2870 Posterior reversible encephalopathy syndrome and heart failure tacrolimus-induced after liver transplantation: A case report

*Liu JF, Shen T, Zhang YT*

- 2876 Significant benefits of pembrolizumab in treating refractory advanced pulmonary sarcomatoid carcinoma: A case report

*Chen P, Yu M, Zhang JL, Chen WY, Zhu L, Song Y, Jiang CY, Zhang S*

- 2885 Two sequential surgeries in infant with multiple floor of the mouth dermoid cysts: A case report

*Liu NN, Zhang XY, Tang YY, Wang ZM*

**ABOUT COVER**

Editorial board member of *World Journal of Clinical Cases*, Dr. El Ghoch is a Full Professor in the Faculty of Health Sciences, Beirut Arab University, Lebanon. Having received his MD degree from University of Bologna, Italy in 2005, and undertook his postgraduate degree in Clinical Nutrition at the University of Modena and Reggio Emilia, Italy in 2009. In the following 10 year, he had a wide clinical and research activity in Italy in the field of obesity and eating disorders, and gained an international leadership in the study of the body composition in anorexia nervosa. In October 2018 he was appointed as Professor in the Clinical Nutrition, and Chairperson of the Department of Nutrition and Dietetics, Beirut Arab University, Lebanon. His ongoing research interests are body composition, physical activity, weight cycling, etc.

**AIMS AND SCOPE**

The primary aim of *World Journal of Clinical Cases* (*WJCC*, *World J Clin Cases*) is to provide scholars and readers from various fields of clinical medicine with a platform to publish high-quality clinical research articles and communicate their research findings online.

*WJCC* mainly publishes articles reporting research results and findings obtained in the field of clinical medicine and covering a wide range of topics, including case control studies, retrospective cohort studies, retrospective studies, clinical trials studies, observational studies, prospective studies, randomized controlled trials, randomized clinical trials, systematic reviews, meta-analysis, and case reports.

**INDEXING/ABSTRACTING**

The *WJCC* is now indexed in Science Citation Index Expanded (also known as SciSearch®), Journal Citation Reports/Science Edition, PubMed, and PubMed Central. The 2020 Edition of Journal Citation Reports® cites the 2019 impact factor for *WJCC* as 1.013 (5-year impact factor: N/A), ranking *WJCC* as 120 among 165 journals in medicine, general and internal (quartile in category Q3).

**RESPONSIBLE EDITORS FOR THIS ISSUE**

Electronic Editor: Yan-Xia Xing, Production Department Director: Yun-Xiaojian Wu, Editorial Office Director: Jin-Lai Wang.

**NAME OF JOURNAL**

*World Journal of Clinical Cases*

**ISSN**

ISSN 2307-8960 (online)

**LAUNCH DATE**

April 16, 2013

**FREQUENCY**

Semimonthly

**EDITORS-IN-CHIEF**

Dennis A Bloomfield, Sandro Vento, Bao-Gan Peng

**EDITORIAL BOARD MEMBERS**

<https://www.wjgnet.com/2307-8960/editorialboard.htm>

**PUBLICATION DATE**

July 6, 2020

**COPYRIGHT**

© 2020 Baishideng Publishing Group Inc

**INSTRUCTIONS TO AUTHORS**

<https://www.wjgnet.com/bpg/gerinfo/204>

**GUIDELINES FOR ETHICS DOCUMENTS**

<https://www.wjgnet.com/bpg/GerInfo/287>

**GUIDELINES FOR NON-NATIVE SPEAKERS OF ENGLISH**

<https://www.wjgnet.com/bpg/gerinfo/240>

**PUBLICATION ETHICS**

<https://www.wjgnet.com/bpg/GerInfo/288>

**PUBLICATION MISCONDUCT**

<https://www.wjgnet.com/bpg/gerinfo/208>

**ARTICLE PROCESSING CHARGE**

<https://www.wjgnet.com/bpg/gerinfo/242>

**STEPS FOR SUBMITTING MANUSCRIPTS**

<https://www.wjgnet.com/bpg/GerInfo/239>

**ONLINE SUBMISSION**

<https://www.f6publishing.com>

# Metallic ureteral stent in restoring kidney function: Nine case reports

Wei Gao, Tong-Wen Ou, Xin Cui, Jiang-Tao Wu, Bo Cui

**ORCID number:** Wei Gao 0000-0001-6210-1286; Tong-Wen Ou 0000-0002-6625-0876; Xin Cui 0000-0003-3769-8329; Jiang-Tao Wu 0000-0001-5867-0187; Bo Cui 0000-0002-9407-1867.

**Author contributions:** Gao W, Ou TW, Cui X, Wu JT and Cui B conducted the clinical study; Gao W and Ou TW were responsible for the integrity of the entire study; Gao W contributed to study concept, design, data collection, data management, interpretation and supervision and statistical analysis and drafted the manuscript.

**Informed consent statement:** Informed written consent was obtained from the patient for publication of this report and any accompanying images.

**Conflict-of-interest statement:** The authors declare that they have no conflict of interest.

**CARE Checklist (2016) statement:** The authors have read the CARE Checklist (2016), and the manuscript was prepared and revised according to the CARE Checklist (2016).

**Open-Access:** This article is an open-access article that was selected by an in-house editor and fully peer-reviewed by external reviewers. It is distributed in accordance with the Creative Commons Attribution

Wei Gao, Tong-Wen Ou, Xin Cui, Jiang-Tao Wu, Bo Cui, Department of Urology, Xuanwu Hospital, Capital Medical University, Beijing 100053, China

**Corresponding author:** Wei Gao, MD, Associate Chief Physician, Department of Urology, Xuanwu Hospital, Capital Medical University, Changchun Street No. 45, Xicheng District, Beijing 100053, China. [polarbeargaowe@sina.com](mailto:polarbeargaowe@sina.com)

## Abstract

### BACKGROUND

Retroperitoneal fibrosis is an exceptionally rare disease characterized by proliferation of fibrous tissue and inflammation in the retroperitoneum. It features many symptoms in the kidneys and in other organs and usually leads to ureteral obstruction.

### CASE SUMMARY

Here we present 9 consecutive cases of idiopathic retroperitoneal fibrosis (IRPF) in patients who presented to the Department of Nephrology or Department of Rheumatology, Xuanwu Hospital, Capital Medical University, Beijing, China, between January 2012 and June 2017 with ureteral obstruction due to external compression of the ureter that led to hydronephrosis and kidney dysfunction. Computed tomography imaging was used to identify hydronephrosis and ureteral obstruction and to evaluate kidney function. Each patient was diagnosed with IRPF based on clinical observation and computed tomography examination results. To restore kidney function, a retrograde metallic stent was placed in the ureter under X-ray guidance 2 d after each patient's admission. No perioperative complications occurred in any patient, but postoperative complications occurred in two patients as follows: Patient 2 had stent migration and repeated metallic stent infections that resolved with treatment; and patient 4 had postoperative hematuria because he resumed normal activities too soon after stent placement (contrary to instruction). Placement of the metallic ureteral stents provided relief from ureteral obstruction and restored kidney function in all patients.

### CONCLUSION

Our 9-case series underscores the utility and efficacy of applying the Resonance® metallic ureteral stent to treat ureteral obstruction in patients with IRPF. For all retroperitoneal fibrosis cases in our series, ureteral stents provided effective relief and were shown to reduce the incidence rate of perioperative and postoperative complications.

**Key words:** Retroperitoneal fibrosis; Metallic ureteral stent; Ureteral obstruction;

NonCommercial (CC BY-NC 4.0) license, which permits others to distribute, remix, adapt, build upon this work non-commercially, and license their derivative works on different terms, provided the original work is properly cited and the use is non-commercial. See: <http://creativecommons.org/licenses/by-nc/4.0/>

**Manuscript source:** Unsolicited manuscript

**Received:** December 23, 2019

**Peer-review started:** December 23, 2019

**First decision:** March 5, 2020

**Revised:** May 12, 2020

**Accepted:** June 7, 2020

**Article in press:** June 7, 2020

**Published online:** July 6, 2020

**P-Reviewer:** Moralioglu S

**S-Editor:** Zhang L

**L-Editor:** Filipodia

**E-Editor:** Xing YX



Computed tomography; Kidney function; Plastic stent; Case report

©The Author(s) 2020. Published by Baishideng Publishing Group Inc. All rights reserved.

**Core tip:** Nine patients with idiopathic retroperitoneal fibrosis admitted to our institution within a 5-year period received Resonance® metallic stents to restore kidney function. Ureteral obstruction was relieved in all 9 cases, and only 2 patients experienced adverse effects (stent migration and repeated metallic stent infection in one patient and postoperative hematuria in another). Overall, these stents demonstrated effective relief and resulted in fewer complications in the treatment of ureteral stenosis in patients with idiopathic retroperitoneal fibrosis.

**Citation:** Gao W, Ou TW, Cui X, Wu JT, Cui B. Metallic ureteral stent in restoring kidney function: Nine case reports. *World J Clin Cases* 2020; 8(13): 2841-2848

**URL:** <https://www.wjgnet.com/2307-8960/full/v8/i13/2841.htm>

**DOI:** <https://dx.doi.org/10.12998/wjcc.v8.i13.2841>

## INTRODUCTION

Retroperitoneal fibrosis (RPF) is a disease featuring the proliferation of fibrous tissue in the retroperitoneum. It is a rare disease characterized by extensive fibrosis and inflammation in the retroperitoneal region and causes many symptoms in the kidneys and other organs<sup>[1]</sup>. Clinicians have classified the disease into two forms: Idiopathic RPF (IRPF) and RPF secondary to a malignancy<sup>[2]</sup>. The pathology of RPF secondary to a malignancy is similar to that of IRPF, except for the invasive growth of cancer cells in muscle and bone tissues. IRPF may be considered an autoimmune disease due to its association with various immune-related conditions and response to immunosuppression<sup>[3]</sup>. Patients with either of these two forms of RPF may experience compression of the ureter, resulting in ureteral obstruction with traction displacement<sup>[4]</sup>. Ureterolysis is a standard treatment, but it is time-consuming, risky and may not be tolerated by some patients<sup>[5,6]</sup>.

A ureteral stent can be used to drain the kidney and restore kidney function, thereby providing time for further treatment and improving the patient's quality of life. However, the conventional plastic or polymeric stents may become occluded after several months, so frequent monitoring is needed. Also, the plastic stent must be replaced immediately once the hydronephrosis has occurred. Moreover, a typical plastic or polymeric ureteral stent may provide insufficient resistance to the traction displacement of the ureter<sup>[4]</sup>.

Metallic ureteral stents are widely used for the treatment of ureteral obstructions secondary to malignant retroperitoneal metastases<sup>[7]</sup>. In these RPF patients, the retroperitoneal metastatic foci are characterized by the infiltration of fibroblasts and cancer cells<sup>[7]</sup>. The Resonance® metallic stent has no magnetic metal but has potent tensile strength and provides good drainage. In addition, it is resistant to external compression secondary to RPF and also is resistant to occlusion. These properties allow longer dwelling time and less frequent stent exchanges. Thus, this stent provides a long-term renoprotective effect and might be more cost-effective<sup>[8]</sup>. However, the stent should still be refreshed once a year, and it may be more difficult to exchange a metallic stent than a plastic or a polymeric stent. Herein, we explored the outcomes of using a metallic ureteral stent for treatment of 9 cases of IRPF.

## CASE PRESENTATION

This case series includes 9 consecutive patients with IRPF who were admitted to the Department of Nephrology or Division of Rheumatology of Xuanwu Hospital, Capital Medical University, Beijing, China, where they received comprehensive examinations from January 2012 to June 2017 (Table 1). Patients' mean age was 61-years-old, and 8 patients were male. Each patient had ureteral obstruction due to external compression, which led to hydronephrosis and kidney dysfunction. After consultation with urologists, they were transferred to the Department of Urology and then were

**Table 1 Characteristics of patients who received metallic ureteral stents to restore kidney function due to idiopathic retroperitoneal fibrosis**

Patient No.	Age in yr, sex	Initial admission	Metallic stent properties	Stent placement, n	Reason for stent failure/removal	Follow-up in mo
1 <sup>1</sup>	53, M	January, 2012	Left: 6 Fr, 26 cm	6	NA	66
2 <sup>2</sup>	55, F	July, 2012	Bilateral: 6 Fr, 26 cm (first); Right: 26 cm (second); Right: 24 cm (third)	3	Recurrent obstruction after removal	60
3	64, M	August, 2012	Bilateral: 6 Fr, 26 cm	1	NA	6
4 <sup>3</sup>	74, M	December, 2012	Right: 6 Fr, 28 cm (patient height > 180 cm)	1	Removal at 7 mo following patient's request	37
5	64, M	January, 2013	Right: 6 Fr, 26 cm	4	Obstruction after refreshing with a general stent	54
6	63, M	February, 2014	Right: 6 Fr, 26 cm	4	NA	41
7	61, M	March, 2015	Bilateral: 6 Fr, 26 cm	2	NA	28
8	44, M	May, 2015	Left: 6 Fr, 28 cm	1	NA	6
9	71, M	October, 2012	Left: 6 Fr, 26 cm	4	NA	51

<sup>1</sup>Patient 1 received a sixth stent placement more than 60 mo after the first placement.

<sup>2</sup>Patient 2 experienced stent migration and repeated metallic stent infections between July 2016 and October 2016.

<sup>3</sup>Patient 4 experienced postoperative hematuria because he resumed normal activities after stent placement, contrary to instructions. F: Female; Fr: French scale; M: Male; NA: Not applicable.

scheduled to receive Resonance® metallic ureteral stents.

### **Chief complaints and History of present illness**

**Case 1:** A 53-year-old male was admitted on 19 January 2012. He was the first to receive a metallic stent for treatment of ureteral obstruction due to IRPF.

**Case 2:** A 55-year-old female was admitted to the Department of Nephrology due to acute renal failure on 8 July 2012. She received a diagnosis of IRPF and bilateral hydronephrosis based on computed tomography (CT) results.

**Case 3:** A 64-year-old male was admitted in August 2012 and was diagnosed with IRPF, bilateral hydronephrosis and chronic renal failure.

**Case 4:** A 74-year-old male was admitted and diagnosed with IRPF, right hydronephrosis and left renal atrophy. He had received bilateral ureterolysis more than 10 years previously.

**Case 5:** A 64-year-old male was admitted in 2013 and diagnosed with IRPF and right hydronephrosis.

**Case 6:** A 63-year-old male diagnosed with IRPF and right hydronephrosis was suspected to have immunoglobulin G (IgG)4-related sclerotic disease. On February 14, 2014, he was admitted to the Division of Rheumatology, and IgG4-related sclerotic disease was confirmed.

**Case 7:** A 61-year-old male was admitted in 2014 and diagnosed with IRPF, bilateral hydronephrosis and chronic renal failure.

**Case 8:** A 44-year-old male was admitted in 2014 and diagnosed with IRPF, left hydronephrosis, right renal atrophy and acute renal failure.

**Case 9:** This 71-year-old patient was admitted into the Department of Urology on 11 April 2013, and ultrasonography indicated left hydronephrosis.

### **History of past illness**

**Case 1:** This patient had left hydronephrosis because he received a left ureteral stent that was refreshed on 9 January 2013. In January 2014, the clinician in the Division of Rheumatology believed a metallic stent was unnecessary for treatment of ureteral obstruction due to IRPF and recommended stent removal due to the patient's stable

condition.

**Cases 2, 3 and 5-8:** Patient had a free previous medical history.

**Case 4:** The patient had received bilateral ureterolysis more than 10 years previously.

**Case 9:** At a prior admission on 17 October 2012, this patient complained of dull pain in the left waist for more than 4 mo and left hydronephrosis. CT results indicated a left-middle ureteral obstruction (inflammation-related adhesion) and left hydronephrosis. Exploratory ureteroscopy of the left ureter was performed, with dilation of the stenotic ureter, biopsy and 7 French scale (Fr) double pigtail stent placement. Stenosis was observed after the ureteroscope was inserted 15 cm, and a 5 Fr ureteral catheter was inserted through the stenotic site. The ureteral wall was smooth, pelvic urine was collected for anti-acid staining and bacterial culture, and ureteral mucosa was collected at the stenotic site. The ureter dilator was used for progressive dilation of the stenotic segment until 12 Fr. Then, we attempted, but failed, to place 5 Fr and 7 Fr double pigtail stents and instead placed a 7 Fr double pigtail stent. There was no evidence of infection.

### Laboratory examinations

**Case 2:** On admission, this patient's creatinine clearance rate (CCr) was 708 mmol/L.

**Case 4:** At admission, this patient's glomerular filtration rate (GFR) was 1.4 and 46.3 mL/min in the left and right kidney, respectively.

**Case 6:** Prior to surgery, this patient's serum CCr was 266 mmol/L.

**Case 9:** This patient's initial serum creatinine (SCr) was 108  $\mu$ mol/L, carcinoembryonic antigen was 6.06 ng/mL, and CYFRA 21-1 was 5.59 ng/mL. The GFR was 15.7 and 44.6 in the left kidney and right kidney, respectively. At subsequent admission, his SCr was 95  $\mu$ mol/L and the GFR was 9.56 and 44.7 in the left and right kidney, respectively.

### Imaging examinations

Kidney function was dynamically monitored for all patients at baseline and postoperatively. CT scans of the kidney, ureter and bladder were performed, which allowed the identification of hydronephrosis and ureteral obstruction and the evaluation of kidney function based on findings in the renal arterial and venous phases.

## FINAL DIAGNOSIS

Final diagnosis in all cases was ureteral obstruction due to external compression, which led to hydronephrosis and kidney dysfunction. All patients were indicated for metallic stent placement.

## TREATMENT

For all 9 patients, on the 2<sup>nd</sup> d after admission, a retrograde metallic stent was placed in the ureter under X-ray guidance, while the patients were under general anesthesia. This procedure involved the application of a cystoscope (Olympus 24 Fr, Tokyo, Japan) and a Resonance<sup>®</sup> nickel/chrome/cobalt/molybdenum alloy stent (6 Fr) (Cook Medical, Bloomington, IN, United States). The stent was 24 cm for patients shorter than 165 cm, 26 cm for patients who were 165-175 cm, and 28 cm for patients taller than 175 cm. The retrograde insertion of a guide wire was performed to the renal pelvis, then a ureteral catheter (5, 6 or 8 Fr) was used to dilate the ureter. A 10 Fr double-chamber ureteral catheter was then inserted for further dilation of the ureter, while preserving the guide wire. An 8.3 Fr metallic stent sheath was then inserted, followed by withdrawal of the guide wire. The stent was then inserted retrogradely along the sheath, and the sheath was then removed. All procedures were performed in accordance with X-ray guidance, and the metallic stent was directly observed using the cystoscope.

## OUTCOME AND FOLLOW-UP

The 9 patients received a mean number of 2.5 metallic stent placements. The mean follow-up time was 39 mo. No perioperative complications occurred in any patient, and stent placement provided relief from ureteral obstruction for all patients. Postoperative complications occurred in two patients: patient 2 had stent migration and repeated metallic stent infections between July 2016 and October 2016; and patient 4 had postoperative hematuria because he resumed normal activities after stent placement, contrary to instructions. The final location of the stent was confirmed by X-ray imaging after surgery. The examinations described above were performed postoperatively to evaluate therapeutic efficacy.

### Case 1

Because stent removal was recommended for this patient, a general double pigtail tube was placed (4.7 Fr Bard INLAY®). In July 2014, ultrasonography showed severe left hydronephrosis, so the patient was readmitted to the Department of Urology. A metallic stent was placed again and was refreshed. CT scans of the kidney, ureter and bladder in another hospital had shown that the renal cortical thickness was identical in the left and right kidneys. Renal angiography findings were favorable, and there was no left hydronephrosis.

### Case 2

Obstruction was relieved for this patient after she received bilateral metallic stents. At 1 year later, the stent was removed in our department by another surgeon because a rheumatologist in another hospital refused further treatment if the stent was not removed. On 27 November 2014, a CT scan indicated complete left renal atrophy. Because this stent had migrated, the patient developed a urinary tract infection, with frequent urination, urinary urgency and dysuria; thus, she was admitted again on 24 October 2016. The stent was subsequently replaced with a shorter one (26 cm to 24 cm) because of her long legs and compact trunk. Her symptoms resolved after the operation. She received follow-up visits every 3 mo, including ultrasonography, and currently remains symptom-free (Figure 1).

### Case 3

After a bilateral metallic stent was placed, this patient's kidney function improved soon after surgery. His GFR was 18.9 and 11.1 in the right and left kidney, respectively. However, this patient was lost to follow-up.

### Case 4

A right metallic stent was placed successfully for this patient. However, the patient remained physically active, which presumably led to repeated hematuria. A clinician from another hospital who did not agree with placement of the metallic stent recommended removal, but removal failed due to lack of cystoscopic equipment. A laparotomy was then performed for stent removal in the other institution. In January 2016, this patient was reported to have kidney dysfunction and leg edema. We recommended metallic stent placement, but he refused.

### Case 5

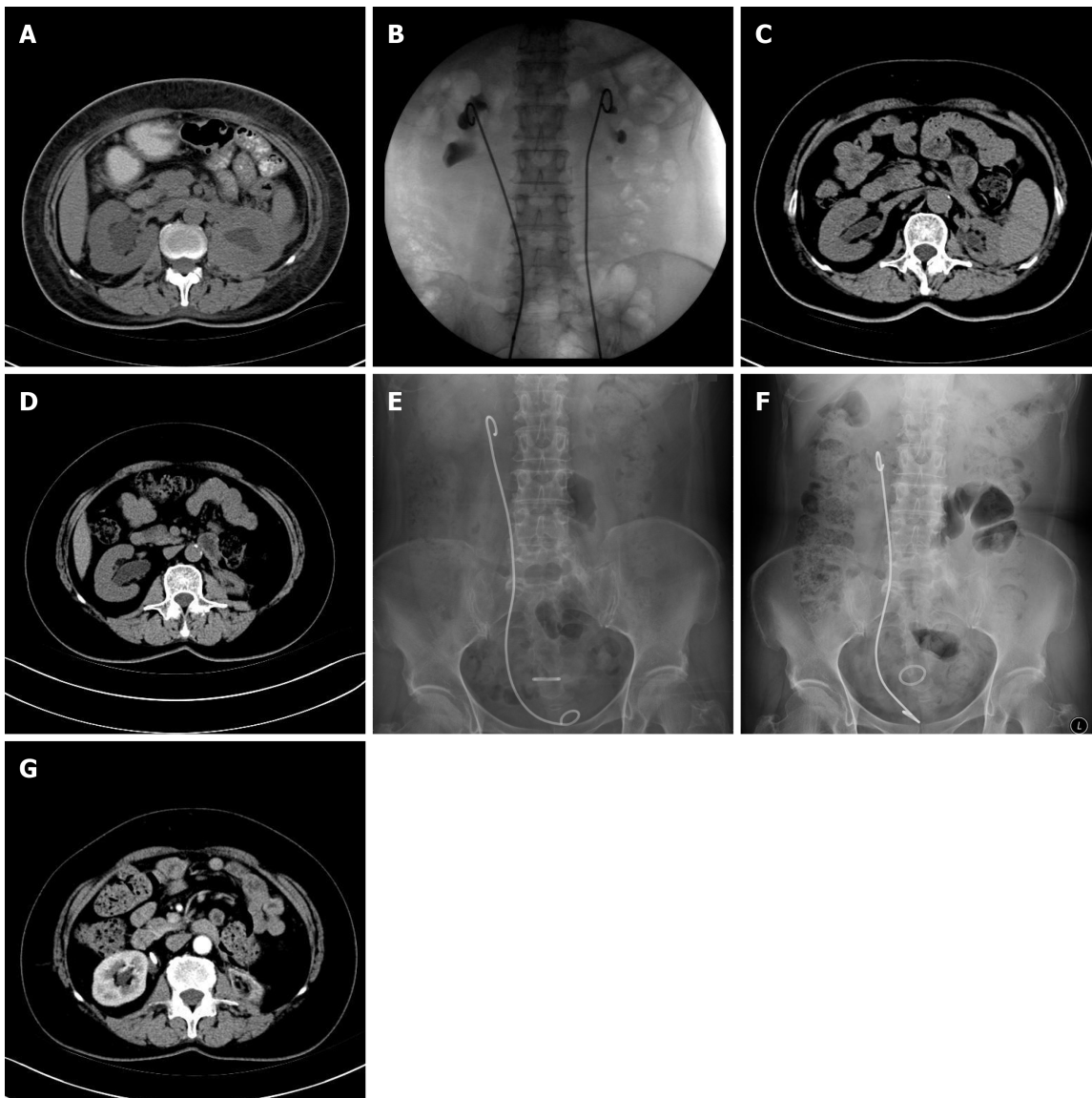
This patient received a right metallic stent in January 2013. On 18 July 2014, the stent was replaced with a polymeric stent (7 Fr Bard, INLAY®). Although he received follow-up ultrasonography every 3 mo, he developed moderate right hydronephrosis. On 29 June 2015, the polymeric stent was replaced with a metallic stent. Thereafter, the stent was refreshed yearly, and the last placement was in July 2016. The indwelling metallic stent existed for 13–39 mo.

### Case 6

A metallic stent was placed in the right ureter of this patient and relieved obstruction successfully. The stent was refreshed yearly thereafter.

### Case 7

In March 2015, a bilateral metallic stent was placed for this patient, and ureteral obstruction was relieved. The stent was refreshed in May 2016.



**Figure 1** Case 2 received follow-up visits every 3 mo, including ultrasonography. A: 8 July 2012, the computed tomography (CT) showed bilateral hydronephrosis; B: X-ray guided the placement of metallic stent retrogradely; C: 27 November 2014, the CT scan indicated the left renal atrophy was complete; D: 13 June 2016, the CT showed right kidney severe hydronephrosis. The left kidney was completely atrophied. The patient had renal insufficiency; E: 24 October 2016, the patient had normal renal function, but severe irritative symptoms of bladder. The patient was not tolerant because the distal end of the long metallic stent was in the bladder and exceeded the midline to stimulate the vesical triangle; F: After replacing this stent with a shorter metallic stent (24 cm to substitute for 26 cm), the end of the metallic stent in the bladder did not cross over the midline, and the irritative symptoms of bladder disappeared. The patient tolerated well the shorter metallic stent, and it was replaced every year. Total renal function was normal; G: 8 October 2018, contrast-enhanced CT revealed contrast was well distributed in the right kidney (total renal function). The metallic stent was located in the right ureteropelvic junction. The left kidney was completely atrophied.

### Case 8

This patient received a left metallic stent placement in May 2015. His serum CCr had been 266 mmol/L before surgery, and 185 mmol/L 1 d after surgery. The GFR was 3.8 and 37.4 mL/min in the right and left kidney, respectively. On 22 May 2015, he was transferred into the Department of General Surgery because of T12-L5 fusion and a mass, suspected of being a tumor. Retroperitoneal exploration was conducted by laparoscopy, and laparotomy was performed. Postoperative pathological examination confirmed the diagnosis of IRPF, but this patient was not re-examined and the stent was also not replaced. A general stent had been placed at the initial treatment, but as hydronephrosis and kidney dysfunction worsened, it was replaced by a metallic stent after his kidney function stabilized.

### Case 9

After this patient received a 26 cm metallic stent in April 2013, he was readmitted into the Division of Rheumatology on 7 May 2013, where he received a diagnosis of IRPF

and was treated with prednisone and tamoxifen, with dose reduction on 24 February 2014. Ultrasonography showed that both kidneys were normal. However, a CT scan showed the metallic stent in the collection system of the left kidney, the left kidney was smaller than the right kidney, the left renal cortex was thinned, soft tissues in the left ureteral area and around the left common iliac artery were reduced, and there was no retroperitoneal lymphadenopathy, leading to a suspected diagnosis of IgG4-related sclerotic disease. The patient was again admitted into the Department of Urology on 23 September 2014, and the metallic stent was refreshed. On admission, he received oral tamoxifen, but the steroid treatment was discontinued. His SCr was 106  $\mu\text{mol/L}$ , and the GFR was 10.5 and 44.2 in the left and right kidney, respectively. He was readmitted to the Department of Urology on 30 May 2016, and the metallic stent was refreshed. On admission, he received oral tamoxifen. His SCr was 99  $\mu\text{mol/L}$ , and the GFR was 10.46 and 44.6 mL/min in the left kidney and right kidney, respectively. The patient was followed regularly. On 1 June 2017, the contrast-enhanced CT still showed that the anterior and the bilateral sides of the aorta were surrounded by fibrotic tissues of peri-aortic inflammation caused by IRPF. The left ureter was involved in these tissues. However, contrast revealed that drainage of the left ureteral lumen was ensured by the metallic stent without obstruction.

## DISCUSSION

Our institution admitted 9 patients with IRPF over a 5-year period, all of whom received Resonance<sup>®</sup> metallic stents to restore kidney function. We found that these stents relieved ureteral obstruction in all 9 cases, and that only 2 patients (patients 2 and 4) experienced adverse effects (stent migration and repeated metallic stent infections in patient 2, and postoperative hematuria in patient 4). Thus, these stents demonstrated effective relief and resulted in fewer complications for the treatment of ureteral stenosis in patients with IRPF.

In this case series, the Resonance<sup>®</sup> metallic ureteral stent had a mean indwelling time of 12 mo. The stent was longer than plastic or polymeric stents, which was echoed in the results reported by Christman *et al.*<sup>[4]</sup> showing that the critical pressure was 4 lbs for plastic stents and 32 lbs for the Resonance<sup>®</sup> metallic stent. The authors of that study also reported that, after removal of the pressure, the plastic stent did not recover its original shape, but the metallic stent recovered completely and continued to provide good drainage. This parallels our experience with insertion of metallic stents.

The pathogenesis of IRPF is similar to that of other autoimmune diseases, in that it causes chronic and non-specific inflammation. The progressive fibrous hyperplasia around the retroperitoneal major arteries and compression of major tissues, especially the ureter, can cause obstruction<sup>[1]</sup>. In addition to pharmacological treatments for IRPF<sup>[9,10]</sup>, surgery is also needed to provide relief from the inevitable ureteral obstruction. A ureteral stent is usually successful in restoring renal flow, but laparotomy /laparoscopy may be needed for ureterolysis if the disease continues to progress or the ureteroscopy fails<sup>[5]</sup>. In the present case series, we found that stent placement was successful in all 9 patients, and none of them required ureterolysis. Ultrasonography provides reliable evidence of hydronephrosis, aortic dilatation, aneurysm and masses besides the aorta<sup>[11-13]</sup>. CT, magnetic resonance imaging, Doppler-weighted ultrasound and fluorodeoxyglucose-positron emission tomography may also be used for diagnosis and the assessment of disease progression and treatment efficacy, as reported previously<sup>[14]</sup>.

## CONCLUSION

Detailed review of all 9 cases in this series shows that ureteral stents provide effective relief and reduce the incidence rate of perioperative and postoperative complications in patients with IRPF. IRPF is a rare and chronic disease, which made it very difficult for us to increase case numbers of IRPF. However, we conclude that our experience with these 9 cases underscores the utility and efficacy of applying the Resonance<sup>®</sup> metallic ureteral stent to treat ureteral obstruction in this patient population.

## REFERENCES

- 1 **Vaglio A**, Salvarani C, Buzio C. Retroperitoneal fibrosis. *Lancet* 2006; **367**: 241-251 [PMID: [16427494](#) DOI: [10.1016/S0140-6736\(06\)68035-5](#)]
- 2 **Urban ML**, Palmisano A, Nicastro M, Corradi D, Buzio C, Vaglio A. Idiopathic and secondary forms of retroperitoneal fibrosis: a diagnostic approach. *Rev Med Interne* 2015; **36**: 15-21 [PMID: [25455951](#) DOI: [10.1016/j.revmed.2014.10.008](#)]
- 3 **Oshiro H**, Ebihara Y, Serizawa H, Shimizu T, Teshima S, Kuroda M, Kudo M. Idiopathic retroperitoneal fibrosis associated with immunohematological abnormalities. *Am J Med* 2005; **118**: 782-786 [PMID: [15989914](#) DOI: [10.1016/j.amjmed.2005.02.004](#)]
- 4 **Christman MS**, L'esperance JO, Choe CH, Stroup SP, Auge BK. Analysis of ureteral stent compression force and its role in malignant obstruction. *J Urol* 2009; **181**: 392-396 [PMID: [19010490](#) DOI: [10.1016/j.juro.2008.08.125](#)]
- 5 **Duchene DA**, Winfield HN, Cadeddu JA, Clayman RV, Gomella LG, Kavoussi LR, Mikhail AA, Park S, Permpongkosol S, Shalhav AL. Multi-institutional survey of laparoscopic ureterolysis for retroperitoneal fibrosis. *Urology* 2007; **69**: 1017-1021 [PMID: [17572177](#) DOI: [10.1016/j.urology.2007.02.004](#)]
- 6 **Stifelman MD**, Shah O, Mufarrij P, Lipkin M. Minimally invasive management of retroperitoneal fibrosis. *Urology* 2008; **71**: 201-204 [PMID: [18308083](#) DOI: [10.1016/j.urology.2007.10.026](#)]
- 7 **Benson AD**, Taylor ER, Schwartz BF. Metal ureteral stent for benign and malignant ureteral obstruction. *J Urol* 2011; **185**: 2217-2222 [PMID: [21497845](#) DOI: [10.1016/j.juro.2011.02.008](#)]
- 8 **Polcari AJ**, Huguen CM, López-Huertas HL, Turk TM. Cost analysis and clinical applicability of the Resonance metallic ureteral stent. *Expert Rev Pharmacoecon Outcomes Res* 2010; **10**: 11-15 [PMID: [20121560](#) DOI: [10.1586/erp.09.74](#)]
- 9 **Khosroshahi A**, Stone JH. A clinical overview of IgG4-related systemic disease. *Curr Opin Rheumatol* 2011; **23**: 57-66 [PMID: [21124086](#) DOI: [10.1097/BOR.0b013e3283418057](#)]
- 10 **Pelkmans LG**, Hendriksz TR, Westenend PJ, Vermeer HJ, van Bommel EFH. Elevated serum IgG4 levels in diagnosis and treatment response in patients with idiopathic retroperitoneal fibrosis. *Clin Rheumatol* 2017; **36**: 903-912 [PMID: [28105551](#) DOI: [10.1007/s10067-017-3542-8](#)]
- 11 **Borin JF**, Melamud O, Clayman RV. Initial experience with full-length metal stent to relieve malignant ureteral obstruction. *J Endourol* 2006; **20**: 300-304 [PMID: [16724898](#) DOI: [10.1089/end.2006.20.300](#)]
- 12 **Mishra K**, Zargar H, Tarplin S, Ramanathan R, Stein RJ. Idiopathic retroperitoneal fibrosis. *J Urol* 2015; **193**: 1657-1658 [PMID: [25659660](#) DOI: [10.1016/j.juro.2015.01.101](#)]
- 13 **Wah TM**, Irving HC, Cartledge J. Initial experience with the resonance metallic stent for antegrade ureteric stenting. *Cardiovasc Intervent Radiol* 2007; **30**: 705-710 [PMID: [17508238](#) DOI: [10.1007/s00270-007-9043-4](#)]
- 14 **Jansen I**, Hendriksz TR, Han SH, Huiskes AW, van Bommel EF. (18)F-fluorodeoxyglucose position emission tomography (FDG-PET) for monitoring disease activity and treatment response in idiopathic retroperitoneal fibrosis. *Eur J Intern Med* 2010; **21**: 216-221 [PMID: [20493425](#) DOI: [10.1016/j.ejim.2010.02.008](#)]



Published by **Baishideng Publishing Group Inc**  
7041 Koll Center Parkway, Suite 160, Pleasanton, CA 94566, USA

**Telephone:** +1-925-3991568

**E-mail:** [bpgoffice@wjgnet.com](mailto:bpgoffice@wjgnet.com)

**Help Desk:** <https://www.f6publishing.com/helpdesk>

<https://www.wjgnet.com>

