

World Journal of *Clinical Cases*

World J Clin Cases 2020 August 6; 8(15): 3136-3376



OPINION REVIEW

- 3136** Impacts and challenges of United States medical students during the COVID-19 pandemic
Rolak S, Keefe AM, Davidson EL, Aryal P, Parajuli S
- 3142** Recent advances in the management of gastrointestinal stromal tumor
Ahmed M
- 3156** Medical research during the COVID-19 pandemic
AlNaamani K, AlSinani S, Barkun AN

REVIEW

- 3164** Progress of intravoxel incoherent motion diffusion-weighted imaging in liver diseases
Tao YY, Zhou Y, Wang R, Gong XQ, Zheng J, Yang C, Yang L, Zhang XM

MINIREVIEWS

- 3177** Typical and atypical COVID-19 computed tomography findings
Caruso D, Polidori T, Guido G, Nicolai M, Bracci B, Cremona A, Zerunian M, Polici M, Pucciarelli F, Rucci C, Dominici CD, Girolamo MD, Argento G, Sergi D, Laghi A
- 3188** Review of possible psychological impacts of COVID-19 on frontline medical staff and reduction strategies
Fu XW, Wu LN, Shan L

ORIGINAL ARTICLE

Clinical and Translational Research

- 3197** Overexpression of AMPD2 indicates poor prognosis in colorectal cancer patients *via* the Notch3 signaling pathway
Gao QZ, Qin Y, Wang WJ, Fei BJ, Han WF, Jin JQ, Gao X

Case Control Study

- 3209** Effect of motivational interviewing on postoperative weight control in patients with obstructive sleep apnea-hypopnea syndrome
Sun XH, Xue PS, Qi XX, Fan L

Retrospective Study

- 3218** Thalidomide for refractory gastrointestinal bleeding from vascular malformations in patients with significant comorbidities
Bayudan AM, Chen CH

- 3230** Colorectal adenocarcinoma patients with M1a diseases gain more clinical benefits from palliative primary tumor resection than those with M1b diseases: A propensity score matching analysis

Li CL, Tang DR, Ji J, Zang B, Chen C, Zhao JQ

- 3240** Surgical outcomes of bladder augmentation: A comparison of three different augmentation procedures

Sun XG, Wang RY, Xu JL, Li DG, Chen WX, Li JL, Wang J, Li AW

Clinical Trials Study

- 3249** Comparison of measurements of anterior chamber angle *via* anterior segment optical coherence tomography and ultrasound biomicroscopy

Yu ZY, Huang T, Lu L, Qu B

Observational Study

- 3259** Dydrogesterone treatment for menstrual-cycle regularization in abnormal uterine bleeding – ovulation dysfunction patients

Wang L, Guan HY, Xia HX, Chen XY, Zhang W

CASE REPORT

- 3267** Multi-organ IgG4-related disease continues to mislead clinicians: A case report and literature review

Strainiene S, Sarlauskas L, Savlan I, Liakina V, Stundiene I, Valantinas J

- 3280** *Campylobacter jejuni* enterocolitis presenting with testicular pain: A case report

Sanagawa M, Kenzaka T, Kato S, Yamaoka I, Fujimoto S

- 3284** Natural killer/T-cell lymphoma with intracranial infiltration and Epstein-Barr virus infection: A case report

Li N, Wang YZ, Zhang Y, Zhang WL, Zhou Y, Huang DS

- 3291** Successful management of tubular colonic duplication using a laparoscopic approach: A case report and review of the literature

Li GB, Han JG, Wang ZJ, Zhai ZW, Tao Y

- 3299** Hypothyroidism with elevated pancreatic amylase and lipase without clinical symptoms: A case report

Xu YW, Li R, Xu SC

- 3305** Two mechanically ventilated cases of COVID-19 successfully managed with a sequential ventilation weaning protocol: Two case reports

Peng M, Ren D, Liu YF, Meng X, Wu M, Chen RL, Yu BJ, Tao LC, Chen L, Lai ZQ

- 3314** Adult duodenal intussusception with horizontal adenoma: A rare case report

Wang KP, Jiang H, Kong C, Wang LZ, Wang GY, Mo JG, Jin C

- 3320** Isolated metachronous splenic multiple metastases after colon cancer surgery: A case report and literature review

Hu L, Zhu JY, Fang L, Yu XC, Yan ZL

- 3329** Imaging of hemorrhagic primary central nervous system lymphoma: A case report
Wu YW, Zheng J, Liu LL, Cai JH, Yuan H, Ye J
- 3334** Coexistence of ovarian serous papillary cystadenofibroma and type A insulin resistance syndrome in a 14-year-old girl: A case report
Yan FF, Huang BK, Chen YL, Zhuang YZ, You XY, Liu CQ, Li XJ
- 3341** Acute suppurative oesophagitis with fever and cough: A case report
Men CJ, Singh SK, Zhang GL, Wang Y, Liu CW
- 3349** Computed tomography, magnetic resonance imaging, and F-deoxyglucose positron emission computed tomography/computed tomography findings of alveolar soft part sarcoma with calcification in the thigh: A case report
Wu ZJ, Bian TT, Zhan XH, Dong C, Wang YL, Xu WJ
- 3355** COVID-19 with asthma: A case report
Liu AL, Xu N, Li AJ
- 3365** Total laparoscopic segmental gastrectomy for gastrointestinal stromal tumors: A case report
Ren YX, He M, Ye PC, Wei SJ
- 3372** Facial and bilateral lower extremity edema due to drug-drug interactions in a patient with hepatitis C virus infection and benign prostate hypertrophy: A case report
Li YP, Yang Y, Wang MQ, Zhang X, Wang WJ, Li M, Wu FP, Dang SS

ABOUT COVER

Editorial Board Member of *World Journal of Clinical Cases*, Dr. Romano is Professor of Medicine-Gastroenterology at the University of Campania “Luigi Vanvitelli” in Naples, Italy. Dr. Romano received his MD degree cum Laude at the University Federico II in Naples, Italy in 1980 and, after 4 year of Post-Graduate course, he became Specialist in Gastroenterology and Gastrointestinal Endoscopy. Dr. Romano’s research interest was on the cross-talk between H. pylori and gastric epithelial cells, and presently is mainly focused on H. pylori eradication therapy and on the role of nutraceuticals in gastrointestinal diseases. Dr. Romano is presently the Chief of the Endoscopy and Chronic Inflammatory Gastrointestinal Disorders Unit, and Teacher at the University of Campania “Luigi Vanvitelli” in Naples, Italy.

AIMS AND SCOPE

The primary aim of *World Journal of Clinical Cases* (*WJCC*, *World J Clin Cases*) is to provide scholars and readers from various fields of clinical medicine with a platform to publish high-quality clinical research articles and communicate their research findings online.

WJCC mainly publishes articles reporting research results and findings obtained in the field of clinical medicine and covering a wide range of topics, including case control studies, retrospective cohort studies, retrospective studies, clinical trials studies, observational studies, prospective studies, randomized controlled trials, randomized clinical trials, systematic reviews, meta-analysis, and case reports.

INDEXING/ABSTRACTING

The *WJCC* is now indexed in Science Citation Index Expanded (also known as SciSearch®), Journal Citation Reports/Science Edition, PubMed, and PubMed Central. The 2020 Edition of Journal Citation Reports® cites the 2019 impact factor (IF) for *WJCC* as 1.013; IF without journal self cites: 0.991; Ranking: 120 among 165 journals in medicine, general and internal; and Quartile category: Q3.

RESPONSIBLE EDITORS FOR THIS ISSUE

Electronic Editor: *Yan-Xia Xing*, Production Department Director: *Yun-Xiaojian Wu*, Editorial Office Director: *Jin-Lei Wang*.

NAME OF JOURNAL

World Journal of Clinical Cases

ISSN

ISSN 2307-8960 (online)

LAUNCH DATE

April 16, 2013

FREQUENCY

Semimonthly

EDITORS-IN-CHIEF

Dennis A Bloomfield, Sandro Vento, Bao-Gan Peng

EDITORIAL BOARD MEMBERS

<https://www.wjgnet.com/2307-8960/editorialboard.htm>

PUBLICATION DATE

August 6, 2020

COPYRIGHT

© 2020 Baishideng Publishing Group Inc

INSTRUCTIONS TO AUTHORS

<https://www.wjgnet.com/bpg/gerinfo/204>

GUIDELINES FOR ETHICS DOCUMENTS

<https://www.wjgnet.com/bpg/GerInfo/287>

GUIDELINES FOR NON-NATIVE SPEAKERS OF ENGLISH

<https://www.wjgnet.com/bpg/gerinfo/240>

PUBLICATION ETHICS

<https://www.wjgnet.com/bpg/GerInfo/288>

PUBLICATION MISCONDUCT

<https://www.wjgnet.com/bpg/gerinfo/208>

ARTICLE PROCESSING CHARGE

<https://www.wjgnet.com/bpg/gerinfo/242>

STEPS FOR SUBMITTING MANUSCRIPTS

<https://www.wjgnet.com/bpg/GerInfo/239>

ONLINE SUBMISSION

<https://www.f6publishing.com>

Clinical Trials Study

Comparison of measurements of anterior chamber angle via anterior segment optical coherence tomography and ultrasound biomicroscopy

Zi-Yan Yu, Ting Huang, Lu Lu, Bo Qu

ORCID number: Zi-Yan Yu 0000-0003-1091-428X; Ting Huang 0000-0003-0677-0631; Lu Lu 0000-0002-9771-0206; Bo Qu 0000-0002-2261-8464.

Author contributions: Yu ZY and Huang T contributed equally to this work; all authors helped to perform the research; Qu B drafted the manuscript; Yu ZY, Huang T, and Lu L reviewed the published articles and analyzed the data; all authors read and approved the final manuscript.

Institutional review board statement: This study was reviewed and approved by the Ethics Committee of the Fourth Affiliated Hospital of China Medical University.

Clinical trial registration statement: The name of the trial registry is agreement between anterior segment optical coherence tomography, lenstar and ultrasound biomicroscopy measurements of anterior segment parameters. The registry's URL is www.medresman.org and the registration number is ChiCTR1900021378.

Informed consent statement: Written informed consent was

Zi-Yan Yu, Lu Lu, Bo Qu, Department of Ophthalmology, Fourth Affiliated Hospital of China Medical University, Eye Hospital of China Medical University, Key Laboratory of Lens Research of Liaoning Province, Shenyang 110005, Liaoning Province, China

Ting Huang, Department of Cataract, Aier Mega Ophthalmic Hospital of Chongqing, Chongqing 400060, China

Corresponding author: Bo Qu, MD, PhD, Associate Professor, Department of Ophthalmology, Fourth Affiliated Hospital of China Medical University, Eye Hospital of China Medical University, Key Laboratory of Lens Research of Liaoning Province, No. 11 Xinhua Road, Shenyang 110005, Liaoning Province, China. dolphinemu@foxmail.com

Abstract

BACKGROUND

Glaucoma is an irreversible optic neuropathy with the loss of visual field and decrease of vision. The variable clinical manifestations may result in differential diagnostic difficulties. The early screening and diagnosis of glaucoma are currently experiencing a demand for anterior segment analysis tools that can gather more information with one short measurement. Therefore, we analyzed the agreement, difference, and correlation of chamber angle parameters such as angle opening distance at 500 μm (AOD500) and trabeculo-iris space area at 500 μm^2 (TISA500) measured by anterior segment optical coherence tomography (AS-OCT) and ultrasound biomicroscopy (UBM).

AIM

To compare the differences, correlation, and agreement in measuring AOD500 and TISA500 by AS-OCT and UBM.

METHODS

Both AS-OCT and UBM were performed to measure AOD500 and TISA500 in 45 subjects (72 eyes). All subjects without glaucoma were collected from October 2015 to August 2016 at the Ophthalmology Department of the Fourth Affiliated Hospital of China Medical University. Data of the two groups (AOD500 and TISA500) were compared by nonparametric tests. Pearson correlative analysis and Bland-Altman analysis were used to compare the correlation and agreement.

obtained from all the patients.

Conflict-of-interest statement: The authors have stated that they have no conflicts of interest.

Data sharing statement: The datasets of this study are readily available from the corresponding author on reasonable request.

CONSORT 2010 statement: The guidelines of the CONSORT 2010 statement have been adopted.

Open-Access: This article is an open-access article that was selected by an in-house editor and fully peer-reviewed by external reviewers. It is distributed in accordance with the Creative Commons Attribution NonCommercial (CC BY-NC 4.0) license, which permits others to distribute, remix, adapt, build upon this work non-commercially, and license their derivative works on different terms, provided the original work is properly cited and the use is non-commercial. See: <http://creativecommons.org/licenses/by-nc/4.0/>

Manuscript source: Unsolicited manuscript

Received: April 9, 2020

Peer-review started: April 9, 2020

First decision: April 29, 2020

Revised: May 11, 2020

Accepted: July 14, 2020

Article in press: July 14, 2020

Published online: August 6, 2020

P-Reviewer: Apisarnthanarax S, Snowdon VK, Voigt M

S-Editor: Wang JL

L-Editor: Wang TQ

E-Editor: Xing YX



RESULTS

There were no significant differences between AS-OCT and UBM in measuring AOD500 ($P_1 = 0.110$, $P_2 = 0.633$, $P_3 = 0.078$, and $P_4 = 0.474$) and TISA500 ($P_1 = 0.584$, $P_2 = 0.889$, $P_3 = 0.297$, and $P_4 = 0.550$) of the four quadrants of the anterior chamber angle. There was a high correlation in measuring AOD500 ($r_1 = 0.562$, $r_2 = 0.671$, $r_3 = 0.635$, and $r_4 = 0.720$; $P < 0.001$) and TISA500 ($r_1 = 0.584$, $r_2 = 0.889$, $r_3 = 0.297$, and $r_4 = 0.550$; $P < 0.001$). There was a good agreement in measuring AOD500 and TISA500 by the two modalities.

CONCLUSION

There is a high correlation and agreement between AOD500 and TISA500 measurements by AS-OCT and UBM. They are interchangeable under some circumstances. AS-OCT proves to be a better early screening tool for glaucoma.

Key words: Anterior segment-optical coherence tomography; Primary angle closure glaucoma; Anterior chamber angle; Angel opening distance at 500 μm ; Trabeculo-iris space area at 500 μm^2

©The Author(s) 2020. Published by Baishideng Publishing Group Inc. All rights reserved.

Core tips: Glaucoma is an irreversible optic neuropathy with the loss of visual field and decrease of vision. The early screening and diagnosis of glaucoma are currently experiencing a demand for anterior segment analysis tools that can gather more information with one short measurement. In this study, we compared the agreement, difference, and correlation of anterior chamber angle parameters such as angel opening distance at 500 μm and trabeculo-iris space area at 500 μm^2 measured by anterior segment optical coherence tomography and ultrasound biomicroscopy.

Citation: Yu ZY, Huang T, Lu L, Qu B. Comparison of measurements of anterior chamber angle via anterior segment optical coherence tomography and ultrasound biomicroscopy. *World J Clin Cases* 2020; 8(15): 3249-3258

URL: <https://www.wjgnet.com/2307-8960/full/v8/i15/3249.htm>

DOI: <https://dx.doi.org/10.12998/wjcc.v8.i15.3249>

INTRODUCTION

Glaucoma is an irreversible optic neuropathy with the loss of visual field and decrease of vision. There are no obvious clinical manifestations in the early stage of glaucoma; typical visual field defects or progressive loss of visual acuity and other symptoms may appear in the moderate or severe phase of glaucoma^[1,2]. Approximately 80% of aqueous humor flows out through the anterior chamber angle, when aqueous humor outflow obstruction is caused by abnormality of anterior chamber angle structure or function, and compensatory imbalance of aqueous humor leads to increased intraocular pressure.

At present, gonioscopy, anterior segment optical coherence tomography (AS-OCT), and ultrasound biomicroscopy (UBM) are commonly used to evaluate anterior chamber angle^[3-5]. AS-OCT and other non-contact imaging modalities provide a quick, user-friendly, and objective non-invasive method of assessing the anterior segment parameters and anterior chamber angle, are well tolerated by the patient, and correlate well with the information provided by gonioscopy^[6,7].

In this study, we evaluated the agreement, difference, and correlation of chamber angle parameters such as angel opening distance at 500 μm (AOD500) and trabeculo-iris space area at 500 μm^2 (TISA500) measured by AS-OCT and UBM.

MATERIALS AND METHODS

Study subjects

Forty-five subjects (15 males and 30 females; age range, 50–80 years) without glaucoma who visited the Fourth Affiliated Hospital of China Medical University from October 2015 to August 2016 were selected. All subjects underwent routine ophthalmological examinations (including visual acuity, intraocular pressure, integrated optometry, slit lamp examination, and fundus examination) and AS-OCT and UBM. None of the subjects had an intraocular surgery or laser procedure, and none of the subjects had evidence of glaucoma, dry eye disease, ocular inflammatory activity, or other ocular diseases.

This study was approved by the Fourth Affiliated Hospital of China Medical University Committee on Human Research. The registry's URL is www.medresman.org and the registration number is ChiCTR1900021378. All study procedures adhered to the Declaration of Helsinki for research involving human participants. All participants provided informed consent after explanation of possible consequences of the study to them.

AOD500 and TISA500 evaluation procedures

The patients were examined in the order of AS-OCT (sitting position) and UBM (supine position). The interval of examinations was about 5 min; all the examinations with the same instrument were performed three times in the same brightness environment and by the same operator. The average values of AOD500 and TISA500 of four quadrants for each eye were recorded.

Statistical analysis

All descriptive analyses, difference analyses, and correlation analyses were performed with SPSS version 19.0, and agreement analysis was performed with MedCalc version 15.0. All descriptive results are expressed as the mean \pm SD. The differences in the two instruments were analyzed by paired *t*-test if the data were in accordance with the normal distribution and the variance was homogeneous; otherwise, nonparametric tests were used. Correlations and agreements between the instruments were performed by Pearson correlation analysis and Bland–Altman analysis. *P* < 0.05 was considered statistically significant.

RESULTS

A total of 15 male subjects (24 eyes) and 30 female subjects (48 eyes) were examined by UBM and AS-OCT for anterior chamber angles parameters (AOD500 and TISA500), with a mean age of 59.47 ± 14.481 years.

AOD500 and TISA500 measured by AS-OCT and UBM

AOD500 at 90° (12 o'clock position) was 0.2453 ± 0.2566 mm by AS-OCT and 0.1642 ± 0.1502 mm by UBM. AOD500 at 0° (3 o'clock position) was 0.2493 ± 0.2065 mm by AS-OCT and 0.2090 ± 0.1344 mm by UBM. AOD500 at 270° (6 o'clock position) was 0.2828 ± 0.2587 mm by AS-OCT and 0.1914 ± 0.1410 mm by UBM. AOD500 at 180° (9 o'clock position) was 0.2661 ± 0.2300 mm by AS-OCT and 0.2194 ± 0.1523 mm by UBM.

TISA500 at 90° (12 o'clock position) was 0.0912 ± 0.0884 mm by AS-OCT and 0.0749 ± 0.0630 mm by UBM. TISA500 at 0° (3 o'clock position) was 0.0997 ± 0.0716 mm by AS-OCT and 0.0982 ± 0.0676 mm by UBM. TISA500 at 270° (6 o'clock position) was 0.1066 ± 0.0941 mm by AS-OCT and 0.0842 ± 0.0625 mm by UBM. TISA500 at 180° (9 o'clock position) was 0.1071 ± 0.0773 mm by AS-OCT and 0.1004 ± 0.0765 mm by UBM.

For AOD500 and TISA500 of the four quadrants of the chamber angles, measurements by AS-OCT were greater than those by UBM. AOD500 measured by AS-OCT from wide to narrow were 6 o'clock, 9 o'clock, 3 o'clock, and 12 o'clock positions. AOD500 measured by UBM from big to small were 9 o'clock, 3 o'clock, 6 o'clock, and 12 o'clock positions. TISA500 measurements by AS-OCT from wide to narrow were 9 o'clock, 6 o'clock, 3 o'clock, and 12 o'clock positions. TISA500 measurements by UBM from big to small were 9 o'clock, 3 o'clock, 6 o'clock, and 12 o'clock positions.

Differences in AOD500 and TISA500 measured by AS-OCT and UBM

The measurements of AOD500 and TISA500 using the two methods were not normally

distributed, and the homogeneity of variance (Mann-Whitney test) and the differences in them were compared using nonparametric tests. There was no significant differences between the two methods in measuring AOD500 of the four quadrants of the chamber angles ($P_1 = 0.110$, $P_2 = 0.633$, $P_3 = 0.078$, and $P_4 = 0.474$). There was no significant differences between the two methods in measuring TISA500 of the four quadrants of the chamber angles ($P_1 = 0.584$, $P_2 = 0.889$, $P_3 = 0.297$, and $P_4 = 0.550$). Comparing the AOD500 and TISA500 measured by AS-OCT and UBM, the results were not significantly different ($P > 0.05$).

Correlations of AOD500 and TISA500 measured by the two methods

The AOD500 measurements by AS-OCT and UBM at 90° ($r = 0.562$, $P < 0.001$), 0° ($r = 0.671$, $P < 0.001$), 270° ($r = 0.635$, $P < 0.001$), and 180° ($r = 0.720$, $P < 0.001$) were highly correlated (Figure 1).

The TISA500 measurements by AS-OCT and UBM at 90° ($r = 0.466$, $P < 0.001$), 0° ($r = 0.652$, $P < 0.001$), 270° ($r = 0.507$, $P < 0.001$), and 180° ($r = 0.545$, $P < 0.001$) were highly correlated (Figure 2).

Agreements of AOD500 and TISA500 measured by the two methods

Agreement of the AOD500 measurements by the two methods was analyzed by Bland-Altman diagram at the four quadrants of the anterior chamber angles (Figure 3). At 90° , four (2.78%) of 144 points were outside the confidence interval. At 0° , four of 144 points were outside the confidence interval. At 270° , three (2.08%) of 144 points were outside the confidence interval. At 180° , four of 144 points were outside the confidence interval. The Bland-Altman diagram of AOD500 measurements at any quadrants of the chamber angles showed that $> 95\%$ of the data points were in the 95% agreement interval and the confidence interval was relatively narrow, with no significant difference, and could be clinically accepted. Bland-Altman diagram analysis showed that the results of AOD500 measurements at four quadrants of the chamber angles measured by the two methods were in good agreement.

Agreements of the TISA500 measurements by the two methods were analyzed by Bland-Altman diagram at the four quadrants of the anterior chamber angles (Figure 4). At 90° , four (2.78%) of 144 points were outside the confidence interval. At 0° , five (3.47%) of 144 points were outside the confidence interval. At 270° , three (2.08%) of 144 points were outside the confidence interval. At 180° , five (3.47%) of 144 points were outside the confidence interval. The Bland-Altman diagram of TISA500 measurements at any quadrants of the chamber angles showed that $> 95\%$ of the data points were in the 95% agreement interval and the confidence interval was relatively narrow, with no significant difference, and could be clinically accepted. Bland-Altman diagram analysis showed that the results of TISA500 measurements at four quadrants of the chamber angles measured by the two methods were in good agreement.

DISCUSSION

Microstructures of the anterior chamber angle (such as iris root, scleral protrusion, and trabecular meshwork) can be observed to estimate the degree of opening of the anterior chamber angle, and its structure and function can be estimated by gonioscopy^[8,9]. Observation of a scleral spur suggests complete exposure of the functional trabecular meshwork, and this is a marker in imaging examination and the first step in observation^[10]. AOD500 and TISA500 measurements are affected by body position, eye position, whether there is contact or pressure on the eye during measurement, and whether front and rear boundary measurements are accurate^[11,12]. Under the influence of gravity, the cornea can be compressed by the upper eyelid, and the normal anterior chamber angle shows that the top position is narrowest and the bottom position is widest, followed by nasal and temporal position^[13].

At present, objective methods of visualizing anterior chamber angle are UBM and AS-OCT. AOD500 and TISA500 measurements by AS-OCT were, respectively, 0.2453 ± 0.2566 mm and 0.0912 ± 0.0884 mm at 90° , 0.2828 ± 0.2587 mm and 0.1066 ± 0.0941 mm at 270° , 0.2493 ± 0.2065 mm and 0.2661 ± 0.2300 mm at 0° , and 0.0997 ± 0.0716 mm and 0.1071 ± 0.0773 mm at 180° . AS-OCT is a non-contact examination with the subject in the sitting position, and it is not affected by body and eye positions^[14]. In AOD500 and TISA500 measurements, the top position angle is narrowest and coincides with the physiological state. In AOD500 measurements, the bottom position angle is widest and coincides with the physiological state. In TISA500 measurements, related to the measurement error, the 270° angle is widest but not much different from the bottom

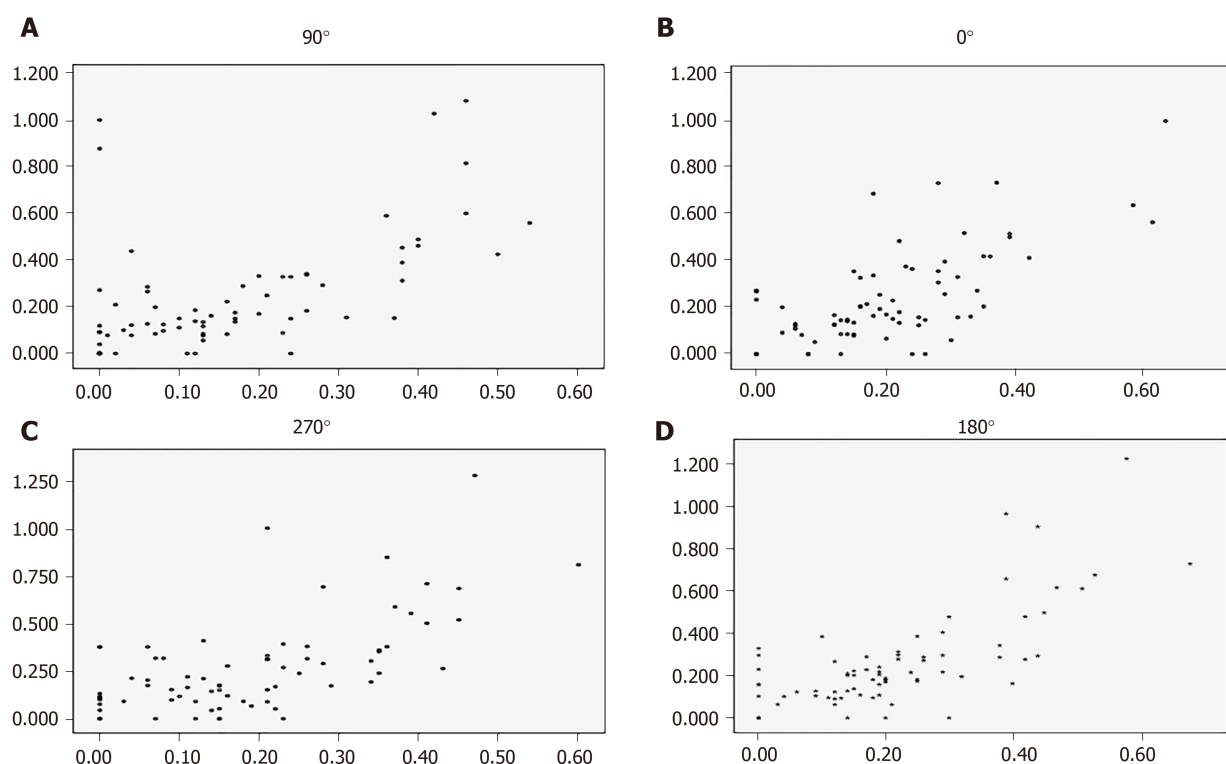


Figure 1 Correlation diagrams of angle opening distance at 500 μm measured by the two instruments of the four quadrants of the chamber angles. The X axis represents ultrasound biomicroscopy. The Y axis represents anterior segment optical coherence tomography. A: At 90°; B: At 0°; C: At 270°; D: At 180°.

position angle. There are many reasons for the measurement error. The eyeball may be completely exposed while measuring, which can exert pressure on the eyeball, thus affecting the accuracy of measurement. The measurements are automatically identified by computer, resulting in inaccuracy of the positioning boundaries.

AOD500 and TISA500 measurements by UBM were, respectively, 0.1642 ± 0.1502 mm and 0.0749 ± 0.0630 mm at 90° position, 0.1914 ± 0.1410 mm and 0.0842 ± 0.0625 mm at 270°, 0.2090 ± 0.1344 mm and 0.2194 ± 0.1523 mm at 0°, and 0.0982 ± 0.0676 mm and 0.1004 ± 0.0765 mm at 180°. In AOD500 and TISA500 measurements, the top position angle is narrowest, the 180° position angle is widest, and the 0° position takes second place. Considering that UBM is performed with the patient in the supine position, change of barycenter leads to redistribution of aqueous humor; the width of the horizontal anterior chamber angle increases, and the width of the lower anterior chamber angle decreases. When measuring in one direction, the patient's eyeball rotates and eye position changes in that direction, which can cause measurement error. It is a contact examination and has a greater possibility of eye compression, both of which can affect the measurement results. Moreover, UBM resolution is lower, and manual measurement can introduce human error.

Comparing the degree of openness of the anterior chamber angle can determine opening and closing and degree of stenosis of the anterior chamber angle. Moreover, it can be used to compare preoperative and postoperative chamber angle changes^[15-17]. By comparing the AOD500 and TISA500 measurements *via* UBM and AS-OCT, we conclude that the agreement and correlation are excellent, and there is no significant difference between them, proving that they are interchangeable. Previous studies also support this viewpoint^[1,18-21]. Compared with UBM, AS-OCT has better repeatability, noninvasiveness, rapidity, high resolution, and automatic analysis. These features can avoid measurement errors caused by eye compression, eyeball rotation, and body position change, making anterior chamber angle parameters more coincident with those under physiological conditions. AS-OCT can also avoid human measurement error, making the data in good repeatability. As a non-contact device, with short measure time, fast and clear imaging, and easily follow-up, AS-OCT can be widely used in glaucoma screening, open eye injury, and other diseases. However, UBM can be used to diagnose ciliary body detachment, ciliary body tumor, peripheral retinal detachment, and other diseases, while AS-OCT cannot.

The effect of intragroup differences on the results was considered. Age, sex, and

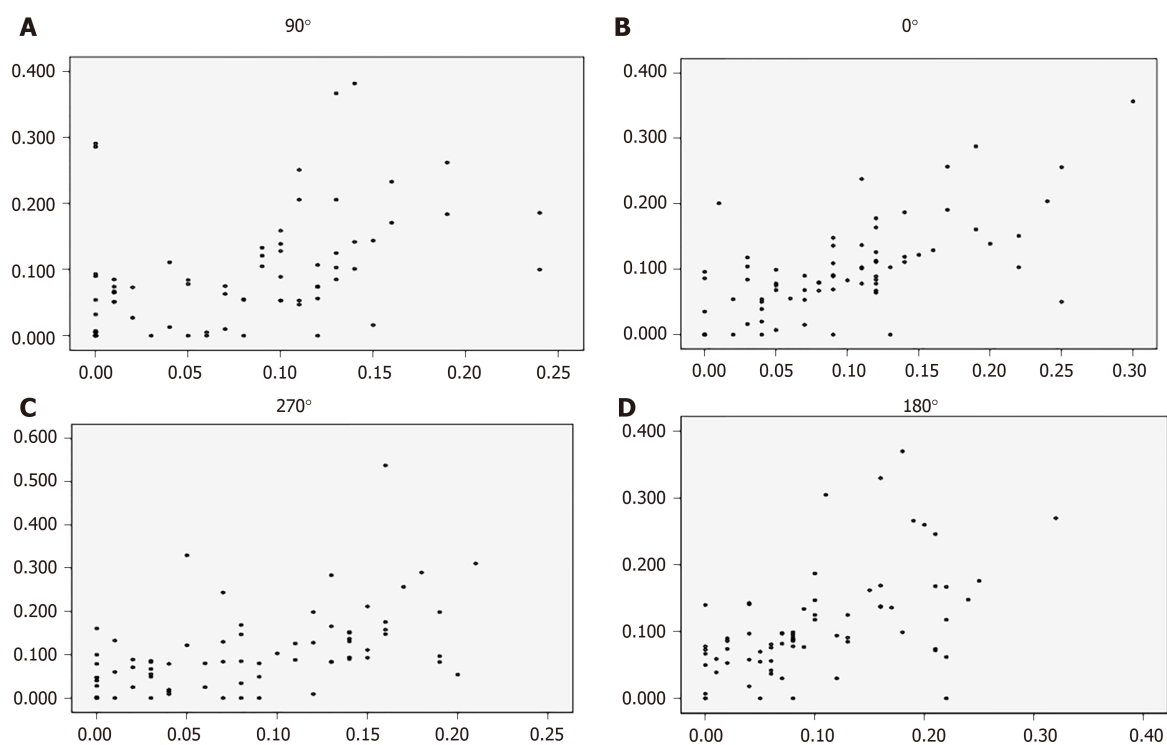


Figure 2 Correlation diagrams of trabeculo-iris space area at 500 μm^2 measured by the two instruments of the four quadrants of the chamber angles. The X axis represents ultrasound biomicroscopy. The Y axis represents anterior segment optical coherence tomography. A: At 90 °; B: At 0 °; C: At 270 °; D: At 180 °.

laterality of the eye were not distinguished. The measurements were not classified based on the width of anterior chamber angle and status of diseases. There were only 72 eyes, and the data did not satisfy a normal distribution. The influence of the above factors on the measurement results should be investigated further using a larger study sample size.

In conclusion, there is a good correlation and agreement between AOD500 and TISA500 measurements by AS-OCT and UBM. The two methods are interchangeable for measurement of the anterior segment angle and cannot be completely replaced by each other. AS-OCT can be used as the first choice for early glaucoma screening, and can be used for follow-up of glaucoma surgery.

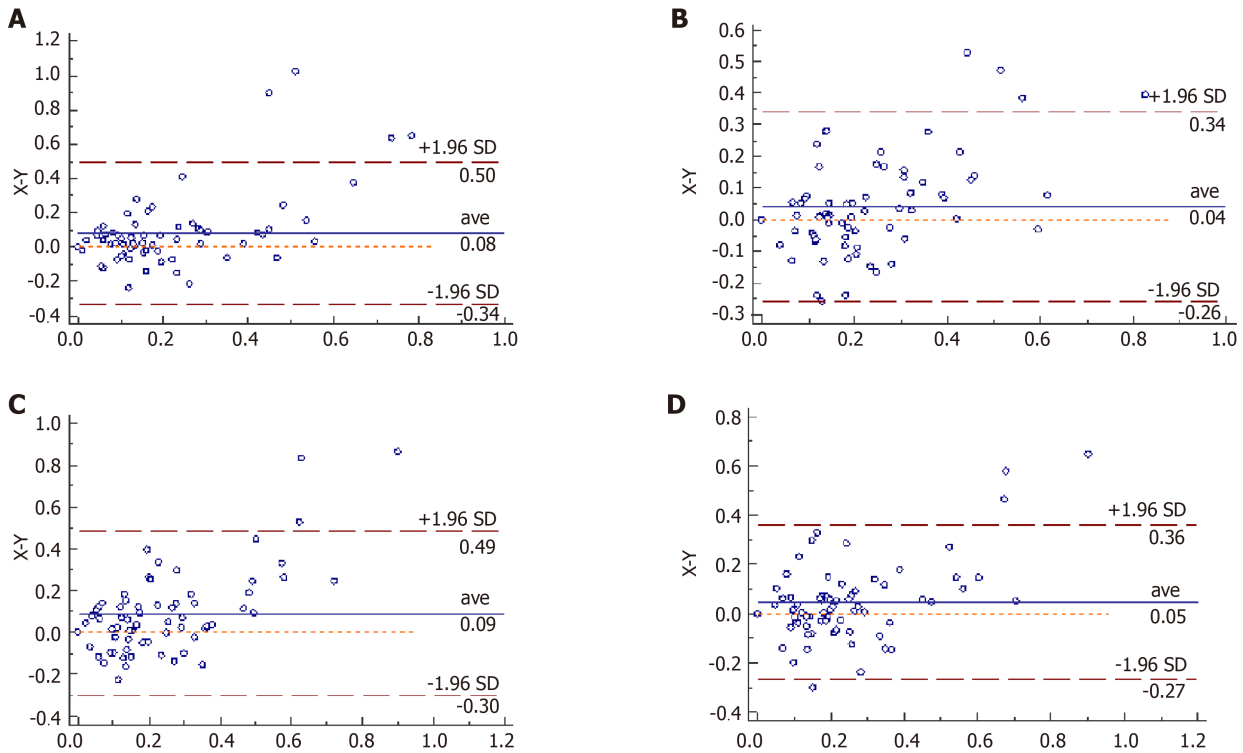


Figure 3 Bland-Altman charts of angel opening distance at 500 μm at four quadrants of the chamber angles measured by the two devices. The X axis represents anterior segment optical coherence tomography. The Y axis represents ultrasound biomicroscopy. A: At 90°; B: At 0°; C: At 270°; D: At 180°.

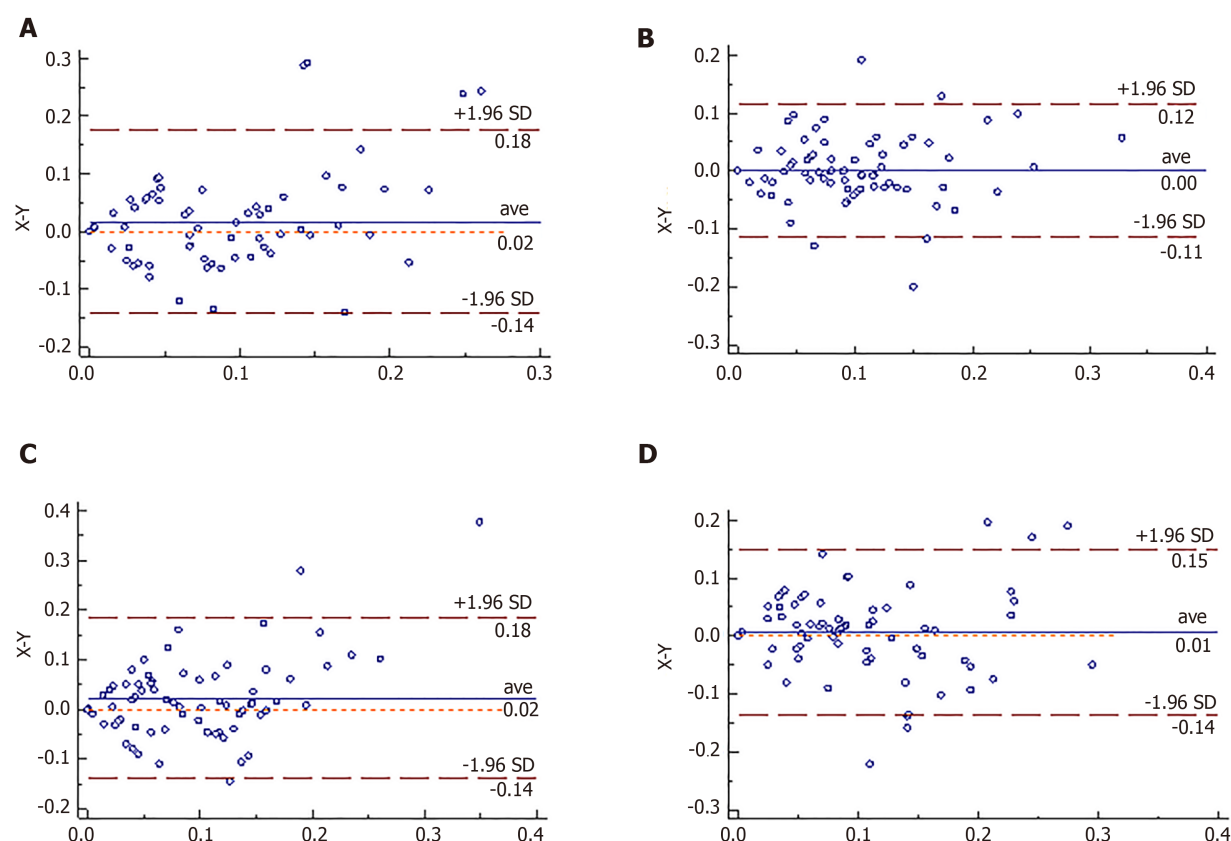


Figure 4 Bland-Altman charts of trabeculo-iris space area at 500 μm^2 at four quadrants of the chamber angles measured by the two devices. The X axis represents anterior segment optical coherence tomography. The Y axis represents ultrasound biomicroscopy. A: At 90 °; B: At 0 °; C: At 270 °; D: At 180 °.

ARTICLE HIGHLIGHTS

Research background

Glaucoma is an irreversible optic neuropathy with the loss of visual field and decrease of vision. A quick, user-friendly, and non-invasive method of assessing the anterior segment parameters is essential for early screening and diagnosis of glaucoma.

Research motivation

The main topic is to compare the difference between anterior chamber angle parameters measured by different methods.

Research objectives

To investigate the agreement, difference, and correlation of chamber angle parameters such as angel opening distance at 500 μm (AOD500) and trabeculo-iris space area at 500 μm^2 (TISA500) measured by anterior segment optical coherence tomography (AS-OCT) and ultrasound biomicroscopy (UBM) in normal subjects.

Research methods

Both AS-OCT and UBM were performed to measure AOD500 and TISA500 in 45 subjects (72 eyes). All subjects without glaucoma were collected from October 2015 to August 2016 at the Ophthalmology Department of the Fourth Affiliated Hospital of China Medical University. Data of the two groups (AOD500 and TISA500) were compared by nonparametric tests. Pearson correlative analysis and Bland-Altman analysis were used to compare the correlation and agreement.

Research results

There were no significant differences between AS-OCT and UBM in measuring AOD500 and TISA500 of the four quadrants of the anterior chamber angle. There was a high correlation in measuring AOD500 and TISA500. There was a good agreement in measuring AOD500 and TISA500.

Research conclusions

There is a high correlation and agreement between AOD500 and TISA500 measurements by AS-OCT and UBM. They are interchangeable under some circumstances. AS-OCT proves to be a better early screening tool for glaucoma.

Research perspectives

AS-OCT and UBM are interchangeable for AOD500 and TISA500 measurements and cannot be completely replaced by each other. AS-OCT can be used as the first choice for early glaucoma screening, especially for primary open-angle glaucoma patients.

REFERENCES

- 1 Kuerten D, Plange N, Becker J, Walter P, Fuest M. Evaluation of Long-term Anatomic Changes Following Canaloplasty With Anterior Segment Spectral-domain Optical Coherence Tomography and Ultrasound Biomicroscopy. *J Glaucoma* 2018; **27**: 87-93 [PMID: 29194201 DOI: 10.1097/IJG.0000000000000827]
- 2 Tham YC, Li X, Wong TY, Quigley HA, Aung T, Cheng CY. Global prevalence of glaucoma and projections of glaucoma burden through 2040: a systematic review and meta-analysis. *Ophthalmology* 2014; **121**: 2081-2090 [PMID: 24974815 DOI: 10.1016/j.ophttha.2014.05.013]
- 3 Lata S, Venkatesh P, Temkar S, Selvan H, Gupta V, Dada T, Upadhyay AD, Sihota R. Comparative Evaluation of Anterior Segment Optical Coherence Tomography, Ultrasound Biomicroscopy, and Intraocular Pressure Changes After Panretinal Photocoagulation by Pascal and Conventional Laser. *Retina* 2020; **40**: 537-545 [PMID: 30531420 DOI: 10.1097/IAE.0000000000002400]
- 4 Xu BY, Burkemper B, Lewinger JP, Jiang X, Pardeshi AA, Richter G, Torres M, McKean-Cowdin R, Varma R. Correlation between Intraocular Pressure and Angle Configuration Measured by OCT: The Chinese American Eye Study. *Ophthalmol Glaucoma* 2018; **1**: 158-166 [PMID: 31025032 DOI: 10.1016/j.ogla.2018.09.001]
- 5 Sedaghat MR, Mohammad Zadeh V, Fadakar K, Kadivar S, Abrishami M. Normative values and contralateral comparison of anterior chamber parameters measured by Pentacam and its correlation with corneal biomechanical factors. *Saudi J Ophthalmol* 2017; **31**: 7-10 [PMID: 28337056 DOI: 10.1016/j.sjopt.2016.11.006]
- 6 Porporato N, Baskaran M, Tun TA, Sultana R, Tan M, Quah JH, Allen JC, Perera S, Friedman DS, Cheng CY, Aung T. Understanding diagnostic disagreement in angle closure assessment between anterior segment optical coherence tomography and gonioscopy. *Br J Ophthalmol* 2020; **104**: 795-799 [PMID: 31492674 DOI: 10.1136/bjophthalmol-2019-314672]
- 7 Phu J, Wang H, Khou V, Zhang S, Kalloniatis M. Remote Grading of the Anterior Chamber Angle Using Gonioscopic Images and Optical Coherence Tomography: Implications for Telemedicine or Virtual Clinics. *Transl Vis Sci Technol* 2019; **8**: 16 [PMID: 31588379 DOI: 10.1167/tvst.8.5.16]
- 8 Phu J, Wang H, Khuu SK, Zangerl B, Hennessy MP, Masselos K, Kalloniatis M. Anterior Chamber Angle Evaluation Using Gonioscopy: Consistency and Agreement between Optometrists and Ophthalmologists. *Optom Vis Sci* 2019; **96**: 751-760 [PMID: 31592958 DOI: 10.1097/OPX.0000000000001432]
- 9 Rahmatnejad K, Pruzan NL, Amanullah S, Shaukat BA, Resende AF, Waisbourd M, Zhan T, Moster MR. Surgical Outcomes of Gonioscopy-assisted Transluminal Trabeculotomy (GATT) in Patients With Open-angle Glaucoma. *J Glaucoma* 2017; **26**: 1137-1143 [PMID: 29035912 DOI: 10.1097/IJG.0000000000000802]
- 10 Swain DL, Ho J, Lai J, Gong H. Shorter scleral spur in eyes with primary open-angle glaucoma. *Invest Ophthalmol Vis Sci* 2015; **56**: 1638-1648 [PMID: 25670488 DOI: 10.1167/iovs.14-15593]
- 11 Salim S. The role of anterior segment optical coherence tomography in glaucoma. *J Ophthalmol* 2012; **2012**: 476801 [PMID: 22900146 DOI: 10.1155/2012/476801]
- 12 Leung CK, Weinreb RN. Anterior chamber angle imaging with optical coherence tomography. *Eye (Lond)* 2011; **25**: 261-267 [PMID: 21242985 DOI: 10.1038/eye.2010.201]
- 13 Liu S, Yu M, Ye C, Lam DS, Leung CK. Anterior chamber angle imaging with swept-source optical coherence tomography: an investigation on variability of angle measurement. *Invest Ophthalmol Vis Sci* 2011; **52**: 8598-8603 [PMID: 21948547 DOI: 10.1167/iovs.11-7507]
- 14 Fu H, Xu Y, Lin S, Zhang X, Wong DWK, Liu J, Frangi AF, Baskaran M, Aung T. Segmentation and Quantification for Angle-Closure Glaucoma Assessment in Anterior Segment OCT. *IEEE Trans Med Imaging* 2017; **36**: 1930-1938 [PMID: 28499992 DOI: 10.1109/TMI.2017.2703147]
- 15 Moghimi S, Chen R, Johari M, Bijani F, Mohammadi M, Khodabandeh A, He M, Lin SC. Changes in Anterior Segment Morphology After Laser Peripheral Iridotomy in Acute Primary Angle Closure. *Am J Ophthalmol* 2016; **166**: 133-140 [PMID: 27038894 DOI: 10.1016/j.ajo.2016.03.032]
- 16 Ramakrishnan R, Mitra A, Abdul Kader M, Das S. To Study the Efficacy of Laser Peripheral Iridoplasty in the Treatment of Eyes With Primary Angle Closure and Plateau Iris Syndrome, Unresponsive to Laser Peripheral Iridotomy, Using Anterior-Segment OCT as a Tool. *J Glaucoma* 2016; **25**: 440-446 [PMID: 26372154 DOI: 10.1097/IJG.0000000000000307]
- 17 Kokubun T, Kunikata H, Tsuda S, Himori N, Maruyama K, Nakazawa T. Quantification of the filtering bleb's structure with anterior segment optical coherence tomography. *Clin Exp Ophthalmol* 2016; **44**: 446-454 [PMID: 27452223 DOI: 10.1111/ceo.12689]
- 18 Mansouri K, Sommerhalder J, Shaarawy T. Prospective comparison of ultrasound biomicroscopy and anterior segment optical coherence tomography for evaluation of anterior chamber dimensions in European eyes with primary angle closure. *Eye (Lond)* 2010; **24**: 233-239 [PMID: 19444291 DOI: 10.1038/eye.2009.103]
- 19 Kwon J, Sung KR, Han S, Moon YJ, Shin JW. Subclassification of Primary Angle Closure Using Anterior

- Segment Optical Coherence Tomography and Ultrasound Biomicroscopic Parameters. *Ophthalmology* 2017; **124**: 1039-1047 [PMID: 28385302 DOI: 10.1016/j.ophtha.2017.02.025]
- 20 **Wan T**, Yin H, Yang Y, Wu F, Wu Z, Yang Y. Comparative study of anterior segment measurements using 3 different instruments in myopic patients after ICL implantation. *BMC Ophthalmol* 2019; **19**: 182 [PMID: 31409385 DOI: 10.1186/s12886-019-1194-y]
- 21 **Loya-Garcia D**, Hernandez-Camarena JC, Valdez-Garcia JE, Rodríguez-Garcia A. Cogan-Reese syndrome: image analysis with specular microscopy, optical coherence tomography, and ultrasound biomicroscopy. *Digit J Ophthalmol* 2019; **25**: 26-29 [PMID: 31327934 DOI: 10.5693/djo.02.2019.05.001]



Published by **Baishideng Publishing Group Inc**
7041 Koll Center Parkway, Suite 160, Pleasanton, CA 94566, USA

Telephone: +1-925-3991568

E-mail: bpgoffice@wjgnet.com

Help Desk: <https://www.f6publishing.com/helpdesk>

<https://www.wjgnet.com>

