

World Journal of *Clinical Cases*

World J Clin Cases 2020 August 6; 8(15): 3136-3376



OPINION REVIEW

- 3136** Impacts and challenges of United States medical students during the COVID-19 pandemic
Rolak S, Keefe AM, Davidson EL, Aryal P, Parajuli S
- 3142** Recent advances in the management of gastrointestinal stromal tumor
Ahmed M
- 3156** Medical research during the COVID-19 pandemic
AlNaamani K, AlSinani S, Barkun AN

REVIEW

- 3164** Progress of intravoxel incoherent motion diffusion-weighted imaging in liver diseases
Tao YY, Zhou Y, Wang R, Gong XQ, Zheng J, Yang C, Yang L, Zhang XM

MINIREVIEWS

- 3177** Typical and atypical COVID-19 computed tomography findings
Caruso D, Polidori T, Guido G, Nicolai M, Bracci B, Cremona A, Zerunian M, Polici M, Pucciarelli F, Rucci C, Dominici CD, Girolamo MD, Argento G, Sergi D, Laghi A
- 3188** Review of possible psychological impacts of COVID-19 on frontline medical staff and reduction strategies
Fu XW, Wu LN, Shan L

ORIGINAL ARTICLE

Clinical and Translational Research

- 3197** Overexpression of AMPD2 indicates poor prognosis in colorectal cancer patients *via* the Notch3 signaling pathway
Gao QZ, Qin Y, Wang WJ, Fei BJ, Han WF, Jin JQ, Gao X

Case Control Study

- 3209** Effect of motivational interviewing on postoperative weight control in patients with obstructive sleep apnea-hypopnea syndrome
Sun XH, Xue PS, Qi XX, Fan L

Retrospective Study

- 3218** Thalidomide for refractory gastrointestinal bleeding from vascular malformations in patients with significant comorbidities
Bayudan AM, Chen CH

- 3230** Colorectal adenocarcinoma patients with M1a diseases gain more clinical benefits from palliative primary tumor resection than those with M1b diseases: A propensity score matching analysis

Li CL, Tang DR, Ji J, Zang B, Chen C, Zhao JQ

- 3240** Surgical outcomes of bladder augmentation: A comparison of three different augmentation procedures

Sun XG, Wang RY, Xu JL, Li DG, Chen WX, Li JL, Wang J, Li AW

Clinical Trials Study

- 3249** Comparison of measurements of anterior chamber angle *via* anterior segment optical coherence tomography and ultrasound biomicroscopy

Yu ZY, Huang T, Lu L, Qu B

Observational Study

- 3259** Dydrogesterone treatment for menstrual-cycle regularization in abnormal uterine bleeding – ovulation dysfunction patients

Wang L, Guan HY, Xia HX, Chen XY, Zhang W

CASE REPORT

- 3267** Multi-organ IgG4-related disease continues to mislead clinicians: A case report and literature review

Strainiene S, Sarlauskas L, Savlan I, Liakina V, Stundiene I, Valantinas J

- 3280** *Campylobacter jejuni* enterocolitis presenting with testicular pain: A case report

Sanagawa M, Kenzaka T, Kato S, Yamaoka I, Fujimoto S

- 3284** Natural killer/T-cell lymphoma with intracranial infiltration and Epstein-Barr virus infection: A case report

Li N, Wang YZ, Zhang Y, Zhang WL, Zhou Y, Huang DS

- 3291** Successful management of tubular colonic duplication using a laparoscopic approach: A case report and review of the literature

Li GB, Han JG, Wang ZJ, Zhai ZW, Tao Y

- 3299** Hypothyroidism with elevated pancreatic amylase and lipase without clinical symptoms: A case report

Xu YW, Li R, Xu SC

- 3305** Two mechanically ventilated cases of COVID-19 successfully managed with a sequential ventilation weaning protocol: Two case reports

Peng M, Ren D, Liu YF, Meng X, Wu M, Chen RL, Yu BJ, Tao LC, Chen L, Lai ZQ

- 3314** Adult duodenal intussusception with horizontal adenoma: A rare case report

Wang KP, Jiang H, Kong C, Wang LZ, Wang GY, Mo JG, Jin C

- 3320** Isolated metachronous splenic multiple metastases after colon cancer surgery: A case report and literature review

Hu L, Zhu JY, Fang L, Yu XC, Yan ZL

- 3329** Imaging of hemorrhagic primary central nervous system lymphoma: A case report
Wu YW, Zheng J, Liu LL, Cai JH, Yuan H, Ye J
- 3334** Coexistence of ovarian serous papillary cystadenofibroma and type A insulin resistance syndrome in a 14-year-old girl: A case report
Yan FF, Huang BK, Chen YL, Zhuang YZ, You XY, Liu CQ, Li XJ
- 3341** Acute suppurative oesophagitis with fever and cough: A case report
Men CJ, Singh SK, Zhang GL, Wang Y, Liu CW
- 3349** Computed tomography, magnetic resonance imaging, and F-deoxyglucose positron emission computed tomography/computed tomography findings of alveolar soft part sarcoma with calcification in the thigh: A case report
Wu ZJ, Bian TT, Zhan XH, Dong C, Wang YL, Xu WJ
- 3355** COVID-19 with asthma: A case report
Liu AL, Xu N, Li AJ
- 3365** Total laparoscopic segmental gastrectomy for gastrointestinal stromal tumors: A case report
Ren YX, He M, Ye PC, Wei SJ
- 3372** Facial and bilateral lower extremity edema due to drug-drug interactions in a patient with hepatitis C virus infection and benign prostate hypertrophy: A case report
Li YP, Yang Y, Wang MQ, Zhang X, Wang WJ, Li M, Wu FP, Dang SS

ABOUT COVER

Editorial Board Member of *World Journal of Clinical Cases*, Dr. Romano is Professor of Medicine-Gastroenterology at the University of Campania “Luigi Vanvitelli” in Naples, Italy. Dr. Romano received his MD degree cum Laude at the University Federico II in Naples, Italy in 1980 and, after 4 year of Post-Graduate course, he became Specialist in Gastroenterology and Gastrointestinal Endoscopy. Dr. Romano’s research interest was on the cross-talk between H. pylori and gastric epithelial cells, and presently is mainly focused on H. pylori eradication therapy and on the role of nutraceuticals in gastrointestinal diseases. Dr. Romano is presently the Chief of the Endoscopy and Chronic Inflammatory Gastrointestinal Disorders Unit, and Teacher at the University of Campania “Luigi Vanvitelli” in Naples, Italy.

AIMS AND SCOPE

The primary aim of *World Journal of Clinical Cases* (*WJCC*, *World J Clin Cases*) is to provide scholars and readers from various fields of clinical medicine with a platform to publish high-quality clinical research articles and communicate their research findings online.

WJCC mainly publishes articles reporting research results and findings obtained in the field of clinical medicine and covering a wide range of topics, including case control studies, retrospective cohort studies, retrospective studies, clinical trials studies, observational studies, prospective studies, randomized controlled trials, randomized clinical trials, systematic reviews, meta-analysis, and case reports.

INDEXING/ABSTRACTING

The *WJCC* is now indexed in Science Citation Index Expanded (also known as SciSearch®), Journal Citation Reports/Science Edition, PubMed, and PubMed Central. The 2020 Edition of Journal Citation Reports® cites the 2019 impact factor (IF) for *WJCC* as 1.013; IF without journal self cites: 0.991; Ranking: 120 among 165 journals in medicine, general and internal; and Quartile category: Q3.

RESPONSIBLE EDITORS FOR THIS ISSUE

Electronic Editor: *Yan-Xia Xing*, Production Department Director: *Yun-Xiaojian Wu*, Editorial Office Director: *Jin-Lei Wang*.

NAME OF JOURNAL

World Journal of Clinical Cases

ISSN

ISSN 2307-8960 (online)

LAUNCH DATE

April 16, 2013

FREQUENCY

Semimonthly

EDITORS-IN-CHIEF

Dennis A Bloomfield, Sandro Vento, Bao-Gan Peng

EDITORIAL BOARD MEMBERS

<https://www.wjgnet.com/2307-8960/editorialboard.htm>

PUBLICATION DATE

August 6, 2020

COPYRIGHT

© 2020 Baishideng Publishing Group Inc

INSTRUCTIONS TO AUTHORS

<https://www.wjgnet.com/bpg/gerinfo/204>

GUIDELINES FOR ETHICS DOCUMENTS

<https://www.wjgnet.com/bpg/GerInfo/287>

GUIDELINES FOR NON-NATIVE SPEAKERS OF ENGLISH

<https://www.wjgnet.com/bpg/gerinfo/240>

PUBLICATION ETHICS

<https://www.wjgnet.com/bpg/GerInfo/288>

PUBLICATION MISCONDUCT

<https://www.wjgnet.com/bpg/gerinfo/208>

ARTICLE PROCESSING CHARGE

<https://www.wjgnet.com/bpg/gerinfo/242>

STEPS FOR SUBMITTING MANUSCRIPTS

<https://www.wjgnet.com/bpg/GerInfo/239>

ONLINE SUBMISSION

<https://www.f6publishing.com>

Coexistence of ovarian serous papillary cystadenofibroma and type A insulin resistance syndrome in a 14-year-old girl: A case report

Fang-Fang Yan, Bing-Kun Huang, Yin-Ling Chen, Yan-Zhen Zhuang, Xue-Ye You, Chang-Qin Liu, Xue-Jun Li

ORCID number: Fang-Fang Yan 0000-0003-1950-0614; Bing-Kun Huang 0000-0003-1633-6150; Yin-Ling Chen 0000-0001-7966-2100; Yan-Zhen Zhuang 0000-0002-5563-4487; Xue-Ye You 0000-0002-8060-372X; Chang-Qin Liu 0000-0001-8063-7906; Xue-Jun Li 0000-0001-6940-3180.

Author contributions: Yan FF and Huang BK wrote the manuscript draft; Chen YL created the figures; Zhuang YZ and You XY conducted the staining and pathological diagnosis; Liu CQ collected the clinical information; Li XJ designed the study and revised the submission; all authors contributed to the discussion and approved the final manuscript for the version to be submitted.

Informed consent statement:

Informed written consent was obtained from the father of the patient for publication of this report and any accompanying images.

Conflict-of-interest statement: The authors declare that they have no conflict of interest.

CARE Checklist (2016) statement:

The authors have read the CARE Checklist (2016), and the manuscript was prepared and revised according to the CARE Checklist (2016).

Fang-Fang Yan, Bing-Kun Huang, Yin-Ling Chen, Chang-Qin Liu, Xue-Jun Li, Department of Endocrinology and Diabetes, The First Affiliated Hospital of Xiamen University, Xiamen 361003, Fujian Province, China

Yan-Zhen Zhuang, Xue-Ye You, Department of Pathology, The First Affiliated Hospital of Xiamen University, Xiamen 361003, Fujian Province, China

Corresponding author: Xue-Jun Li, MD, PhD, Chief Doctor, Professor, Department of Endocrinology and Diabetes, the First Affiliated Hospital of Xiamen University, No. 55 Zhenhai Road, Siming District, Xiamen 361003, Fujian Province, China. xmlixuejun@163.com

Abstract

BACKGROUND

Type A insulin resistance syndrome is a rare disorder caused by mutations in the gene encoding the insulin receptor. Its coexistence with ovarian serous papillary cystadenofibroma is even rarer.

CASE SUMMARY

A 14-year-old girl developed type A insulin resistance syndrome and showed high fasting insulin, glucose, and hemoglobin A1c (HbA1c) levels. The girl suffered from ovarian serous papillary cystadenofibroma. The laboratory results were as follows: fasting insulin was 2624.90 pmol/L and HbA1c was 8.5%. A heterozygous missense mutation on exon 20 of the insulin receptor gene (c.3601C>T, Arg1201Trp) was observed. The histopathological diagnosis was a cystic lesion that extended to the upper right uterus, indicating a right ovarian serous papillary cystadenofibroma accompanied by focal interstitial hyperplasia. The patient was treated with metformin for over 6 mo. Additionally, laparoscopic resection (bilateral) of the ovarian lesion and laparoscopic intestinal adhesiolysis were performed under general anesthesia. Diet therapy combined with exercise was then initiated. The patient had an uneventful recovery. The patient also showed improved blood glucose control, with reduced levels of fasting insulin (857.84 pmol/L) and HbA1c (7.0%).

CONCLUSION

Insulin resistance may play a significant role in the induction of tumors. It is important to investigate further the association between insulin resistance and tumors and the underlying mechanism.

Open-Access: This article is an open-access article that was selected by an in-house editor and fully peer-reviewed by external reviewers. It is distributed in accordance with the Creative Commons Attribution NonCommercial (CC BY-NC 4.0) license, which permits others to distribute, remix, adapt, build upon this work non-commercially, and license their derivative works on different terms, provided the original work is properly cited and the use is non-commercial. See: <http://creativecommons.org/licenses/by-nc/4.0/>

Manuscript source: Unsolicited manuscript

Received: March 27, 2020

Peer-review started: March 30, 2020

First decision: April 24, 2020

Revised: May 27, 2020

Accepted: July 14, 2020

Article in press: July 14, 2020

Published online: August 6, 2020

P-Reviewer: Ishibashi S

S-Editor: Gong ZM

L-Editor: Filipodia

E-Editor: Liu JH



Key words: Type A insulin resistance syndrome; Ovarian serous papillary cystadenofibroma; Acanthosis nigricans; Treatment; Case report

©The Author(s) 2020. Published by Baishideng Publishing Group Inc. All rights reserved.

Core tip: Type A insulin resistance syndrome (TAIRS) is a rare disorder that results from mutations in the gene encoding the insulin receptor. We present a rare case of TAIRS coexisting with an ovarian serous papillary cystadenofibroma in a 14-year-old girl caused by gene mutation. This case demonstrates that metformin has partial efficacy in the treatment of TAIRS. Furthermore, insulin may play a critical role in the development and progression of ovarian cystadenofibroma.

Citation: Yan FF, Huang BK, Chen YL, Zhuang YZ, You XY, Liu CQ, Li XJ. Coexistence of ovarian serous papillary cystadenofibroma and type A insulin resistance syndrome in a 14-year-old girl: A case report. *World J Clin Cases* 2020; 8(15): 3334-3340

URL: <https://www.wjgnet.com/2307-8960/full/v8/i15/3334.htm>

DOI: <https://dx.doi.org/10.12998/wjcc.v8.i15.3334>

INTRODUCTION

Type A insulin resistance syndrome (TAIRS), which is similar to Rabson-Mendenhall syndrome and Leprechaunism syndrome, is a rare disorder caused by mutations in the gene encoding the insulin receptor^[1]. It is usually diagnosed in lean adolescent girls accompanied by hirsutism, oligomenorrhea, acne, and acanthosis nigricans. In contrast to Rabson-Mendenhall syndrome and Leprechaunism syndrome, which are characterized by several phenotypes including intrauterine and postnatal growth retardation, dysmorphic features, and early mortality, TAIRS is relatively mild. Ovarian serous papillary cystadenofibroma is also an infrequent disorder that contains both epithelial and fibrous stromal components and is mainly found in women aged from 15 years to 65 years. Here, we present an unusual case of TAIRS coexisting with an ovarian cystadenofibroma in a 14-year-old girl. To the best of our knowledge, this is the first case to report such a combination.

CASE PRESENTATION

Chief complaints

A 14-year-old girl was transferred to our outpatient department with symptoms including hirsutism and acanthosis nigricans, which had been noted since the age of 10 years. Her birth weight was 2.75 kg at a gestational age of 40 wk. Secondary sex characteristics and accelerated growth occurred from the age of 13 but without menarche.

Physical examinations upon admission

Physical examination revealed that her body mass index was 18.1 kg/m². The Ferriman-Gallwey score was 19 (average 5). Clinical symptoms, laboratory indices, and treatment of the patient during 2018-2019 are shown in Figure 1. Evidence of acanthosis nigricans was observed in the neck and axillae (Figure 2A-C). Examination of the genitalia disclosed a mild clitoromegaly.

Laboratory examination

A 75-g oral glucose tolerance test (OGTT) showed that plasma glucose was 5.7, 10.8, 13.8, and 16.7 mmol/L at 0, 0.5-, 1-, and 2-h, respectively. Serum insulin concentrations were 1220.6, 2594.9, 3649.9, and 6958.3 pmol/L, respectively. Hemoglobin A1c (HbA1c) level was 8.3%. Hormone tests showed an elevated testosterone level at 82.85 ng/mL, (reference range 14-76 ng/mL). Molecular analysis showed a heterozygous missense mutation on exon 20 of the insulin receptor gene (Arg1201Trp) (Figure 3A). Furthermore, the patient's phenotype matched the common genotypes of the mutation occurring in the insulin receptor gene. Chromosome test revealed a 46, XX karyotype.

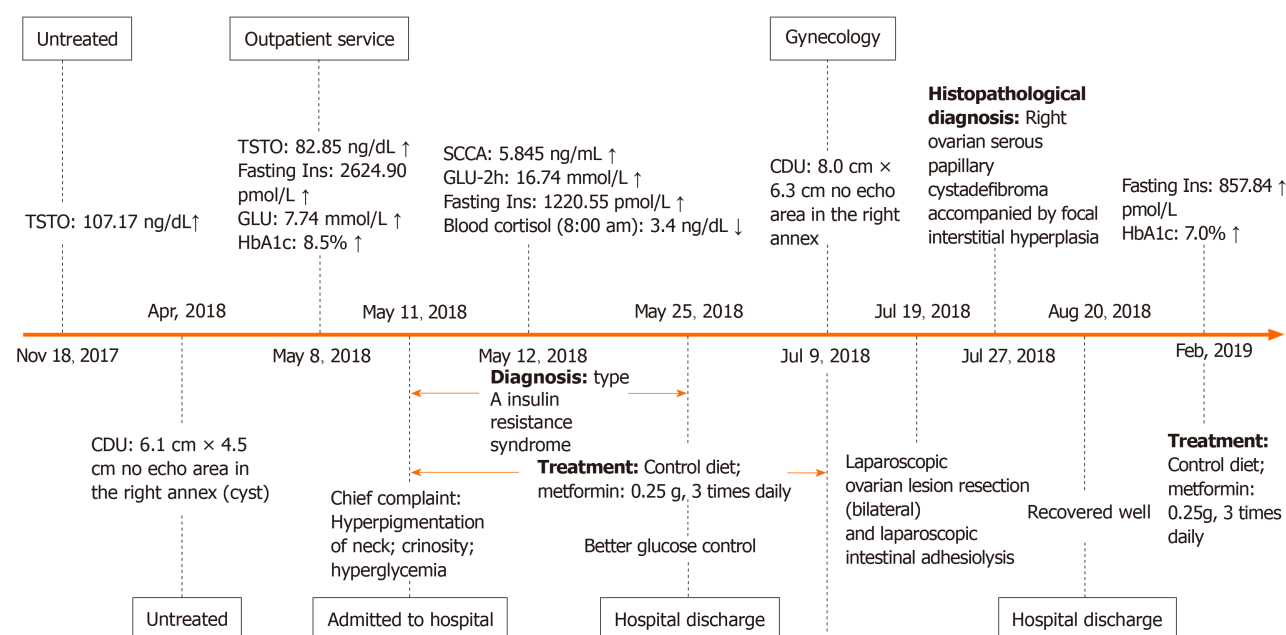


Figure 1 Clinical symptoms and laboratory indices in the 14-year-old girl patient. “↑” indicates above the normal range; “↓” indicates below the normal range. TSTO: Testosterone; CDU: Color Doppler ultrasound; Ins: Insulin; GLU: Glucose; HbA1c: Hemoglobin A1c; SCCA: Squamous cell carcinoma antigen.

Imaging examination

No masses were identified on abdominal palpation. Pelvic sonography showed an 8.0 cm × 6.3 cm cystic lesion that extended to the upper right uterus, which appeared to originate from the ovary (Figure 2D). In addition, the cystic lesion included a larger quasi-circular anechoic area (1.4 cm × 1.2 cm) (Figure 2E). There was no free or circumscribed fluid in the pelvis. Patient was suspected to have an ovarian tumor.

Family history

Her father was diagnosed with type 2 diabetes by the 75-g OGTT (fasting glucose, 14.3 mmol/L and postprandial, 26.7 mmol/L). He did not show any common clinical features of TAIRS. His blood glucose was well controlled with metformin 500 mg three times a day. Her mother's glucose level was normal by 75-g OGTT (Table 1). Fasting plasma glucose and fasting insulin level in her younger brother were 4.27 mmol/L and 212.67 pmol/L, respectively. The family history of diabetes is shown in Figure 4. Her father underwent genetic analyses and showed a heterozygous missense mutation on exon 20 of the insulin receptor gene (Arg1201Trp) (Figure 3B). Her mother was normal in the genetic analyses (Figure 3C).

FINAL DIAGNOSIS

Based on her clinical features, blood glucose, and insulin level, the patient was diagnosed with TAIRS. Final histopathological diagnosis of postsurgical tissue showed a right ovarian serous papillary cystadenofibroma accompanied by focal interstitial hyperplasia (Figure 2F and G).

TREATMENT

The patient took metformin for over 6 mo to treat TAIRS. Furthermore, laparoscopic resection (bilateral) of the ovarian lesion and laparoscopic intestinal adhesiolysis were performed under general anesthesia.

OUTCOME AND FOLLOW-UP

Fasting insulin level decreased to 857.84 pmol/L and HbA1c level dropped to 7.0%.

Table 1 Glucose and insulin levels of parents

	0 min	30 min	60 min	120 min
Father				
Glucose in mmol/L	14.33	19.88	26.72	28.62
Insulin in pmol/L	148.35	176.44	325.94	315.81
Mother				
Glucose in mmol/L	5.38	8.04	8.73	6.30
Insulin in pmol/L	45.82	269.79	372.97	279.81

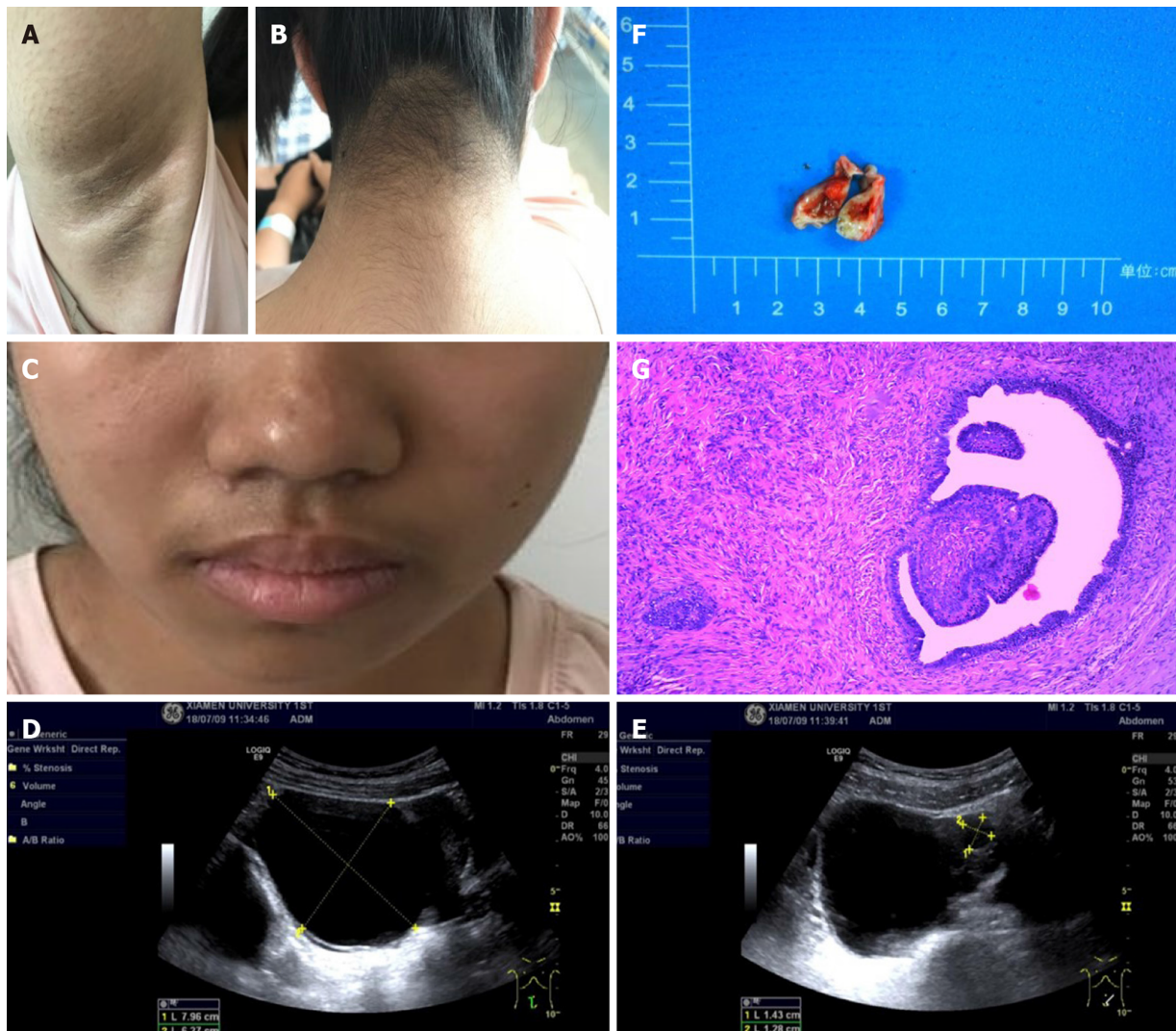


Figure 2 Clinical characteristics, genetic diagnosis, and histopathological diagnosis in this patient. A: Axillary skin is hairy, dark, coarse, and warty, with small papillae; B: The skin on the neck is black, thickened, rough, and warty, with small papillae; C: Whiskers are present on the upper lip; D: A cystic lesion was found at the upper right side of the uterus, approximately 8.0 cm × 6.3 cm, with well-defined borders; E: The cystic lesion included a larger quasi-circular anechoic area, approximately 1.4 cm × 1.2 cm; F: The nodular mass of the right ovary is cystic and solid in section, with a pale brown solid area approximately 1.5 cm × 1.2 cm × 0.8 cm in size; G: Right ovarian serous papillary cystadenofibroma accompanied by focal interstitial hyperplasia (hematoxylin-eosin, × 40).

Menstruation was not recorded during or after treatment. The patient had an uneventful recovery. Outpatient follow-up indicated that the patient was following the doctor's advice by controlling her diet, taking her daily medicine, and exercising.

The pedigree chart illustrates the inheritance of two traits: Diabetes and High glucose level across three generations (I, II, and III).

- Generation I:** Consists of three couples. The first couple (I-1 and I-2) has a son (II-1) affected by Diabetes and a daughter (II-2) affected by High glucose level. The second couple (I-3 and I-4) has a daughter (II-3) affected by High glucose level. The third couple (I-5 and I-6) has a daughter (II-4) affected by High glucose level.
- Generation II:** Consists of seven individuals. II-1 and II-2 are affected by Diabetes. II-3 and II-4 are affected by High glucose level. II-5 and II-6 are unaffected.
- Generation III:** Consists of three individuals. III-1 is affected by Diabetes. III-2 and III-3 are affected by High glucose level.

The chart shows that Diabetes is inherited as an autosomal recessive trait, and High glucose level is inherited as an autosomal dominant trait.

DISCUSSION

 **JGIM** | **WJCC** | <https://www.wjgnet.com>

with different gene mutations^[3]. The Arg1201Trp mutation that was identified in our patient has previously been reported in patients with severe syndromes of insulin resistance, such as leprechaunism and Rabson-Mendenhall syndrome^[3-6], but has not been found in patient with TAIRS. Thus, the phenotype attributed to the mutation of the same gene locus can also be inconsistent.

There is a lack of large-scale, long-term, randomized controlled studies focusing on the treatment and prognosis of TAIRS to guide treatment choice in clinical practice. Treatment of TAIRS is usually empirical and lacks evidence. Many medications, including metformin, thiazolidinediones, acarbose, and leptin, have been used in patients with severe insulin resistance syndrome^[7-10]. In China, metformin is the only oral antidiabetic agent approved for use in patients under the age of 14 years. In our case, the patient was treated with metformin for 6 mo, and fasting serum insulin level decreased from 1220.55 pmol/L to 857.84 pmol/L, and HbA1c level decreased by 1.3%. This indicated that metformin had a partial effect and can improve insulin sensitivity to a certain degree, as reported previously^[11]. Despite acceptable control during adolescence, long-term metabolic control has been reported to be poor and diabetes complications are frequent in TAIRS patients^[10,12]. Therefore, other than metformin, several future-proof treatments such as metreleptin, sodium-glucose cotransporter 2 inhibitor, and incretin^[10,13] should be introduced during childhood.

Ovarian cystadenofibroma accounts for 1.7% of all benign ovarian tumors^[14] that originate in the epithelium, which are classified as serous, endometrioid, mucinous, clear cell, and mixed categories. Ovarian cystadenofibroma is usually asymptomatic and is found incidentally, as in our case. A cystadenofibroma may show a solitary cyst or a multiloculated cystic mass, with solid nodules or papillary projections, and almost half of cases demonstrate increased vascularity on ultrasonography^[15]. Clinically, because ovarian cystadenofibroma is a multicystic mass with solid components, preoperative differential diagnosis is important to distinguish it from malignant neoplasms. A computed tomography scan also provides limited information in the evaluation of this tumor. A frozen section diagnosis may be helpful in these cases and may help to avoid an extensive surgical procedure. The patient in this study had two rarely diagnosed conditions. It is unknown whether there is a correlation between these two rare diseases. Insulin can activate both the insulin receptor and insulin-like growth factor receptor, particularly at high concentrations, to promote tumor cell proliferation and migration, which possibly plays a critical role in tumor development and progression^[16,17]. Previous studies suggest that exogenous insulin exposure is significantly associated with an increased incidence of cancer^[18]. Although a high insulin level may be related to ovarian serous papillary cystadenofibroma onset and/or progression, the mechanism remains unclear. Further study is required to determine the mechanistic details associated with the connection between TAIRS and ovarian cystadenofibroma.

In this report, we highlight the rare coexistence of TAIRS and an ovarian serous papillary cystadenofibroma. However, this study also had some limitations. First, there was an over 1-mo delaying in treating TAIRS as the patient underwent surgery. Second, the patient's ovarian cysts were surgically treated more than 1 year after diagnosis.

CONCLUSION

We report the first case of TAIRS coexisting with an ovarian serous papillary cystadenofibroma in a 14-year-old girl. We found that metformin had partial efficacy in TAIRS and improved insulin sensitivity to a certain extent. With respect to the ovarian serous papillary cystadenofibroma, cystectomy should be performed after puberty to prevent the risk of tumor development in the ovaries. The clinicopathological results support the notions that insulin may play a critical role in tumor development and progression.

ACKNOWLEDGEMENTS

We would like to thank all of the patient, doctors, nurses, and technicians involved at our center for their dedication to the study.

REFERENCES

- 1 **Parker VE**, Semple RK. Genetics in endocrinology: genetic forms of severe insulin resistance: what endocrinologists should know. *Eur J Endocrinol* 2013; **169**: R71-R80 [PMID: [23857978](#) DOI: [10.1530/EJE-13-0327](#)]
- 2 **Ardon O**, Procter M, Tvrdik T, Longo N, Mao R. Sequencing analysis of insulin receptor defects and detection of two novel mutations in *INSR* gene. *Mol Genet Metab Rep* 2014; **1**: 71-84 [PMID: [27896077](#) DOI: [10.1016/j.ymgmr.2013.12.006](#)]
- 3 **Longo N**, Wang Y, Smith SA, Langley SD, DiMeglio LA, Giannella-Neto D. Genotype-phenotype correlation in inherited severe insulin resistance. *Hum Mol Genet* 2002; **11**: 1465-1475 [PMID: [12023989](#) DOI: [10.1093/hmg/11.12.1465](#)]
- 4 **Takasawa K**, Tsuji-Hosokawa A, Takishima S, Wada Y, Nagasaki K, Dateki S, Numakura C, Hijikata A, Shirai T, Kashimada K, Morio T. Clinical characteristics of adolescent cases with Type A insulin resistance syndrome caused by heterozygous mutations in the β -subunit of the insulin receptor (*INSR*) gene. *J Diabetes* 2019; **11**: 46-54 [PMID: [29877041](#) DOI: [10.1111/1753-0407.12797](#)]
- 5 **Whitehead JP**, Soos MA, Jackson R, Tasie V, Kocova M, O'Rahilly S. Multiple molecular mechanisms of insulin receptor dysfunction in a patient with Donohue syndrome. *Diabetes* 1998; **47**: 1362-1364 [PMID: [9703342](#) DOI: [10.2337/diab.47.8.1362](#)]
- 6 **Tsuji-Hosokawa A**, Takasawa K, Nomura R, Miyakawa Y, Numakura C, Hijikata A, Shirai T, Ogawa Y, Kashimada K, Morio T. Molecular mechanisms of insulin resistance in 2 cases of primary insulin receptor defect-associated diseases. *Pediatr Diabetes* 2017; **18**: 917-924 [PMID: [28181734](#) DOI: [10.1111/pedi.12508](#)]
- 7 **Semple RK**, Williams RM, Dunger DB. What is the best management strategy for patients with severe insulin resistance? *Clin Endocrinol (Oxf)* 2010; **73**: 286-290 [PMID: [20455892](#) DOI: [10.1111/j.1365-2265.2010.03810.x](#)]
- 8 **Hattori Y**, Satoh H, Namatame T, Hattori S, Kasai K. A patient with extreme insulin resistance syndrome treated with pioglitazone. *Diabetes Care* 2006; **29**: 2328-2329 [PMID: [17003320](#) DOI: [10.2337/dc05-1249](#)]
- 9 **Cochran E**, Young JR, Sebring N, DePaoli A, Oral EA, Gorden P. Efficacy of recombinant methionyl human leptin therapy for the extreme insulin resistance of the Rabson-Mendenhall syndrome. *J Clin Endocrinol Metab* 2004; **89**: 1548-1554 [PMID: [15070911](#) DOI: [10.1210/jc.2003-031952](#)]
- 10 **Brown RJ**, Cochran E, Gorden P. Metreleptin improves blood glucose in patients with insulin receptor mutations. *J Clin Endocrinol Metab* 2013; **98**: E1749-E1756 [PMID: [23969187](#) DOI: [10.1210/jc.2013-2317](#)]
- 11 **Moreira RO**, Zagury RL, Nascimento TS, Zagury L. Multidrug therapy in a patient with Rabson-Mendenhall syndrome. *Diabetologia* 2010; **53**: 2454-2455 [PMID: [20711714](#) DOI: [10.1007/s00125-010-1879-5](#)]
- 12 **Musso C**, Cochran E, Moran SA, Skarulis MC, Oral EA, Taylor S, Gorden P. Clinical course of genetic diseases of the insulin receptor (type A and Rabson-Mendenhall syndromes): a 30-year prospective. *Medicine (Baltimore)* 2004; **83**: 209-222 [PMID: [15232309](#) DOI: [10.1097/01.md.0000133625.73570.45](#)]
- 13 **Kawana Y**, Imai J, Sawada S, Yamada T, Katagiri H. Sodium-Glucose Cotransporter 2 Inhibitor Improves Complications of Lipodystrophy: A Case Report. *Ann Intern Med* 2017; **166**: 450-451 [PMID: [28320010](#) DOI: [10.7326/L16-0372](#)]
- 14 **Cho SM**, Byun JY, Rha SE, Jung SE, Park GS, Kim BK, Kim B, Cho KS, Jung NY, Kim SH, Lee JM. CT and MRI findings of cystadenofibromas of the ovary. *Eur Radiol* 2004; **14**: 798-804 [PMID: [14504904](#) DOI: [10.1007/s00330-003-2060-z](#)]
- 15 **Alcázar JL**, Errasti T, Mínguez JA, Galán MJ, García-Manero M, Ceamanos C. Sonographic features of ovarian cystadenofibromas: spectrum of findings. *J Ultrasound Med* 2001; **20**: 915-919 [PMID: [11503928](#) DOI: [10.7863/jum.2001.20.8.915](#)]
- 16 **Rostoker R**, Abelson S, Bitton-Worms K, Genkin I, Ben-Shmuel S, Dakwar M, Orr ZS, Caspi A, Tzukerman M, LeRoith D. Highly specific role of the insulin receptor in breast cancer progression. *Endocr Relat Cancer* 2015; **22**: 145-157 [PMID: [25694511](#) DOI: [10.1530/ERC-14-0490](#)]
- 17 **Singh P**, Alex JM, Bast F. Insulin receptor (IR) and insulin-like growth factor receptor 1 (IGF-1R) signaling systems: novel treatment strategies for cancer. *Med Oncol* 2014; **31**: 805 [PMID: [24338270](#) DOI: [10.1007/s12032-013-0805-3](#)]
- 18 **Karlstad O**, Starup-Linde J, Vestergaard P, Hjellvik V, Bazelier MT, Schmidt MK, Andersen M, Auvinen A, Haukka J, Furu K, de Vries F, De Bruin ML. Use of insulin and insulin analogs and risk of cancer - systematic review and meta-analysis of observational studies. *Curr Drug Saf* 2013; **8**: 333-348 [PMID: [24215311](#) DOI: [10.2174/15680266113136660067](#)]



Published by **Baishideng Publishing Group Inc**
7041 Koll Center Parkway, Suite 160, Pleasanton, CA 94566, USA

Telephone: +1-925-3991568

E-mail: bpgoffice@wjgnet.com

Help Desk: <https://www.f6publishing.com/helpdesk>

<https://www.wjgnet.com>

