

# World Journal of *Clinical Cases*

*World J Clin Cases* 2020 August 6; 8(15): 3136-3376



## Contents

Semimonthly Volume 8 Number 15 August 6, 2020

### OPINION REVIEW

- 3136** Impacts and challenges of United States medical students during the COVID-19 pandemic  
*Rolak S, Keefe AM, Davidson EL, Aryal P, Parajuli S*
- 3142** Recent advances in the management of gastrointestinal stromal tumor  
*Ahmed M*
- 3156** Medical research during the COVID-19 pandemic  
*AlNaamani K, AlSinani S, Barkun AN*

### REVIEW

- 3164** Progress of intravoxel incoherent motion diffusion-weighted imaging in liver diseases  
*Tao YY, Zhou Y, Wang R, Gong XQ, Zheng J, Yang C, Yang L, Zhang XM*

### MINIREVIEWS

- 3177** Typical and atypical COVID-19 computed tomography findings  
*Caruso D, Polidori T, Guido G, Nicolai M, Bracci B, Cremona A, Zerunian M, Polici M, Pucciarelli F, Rucci C, Dominici CD, Girolamo MD, Argento G, Sergi D, Laghi A*
- 3188** Review of possible psychological impacts of COVID-19 on frontline medical staff and reduction strategies  
*Fu XW, Wu LN, Shan L*

### ORIGINAL ARTICLE

#### Clinical and Translational Research

- 3197** Overexpression of AMPD2 indicates poor prognosis in colorectal cancer patients *via* the Notch3 signaling pathway  
*Gao QZ, Qin Y, Wang WJ, Fei BJ, Han WF, Jin JQ, Gao X*

#### Case Control Study

- 3209** Effect of motivational interviewing on postoperative weight control in patients with obstructive sleep apnea-hypopnea syndrome  
*Sun XH, Xue PS, Qi XX, Fan L*

#### Retrospective Study

- 3218** Thalidomide for refractory gastrointestinal bleeding from vascular malformations in patients with significant comorbidities  
*Bayudan AM, Chen CH*

- 3230** Colorectal adenocarcinoma patients with M1a diseases gain more clinical benefits from palliative primary tumor resection than those with M1b diseases: A propensity score matching analysis

*Li CL, Tang DR, Ji J, Zang B, Chen C, Zhao JQ*

- 3240** Surgical outcomes of bladder augmentation: A comparison of three different augmentation procedures

*Sun XG, Wang RY, Xu JL, Li DG, Chen WX, Li JL, Wang J, Li AW*

### Clinical Trials Study

- 3249** Comparison of measurements of anterior chamber angle *via* anterior segment optical coherence tomography and ultrasound biomicroscopy

*Yu ZY, Huang T, Lu L, Qu B*

### Observational Study

- 3259** Dydrogesterone treatment for menstrual-cycle regularization in abnormal uterine bleeding – ovulation dysfunction patients

*Wang L, Guan HY, Xia HX, Chen XY, Zhang W*

### CASE REPORT

- 3267** Multi-organ IgG4-related disease continues to mislead clinicians: A case report and literature review

*Strainiene S, Sarlauskas L, Savlan I, Liakina V, Stundiene I, Valantinas J*

- 3280** *Campylobacter jejuni* enterocolitis presenting with testicular pain: A case report

*Sanagawa M, Kenzaka T, Kato S, Yamaoka I, Fujimoto S*

- 3284** Natural killer/T-cell lymphoma with intracranial infiltration and Epstein-Barr virus infection: A case report

*Li N, Wang YZ, Zhang Y, Zhang WL, Zhou Y, Huang DS*

- 3291** Successful management of tubular colonic duplication using a laparoscopic approach: A case report and review of the literature

*Li GB, Han JG, Wang ZJ, Zhai ZW, Tao Y*

- 3299** Hypothyroidism with elevated pancreatic amylase and lipase without clinical symptoms: A case report

*Xu YW, Li R, Xu SC*

- 3305** Two mechanically ventilated cases of COVID-19 successfully managed with a sequential ventilation weaning protocol: Two case reports

*Peng M, Ren D, Liu YF, Meng X, Wu M, Chen RL, Yu BJ, Tao LC, Chen L, Lai ZQ*

- 3314** Adult duodenal intussusception with horizontal adenoma: A rare case report

*Wang KP, Jiang H, Kong C, Wang LZ, Wang GY, Mo JG, Jin C*

- 3320** Isolated metachronous splenic multiple metastases after colon cancer surgery: A case report and literature review

*Hu L, Zhu JY, Fang L, Yu XC, Yan ZL*

- 3329** Imaging of hemorrhagic primary central nervous system lymphoma: A case report  
*Wu YW, Zheng J, Liu LL, Cai JH, Yuan H, Ye J*
- 3334** Coexistence of ovarian serous papillary cystadenofibroma and type A insulin resistance syndrome in a 14-year-old girl: A case report  
*Yan FF, Huang BK, Chen YL, Zhuang YZ, You XY, Liu CQ, Li XJ*
- 3341** Acute suppurative oesophagitis with fever and cough: A case report  
*Men CJ, Singh SK, Zhang GL, Wang Y, Liu CW*
- 3349** Computed tomography, magnetic resonance imaging, and F-deoxyglucose positron emission computed tomography/computed tomography findings of alveolar soft part sarcoma with calcification in the thigh: A case report  
*Wu ZJ, Bian TT, Zhan XH, Dong C, Wang YL, Xu WJ*
- 3355** COVID-19 with asthma: A case report  
*Liu AL, Xu N, Li AJ*
- 3365** Total laparoscopic segmental gastrectomy for gastrointestinal stromal tumors: A case report  
*Ren YX, He M, Ye PC, Wei SJ*
- 3372** Facial and bilateral lower extremity edema due to drug-drug interactions in a patient with hepatitis C virus infection and benign prostate hypertrophy: A case report  
*Li YP, Yang Y, Wang MQ, Zhang X, Wang WJ, Li M, Wu FP, Dang SS*



**ABOUT COVER**

Editorial Board Member of *World Journal of Clinical Cases*, Dr. Romano is Professor of Medicine-Gastroenterology at the University of Campania “Luigi Vanvitelli” in Naples, Italy. Dr. Romano received his MD degree cum Laude at the University Federico II in Naples, Italy in 1980 and, after 4 year of Post-Graduate course, he became Specialist in Gastroenterology and Gastrointestinal Endoscopy. Dr. Romano’s research interest was on the cross-talk between H. pylori and gastric epithelial cells, and presently is mainly focused on H. pylori eradication therapy and on the role of nutraceuticals in gastrointestinal diseases. Dr. Romano is presently the Chief of the Endoscopy and Chronic Inflammatory Gastrointestinal Disorders Unit, and Teacher at the University of Campania “Luigi Vanvitelli” in Naples, Italy.

**AIMS AND SCOPE**

The primary aim of *World Journal of Clinical Cases* (*WJCC*, *World J Clin Cases*) is to provide scholars and readers from various fields of clinical medicine with a platform to publish high-quality clinical research articles and communicate their research findings online.

*WJCC* mainly publishes articles reporting research results and findings obtained in the field of clinical medicine and covering a wide range of topics, including case control studies, retrospective cohort studies, retrospective studies, clinical trials studies, observational studies, prospective studies, randomized controlled trials, randomized clinical trials, systematic reviews, meta-analysis, and case reports.

**INDEXING/ABSTRACTING**

The *WJCC* is now indexed in Science Citation Index Expanded (also known as SciSearch®), Journal Citation Reports/Science Edition, PubMed, and PubMed Central. The 2020 Edition of Journal Citation Reports® cites the 2019 impact factor (IF) for *WJCC* as 1.013; IF without journal self cites: 0.991; Ranking: 120 among 165 journals in medicine, general and internal; and Quartile category: Q3.

**RESPONSIBLE EDITORS FOR THIS ISSUE**

Electronic Editor: Yan-Xia Xing, Production Department Director: Yun-Xiaojian Wu, Editorial Office Director: Jin-Lei Wang.

**NAME OF JOURNAL**

*World Journal of Clinical Cases*

**ISSN**

ISSN 2307-8960 (online)

**LAUNCH DATE**

April 16, 2013

**FREQUENCY**

Semimonthly

**EDITORS-IN-CHIEF**

Dennis A Bloomfield, Sandro Vento, Bao-Gan Peng

**EDITORIAL BOARD MEMBERS**

<https://www.wjgnet.com/2307-8960/editorialboard.htm>

**PUBLICATION DATE**

August 6, 2020

**COPYRIGHT**

© 2020 Baishideng Publishing Group Inc

**INSTRUCTIONS TO AUTHORS**

<https://www.wjgnet.com/bpg/gerinfo/204>

**GUIDELINES FOR ETHICS DOCUMENTS**

<https://www.wjgnet.com/bpg/GerInfo/287>

**GUIDELINES FOR NON-NATIVE SPEAKERS OF ENGLISH**

<https://www.wjgnet.com/bpg/gerinfo/240>

**PUBLICATION ETHICS**

<https://www.wjgnet.com/bpg/GerInfo/288>

**PUBLICATION MISCONDUCT**

<https://www.wjgnet.com/bpg/gerinfo/208>

**ARTICLE PROCESSING CHARGE**

<https://www.wjgnet.com/bpg/gerinfo/242>

**STEPS FOR SUBMITTING MANUSCRIPTS**

<https://www.wjgnet.com/bpg/GerInfo/239>

**ONLINE SUBMISSION**

<https://www.f6publishing.com>

# Total laparoscopic segmental gastrectomy for gastrointestinal stromal tumors: A case report

Yi-Xing Ren, Ming He, Peng-Cheng Ye, Shou-Jiang Wei

**ORCID number:** Yi-Xing Ren 0000-0001-5227-9064; Ming He 0000-0002-2965-4310; Peng-Cheng Ye 0000-0002-8157-7201; Shou-Jiang Wei 0000-0002-9369-6742.

**Author contributions:** He M and Ren YX participated in the acquisition and analysis of the data and drafted the initial manuscript; Ye PC revised the article critically for important intellectual content; Wei SJ designed the study and submitted the manuscript; all authors read and approved the final manuscript.

**Supported by** National Natural Science Foundation of China, No. 81500396.

**Informed consent statement:** Informed written consent was obtained from the patients for publication of this report and any accompanying images.

**Conflict-of-interest statement:** The authors declare that they have no conflict of interest.

**CARE Checklist (2016) statement:** The authors have read the CARE Checklist (2016), and the manuscript was prepared and revised in accordance with the CARE Checklist (2016).

**Open-Access:** This article is an open-access article that was

**Yi-Xing Ren, Ming He, Peng-Cheng Ye, Shou-Jiang Wei**, Department of General Surgery and Institute of Hepato-Biliary-Pancreas and Intestinal Disease, Affiliated Hospital of North Sichuan Medical College, Nanchong 637000, Sichuan Province, China

**Corresponding author:** Shou-Jiang Wei, MD, PhD, Chief Doctor, Department of General Surgery, and Institute of Hepato-Biliary-Pancreas and Intestinal Disease, Affiliated Hospital of North Sichuan Medical College, No. 63 Wenhua Road, Shunqing District, Nanchong 637000, Sichuan Province, China. [nsmcwsj@163.com](mailto:nsmcwsj@163.com)

## Abstract

### BACKGROUND

Gastrointestinal stromal tumors are lesions that originate from digestive tract walls. Several laparoscopic techniques, including local resections, wedge resections and partial gastrectomies, have been used successfully. However, there are no reports on laparoscopic segmental gastrectomy for gastrointestinal stromal tumors.

### CASE SUMMARY

We present our analysis of 17 patients who were admitted to our hospital from January 2014 to December 2018. All tumors were located in the corpus and antrum of the stomach, close to the lesser curvature of the stomach. The tumors originated from the anterior wall in nine cases and from the posterior wall of the stomach in eight cases. Laparoscopic segmental gastrectomy and end-to-end anastomosis between the proximal and the distal residual stomach were used in all patients. The mean operative time was 112.4 min. The mean length of hospital stay was 4.6 d. Mean operative blood loss was 73.5 mL. There were no leaks, no postoperative bleeding nor need for reintervention. Mean postoperative follow-up was 35.4 mo. The Visick grading index showed fewer gastrointestinal symptoms 3 mo after surgery. Two patients (11.8%) had reflux esophagitis and gastritis.

### CONCLUSION

Laparoscopic segmental gastrectomy may be a new function-preserving gastrectomy that is feasible for treatment of gastrointestinal stromal tumors that grow in the middle third of the stomach and on the lesser stomach curvature.

**Key words:** Gastrointestinal stromal tumors; Laparoscopy; Segmental gastrectomy; Digestive tract; Case report

selected by an in-house editor and fully peer-reviewed by external reviewers. It is distributed in accordance with the Creative Commons Attribution NonCommercial (CC BY-NC 4.0) license, which permits others to distribute, remix, adapt, build upon this work non-commercially, and license their derivative works on different terms, provided the original work is properly cited and the use is non-commercial. See: <http://creativecommons.org/licenses/by-nc/4.0/>

**Manuscript source:** Unsolicited manuscript

**Received:** April 7, 2020

**Peer-review started:** April 7, 2020

**First decision:** June 13, 2020

**Revised:** July 8, 2020

**Accepted:** July 15, 2020

**Article in press:** July 15, 2020

**Published online:** August 6, 2020

**P-Reviewer:** Hilmi I

**S-Editor:** Zhang L

**L-Editor:** Filipodia

**E-Editor:** Xing YX



©The Author(s) 2020. Published by Baishideng Publishing Group Inc. All rights reserved.

**Core tip:** Local resection, wedge resection and partial gastrectomy have been successfully applied to the treatment of gastrointestinal stromal tumors. However, the application of laparoscopic segmental gastrectomy in the treatment of gastrointestinal stromal tumors has not been reported. In this study, we analyzed a series of cases from 2014 to 2018 in our single center of applied laparoscopic segmental gastrectomy for gastrointestinal stromal tumors. We describe the preoperative and intraoperative conditions of all patients as well as the postoperative complications.

**Citation:** Ren YX, He M, Ye PC, Wei SJ. Total laparoscopic segmental gastrectomy for gastrointestinal stromal tumors: A case report. *World J Clin Cases* 2020; 8(15): 3365-3371

**URL:** <https://www.wjgnet.com/2307-8960/full/v8/i15/3365.htm>

**DOI:** <https://dx.doi.org/10.12998/wjcc.v8.i15.3365>

## INTRODUCTION

Gastrointestinal stromal tumors (GISTs), once known as gastrointestinal leiomyosarcomas, represent about 1% of gastrointestinal malignancies but are the most common of the mesenchymal tumors. They tend to occur in individuals older than 60 years<sup>[1,2]</sup>. The annual incidence is ten cases per million inhabitants<sup>[2,3]</sup>. They have a characteristic morphology, are generally positive for CD117 (c-kit) and are primarily caused by activating mutations in the KIT or PDGFRA genes<sup>[4,5]</sup>. The main treatment is surgical excision combined with imatinib therapy. However, several laparoscopic techniques for GISTs, including local resections, wedge resections and partial gastrectomies, have been used successfully. No current consensus exists on the therapy of GISTs concomitant with performance of a laparoscopic segmental gastrectomy procedure.

The superiority of segmental gastrectomy over conventional D2 (extended lymph node dissection) gastrectomy for early gastric cancer in terms of postoperative quality of life seems apparent<sup>[6-10]</sup>. Because of the characteristics of GISTs, segmental resection of the intestine and stomach is accepted. Thus, an aggressive and more extensive surgery to remove unaffected tissue is unnecessary.

We describe our single-center experience on laparoscopic segmental gastrectomy for GISTs that were growing in the middle third of the stomach and on the lesser stomach curvature. We used mechanical stapling devices for end-to-end anastomosis between the proximal residual stomach and the distal residual stomach.

## CASE PRESENTATION

### Chief complaints

The study includes 17 patients with GIST that were operated on from January 2014 to December 2018 in the Department of General Surgery of our hospital. Patients with metastatic disease at the time of resection and patients operated without histologic confirmation of GISTs were excluded from the study. All tumors were located in the corpus and antrum of the stomach, close to the lesser curvature of the stomach. The tumors originated from the anterior wall in nine cases and from the posterior wall of the stomach in eight cases. **Table 1** presents the preoperative demographic and clinical characteristics of the case series. This report is a retrospective, noncomparative review of confirmed GIST cases performed in a single center.

## FINAL DIAGNOSIS

Based on the history of all patients and preoperative examination, 17 patients were diagnosed with GISTs.

Table 1 Preoperative demographic and clinical characteristics

Subjects	Age in yr	Sex	Weight in kg	Height in m	BMI in kg/m <sup>2</sup>	Anterior wall	Posterior wall
1	43	M	62	1.68	22.0	Yes	
2	50	F	54	1.56	22.2	Yes	
3	62	M	68	1.65	25.0		Yes
4	58	M	74	1.72	25.0		Yes
5	35	F	50	1.56	20.6	Yes	
6	70	F	59	1.53	25.2		Yes
7	47	F	56	1.54	23.6		Yes
8	55	M	64	1.70	22.2	Yes	
9	73	M	68	1.68	24.1	Yes	
10	61	F	55	1.49	24.8	Yes	
11	59	F	62	1.63	23.3	Yes	
12	57	F	59	1.55	24.6	Yes	
13	63	F	48	1.50	21.3	Yes	
14	40	M	85	1.75	27.8		Yes
15	52	M	70	1.70	24.2		Yes
16	49	F	50	1.54	21.1		Yes
17	60	M	75	1.68	26.6		Yes

BMI: Body mass index.

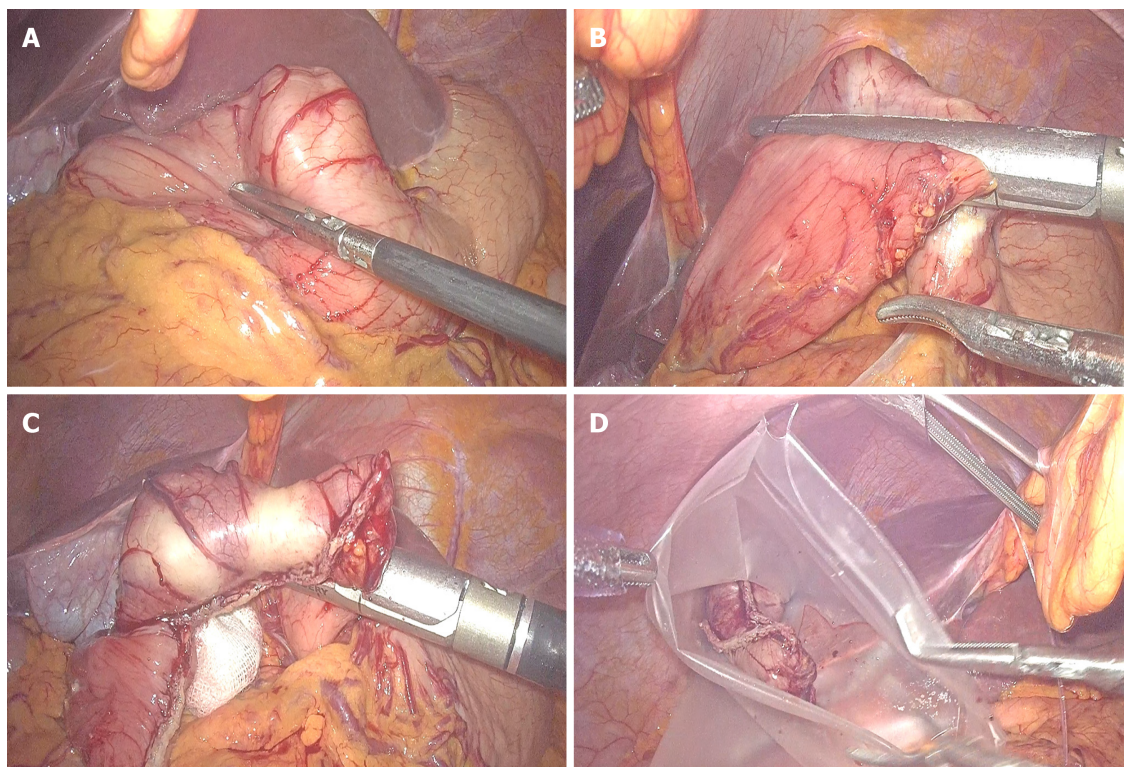
## TREATMENT

Because these tumors are on the lesser stomach curvature, all patients with primary gastric GISTs were initially prepared for laparoscopic segmental gastrectomy using mechanical stapling devices for end-to-end anastomosis between the proximal residual stomach and the distal residual stomach. Laparoscopic segmental gastrectomy was performed with a standard technique. After general anesthesia with endotracheal intubation, the pneumoperitoneum was established *via* umbilical puncture with a Veress needle. A 1 cm transverse skin incision was made on the umbilicus, and a 10 mm lengthened trocar was implanted as the observation hole. Under the guidance of a laparoscope, a 10 mm trocar was implanted in the midline of the left upper abdomen clavicle as the main operation hole. Additionally, 10 mm and 5 mm trocars were respectively implanted in the corresponding location of the right side of the abdominal wall and above the main surgical opening as auxiliary operation holes. A 10 mm trocar was also implanted below the xiphoid to place the liver retractor and expose the operative area when necessary. The resection line was made close to the tumor margins between differentiated and undifferentiated-type histology. The greater omentum was preserved, and the gastrocolic ligament corresponding to the resection area of the stomach was dissected after separation at least 3 cm away from the gastroepiploic vessels. After transection of the stomach, the surgical margins were subjected to intraoperative histological examination by frozen section analysis. Reconstruction was performed using mechanical stapling devices for end-to-end anastomosis. Special care was taken to avoid tumor capsule rupture during specimen handling and extraction from the cavity. The specimen was retrieved using a special pouch (Endocatch; Covidien, United States). **Figure 1** shows the process of tumor resection. The procedure of end-to-end anastomosis is presented in **Figure 2**. **Figure 3** shows the gastric sac after segmental resection.

## OUTCOME AND FOLLOW-UP

There were no conversions to open technique or other procedures. The mean [standard





**Figure 1 Process of tumor resection.** A: Size of the tumor is measured during surgery and location of the tumor is determined; B and C: Using mechanical anastomotic devices for laparoscopic segmental gastrectomy; D: Specimen is retrieved using a special pouch.

deviation (SD)] operative time was 112.4 (32.4) min (range 60-180 min). Mean (SD) operative blood loss was 73.5 (33.1) mL (range 30-150 mL). The mean (SD) length of hospital stay was 4.6 (0.8) d (range 3-6 d). There were no instances of anastomotic leakage, hemorrhage, gastric stasis, wound infection or operative death.

The mean (SD) follow-up time was 35.4 (13.0) mo (range 6-60 mo). The postoperative course is summarized in Table 2. In the 3 mo after surgery, postoperative weight recovery was significantly improved in all patients (before *vs* after:  $62.3 \pm 9.8$  *vs*  $61.1 \pm 9.6$ ,  $P < 0.05$ ). The incidence of reflux esophagitis and gastritis after surgery was less frequent in the laparoscopic segmental gastrectomy patients. Reflux gastritis<sup>[11]</sup> (segmental gastrectomy *vs* distal gastrectomy: 11.8 *vs* 63.8%,  $P < 0.05$ ).

The number of meals, single meal intake and Visick quality of life assessment are summarized in Table 3. Three mo after surgery all patients had a single meal intake that was more than half of the preoperative dose and ate fewer meals. The Visick grading index assessment was performed according to the degree of gastrointestinal symptoms in patients 3 mo after surgery. No recurrence or death was observed in all patients during a median follow-up period of 35.4 mo.

## DISCUSSION

GISTs are infamous for their complexity in management from diagnosis to treatment. Tumors are usually discovered in patients who present with abdominal pain, anemia, stomach upset, early satiety or other signs of gastrointestinal bleeding. Thus, GISTs are often diagnosed incidentally<sup>[12]</sup>. Surgery remains the gold standard for the management of GISTs. According guidelines from the European Society for Medical Oncology, lesions larger than 2 cm should be removed<sup>[13]</sup>. A primary gastric GIST should be resected by wedge resection or a larger resection that includes subtotal gastrectomy and total gastrectomy.

As for tumors that grow in the middle third of the stomach and on the lesser stomach curvature, removal by wedge resection can injure the cardia and pylorus, causing postoperative gastric stenosis and even residual gastric obstruction. Therefore, laparoscopic primary GIST resection for these tumors should be considered by surgeons with advanced laparoscopic skills for subtotal gastrectomy or total

**Table 2 Postoperative course**

Postoperative complications	n (%)
Gastric stasis	0
Umping syndrome	0
Reflux gastritis <sup>a</sup>	2 (11.8)
Reflux esophagitis	2 (11.8)

<sup>a</sup> $P < 0.05$  vs distal gastrectomy.

**Table 3 Quality of life 3 mo after surgery**

Post-operative meal	n (%)
The number of meals > 5 times	0
Compared with preoperative, single meal intake > 50%	17 (100)
Visick quality of life assessment	
Grade I	12 (70.6)
Grade II	5 (29.4)
Grade III	0 (0.0)
Grade IV	0 (0.0)

gastrectomy.

However, GISTs are benign tumors with a tendency toward malignant transformation. Postoperative tumor-free survival is usually longer making eating and quality of life important considerations after surgery. Unfortunately, radical resection with retention of gastric function is often at odds with improved survival and quality of life.

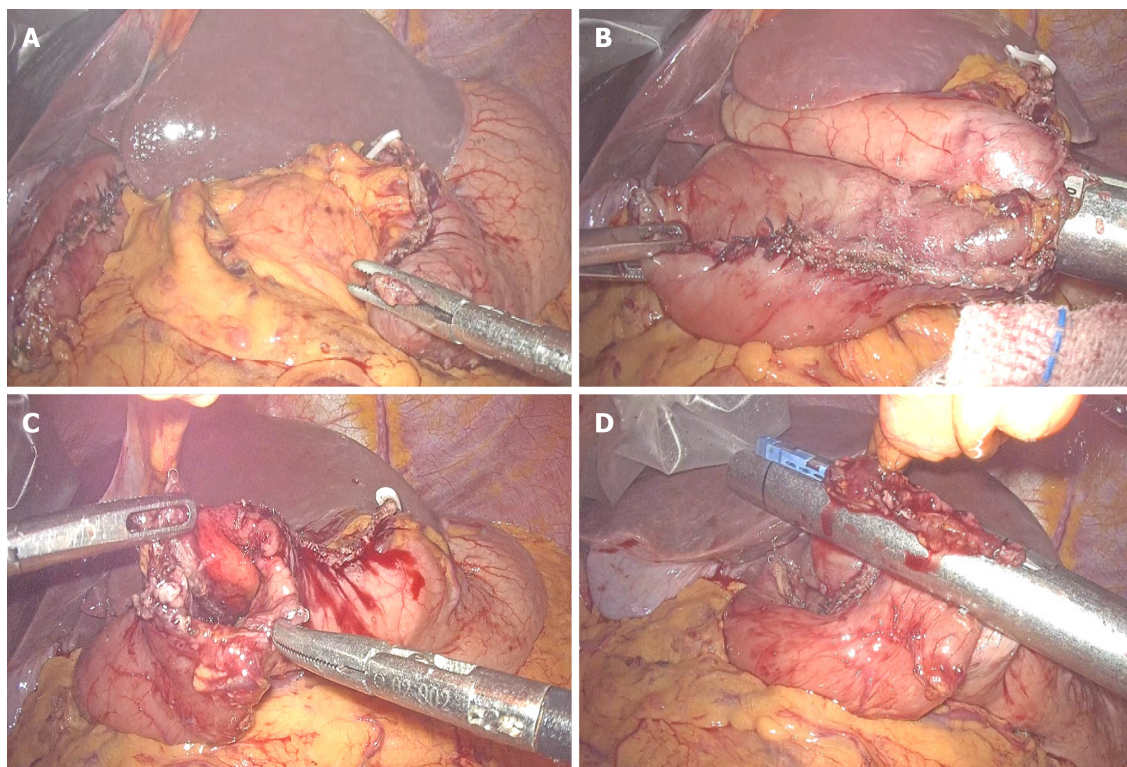
In this study, we reported laparoscopic segmental gastrectomy with residual gastric end-to-end anastomosis in 17 patients with GISTs. Segmental gastrectomy has not been previously used to treat GISTs, since it was first reported by Wangenstein *et al*<sup>[14]</sup> as an operation for peptic ulcer in 1952. Yang *et al*<sup>[11]</sup> reported that the incidence of biliary reflux was 60.9% with uncut Roux-en-Y and 90.3% with Billroth II reconstruction 1 year after distal gastrectomy. The incidence of reflux gastritis was similar for both techniques (70.8% for Roux-en-Y and 63.8% for Billroth II).

In our series, the incidence of reflux esophagitis and gastritis after surgery was infrequent, occurring in only one patient. Meanwhile, not only the blood supply but also the venous drainage of the pyloric region was better with our procedure, and no postoperative gastric stasis was observed. The number of meals, single meal intakes and the Visick assessment of quality of life 3 mo after surgery suggests that all patients had better recovery of gastrointestinal function.

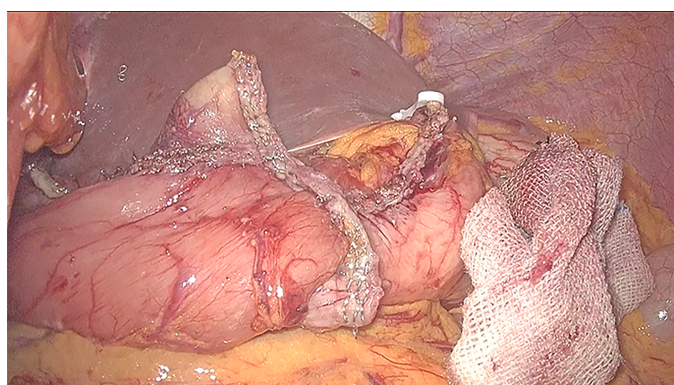
## CONCLUSION

Laparoscopic segmental gastrectomy for primary gastric GISTs seems to be feasible and safe. However, further studies including a larger series of patients and longer follow-up periods are needed to fully evaluate the advantages of laparoscopic segmental gastrectomy.





**Figure 2 Procedure of end-to-end anastomosis.** A: Proximal residual stomach and distal end after segmental resection of the stomach; B: Using mechanical anastomotic devices for proximal residual stomach and distal end end-to-end anastomosis between the residual stomach; C: Residual common openings after end-to-end anastomosis between the residual stomach; D: Residual common opening was closed by mechanical anastomotic devices.



**Figure 3** Gastric caps are well closed after segmental gastrectomy.

## ACKNOWLEDGEMENTS

We would like to acknowledge the assistance of John T. Cathey in language.

## REFERENCES

- 1 **Rubin JL**, Sanon M, Taylor DC, Coombs J, Bollu V, Sirulnik L. Epidemiology, survival, and costs of localized gastrointestinal stromal tumors. *Int J Gen Med* 2011; **4**: 121-130 [PMID: [21475624](#) DOI: [10.2147/ijgm.s16090](#)]
- 2 **Mucciarini C**, Rossi G, Bertolini F, Valli R, Cirilli C, Rashid I, Marcheselli L, Luppi G, Federico M. Incidence and clinicopathologic features of gastrointestinal stromal tumors. A population-based study. *BMC Cancer* 2007; **7**: 230 [PMID: [18096058](#) DOI: [10.1186/1471-2407-7-230](#)]
- 3 **Kingham TP**, DeMatteo RP. Multidisciplinary treatment of gastrointestinal stromal tumors. *Surg Clin North Am* 2009; **89**: 217-233, x [PMID: [19186237](#) DOI: [10.1016/j.suc.2008.10.003](#)]
- 4 **Rubin BP**, Singer S, Tsao C, Duensing A, Lux ML, Ruiz R, Hibbard MK, Chen CJ, Xiao S, Tuveson DA, Demetri GD, Fletcher CD, Fletcher JA. KIT activation is a ubiquitous feature of gastrointestinal stromal

- tumors. *Cancer Res* 2001; **61**: 8118-8121 [PMID: [11719439](#)]
- 5 **Heinrich MC**, Corless CL, Duensing A, McGreevey L, Chen CJ, Joseph N, Singer S, Griffith DJ, Haley A, Town A, Demetri GD, Fletcher CD, Fletcher JA. PDGFRA activating mutations in gastrointestinal stromal tumors. *Science* 2003; **299**: 708-710 [PMID: [12522257](#) DOI: [10.1126/science.1079666](#)]
  - 6 **Furukawa H**, Hiratsuka M, Imaoka S, Ishikawa O, Kabuto T, Sasaki Y, Kameyama M, Ohigashi H, Nakano H, Yasuda T, Murata K. Phase II study of limited surgery for early gastric cancer: segmental gastric resection. *Ann Surg Oncol* 1999; **6**: 166-170 [PMID: [10082042](#) DOI: [10.1007/s10434-999-0166-5](#)]
  - 7 **Ishikawa K**, Arita T, Ninomiya S, Bandoh T, Shiraishi N, Kitano S. Outcome of segmental gastrectomy versus distal gastrectomy for early gastric cancer. *World J Surg* 2007; **31**: 2204-2207 [PMID: [17721722](#) DOI: [10.1007/s00268-007-9192-2](#)]
  - 8 **Shimoyama S**, Seto Y, Yasuda H, Mafune K, Kaminishi M. Concepts, rationale, and current outcomes of less invasive surgical strategies for early gastric cancer: data from a quarter-century of experience in a single institution. *World J Surg* 2005; **29**: 58-65 [PMID: [15599744](#) DOI: [10.1007/s00268-004-7427-z](#)]
  - 9 **Morita S**, Katai H, Saka M, Fukagawa T, Sano T, Sasako M. Outcome of pylorus-preserving gastrectomy for early gastric cancer. *Br J Surg* 2008; **95**: 1131-1135 [PMID: [18690631](#) DOI: [10.1002/bjs.6295](#)]
  - 10 **Poveda A**, García Del Muro X, López-Guerrero JA, Cubedo R, Martínez V, Romero I, Serrano C, Valverde C, Martín-Broto J; GEIS (Grupo Español de Investigación en Sarcomas/Spanish Group for Sarcoma Research). GEIS guidelines for gastrointestinal sarcomas (GIST). *Cancer Treat Rev* 2017; **55**: 107-119 [PMID: [28351781](#) DOI: [10.1016/j.ctrv.2016.11.011](#)]
  - 11 **Yang D**, He L, Tong WH, Jia ZF, Su TR, Wang Q. Randomized controlled trial of uncut Roux-en-Y vs Billroth II reconstruction after distal gastrectomy for gastric cancer: Which technique is better for avoiding biliary reflux and gastritis? *World J Gastroenterol* 2017; **23**: 6350-6356 [PMID: [28974902](#) DOI: [10.3748/wjg.v23.i34.6350](#)]
  - 12 **Patil DT**, Rubin BP. Gastrointestinal stromal tumor: advances in diagnosis and management. *Arch Pathol Lab Med* 2011; **135**: 1298-1310 [PMID: [21970485](#) DOI: [10.5858/arpa.2011-0022-RA](#)]
  - 13 **Casali PG**, Jost L, Reichardt P, Schlemmer M, Blay JY; ESMO Guidelines Working Group. Gastrointestinal stromal tumours: ESMO clinical recommendations for diagnosis, treatment and follow-up. *Ann Oncol* 2009; **20** Suppl 4: 64-67 [PMID: [19454466](#) DOI: [10.1093/annonc/mdp131](#)]
  - 14 **Wangenstein OH**. Segmental gastric resection for peptic ulcer; method permitting restoration of anatomic continuity. *J Am Med Assoc* 1952; **149**: 18-23 [PMID: [14917552](#) DOI: [10.1001/jama.1952.02930180020005](#)]



Published by **Baishideng Publishing Group Inc**  
7041 Koll Center Parkway, Suite 160, Pleasanton, CA 94566, USA

**Telephone:** +1-925-3991568

**E-mail:** [bpgoffice@wjgnet.com](mailto:bpgoffice@wjgnet.com)

**Help Desk:** <https://www.f6publishing.com/helpdesk>

<https://www.wjgnet.com>

