

# World Journal of *Clinical Cases*

*World J Clin Cases* 2020 August 26; 8(16): 3377-3620



### OPINION REVIEW

- 3377** Novel computerized psychometric tests as primary screening tools for the diagnosis of minimal hepatic encephalopathy  
*Luo M, Mu R, Liu JF, Bai FH*

### REVIEW

- 3390** Management of cancer patients during COVID-19 pandemic at developing countries  
*González-Montero J, Valenzuela G, Ahumada M, Barajas O, Villanueva L*

### MINIREVIEWS

- 3405** Liver in the limelight in the corona (COVID-19) time  
*Chela HK, Pasha SB, Basar O, Daglilar E, Tahan V*
- 3411** Steroid-responsive pancreatitis  
*Pelaez-Luna M, Soriano-Rios A, Lira-Treviño AC, Uscanga-Domínguez L*

### ORIGINAL ARTICLE

#### Clinical and Translational Research

- 3431** Application of molybdenum target X-ray photography in imaging analysis of caudal intervertebral disc degeneration in rats  
*Su QH, Zhang Y, Shen B, Li YC, Tan J*
- 3440** Accuracy study of a binocular-stereo-vision-based navigation robot for minimally invasive interventional procedures  
*Wang R, Han Y, Luo MZ, Wang NK, Sun WW, Wang SC, Zhang HD, Lu LJ*

#### Retrospective Study

- 3450** Value of virtual bronchoscopic navigation and transbronchial ultrasound-guided sheath-guided exploration in diagnosis of peripheral lung cancer  
*Liu Y, Wang F, Zhang QC, Tong ZH*
- 3458** Significance of serum fibroblast growth factor-23 and miR-208b in pathogenesis of atrial fibrillation and their relationship with prognosis  
*Chen JM, Zhong YT, Tu C, Lan J*
- 3465** Home quarantine compliance is low in children with fever during COVID-19 epidemic  
*Lou Q, Su DQ, Wang SQ, Gao E, Li LQ, Zhuo ZQ*

- 3474** Combination of endoscopic submucosal dissection and laparoscopic sentinel lymph node dissection in early mucinous gastric cancer: Role of lymph node metastasis

*Li H, Zhao LL, Zhang XC, Liu DX, Wang GY, Huo ZB, Chen SB*

- 3483** Factors affecting failed trial of labor and countermeasures: A retrospective analysis

*Wang JG, Sun JL, Shen J*

- 3493** Value of miR-1271 and glypican-3 in evaluating the prognosis of patients with hepatocellular carcinoma after transcatheter arterial chemoembolization

*Guo Z, Wang J, Li L, Liu R, Fang J, Tie B*

### Observational Study

- 3503** Follow-up study on symptom distress in esophageal cancer patients undergoing repeated dilation

*Liu L, Liu QW, Wu XD, Liu SY, Cao HJ, Hong YT, Qin HY*

- 3515** Long-term medical treatment of patients with severe burns at exposed sites

*Du Y, Lv GZ, Yu S, Wang D, Tan Q*

### CASE REPORT

- 3527** Laparoscopic management of a giant mucinous benign ovarian mass weighing 10150 grams: A case report

*Sanna E, Madeddu C, Melis L, Nemolato S, Macciò A*

- 3534** Concurrent hepatocellular carcinoma metastasis to stomach, colon, and brain: A case report

*Kim R, Song J, Kim SB*

- 3542** Disseminated osteomyelitis after urinary tract infection in immunocompetent adult: A case report

*Kim YJ, Lee JH*

- 3548** Pelvic lipomatosis and renal transplantation: A case report

*Zhao J, Fu YX, Feng G, Mo CB*

- 3553** Intestinal obstruction in pregnancy with reverse rotation of the midgut: A case report

*Zhao XY, Wang X, Li CQ, Zhang Q, He AQ, Liu G*

- 3560** Clinical laboratory investigation of a patient with an extremely high D-dimer level: A case report

*Sun HX, Ge H, Xu ZQ, Sheng HM*

- 3567** Recovery from a biliary stricture of a common bile duct ligature injury: A case report

*Fan Z, Pan JY, Zhang YW*

- 3573** Spontaneous pneumomediastinum in an elderly COVID-19 patient: A case report

*Kong N, Gao C, Xu MS, Xie YL, Zhou CY*

- 3578** Acute generalized exanthematous pustulosis with airway mucosa involvement: A case report

*Li LL, Lu YQ, Li T*

- 3583** Multifocal neuroendocrine cell hyperplasia accompanied by tumorlet formation and pulmonary sclerosing pneumocytoma: A case report  
*Han XY, Wang YY, Wei HQ, Yang GZ, Wang J, Jia YZ, Ao WQ*
- 3591** Giant benign phyllodes breast tumour with pulmonary nodule mimicking malignancy: A case report  
*Zhang T, Feng L, Lian J, Ren WL*
- 3601** Spontaneous multivessel coronary artery spasm diagnosed with intravascular ultrasound imaging: A case report  
*Wu HY, Cao YW, Chang FJ, Liang L*
- 3608** Delayed perforation after endoscopic resection of a colonic laterally spreading tumor: A case report and literature review  
*Zhou GYJ, Hu JL, Wang S, Ge N, Liu X, Wang GX, Sun SY, Guo JT*
- 3616** First branchial cleft cyst accompanied by external auditory canal atresia and middle ear malformation: A case report  
*Zhang CL, Li CL, Chen HQ, Sun Q, Liu ZH*



**ABOUT COVER**

Editorial board member of *World Journal of Clinical Cases*, Dr. Kvolik is a Professor in the School of Medicine, Osijek University, Croatia. She obtained her MD degree, with specialization in the field of anesthesiology, resuscitation and intensive care from the Zagreb Medical School, Croatia. Afterwards, she undertook postgraduate training in Clinical Pharmacology at the same institution, defending both a Master's thesis and PhD thesis. In 2006, she joined the Osijek University Medical Faculty as a lecturer and was promoted to Professor in 2009. In 2012, she was elected Head of the Department of Anesthesiology, Resuscitation, Intensive Care and Pain Therapy, a position she occupies to this day. She is also the current Head of the Intensive Care Unit at the Osijek University Hospital, Croatia. (L-Editor: Filipodia)

**AIMS AND SCOPE**

The primary aim of *World Journal of Clinical Cases* (*WJCC*, *World J Clin Cases*) is to provide scholars and readers from various fields of clinical medicine with a platform to publish high-quality clinical research articles and communicate their research findings online.

*WJCC* mainly publishes articles reporting research results and findings obtained in the field of clinical medicine and covering a wide range of topics, including case control studies, retrospective cohort studies, retrospective studies, clinical trials studies, observational studies, prospective studies, randomized controlled trials, randomized clinical trials, systematic reviews, meta-analysis, and case reports.

**INDEXING/ABSTRACTING**

The *WJCC* is now indexed in Science Citation Index Expanded (also known as SciSearch®), Journal Citation Reports/Science Edition, PubMed, and PubMed Central. The 2020 Edition of Journal Citation Reports® cites the 2019 impact factor (IF) for *WJCC* as 1.013; IF without journal self cites: 0.991; Ranking: 120 among 165 journals in medicine, general and internal; and Quartile category: Q3.

**RESPONSIBLE EDITORS FOR THIS ISSUE**

Production Editor: Ji-Hong Lin; Production Department Director: Xiang Li; Editorial Office Director: Jin-Lai Wang.

**NAME OF JOURNAL**

*World Journal of Clinical Cases*

**ISSN**

ISSN 2307-8960 (online)

**LAUNCH DATE**

April 16, 2013

**FREQUENCY**

Semimonthly

**EDITORS-IN-CHIEF**

Dennis A Bloomfield, Sandro Vento, Bao-Gan Peng

**EDITORIAL BOARD MEMBERS**

<https://www.wjgnet.com/2307-8960/editorialboard.htm>

**PUBLICATION DATE**

August 26, 2020

**COPYRIGHT**

© 2020 Baishideng Publishing Group Inc

**INSTRUCTIONS TO AUTHORS**

<https://www.wjgnet.com/bpg/gerinfo/204>

**GUIDELINES FOR ETHICS DOCUMENTS**

<https://www.wjgnet.com/bpg/GerInfo/287>

**GUIDELINES FOR NON-NATIVE SPEAKERS OF ENGLISH**

<https://www.wjgnet.com/bpg/gerinfo/240>

**PUBLICATION ETHICS**

<https://www.wjgnet.com/bpg/GerInfo/288>

**PUBLICATION MISCONDUCT**

<https://www.wjgnet.com/bpg/gerinfo/208>

**ARTICLE PROCESSING CHARGE**

<https://www.wjgnet.com/bpg/gerinfo/242>

**STEPS FOR SUBMITTING MANUSCRIPTS**

<https://www.wjgnet.com/bpg/GerInfo/239>

**ONLINE SUBMISSION**

<https://www.f6publishing.com>



## Delayed perforation after endoscopic resection of a colonic laterally spreading tumor: A case report and literature review

Ge-Yu-Jia Zhou, Jin-Long Hu, Sheng Wang, Nan Ge, Xiang Liu, Guo-Xin Wang, Si-Yu Sun, Jin-Tao Guo

**ORCID number:** Ge-Yu-Jia Zhou 0000-0002-4196-1436; Jin-Long Hu 0000-0002-9662-4621; Sheng Wang 0000-0002-1531-7655; Nan Ge 0000-0002-5764-7054; Xiang Liu 0000-0001-7538-6786; Guo-Xin Wang 0000-0002-5928-3370; Si-Yu Sun 0000-0002-7308-0473; Jin-Tao Guo 0000-0001-5722-6359.

**Author contributions:** Zhou GYJ and Hu JL prepared the case and contributed to manuscript drafting; Zhou GYJ and Guo JT analyzed the case and reviewed the literature; Sun SY and Guo JT contributed to study concept and manuscript drafting; Wang S, Ge N, Liu X, and Wang GX contributed to manuscript revision for important intellectual content; all authors gave final approval for the version to be submitted.

**Supported by** Natural Science Foundation of Liaoning Province, No. 20170541024; and Shengjing Free Researcher Project Foundation, No. 201702.

**Informed consent statement:** Informed written consent was obtained from the patient.

**Conflict-of-interest statement:** The authors declare that they have no conflict of interest.

**CARE Checklist (2016) statement:** The authors have read the CARE

**Ge-Yu-Jia Zhou, Jin-Long Hu, Sheng Wang, Nan Ge, Xiang Liu, Guo-Xin Wang, Si-Yu Sun, Jin-Tao Guo,** Department of Gastroenterology, Shengjing Hospital of China Medical University, Shenyang 110004, Liaoning Province, China

**Corresponding author:** Si-Yu Sun, MD, PhD, Chief Doctor, Director, Professor, Department of Gastroenterology, Shengjing Hospital of China Medical University, No. 36 Sanhao Street, Shenyang 110004, Liaoning Province, China. [sunsy@sj-hospital.org](mailto:sunsy@sj-hospital.org)

### Abstract

#### BACKGROUND

Endoscopic mucosal resection (EMR) and endoscopic submucosal dissection (ESD) have been widely used for the treatment of early gastrointestinal cancer. Endoscopic piecemeal mucosal resection (EMPR) is derived from the combination of EMR and ESD. Delayed perforation with peritonitis after colonic EMPR is a rare but severe complication, sometimes requiring surgery. There are some associated risk factors, including patient- (location, diameter, and presence of fibrosis) and procedure-related factors. Early recognition and timely treatment are crucial for its management.

#### CASE SUMMARY

We report a case in which delayed perforation with peritonitis was treated using endoscopic closure. A 54-year-old man was diagnosed with a 30-mm-diameter laterally spreading tumor in the colonic hepatic curvature. Fifteen hours after endoscopic resection, peritonitis caused by delayed perforation occurred and gradually aggravated. Conservative treatment was ineffective and no obvious perforation was observed. After timely endoscopic closure, the patient was discharged on postoperative day 4.

#### CONCLUSION

In occasion of localized peritonitis aggravating without macroscopic perforation, endoscopic closure is an effective treatment for delayed perforation with stable vital signs in the early stage.

**Key words:** Endoscopic mucosal resection; Endoscopic submucosal dissection; Endoscopic piecemeal mucosal resection; Delayed perforation; Endoscopic closure; Case report

©The Author(s) 2020. Published by Baishideng Publishing Group Inc. All rights reserved.

Checklist (2016), and the manuscript was prepared and revised according to the CARE Checklist (2016).

**Open-Access:** This article is an open-access article that was selected by an in-house editor and fully peer-reviewed by external reviewers. It is distributed in accordance with the Creative Commons Attribution NonCommercial (CC BY-NC 4.0) license, which permits others to distribute, remix, adapt, build upon this work non-commercially, and license their derivative works on different terms, provided the original work is properly cited and the use is non-commercial. See: <http://creativecommons.org/licenses/by-nc/4.0/>

**Manuscript source:** Unsolicited manuscript

**Received:** April 8, 2020

**Peer-review started:** April 8, 2020

**First decision:** April 28, 2020

**Revised:** April 29, 2020

**Accepted:** July 14, 2020

**Article in press:** July 14, 2020

**Published online:** August 26, 2020

**P-Reviewer:** Coffin CS, Kato M

**S-Editor:** Wang JL

**L-Editor:** Wang TQ

**P-Editor:** Liu JH



**Core tip:** We report a case in which delayed perforation occurred 15 h after colonic endoscopic resection of a laterally spreading tumor in the colonic hepatic curvature. Peritonitis aggravated progressively without macroscopic perforation and conservative treatment had no effect. Micro-perforation was successfully closed under endoscopy with clips to avoid worse complications and surgical intervention.

**Citation:** Zhou GYJ, Hu JL, Wang S, Ge N, Liu X, Wang GX, Sun SY, Guo JT. Delayed perforation after endoscopic resection of a colonic laterally spreading tumor: A case report and literature review. *World J Clin Cases* 2020; 8(16): 3608-3615

**URL:** <https://www.wjgnet.com/2307-8960/full/v8/i16/3608.htm>

**DOI:** <https://dx.doi.org/10.12998/wjcc.v8.i16.3608>

## INTRODUCTION

Endoscopic mucosal resection (EMR) is a common treatment for gastrointestinal mucosal lesions worldwide. Developed on the basis of EMR, endoscopic submucosal dissection (ESD) makes *en bloc* resection possible and endoscopic piecemeal mucosal resection (EPMR) is suitable for large tumors. Endoscopic therapy requires complicated technology and is associated with a high risk of complications<sup>[1]</sup>. Perforation is one of the most severe complications; there is both intraoperative perforation and delayed perforation. The latter is often associated with severe systemic symptoms or signs once found; therefore, it requires immediate diagnosis and managements<sup>[2]</sup>.

Here, we report a case in which delayed perforation occurred after colonic endoscopic resection of a laterally spreading tumor (LST) in the hepatic flexure of the colon and peritonitis aggravated progressively. This case is being reported because delayed perforation was identified in a timely fashion and endoscopic closure was performed without macroscopic perforation to avoid worse complications and surgical intervention. We discuss the clinical course of this rare case about micro-perforation and also review the relevant literature.

## CASE PRESENTATION

### Chief complaints

A 54-year-old man complained of aggravating abdominal pain 15 h after endoscopic resection of a colonic LST.

### History of present illness

The patient was referred to our hospital for endoscopic resection of an LST measuring 30 mm that was diagnosed as an adenoma on pathology in the medial side of the colonic hepatic curvature. The patient was placed on a low-fiber diet on the day prior to endoscopic surgery. Adequate bowel preparation (BBPS: 3 points) was achieved using a spilt regimen of 4 L of polyethylene glycol solution and simethicone. During the procedure, our experienced team performed ESD for this lesion at first. When damage to the muscular layer caused by poor scope operability was observed, we changed into EPMR to quickly finish the operation. Prophylactic closure with clips was performed at the damage site. The tumor was removed without residue, and the wound was treated quite well without obvious perforation or hemorrhage. There was no abdominal pain after resection, and the patient was in a good condition. Routine antibiotics and intravenous nutrition were used in consideration of the large mucosal defect. Fifteen hours after endoscopic resection, the patient passed gas and then suddenly experienced severe abdominal pain that aggravated progressively over time without any alleviation.

### History of past illness

The patient had a history of diabetes for 10 years without a regular oral hypoglycemic treatment. He had no history of other chronic diseases like cardiovascular disease and hypertension, and no history of trauma, surgery, or blood transfusion. He had no history of food and drug allergy.

### **Personal and family history**

The patient occasionally drank alcohol and denied a history of smoking. He had no family history of intestinal tumors.

### **Physical examination**

Physical examination showed intolerable compression pain and rebound pain localized in the right abdomen, suggesting the presence of peritonitis.

### **Laboratory examinations**

Emergency blood analysis showed that neutrophil proportion increased slightly (79.9%) with normal white blood cell count, hemoglobin, and red blood cell count.

### **Imaging examinations**

Emergency computed tomography (CT) revealed a small amount of pneumoperitoneum and substantial exudate (Figure 1).

---

## **FINAL DIAGNOSIS**

---

The final diagnosis was a perforation after endoscopic resection.

---

## **TREATMENT**

---

The attempt of placing gastrointestinal decompression did not relieve the symptoms. Emergent colonoscopy with carbon dioxide insufflation was performed. No obvious perforation was observed. We believed that there was a micro-perforation, and the wound was closed using clips (Figure 2). It only took 2 h from the beginning of abdominal pain to achieve successful endoscopic closure. The patient was asked to maintain a semi-recumbent position and was treated with fasting and broad-spectrum antibiotics.

---

## **OUTCOME AND FOLLOW-UP**

---

During the night after endoscopic closure, the patient experienced a fever of 38.3°C, but the pain was slightly relieved. Three days after endoscopic closure, the patient's abdominal pain totally subsided, and after tolerating oral diet, he was discharged on the 4<sup>th</sup> day after endoscopic closure (Figure 3).

No recurrence occurred in the follow-up. The patient was content with our timely treatment, and informed consent was obtained.

---

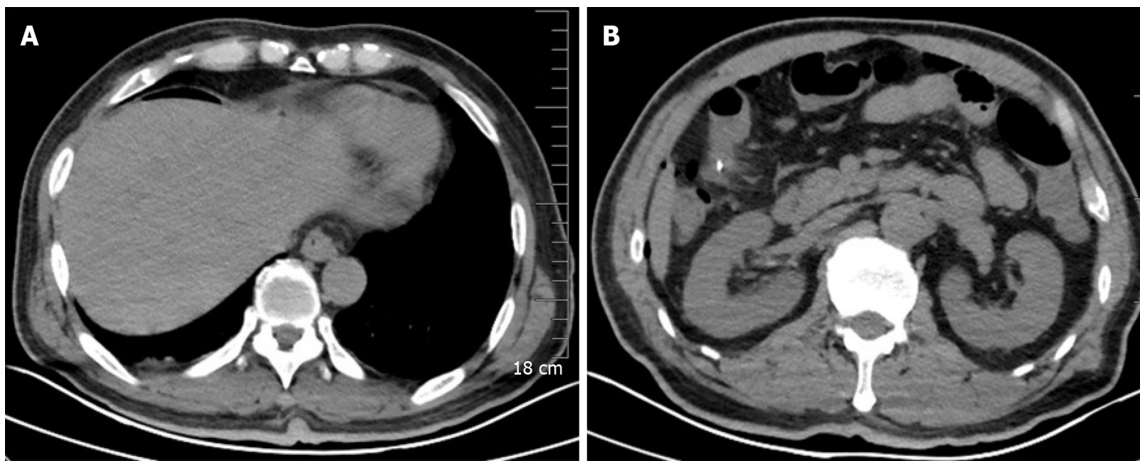
## **DISCUSSION**

---

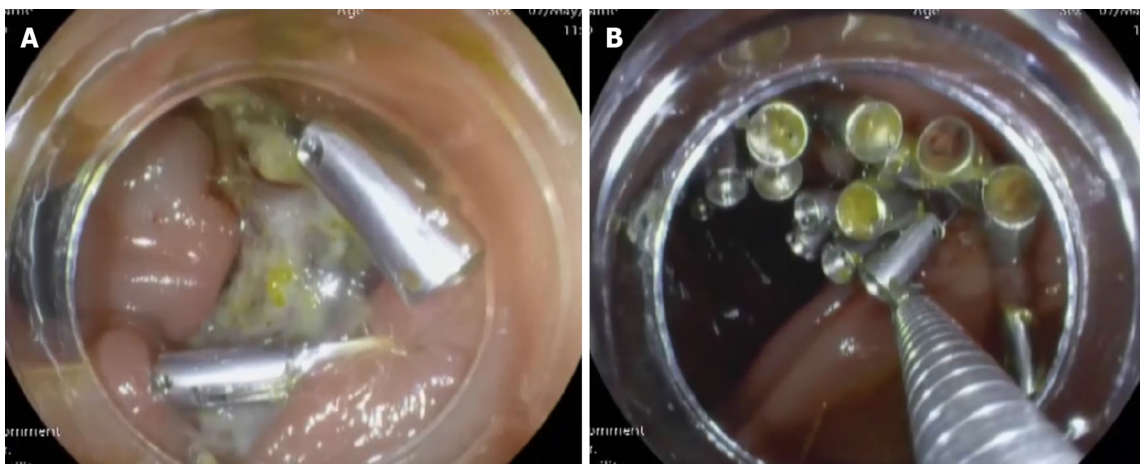
In the present case, delayed perforation occurred 15 h after colonic endoscopic resection of LST in the hepatic flexure of colon. Peritonitis aggravated progressively without obvious perforation and conservative treatment had no effect. Micro-perforation was successfully closed under endoscopy with clips, which had not been reflected in the previous cases ever.

EMR is effective for lesions < 20 mm, and ESD is recommended for lesions > 20 mm with limited submucosal invasion<sup>[3]</sup>. Nevertheless, there remain no definitive guidelines for treatment of lesions > 20 mm with no invasion or invasion limited in the mucosal layer. We were planning to perform ESD according to anticipatory judgment; however, poor scope operability causing damage to the muscular layer caused us to change to EPMR. Fortunately, no perforation or obvious hemorrhage occurred throughout the procedure, suggesting that our strategy was reasonable.

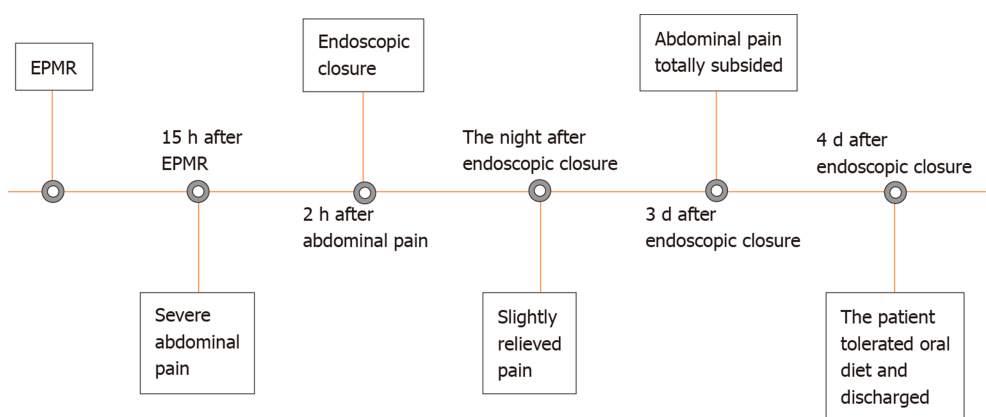
Perforation is considered one of the most serious complications of therapeutic colonoscopy. Because of intraperitoneal leakage of the intestinal fluid with digestive enzymes and fecal fluid with large amounts of bacteria, peritonitis caused by colorectal perforation is more serious than gastroesophageal perforation<sup>[4]</sup>. The probability of perforation after ESD is higher than that after EMR, accounting for 1.4%-14.0%<sup>[4-6]</sup>. Endoscopic perforation is classified as intraoperative and delayed



**Figure 1 Emergency computed tomography.** A: Free air can be seen under the diaphragm; B: Free air can be found surrounding the endoscopic resection site.



**Figure 2 Emergent colonoscopy with carbon dioxide insufflation was performed.** A: No obvious delayed perforation was seen at the wound site; B: The wound was closed using clips.



**Figure 3 Timeline of the patient.** EPMR: Endoscopic piecemeal mucosal resection.

perforation; the latter is even rarer, with reported rates of 0.3%-0.7%<sup>[7]</sup> and is defined as perforation within 48 h after endoscopic surgery. All previously reported ten cases occurred within 48 h after ESD or EMR<sup>[8-12]</sup>, accompanied by peritonitis of various degrees. Delayed perforation in our case took place in 15 h and caused progressively increasing peritonitis, which is even rarer because of the aggravating peritonitis and our earlier recognition compared with previous case reports.



Several studies have demonstrated that many factors contribute to the occurrence of delayed perforation. Kang *et al*<sup>[13]</sup> reported that LSTs were the most common type of lesions causing endoscopic perforation. The most common location was the right colon, including the cecum, ascending colon, and transverse colon, because colonoscopy might be technically complicated there. Of the reported ten cases, 70% occurred in the right colon. The other risk factors include large tumor diameter, presence of fibrosis, and procedure-related factors<sup>[7,13]</sup>. Our present case is partly consistent with these reports in terms of tumor diameter and tumor location.

The mechanism of immediate colonic perforation is believed to be associated with unintended deep dissection. Delayed perforation is thought to result from thermal injury, that is to say, immoderate thermocoagulation damages both the submucosal and muscular layers, leading to small perforations over time<sup>[14,15]</sup>. In our present case, neither an obvious perforation nor a small perforation was observed during the subsequent emergent endoscopy. Therefore, we believed that there was a micro-perforation where there was deep dissection or thermal injury of the muscular layer during the procedure.

Several studies have emphasized that prompt and accurate diagnosis is essential for appropriate management and favorable prognosis after delayed perforation<sup>[2,15]</sup>. Symptoms and signs should be recorded and evaluated carefully. Abdominal pain is one of the earliest and most common symptoms, accompanied by peritoneal irritation signs. Abdominal distention, fever, tachycardia, tachypnea, and subcutaneous emphysema also raise the index of suspicion for delayed perforation. To obtain a definitive diagnosis, plain abdominal radiography or abdominal computed tomography is recommended to detect subdiaphragmatic free air and fluid leak with high accuracy. Laboratory indicators such as complete blood counts are useful to estimate the degree of abdominal contamination. In our case, when perforation was suspected, a CT scan was performed emergently, which finally indicated pneumoperitoneum and exudation, thereby confirming our suspicion.

Currently, there are no guidelines on the management of delayed perforation after colonic endoscopic resection. Delayed perforation after therapeutic colonoscopy is a rare event; however, it is severe, and emergent surgery is the most common treatment for this situation, especially in the context of peritonitis<sup>[12]</sup>. With the development of endoscopic techniques<sup>[11,16-19]</sup>, timely endoscopic closure may be a good option, if delayed perforation occurs in the patient's fasting period with local peritonitis. In the present case, although there was no obvious perforation, peritonitis increased over time and conservative treatment was ineffective. Micro-perforation was diagnosed and successfully closed using clips with carbon dioxide insufflation under colonoscopy. Fasting and intravenous broad-spectrum antibiotics were also administered to avoid the need for surgical rescue.

In the English literature, only five other reports (10 cases) of delayed perforation after EMR and ESD with non-surgical management have been reported<sup>[8-12]</sup> (Table 1). The decision to conduct an endoscopic operation also depends on the perforation size, endoscopist's experience, and instruments available<sup>[2,15,20-23]</sup>. During endoscopic closure, carbon dioxide insufflation is generally preferred to prevent barotrauma because this gas is absorbed more quickly than air<sup>[24]</sup>. Inoki *et al*<sup>[9]</sup> reported a case in which delayed perforation after EMR was closed with endoscopic clips. Currently, increasing numbers of endoscopic techniques and equipment have been used. Both through-the-scope-clip and over-the-scope-clip are widely used for endoscopic repair, the former for smaller perforations and the latter for larger ones. Xiao *et al*<sup>[11]</sup> demonstrated an endoscopic method called the overtube approach. Nagami *et al*<sup>[10]</sup> demonstrated that polyglycolic acid sheets and fibrin glue were effective for endoscopic closure of delayed perforation. Subsequent conservative treatment after closure is indispensable, including fasting, intravenous antibiotics, gastrointestinal decompression, and nutrition support<sup>[25]</sup>. Kawashima *et al*<sup>[8]</sup> described completely conservative treatment, including transnasal decompression, as a method to manage delayed perforation. Nevertheless, not all cases can be treated endoscopically. Delayed perforation with general peritonitis, hemodynamic disorder, and failure in endoscopic closure require immediate surgical treatment<sup>[26]</sup>.

## CONCLUSION

Delayed perforation with peritonitis after endoscopic operation is an uncommon but serious complication. Endoscopists should operate carefully throughout the procedure, especially for LSTs in the right colon. If delayed perforation occurs and

Table 1 Summary of previous reports of delayed perforation with non-surgical management

| Ref.   | Case | Age (yr) | Sex    | Morphology | Location         | Tumor diameter (mm) | Endoscopic therapy | Time of delayed perforation (h) | Perforation size (mm) | Treatment  | Hospital stay (d) |
|--|------|----------|--------|------------|------------------|---------------------|--------------------|---------------------------------|-----------------------|--|-------------------|
| Kawashima <i>et al</i> <sup>[8]</sup> , 2018 | 1    | 66       | Male   | LST        | Cecum            | 40                  | ESD                | Within 24                       | 10                    | Transnasal decompression, antibiotics  | 26                |
| Inoki <i>et al</i> <sup>[9]</sup> , 2016     | 2    | 73       | Male   | LST        | Transverse colon | 18                  | EMR                | Within 24                       | NM                    | Endoscopic closure with clips, antibiotics   | 9                 |
| Nagami <i>et al</i> <sup>[10]</sup> , 2019   | 3    | 81       | Male   | LST        | Ascending colon  | 40                  | ESD                | Within 48                       | NM                    | Endoscopic closure with clips, polyglycolic acid sheets and fibrin glue, antibiotics | 16                |
| Xiao <i>et al</i> <sup>[11]</sup> , 2014     | 4    | 49       | Female | LST        | Sigmoid colon    | NM                  | ESD                | Within 24-48                    | 3                     | Endoscopic closure with clips, overtube, nasobiliary tube, antibiotics               | 29                |
| Xiao <i>et al</i> <sup>[11]</sup> , 2014     | 5    | 77       | Male   | LST        | Ascending colon  | NM                  | ESD                | Within 24-48                    | 6                     | Endoscopic closure with clips, overtube, nasobiliary tube, antibiotics               | 12                |
| Xiao <i>et al</i> <sup>[11]</sup> , 2014     | 6    | 41       | Female | Polyp      | Transverse colon | NM                  | EMR                | Within 24-48                    | 5                     | Endoscopic closure with clips, overtube, nasobiliary tube, antibiotics               | 7                 |
| Iwatsubo <i>et al</i> <sup>[12]</sup> , 2019 | 7    | 45       | Male   | Protruded  | Descending colon | 10                  | ESD                | 24                              | NM                    | Conservative therapy, antibiotics  | 13                |
| Iwatsubo <i>et al</i> <sup>[12]</sup> , 2019 | 8    | 53       | Male   | Flat       | Transverse colon | 22                  | ESD                | 19                              | NM                    | Conservative therapy, antibiotics  | 12                |
| Iwatsubo <i>et al</i> <sup>[12]</sup> , 2019 | 9    | 74       | Female | Protruded  | Rectum           | 110                 | ESD                | 14                              | NM                    | Conservative therapy, antibiotics  | 14                |
| Iwatsubo <i>et al</i> <sup>[12]</sup> , 2019 | 10   | 58       | Male   | Protruded  | Ascending colon  | 55                  | ESD                | 24                              | NM                    | Conservative therapy, antibiotics  | 13                |

NM: Not mentioned; ESD: Endoscopic submucosal dissection; EMR: Endoscopic mucosal resection; LST: Laterally spreading tumor.

localized peritonitis exacerbates, even without macroscopic perforation, endoscopic closure is an alternative for patients with stable vital signs in the early stage.

## REFERENCES

- Hong SN**, Byeon JS, Lee BI, Yang DH, Kim J, Cho KB, Cho JW, Jang HJ, Jeon SW, Jung SA, Chang DK. Prediction model and risk score for perforation in patients undergoing colorectal endoscopic submucosal dissection. *Gastrointest Endosc* 2016; **84**: 98-108 [PMID: 26708921 DOI: 10.1016/j.gie.2015.12.011]
- Paspatis GA**, Dumonceau JM, Barthet M, Meisner S, Repici A, Saunders BP, Vezakis A, Gonzalez JM, Turino SY, Tsiamoulos ZP, Fockens P, Hassan C. Diagnosis and management of iatrogenic endoscopic perforations: European Society of Gastrointestinal Endoscopy (ESGE) Position Statement. *Endoscopy* 2014; **46**: 693-711 [PMID: 25046348 DOI: 10.1055/s-0034-1377531]
- Pimentel-Nunes P**, Dinis-Ribeiro M, Ponchon T, Repici A, Vieth M, De Ceglie A, Amato A, Berr F, Bhandari P, Bialek A, Conio M, Haringsma J, Langner C, Meisner S, Messmann H, Morino M, Neuhaus H, Piessevaux H, Rugge M, Saunders BP, Robaszkiewicz M, Seewald S, Kashin S, Dumonceau JM, Hassan C, Deprez PH. Endoscopic submucosal dissection: European Society of Gastrointestinal Endoscopy (ESGE) Guideline. *Endoscopy* 2015; **47**: 829-854 [PMID: 26317585 DOI: 10.1055/s-0034-1392882]

- 4 **Taku K**, Sano Y, Fu KI, Saito Y, Matsuda T, Uraoka T, Yoshino T, Yamaguchi Y, Fujita M, Hattori S, Ishikawa T, Saito D, Fujii T, Kaneko E, Yoshida S. Iatrogenic perforation associated with therapeutic colonoscopy: a multicenter study in Japan. *J Gastroenterol Hepatol* 2007; **22**: 1409-1414 [PMID: [17593224](#) DOI: [10.1111/j.1440-1746.2007.05022.x](#)]
- 5 **Saito Y**, Fukuzawa M, Matsuda T, Fukunaga S, Sakamoto T, Uraoka T, Nakajima T, Ikehara H, Fu KI, Itoi T, Fujii T. Clinical outcome of endoscopic submucosal dissection versus endoscopic mucosal resection of large colorectal tumors as determined by curative resection. *Surg Endosc* 2010; **24**: 343-352 [PMID: [19517168](#) DOI: [10.1007/s00464-009-0562-8](#)]
- 6 **Tamegai Y**, Saito Y, Masaki N, Hinohara C, Oshima T, Kogure E, Liu Y, Uemura N, Saito K. Endoscopic submucosal dissection: a safe technique for colorectal tumors. *Endoscopy* 2007; **39**: 418-422 [PMID: [17516348](#) DOI: [10.1055/s-2007-966427](#)]
- 7 **Isomoto H**, Nishiyama H, Yamaguchi N, Fukuda E, Ishii H, Ikeda K, Ohnita K, Nakao K, Kohno S, Shikuwa S. Clinicopathological factors associated with clinical outcomes of endoscopic submucosal dissection for colorectal epithelial neoplasms. *Endoscopy* 2009; **41**: 679-683 [PMID: [19670135](#) DOI: [10.1055/s-0029-1214979](#)]
- 8 **Kawashima K**, Hikichi T, Fujiwara T, Gunji N, Nakamura J, Watanabe K, Katakura K, Ohira H. Delayed perforation after endoscopic submucosal dissection for mucosal colon cancer: A conservatively treated case. *Fukushima J Med Sci* 2018; **64**: 157-162 [PMID: [30197398](#) DOI: [10.5387/fms.2018-04](#)]
- 9 **Inoki K**, Sakamoto T, Sekiguchi M, Yamada M, Nakajima T, Matsuda T, Saito Y. Successful endoscopic closure of a colonic perforation one day after endoscopic mucosal resection of a lesion in the transverse colon. *World J Clin Cases* 2016; **4**: 238-242 [PMID: [27574613](#) DOI: [10.12998/wjcc.v4.i8.238](#)]
- 10 **Nagami Y**, Fukunaga S, Kanamori A, Sakai T, Ominami M, Watanabe T, Fujiwara Y. Endoscopic closure using polyglycolic acid sheets for delayed perforation after colonic endoscopic submucosal dissection. *Endoscopy* 2020; **52**: E11-E12 [PMID: [31398745](#) DOI: [10.1055/a-0978-4501](#)]
- 11 **Xiao YF**, Bai JY, Yu J, Lin XL, Zhao XY, Yang SM, Fan CQ. Endoscopic treatment of delayed colon perforation: the enteroscopy overtube approach. *Endoscopy* 2014; **46**: 503-508 [PMID: [24777425](#) DOI: [10.1055/s-0034-1365040](#)]
- 12 **Iwatsubo T**, Takeuchi Y, Yamasaki Y, Nakagawa K, Arao M, Ohmori M, Iwagami H, Matsuno K, Inoue S, Nakahira H, Matsuura N, Shichijo S, Maekawa A, Kanesaka T, Yamamoto S, Higashino K, Uedo N, Ishihara R. Differences in Clinical Course of Intraprocedural and Delayed Perforation Caused by Endoscopic Submucosal Dissection for Colorectal Neoplasms: A Retrospective Study. *Dig Dis* 2019; **37**: 53-62 [PMID: [30227392](#) DOI: [10.1159/000492868](#)]
- 13 **Kang DU**, Choi Y, Lee HS, Lee HJ, Park SH, Yang DH, Yoon SM, Kim KJ, Ye BD, Myung SJ, Yang SK, Kim JH, Byeon JS. Endoscopic and Clinical Factors Affecting the Prognosis of Colorectal Endoscopic Submucosal Dissection-Related Perforation. *Gut Liver* 2016; **10**: 420-428 [PMID: [26780090](#) DOI: [10.5009/gnl15252](#)]
- 14 **Ko YB**, Lee JM, Kim WS, Kwak MS, Lee JW, Shin DY, Yang DH, Byeon JS. Unexpected Delayed Colon Perforation after the Endoscopic Submucosal Dissection with Snaring of a Laterally Spreading Tumor. *Clin Endosc* 2015; **48**: 570-575 [PMID: [26668808](#) DOI: [10.5946/ce.2015.48.6.570](#)]
- 15 **Alsowaina KN**, Ahmed MA, Alkhamisi NA, Elnahas AI, Hawel JD, Khanna NV, Schlachta CM. Management of colonoscopic perforation: a systematic review and treatment algorithm. *Surg Endosc* 2019; **33**: 3889-3898 [PMID: [31451923](#) DOI: [10.1007/s00464-019-07064-7](#)]
- 16 **Nunes G**, Marques PP, Patita M, Allen M, Gargatè L. EUS-guided recanalization of complete colorectal anastomotic stenosis using a lumen-apposing metal stent. *Endosc Ultrasound* 2019; **8**: 211-212 [PMID: [30785118](#) DOI: [10.4103/eus.eus\\_62\\_18](#)]
- 17 **Guo J**, Sun S. EUS-guided gallbladder drainage and gallbladder interventions in China. *Endosc Ultrasound* 2018; **7**: 83-84 [PMID: [29667621](#) DOI: [10.4103/eus.eus\\_6\\_18](#)]
- 18 **Wang G**, Liu X, Wang S, Ge N, Guo J, Sun S. Endoscopic Ultrasound-guided Gastroenterostomy: A Promising Alternative to Surgery. *J Transl Int Med* 2019; **7**: 93-99 [PMID: [31637179](#) DOI: [10.2478/jtim-2019-0021](#)]
- 19 **Theerasuwipakorn N**, Tasneem AA, Kongkam P, Angsuwatcharakon P, Ridditid W, Navicharern P, Kitisin K, Wangrattanapranee P, Rerknimitr R, Kullavanijaya P. Walled-off Peripancreatic Fluid Collections in Asian Population: Paradigm Shift from Surgical and Percutaneous to Endoscopic Drainage. *J Transl Int Med* 2019; **7**: 170-177 [PMID: [32010603](#) DOI: [10.2478/jtim-2019-0032](#)]
- 20 **de'Angelis N**, Di Saverio S, Chiara O, Sartelli M, Martínez-Pérez A, Patrizi F, Weber DG, Ansaloni L, Biffi W, Ben-Ishay O, Bala M, Brunetti F, Gaiani F, Abdalla S, Amiot A, Bahouth H, Bianchi G, Casanova D, Coccolini F, Coimbra R, de'Angelis GL, De Simone B, Fraga GP, Genova P, Ivatury R, Kashuk JL, Kirkpatrick AW, Le Baleur Y, Machado F, Machain GM, Maier RV, Chichom-Mefire A, Memeo R, Mesquita C, Salamea Molina JC, Mutignani M, Manzano-Núñez R, Ordoñez C, Peitzman AB, Pereira BM, Picetti E, Pisano M, Puyana JC, Rizoli S, Siddiqui M, Sobhani I, Ten Broek RP, Zorcolo L, Carra MC, Kluger Y, Catena F. 2017 WSES guidelines for the management of iatrogenic colonoscopy perforation. *World J Emerg Surg* 2018; **13**: 5 [PMID: [29416554](#) DOI: [10.1186/s13017-018-0162-9](#)]
- 21 **Sun S**, Wang C, Wang S. Remember, interventional EUS is performed using an elevator-containing scope as well. *Endosc Ultrasound* 2018; **7**: 73-75 [PMID: [29667618](#) DOI: [10.4103/eus.eus\\_14\\_18](#)]
- 22 **Ge N**, Hu J, Sun S, Linghu E, Jin Z, Li Z. Endoscopic Ultrasound-guided Pancreatic Pseudocyst Drainage with Lumen-apposing Metal Stents or Plastic Double-pigtail Stents: A Multifactorial Analysis. *J Transl Int Med* 2017; **5**: 213-219 [PMID: [29340278](#) DOI: [10.1515/jtim-2017-0036](#)]
- 23 **Ge N**, Sun S. Endoscopic ultrasound: An all in one technique vibrates virtually around the whole internal medical field. *J Transl Intern Med* 2014; **2**: 104-106
- 24 **Dellon ES**, Hawk JS, Grimm IS, Shaheen NJ. The use of carbon dioxide for insufflation during GI endoscopy: a systematic review. *Gastrointest Endosc* 2009; **69**: 843-849 [PMID: [19152906](#) DOI: [10.1016/j.gie.2008.05.067](#)]
- 25 **Tanaka S**, Kashida H, Saito Y, Yahagi N, Yamano H, Saito S, Hisabe T, Yao T, Watanabe M, Yoshida M, Kudo SE, Tsuruta O, Sugihara KI, Watanabe T, Saitoh Y, Igarashi M, Toyonaga T, Ajioka Y, Ichinose M, Matsui T, Sugita A, Sugano K, Fujimoto K, Tajiri H. JGES guidelines for colorectal endoscopic submucosal



- dissection/endoscopic mucosal resection. *Dig Endosc* 2015; **27**: 417-434 [PMID: 25652022 DOI: 10.1111/den.12456]
- 26 **Cho SB**, Lee WS, Joo YE, Kim HR, Park SW, Park CH, Kim HS, Choi SK, Rew JS. Therapeutic options for iatrogenic colon perforation: feasibility of endoscopic clip closure and predictors of the need for early surgery. *Surg Endosc* 2012; **26**: 473-479 [PMID: 21938583 DOI: 10.1007/s00464-011-1903-y]



Published by **Baishideng Publishing Group Inc**  
7041 Koll Center Parkway, Suite 160, Pleasanton, CA 94566, USA

**Telephone:** +1-925-3991568

**E-mail:** [bpgoffice@wjgnet.com](mailto:bpgoffice@wjgnet.com)

**Help Desk:** <https://www.f6publishing.com/helpdesk>

<https://www.wjgnet.com>

