

A portrait of a man with a beard and mustache, wearing a teal scrub top. He is smiling slightly. In the background, there is a framed diploma on the left and a diagram of a heart on the right. The diploma is from the University of Campania and mentions 'ARIA ELIA' and 'CHIPVIRGO'. The heart diagram is a detailed anatomical drawing of the human heart with its major vessels.

Contents

Semimonthly Volume 8 Number 17 September 6, 2020

REVIEW

- 3621 Autoimmunity as the comet tail of COVID-19 pandemic
Talotta R, Robertson E
- 3645 Gender medicine: Lessons from COVID-19 and other medical conditions for designing health policy
Machluf Y, Chaïter Y, Tal O

MINIREVIEWS

- 3669 Complexities of diagnosis and management of COVID-19 in autoimmune diseases: Potential benefits and detriments of immunosuppression
Georgiev T, Angelov AK

ORIGINAL ARTICLE

Retrospective Study

- 3679 Incidental anal ¹⁸fluorodeoxyglucose uptake: Should we further examine the patient?
Moussaddaq AS, Brochard C, Palard-Novello X, Garin E, Wallenhorst T, Le Balc'h E, Merlini L'heritier A, Grainville T, Siproudhis L, Lièvre A
- 3691 Emergency surgery in COVID-19 outbreak: Has anything changed? Single center experience
D'Urbano F, Fabbri N, Koleva Radica M, Rossin E, Carcoforo P
- 3697 Somatostatin receptor scintigraphy in the follow up of neuroendocrine neoplasms of appendix
Saponjski J, Macut D, Sobic-Saranovic D, Ognjanovic S, Bozic Antic I, Pavlovic D, Artiko V
- 3708 Efficacy of stool multiplex polymerase chain reaction assay in adult patients with acute infectious diarrhea
Ahn JS, Seo SI, Kim J, Kim T, Kang JG, Kim HS, Shin WG, Jang MK, Kim HY
- 3718 Comparison of gemcitabine plus nab-paclitaxel and FOLFIRINOX in metastatic pancreatic cancer
Han SY, Kim DU, Seol YM, Kim S, Lee NK, Hong SB, Seo HI
- 3730 Shear wave elastography may be sensitive and more precise than transient elastography in predicting significant fibrosis
Yao TT, Pan J, Qian JD, Cheng H, Wang Y, Wang GQ
- 3743 Radioactive ¹²⁵I seed implantation for locally advanced pancreatic cancer: A retrospective analysis of 50 cases
Li CG, Zhou ZP, Jia YZ, Tan XL, Song YY
- 3751 Active surveillance in metastatic pancreatic neuroendocrine tumors: A 20-year single-institutional experience
Gao HL, Wang WQ, Xu HX, Wu CT, Li H, Ni QX, Yu XJ, Liu L

- 3763** Clinical efficacy of tocilizumab treatment in severe and critical COVID-19 patients

Zeng J, Xie MH, Yang J, Chao SW, Xu EL

- 3774** Phosphatidylinositol-3,4,5-trisphosphate dependent Rac exchange factor 1 is a diagnostic and prognostic biomarker for hepatocellular carcinoma

Cai Y, Zheng Q, Yao DJ

Observational Study

- 3786** Awareness and attitude of fecal microbiota transplantation through transendoscopic enteral tubing among inflammatory bowel disease patients

Zhong M, Sun Y, Wang HG, Marcella C, Cui BT, Miao YL, Zhang FM

CASE REPORT

- 3797** Cauda equina arachnoiditis – a rare manifestation of West Nile virus neuroinvasive disease: A case report

Santini M, Zupetic I, Viskovic K, Krznaric J, Kutlesa M, Krajinovic V, Polak VL, Savic V, Tabain I, Barbic L, Bogdanic M, Stevanovic V, Mrzljak A, Vilibic-Cavlek T

- 3804** Portal gas in neonates; is it always surgical? A case report

Altokhais TI

- 3808** Large lingual heterotopic gastrointestinal cyst in a newborn: A case report

Lee AD, Harada K, Tanaka S, Yokota Y, Mima T, Enomoto A, Kogo M

- 3814** Osteochondral lesion of talus with gout tophi deposition: A case report

Kim T, Choi YR

- 3821** Traumatic neuroma of remnant cystic duct mimicking duodenal subepithelial tumor: A case report

Kim DH, Park JH, Cho JK, Yang JW, Kim TH, Jeong SH, Kim YH, Lee YJ, Hong SC, Jung EJ, Ju YT, Jeong CY, Kim JY

- 3828** Autoimmune hepatitis in a patient with immunoglobulin A nephropathy: A case report

Jeon YH, Kim DW, Lee SJ, Park YJ, Kim HJ, Han M, Kim IY, Lee DW, Song SH, Lee SB, Seong EY

- 3835** Diagnosis of an actively bleeding brachial artery hematoma by contrast-enhanced ultrasound: A case report

Ma JJ, Zhang B

- 3841** Lung adenocarcinoma harboring rare epidermal growth factor receptor L858R and V834L mutations treated with icotinib: A case report

Zhai SS, Yu H, Gu TT, Li YX, Lei Y, Zhang HY, Zhen TH, Gao YG

- 3847** Gastroduodenitis associated with ulcerative colitis: A case report

Yang Y, Li CQ, Chen WJ, Ma ZH, Liu G

- 3853** Majocchi's granuloma caused by *Trichophyton rubrum* after facial injection with hyaluronic acid: A case report

Liu J, Xin WQ, Liu LT, Chen CF, Wu L, Hu XP

- 3859** Novel deletion mutation in Bruton's tyrosine kinase results in X-linked agammaglobulinemia: A case report
Hu XM, Yuan K, Chen H, Chen C, Fang YL, Zhu JF, Liang L, Wang CL
- 3867** Multidisciplinary treatment of life-threatening hemoptysis and paraplegia of choriocarcinoma with pulmonary, hepatic and spinal metastases: A case report
Lin YY, Sun Y, Jiang Y, Song BZ, Ke LJ
- 3875** Diagnostic value of ultrasound in the spontaneous rupture of renal angiomyolipoma during pregnancy: A case report
Zhang T, Xue S, Wang ZM, Duan XM, Wang DX
- 3881** Gallbladder sarcomatoid carcinoma: Seven case reports
Qin Q, Liu M, Wang X
- 3890** Surgical strategy used in multilevel cervical disc replacement and cervical hybrid surgery: Four case reports
Wang XF, Meng Y, Liu H, Hong Y, Wang BY
- 3903** Diagnosis and treatment of an elderly patient with 2019-nCoV pneumonia and acute exacerbation of chronic obstructive pulmonary disease in Gansu Province: A case report
He TP, Wang DL, Zhao J, Jiang XY, He J, Feng JK, Yuan Y
- 3911** Diagnosis and treatment of mixed infection of hepatic cystic and alveolar *echinococcosis*: Four case reports
A JD, Chai JP, Wang H, Gao W, Peng Z, Zhao SY, A XR

ABOUT COVER

Editorial board member of World Journal of Clinical Cases, Dr. Elia de Maria is Adjunct Professor of Arrhythmology Lab in the Cardiology Unit, Ramazzini Hospital in Carpi, Italy. He graduated in Medicine and Surgery from the University of Napoli in 1999, continuing on to obtain specialization in Cardiology in 2003. He also holds the distinction of High Degree Master in Electrophysiology and Cardiac Stimulation. Since 2005, he has practiced as a Permanent Consultant Cardiologist in the Italian Public Hospitals, and since 2015 as an External Contract Professor in the Faculty of Medicine and Surgery of University of Verona. His clinical and research interests encompass pharmacological therapy in acute and chronic cardiac conditions, temporary and definitive pacing, thoracentesis and pericardiocentesis, and hemodynamic monitoring. (L-Editor: Filipodia)

AIMS AND SCOPE

The primary aim of *World Journal of Clinical Cases* (WJCC, *World J Clin Cases*) is to provide scholars and readers from various fields of clinical medicine with a platform to publish high-quality clinical research articles and communicate their research findings online.

WJCC mainly publishes articles reporting research results and findings obtained in the field of clinical medicine and covering a wide range of topics, including case control studies, retrospective cohort studies, retrospective studies, clinical trials studies, observational studies, prospective studies, randomized controlled trials, randomized clinical trials, systematic reviews, meta-analysis, and case reports.

INDEXING/ABSTRACTING

The WJCC is now indexed in Science Citation Index Expanded (also known as SciSearch®), Journal Citation Reports/Science Edition, PubMed, and PubMed Central. The 2020 Edition of Journal Citation Reports® cites the 2019 impact factor (IF) for WJCC as 1.013; IF without journal self cites: 0.991; Ranking: 120 among 165 journals in medicine, general and internal; and Quartile category: Q3.

RESPONSIBLE EDITORS FOR THIS ISSUE

Production Editor: Yan-Xia Xing; Production Department Director: Yun-Xiaojuan Wu; Editorial Office Director: Jin-Lai Wang.

NAME OF JOURNAL

World Journal of Clinical Cases

ISSN

ISSN 2307-8960 (online)

LAUNCH DATE

April 16, 2013

FREQUENCY

Semimonthly

EDITORS-IN-CHIEF

Dennis A Bloomfield, Sandro Vento, Bao-Gan Peng

EDITORIAL BOARD MEMBERS

<https://www.wjgnet.com/2307-8960/editorialboard.htm>

PUBLICATION DATE

September 6, 2020

COPYRIGHT

© 2020 Baishideng Publishing Group Inc

INSTRUCTIONS TO AUTHORS

<https://www.wjgnet.com/bpg/gerinfo/204>

GUIDELINES FOR ETHICS DOCUMENTS

<https://www.wjgnet.com/bpg/GerInfo/287>

GUIDELINES FOR NON-NATIVE SPEAKERS OF ENGLISH

<https://www.wjgnet.com/bpg/gerinfo/240>

PUBLICATION ETHICS

<https://www.wjgnet.com/bpg/GerInfo/288>

PUBLICATION MISCONDUCT

<https://www.wjgnet.com/bpg/gerinfo/208>

ARTICLE PROCESSING CHARGE

<https://www.wjgnet.com/bpg/gerinfo/242>

STEPS FOR SUBMITTING MANUSCRIPTS

<https://www.wjgnet.com/bpg/GerInfo/239>

ONLINE SUBMISSION

<https://www.f6publishing.com>



Retrospective Study

Clinical efficacy of tocilizumab treatment in severe and critical COVID-19 patients

Jia Zeng, Ming-Hui Xie, Jing Yang, Sheng-Wu Chao, Er-Li Xu

ORCID number: Jia Zeng 0000-0001-5201-4526; Ming-Hui Xie 0000-0002-3001-5827; Jing Yang 0000-0002-3244-0971; Sheng-Wu Chao 0000-0002-3031-8670; Er-Li Xu 0000-0001-9453-0801.

Author contributions: Zeng J and Xie MH contributed equally to this work; Zeng J and Xu EL designed the research; Zeng J, Yang J and Chao SW collected and analyzed the clinical data; Zeng J, Yang J and Chao SW wrote the manuscript; Xu EL revised the manuscript.

Institutional review board

statement: The study was reviewed and approved by the Optical Valley Campus of Hubei Maternal and Child Health Care Hospital Institutional Review Board.

Informed consent statement: We obtained consent from the patients or their relatives for publication of this report.

Conflict-of-interest statement: The authors declare that they have no conflicts of interest.

Data sharing statement: No additional data are available.

Open-Access: This article is an open-access article that was selected by an in-house editor and

Jia Zeng, Er-Li Xu, Department of Aviation Disease, Naval Medical Center of PLA, Shanghai 200052, China

Jia Zeng, Ming-Hui Xie, Jing Yang, Sheng-Wu Chao, No. 1 Department of Infection, Optical Valley Campus of Hubei Maternal and Child Health Care Hospital, Wuhan 430073, Hubei Province, China

Ming-Hui Xie, Department of Interventional Therapy, First Affiliated Hospital, the Second Military Medical University, Shanghai 200433, China

Jing Yang, Department of Nephrology, Naval Medical Center of PLA, Shanghai 200052, China

Sheng-Wu Chao, Department of Cardiovascular Medicine, Naval Medical Center of PLA, Shanghai 200052, China

Corresponding author: Er-Li Xu, BMed, Associate Chief Physician, Department of Aviation Disease, Naval Medical Center of PLA, No. 338 Huaihai West Road, Changning District, Shanghai 200052, China. yijiaicheng455@163.com

Abstract

BACKGROUND

The main pathophysiological basis of coronavirus disease 2019 (COVID-19) causing respiratory failure is a cytokine storm and interleukin-6 (IL-6) is an important component of the COVID-19 cytokine storm. As a specific antagonist of IL-6, tocilizumab may block the cytokine storm of COVID-19. The Diagnosis and Treatment Guidelines of New Coronavirus Pneumonia (7th Edition) includes tocilizumab as a recommended drug for immunotherapy in severe and critical COVID-19 patients. However, the specific clinical efficacy of tocilizumab in the treatment of COVID-19 patients is worth studying.

AIM

To determine the clinical efficacy of tocilizumab in inhibiting the cytokine storm in COVID-19.

METHODS

In total, 19 severe and critical COVID-19 patients were enrolled in this study, and were treated with tocilizumab in Optical Valley Campus of Hubei Maternal and Child Health Care Hospital from February 20 to March 31, 2020. The imaging

fully peer-reviewed by external reviewers. It is distributed in accordance with the Creative Commons Attribution NonCommercial (CC BY-NC 4.0) license, which permits others to distribute, remix, adapt, build upon this work non-commercially, and license their derivative works on different terms, provided the original work is properly cited and the use is non-commercial. See: <http://creativecommons.org/licenses/by-nc/4.0/>

Manuscript source: Unsolicited manuscript

Received: May 8, 2020

Peer-review started: May 8, 2020

First decision: June 7, 2020

Revised: June 8, 2020

Accepted: August 6, 2020

Article in press: August 6, 2020

Published online: September 6, 2020

P-Reviewer: Bello BL, Kahrilas PJ, Yoshio S

S-Editor: Wang JL

L-Editor: Webster JR

P-Editor: Xing YX



manifestations and clinical data before and after treatment were analyzed retrospectively, including routine peripheral venous blood tests, routine blood biochemical tests, coagulation test, C-reactive protein (CRP), IL-6, and arterial blood gas analysis.

RESULTS

Of the 19 patients in this group, 13 (68.4%) had significantly improved symptoms of COVID-19 (5 patients were discharged directly and 8 patients were transferred after improvement) following treatment. One case was invalid, 1 case was exacerbated, and 4 deaths (21.1%) were observed (all critical cases). The lymphocyte count, CRP, lactic acid, oxygenation index, fibrinogen (FIB) and IL-6 levels were significantly different in the improved group.

CONCLUSION

Tocilizumab treatment is effective against IL-6 in COVID-19 patients, but it does not completely inhibit the inflammation and cytokine storm in all patients with COVID-19. In the clinical treatment of COVID-19 patients, attention should be paid to the timing of drug administration and other adjuvant treatments.

Key words: COVID-19; Cytokine storm; Tocilizumab; Interleukin-6

©The Author(s) 2020. Published by Baishideng Publishing Group Inc. All rights reserved.

Core tip: Tocilizumab treatment is effective against IL-6 in Coronavirus Disease 2019 (COVID-19) patients, but it does not completely inhibit the inflammation and cytokine storm in all patients with COVID-19. In the clinical treatment of COVID-19 patients, attention should be paid to the timing of drug administration and other adjuvant treatments.

Citation: Zeng J, Xie MH, Yang J, Chao SW, Xu EL. Clinical efficacy of tocilizumab treatment in severe and critical COVID-19 patients. *World J Clin Cases* 2020; 8(17): 3763-3773

URL: <https://www.wjgnet.com/2307-8960/full/v8/i17/3763.htm>

DOI: <https://dx.doi.org/10.12998/wjcc.v8.i17.3763>

INTRODUCTION

The global pandemic of Coronavirus Disease 2019 (COVID-19) is a serious threat to people's lives^[1,2]. Some studies^[3-5] have found that the main pathophysiological basis of COVID-19 causing respiratory failure and even hypoxic death, is immune cells released by mononuclear/macrophage cells after infection with the new coronavirus (SARS-CoV-2) in the blood which further activate the body's immune cells (such as monocytes, macrophages, T cells, B cells, etc.) or non-immune cells (such as endothelial cells), causing these cells to release a large number of cytokines (cytokine storm), thereby seriously destroying the ventilation function of lungs. Interleukin-6 (IL-6) is an important component of the COVID-19 cytokine storm. As a specific antagonist of IL-6, tocilizumab may block the cytokine storm in COVID-19 and prevent the severe to critical transition in patients. The Diagnosis and Treatment Guidelines of New Coronavirus Pneumonia (7th Edition) includes tocilizumab as a recommended drug for immunotherapy in patients with severe COVID-19^[6,7]. We analyzed the clinical data of 19 severe and critical COVID-19 patients who were treated with tocilizumab in Optical Valley Campus of Hubei Maternal and Child Health Care Hospital, in order to analyze the effect of tocilizumab on inhibition of the COVID-19 cytokine storm and provide a theoretical reference for the clinical treatment of patients with severe COVID-19.

MATERIALS AND METHODS

Case group

Inclusion criteria: The Guidelines of the 7th Edition were used for the diagnosis and

clinical classification of COVID-19^[8]. Patients were eligible if they met the following criteria: Age > 18 years, positive nucleic acid test, fever or respiratory symptoms, imaging findings of viral pneumonia, oxygen saturation (SaO₂) at rest less than 93% on admission, and IL-6 in peripheral blood > 30 pg/mL (upper limit of normal value: 10 pg/mL).

Exclusion criteria were as follows: (1) Previous medical history combined with organ transplantation and immune system diseases; (2) Pregnant or lactating women; (3) Suffering from mental illness; and (4) Disagree with treatment of tocilizumab.

In total, 19 severe and critical patients (12 males and 7 females, aged 55-94 years, median age: 76.00 ± 10.76 years, clinical classification at admission: 11 severe cases and 8 critical cases) with COVID-19 who met the above criteria were included in the study. This study conforms to the Declaration of Helsinki (2000) of the World Medical Association. All patients signed consent forms or their family members agreed by phone, and this was recorded. The clinical data were analyzed retrospectively.

Method

On the basis of routine treatment, all patients stopped immunoglobulin treatment for more than 3 d. The recommended dose of 8 mg/kg of tocilizumab (Roche Pharma Ltd., Switzerland) was diluted with 0.9% sodium chloride solution to 100 mL, protected from light, and intravenously infused for more than 1 h. Observation indices were as follows: (1) Chest computed tomography or chest radiography before and after tocilizumab treatment; and (2) Routine peripheral venous blood tests, routine blood biochemical tests, coagulation test, C-reactive protein (CRP), IL-6 and arterial blood gas analysis were carried out before and after tocilizumab treatment at 1 d, 3 d, 5 d, and 10 d, respectively.

According to the treatment process and final outcome of the included patients, patients were divided into the "effective group" and "ineffective group". The above observation indices in the two groups were then determined and a retrospective controlled study was carried out to analyze the specific therapeutic effect and the reasons for the differences in the therapeutic effect of tocilizumab in the treatment of COVID-19 patients. In addition, rational clinical application, timing of drug administration, observation items and auxiliary treatment were also investigated.

Statistical analysis

Statistical analysis of the data was performed using the SPSS 24.0 software package. Counted data were expressed as a percentage (%), and compared using the χ^2 test. Normally distributed continuous variables are presented as the mean ± SD, and skewed continuous variables are presented as the median (interquartile range). *t*-test was used to compare the mean values of two groups of measurement data with normal distribution and equal variances assumed, *t'*-test was used for equal variances not assumed; *One-Way ANOVA* was used to compare the mean values of the same item at different times in the same group. Comparisons of skewed distribution measurement data was performed by the Mann-Whitney *U* test or Kruskal-Wallis *H* test. In the correlation analysis of measurement data in accordance with skewed distribution, Spearman rank correlation was adopted. *P* < 0.05 represents a significant difference.

RESULTS

All 19 severe and critical COVID-19 patients underwent tocilizumab therapy. In 13 patients (68.4%), the symptoms were significantly improved, and 5 patients were discharged from hospital, 8 were transferred after improvement, 1 was transferred after exacerbation, treatment was ineffective in 1, and 4 patients died (21.1%). The patients who died all had critical COVID-19, including: 1 case of lung tumor with bone metastasis combined with pathological fracture which was suspected before admission, and the patient died of respiratory failure 2 d after tocilizumab treatment. One patient had COVID-19 combined with atrial fibrillation and pleural effusion, and died of respiratory failure 2 d after tocilizumab treatment. Two patients died of gastrointestinal bleeding on the 7th and 12th days after tocilizumab treatment. Thirteen cases with obvious improvement of symptoms were included in the "effective group". Six cases of invalid or worsening disease were included in the "ineffective group". Imaging examination showed that after treatment with tocilizumab, pulmonary viral pneumonia improved significantly in the effective group, and inflammation was absorbed (Figure 1 and Figure 2). However, the ineffective group showed that viral

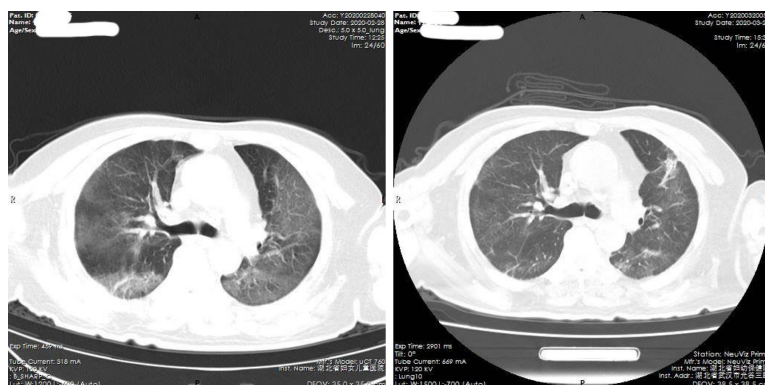


Figure 1 Improvement after tocilizumab treatment (computed tomography of the lung shows reduced lung inflammation).

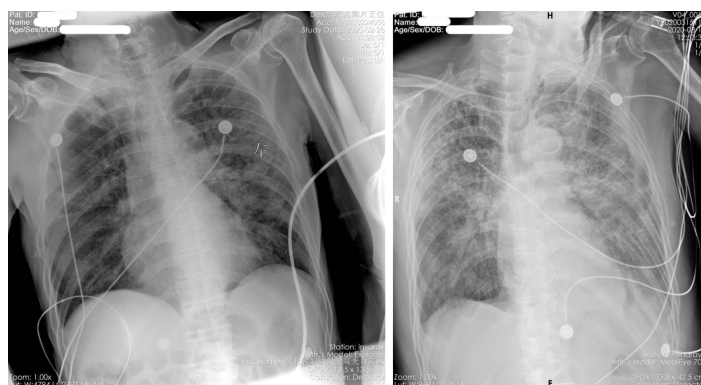


Figure 2 Chest radiography in a patient who subsequently died after tocilizumab treatment (bedside chest radiograph show increased inflammation and significantly increased exudation).

inflammation of the lung was obviously aggravated and exudation was increased.

Routine peripheral venous blood tests, routine blood biochemical tests, coagulation test, CRP, IL-6 and arterial blood gas were analyzed before and after treatment in the two groups (Table 1). The results showed that after tocilizumab treatment, the lymphocyte count and oxygenation index of the improved patients increased significantly, while CRP and FIB showed an overall downward trend. Although the levels of lactic acid and IL-6 temporarily increased, there was an overall decline. These findings showed that the cytokine storm and inflammation in COVID-19 patients can be controlled by tocilizumab treatment. However, the ineffective group showed that CRP was different to lactic acid, lactate dehydrogenase (LDH) and IL-6. CRP showed a general downward trend, while lactic acid, LDH and IL-6 showed an overall upward trend, which suggested that tocilizumab did not inhibit the cytokine storm in these patients.

The same factors were statistically analyzed between the two groups (Table 1). The results showed that the ineffective cases were significantly older than the effective cases, and most were critical, with more bacterial infections and hypercoagulable states. The patients who improved were admitted with less serious illness than those who failed. After tocilizumab treatment, the lymphocytes and oxygenation index in the ineffective group not only did not increase significantly, but showed a downward trend. However, CRP, LDH and IL-6 levels in these patients were statistically significantly higher than in those who improved.

Oxygen therapy in this group of patients consisted of invasive ventilator therapy during treatment in 8 patients (42.1%), high-flow oxygen therapy in 16 (84.2%), and noninvasive ventilator therapy in 3 (15.7%). Following tocilizumab treatment, the changes in patients' oxygen therapy are shown in Figure 3. Among the 14 patients who underwent high-flow oxygen therapy before tocilizumab treatment, 10 patients (71.4%) improved. The improvement rate of invasive ventilator therapy before and after tocilizumab treatment was only 33.3%. During the course of treatment, of the 8 patients who underwent invasive ventilator therapy, 2 cases were treated with extracorporeal membrane oxygenation and were successfully weaned from the

Table 1 General information on patients and laboratory test results before and after treatment with tocilizumab

Group	Age (yr)	M:F	Critical: severe	Laboratory test items	Before treatment	1 st day after treatment	3 rd day after treatment	5 th day after treatment	10 th day after treatment	Statistical value	P value
Effective	55-94 (74 ± 10.66)	9:4	3:10	SaO ₂ (%)	80-93 (86.38 ± 5.21)						
				Lymphocyte (× 10 ⁹ /L)	0.30-1.56 (0.67 ± 0.33)	0.51-2.07 (0.92 ± 0.49)	0.29-1.75 (0.90 ± 0.52)	0.59-1.91 (1.20 ± 0.46)	0.58-2.38 (1.32 ± 0.57)	3.76	0.0085
				WBC (× 10 ⁹ /L)	3.5-15.1 (9.47 ± 4.11)	5.1-13.7 (8.8 ± 3.25)	3.4-19.7 (9.08 ± 4.72)	3.3-21.6 (9.13 ± 5.40)	3.7-17.7 (9.6 ± 5.35)	0.06	0.9927
				PLT (× 10 ⁹ /L)	80-456 (220.92 ± 110.19)	70-396 (226.55 ± 115.44)	54-370 (192.4 ± 96.51)	53-384 (226.25 ± 112.38)	46-324 (208.1 ± 77.42)	0.26	0.9026
				CRP (mg/L)	10.85-235.29 (63.76 ± 67.83)	4.43-231.35 (63.31 ± 64.77)	3.83-99.75 (23.36 ± 30.93)	1.03-15.33 (6.11 ± 4.44)	0.14-14.61 (2.42 ± 4.33)	5.91	0.0004
				Lactic acid (mmol/L)	1.10-6.20 (2.65 ± 1.38)	1.10-2.10 (1.72 ± 0.41)	1.40-3.20 (2.28 ± 0.82)	1.40-5.80 (3.12 ± 1.81)	0.40-2.50 (1.45 ± 1.48)	3.64	0.0102
				LDH (U/L)	187-633 (356 ± 198.2)	206-609 (333.8 ± 166.38)	207-949 (421.5 ± 353.52)	185-1085 (391.8 ± 388.05)	192-520 (269.75 ± 168.68)	0.59	0.6704
				Oxygenation index (mmHg)	67-300 (166 ± 67.13)	98-385 (204.08 ± 94.22)	98-395 (231.17 ± 93.95)	122-380 (254.25 ± 79.4)	216-397 (327.42 ± 62.02)	7.35	0.0001
				FIB (g/L)	2.05-9.46 (4.84 ± 2.09)	3.55-4.57 (3.9 ± 0.39)	1.16-4.66 (3.1 ± 1.29)	1.41-5.64 (2.88 ± 1.29)	0.97-2.13 (1.5 ± 0.37)	12.56	0.0000
				IL-6 (pg/mL)	30.37-609.36 (107.17 ± 154.91)	36.59-12600.94 (1793.42 ± 3675.7)	73.80-7295.1 (1286.84 ± 2291.07)	24.05-2502.67 (541.42 ± 687.93)	14-1109.47 (286.33 ± 342.37)	11.71	0.0016
Ineffective	57-88 (83 ± 11.93) ¹	4:2	5:1 ¹	D-dimer (mg/L)	0.98-12.21 (3.5 ± 3.71)	0.66-26.11 (5.62 ± 10.09)	0.78-20.26 (5.75 ± 6.73)	0.73-29.48 (6.4 ± 9.53)	1.28-4.2 (2.2 ± 0.89)	0.81	0.5260
				SaO ₂ (%)	70-88 (77.67 ± 8.89) ¹						
				Lymphocyte (× 10 ⁹ /L)	0.15-1.74 (0.69 ± 0.56)	0.08-1.59 (0.68 ± 0.59)	0.36-0.17 (0.41 ± 0.27) ¹	0.18-0.98 (0.62 ± 0.4) ¹	0.29-0.66 (0.5 ± 0.15) ¹	0.29	0.8816
				WBC (× 10 ⁹ /L)	3.7-26.0 (10.68 ± 8.02)	2.9-22.1 (9.92 ± 8.72)	4-11.8 (8.33 ± 3.71)	7.5-10.3 (9.03 ± 1.49)	4.7-14.1 (8 ± 4.22)	0.21	0.9290
				PLT (× 10 ⁹ /L)	41-338 (160.67 ± 102.66)	11-313 (153.8 ± 110.39)	113-301 (171.5 ± 84.47)	76-287 (137.65 ± 100.42)	40-276 (147.75 ± 98.65)	0.10	0.9817
				CRP (mg/L)	39.78-241.53 (122.8 ± 83.7)	34.65-254.52 (98.38 ± 90.03)	9.51-20.89 (15.44 ± 5.26)	7.45-11.86 (9.08 ± 1.52)	3.2-53.33 (17.05 ± 24.22) ¹	5.51	0.0025
				Lactic acid (mmol/L)	1.1-3.4 (2.38 ± 0.96)	1.7-2.36 (2.09 ± 0.34)	Untested	Untested	12.58 (12.58) ¹	194.84	0.0000
				LDH (U/L)	203-345 (274 ± 100.41)	275-338 (306.5 ± 44.55)	320-542 (427.33 ± 111.18)	308-687 (497.5 ± 267.99)	488-673 (580.5 ± 130.82) ¹	4.37	0.0082
				Oxygenation index (mmHg)	51-180 (106.34 ± 52.53)	59.1-266 (137.02 ± 83.46)	82-283 (185 ± 82.13)	94-200 (141.75 ± 45.49) ¹	84-200 (124.5 ± 53.12) ¹	1.20	0.3374
				FIB (g/L)	1.59-4.87 (3.77 ± 1.26)	1.34-3.21 (2.48 ± 1)	0.85-5.29 (2.68 ± 2.32)	1.09-3.1 (1.82 ± 0.93)	0.88-2.4 (1.42 ± 0.85)	1.77	0.1817
				IL-6 (pg/mL)	30.63-157.08 (78.27 ± 43.81)	167.08-2124.42 (878.54 ± 911.52) ¹	559.96-23138.48 (6644.37 ± 11006.23) ¹	990.81-2725.70 (1703.35 ± 907.99) ¹	44.95-50000 (20562.42 ± 26144.85) ¹	3.01	0.0478

D-Dimer (mg/L)	0.40-53.81 (11.63 ± 20.8) ¹	1.29-69.56 (29.7 ± 35.55) ¹	3.16-24.6 (10.91 ± 11.89)	5.44-15.63 (9.81 ± 6.74)	1.75-6.88 (4.06 ± 2.6)	0.83	0.5223
----------------	--	--	---------------------------	--------------------------	------------------------	------	--------

¹Comparison between the two groups of the same item (*P* < 0.05). WBC: White blood cell; PLT: Platelet; CRP: C-reactive protein; IL-6: Interleukin-6.

machine to the invasive ventilator, 3 cases improved and changed to a non-invasive ventilator, and 2 patients with infection resumed invasive ventilator therapy (Table 2). These findings suggest that the improvement rate after oxygen therapy was closely related to the patient's basic condition.

DISCUSSION

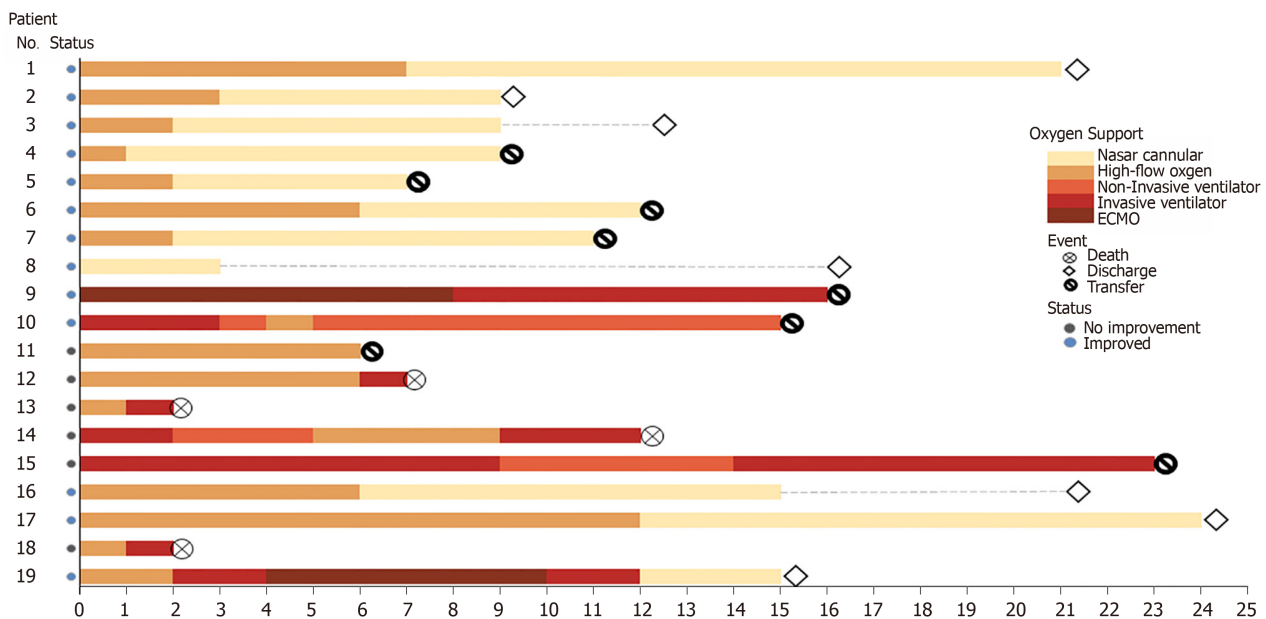
It has been reported that SARS-CoV-2 enters lung cells through endocytosis mediated by the ACE2 receptor, proliferates in large quantities, and releases more virus by budding or inducing programmed cell death^[9,10]. After being recognized by the pattern recognition receptor on the body's immune cells, a large number of cytokines are released through signal transduction to activate more immune cells to participate in virus clearance, thus forming a cytokine storm. The over-activated immune system will certainly kill a large number of normal lung cells, seriously destroy the ventilation function of the lung, leading to respiratory failure, and death due to hypoxia. The cytokine storm caused by COVID-19 is mainly related to IL-1B, IL-6, IL-12, interferon γ , interferon-gamma-inducible protein-10 and monocyte chemotactic protein-1. The expression of IL-6 is greater than that of tumor necrosis factor- α and IL-1. A high concentration of IL-6 can induce various pathological functions related to thrombosis, vascular leakage and myocardial dysfunction, resulting in tissue hypoxia, hypotension, multiple organ dysfunction and disseminated intravascular coagulation. Therefore, IL-6 is generally used as a biomarker of disease severity and prognosis in the COVID-19 cytokine storm. In this study, the lymphocyte count, white blood cell count, platelets, lactic acid, LDH, FIB, IL-6 and D-dimer were selected as the observation indices.

In the present study, we found that most of the patients with COVID-19 had a reduced IL-6 level and inflammation indices after treatment with tocilizumab, and the results of pulmonary imaging showed that inflammation had improved. However, 8 patients showed an abnormal elevation of IL-6 (> 1000) 3 d after tocilizumab administration, and all showed disease aggravation, especially an increase in lung inflammation and exudation. Four of these patients died. This suggests that the source of inflammation in patients with COVID-19 is not only due to the virus infection, but also due to secondary infection and other factors. Inhibition of IL-6 by tocilizumab alone does not completely inhibit all inflammation and the cytokine storm in patients with COVID-19. Targeted treatment and other adjuvant therapy measures should also

Table 2 Improvement of oxygen therapy in patients before and after tocilizumab treatment

		The number of patients before treatment with tocilizumab			
		ECMO (n = 1)	Invasive ventilator (n = 3)	High flow oxygen (n = 14)	Nasal catheter oxygen (n = 1)
Number of patients after treatment with tocilizumab	Death	0	1	3	0
	ECMO	0	0	0	0
	Invasive ventilator	1	1	0	0
	Noninvasive ventilator	0	1	0	0
	High flow oxygen	0	0	1	0
	Nasal catheter oxygen	0	0	6	0
	Non oxygen inhalation	0	0	4	1
	Improved	1 (100%)	1 (33.3%)	10 (71.4%)	1 (100%)

ECMO: Extracorporeal membrane oxygenation.

**Figure 3 Oxygen therapy and curative effect in 19 patients with Coronavirus Disease 2019.**

be introduced to inhibit the inflammatory response. Therefore, we administered methylprednisolone 40-80 mg/d on the basis of tocilizumab inhibition of IL-6 treatment, by intravenous drip for 3-5 d, supplemented with DFPP plasma exchange to clear inflammatory factors, or infusion of plasma from patients who had recovered from COVID-19, or intravenous infusion of ulinastatin and other measures, which ultimately significantly improved the condition of these patients. Therefore, in the clinical treatment of COVID-19 patients, the changes in relevant inflammatory indices should be closely monitored. If the cytokine storm cannot be inhibited, we should timely identify other causes of the inflammatory cascade for targeted treatment, with additional treatment measures in order to avoid missing the opportunity of treatment. In this group, we found that the therapeutic effect of tocilizumab was not so good in elderly critical patients. Therefore, tocilizumab should be administered as much as possible before the patient develops serious secondary complications. Otherwise, if the best opportunity of treatment is missed, the clinical effect will be limited.

Cytokine storm is an excessive immune phenomenon produced by the body due to external stimuli. Unrestricted mass release of cytokines leads to systemic

inflammation. Infections can trigger cytokine storms, but many diseases can also induce cytokine storms. It has been reported that the level of IL-6 in patients with COVID-19 does not decrease but increases after tocilizumab treatment^[11-13]. The higher the IL-6 level, the worse the prognosis. We also found that the level of IL-6 in all cases increased significantly on the 1st day and the 3rd day after tocilizumab treatment, while the level of IL-6 in improved patients decreased significantly, but still increased significantly in the ineffective group. This is consistent with the above report. These findings suggest that the source of IL-6 may not only be due to the virus infection, but also due to other complications such as secondary bacterial infection. The side effects of tocilizumab include coagulation dysfunction and severe hypoxemia, which may endanger the life of patients. The 4 patients who died all had significantly increased IL-6 after tocilizumab treatment and 2 of these patients died of respiratory failure, and the other 2 died of gastrointestinal bleeding. Is it not known whether gastrointestinal bleeding is a side effect of tocilizumab and is worthy of vigilance and further investigation (Figure 4).

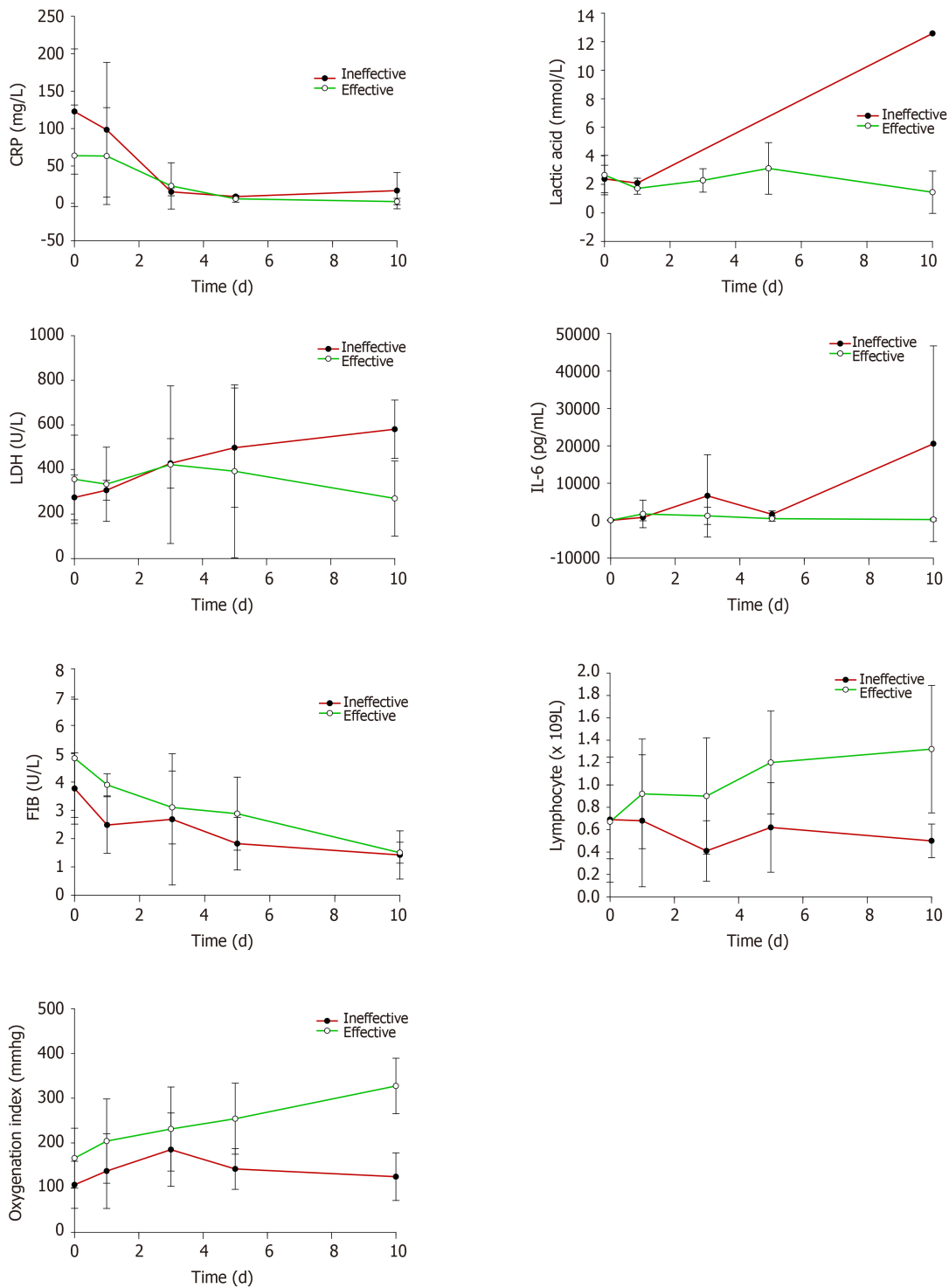


Figure 4 Trend in each test index between the effective group and ineffective group.

ARTICLE HIGHLIGHTS

Research background

The main pathophysiological basis of Coronavirus disease 2019 (COVID-19) causing respiratory failure, is the cytokine storm, and interleukin-6 (IL-6) is an important component of the COVID-19 cytokine storm. As a specific antagonist of IL-6, tocilizumab may block the cytokine storm in COVID-19.

Research motivation

The Diagnosis and Treatment Guidelines of New Coronavirus Pneumonia (7th Edition) includes tocilizumab as a recommended drug for immunotherapy in severe COVID-19

patients. However, the specific clinical efficacy of tocilizumab in the treatment of COVID-19 is worth studying.

Research objectives

This study aimed to determine the clinical efficacy of tocilizumab in inhibiting the cytokine storm in COVID-19.

Research methods

In total, 19 severe and critical COVID-19 patients who were treated with tocilizumab were included in this study. The imaging manifestations and the clinical data before and after treatment were analyzed retrospectively, including routine peripheral venous blood tests, routine blood biochemical tests, coagulation test, C-reactive protein (CRP), IL-6, and arterial blood gas analysis.

Research results

Of the 19 patients in this group, 13 (68.4%) had significantly improved symptoms of COVID-19 (5 patients were discharged directly and 8 patients were transferred after improvement). One case was invalid, 1 case was exacerbated, and 4 deaths (21.1%) all critical cases were observed. The lymphocyte count, CRP, lactic acid, oxygenation index, FIB and IL-6 levels were significantly different in the improved group.

Research conclusions

Tocilizumab treatment is effective against IL-6 in COVID-19 patients, but it does not completely inhibit the inflammation and cytokine storm in all patients with COVID-19. In the clinical treatment of patients, attention should be paid to the timing of drug administration and other adjuvant treatments.

Research perspectives

In this study, we found that most of the patients with COVID-19 had reduced IL-6 levels and inflammation indices following treatment with tocilizumab, however, the therapeutic effect of tocilizumab is not so good in elderly critical patients. Therefore, we should administer tocilizumab as much as possible before patients develop serious secondary complications. Otherwise, if the best opportunity of treatment is missed, the clinical effect will be limited.

REFERENCES

- 1 **Lipsitch M**, Swerdlow DL, Finelli L. Defining the Epidemiology of Covid-19 - Studies Needed. *N Engl J Med* 2020; **382**: 1194-1196 [PMID: 32074416 DOI: 10.1056/NEJMp2002125]
- 2 **Hu Y**, Sun J, Dai Z, Deng H, Li X, Huang Q, Wu Y, Sun L, Xu Y. Prevalence and severity of corona virus disease 2019 (COVID-19): A systematic review and meta-analysis. *J Clin Virol* 2020; **127**: 104371 [PMID: 32315817 DOI: 10.1016/j.jcv.2020.104371]
- 3 **Choudhury R**, Barrett CD, Moore HB, Moore EE, McIntyre RC, Moore PK, Talmor DS, Nydam TL, Yaffe MB. Salvage use of tissue plasminogen activator (tPA) in the setting of acute respiratory distress syndrome (ARDS) due to COVID-19 in the USA: a Markov decision analysis. *World J Emerg Surg* 2020; **15**: 29 [PMID: 32312290 DOI: 10.1186/s13017-020-00305-4]
- 4 **Gattinoni L**, Chiumello D, Rossi S. COVID-19 pneumonia: ARDS or not? *Crit Care* 2020; **24**: 154 [PMID: 32299472 DOI: 10.1186/s13054-020-02880-z]
- 5 **Chiappelli F**, Khakshooy A, Greenberg G. CoViD-19 Immunopathology and Immunotherapy. *Bioinformation* 2020; **16**: 219-222 [PMID: 32308263 DOI: 10.6026/97320630016219]
- 6 **Buonaguro FM**, Puzanov I, Ascierto PA. Anti-IL6R role in treatment of COVID-19-related ARDS. *J Transl Med* 2020; **18**: 165 [PMID: 32290847 DOI: 10.1186/s12967-020-02333-9]
- 7 **Fu B**, Xu X, Wei H. Why tocilizumab could be an effective treatment for severe COVID-19? *J Transl Med* 2020; **18**: 164 [PMID: 32290839 DOI: 10.1186/s12967-020-02339-3]
- 8 **Yang H**, Sun G, Tang F, Peng M, Gao Y, Peng J, Xie H, Zhao Y, Jin Z. Clinical features and outcomes of pregnant women suspected of coronavirus disease 2019. *J Infect* 2020; **81**: e40-e44 [PMID: 32294503 DOI: 10.1016/j.jinf.2020.04.003]
- 9 **Cure E**, Cumhur Cure M. Angiotensin-converting enzyme inhibitors and angiotensin receptor blockers may be harmful in patients with diabetes during COVID-19 pandemic. *Diabetes Metab Syndr* 2020; **14**: 349-350 [PMID: 32311651 DOI: 10.1016/j.dsx.2020.04.019]
- 10 **Li G**, He X, Zhang L, Ran Q, Wang J, Xiong A, Wu D, Chen F, Sun J, Chang C. Assessing ACE2 expression patterns in lung tissues in the pathogenesis of COVID-19. *J Autoimmun* 2020; **112**: 102463 [PMID: 32303424 DOI: 10.1016/j.jaut.2020.102463]
- 11 **Ceribelli A**, Motta F, De Santis M, Ansari AA, Ridgway WM, Gershwin ME, Selmi C. Recommendations for coronavirus infection in rheumatic diseases treated with biologic therapy. *J Autoimmun* 2020; **109**: 102442 [PMID: 32253068 DOI: 10.1016/j.jaut.2020.102442]
- 12 **Zhang X**, Song K, Tong F, Fei M, Guo H, Lu Z, Wang J, Zheng C. First case of COVID-19 in a patient with

- multiple myeloma successfully treated with tocilizumab. *Blood Adv* 2020; **4**: 1307-1310 [PMID: [32243501](#) DOI: [10.1182/bloodadvances.2020001907](#)]
- 13 **Michot JM**, Albiges L, Chaput N, Saada V, Pommeret F, Griscelli F, Balleyguier C, Besse B, Marabelle A, Netzer F, Merad M, Robert C, Barlesi F, Gachot B, Stoclin A. Tocilizumab, an anti-IL-6 receptor antibody, to treat COVID-19-related respiratory failure: a case report. *Ann Oncol* 2020; **31**: 961-964 [PMID: [32247642](#) DOI: [10.1016/j.annonc.2020.03.300](#)]



Published by **Baishideng Publishing Group Inc**
7041 Koll Center Parkway, Suite 160, Pleasanton, CA 94566, USA

Telephone: +1-925-3991568

E-mail: bpgoffice@wjgnet.com

Help Desk: <https://www.f6publishing.com/helpdesk>

<https://www.wjgnet.com>

