

World Journal of *Clinical Cases*

World J Clin Cases 2020 September 6; 8(17): 3621-3919



Contents

Semimonthly Volume 8 Number 17 September 6, 2020

REVIEW

- 3621 Autoimmunity as the comet tail of COVID-19 pandemic
Talotta R, Robertson E
- 3645 Gender medicine: Lessons from COVID-19 and other medical conditions for designing health policy
Machluf Y, Chaïter Y, Tal O

MINIREVIEWS

- 3669 Complexities of diagnosis and management of COVID-19 in autoimmune diseases: Potential benefits and detriments of immunosuppression
Georgiev T, Angelov AK

ORIGINAL ARTICLE

Retrospective Study

- 3679 Incidental anal ¹⁸fluorodeoxyglucose uptake: Should we further examine the patient?
Moussaddaq AS, Brochard C, Palard-Novello X, Garin E, Wallenhorst T, Le Balc'h E, Merlini L'heritier A, Grainville T, Siproudhis L, Lièvre A
- 3691 Emergency surgery in COVID-19 outbreak: Has anything changed? Single center experience
D'Urbano F, Fabbri N, Koleva Radica M, Rossin E, Carcoforo P
- 3697 Somatostatin receptor scintigraphy in the follow up of neuroendocrine neoplasms of appendix
Saponjski J, Macut D, Sobic-Saranovic D, Ognjanovic S, Bozic Antic I, Pavlovic D, Artiko V
- 3708 Efficacy of stool multiplex polymerase chain reaction assay in adult patients with acute infectious diarrhea
Ahn JS, Seo SI, Kim J, Kim T, Kang JG, Kim HS, Shin WG, Jang MK, Kim HY
- 3718 Comparison of gemcitabine plus nab-paclitaxel and FOLFIRINOX in metastatic pancreatic cancer
Han SY, Kim DU, Seol YM, Kim S, Lee NK, Hong SB, Seo HI
- 3730 Shear wave elastography may be sensitive and more precise than transient elastography in predicting significant fibrosis
Yao TT, Pan J, Qian JD, Cheng H, Wang Y, Wang GQ
- 3743 Radioactive ¹²⁵I seed implantation for locally advanced pancreatic cancer: A retrospective analysis of 50 cases
Li CG, Zhou ZP, Jia YZ, Tan XL, Song YY
- 3751 Active surveillance in metastatic pancreatic neuroendocrine tumors: A 20-year single-institutional experience
Gao HL, Wang WQ, Xu HX, Wu CT, Li H, Ni QX, Yu XJ, Liu L

- 3763** Clinical efficacy of tocilizumab treatment in severe and critical COVID-19 patients

Zeng J, Xie MH, Yang J, Chao SW, Xu EL

- 3774** Phosphatidylinositol-3,4,5-trisphosphate dependent Rac exchange factor 1 is a diagnostic and prognostic biomarker for hepatocellular carcinoma

Cai Y, Zheng Q, Yao DJ

Observational Study

- 3786** Awareness and attitude of fecal microbiota transplantation through transendoscopic enteral tubing among inflammatory bowel disease patients

Zhong M, Sun Y, Wang HG, Marcella C, Cui BT, Miao YL, Zhang FM

CASE REPORT

- 3797** Cauda equina arachnoiditis – a rare manifestation of West Nile virus neuroinvasive disease: A case report

Santini M, Zupetic I, Viskovic K, Krznaric J, Kutlesa M, Krajinovic V, Polak VL, Savic V, Tabain I, Barbic L, Bogdanic M, Stevanovic V, Mrzljak A, Vilibic-Cavlek T

- 3804** Portal gas in neonates; is it always surgical? A case report

Altokhais TI

- 3808** Large lingual heterotopic gastrointestinal cyst in a newborn: A case report

Lee AD, Harada K, Tanaka S, Yokota Y, Mima T, Enomoto A, Kogo M

- 3814** Osteochondral lesion of talus with gout tophi deposition: A case report

Kim T, Choi YR

- 3821** Traumatic neuroma of remnant cystic duct mimicking duodenal subepithelial tumor: A case report

Kim DH, Park JH, Cho JK, Yang JW, Kim TH, Jeong SH, Kim YH, Lee YJ, Hong SC, Jung EJ, Ju YT, Jeong CY, Kim JY

- 3828** Autoimmune hepatitis in a patient with immunoglobulin A nephropathy: A case report

Jeon YH, Kim DW, Lee SJ, Park YJ, Kim HJ, Han M, Kim IY, Lee DW, Song SH, Lee SB, Seong EY

- 3835** Diagnosis of an actively bleeding brachial artery hematoma by contrast-enhanced ultrasound: A case report

Ma JJ, Zhang B

- 3841** Lung adenocarcinoma harboring rare epidermal growth factor receptor L858R and V834L mutations treated with icotinib: A case report

Zhai SS, Yu H, Gu TT, Li YX, Lei Y, Zhang HY, Zhen TH, Gao YG

- 3847** Gastroduodenitis associated with ulcerative colitis: A case report

Yang Y, Li CQ, Chen WJ, Ma ZH, Liu G

- 3853** Majocchi's granuloma caused by *Trichophyton rubrum* after facial injection with hyaluronic acid: A case report

Liu J, Xin WQ, Liu LT, Chen CF, Wu L, Hu XP

- 3859** Novel deletion mutation in Bruton's tyrosine kinase results in X-linked agammaglobulinemia: A case report
Hu XM, Yuan K, Chen H, Chen C, Fang YL, Zhu JF, Liang L, Wang CL
- 3867** Multidisciplinary treatment of life-threatening hemoptysis and paraplegia of choriocarcinoma with pulmonary, hepatic and spinal metastases: A case report
Lin YY, Sun Y, Jiang Y, Song BZ, Ke LJ
- 3875** Diagnostic value of ultrasound in the spontaneous rupture of renal angiomyolipoma during pregnancy: A case report
Zhang T, Xue S, Wang ZM, Duan XM, Wang DX
- 3881** Gallbladder sarcomatoid carcinoma: Seven case reports
Qin Q, Liu M, Wang X
- 3890** Surgical strategy used in multilevel cervical disc replacement and cervical hybrid surgery: Four case reports
Wang XF, Meng Y, Liu H, Hong Y, Wang BY
- 3903** Diagnosis and treatment of an elderly patient with 2019-nCoV pneumonia and acute exacerbation of chronic obstructive pulmonary disease in Gansu Province: A case report
He TP, Wang DL, Zhao J, Jiang XY, He J, Feng JK, Yuan Y
- 3911** Diagnosis and treatment of mixed infection of hepatic cystic and alveolar *echinococcosis*: Four case reports
A JD, Chai JP, Wang H, Gao W, Peng Z, Zhao SY, A XR

ABOUT COVER

Editorial board member of World Journal of Clinical Cases, Dr. Elia de Maria is Adjunct Professor of Arrhythmology Lab in the Cardiology Unit, Ramazzini Hospital in Carpi, Italy. He graduated in Medicine and Surgery from the University of Napoli in 1999, continuing on to obtain specialization in Cardiology in 2003. He also holds the distinction of High Degree Master in Electrophysiology and Cardiac Stimulation. Since 2005, he has practiced as a Permanent Consultant Cardiologist in the Italian Public Hospitals, and since 2015 as an External Contract Professor in the Faculty of Medicine and Surgery of University of Verona. His clinical and research interests encompass pharmacological therapy in acute and chronic cardiac conditions, temporary and definitive pacing, thoracentesis and pericardiocentesis, and hemodynamic monitoring. (L-Editor: Filipodia)

AIMS AND SCOPE

The primary aim of *World Journal of Clinical Cases* (WJCC, *World J Clin Cases*) is to provide scholars and readers from various fields of clinical medicine with a platform to publish high-quality clinical research articles and communicate their research findings online.

WJCC mainly publishes articles reporting research results and findings obtained in the field of clinical medicine and covering a wide range of topics, including case control studies, retrospective cohort studies, retrospective studies, clinical trials studies, observational studies, prospective studies, randomized controlled trials, randomized clinical trials, systematic reviews, meta-analysis, and case reports.

INDEXING/ABSTRACTING

The WJCC is now indexed in Science Citation Index Expanded (also known as SciSearch®), Journal Citation Reports/Science Edition, PubMed, and PubMed Central. The 2020 Edition of Journal Citation Reports® cites the 2019 impact factor (IF) for WJCC as 1.013; IF without journal self cites: 0.991; Ranking: 120 among 165 journals in medicine, general and internal; and Quartile category: Q3.

RESPONSIBLE EDITORS FOR THIS ISSUE

Production Editor: Yan-Xia Xing; Production Department Director: Yun-Xiaojian Wu; Editorial Office Director: Jin-Lai Wang.

NAME OF JOURNAL

World Journal of Clinical Cases

ISSN

ISSN 2307-8960 (online)

LAUNCH DATE

April 16, 2013

FREQUENCY

Semimonthly

EDITORS-IN-CHIEF

Dennis A Bloomfield, Sandro Vento, Bao-Gan Peng

EDITORIAL BOARD MEMBERS

<https://www.wjgnet.com/2307-8960/editorialboard.htm>

PUBLICATION DATE

September 6, 2020

COPYRIGHT

© 2020 Baishideng Publishing Group Inc

INSTRUCTIONS TO AUTHORS

<https://www.wjgnet.com/bpg/gerinfo/204>

GUIDELINES FOR ETHICS DOCUMENTS

<https://www.wjgnet.com/bpg/GerInfo/287>

GUIDELINES FOR NON-NATIVE SPEAKERS OF ENGLISH

<https://www.wjgnet.com/bpg/gerinfo/240>

PUBLICATION ETHICS

<https://www.wjgnet.com/bpg/GerInfo/288>

PUBLICATION MISCONDUCT

<https://www.wjgnet.com/bpg/gerinfo/208>

ARTICLE PROCESSING CHARGE

<https://www.wjgnet.com/bpg/gerinfo/242>

STEPS FOR SUBMITTING MANUSCRIPTS

<https://www.wjgnet.com/bpg/GerInfo/239>

ONLINE SUBMISSION

<https://www.f6publishing.com>



Gallbladder sarcomatoid carcinoma: Seven case reports

Qing Qin, Ming Liu, Xin Wang

ORCID number: Qing Qin 0000-0003-3618-9354; Ming Liu 0000-0002-8662-3190; Xin Wang 0000-0001-6315-8831.

Author contributions: Qin Q collected the data and contributed to drafting the manuscript; Liu M critically revised the manuscript; Wang X designed the case report presentation. All authors have read and approved the final version to be published.

Informed consent statement:

Informed written consent was obtained from the patients for publication of this report and any accompanying images.

Conflict-of-interest statement:

There are no conflicts of interest for this study.

CARE Checklist (2016) statement:

The authors have read the CARE Checklist (2016), and the manuscript was prepared and revised according to the CARE Checklist (2016).

Open-Access: This article is an open-access article that was selected by an in-house editor and fully peer-reviewed by external reviewers. It is distributed in accordance with the Creative Commons Attribution NonCommercial (CC BY-NC 4.0) license, which permits others to distribute, remix, adapt, build upon this work non-commercially,

Qing Qin, Ming Liu, Department of Medical Oncology, Cancer Center, West China Hospital, Sichuan University, Chengdu 610041, Sichuan Province, China

Qing Qin, Department of Oncology, Chengdu Shangjin Nanfu Hospital, Chengdu 611730, Sichuan Province, China

Xin Wang, Department of Abdominal Oncology, Department of Radiation Oncology, Cancer Center, West China Hospital, Sichuan University, Chengdu 610041, Sichuan Province, China

Corresponding author: Xin Wang, PhD, Professor, Department of Abdominal Oncology, Department of Radiation Oncology, Cancer Center, West China Hospital, Sichuan University, No.37 Guoxue Alley, Chengdu 610041, Sichuan Province, China. wangxinhuaxi@126.com

Abstract

BACKGROUND

Gallbladder sarcomatoid carcinoma is a rare and aggressive tumor, and little is known about its clinical behavior, prognosis, and optimal treatment.

CASE SUMMARY

From 1997 to 2017, we collected seven cases of gallbladder sarcomatoid carcinoma at our institution. The median patient age was 68.5 years. Six (85.7%) patients were female. Overall, 85.7% (6/7) of the tumors had a maximal diameter greater than 7 cm. Late TNM stage was associated with a significantly poor prognosis. All patients with advanced-stage (III/IV) disease died from metastases or disease progression shortly after surgery. One patient with stage IIIB disease who received adjuvant chemoradiotherapy (gemcitabine and capecitabine) achieved a progression-free survival (PFS) of 12 mo and overall survival of 15 mo, which might be the longest PFS reported among patients who ultimately experienced recurrence or metastasis.

CONCLUSION

Sarcomatoid carcinoma is a unique and aggressive gallbladder malignancy. Surgery is suggested as the first and only recognized treatment. There is a significant difference in prognosis between patients with early-stage and advanced-stage disease. Postoperative adjuvant therapy may bring survival benefits for locally advanced patients. Gemcitabine combined with fluorouracil and radiotherapy could be a potential strategy.

Key words: Gallbladder neoplasm; Sarcomatoid carcinoma; Adjuvant therapy; Case report

©The Author(s) 2020. Published by Baishideng Publishing Group Inc. All rights reserved.

and license their derivative works on different terms, provided the original work is properly cited and the use is non-commercial. See: <http://creativecommons.org/licenses/by-nc/4.0/>

Manuscript source: Unsolicited manuscript

Received: March 25, 2020

Peer-review started: March 25, 2020

First decision: June 8, 2020

Revised: June 21, 2020

Accepted: August 13, 2020

Article in press: August 13, 2020

Published online: September 6, 2020

P-Reviewer: Filippou D, Kai K

S-Editor: Zhang H

L-Editor: Wang TQ

P-Editor: Li JH



Core tip: From 1997 to 2017, we collected seven cases of gallbladder sarcomatoid carcinoma at our institution. By reporting these cases, this paper will enrich the clinical information of this rare tumor. TNM stage seemed to be a highly important prognostic indicator. There was a significant difference in prognosis between patients with early-stage and advanced-stage disease. For the first time, we report a patient treated with postoperative adjuvant therapy who achieved a progression-free survival for up to 12 mo. This approach may provide a potential strategy for gallbladder sarcomatoid carcinoma, which is a kind of rare and aggressive tumor with no standard treatment to date.

Citation: Qin Q, Liu M, Wang X. Gallbladder sarcomatoid carcinoma: Seven case reports.

World J Clin Cases 2020; 8(17): 3881-3889

URL: <https://www.wjgnet.com/2307-8960/full/v8/i17/3881.htm>

DOI: <https://dx.doi.org/10.12998/wjcc.v8.i17.3881>

INTRODUCTION

Gallbladder cancer is the fifth most common malignancy of the gastrointestinal tract^[1]. It is also the most aggressive cancer of the biliary tract with the shortest median survival time^[2]. Adenocarcinoma is the most common type, while sarcomatoid carcinoma is rare and even more aggressive than other pathological types. Gallbladder sarcomatoid carcinoma accounts for only 4.3% of gallbladder cancers^[3] and has often been confused with carcinosarcoma in previous reports. If we exclude the reports that may have confused sarcomatoid carcinoma and carcinosarcoma, there are approximately 20 cases of sarcomatoid carcinoma of the gallbladder described in the English-language literature worldwide^[3-8]. Because of the rarity of this tumor, little is known about its clinical behavior, prognosis, and optimal treatment.

Despite rapid advances in surgery, chemotherapy, radiotherapy, and biomedicine in the past several decades, gallbladder cancer remains an invasive cancer with a discouraging prognosis, and there is no standard treatment for gallbladder sarcomatoid carcinoma^[9]. Surgery is suggested as the main and only recognized treatment for sarcomatoid carcinoma of the gallbladder^[6]. However, even with radical excision, patients still develop recurrence quickly, and postoperative adjuvant treatment might be necessary^[6]. However, there is no standard adjuvant treatment, and only a few patients have received adjuvant chemotherapy in previous reports with unfavorable results^[3].

To enrich this information, we retrospectively reviewed the data of patients with gallbladder sarcomatoid carcinoma at our institution over the past 20 years. We found seven patients, among whom one treated with chemoradiotherapy after surgery achieved a progression-free survival (PFS) of 12 mo and overall survival (OS) of 15 mo, which might be the longest PFS reported among patients who ultimately experienced recurrence or metastasis.

CASE PRESENTATION

Chief complaints

A total of seven patients were diagnosed with gallbladder sarcomatoid carcinoma and treated at our institution from 1997 to 2017. The median age was 68.5 years (ranging from 50 to 83 years). Six patients were female, and only one was male. All seven patients presented to hospital complaining of abdominal pain.

History of present illness

Although the duration of abdominal pain prior to admission ranged between 20 d and 4 years, the majority (71.4%) experienced pain for less than 2 mo (Table 1).

History of past illness

Case 1 and case 6 had undergone inguinal herniorrhaphy and appendectomy respectively. Case 2 had a history of hypertension.

Table 1 Chief complaints

Characteristic	No recurrence		Recurrence or metastasis				
	Case 1	Case 2	Case 3	Case 4	Case 5	Case 6	Case 7
Age	83	79	50	51	76	65	76
Sex (F/M)	M	F	F	F	F	F	F
Duration of pain	1 mo	6 mo	4 yr	1 mo	1 mo	20 d	2 mo

M: Male; F: Female.

Physical examination

Both case 6 and case 7 had mild tenderness in the right upper abdomen and no obvious rebound pain. No obvious abnormality was found in the physical examination of the other patients.

Laboratory examinations

The laboratory examinations revealed that only case 2 and case 4 had liver dysfunction (Table 2). The preoperative serum levels of several tumor markers [carbohydrate antigen (CA) 19-9, CA-125, carcinoembryonic antigen (CEA), and alpha-fetoprotein (AFP)] are shown in Table 2. The CEA and CA19-9 levels for both patients without recurrence were normal, and the CA-125 level was slightly elevated in one of these patients. Two (40%) patients with recurrence or metastasis had elevated serum CEA levels. Three (60%) patients with recurrence or metastasis had significantly high CA19-9 levels, with the highest one exceeding 1000 U/mL. Three (60%) patients with recurrence or metastasis had notably elevated CA-125, two of whom had high levels of both CA19-9 and CA-125. All the seven patients, with or without recurrence, showed normal AFP levels.

Imaging examinations

Case 1 and case 5 underwent contrast-enhanced abdominal MRI, and the rest of the patients underwent contrast-enhanced abdominal computed tomography (CT). Gallbladder mass was found in all patients. Granulomatous hyperplasia was considered in case 1 and malignant tumor was considered in other patients.

FINAL DIAGNOSIS

The seven patients were eventually diagnosed with gallbladder sarcomatoid carcinoma. A total of 57.1% (4/7) of the tumors were located in the gallbladder body, one located in the body and choledochus, one in the fundus and neck, and one in the fundus. A total of 85.7% (6/7) of the tumors had a maximal diameter greater than 7 cm. Two patients without recurrence had early-stage disease; one had stage I disease with a tumor restricted to the lamina propria, and the other had stage II disease with a tumor restricted to the connective tissue without extension beyond the serosa. The other five patients had advanced-stage disease, including one with stage IIIB, three with stage IVB, and one with stage III/IV with unknown lymph node status (Table 3).

Pathological appearance

The pathological appearance of the sarcomatoid carcinoma samples is shown in Figure 1 and Table 4. Hematoxylin and eosin staining showed poorly differentiated carcinoma with spindle-shaped cells and a commonly pleomorphic morphology, which were typical figures of sarcomatoid carcinoma (Figure 1A and B). According to immunohistochemical staining, all seven patients strongly and diffusely expressed pan-cytokeratin (Figure 1C). Other epithelioid markers, such as CK-7 and CK-19, were also detected in some patients. Sarcoma-like spindle cells were negative for desmin in all seven patients (Figure 1D, Table 4) and negative for a-SMA in six patients (Table 4). All of these immunohistochemical results suggested that the sarcoma-like component was essentially carcinoma. Sarcomatoid carcinoma was usually pleomorphic. Adenocarcinoma and adenosquamous carcinoma can be found after extensive sampling. In the cases we collected, we also found some mixed components of carcinoma. Adenocarcinoma was common (3/7), with adenosquamous sometimes

Table 2 Laboratory examinations

	No recurrence		Recurrence or metastasis				
	Case 1	Case 2	Case 3	Case 4	Case 5	Case 6	Case 7
DBIL	12.2↑	4.5	3.8	7.2	3.3	5.6	3.8
ALT	11	10	10	75↑	18	8	38
AST	21	15	21	62	22	14	25
CEA	1.05	1.37	N/A	2.54	47.4↑	0.29	5.74↑
CA19-9	22.7	19.46	125↑	> 1000↑	446.8↑	7.8	24.42
CA-125	40.12	7.19	102.1↑	115.8↑	N/A	43.77	272.3↑
AFP	4.15	1.94	0.69	8.77	3.22	0.79	N/A

DBIL: Direct bilirubin; ALT: Alanine transaminase; AST: Aspartate transaminase; CA19-9: Carbohydrate antigen; CEA: Carcinoembryonic antigen; AFP: Alpha-fetoprotein; N/A: Not available.

Table 3 Tumor characteristics

Characteristic	No recurrence		Recurrence or metastasis				
	Case 1	Case 2	Case 3	Case 4	Case 5	Case 6	Case 7
Position	Body and choledochus	Body	Body	Fundus and neck	Body	Body	Fundus
Diameter	3 cm	7.2 cm	7 cm	7 cm	9 cm	10 cm	7 cm
Operation	P	R	R	R	R	R (colon)	P
Depth	T1	T2	T2	T3	T3	T3	T3
Lymph node	N0 ¹	N0	N1	N2	Nx	N2	Nx
Metastasis	M0	M0	M0	M0	M0	M0	M1
Stage	I	II	IIIB	IVB	III/IV	IVB	IVB

¹Preoperative magnetic resonance imaging evaluation. R: Radical surgery; P: Palliative cholecystectomy.

occurring concurrently (2/7).

TREATMENT

Surgical procedures

All patients underwent surgical procedures. Case 1 underwent cholecystectomies without lymphadenectomy because intraoperative frozen section analysis resulted in a diagnosis of “adenoma”, which was finally proven to be sarcomatoid carcinoma by paraffin section analysis. Case 7, who had stage IV disease with peritoneal metastasis and intraperitoneal hematoma, underwent palliative cholecystectomy. The other five patients underwent radical surgery, which included resection of the primary gallbladder tumor, involved extrahepatic biliary tract, and portions of liver tissue (cases 2/3/4/5), lymphadenectomy, and right hemicolectomy (case 6). No serious surgical complications or death occurred.

Adjuvant therapy

Case 3 was a 50-year-old woman who underwent cholecystectomy, lymphadenectomy, and partial resection of the liver. She received adjuvant chemotherapy and radiotherapy 1 mo after surgery for stage T2N1M0 (IIIB) disease. She was treated with gemcitabine and capecitabine in 21-d cycles. After two cycles of chemotherapy, she received radiotherapy (5040 cGy to the tumor bed and regional lymph nodes). Two other cycles of chemotherapy were administered after radiotherapy. One month after the completion of all the adjuvant therapy, a CT scan was carried out to reassess the

Table 4 Pathological diagnosis

	No recurrence		Recurrence or metastasis				
	Case 1	Case 2	Case 3	Case 4	Case 5	Case 6	Case 7
Carcinoma	Adenocarcinoma	NM	NM	Adenosquamous	Adenosquamous	Adenocarcinoma	Adenocarcinoma
PCK	(+)	(+)	(+)	(+)	(+)	(+)	(+)
Cytokeratin	CK19+	CK7 (+), CK20 (-)	CK19 (focal+), CK7 (-)	CK7 (+), CK19 (+)	NT	CK7 (focal+), CK20 (focal+)	NT
EMA	NT	(+)	(focal +)	NT	NT	+	NT
Vimentin	NT	NT	NT	NT	NT	(focal +)	NT
Desmin	(-)	(-)	(-)	(-)	(-)	(-)	(-)
a-SMA	(-)	(-)	NT	(-)	(-)	(-)	(-)
Other positive markers		S-100 (±)		P63 (focal +)		CAM5.2 (focal +)	
Other negative markers	Syn (-), CgA (-)			HCC (-), CD34 (-)		DOG1 (-), CD117 (-), CD34 (-)	

NM: Not mentioned; NT: Not tested; PCK: Pan-cytokeratin.

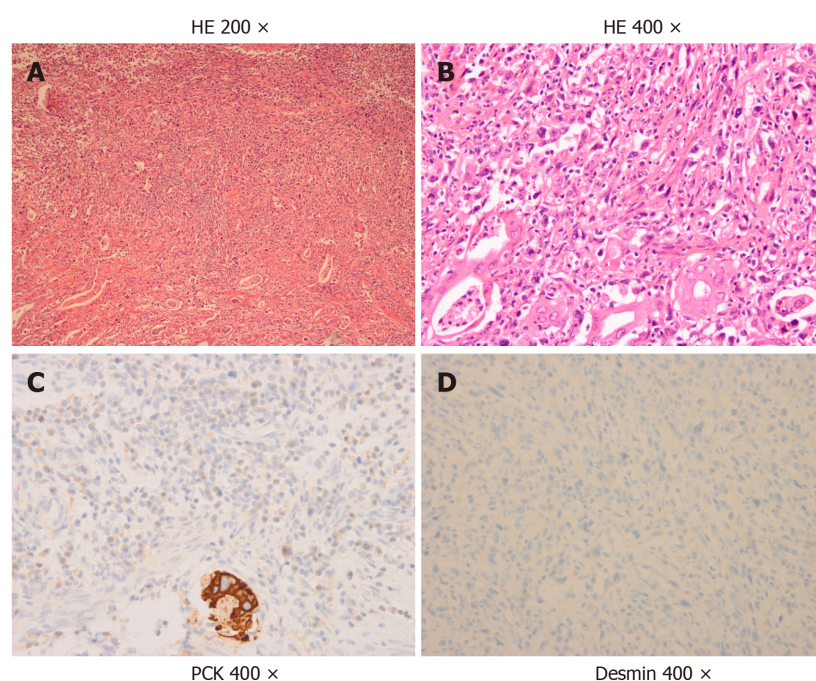


Figure 1 Pathological findings. A and B: Representative images of hematoxylin and eosin staining (HE)-stained tumor tissue (A: × 200; B: × 400); C and D: Immunohistochemical images showing positive staining for pan-cytokeratin (C) and negative staining for desmin (D) (× 400). HE: Hematoxylin and eosin; PCK: Pan-cytokeratin.

enlarged lymph node that was found before adjuvant therapy (Figure 2A), which had already shrunk without recurrence or metastases (Figure 2B). Three months after the completion of adjuvant therapy, the patient came to the hospital with abdominal distention, and the CT scan found metastases in the liver (Figure 2C) and thoracic vertebra (Figure 2D). She was treated with FOLFOXIRI as second-line chemotherapy for two cycles. She did not visit our hospital for antitumor therapy again because of her gradually declining general medical condition. She died 2 mo after second-line chemotherapy. With serial adjuvant therapies, she achieved a PFS of 12 mo and OS of 15 mo, which are the longest reported periods to date in such patients.

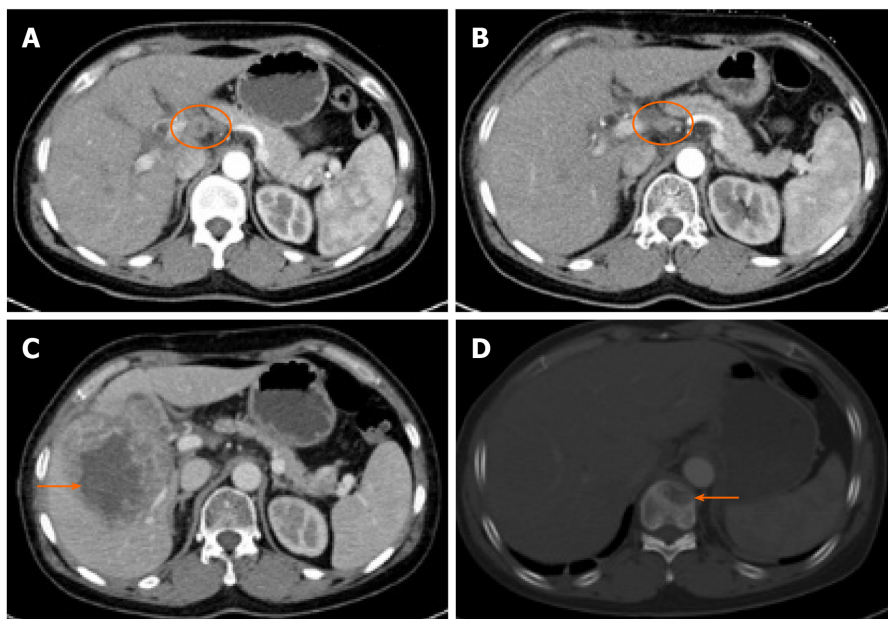


Figure 2 Computed tomography images. A: Lymph node involvement before adjuvant therapy; B: Computed tomography image showing a significant reduction in lymph node involvement (B circle) compared to that before adjuvant therapy (A circle); C: Metastases in the liver (arrow); D: Metastases in the thoracic vertebra (arrow).

OUTCOME AND FOLLOW-UP

The follow-up time ranged from 1.5 years to 5 years. Tumor node metastasis (TNM) stage seemed to be a very important prognostic indicator. There was a significant difference in prognosis between patients with early-stage and advanced-stage disease. Two patients with early-stage (I/II) disease were still alive without recurrence for 5 years and 3 years. Neither patient received adjuvant therapy after the operation. All five patients with advanced-stage (III/IV) disease died from metastases or disease progression shortly after surgery. Four of five patients without adjuvant therapy developed metastases or progressed within 2 mo and died within 3 mo, while only one patient with stage IIIB disease who received adjuvant chemotherapy and radiotherapy achieved a PFS of 12 mo and OS of 15 mo (Table 5). Liver metastases were most common (4/5), followed by bone and peritoneal metastases.

DISCUSSION

Gallbladder sarcomatoid carcinoma is an extremely rare malignancy with aggressive behavior, representing only 4.3% of all gallbladder cancers, and has often been confused with carcinosarcoma in previous reports, as long as they have both epithelioid and sarcomatoid components^[10]. In our opinion, there are two different kinds of malignant neoplasms. Kim *et al*^[4] found that in sarcomatoid carcinoma, the tumor cells of the sarcomatous area coexpress CK and vimentin immunohistochemically and ultrastructurally showed desmosome-like junctions and aggregates of cytoplasmic intermediate filaments. These findings suggested that the sarcomatoid components in sarcomatoid carcinoma were essentially carcinoma. According to the World Health Organization classification of digestive system tumors^[11], carcinosarcoma is composed of carcinoma and sarcoma components. The sarcoma components can be chondrosarcoma, fibrosarcoma, leiomyosarcoma and so on. In this situation, immunohistochemistry shows that sarcomatoid and epithelioid components express interstitial and epithelioid markers, respectively^[12]. Although sarcoma-like spindle cells were mixed with carcinoma tissue in our report, the cells actually expressed epithelioid markers and not sarcomatoid markers on immunohistochemistry. These results indicated that the sarcoma-like component was essentially carcinoma, and our pathologists defined those as sarcomatoid carcinoma rather than carcinosarcoma.

Females seem to be more likely to develop gallbladder tumors than males. Among all cases of gallbladder cancer, female patients are three times more common than

Table 5 Prognosis

	No recurrence		Recurrence or metastasis				
	Case 1	Case 2	Case 3	Case 4	Case 5	Case 6	Case 7
Stage	I	II	IIIB	IVB	III/IV	IIIB	IVB
Adjuvant therapy	No	No	Yes	No	No	No	No
Recurrence or metastasis	No	No	Liver and bone	Liver	Liver	Liver	Peritoneum
PFS	> 5 yr	> 3 yr	12 mo	2 mo	2 mo	1 mo	-
OS	> 5 yr	> 3 yr	15 mo	2.6 mo	2.5 mo	2 mo	1.8 mo

PFS: Progression-free survival; OS: Overall survival.

male patients, and in sarcomatoid carcinoma, the trend is much more pronounced, as female patients are five to six times more common^[2]. Advanced age is considered to be a high-risk factor for gallbladder cancer^[2]. The median age was 68.5 years, and approximately 71.4% (5/7) of the patients in our center were over 65 years old, which is higher than the 40% in previous reports^[3-8]. Nevertheless, interestingly, we found that two patients who have not yet developed recurrence were as old as 80, which may suggest that advanced age is a predictor of a better prognosis in gallbladder sarcomatoid carcinoma. Almost every patient with gallbladder sarcomatoid carcinoma shows symptoms of abdominal pain. However, most of the patients in our report had advanced-stage disease, and the tumor was larger than 7 cm. Visiting the hospital for an abdominal CT or ultrasound examination after the onset of abdominal symptoms is too late. For older patients, it may be more possible and economical to detect gallbladder lesions at an earlier stage by routine abdominal sonography, especially high-resolution^[13] or contrast-enhanced^[14] sonography, before the onset of symptoms.

The elevations in CEA, CA19-9, and CA-125 appear to be indicators of a poor prognosis in patients with gallbladder sarcomatoid carcinoma. CEA and CA19-9 are recommended tumor markers associated with gallbladder cancer in the National Comprehensive Cancer Network (NCCN) guidelines. The elevations in CEA and CA19-9 in gallbladder sarcomatoid carcinoma reported in the previous literature were not obvious^[4,5,7,8]. In our report, three (60%) patients with recurrence or metastasis had significantly high CA19-9 levels, with the highest level exceeding 1000 U/mL. CA-125, initially thought to be a specific biomarker for ovarian cancer, is considered a potential biomarker of digestive tract neoplasms and is associated with a poor survival^[15,16]. There were three (60%) patients with recurrence or metastasis who had significantly high CA-125 levels, and the number of patients with stage IV disease was approximately seven times higher than normal. Furthermore, the two patients without recurrence with stage I or stage II disease showed normal CEA, CA19-9, and CA-125 levels. Unfortunately, we did not continue to monitor the changes in the above tumor markers after progression and cannot further explain their correlations with the disease.

TNM stage seems to be an important indicator for the prognosis of gallbladder neoplasm^[17]. In our report, the prognosis of patients with early-stage disease (stage I and stage II) was much better than that of patients with advanced-stage disease. The patients with stage I and stage II disease did not have recurrence for more than 5 years and 3 years, respectively. However, most of the patients who had advanced-stage disease were found to have recurred at approximately 2 mo and died quickly thereafter. These data are similar to those reported in the previous literature. The majority of patients with advanced stages disease recurred between 2 and 3 mo, and the survival time was between 5 and 12 mo in previous reports^[3-8]. The data of patients with early-stage disease were not clear because there were no previous reports. However, no mention of long-term survival in patients with advanced-stage disease has been found until now.

Surgery is suggested as the first and only recognized treatment for sarcomatoid carcinoma of the gallbladder. Radical cholecystectomy refers to extensive resection of the gallbladder bed with a rim of liver tissues and peripheral metastatic lymph nodes or tissues. However, even with such a wide excision range, patients with late stage disease still recurred quickly after surgery, and the liver was the most common site, which may be because the serosa is lacking on the side that the gallbladder embeds in the liver. In total, two patients in our report and six in the past literature recurred only

2 mo after the operation^[3-5,8]. These frustrating results suggest that surgical treatment is not enough for patients with locally advanced disease and that postoperative adjuvant treatment may be appropriate. Because of the rarity of gallbladder sarcomatoid carcinoma, there was no previously recommended adjuvant treatment. We considered that sarcomatoid carcinoma of the gallbladder was a kind of carcinoma, not sarcoma, so we referred to the adjuvant treatment regimen for gallbladder cancer. A nomogram suggested that certain subsets of patients with at least stage T2 or N1 disease will gain survival benefits from adjuvant chemoradiotherapy^[18]. Wang *et al*^[19] suggested that adjuvant radiotherapy provides a survival benefit in node-positive or \geq T2 gallbladder cancer. The combination of gemcitabine and capecitabine followed by concurrent capecitabine and radiotherapy (45 Gy to regional lymph nodes; 54 to 59.4 Gy to the tumor bed) was proven to be well tolerated and promising by Ben-Josef *et al*^[20]. Gemcitabine and cisplatin were used in a randomized, multinational phase III trial and were thought to increase the 24-mo postoperative disease-free survival (DFS) rate from 35% to 55% in gallbladder cancer^[21]. Moreover, adjuvant chemotherapy with gemcitabine and adjuvant radiotherapy are still recommended by the NCCN clinical practice guidelines. Therefore, we treated the patient with a stage T2N1M0 tumor with gemcitabine and capecitabine for two cycles followed by radiotherapy (5040 cGy to the tumor bed and regional lymph nodes). Two additional cycles of the same chemotherapy as before were administered after the radiotherapy. With the combination of adjuvant chemotherapy and radiotherapy, the PFS of this patient was 12 mo, which is much longer than that of patients with advanced-stage gallbladder sarcomatoid carcinoma reported in the literature. To the best of our knowledge, this is the first detailed report of postoperative adjuvant treatment for gallbladder sarcomatoid carcinoma, and the patient got a PFS of 12 mo, which is the longest reported period to date. Gemcitabine combined with fluorouracil and radiotherapy could be considered as an adjuvant treatment for patients with locally advanced gallbladder sarcomatoid carcinoma. Unfortunately, liver and bone metastases occurred 3 mo in the patient after the completion of adjuvant therapy, suggesting that our adjuvant regimen could be further optimized. These optimizations may include an increase in the dose of radiotherapy at the liver site, as well as appropriate maintenance chemotherapy.

CONCLUSION

Gallbladder sarcomatoid carcinoma is a unique gallbladder malignancy with a poor prognosis. Surgery is suggested as the first and only recognized treatment. There is a significant difference in prognosis between patients with early-stage and advanced-stage disease. Postoperative adjuvant therapy may bring survival benefits for locally advanced patients. Gemcitabine combined with fluorouracil and radiotherapy could be a choice that should be further tested and optimized.

ACKNOWLEDGEMENTS

This study was generously supported by the Department of Pathology, West China Hospital of Sichuan University.

REFERENCES

- 1 Bartlett DL. Gallbladder cancer. *Semin Surg Oncol* 2000; **19**: 145-155 [PMID: 11126379 DOI: 10.1002/1098-2388(200009)19:2<145::aid-ssu7>3.0.co;2-6]
- 2 Kanthan R, Senger JL, Ahmed S, Kanthan SC. Gallbladder Cancer in the 21st Century. *J Oncol* 2015; **2015**: 967472 [PMID: 26421012 DOI: 10.1155/2015/967472]
- 3 Liu KH, Yeh TS, Hwang TL, Jan YY, Chen MF. Surgical management of gallbladder sarcomatoid carcinoma. *World J Gastroenterol* 2009; **15**: 1876-1879 [PMID: 19370786 DOI: 10.3748/wjg.15.1876]
- 4 Kim MJ, Yu E, Ro JY. Sarcomatoid carcinoma of the gallbladder with a rhabdoid tumor component. *Arch Pathol Lab Med* 2003; **127**: e406-e408 [PMID: 14521442 DOI: 10.1043/1543-2165(2003)1272.0.CO;2]
- 5 Takahashi Y, Fukushima J, Fukusato T, Shiga J. Sarcomatoid carcinoma with components of small cell carcinoma and undifferentiated carcinoma of the gallbladder. *Pathol Int* 2004; **54**: 866-871 [PMID: 15533231 DOI: 10.1111/j.1440-1827.2004.01771.x]
- 6 Hu ZH, Li ZW, Shen L, Zhang M, Zheng SS. Surgical therapy and prognosis of sarcomatoid carcinoma of the gallbladder. *Hepatobiliary Pancreat Dis Int* 2010; **9**: 175-179 [PMID: 20382590]
- 7 Kataria K, Yadav R, Seenu V. Sarcomatoid carcinoma of the gall bladder. *J Surg Case Rep* 2012; **2012**: 5

- [PMID: [24960781](#) DOI: [10.1093/jscr/2012.2.5](#)]
- 8 **Doval DC**, Azam S, Mehta A, Pruthi A, Batra U, Choudhury KD, Kumar K. A report of sarcomatoid carcinoma of the gallbladder treated with palliative docetaxel and gemcitabine chemotherapy. *J Gastrointest Cancer* 2014; **45** Suppl 1: 270-274 [PMID: [25326734](#) DOI: [10.1007/s12029-014-9654-3](#)]
 - 9 **Rahman R**, Simoes EJ, Schmaltz C, Jackson CS, Ibdah JA. Trend analysis and survival of primary gallbladder cancer in the United States: a 1973-2009 population-based study. *Cancer Med* 2017; **6**: 874-880 [PMID: [28317286](#) DOI: [10.1002/cam4.1044](#)]
 - 10 **Lopez-Beltran A**, Pacelli A, Rothenberg HJ, Wollan PC, Zincke H, Blute ML, Bostwick DG. Carcinosarcoma and sarcomatoid carcinoma of the bladder: clinicopathological study of 41 cases. *J Urol* 1998; **159**: 1497-1503 [PMID: [9554341](#) DOI: [10.1097/00005392-199805000-00023](#)]
 - 11 **Hamilton S.R.** ALA. World Health Organization Classification of Tumours. Pathology and Genetics of Tumours of the Digestive System. IARC Press. 2000; 203-217
 - 12 **Bloxham CA**, Bennett MK, Robinson MC. Bladder carcinosarcomas: three cases with diverse histogenesis. *Histopathology* 1990; **16**: 63-67 [PMID: [1689690](#) DOI: [10.1111/j.1365-2559.1990.tb01062.x](#)]
 - 13 **Kim JH**, Lee JY, Baek JH, Eun HW, Kim YJ, Han JK, Choi BI. High-resolution sonography for distinguishing neoplastic gallbladder polyps and staging gallbladder cancer. *AJR Am J Roentgenol* 2015; **204**: W150-W159 [PMID: [25615775](#) DOI: [10.2214/AJR.13.11992](#)]
 - 14 **Wang H**, Ling W, Luo Y. Contrast-enhanced ultrasound findings of gallbladder adenocarcinoma with sarcomatoid carcinoma accompanied by intrahepatic metastasis: A case report and literature review. *Medicine (Baltimore)* 2018; **97**: e10773 [PMID: [29794755](#) DOI: [10.1097/MD.00000000000010773](#)]
 - 15 **Streppel MM**, Vincent A, Mukherjee R, Campbell NR, Chen SH, Konstantopoulos K, Goggins MG, Van Seuningen I, Maitra A, Montgomery EA. Mucin 16 (cancer antigen 125) expression in human tissues and cell lines and correlation with clinical outcome in adenocarcinomas of the pancreas, esophagus, stomach, and colon. *Hum Pathol* 2012; **43**: 1755-1763 [PMID: [22542127](#) DOI: [10.1016/j.humpath.2012.01.005](#)]
 - 16 **Luo T**, Chen W, Wang L, Zhao H. CA-125 is a potential biomarker to predict surgically incurable gastric and cardia cancer: A retrospective study. *Medicine (Baltimore)* 2016; **95**: e5297 [PMID: [28002320](#) DOI: [10.1097/MD.00000000000005297](#)]
 - 17 **Fong Y**, Jarnagin W, Blumgart LH. Gallbladder cancer: comparison of patients presenting initially for definitive operation with those presenting after prior noncurative intervention. *Ann Surg* 2000; **232**: 557-569 [PMID: [10998654](#) DOI: [10.1097/0000658-200010000-00011](#)]
 - 18 **Wang SJ**, Lemieux A, Kalpathy-Cramer J, Ord CB, Walker GV, Fuller CD, Kim JS, Thomas CR Jr. Nomogram for predicting the benefit of adjuvant chemoradiotherapy for resected gallbladder cancer. *J Clin Oncol* 2011; **29**: 4627-4632 [PMID: [22067404](#) DOI: [10.1200/JCO.2010.33.8020](#)]
 - 19 **Wang SJ**, Fuller CD, Kim JS, Sittig DF, Thomas CR Jr, Ravdin PM. Prediction model for estimating the survival benefit of adjuvant radiotherapy for gallbladder cancer. *J Clin Oncol* 2008; **26**: 2112-2117 [PMID: [18378567](#) DOI: [10.1200/JCO.2007.14.7934](#)]
 - 20 **Ben-Josef E**, Guthrie KA, El-Khoueiry AB, Corless CL, Zalupski MM, Lowy AM, Thomas CR Jr, Alberts SR, Dawson LA, Micetich KC, Thomas MB, Siegel AB, Blanke CD. SWOG S0809: A Phase II Intergroup Trial of Adjuvant Capecitabine and Gemcitabine Followed by Radiotherapy and Concurrent Capecitabine in Extrahepatic Cholangiocarcinoma and Gallbladder Carcinoma. *J Clin Oncol* 2015; **33**: 2617-2622 [PMID: [25964250](#) DOI: [10.1200/JCO.2014.60.2219](#)]
 - 21 **Stein A**, Arnold D, Bridgewater J, Goldstein D, Jensen LH, Klumpen HJ, Lohse AW, Nashan B, Primrose J, Schrum S, Shannon J, Vettorazzi E, Wege H. Adjuvant chemotherapy with gemcitabine and cisplatin compared to observation after curative intent resection of cholangiocarcinoma and muscle invasive gallbladder carcinoma (ACTCCA-1 trial) - a randomized, multidisciplinary, multinational phase III trial. *BMC Cancer* 2015; **15**: 564 [PMID: [26228433](#) DOI: [10.1186/s12885-015-1498-0](#)]



Published by **Baishideng Publishing Group Inc**
7041 Koll Center Parkway, Suite 160, Pleasanton, CA 94566, USA

Telephone: +1-925-3991568

E-mail: bpgoffice@wjgnet.com

Help Desk: <https://www.f6publishing.com/helpdesk>

<https://www.wjgnet.com>

