

World Journal of *Clinical Cases*

World J Clin Cases 2020 September 26; 8(18): 3920-4279



Contents

Semimonthly Volume 8 Number 18 September 26, 2020

OPINION REVIEW

- 3920 Special features of SARS-CoV-2 in daily practice
Charitos IA, Ballini A, Bottalico L, Cantore S, Passarelli PC, Inchingolo F, D'Addona A, Santacroce L

EVIDENCE REVIEW

- 3934 Gastrointestinal insights during the COVID-19 epidemic
Nie K, Yang YY, Deng MZ, Wang XY

REVIEW

- 3942 From infections to autoimmunity: Diagnostic challenges in common variable immunodeficiency
Więsik-Szewczyk E, Jahnz-Różyk K
- 3956 One disease, many faces-typical and atypical presentations of SARS-CoV-2 infection-related COVID-19 disease
Philips CA, Mohan N, Ahamed R, Kumbar S, Rajesh S, George T, Mohanan M, Augustine P

MINIREVIEWS

- 3971 Application of artificial neural networks in detection and diagnosis of gastrointestinal and liver tumors
Mao WB, Lyu JY, Vaishnani DK, Lyu YM, Gong W, Xue XL, Shentu YP, Ma J
- 3978 Hepatic epithelioid hemangioendothelioma: Update on diagnosis and therapy
Kou K, Chen YG, Zhou JP, Sun XD, Sun DW, Li SX, Lv GY

ORIGINAL ARTICLE

Clinical and Translational Research

- 3988 *Streptococcus agalactiae*: Identification methods, antimicrobial susceptibility, and resistance genes in pregnant women
Santana FAF, de Oliveira TVL, Filho MBDS, da Silva LSC, de Brito BB, de Melo FF, Souza CL, Marques LM, Oliveira MV
- 3999 Twelve-month evaluation of the atraumatic restorative treatment approach for class III restorations: An interventional study
Shivanna MM, Ganesh S, Khanagar SB, Naik S, Divakar DD, Al-Kheraif AA, Jhugroo C

Case Control Study

- 4010 Effects of different doses of metformin on bone mineral density and bone metabolism in elderly male patients with type 2 diabetes mellitus
Wang LX, Wang GY, Su N, Ma J, Li YK

- 4017** Relationship between granulomatous lobular mastitis and methylene tetrahydrofolate reductase gene polymorphism

Lei QR, Yang X, Miao CM, Wang JC, Yang Y

Retrospective Cohort Study

- 4022** First-line chemotherapy in very elderly patients with metastatic pancreatic cancer: Gemcitabine monotherapy vs combination chemotherapy

Han SY, Kim DU, Seol YM, Kim S, Lee NK, Hong SB, Seo HI

Retrospective Study

- 4034** Pre- and intraoperative predictors of acute kidney injury after liver transplantation

Mrzljak A, Franusic L, Pavicic-Saric J, Kelava T, Jurekovic Z, Kocman B, Mikulic D, Budimir-Bekan I, Knotek M

- 4043** Clinical value of needleless sling in treatment of female stress urinary incontinence

Chen YG, Zhang YG, Zhang W, Li X, Wang X

- 4051** Intratympanic dexamethasone injection for sudden sensorineural hearing loss in pregnancy

Lyu YL, Zeng FQ, Zhou Z, Yan M, Zhang W, Liu M, Ke ZY

- 4059** Research on the effect of health care integration on patients' negative emotions and satisfaction with lung cancer nursing activities

Long FJ, Chen H, Wang YF, He LM, Chen L, Liang ZB, Chen YN, Gong XH

- 4067** Comparison between computed tomography and magnetic resonance imaging in clinical diagnosis and treatment of tibial platform fractures

Liu XD, Wang HB, Zhang TC, Wan Y, Zhang CZ

SYSTEMATIC REVIEWS

- 4075** Primary sclerosing cholangitis and autoimmune hepatitis overlap syndrome associated with inflammatory bowel disease: A case report and systematic review

Ballotin VR, Bigarella LG, Riva F, Onzi G, Balbinot RA, Balbinot SS, Soldera J

CASE REPORT

- 4094** Epidermolytic acanthoma: A case report

Ginsberg AS, Rajagopalan A, Terlizzi JP

- 4100** Management of pembrolizumab-induced steroid refractory mucositis with infliximab: A case report

Dang H, Sun J, Wang G, Renner G, Layfield L, Hilli J

- 4109** Small bowel obstruction caused by a bezoar following an adult simultaneous liver-kidney transplantation: A case report

Pan G, Kim RD, Campsen J, Rofaiel G

- 4114** Laparoscopic resection of primary retroperitoneal schwannoma: A case report

Ribeiro Jr MA, Elias YG, Augusto SDS, Néder PR, Costa CT, Maurício AD, Sampaio AP, Fonseca AZ

- 4122** Sweet syndrome as a paraneoplastic manifestation of cholangiocarcinoma: A case report
Lemaire CC, Portilho ALC, Pinheiro LV, Vivas RA, Britto M, Montenegro M, Rodrigues LFDF, Arruda S, Lyra AC, Cavalcante LN
- 4128** Multidisciplinary approach to suspected sudden unexpected infant death caused by milk-aspiration: A case report
Maiese A, La Russa R, Arcangeli M, Volonnino G, De Matteis A, Frati P, Fineschi V
- 4135** Stress fractures in uncommon location: Six case reports and review of the literature
Ficek K, Cyganik P, Rajca J, Racut A, Kiełtyka A, Grzywocz J, Hajduk G
- 4151** Celiac disease and Sjögren's syndrome: A case report and review of literature
Balaban DV, Mihai A, Dima A, Popp A, Jinga M, Jurcut C
- 4162** Nonasthmatic eosinophilic bronchitis in an ulcerative colitis patient – a putative adverse reaction to mesalazine: A case report and review of literature
Cernomaz AT, Bordeianu G, Terinte C, Gavrilescu CM
- 4169** Insulinoma presenting with postprandial hypoglycemia and a low body mass index: A case report
Přidavková D, Samoš M, Kyčina R, Adamicová K, Kalman M, Belicová M, Mokáň M
- 4177** Neoadjuvant chemoradiotherapy for locally advanced gastric cancer with bulky lymph node metastasis: Five case reports
Nomura E, Kayano H, Machida T, Izumi H, Yamamoto S, Sugawara A, Mukai M, Hasebe T
- 4186** Unilateral pleuroparenchymal fibroelastosis as a rare form of idiopathic interstitial pneumonia: A case report
Lee JH, Jang HJ, Park JH, Kim HK, Lee S, Kim JY, Kim SH
- 4193** Superior mesenteric vein thrombosis induced by influenza infection: A case report
Oh GM, Jung K, Kim JH, Kim SE, Moon W, Park MI, Park SJ
- 4200** Mucinous adenocarcinoma of the buttock associated with hidradenitis: A case report
Kim SJ, Kim TG, Gu MJ, Kim S
- 4207** TFE3-expressing malignant perivascular epithelioid cell tumor of the mesentery: A case report and review of literature
Kim NI, Lee JS, Choi YD, Ju UC, Nam JH
- 4215** Robotic surgery in giant multilocular cystadenoma of the prostate: A rare case report
Fan LW, Chang YH, Shao IH, Wu KF, Pang ST
- 4223** Multiple recurrent neurofibromas in the abdominal wall: A case report
Zhao XF, Shen YM, Chen J
- 4228** Mine disaster survivor's pelvic floor hernia treated with laparoscopic surgery and a perineal approach: A case report
Chen K, Lan YZ, Li J, Xiang YY, Zeng DZ

- 4234** Successful treatment of encrusted cystitis: A case report and review of literature
Fu JG, Xie KJ
- 4245** Massive pulmonary haemorrhage due to severe trauma treated with repeated alveolar lavage combined with extracorporeal membrane oxygenation: A case report
Zhang BY, Chen XC, You Y, Chen M, Yu WK
- 4252** Gitelman syndrome caused by a rare homozygous mutation in the *SLC12A3* gene: A case report
Yu RZ, Chen MS
- 4259** Arterial embolism caused by a peripherally inserted central catheter in a very premature infant: A case report and literature review
Huang YF, Hu YL, Wan XL, Cheng H, Wu YH, Yang XY, Shi J
- 4266** Left bundle branch pacing with optimization of cardiac resynchronization treatment: A case report
Zhang DH, Lang MJ, Tang G, Chen XX, Li HF
- 4272** Lymphoplasmacyte-rich meningioma with atypical cystic-solid feature: A case report
Gu KC, Wan Y, Xiang L, Wang LS, Yao WJ

ABOUT COVER

Editorial board member of *World Journal of Clinical Cases*, Dr. Li is a Professor at the Nanjing University Medical School in Nanjing, China. Having received his Bachelor's degree from Xuzhou Medical College in 1997, Dr. Li undertook his postgraduate training first at Nanjing Medical University, receiving his Master's degree in 2004, and then at Fudan University, receiving his PhD in 2007. He advanced to Chief Physician in the Department of Anesthesiology at The Affiliated Hospital of Nanjing University Medical School in 2017 and has held the position since. His ongoing research interests involve ultrasound (transthoracic echo and transesophageal echo) in clinical anesthesia and ultrasound-guided limb and trunk nerve block in postoperative pain management. (L-Editor: Filipodia)

AIMS AND SCOPE

The primary aim of *World Journal of Clinical Cases* (*WJCC*, *World J Clin Cases*) is to provide scholars and readers from various fields of clinical medicine with a platform to publish high-quality clinical research articles and communicate their research findings online.

WJCC mainly publishes articles reporting research results and findings obtained in the field of clinical medicine and covering a wide range of topics, including case control studies, retrospective cohort studies, retrospective studies, clinical trials studies, observational studies, prospective studies, randomized controlled trials, randomized clinical trials, systematic reviews, meta-analysis, and case reports.

INDEXING/ABSTRACTING

The *WJCC* is now indexed in Science Citation Index Expanded (also known as SciSearch®), Journal Citation Reports/Science Edition, PubMed, and PubMed Central. The 2020 Edition of Journal Citation Reports® cites the 2019 impact factor (IF) for *WJCC* as 1.013; IF without journal self cites: 0.991; Ranking: 120 among 165 journals in medicine, general and internal; and Quartile category: Q3.

RESPONSIBLE EDITORS FOR THIS ISSUE

Production Editor: Ji-Hong Liu; Production Department Director: Xiang Li; Editorial Office Director: Jin-Lai Wang.

NAME OF JOURNAL

World Journal of Clinical Cases

ISSN

ISSN 2307-8960 (online)

LAUNCH DATE

April 16, 2013

FREQUENCY

Semimonthly

EDITORS-IN-CHIEF

Dennis A Bloomfield, Sandro Vento, Bao-Gan Peng

EDITORIAL BOARD MEMBERS

<https://www.wjgnet.com/2307-8960/editorialboard.htm>

PUBLICATION DATE

September 26, 2020

COPYRIGHT

© 2020 Baishideng Publishing Group Inc

INSTRUCTIONS TO AUTHORS

<https://www.wjgnet.com/bpg/gerinfo/204>

GUIDELINES FOR ETHICS DOCUMENTS

<https://www.wjgnet.com/bpg/GerInfo/287>

GUIDELINES FOR NON-NATIVE SPEAKERS OF ENGLISH

<https://www.wjgnet.com/bpg/gerinfo/240>

PUBLICATION ETHICS

<https://www.wjgnet.com/bpg/GerInfo/288>

PUBLICATION MISCONDUCT

<https://www.wjgnet.com/bpg/gerinfo/208>

ARTICLE PROCESSING CHARGE

<https://www.wjgnet.com/bpg/gerinfo/242>

STEPS FOR SUBMITTING MANUSCRIPTS

<https://www.wjgnet.com/bpg/GerInfo/239>

ONLINE SUBMISSION

<https://www.f6publishing.com>

Massive pulmonary haemorrhage due to severe trauma treated with repeated alveolar lavage combined with extracorporeal membrane oxygenation: A case report

Bei-Yuan Zhang, Xian-Cheng Chen, Yong You, Ming Chen, Wen-Kui Yu

ORCID number: Bei-Yuan Zhang 0000-0001-8760-6520; Xian-Cheng Chen 0000-0002-5837-1897; Yong You 0000-0002-3735-9119; Ming Chen 0000-0002-0308-5690; Wen-Kui Yu 0000-0003-1298-8928.

Author contributions: Zhang BY, Chen XC, You Y, Chen M and Yu WK were involved in in-hospital treatment of this case; Zhang BY and Chen XC helped to draft the manuscript; Zhang BY was a major contributor in writing the manuscript; You Y and Chen M analysed and interpreted the patient data; Yu WK designed the work and approved the submitted version; all authors issued final approval for the version to be submitted.

Informed consent statement: Informed written consent was obtained from the patient for publication of this report and any accompanying images.

Conflict-of-interest statement: The authors declare that they have no conflicts of interest.

CARE Checklist (2016) statement: The authors have read the CARE Checklist (2016), and the manuscript was prepared and revised according to the CARE Checklist (2016).

Bei-Yuan Zhang, Xian-Cheng Chen, Yong You, Ming Chen, Wen-Kui Yu, Department of Critical Care Medicine, Nanjing Drum Tower Hospital, The Affiliated Hospital of Nanjing University Medical School, Nanjing 210008, Jiangsu Province, China

Corresponding author: Wen-Kui Yu, DSc, MD, PhD, Chief Doctor, Department of Critical Care Medicine, Nanjing Drum Tower Hospital, The Affiliated Hospital of Nanjing University Medical School, No. 321 Zhongshan Road, Nanjing 210008, Jiangsu Province, China. yudrnj@163.com

Abstract

BACKGROUND

Massive pulmonary haemorrhage can spoil the entire lung and block the airway in a short period of time due to severe bleeding, which quickly leads to death. Alveolar lavage is an effective method for haemostasis and airway maintenance. However, patients often cannot tolerate alveolar lavage due to severe hypoxia. We used extracorporeal membrane oxygenation (ECMO) to overcome this limitation in a patient with massive pulmonary haemorrhage due to severe trauma and succeeded in saving the life by repeated alveolar lavage.

CASE SUMMARY

A 22-year-old man sustained multiple injuries in a motor vehicle accident and was transferred to our emergency department. On admission, he had a slight cough and a small amount of bloody sputum; computed tomography revealed multiple fractures and mild pulmonary contusion. At 37 h after admission, he developed severe chest tightness, chest pain, dizziness and haemoptysis. His oxygen saturation was 68%. Emergency endotracheal intubation was performed, and a large amount of bloody sputum was suctioned. After transfer to the intensive care unit, he developed refractory hypoxemia and heparin-free venovenous ECMO was initiated. Fiberoptic bronchoscopy revealed diffuse and profuse blood in all bronchopulmonary segment. Bleeding was observed in the trachea and right bronchus, and repeated alveolar lavage was performed. On day 3, the patient's haemoptysis ceased, and ECMO support was terminated 10 d later. Tracheostomy was performed on day 15, and the patient was weaned from the ventilator on day 21.

CONCLUSION

Open-Access: This article is an open-access article that was selected by an in-house editor and fully peer-reviewed by external reviewers. It is distributed in accordance with the Creative Commons Attribution NonCommercial (CC BY-NC 4.0) license, which permits others to distribute, remix, adapt, build upon this work non-commercially, and license their derivative works on different terms, provided the original work is properly cited and the use is non-commercial. See: <http://creativecommons.org/licenses/by-nc/4.0/>

Received: April 13, 2020

Peer-review started: April 13, 2020

First decision: July 25, 2020

Revised: July 31, 2020

Accepted: August 15, 2020

Article in press: August 15, 2020

Published online: September 26, 2020

P-Reviewer: Ciccone MM, Pereira-Vega A

S-Editor: Yan JP

L-Editor: Filipodia

P-Editor: Li JH



Alveolar lavage combined with ECMO can control bleeding in trauma-induced massive pulmonary haemorrhage, is safe and can be performed bedside.

Key Words: Pulmonary contusion; Massive pulmonary haemorrhage; Alveolar lavage; Extracorporeal membrane oxygenation; Case report

©The Author(s) 2020. Published by Baishideng Publishing Group Inc. All rights reserved.

Core Tip: Massive pulmonary haemorrhage due to trauma is a rare but life-threatening form of pulmonary contusion. In this work, we report a patient who presented with progressive massive pulmonary haemorrhage that was successfully treated with repeated alveolar lavage combined with extracorporeal membrane oxygenation. Our study indicates the efficacy of a novel option for the treatment of massive pulmonary haemorrhage. Moreover, we discuss the medication regimen of alveolar lavage and the management of heparin-free extracorporeal membrane oxygenation.

Citation: Zhang BY, Chen XC, You Y, Chen M, Yu WK. Massive pulmonary haemorrhage due to severe trauma treated with repeated alveolar lavage combined with extracorporeal membrane oxygenation: A case report. *World J Clin Cases* 2020; 8(18): 4245-4251

URL: <https://www.wjgnet.com/2307-8960/full/v8/i18/4245.htm>

DOI: <https://dx.doi.org/10.12998/wjcc.v8.i18.4245>

INTRODUCTION

Severe trauma is a leading cause of death among young adults worldwide and is often complicated by pulmonary contusion (PC)^[1], which is defined as the destruction of the lung parenchyma by blunt force trauma to the chest and pulmonary haemorrhage due to pulmonary vascular injury. Approximately 10%-35% cases of trauma are complicated by PC^[2,3]. Massive pulmonary haemorrhage due to trauma is a rare but life-threatening form of PC that often manifests as marked dyspnoea, tachypnoea and haemoptysis within hours of the trauma. Massive pulmonary haemorrhage can destroy the entire lung, and the severe bleeding can cause rapid blockage of the airway resulting in severe hypoxia and shock or even death. Therefore, simultaneous respiratory maintenance and bleeding control is the main principle of treatment for massive pulmonary haemorrhage^[4].

Flexible bronchoscopes have become more advanced over the last two decades. Because of its relative safety and bedside availability, flexible bronchoscopy has become a common method for localizing the bleeding sites and controlling bleeding for mild to moderate haemoptysis^[5]. However, the use of flexible bronchoscopes in the treatment of massive pulmonary haemorrhage in severe trauma patients, to our knowledge, has never been reported. One main reason is that such patients cannot tolerate alveolar lavage due to severe hypoxemia. Therefore, we used repeated alveolar lavage combined with extracorporeal membrane oxygenation (ECMO) to overcome this limitation and successfully treat a patient with massive pulmonary haemorrhage.

CASE PRESENTATION

Chief complaints

A 22-year-old man was admitted to our emergency department following a road traffic accident and presented with a slight cough and a small amount of bloody sputum. Approximately 37 h after admission, he developed severe chest tightness, chest pain, dizziness and haemoptysis. His was 178 cm in height and 82 kg in weight.

History of present illness

The patient experienced multiple traumas when his motorcycle collided with a truck. On admission to our emergency department, he was conscious and had a slight cough and a small amount of bloody sputum. His blood pressure and breathing were stable,

with an oxygen saturation (SpO_2) of 95%-97% at 5 L/min of mask O_2 . Whole-body computed tomography (CT) showed a left fifth rib fracture and mild PC (Figure 1A) as well as fractures to the left clavicle and scapula, pubis, left femoral shaft and right ulna. After plaster fixation of his right upper arm, he was admitted 18 h after the onset of mild PC to the orthopaedic ward for further surgical treatment. There he received an analgesic, antibiotics and left tibial tuberosity traction treatment. However, he developed severe chest tightness, chest pain, dizziness and haemoptysis 19 h later. Clinical examination revealed severe hypoxia with an SpO_2 of 68%, tachypnoea (respiratory rate: 36 breaths/min) and tachycardia (heart rate: 157 bpm). Endotracheal intubation was subsequently performed, and a large amount of bloody sputum was suctioned from the endotracheal tube. The patient was transferred to the intensive care unit (ICU) 15 min later.

History of past illness

The patient was free of relevant medical history.

Physical examination

When transferred to the ICU, the patient received volume-controlled ventilation and the following parameters were set: Fraction of inspired oxygen, 100%; positive end-expiratory pressure, 15 cm H_2O ; tidal volume, 420 mL (6 mL/kg); and respiratory rate, 20 breaths/min. The patient was maintained under deep sedation (Richmond Agitation-Sedation Scale: -3 to -4) to reduce respiratory distress, and a lung recruitment manoeuvre was performed to open his airways. Nevertheless, he developed refractory hypoxemia (SpO_2 : 78%) and hypotension (invasive blood pressure: 10.5/5.5 kPa). Physical examination revealed coarse, moist rales that pervaded the lung. No apparent abnormalities were found in the heart or abdomen. Both legs were deformed and swollen, and multiple skin abrasions were observed all over his body.

Laboratory examinations

Arterial blood gas analysis revealed a pH of 7.44, partial pressure of CO_2 of 5.2 kPa and partial pressure of O_2 of 7.9 kPa. Routine blood examination indicated mild leucocytosis (15.3×10^9 cells/L) and a reduction in haemoglobin (from 12.3 g/dL at admission to 10.3 g/dL after transfer to the ICU). Coagulation function test results showed a normal prothrombin time, activated partial thromboplastin time and thrombin time; however, his fibrinogen level was low (1.4 g/L). Biochemical examination revealed a glutamate transaminase level of 74.2 U/L and glutamate transaminase level of 44.9 U/L, indicating slightly abnormal liver function.

Imaging examinations

Bedside chest X-ray showed diffuse infiltration on both sides (Figure 2A). After ECMO was established, chest CT and pulmonary artery imaging were performed, at which point there was no evidence of a pulmonary embolism, but substantial consolidation was noted in both lungs (Figure 1B). Fibreoptic bronchoscopy revealed diffuse and profuse blood in all bronchopulmonary segments and fresh bleeding was observed in the trachea and right bronchus.

FINAL DIAGNOSIS

Massive pulmonary haemorrhage, acute respiratory distress syndrome, hypovolemic shock, multiple trauma, PC, left rib fracture, left clavicle fracture, left scapula fracture, pubis fracture, left femoral shaft fracture, right ulna fracture and mild liver injury.

TREATMENT

After the patient was transferred to the ICU, we established venovenous ECMO and performed cannulation *via* the right jugular vein (17-Fr cannula for inflow, Rastatt, Germany) and the right femoral vein (21-Fr cannula for outflow, Rastatt, Germany) simultaneously. After we established heparin-free venovenous ECMO (3500 rpm; pump flow, 4 L/min; O_2 flow, 4 L/min), the patient's SpO_2 increased to 99%. The ventilator parameters were readjusted (fraction of inspired oxygen: 30%; positive end-expiratory pressure: 8 cm H_2O ; tidal volume: 380 mL; respiratory rate: 12/min) to

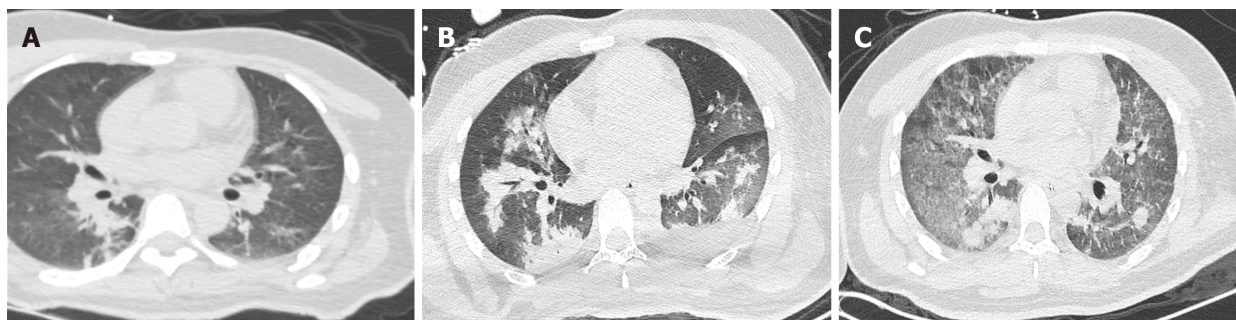


Figure 1 Changes in chest computed tomography. A: The chest computed tomography (CT) on admission showed mild pulmonary contusion on both sides of the lung; B: The chest CT after intubation and support of extracorporeal membrane oxygenation (ECMO) revealed substantial consolidation in both lungs; C: The chest CT on the second day after the termination of ECMO showed resolution of the lung consolidation.

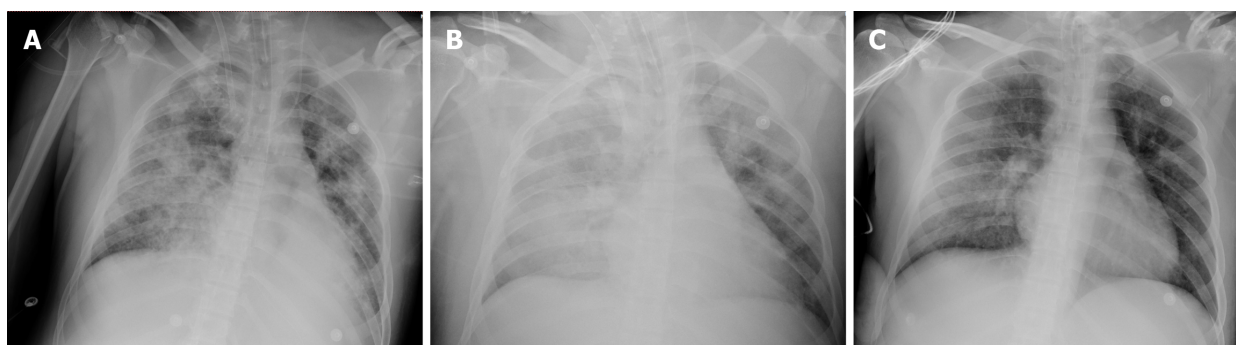


Figure 2 Changes in bedside chest X-ray. A: The bedside chest X-ray after intubation showed diffuse infiltration in both sides of the lung; B: The bedside chest X-ray on day 3 after admission to the intensive care unit revealed persistent, severe diffuse infiltration of both the lungs; C: The bedside chest X-ray on the day before the termination of extracorporeal membrane oxygenation showed significantly decreased lung infiltration.

reduce the risk of barotrauma. After chest CT and pulmonary artery imaging, therapeutic fiberoptic bronchoscopy was performed *via* endotracheal tube; this revealed diffuse and profuse blood in all bronchopulmonary segments. We suctioned the blood and performed alveolar lavage. Fresh bleeding was observed in the trachea and right bronchus. We repeated the cold saline lavage together with topical application of epinephrine (1:20000) and allowed the cold saline to remain within the bronchopulmonary segments on the right side for a few seconds. We continued to administer repeated alveolar lavage (once per day with 150 mL cold saline each time), antibiotic therapy, glucocorticoids and enteral nutrition. Bloody sputum was alleviated, and norepinephrine was discontinued on day 3. However, bedside chest X-ray revealed persistent, severe diffuse infiltration of both lungs (Figure 2B). We reduced the frequency of alveolar lavage (to every second day), performed negative fluid balance therapy and continued to perform ECMO without heparin. The patient's D-dimer level gradually increased to 18.4 mg/L (Figure 3). On day 9, a large blood clot was found inside the microporous membrane oxygenator, and the O₂ pressure of the blood drawn from behind the oxygenator was 11.2 kPa; hence, ECMO was replaced.

OUTCOME AND FOLLOW-UP

On day 13, fiberoptic bronchoscopy revealed blood clots on the bronchial wall but no active bleeding. Bedside chest X-ray showed significantly decreased lung infiltration (Figure 2C); thus, ECMO support was terminated on day 13. On the second day after ECMO termination (day 15), we performed another chest CT scan, which revealed further dissipation of lung consolidation (Figure 1C). Tracheostomy was performed on day 15, and the patient was weaned from the ventilator on day 21. He then returned to the orthopaedic ward and underwent surgery for his left clavicle, left femur and right ulna. The patient was discharged 1 wk later. The changes in PC and the course of treatment are presented in Table 1.

Table 1 Timeline

Date	April 2, 2019	April 3, 2019	April 15, 2019	April 23, 2019
Diagnosis and treatment of PC	Chest CT scan showed mild PC	MV combined with ECMO to maintain oxygenation; Chest CT scan showed substantial consolidation; Bronchoscopy revealed diffuse pulmonary haemorrhage; Alveolar lavage combined with ECMO were performed	Fibreoptic bronchoscopy found no active bleeding; ECMO support was terminated; Chest CT scan indicated consolidation dissipation	The patient was weaned from the ventilator

CT: Computed tomography; ECMO: Extracorporeal membrane oxygenation; MV: Mechanical ventilation; PC: Pulmonary contusion.

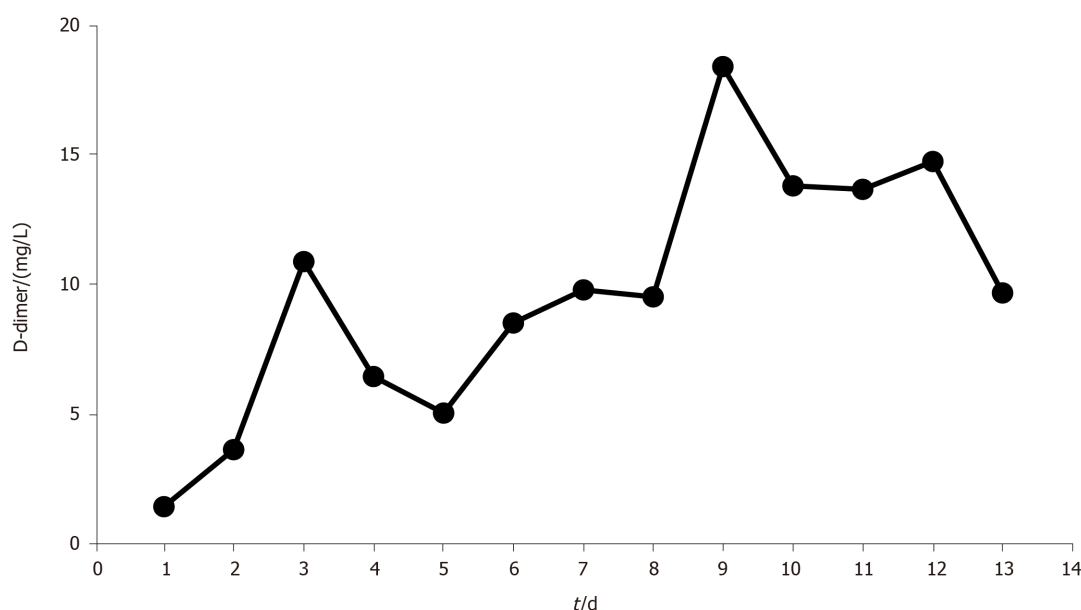


Figure 3 Trend of the D-dimer level during extracorporeal membrane oxygenation. The D-dimer level gradually increased until the extracorporeal membrane oxygenation was replaced on day 9 and then decreased.

DISCUSSION

This is the first report describing a case of severe PC (presenting as massive pulmonary haemorrhage) that was successfully treated with repeated alveolar lavage combined with ECMO. PC caused by severe trauma is a major clinical challenge and may be fatal; trauma patients with PC have a significantly higher mortality rate than trauma patients without PC^[6]. The pathological findings range from radiographic findings without clinical manifestations to respiratory failure requiring intubation and mechanical ventilation depending on the extent of the contusion and affected alveolar area. Massive pulmonary haemorrhage due to trauma is a rare but life-threatening form of PC. Severe hypovolemic shock from uncontrolled bleeding and respiratory failure due to airway obstruction caused by blood clots are the main causes of death. Maintenance of adequate oxygenation and bleeding control should be performed simultaneously to rescue life in cases of massive pulmonary haemorrhage.

Fibreoptic bronchoscopy plays an important role in the management of mild to moderate haemoptysis because it is relatively safe and can be performed at the patient's bedside^[5]. However, fibreoptic bronchoscopy is rarely applied in patients with massive pulmonary haemorrhage due to poor tolerance. Bronchoscopy can be used to localize the bleeding sites and clear the airways of blood to prevent infection and maintain adequate ventilation, particularly in the non-bleeding lung. More importantly, it supports the implementation of other endobronchial techniques such as alveolar lavage to control bleeding. Multiple agents, including cold saline, diluted epinephrine, ornipressin, terlipressin and tranexamic acid, are used to obtain haemostasis in alveolar lavage. Conlan *et al*^[7] used alveolar lavage with cold saline to treat 12 patients with severe haemoptysis within 24 h and achieved haemostasis in all 12 patients. However, one patient experienced transient bradycardia, and two experienced recurrent bleeding. Epinephrine has been used in cases of massive

haemoptysis to control bleeding; however, different doses and dilutions have been reported, from a 1:100000 solution to 20 mL of 1:20000 solution^[8]. Unfortunately, the haemostatic effect of diluted epinephrine (1:20000) is not effective because the drug is easily flushed out with bleeding. Even at dilutions as low as 1:20000, arrhythmia, ventricular fibrillation and hypotension have been reported to occur with the use of epinephrine^[9]. Tüller *et al*^[10] reported the endobronchial application of ornipressin and terlipressin in 30 patients with mild to moderate airway bleeding following transbronchial lung biopsy. Terlipressin caused significant changes in heart rate and blood pressure; however, ornipressin did not result in any adverse events. Tranexamic acid, a synthetic antifibrinolytic agent, can also be applied endobronchially to treat massive haemoptysis following transbronchial lung biopsy, but few case reports have described its use^[11,12].

Venovenous ECMO serves as the final recourse when conventional ventilation strategies fail to maintain oxygenation. This makes it possible to treat massive pulmonary haemorrhage with bronchoscopy. There have been a few case reports and small case series on the use of ECMO in trauma patients with various injury patterns, but mixed outcomes were reported^[13-16]. However, ECMO is not often used in trauma patients, largely because of concerns about the risk of haemorrhage. In recent years, with advances in ECMO equipment, including centrifugal pumps, heparin-coated circuits and polymethylpentene oxygenators, the need for anticoagulants and the risk of thrombosis have decreased. This has led to a growing body of evidence on the use of heparin-free ECMO in trauma patients^[17-20]. The longest reported duration of heparin-free venovenous ECMO in trauma patients is 11 d^[19]. To maintain heparin-free ECMO for as long as possible, there are three recommendations: (1) The blood flow should be set at > 1.5 L/min; most reports state that the blood flow was set at 4-5 L/min to prevent blood clots; (2) All clotting factors should be administered *via* a peripheral vein or postoxygenator rather than *via* a central vein to preserve the membrane oxygenator; and (3) Coagulation indicators (activated partial thromboplastin time, prothrombin time, activated clotting time of the whole blood and D-dimer) need to be continuously monitored. D-dimer monitoring is important because it is a more sensitive indicator of thrombus formation in the membrane oxygenator^[21]. Although the highest D-dimer level in our patient was lower than the cut-off value reported in the literature, his D-dimer levels steadily increased, and a large thrombus developed inside the membrane oxygenators on day 9. After the membrane oxygenators were exchanged, his D-dimer levels decreased. Regardless, heparin-free venovenous ECMO is not a first-line treatment option for respiratory failure in trauma patients with pulmonary haemorrhage due to the higher risk of thrombosis, bleeding and embolism. However, for patients with intractable hypoxemia due to trauma combined with massive pulmonary haemorrhage, ECMO is a highly effective rescue treatment option.

Our findings were merely a single case. In addition, ECMO requires an experienced team for rapid establishment, and this may be a challenge for some hospitals.

CONCLUSION

Massive pulmonary haemorrhage is a rare but life-threatening form of PC in trauma patients. Timely and effective control of bleeding and respiratory support therapy are vital to saving the patient's life. Applying alveolar lavage combined with ECMO could be an alternative and effective treatment in patients with massive pulmonary haemorrhage; moreover, this strategy is relatively safe and can be performed at the patient's bedside.

REFERENCES

- 1 Krug EG, Sharma GK, Lozano R. The global burden of injuries. *Am J Public Health* 2000; **90**: 523-526 [PMID: 10754963 DOI: 10.2105/ajph.90.4.523]
- 2 Hamrick MC, Duhn RD, Ochsner MG. Critical evaluation of pulmonary contusion in the early post-traumatic period: risk of assisted ventilation. *Am Surg* 2009; **75**: 1054-1058 [PMID: 19927504 DOI: 10.1177/000313480907501105]
- 3 Jin H, Tang LQ, Pan ZG, Peng N, Wen Q, Tang YQ, Su L. Ten-year retrospective analysis of multiple trauma complicated by pulmonary contusion. *Mil Med Res* 2014; **1**: 7 [PMID: 25722865 DOI: 10.1186/2054-9369-1-7]
- 4 Crocco JA, Rooney JJ, Fankushen DS, DiBenedetto RJ, Lyons HA. Massive hemoptysis. *Arch Intern Med* 1968; **121**: 495-498 [PMID: 5652400 DOI: 10.1001/archinte.1968.03640060009002]

- 5 **Gavelli F**, Patrucco F, Statti G, Balbo PE. Mild-to-moderate hemoptysis: a diagnostic and clinical challenge. *Minerva Med* 2018; **109**: 239-247 [PMID: 29458243 DOI: 10.23736/S0026-4806.18.05576-3]
- 6 **Gayzik FS**, Martin RS, Gabler HC, Hoth JJ, Duma SM, Meredith JW, Stitzel JD. Characterization of crash-induced thoracic loading resulting in pulmonary contusion. *J Trauma* 2009; **66**: 840-849 [PMID: 19276763 DOI: 10.1097/TA.0b013e318186251e]
- 7 **Conlan AA**, Hurwitz SS. Management of massive haemoptysis with the rigid bronchoscope and cold saline lavage. *Thorax* 1980; **35**: 901-904 [PMID: 7268664 DOI: 10.1136/thx.35.12.901]
- 8 **Radchenko C**, Alraiyes AH, Shojaee S. A systematic approach to the management of massive hemoptysis. *J Thorac Dis* 2017; **9** Suppl 10: S1069-S1086 [PMID: 29214066 DOI: 10.21037/jtd.2017.06.41]
- 9 **Steinfort DP**, Herth FJ, Eberhardt R, Irving LB. Potentially fatal arrhythmia complicating endobronchial epinephrine for control of iatrogenic bleeding. *Am J Respir Crit Care Med* 2012; **185**: 1028-1030 [PMID: 22550217 DOI: 10.1164/ajrccm.185.9.1028]
- 10 **Tüller C**, Tüller D, Tamm M, Brutsche MH. Hemodynamic effects of endobronchial application of ornipressin versus terlipressin. *Respiration* 2004; **71**: 397-401 [PMID: 15316215 DOI: 10.1159/000079646]
- 11 **Zamani A**. Bronchoscopic intratumoral injection of tranexamic acid: a new technique for control of biopsy-induced bleeding. *Blood Coagul Fibrinolysis* 2011; **22**: 440-442 [PMID: 21577092 DOI: 10.1097/MBC.0b013e328346efb7]
- 12 **Hurley M**, Bhatt J, Smyth A. Treatment massive haemoptysis in cystic fibrosis with tranexamic acid. *J R Soc Med* 2011; **104** Suppl 1: S49-S52 [PMID: 21719894 DOI: 10.1258/jrsm.2011.s11109]
- 13 **Ried M**, Bein T, Philipp A, Müller T, Graf B, Schmid C, Zonies D, Diez C, Hofmann HS. Extracorporeal lung support in trauma patients with severe chest injury and acute lung failure: a 10-year institutional experience. *Crit Care* 2013; **17**: R110 [PMID: 23786965 DOI: 10.1186/cc12782]
- 14 **Hill JD**, O'Brien TG, Murray JJ, Dontigny L, Bramson ML, Osborn JJ, Gerbode F. Prolonged extracorporeal oxygenation for acute post-traumatic respiratory failure (shock-lung syndrome). Use of the Bramson membrane lung. *N Engl J Med* 1972; **286**: 629-634 [PMID: 5060491 DOI: 10.1056/NEJM197203232861204]
- 15 **Madershahian N**, Wittwer T, Strauch J, Franke UF, Wippermann J, Kaluza M, Wahlers T. Application of ECMO in multitrauma patients with ARDS as rescue therapy. *J Card Surg* 2007; **22**: 180-184 [PMID: 17488410 DOI: 10.1111/j.1540-8191.2007.00381.x]
- 16 **Wu MY**, Lin PJ, Tseng YH, Kao KC, Hsiao HL, Huang CC. Venovenous extracorporeal life support for posttraumatic respiratory distress syndrome in adults: the risk of major hemorrhages. *Scand J Trauma Resusc Emerg Med* 2014; **22**: 56 [PMID: 25273618 DOI: 10.1186/s13049-014-0056-0]
- 17 **Lorini FL**, Grazioli L, Manfredi R, Rausa E, Ghitti D, Poli G, Peck M, Cattaneo S. A prolonged and successful heparin-free extracorporeal membrane oxygenation run in isolated thoracic trauma: A case report. *Int J Artif Organs* 2020; **43**: 288-291 [PMID: 31702412 DOI: 10.1177/0391398819887400]
- 18 **Ryu KM**, Chang SW. Heparin-free extracorporeal membrane oxygenation in a patient with severe pulmonary contusions and bronchial disruption. *Clin Exp Emerg Med* 2018; **5**: 204-207 [PMID: 29706054 DOI: 10.15441/ceem.17.252]
- 19 **Park JM**, Kim CW, Cho HM, Son BS, Kim DH. Induced airway obstruction under extracorporeal membrane oxygenation during treatment of life-threatening massive hemoptysis due to severe blunt chest trauma. *J Thorac Dis* 2014; **6**: E255-E258 [PMID: 25590003 DOI: 10.3978/j.issn.2072-1439.2014.10.22]
- 20 **Wen PH**, Chan WH, Chen YC, Chen YL, Chan CP, Lin PY. Non-heparinized ECMO serves a rescue method in a multitrauma patient combining pulmonary contusion and nonoperative internal bleeding: a case report and literature review. *World J Emerg Surg* 2015; **10**: 15 [PMID: 25774211 DOI: 10.1186/s13017-015-0006-9]
- 21 **Dornia C**, Philipp A, Bauer S, Stroszczynski C, Schreyer AG, Müller T, Koehl GE, Lehle K. D-dimers Are a Predictor of Clot Volume Inside Membrane Oxygenators During Extracorporeal Membrane Oxygenation. *Artif Organs* 2015; **39**: 782-787 [PMID: 25845704 DOI: 10.1111/aor.12460]



Published by **Baishideng Publishing Group Inc**
7041 Koll Center Parkway, Suite 160, Pleasanton, CA 94566, USA

Telephone: +1-925-3991568

E-mail: bpgoffice@wjgnet.com

Help Desk: <https://www.f6publishing.com/helpdesk>

<https://www.wjgnet.com>

