

World Journal of *Clinical Cases*

World J Clin Cases 2020 October 6; 8(19): 4280-4687



Contents

Semimonthly Volume 8 Number 19 October 6, 2020

OPINION REVIEW

- 4280 Role of monoclonal antibody drugs in the treatment of COVID-19
Ucciferri C, Vecchiet J, Falasca K

MINIREVIEWS

- 4286 Review of simulation model for education of point-of-care ultrasound using easy-to-make tools
Shin KC, Ha YR, Lee SJ, Ahn JH
- 4303 Liver injury in COVID-19: A minireview
Zhao JN, Fan Y, Wu SD

ORIGINAL ARTICLE

Case Control Study

- 4311 Transanal minimally invasive surgery *vs* endoscopic mucosal resection for rectal benign tumors and rectal carcinoids: A retrospective analysis
Shen JM, Zhao JY, Ye T, Gong LF, Wang HP, Chen WJ, Cai YK
- 4320 Impact of *mTOR* gene polymorphisms and gene-tea interaction on susceptibility to tuberculosis
Wang M, Ma SJ, Wu XY, Zhang X, Abesig J, Xiao ZH, Huang X, Yan HP, Wang J, Chen MS, Tan HZ

Retrospective Cohort Study

- 4331 Establishment and validation of a nomogram to predict the risk of ovarian metastasis in gastric cancer: Based on a large cohort
Li SQ, Zhang KC, Li JY, Liang WQ, Gao YH, Qiao Z, Xi HQ, Chen L

Retrospective Study

- 4342 Predictive factors for early clinical response in community-onset *Escherichia coli* urinary tract infection and effects of initial antibiotic treatment on early clinical response
Kim YJ, Lee JM, Lee JH
- 4349 Managing acute appendicitis during the COVID-19 pandemic in Jiaying, China
Zhou Y, Cen LS
- 4360 Clinical application of combined detection of SARS-CoV-2-specific antibody and nucleic acid
Meng QB, Peng JJ, Wei X, Yang JY, Li PC, Qu ZW, Xiong YF, Wu GJ, Hu ZM, Yu JC, Su W
- 4370 Prolonged prothrombin time at admission predicts poor clinical outcome in COVID-19 patients
Wang L, He WB, Yu XM, Hu DL, Jiang H

- 4380** Percutaneous radiofrequency ablation is superior to hepatic resection in patients with small hepatocellular carcinoma

Zhang YH, Su B, Sun P, Li RM, Peng XC, Cai J

- 4388** Clinical study on the surgical treatment of atypical Lisfranc joint complex injury

Li X, Jia LS, Li A, Xie X, Cui J, Li GL

- 4400** Application of medial column classification in treatment of intra-articular calcaneal fractures

Zheng G, Xia F, Yang S, Cui J

Clinical Trials Study

- 4410** Optimal hang time of enteral formula at standard room temperature and high temperature

Lakananurak N, Nalinthassanai N, Suansawang W, Panarat P

META-ANALYSIS

- 4416** Meta-analysis reveals an association between acute pancreatitis and the risk of pancreatic cancer

Liu J, Wang Y, Yu Y

SCIENTOMETRICS

- 4431** Global analysis of daily new COVID-19 cases reveals many static-phase countries including the United States potentially with unstoppable epidemic

Long C, Fu XM, Fu ZF

CASE REPORT

- 4443** Left atrial appendage aneurysm: A case report

Belov DV, Moskalev VI, Garbuzenko DV, Arefyev NO

- 4450** Twenty-year survival after iterative surgery for metastatic renal cell carcinoma: A case report and review of literature

De Raffele E, Mirarchi M, Casadei R, Ricci C, Brunocilla E, Minni F

- 4466** Primary rhabdomyosarcoma: An extremely rare and aggressive variant of male breast cancer

Satală CB, Jung I, Bara TJ, Simu P, Simu I, Vlad M, Szodorai R, Gurzu S

- 4475** Bladder stones in a closed diverticulum caused by *Schistosoma mansoni*: A case report

Alkhamees MA

- 4481** Cutaneous ciliated cyst on the anterior neck in young women: A case report

Kim YH, Lee J

- 4488** Extremely rare case of successful treatment of metastatic ovarian undifferentiated carcinoma with high-dose combination cytotoxic chemotherapy: A case report

Kim HB, Lee HJ, Hong R, Park SG

- 4494** Acute amnesia during pregnancy due to bilateral fornix infarction: A case report
Cho MJ, Shin DI, Han MK, Yum KS
- 4499** Ascaris-mimicking common bile duct stone: A case report
Choi SY, Jo HE, Lee YN, Lee JE, Lee MH, Lim S, Yi BH
- 4505** Eight-year follow-up of locally advanced lymphoepithelioma-like carcinoma at upper urinary tract: A case report
Yang CH, Weng WC, Lin YS, Huang LH, Lu CH, Hsu CY, Ou YC, Tung MC
- 4512** Spontaneous resolution of idiopathic intestinal obstruction after pneumonia: A case report
Zhang BQ, Dai XY, Ye QY, Chang L, Wang ZW, Li XQ, Li YN
- 4521** Successful pregnancy after protective hemodialysis for chronic kidney disease: A case report
Wang ML, He YD, Yang HX, Chen Q
- 4527** Rapid remission of refractory synovitis, acne, pustulosis, hyperostosis, and osteitis syndrome in response to the Janus kinase inhibitor tofacitinib: A case report
Li B, Li GW, Xue L, Chen YY
- 4535** Percutaneous fixation of neonatal humeral physeal fracture: A case report and review of the literature
Tan W, Wang FH, Yao JH, Wu WP, Li YB, Ji YL, Qian YP
- 4544** Severe fundus lesions induced by ocular jellyfish stings: A case report
Zheng XY, Cheng DJ, Lian LH, Zhang RT, Yu XY
- 4550** Application of ozonated water for treatment of gastro-thoracic fistula after comprehensive esophageal squamous cell carcinoma therapy: A case report
Wu DD, Hao KN, Chen XJ, Li XM, He XF
- 4558** Germinomas of the basal ganglia and thalamus: Four case reports
Huang ZC, Dong Q, Song EP, Chen ZJ, Zhang JH, Hou B, Lu ZQ, Qin F
- 4565** Gastrointestinal bleeding caused by jejunal angiosarcoma: A case report
Hui YY, Zhu LP, Yang B, Zhang ZY, Zhang YJ, Chen X, Wang BM
- 4572** High expression of squamous cell carcinoma antigen in poorly differentiated adenocarcinoma of the stomach: A case report
Wang L, Huang L, Xi L, Zhang SC, Zhang JX
- 4579** Therapy-related acute promyelocytic leukemia with FMS-like tyrosine kinase 3-internal tandem duplication mutation in solitary bone plasmacytoma: A case report
Hong LL, Sheng XF, Zhuang HF
- 4588** Metastasis of esophageal squamous cell carcinoma to the thyroid gland with widespread nodal involvement: A case report
Zhang X, Gu X, Li JG, Hu XJ

- 4595** Severe hyperlipemia-induced pseudoerythrocytosis - Implication for misdiagnosis and blood transfusion: A case report and literature review
Zhao XC, Ju B, Wei N, Ding J, Meng FJ, Zhao HG
- 4603** Novel brachytherapy drainage tube loaded with double 125I strands for hilar cholangiocarcinoma: A case report
Lei QY, Jiao DC, Han XW
- 4609** Resorption of upwardly displaced lumbar disk herniation after nonsurgical treatment: A case report
Wang Y, Liao SC, Dai GG, Jiang L
- 4615** Primary hepatic myelolipoma: A case report and review of the literature
Li KY, Wei AL, Li A
- 4624** Endoscopic palliative resection of a giant 26-cm esophageal tumor: A case report
Li Y, Guo LJ, Ma YC, Ye LS, Hu B
- 4633** Solitary hepatic lymphangioma mimicking liver malignancy: A case report and literature review
Long X, Zhang L, Cheng Q, Chen Q, Chen XP
- 4644** Intraosseous venous malformation of the maxilla after enucleation of a hemophilic pseudotumor: A case report
Cai X, Yu JJ, Tian H, Shan ZF, Liu XY, Jia J
- 4652** Intravesically instilled gemcitabine-induced lung injury in a patient with invasive urothelial carcinoma: A case report
Zhou XM, Wu C, Gu X
- 4660** Bochdalek hernia masquerading as severe acute pancreatitis during the third trimester of pregnancy: A case report
Zou YZ, Yang JP, Zhou XJ, Li K, Li XM, Song CH
- 4667** Localized primary gastric amyloidosis: Three case reports
Liu XM, Di LJ, Zhu JX, Wu XL, Li HP, Wu HC, Tuo BG
- 4676** Displacement of peritoneal end of a shunt tube to pleural cavity: A case report
Liu J, Guo M
- 4681** Parathyroid adenoma combined with a rib tumor as the primary disease: A case report
Han L, Zhu XF

ABOUT COVER

Peer-reviewer of *World Journal of Clinical Cases*, Prof. Adrián Ángel Inchauspe, obtained his MD in 1986 from La Plata National University (Argentina), where he remained as Professor of Surgery. Study abroad, at the Aachen and Tübingen Universities in Germany in 1991, led to his certification in laparoscopic surgery, and at the Louis Pasteur University in Strasbourg France, led to his being awarded the Argentine National Invention Award in 1998 for his graduate work in tele-surgery. He currently serves as teacher in the Argentine Acupuncture Society, as Invited Foreigner Professor at the China National Academy of Sciences and Hainan Medical University, and as editorial member and reviewer for many internationally renowned journals. (L-Editor: Filipodia)

AIMS AND SCOPE

The primary aim of *World Journal of Clinical Cases* (*WJCC*, *World J Clin Cases*) is to provide scholars and readers from various fields of clinical medicine with a platform to publish high-quality clinical research articles and communicate their research findings online.

WJCC mainly publishes articles reporting research results and findings obtained in the field of clinical medicine and covering a wide range of topics, including case control studies, retrospective cohort studies, retrospective studies, clinical trials studies, observational studies, prospective studies, randomized controlled trials, randomized clinical trials, systematic reviews, meta-analysis, and case reports.

INDEXING/ABSTRACTING

The *WJCC* is now indexed in Science Citation Index Expanded (also known as SciSearch®), Journal Citation Reports/Science Edition, PubMed, and PubMed Central. The 2020 Edition of Journal Citation Reports® cites the 2019 impact factor (IF) for *WJCC* as 1.013; IF without journal self cites: 0.991; Ranking: 120 among 165 journals in medicine, general and internal; and Quartile category: Q3.

RESPONSIBLE EDITORS FOR THIS ISSUE

Production Editor: Yan-Xia Xing; Production Department Director: Yun-Xiaojuan Wu; Editorial Office Director: Jin-Lai Wang.

NAME OF JOURNAL

World Journal of Clinical Cases

ISSN

ISSN 2307-8960 (online)

LAUNCH DATE

April 16, 2013

FREQUENCY

Semimonthly

EDITORS-IN-CHIEF

Dennis A Bloomfield, Sandro Vento, Bao-Gan Peng

EDITORIAL BOARD MEMBERS

<https://www.wjgnet.com/2307-8960/editorialboard.htm>

PUBLICATION DATE

October 6, 2020

COPYRIGHT

© 2020 Baishideng Publishing Group Inc

INSTRUCTIONS TO AUTHORS

<https://www.wjgnet.com/bpg/gerinfo/204>

GUIDELINES FOR ETHICS DOCUMENTS

<https://www.wjgnet.com/bpg/GerInfo/287>

GUIDELINES FOR NON-NATIVE SPEAKERS OF ENGLISH

<https://www.wjgnet.com/bpg/gerinfo/240>

PUBLICATION ETHICS

<https://www.wjgnet.com/bpg/GerInfo/288>

PUBLICATION MISCONDUCT

<https://www.wjgnet.com/bpg/gerinfo/208>

ARTICLE PROCESSING CHARGE

<https://www.wjgnet.com/bpg/gerinfo/242>

STEPS FOR SUBMITTING MANUSCRIPTS

<https://www.wjgnet.com/bpg/GerInfo/239>

ONLINE SUBMISSION

<https://www.f6publishing.com>

Severe fundus lesions induced by ocular jellyfish stings: A case report

Xiang-Yue Zheng, De-Jin Cheng, Li-Hua Lian, Ru-Ting Zhang, Xiao-Yi Yu

ORCID number: Xiang-Yue Zheng 0000-0001-8190-3022; De-Jin Cheng 0000-0002-7407-0197; Li-Hua Lian 0000-0001-9688-8179; Ru-Ting Zhang 0000-0002-3466-0897; Xiao-Yi Yu 0000-0001-9013-0041.

Author contributions: Zheng XY and Cheng DJ reviewed the literature and contributed to manuscript drafting; Lian LH collected the clinical data; Yu XY and Zhang RT were responsible for revision of the manuscript; all authors issued final approval for the version to be submitted.

Informed consent statement: Informed written consent was obtained from the patient for publication of this report and any accompanying images.

Conflict-of-interest statement: The authors declare that they have no conflict of interest.

CARE Checklist (2016) statement: The authors have read the CARE Checklist (2016), and the manuscript was prepared and revised according to the CARE Checklist (2016).

Open-Access: This article is an open-access article that was selected by an in-house editor and fully peer-reviewed by external reviewers. It is distributed in accordance with the Creative

Xiang-Yue Zheng, Li-Hua Lian, Ru-Ting Zhang, Xiao-Yi Yu, Department of Ophthalmology, First Affiliated Hospital of Guangzhou University of Chinese Medicine, Guangzhou 510405, Guangdong Province, China

De-Jin Cheng, Department of Nephrology, First Affiliated Hospital of Guangzhou University of Chinese Medicine, Guangzhou 510405, Guangdong Province, China

Corresponding author: Xiao-Yi Yu, PhD, Doctor, Professor, Department of Ophthalmology, First Affiliated Hospital of Guangzhou University of Chinese Medicine, No. 16 Yard, Road Street, Baiyun District, Guangzhou 510405, Guangdong Province, China.
yxy741107@126.com

Abstract

BACKGROUND

Globally, although the jellyfish population has increased in recent years, ocular jellyfish stings remain an uncommon ophthalmic emergency, and have been rarely reported. According to a few previous reports, ocular jellyfish stings may cause anterior segment disorders, and most of these injuries were self-limited and spontaneously resolved within 24 to 48 h.

CASE SUMMARY

A brother and sister both presented with severe fundus complications several years after ocular jellyfish stings and both had prolonged blurred vision. To our knowledge, such fundus lesions induced by jellyfish stings have not been reported previously.

CONCLUSION

The fundus status of patients following ocular jellyfish stings should be carefully monitored in cases of irreversible ocular damage.

Key Words: Ocular jellyfish stings; Fundus lesions; Complications; Prolonged blurred vision; Case report

©The Author(s) 2020. Published by Baishideng Publishing Group Inc. All rights reserved.

Core Tip: Ocular jellyfish stings may cause severe fundus complications and result in prolonged blurred vision, which is different from previous reports on jellyfish injuries.

Commons Attribution NonCommercial (CC BY-NC 4.0) license, which permits others to distribute, remix, adapt, build upon this work non-commercially, and license their derivative works on different terms, provided the original work is properly cited and the use is non-commercial. See: <http://creativecommons.org/licenses/by-nc/4.0/>

Manuscript source: Unsolicited manuscript

Received: April 15, 2020

Peer-review started: April 15, 2020

First decision: July 25, 2020

Revised: August 4, 2020

Accepted: August 20, 2020

Article in press: August 20, 2020

Published online: October 6, 2020

P-Reviewer: Vagholkar K

S-Editor: Zhang L

L-Editor: Webster JR

P-Editor: Ma YJ



Citation: Zheng XY, Cheng DJ, Lian LH, Zhang RT, Yu XY. Severe fundus lesions induced by ocular jellyfish stings: A case report. *World J Clin Cases* 2020; 8(19): 4544-4549

URL: <https://www.wjgnet.com/2307-8960/full/v8/i19/4544.htm>

DOI: <https://dx.doi.org/10.12998/wjcc.v8.i19.4544>

INTRODUCTION

Jellyfish are distributed in oceans and coastal zones worldwide. They consist of a bell-shaped body and several tentacles which contain nematocysts. The nematocysts contain venom which is toxic to humans^[1]. The venom can cause potential systemic symptoms including gastrointestinal, muscular, cardiac, neurological and allergic manifestations when the toxins enter the general circulation^[2]. In addition, the venom is also toxic to ocular tissue and can cause conjunctiva injection, punctate epithelial keratitis, corneal stromal edema, endothelial cell swelling, mild anterior chamber flare, atypical severe iritis and increased intraocular pressure^[3-6]. However, ocular fundus disease caused by jellyfish stings has not yet been reported.

Here we report two patients who developed severe fundus complications including optic atrophy, retinal vascular occlusion, thinning of the retina and scar formation in the macular area after ocular jellyfish stings.

CASE PRESENTATION

Chief complaints

A 13-year-old boy accompanied by his father and sister, presented to the Ophthalmology Department in August 2019, complaining of conjunctival injection and blurred vision in his right eye for more than a year.

History of present illness

He had suffered a jellyfish sting in the right eye about two years ago, and experienced severe pain in his right eye and decreased visual acuity after the accident. After a short-term treatment (irrigation of the conjunctiva with normal saline, eye drops and oral drugs), the pain disappeared, but his best corrected visual acuity (BCVA) did not recover. His parents were unaware of his injury; thus, he did not receive any further treatment, and his vision gradually decreased.

History of past illness

His elder sister also coincidentally had a jellyfish sting in the left eye four years ago, and her visual acuity in the left eye decreased one year later, and no other etiology except the jellyfish sting was confirmed after many detailed examinations in a number of hospitals.

Physical examination

On examination, his BCVA was hand movement in the right eye and 1.0 in the left eye, and intraocular pressures were normal. The low vision in his right eye came as shock to his father, as he was unaware of the jellyfish sting, which also attracted our attention. Further examinations of his right eye were carried out to make a definitive diagnosis. Slit-lamp examination of his right eye confirmed that the anterior segment was normal except that the conjunctiva was 1+ injected and the pupil measured 3 mm with a relative afferent pupil defect (Figure 1A). Unexpectedly, the posterior segment examination of his right eye revealed diffuse optic disc pallor, partial retinal vascular occlusion, pigmentation of the retina and a gray-white lesion (scar) inferior to the fovea (Figure 1B). Optical coherence tomography (OCT) of the left eye showed diffuse thinning of the whole retinal layer, OCT B-scans passing through the gray-white lesion showed an elevated hyperreflective signal with disruption of retinal pigment epithelium integrity and mild outer retinal edema. When passing through the optic disk, OCT scans demonstrated a severely reduced peripapillary retinal nerve fiber layer compared with the left eye (Figure 1C and D). Fundus fluorescein angiography examinations of the right eye revealed that the retinal arterial blood filling time and venous blood return time were prolonged, the gray-white lesion was characterized by hyperfluorescence in the early phase, fluorescein staining in the late phase, and

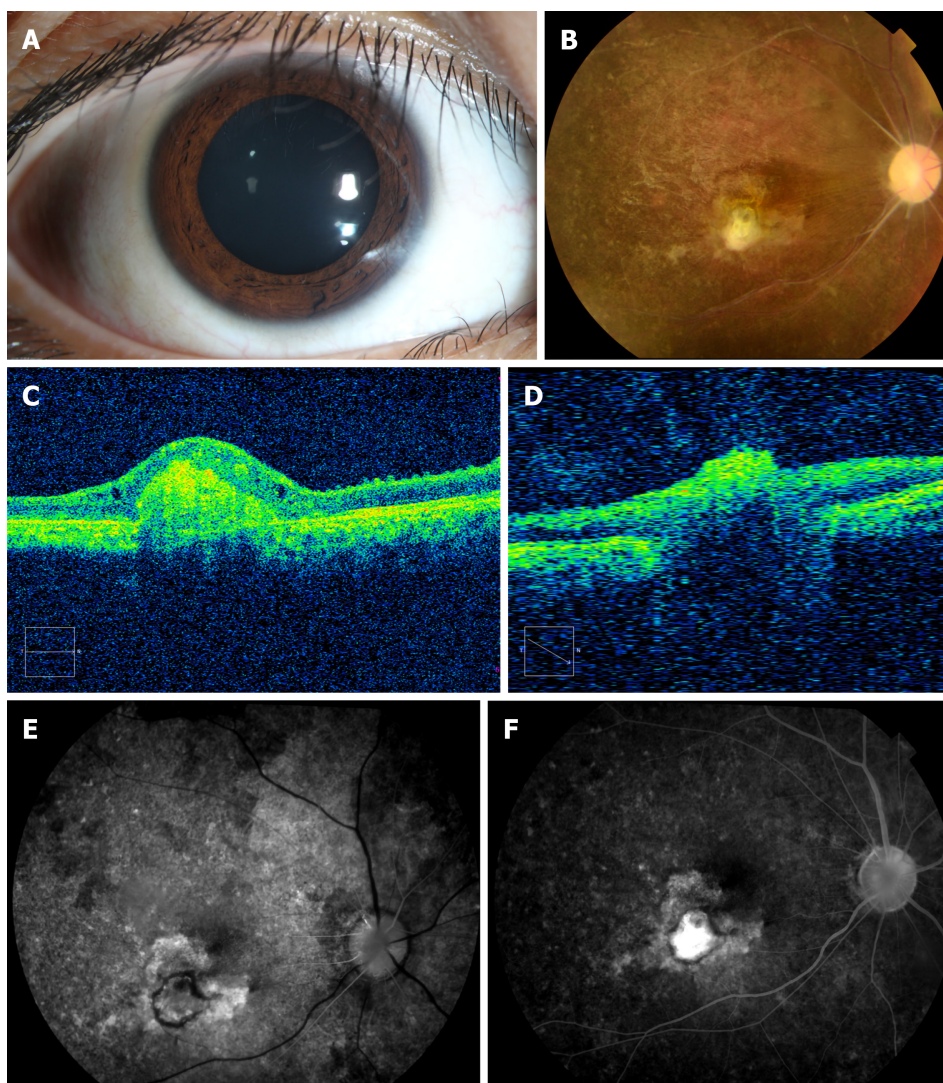


Figure 1 The boy's ocular examination results at presentation. A: The conjunctiva was 1+ injected in the right eye; B: Fundus images showed optic disc pallor, retinal vascular occlusion, pigmentation of the retina and a gray-white lesion (scar) in the right eye; C: Optical coherence tomography B-scans passing through the gray-white lesion showed an elevated lesion, and thinning of the whole retinal layer; D: Optical coherence tomography B-scans passing through the optic disk demonstrated a severely reduced peripapillary retinal nerve fiber layer; E: Fundus fluorescein angiography in the early phase; and F: Fundus fluorescein angiography in the late phase.

stippled areas of hyperfluorescence indicating retinal pigment epithelium dysfunction (Figure 1E and F).

In order to obtain a further understanding of the disease, we carried out a detailed examination of his sister with her consent, and found that the anterior segment was normal except for a relative afferent pupil defect. Therefore, we performed a posterior segment examination of the girl's left eye, which also showed optic disc pallor, partial retinal vascular occlusion, and pigmentation in the peripheral retina (Figure 2A and B). OCT images also confirmed diffuse thinning of the whole retinal layer with cystoid macular edema (Figure 2C and D), and BCVA in her left eye was finger count. The brother and sister, who both suffered from ocular jellyfish stings, showed similar presentations.

Laboratory examinations

In order to determine the etiology, further examinations were performed. He was tested for toxoplasmosis, other agents, rubella, cytomegalovirus and herpes simplex infections, which showed that cytomegalovirus IgG was 12.416 U/mL, rubella IgG was 49.182 IU/mL, and herpes simplex virus-I/II IgG was 22.423 U/mL. Blood analysis of mitochondrial deoxyribonucleic acid for Leber hereditary optic neuropathy was also performed, and no mutations of G3460A, G11778A, and T14484C were detected in the mitochondrial deoxyribonucleic acid analyses.

As the brother and sister had similar ocular lesions, we suggested that genetic

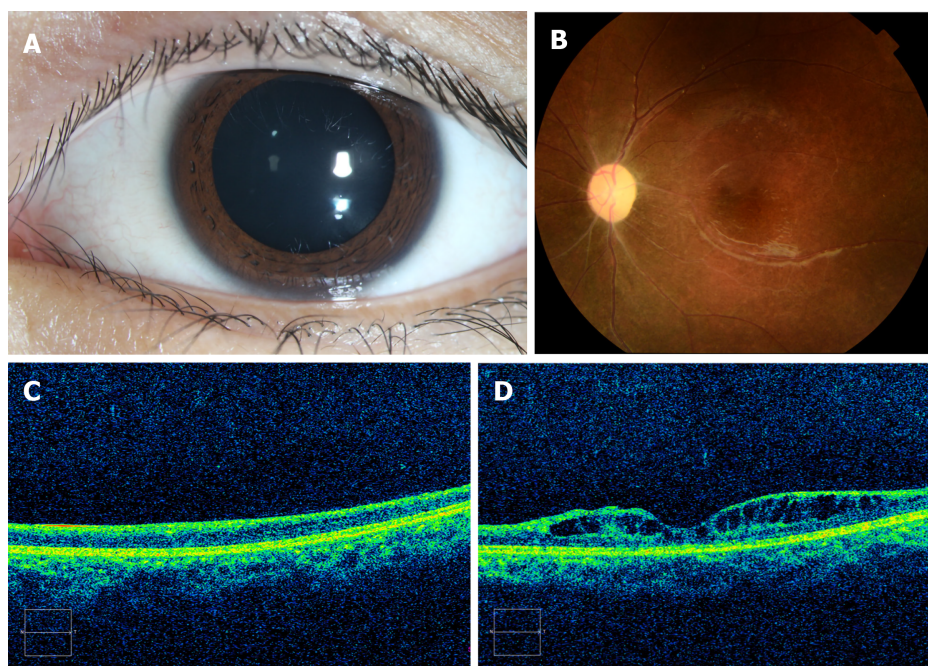


Figure 2 The girl's ocular examination results. A: The anterior segment was normal except for a relative afferent pupil defect, and the dilated pupil was drug-induced; B: Color fundus photographs showed a pale optic disc, retinal vascular occlusion and pigmentation in the peripheral retina; C and D: Optical coherence tomography images confirmed diffuse thinning of the whole retinal layer.

testing should be carried out to exclude genetic diseases, but their father refused. He stated that three years ago when his daughter's vision decreased after a jellyfish sting in the left eye, in order to exclude genetic diseases, all other members of the family (the girl's parents and grandparents, and two sisters and a brother) had undergone ocular examinations in a local hospital, which were verified to be normal.

Imaging examinations

An orbit magnetic resonance imaging scan revealed that the optic nerve in the right eye was thinner than that in the left eye, and there were no obvious brain abnormalities.

FINAL DIAGNOSIS

The final diagnosis of the presented case was optic atrophy, partial retinal vascular occlusion, pigmentation of the retina and a macular scar, which were thought to have been induced by ocular jellyfish stings.

TREATMENT

Treatment included improvement of the ocular blood circulation and protection of the optic nerve for one week.

OUTCOME AND FOLLOW-UP

After one week of treatment, he was discharged from hospital without obvious improvement in his condition (the possible poor prognosis had been explained to the family before treatment). The patient subsequently received the same treatment for 6 mo, and during a total follow-up period of 12 mo, there was still no improvement in his eyesight or fundus characteristics.

DISCUSSION

According to previous reports, jellyfish stings can induce ocular manifestations, such as diseases of the eyelid, conjunctiva, cornea and anterior chamber with severe pain, photophobia and lacrimation^[3-5,7]. Most injuries were self-limited and spontaneously resolved within 24 to 48 h^[8]. However, the potential for long-term sequelae exists. As reported by Glasser *et al*^[6], complications infrequently occur after ocular jellyfish stings, and can include iritis, chronic unilateral glaucoma, mydriasis and loss of accommodation. We are not aware of previous reports of ocular jellyfish stings resulting in ocular fundus diseases. The cases in our report developed severe fundus complications including optic atrophy, retinal vascular occlusion, thinning of the retina and scar formation in the macular area, which resulted in persistent visual impairment. To our knowledge, this report is the first to describe these reactions following ocular jellyfish stings. However, the detailed pathological mechanism remains unclear and requires further investigation.

According to reports, the nematocysts eject their threads with an approximate force of 40000 g to strike the skin or the cornea^[9]. Mao *et al*^[8] suggested that stings due to this weak energy level were incapable of penetrating the full thickness of the skin and cornea. Therefore, most patients recovered without permanent sequelae. Burnett *et al*^[5] concluded that this energy enables the threads to penetrate the upper dermis, which diffuse into the circulation and produce several syndromes. However, these conclusions need to be confirmed. In our cases, both patients suffered from ocular jellyfish stings and then developed ocular fundus diseases, unlike most patients who were reported to recover without permanent sequelae. This may be due to venom penetrating the intraocular area. As reported, the diameter of a jellyfish bell ranges from 2 to 30 cm, and the severity and energy of the sting is correlated with the size of the creature, with small jellyfish (5-7 cm diameter bell) causing less severe stings than larger jellyfish (> 15 cm diameter bell)^[10], which may indicate that the jellyfish which stung the boy was large and the venom may have penetrated the intraocular area and resulted in his poor outcome.

Contact with a jellyfish tentacle causes millions of nematocysts to pierce the skin and inject venom. The venom is a mixture of toxic and antigenic polypeptides and enzymes^[11], and evenomation can lead to harmful consequences and even death^[10,12]. Choudhary *et al*^[12] identified around 150 proteins in jellyfish venom, and considered that some of the components play an important role in the hematological, cytotoxic and allergenic effects of the venom. In addition, it has been reported that the venom can induce vasospasm, ischemia and vasculitis which are likely to be caused by inflammatory mediators or vasoactive substances^[11]. As reported, jellyfish stings can induce severe ischemia and gangrene and result in permanent disability if treatment is delayed, and several cases have been reported^[11,13]. Similarly, if the venom is injected into the eyes, it is possible that this can cause retinal ischemia and even atrophy of retinal tissues as reported in this study.

Although it is possible that the ocular lesions were caused by genetic disorders, taking into consideration all the relevant factors (similar experiences, similar presentations, no related genetic diseases reported and so on), we believe that the ocular lesions were likely caused by jellyfish stings, and this inference is reasonable according to previous reports. Despite the evidence being insufficient, we believe that it still has some reference value for clinical diagnosis.

Therefore, we should attach importance to the development of ocular disease following jellyfish stings, as jellyfish venom may penetrate deep tissues under certain circumstances and cause severe fundus lesions (such as optic atrophy, partial retinal vascular occlusion, pigmentation of the retina and macular scarring) and result in prolonged blurred vision.

CONCLUSION

According to similar experiences and eye presentations, and based on related reports regarding the striking energy and toxic effects of jellyfish, it is believed that the ocular lesions in these cases were likely caused by jellyfish stings. In addition to ocular surface diseases, jellyfish stings in the eyes may also induce ocular fundus diseases which can cause severe fundus lesions and vision loss. Thus, the fundus status of these patients should be carefully monitored during a long follow-up period in cases of irreversible ocular damage even if they initially only have ocular surface diseases.

ACKNOWLEDGEMENTS

We are grateful to the patients and their parents for allowing us to report the cases.

REFERENCES

- 1 **Cegolon L**, Heymann WC, Lange JH, Mastrangelo G. Jellyfish stings and their management: a review. *Mar Drugs* 2013; **11**: 523-550 [PMID: [23434796](#) DOI: [10.3390/md11020523](#)]
- 2 **Tibballs J**. Australian venomous jellyfish, envenomation syndromes, toxins and therapy. *Toxicon* 2006; **48**: 830-859 [PMID: [16928389](#) DOI: [10.1016/j.toxicon.2006.07.020](#)]
- 3 **Sonmez B**, Beden U, Yeter V, Erkan D. Jellyfish sting injury to the cornea. *Ophthalmic Surg Lasers Imaging* 2008; **39**: 415-417 [PMID: [18831428](#) DOI: [10.3928/15428877-20080901-15](#)]
- 4 **Wong SK**, Matoba A. Jellyfish sting of the cornea. *Am J Ophthalmol* 1985; **100**: 739-740 [PMID: [2865896](#) DOI: [10.1016/0002-9394\(85\)90635-x](#)]
- 5 **Burnett JW**, Calton GJ, Burnett HW. Jellyfish envenomation syndromes. *J Am Acad Dermatol* 1986; **14**: 100-106 [PMID: [2869072](#) DOI: [10.1016/s0190-9622\(86\)70013-3](#)]
- 6 **Glasser DB**, Noell MJ, Burnett JW, Kathuria SS, Rodrigues MM. Ocular jellyfish stings. *Ophthalmology* 1992; **99**: 1414-1418 [PMID: [1357615](#) DOI: [10.1016/s0161-6420\(92\)31800-7](#)]
- 7 **Winkel KD**, Hawdon GM, Ashby K, Ozanne-Smith J. Eye injury after jellyfish sting in temperate Australia. *Wilderness Environ Med* 2002; **13**: 203-205 [PMID: [12353597](#) DOI: [10.1580/1080-6032\(2002\)0132.0.co](#)]
- 8 **Mao C**, Hsu CC, Chen KT. Ocular Jellyfish Stings: Report of 2 Cases and Literature Review. *Wilderness Environ Med* 2016; **27**: 421-424 [PMID: [27436284](#) DOI: [10.1016/j.wem.2016.05.007](#)]
- 9 **Holstein T**, Tardent P. An ultrahigh-speed analysis of exocytosis: nematocyst discharge. *Science* 1984; **223**: 830-833 [PMID: [6695186](#) DOI: [10.1126/science.6695186](#)]
- 10 **Auerbach PS**, Gupta D, Van Hoesen K, Zavala A. Dermatological Progression of a Probable Box Jellyfish Sting. *Wilderness Environ Med* 2019; **30**: 310-320 [PMID: [31477508](#) DOI: [10.1016/j.wem.2019.05.004](#)]
- 11 **Lo AH**, Chan YC, Law Y, Cheng SW. Successful treatment of jellyfish sting-induced severe digital ischemia with intravenous iloprost infusion. *J Vasc Surg Cases* 2016; **2**: 31-33 [PMID: [31724607](#) DOI: [10.1016/j.jvsc.2016.02.007](#)]
- 12 **Choudhary I**, Hwang DH, Lee H, Yoon WD, Chae J, Han CH, Yum S, Kang C, Kim E. Proteomic Analysis of Novel Components of *Nemopilema nomurai* Jellyfish Venom: Deciphering the Mode of Action. *Toxins (Basel)* 2019; **11** [PMID: [30857234](#) DOI: [10.3390/toxins11030153](#)]
- 13 **Binnetoglu FK**, Kizildag B, Topaloglu N, Kasapcopur O. Severe digital necrosis in a 4-year-old boy: primary Raynaud's or jellyfish sting. *BMJ Case Rep* 2013; **2013** [PMID: [24248320](#) DOI: [10.1136/bcr-2013-201478](#)]



Published by **Baishideng Publishing Group Inc**
7041 Koll Center Parkway, Suite 160, Pleasanton, CA 94566, USA

Telephone: +1-925-3991568

E-mail: bpgoffice@wjgnet.com

Help Desk: <https://www.f6publishing.com/helpdesk>

<https://www.wjgnet.com>

