

World Journal of *Clinical Cases*

World J Clin Cases 2020 October 6; 8(19): 4280-4687



Contents

Semimonthly Volume 8 Number 19 October 6, 2020

OPINION REVIEW

- 4280 Role of monoclonal antibody drugs in the treatment of COVID-19
Ucciferri C, Vecchiet J, Falasca K

MINIREVIEWS

- 4286 Review of simulation model for education of point-of-care ultrasound using easy-to-make tools
Shin KC, Ha YR, Lee SJ, Ahn JH
- 4303 Liver injury in COVID-19: A minireview
Zhao JN, Fan Y, Wu SD

ORIGINAL ARTICLE

Case Control Study

- 4311 Transanal minimally invasive surgery *vs* endoscopic mucosal resection for rectal benign tumors and rectal carcinoids: A retrospective analysis
Shen JM, Zhao JY, Ye T, Gong LF, Wang HP, Chen WJ, Cai YK
- 4320 Impact of *mTOR* gene polymorphisms and gene-tea interaction on susceptibility to tuberculosis
Wang M, Ma SJ, Wu XY, Zhang X, Abesig J, Xiao ZH, Huang X, Yan HP, Wang J, Chen MS, Tan HZ

Retrospective Cohort Study

- 4331 Establishment and validation of a nomogram to predict the risk of ovarian metastasis in gastric cancer: Based on a large cohort
Li SQ, Zhang KC, Li JY, Liang WQ, Gao YH, Qiao Z, Xi HQ, Chen L

Retrospective Study

- 4342 Predictive factors for early clinical response in community-onset *Escherichia coli* urinary tract infection and effects of initial antibiotic treatment on early clinical response
Kim YJ, Lee JM, Lee JH
- 4349 Managing acute appendicitis during the COVID-19 pandemic in Jiaying, China
Zhou Y, Cen LS
- 4360 Clinical application of combined detection of SARS-CoV-2-specific antibody and nucleic acid
Meng QB, Peng JJ, Wei X, Yang JY, Li PC, Qu ZW, Xiong YF, Wu GJ, Hu ZM, Yu JC, Su W
- 4370 Prolonged prothrombin time at admission predicts poor clinical outcome in COVID-19 patients
Wang L, He WB, Yu XM, Hu DL, Jiang H

- 4380** Percutaneous radiofrequency ablation is superior to hepatic resection in patients with small hepatocellular carcinoma

Zhang YH, Su B, Sun P, Li RM, Peng XC, Cai J

- 4388** Clinical study on the surgical treatment of atypical Lisfranc joint complex injury

Li X, Jia LS, Li A, Xie X, Cui J, Li GL

- 4400** Application of medial column classification in treatment of intra-articular calcaneal fractures

Zheng G, Xia F, Yang S, Cui J

Clinical Trials Study

- 4410** Optimal hang time of enteral formula at standard room temperature and high temperature

Lakananurak N, Nalinthassanai N, Suansawang W, Panarat P

META-ANALYSIS

- 4416** Meta-analysis reveals an association between acute pancreatitis and the risk of pancreatic cancer

Liu J, Wang Y, Yu Y

SCIENTOMETRICS

- 4431** Global analysis of daily new COVID-19 cases reveals many static-phase countries including the United States potentially with unstoppable epidemic

Long C, Fu XM, Fu ZF

CASE REPORT

- 4443** Left atrial appendage aneurysm: A case report

Belov DV, Moskalev VI, Garbuzenko DV, Arefyev NO

- 4450** Twenty-year survival after iterative surgery for metastatic renal cell carcinoma: A case report and review of literature

De Raffele E, Mirarchi M, Casadei R, Ricci C, Brunocilla E, Minni F

- 4466** Primary rhabdomyosarcoma: An extremely rare and aggressive variant of male breast cancer

Satală CB, Jung I, Bara TJ, Simu P, Simu I, Vlad M, Szodorai R, Gurzu S

- 4475** Bladder stones in a closed diverticulum caused by *Schistosoma mansoni*: A case report

Alkhamees MA

- 4481** Cutaneous ciliated cyst on the anterior neck in young women: A case report

Kim YH, Lee J

- 4488** Extremely rare case of successful treatment of metastatic ovarian undifferentiated carcinoma with high-dose combination cytotoxic chemotherapy: A case report

Kim HB, Lee HJ, Hong R, Park SG

- 4494** Acute amnesia during pregnancy due to bilateral fornix infarction: A case report
Cho MJ, Shin DI, Han MK, Yum KS
- 4499** Ascaris-mimicking common bile duct stone: A case report
Choi SY, Jo HE, Lee YN, Lee JE, Lee MH, Lim S, Yi BH
- 4505** Eight-year follow-up of locally advanced lymphoepithelioma-like carcinoma at upper urinary tract: A case report
Yang CH, Weng WC, Lin YS, Huang LH, Lu CH, Hsu CY, Ou YC, Tung MC
- 4512** Spontaneous resolution of idiopathic intestinal obstruction after pneumonia: A case report
Zhang BQ, Dai XY, Ye QY, Chang L, Wang ZW, Li XQ, Li YN
- 4521** Successful pregnancy after protective hemodialysis for chronic kidney disease: A case report
Wang ML, He YD, Yang HX, Chen Q
- 4527** Rapid remission of refractory synovitis, acne, pustulosis, hyperostosis, and osteitis syndrome in response to the Janus kinase inhibitor tofacitinib: A case report
Li B, Li GW, Xue L, Chen YY
- 4535** Percutaneous fixation of neonatal humeral physeal fracture: A case report and review of the literature
Tan W, Wang FH, Yao JH, Wu WP, Li YB, Ji YL, Qian YP
- 4544** Severe fundus lesions induced by ocular jellyfish stings: A case report
Zheng XY, Cheng DJ, Lian LH, Zhang RT, Yu XY
- 4550** Application of ozonated water for treatment of gastro-thoracic fistula after comprehensive esophageal squamous cell carcinoma therapy: A case report
Wu DD, Hao KN, Chen XJ, Li XM, He XF
- 4558** Germinomas of the basal ganglia and thalamus: Four case reports
Huang ZC, Dong Q, Song EP, Chen ZJ, Zhang JH, Hou B, Lu ZQ, Qin F
- 4565** Gastrointestinal bleeding caused by jejunal angiosarcoma: A case report
Hui YY, Zhu LP, Yang B, Zhang ZY, Zhang YJ, Chen X, Wang BM
- 4572** High expression of squamous cell carcinoma antigen in poorly differentiated adenocarcinoma of the stomach: A case report
Wang L, Huang L, Xi L, Zhang SC, Zhang JX
- 4579** Therapy-related acute promyelocytic leukemia with FMS-like tyrosine kinase 3-internal tandem duplication mutation in solitary bone plasmacytoma: A case report
Hong LL, Sheng XF, Zhuang HF
- 4588** Metastasis of esophageal squamous cell carcinoma to the thyroid gland with widespread nodal involvement: A case report
Zhang X, Gu X, Li JG, Hu XJ

- 4595** Severe hyperlipemia-induced pseudoerythrocytosis - Implication for misdiagnosis and blood transfusion: A case report and literature review
Zhao XC, Ju B, Wei N, Ding J, Meng FJ, Zhao HG
- 4603** Novel brachytherapy drainage tube loaded with double 125I strands for hilar cholangiocarcinoma: A case report
Lei QY, Jiao DC, Han XW
- 4609** Resorption of upwardly displaced lumbar disk herniation after nonsurgical treatment: A case report
Wang Y, Liao SC, Dai GG, Jiang L
- 4615** Primary hepatic myelolipoma: A case report and review of the literature
Li KY, Wei AL, Li A
- 4624** Endoscopic palliative resection of a giant 26-cm esophageal tumor: A case report
Li Y, Guo LJ, Ma YC, Ye LS, Hu B
- 4633** Solitary hepatic lymphangioma mimicking liver malignancy: A case report and literature review
Long X, Zhang L, Cheng Q, Chen Q, Chen XP
- 4644** Intraosseous venous malformation of the maxilla after enucleation of a hemophilic pseudotumor: A case report
Cai X, Yu JJ, Tian H, Shan ZF, Liu XY, Jia J
- 4652** Intravesically instilled gemcitabine-induced lung injury in a patient with invasive urothelial carcinoma: A case report
Zhou XM, Wu C, Gu X
- 4660** Bochdalek hernia masquerading as severe acute pancreatitis during the third trimester of pregnancy: A case report
Zou YZ, Yang JP, Zhou XJ, Li K, Li XM, Song CH
- 4667** Localized primary gastric amyloidosis: Three case reports
Liu XM, Di LJ, Zhu JX, Wu XL, Li HP, Wu HC, Tuo BG
- 4676** Displacement of peritoneal end of a shunt tube to pleural cavity: A case report
Liu J, Guo M
- 4681** Parathyroid adenoma combined with a rib tumor as the primary disease: A case report
Han L, Zhu XF

ABOUT COVER

Peer-reviewer of *World Journal of Clinical Cases*, Prof. Adrián Ángel Inchauspe, obtained his MD in 1986 from La Plata National University (Argentina), where he remained as Professor of Surgery. Study abroad, at the Aachen and Tübingen Universities in Germany in 1991, led to his certification in laparoscopic surgery, and at the Louis Pasteur University in Strasbourg France, led to his being awarded the Argentine National Invention Award in 1998 for his graduate work in tele-surgery. He currently serves as teacher in the Argentine Acupuncture Society, as Invited Foreigner Professor at the China National Academy of Sciences and Hainan Medical University, and as editorial member and reviewer for many internationally renowned journals. (L-Editor: Filipodia)

AIMS AND SCOPE

The primary aim of *World Journal of Clinical Cases* (*WJCC*, *World J Clin Cases*) is to provide scholars and readers from various fields of clinical medicine with a platform to publish high-quality clinical research articles and communicate their research findings online.

WJCC mainly publishes articles reporting research results and findings obtained in the field of clinical medicine and covering a wide range of topics, including case control studies, retrospective cohort studies, retrospective studies, clinical trials studies, observational studies, prospective studies, randomized controlled trials, randomized clinical trials, systematic reviews, meta-analysis, and case reports.

INDEXING/ABSTRACTING

The *WJCC* is now indexed in Science Citation Index Expanded (also known as SciSearch®), Journal Citation Reports/Science Edition, PubMed, and PubMed Central. The 2020 Edition of Journal Citation Reports® cites the 2019 impact factor (IF) for *WJCC* as 1.013; IF without journal self cites: 0.991; Ranking: 120 among 165 journals in medicine, general and internal; and Quartile category: Q3.

RESPONSIBLE EDITORS FOR THIS ISSUE

Production Editor: Yan-Xia Xing; Production Department Director: Yun-Xiaojuan Wu; Editorial Office Director: Jin-Lai Wang.

NAME OF JOURNAL

World Journal of Clinical Cases

ISSN

ISSN 2307-8960 (online)

LAUNCH DATE

April 16, 2013

FREQUENCY

Semimonthly

EDITORS-IN-CHIEF

Dennis A Bloomfield, Sandro Vento, Bao-Gan Peng

EDITORIAL BOARD MEMBERS

<https://www.wjgnet.com/2307-8960/editorialboard.htm>

PUBLICATION DATE

October 6, 2020

COPYRIGHT

© 2020 Baishideng Publishing Group Inc

INSTRUCTIONS TO AUTHORS

<https://www.wjgnet.com/bpg/gerinfo/204>

GUIDELINES FOR ETHICS DOCUMENTS

<https://www.wjgnet.com/bpg/GerInfo/287>

GUIDELINES FOR NON-NATIVE SPEAKERS OF ENGLISH

<https://www.wjgnet.com/bpg/gerinfo/240>

PUBLICATION ETHICS

<https://www.wjgnet.com/bpg/GerInfo/288>

PUBLICATION MISCONDUCT

<https://www.wjgnet.com/bpg/gerinfo/208>

ARTICLE PROCESSING CHARGE

<https://www.wjgnet.com/bpg/gerinfo/242>

STEPS FOR SUBMITTING MANUSCRIPTS

<https://www.wjgnet.com/bpg/GerInfo/239>

ONLINE SUBMISSION

<https://www.f6publishing.com>

Solitary hepatic lymphangioma mimicking liver malignancy: A case report and literature review

Xin Long, Lei Zhang, Qi Cheng, Qian Chen, Xiao-Ping Chen

ORCID number: Xin Long 0000-0002-9817-5858; Lei Zhang 0000-0002-2227-0613; Qi Cheng 0000-0002-7069-6811; Qian Chen 0000-0001-8329-5649; Xiao-Ping Chen 0000-0001-8636-0493.

Author contributions: Long X collected primary data, searched the literature and drafted the manuscript; Zhang L involved in computed tomography images and pathology results; Cheng Q contributed to reviewing the manuscript, data analysis and table making; Chen Q critically reviewed and revised the manuscript; Chen XP conceived and designed the study; all authors read and approved the manuscript.

Informed consent statement: Informed consent statement was obtained from the patient and her family.

Conflict-of-interest statement: The authors declare that they have no conflicts of interest.

CARE Checklist (2016) statement: The authors have read the CARE Checklist (2016), prepared and revised the manuscript according to the CARE Checklist (2016).

Open-Access: This article is an open-access article that was selected by an in-house editor and fully peer-reviewed by external

Xin Long, Lei Zhang, Qi Cheng, Xiao-Ping Chen, Hepatic Surgery Center, Tongji Hospital, Tongji Medical College, Huazhong University of Science and Technology, Wuhan 430030, Hubei Province, China

Qian Chen, Endoscopic Unit, Department of Gastroenterology and Hepatology, Tongji Hospital, Tongji Medical College, Huazhong University of Science and Technology, Wuhan 430030, Hubei Province, China

Corresponding author: Xiao-Ping Chen, MD, PhD, Professor, Surgeon, Hepatic Surgery Center, Tongji Hospital, Tongji Medical College, Huazhong University of Science and Technology, No. 1095 Jiefang Avenue, Wuhan 430030, Hubei Province, China. chenxpchenxp@163.com

Abstract

BACKGROUND

Hepatic lymphangioma, a malformation of the liver lymphatic system, is a rare benign neoplasm and usually coexists with other visceral lymphangiomas. Solitary hepatic lymphangioma is much more rarely seen and could cause a clinical misinterpretation as malignancy.

CASE SUMMARY

A 50-year-old woman with a liver mass of approximately 3.5 cm was initially diagnosed with hepatocellular carcinoma given the risk factors for liver cancer that she presented with, including *Schistosoma japonicum* infection and jaundice, and also together with imaging results, which showed the mass enhanced quickly in the arterial phase and faded fast in the venous phase. The patient did not have the surgery first but received three rounds of transarterial chemoembolization because of her anxiety and fears for operation. Finally, the patient underwent laparoscopic liver segment 4b resection and cholecystectomy and was discharged from the hospital only 10 d after the operation. The pathological examination indicated the mass as hepatic lymphangioma. The patient has been followed up for 30 mo without recurrence. To raise the awareness of this misdiagnosed case and to better diagnose and treat this rare disease in future, we reviewed the published literature of solitary hepatic lymphangioma for its clinical symptoms, imaging presentation, operative techniques, histology features and prognosis.

CONCLUSION

Solitary hepatic lymphangioma mimicking malignancy makes diagnosis difficult. Complete surgical resection is the first choice to treat solitary hepatic lymphangioma.

reviewers. It is distributed in accordance with the Creative Commons Attribution NonCommercial (CC BY-NC 4.0) license, which permits others to distribute, remix, adapt, build upon this work non-commercially, and license their derivative works on different terms, provided the original work is properly cited and the use is non-commercial. See: <http://creativecommons.org/licenses/by-nc/4.0/>

Manuscript source: Unsolicited manuscript

Received: April 16, 2020

Peer-review started: April 16, 2020

First decision: July 25, 2020

Revised: August 3, 2020

Accepted: August 25, 2020

Article in press: August 25, 2020

Published online: October 6, 2020

P-Reviewer: Kreisel W, Rossi RE, Sempokuya T, Soresi M

S-Editor: Zhang L

L-Editor: Filipodia

P-Editor: Wang LL



Key Words: Hepatic lymphangioma; Hepatocellular carcinoma; Laparoscopic hepatectomy; Trans-arterial chemoembolization; Adult; Case report

©The Author(s) 2020. Published by Baishideng Publishing Group Inc. All rights reserved.

Core Tip: Hepatic lymphangioma is an extremely rare benign neoplasm. We presented a case of solitary hepatic lymphangioma with a typical imaging performance of hepatocellular carcinoma, thus misdiagnosed as liver cancer and treated with transarterial chemoembolization for three rounds. Finally, the lesion was removed by liver resection and confirmed as lymphangioma in pathology. The patient recovered well and no recurrence was found during follow up. Published literature with solitary hepatic lymphangioma were reviewed and analyzed. Complete surgical resection is the first choice to treat solitary hepatic lymphangioma.

Citation: Long X, Zhang L, Cheng Q, Chen Q, Chen XP. Solitary hepatic lymphangioma mimicking liver malignancy: A case report and literature review. *World J Clin Cases* 2020; 8(19): 4633-4643

URL: <https://www.wjgnet.com/2307-8960/full/v8/i19/4633.htm>

DOI: <https://dx.doi.org/10.12998/wjcc.v8.i19.4633>

INTRODUCTION

Lymphangiomas are rare benign masses characterized by dilated lymphatic vessels, usually resulting from blockade of lymphatic reflux or abnormal development of the lymphatic system in embryogenesis^[1-4]. The lymphatic system and venous system lack communication, which leads to the malformation of lymphatics. Lymphangioma is significantly associated with chromosome abnormalities, including chromosome X abnormalities (Turner syndrome), trisomy 21 (Down syndrome), trisomy 18, trisomy 13, and triploidy, copy number variants, and genetic mutations such as *AKT1*, *PIK3CA*, *VEGFR3*, and *RASA1*^[5-8]. It is reported that lymphangiomas are more common in neonates and children compared to adults^[1,9].

More than 90% of lymphangiomas occur in the lymphatic system outside the abdominal cavity, such as the neck, axilla, mediastinum, and lungs. Less than 5% of intra-abdominal lymphangiomas are described, and the most frequently affected location is the small bowel mesentery, followed by the omentum, mesocolon, and retroperitoneum^[9,10]. When lymphangiomas affect multiple organs, including the liver, spleen, soft tissues, serosa (mesentery), peritoneum, retroperitoneum, and skeletal, the situation is named lymphangiomatosis, which could not be eradicated by surgery but may respond to systemic chemotherapy and radiotherapy with limited efficacy and poor prognosis^[11-13]. In addition, solitary lesions in the liver are rare and are further classified into capillary lymphangioma, cystic lymphangioma, and cavernous lymphangioma^[4,14,15].

When solitary hepatic lymphangioma is presented in a clinical setting, the diagnosis and treatment becomes challenging solitary hepatic due to its rarity, atypical trait, and clinical phenotype. In our case, a rare solitary hepatic lymphangioma resembled the features of liver malignancy. We therefore reviewed the published literature in order to raise concerns of the diagnosis and treatment of this disease.

CASE PRESENTATION

Chief complaints

A 50-year-old woman who had a history of a liver tumor for 2 years was admitted to our hepatic surgery center, Tongji Hospital, Tongji Medical College, Huazhong University of Science and Technology.

History of present illness

Two years ago, a liver mass was found in her left liver lobe by ultrasound during a regular body check. Then, the patient received an enhanced computed tomography

(CT) scan, which showed a regular mass with a diameter around 3.5 cm located in the segment 4b close to falciform ligament. It manifested as a non-rim-like enhancement in the arterial phase (Figure 1A) and nonperipheral washout appearance in the portal venous phase and in delayed scan (Figure 1B and 1C). The lesion was classified as LR-5 according to liver imaging reporting and data system version 2018^[16]. Meanwhile, the CT scan revealed multiple gallbladder stones and splenomegaly (Figure 1). The liver lesion was resectable. However, the patient had fears of surgery and concerns of its complications and was unwilling to receive the operation at first. Finally, the patient received transarterial chemoembolization that displayed the abnormal dying lesion consistent with the features of liver malignancy. The patient recovered well and was discharged 2 d after transarterial chemoembolization. One month later, the enhanced CT displayed the similar change of the lesion as described above and iodized oil deposition in the tumor (Figure 2). Then the patient revisited the hospital every 3 mo in the first year and every 6 mo in the second year. During this period, the patient underwent another two rounds of transarterial chemoembolization treatment as the iodized oil deposition decreased. The lesion was not reduced while tumor markers were in the normal range all the time. Later, the patient was tired of numerous follow-ups, overcame the fear of surgery, and decided to have the operation. She was soon transferred to our hepatic surgery center for further treatment.

History of past illness

The patient recalled a history of infection of *Schistosoma japonicum* 3 years ago as she was found positive by fecal examination or serology testing during the annual *Schistosoma japonicum*-infection census of Hubei Province, China. She also reported jaundice hepatitis during childhood because of yellowing of skin or sclera.

Physical examination

The physical examination revealed jaundice, and therefore the patient was admitted to the infectious disease department of our hospital first.

Laboratory examinations

After admission, the tests for infection of hepatitis B virus, hepatitis C virus, human immunodeficiency virus, *Schistosoma japonicum*, and *Treponema pallidum* were all negative. Blood tests showed hemoglobin 81 g/L, hematocrit 23%, the average hemoglobin content 22.3 pg, mean corpuscular volume 62.7 fL, total bilirubin 57.6 μ mol/L, indirect bilirubin 52.9 μ mol/L, and free hemoglobin 121g/L. Gene test confirmed β -thalassemia with IVS654 heterozygous mutation, which could explain hemolytic anemia and splenomegaly. Serological tumor markers including alpha-fetoprotein (13908 IU/mL, normal range: 0-15770 IU/mL), carbohydrate antigen 19-9 (24.4 U/mL, normal range: 0-27 U/mL), and carcinoembryonic antigen (2.1 ng/mL, normal range: 0-3.4 ng/mL) were within the normal ranges.

Imaging examinations

No additional imaging examinations were performed for the patient after being transferred to our department.

FINAL DIAGNOSIS

Although tumor markers, evidence of hepatitis B virus, hepatitis C virus, and *Schistosoma japonicum* infection, and family history did not support the diagnosis of hepatocellular carcinoma, the results of the CT scan could not rule out liver malignancy. The postoperative histological examination of the liver tumor confirmed hepatic lymphangioma (Figure 3). Other confirmed diseases for the patient were chronic cholecystolithiasis and β -thalassemia with IVS654 heterozygous mutation.

TREATMENT

The patient subsequently received laparoscopic liver segment 4b resection and cholecystectomy. During laparotomy, the morphology, texture, and size showed no abnormality. There was a tumor around 4 cm \times 3 cm in the segment 4b with a clear boundary and soft quality. No satellite lesions or metastasis was observed. The size of the gallbladder with mild edematous serous membrane adhering to the omentum

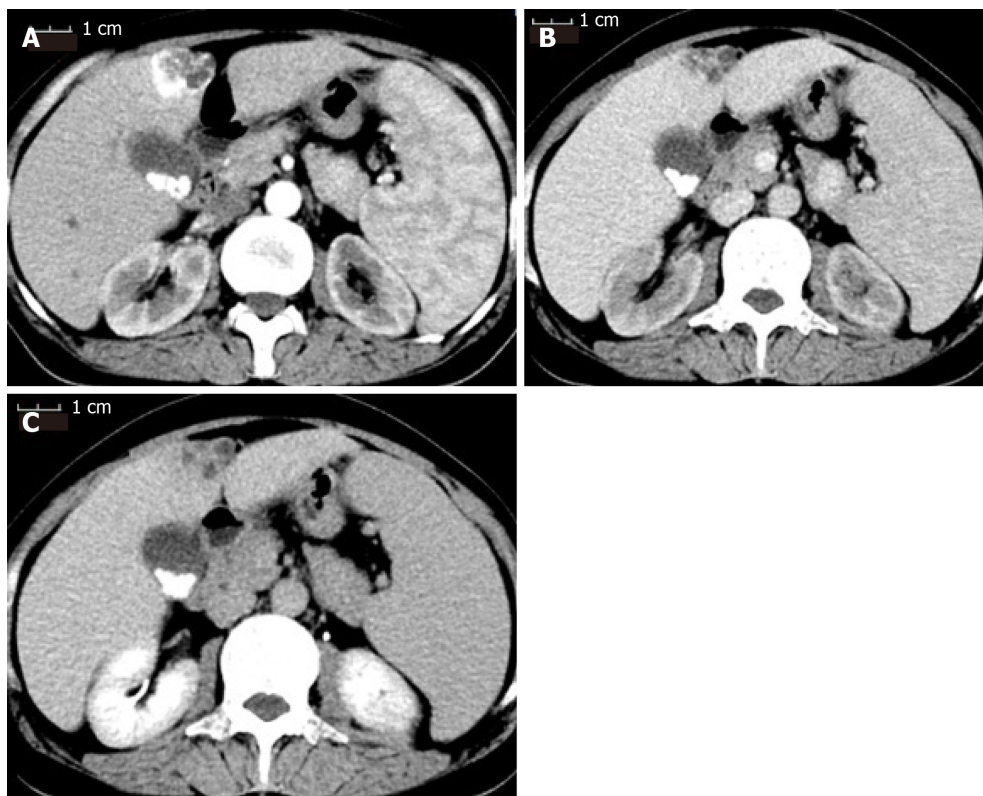


Figure 1 Contrast-enhanced computed tomography scan of the patient before receiving transarterial chemoembolization. A: The mass was enhanced immediately during the arterial phase; B: The enhancement faded away quickly into equal density in the portal venous phase; C: The mass showed hypodensity in the delayed phase. The three phases of the computed tomography scan also showed multiple gallstones and splenomegaly.

majus was 10 cm × 7 cm × 3 cm. Liver segment 4b with 2 cm tumor margin and gallbladder were removed by ultrasonic scalpel.

OUTCOME AND FOLLOW-UP

The operation was successfully accomplished. The total operation time was 180 min, and total blood loss was about 50 mL without blood transfusion.

The patient recovered well and was discharged from the hospital 10 d after the surgery. She visited the hospital every 6 mo. There was no recurrence or metastasis during the 30 mo follow-up.

DISCUSSION

Hepatic lymphangioma is rarely seen in our clinical practice especially for the solitary lesion that could be mistakenly diagnosed as liver malignancies or hepatic cystic diseases and the diagnosis can only be confirmed by surgical pathology. Due to its low incidence and few experiences in management, no consensus or guideline is available at present. Therefore, we reviewed the published literature related to the disease^[17,18] to gain more experience in the diagnosis and treatment of hepatic lymphangioma.

Based on the reviewed literature (Table 1), hepatic lymphangioma could be presented at any age from newborns to the elderly (average age is 30 years)^[19,20]. In our case, the patient was a 50-year-old female. Females have a slightly higher incidence for solitary hepatic lymphangioma compared to males (ratio is 11:8) (Table 1). Clinical manifestation is nonspecific, and most cases are presented as upper abdominal discomfort or pain caused by the lesion compressing adjacent organs. Some cases show no symptoms and are found by routine health examination (Table 1)^[21-27]. Thus preoperative diagnosis of the lesion cannot depend on symptoms and signs. Therefore, it is necessary to turn to imaging.

Ultrasonographic appearances of hepatic lymphangioma are various, including

Table 1 Basic characteristics and manifestations of reviewed solitary hepatic lymphangioma

No.	Ref.	Year	Age	Sex	Manifestation
1	Kohashi <i>et al</i> ^[32]	2017	50 yr	F	Epigastric discomfort
2	Lee <i>et al</i> ^[14]	2016	42 yr	F	Right upper abdominal pain
3	Zouari <i>et al</i> ^[21]	2015	8 mo	M	Abdominal distention
4	Nakano <i>et al</i> ^[19]	2015	18 yr	F	Epigastric pain
5	Liu <i>et al</i> ^[22]	2014	41 yr	M	Right upper abdominal pain
6	Zhang <i>et al</i> ^[4]	2013	42 yr	F	None
7	Nazarewski <i>et al</i> ^[10]	2013	41 yr	F	None
8	Peña Ros <i>et al</i> ^[17]	2013	20 yr	F	Abdominal pain
9	Ak <i>et al</i> ^[18]	2012	58 yr	F	Weight loss
10	Huang <i>et al</i> ^[23]	2010	35 yr	M	Right upper abdominal pain
11	Matsumoto <i>et al</i> ^[1]	2010	52 yr	F	Upper abdominal pain
12	Shahi <i>et al</i> ^[24]	2009	22 d	M	Abdominal distension
13	Zeidan <i>et al</i> ^[25]	2008	23 yr	M	Abdominal pain or vomiting
14	Stunell <i>et al</i> ^[36]	2009	30 yr	F	Right upper quadrant pain
15	Nzegwu <i>et al</i> ^[26]	2007	4 mo	M	Abdominal distension
16	Chan <i>et al</i> ^[28]	2005	15 yr	F	Upper abdominal pain
17	Koh <i>et al</i> ^[29]	2000	6 mo	M	Abdominal girth
18	Stavropoulos <i>et al</i> ^[20]	1994	64 yr	M	Epigastric pain
19	Clerici <i>et al</i> ^[27]	1989	ND	F	ND

ND: Not described.

non-echoic, low-echoic, and mixed-echoic masses with unicystic chamber or multichambers containing cystic and solid components (Table 2). CT scan presents as low density in whole and especially for unilocular cystic mass that reveals unenhanced imaging in the arterial phase. For multilocular mass with mixed components, enhancement is observed for septum in the arterial phase but not the cystic parts. Thus, depending on the above specific CT imaging features, the lesion may be successfully identified before the surgery^[28,29]. However, our case did not follow those specific features because it enhanced quickly in arterial phase and faded away quickly in the venous phase. This resembled the features of hepatic malignancy.

Magnetic resonance imaging (MRI) of hepatic lymphangioma is low signal on T1 weighted imaging, high signal on T2 weighted imaging, and occasionally mixed signals. The specific presentation of enhanced MRI for the disease is similar to that of enhanced CT (Table 2). Usually, MRI is not the first option to be used in diagnosis of the most cases. Although enhanced CT or MRI provide the evident features, it is still difficult to make the diagnosis of hepatic lymphangioma because of no typical symptoms and signs. In addition, the bleeding within the mass adds to the difficulty of the diagnosis (Table 2). Therefore, initial diagnosis needs to be differentiated from simple cyst, cystadenoma, cystadenocarcinoma, hydatid cyst, sclerosing hemangioma, or hepatocellular carcinoma like our case (Table 3).

Biopsy of the lesion to further confirm the diagnosis of the tumor and provide information of nontumorous liver tissue is recommended for cirrhotic liver when the lesion is less than 2 cm with uncertain imaging diagnosis. Imaging diagnosis is conclusive for noncirrhotic liver and liver with uncertain cirrhosis^[30]. For our case, the lesion was classified as LR-5 and diagnosed as hepatocellular carcinoma with 100% certainty. However, although the patient presented with splenomegaly, diagnosis of liver cirrhosis was still difficult. Thus, according to the guidelines, a biopsy should be performed. However, a biopsy of the lesion was not carried out at that time due to the patient refusing surgery. Therefore, we needed to summarize the experience of the treatment of our case, perform a biopsy, and follow the guidelines exactly.

A final definite diagnosis of hepatic lymphangioma relied on pathological

Table 2 Imaging of reviewed solitary hepatic lymphangioma

No.	Ultrasound	CT	MRI
1	Low-echoic, unilocular cystic mass	Low density, non-enhancement	ND
2	Mixed-echoic, mass with cystic and solid components	Low density, non-enhancement	ND
3	Unilocular cystic mass	Low density, non-enhancement	ND
4	Mixed-echoic, mass with cystic and solid components	Low density, non-enhancement	Mixed signal
5	Mixed-echoic, mass with cystic and solid components	Low density, heterogeneous enhancement	ND
6	Mixed-echoic, mass with cystic and solid components	Low density, non-enhancement for cystic region, enhancement for septa	ND
7	Non-echoic, multilocular cystic mass	Low density, non-enhancement for cystic region, enhancement for septa	Enhancement for septa on T1
8	ND	Low density, non-enhancement	ND
9	ND	Low density, non-enhancement for cystic region, enhancement for septa	Low signal on T1, high signal on T2
10	Non-echoic, multilocular cystic mass	Heterogeneous density	Mixed signal on T2
11	Mixed-echoic, mass with cystic and solid components	Low density, non-enhancement for cystic region, enhancement for septa	Low signal on T1, high signal on T2
12	Unilocular cystic mass	Low density	ND
13	Multilocular cystic mass	ND	Low signal, enhancement for septa on T1
14	Non-echoic, multilocular cystic mass	Low density, non-enhancement for cystic region, enhancement for septa	ND
15	Multilocular cystic mass	ND	ND
16	ND	Low density, non-enhancement for cystic region, enhancement for septa	ND
17	Multilocular cystic mass	Low density	ND
18	Mixed-echoic, mass with cystic and solid components	Low density	ND
19	Unilocular cystic mass	Low density	ND

CT: Computed tomography; MRI: Magnetic resonance imaging; ND: Not described.

examination (Table 4). The gross specimen presented as a unilocular cyst or multilocular cysts in different sizes with septum. Some of which contained solid content and were filled with clear serous fluid, chylous fluid, and blood clots. Under the microscope, the mass, parts of which had fibrous hyperplasia constituting solid components, was constituted by a large amount of cystic-dilated lymphatic lumens lined by simple squamous endothelium and filled with acidophilic lymph. The morphology was enough to make the diagnosis for most cases^[13,31]. Certainly, lymphatic marker, D2-40 (podoplanin), further confirmed the identification of the disease^[1,19,32]. In addition, endothelial markers, including von Willebrand factor, CD31, and CD34 and two lymphatic markers, LYVE-1 and Prox-1, are recommended through immunohistochemistry staining when it is difficult to distinguish lymphatic vessels from blood vessels^[1].

Hepatic lymphangioma is usually considered a benign tumor^[20,33]. Treatments for hepatic lymphangioma include complete resection, partial resection with cleaning cystic fluid, needle aspiration, sclerosing agent injection, liver transplantation, and immunosuppressive drugs for diffused and serious condition^[11,12,34-36]. Partial resection with cleaning cystic fluid and needle aspiration can definitely lead to tumor recurrence^[32,36]. The effectiveness of sclerosing agent injection, which is effective for a simple liver cyst, is unknown. The use of immunosuppressive agents to treat hepatic lymphangioma or lymphangiomatosis has not been approved^[12,38]. Liver transplantation is the last choice for hepatic lymphangiomatosis with deteriorated

Table 3 Initial diagnosis and surgical findings of reviewed cases

No.	Initial diagnosis	Location	Number	Size in cm	Texture	Type of surgery
1	Hepatic cyst	Hepatoduodenal ligament	1	13 × 10	Unilocular cyst with serous fluid	LPR/CR
2	Hepatic cystadenoma/cystadenocarcinoma	Segments 7 and 8	1	23 × 30	Multilocular cyst with bloody fluid	CR
3	ND	Right lobe	1	14.9 × 10.7 × 9.7	Unilocular cyst	CR
4	Rupture of a hepatic tumor	Left lobe	1	12.0 × 9.5	Multilocular cyst with blood clot	CR
5	Bile duct cyst/biliary cystadenoma/cystadenocarcinoma/hydatid cyst	Segment 2	1	16.2 × 13.0 × 4.3	Multilocular cyst with serous fluid	CR
6	Hepatic hemangioma/cystadenocarcinoma	Right lobe	1	23 × 15 × 7	Multilocular cyst with brownish fluid	CR
7	Hepatic cyst	Gallbladder and hepatoduodenal ligament	1	13.0 × 5.5 × 6.5	Multilocular cyst with serous fluid	CR
8	ND	Segment 5	1	15 × 9	Unilocular cyst	CR
9	Liver malignancy	Segment 5	1	3.0 × 2.2 × 1.5	Multilocular cyst with mucoid fluid	CR
10	Cystadenoma/cystadenocarcinoma/hepatic cyst with bleeding	Segments 4, 5, 6, 7, 8	1	25 × 23	Multilocular cyst with blood clot	CR
11	Sclerosing hemangioma/biliary cystadenoma/cystadenocarcinoma	Segment 4	1	3	Multilocular cyst with mucoid fluid and solid content	CR
12	Uncertainty	Right lobe	1	9.6 × 8.0 × 13.0	Unilocular cyst with yellowish fluid	CR
13	ND	Right lobe	1	12.6 × 9.4 × 11.5	Multilocular cyst with serous fluid	CR
14	Hepatic cyst	Gallbladder	1	15.2 × 9.4	Multilocular cyst with serous fluid	CR
15	Hepatic cyst	Right lobe	1	ND	Multilocular cyst with serous fluid	CR
16	Hepatic lymphangioma	Segments 4, 5, 6	1	21 × 20 × 6	Multilocular cyst with brownish fluid	CR
17	Lymphangioma/mesenteric cyst	Segment 4	1	20 × 14	Multilocular cyst	CR
18	Uncertainty	Segment 3	1	4	Sponge-like cyst with chylous fluid and blood	CR
19	Hydatid cyst	ND	1	ND	Cystic	Resection

CR: Complete resection; LPR: Laparoscopic partial resection; ND: Not described.

liver function and progressing symptoms affecting the quality of life^[11,12,34,35,37]. It is thought that hepatic lymphangioma or lymphangiomatosis is a low grade malignancy or has the potential to metastasize as hepatic recurrence is observed even after liver transplantation^[12,38]. All the reviewed solitary cases including our case received complete tumor resection, and all are disease free during the follow-up periods. Thus, we suggest that complete resection be the first option when the diagnosis of hepatic lymphangioma is made.

CONCLUSION

In conclusion, solitary hepatic lymphangioma is a very rare disease and the initial

Table 4 Histology and follow-up of reviewed solitary hepatic lymphangioma

No.	Histology	VWF	CD-31	CD-34	D2-40	LYVE-1	Prox-1	Discharged in d	Follow-up in mo	Prognosis
1	Cystic lymphangioma	ND	ND	-	+	ND	ND	ND	24	Alive/disease free
2	Cystic lymphangioma	ND	+	ND	ND	ND	ND	10	18	Alive/disease free
3	Cystic lymphangioma	ND	ND	ND	ND	ND	ND	ND	ND	ND
4	Cystic lymphangioma	ND	+	ND	+	ND	ND	8	48	Alive/disease free
5	Cystic lymphangioma	ND	ND	-	ND	ND	ND	ND	30	Alive/disease free
6	Cystic lymphangioma	ND	ND	+	-	ND	ND	ND	24	Alive/disease free
7	Cystic lymphangioma	ND	ND	ND	ND	ND	ND	ND	ND	Alive/disease free
8	Cystic lymphangioma	ND	ND	ND	ND	ND	ND	ND	ND	ND
9	Cavernous lymphangioma	ND	ND	ND	ND	ND	ND	ND	ND	ND
10	Cystic lymphangioma	ND	ND	ND	ND	ND	ND	ND	17	Alive/disease free
11	Cystic lymphangioma	-	+	+	+	+	+	ND	6	Alive/disease free
12	Cystic lymphangioma	ND	ND	ND	ND	ND	ND	5	1	Alive/disease free
13	Cystic lymphangioma	ND	ND	ND	ND	ND	ND	ND	24	Alive/disease free
14	Cystic lymphangioma	ND	+	ND	ND	ND	ND	4	ND	ND
15	Cystic lymphangioma	ND	ND	ND	ND	ND	ND	ND	4	Alive/disease free
16	Cystic lymphangioma	ND	ND	ND	ND	ND	ND	ND	18	Alive/disease free
17	Cystic lymphangioma	ND	ND	ND	ND	ND	ND	ND	3	Alive/disease free
18	Cavernous lymphangioma	ND	ND	ND	ND	ND	ND	7	24	Alive/disease free
19	Cystic lymphangioma	ND	ND	ND	ND	ND	ND	ND	ND	ND

-. Negative; +. Positive. ND: Not described; VWF: Von Willebrand factor.

diagnosis may be difficult because of its atypical manifestation. Complete surgical resection is the priority to treat hepatic lymphangioma.

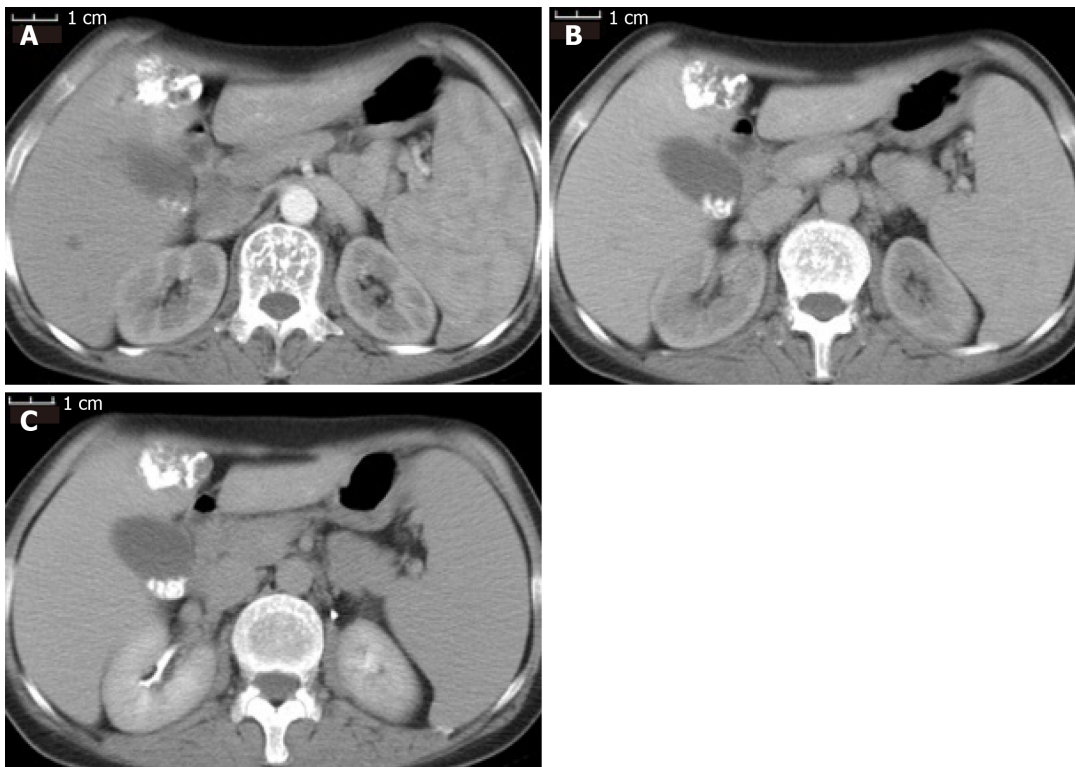


Figure 2 Contrast-enhanced computed tomography scan of the patient after first transarterial chemoembolization. A: Iodized oil deposition in the tumor was observed in the arterial phase; B: Portal venous phase; C: Delayed phase.

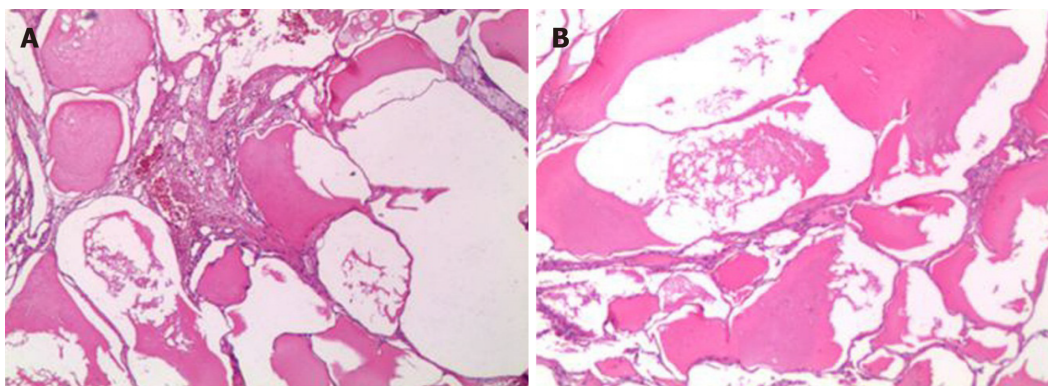


Figure 3 The specimen was examined under microscopy (40 ×). A: The mass was made of dilated-cystic lymphatic lumens lined by endothelium; B: Filled with acidophilic lymph.

ACKNOWLEDGEMENTS

We greatly appreciate the patient and her family and the medical staff involved in this study.

REFERENCES

- 1 **Matsumoto T**, Ojima H, Akishima-Fukasawa Y, Hiraoka N, Onaya H, Shimada K, Mizuguchi Y, Sakurai S, Ishii T, Kosuge T, Kanai Y. Solitary hepatic lymphangioma: report of a case. *Surg Today* 2010; **40**: 883-889 [PMID: 20740355 DOI: 10.1007/s00595-010-4255-7]
- 2 **Godart S**. Embryological significance of lymphangioma. *Arch Dis Child* 1966; **41**: 204-206 [PMID: 5948671 DOI: 10.1136/adc.41.216.204]
- 3 **Wigle JT**, Oliver G. Prox1 function is required for the development of the murine lymphatic system. *Cell* 1999; **98**: 769-778 [PMID: 10499794 DOI: 10.1016/s0092-8674(00)81511-1]
- 4 **Zhang YZ**, Ye YS, Tian L, Li W. Rare case of a solitary huge hepatic cystic lymphangioma. *World J Clin Cases* 2013; **1**: 152-154 [PMID: 24303489 DOI: 10.12998/wjcc.v1.i4.152]

- 5 **Noia G**, Maltese PE, Zampino G, D'Errico M, Cammalleri V, Convertini P, Marceddu G, Mueller M, Guerri G, Bertelli M. Cystic Hygroma: A Preliminary Genetic Study and a Short Review from the Literature. *Lymphat Res Biol* 2019; **17**: 30-39 [PMID: [30475086](#) DOI: [10.1089/lrb.2017.0084](#)]
- 6 **Saccone G**, Di Meglio L, Di Meglio L, Zullo F, Locci M, Zullo F, Berghella V, Di Meglio A. Prenatal ultrasound diagnosis of fetal chest wall cystic lymphangioma: An Italian case series. *Eur J Obstet Gynecol Reprod Biol* 2019; **236**: 139-142 [PMID: [30909010](#) DOI: [10.1016/j.ejogrb.2019.03.014](#)]
- 7 **Bagrodia N**, Defnet AM, Kandel JJ. Management of lymphatic malformations in children. *Curr Opin Pediatr* 2015; **27**: 356-363 [PMID: [25888145](#) DOI: [10.1097/MOP.0000000000000209](#)]
- 8 **Park S**, Kim SH, Youn SE, Lee ST, Kang HC. A Child With Lymphangioma Due to Somatic Mutation in PIK3CA Successfully Treated With Everolimus. *Pediatr Neurol* 2019; **91**: 65-67 [PMID: [30579634](#) DOI: [10.1016/j.pediatrneurol.2018.10.017](#)]
- 9 **Losanoff JE**, Richman BW, El-Sherif A, Rider KD, Jones JW. Mesenteric cystic lymphangioma. *J Am Coll Surg* 2003; **196**: 598-603 [PMID: [12691938](#) DOI: [10.1016/s1072-7515\(02\)01755-6](#)]
- 10 **Nazarewski L**, Patkowski W, Pachon R, Marczevska M, Krawczyk M. Gall-bladder and hepatoduodenal ligament lymphangioma - case report and literature review. *Pol Przegl Chir* 2013; **85**: 39-43 [PMID: [23509201](#) DOI: [10.2478/pjs-2013-0007](#)]
- 11 **Lee A**, Rajanayagam J, Sarikwal A, Davies J, Lewindon P. Hepatobiliary and pancreatic: liver transplantation for massive hepatic lymphangiomatosis. *J Gastroenterol Hepatol* 2014; **29**: 233 [PMID: [24460839](#) DOI: [10.1111/jgh.12493](#)]
- 12 **Ooi CY**, Brody D, Wong R, Moroz S, Ngan BY, Navarro OM, Fecteau A, Grant D, Ng VL. Liver transplantation for massive hepatic lymphangiomatosis in a child. *J Pediatr Gastroenterol Nutr* 2011; **52**: 366-369 [PMID: [21150654](#) DOI: [10.1097/MPG.0b013e3181ec1efb](#)]
- 13 **Van Steenberghe W**, Joosten E, Marchal G, Baert A, Vanstapel MJ, Desmet V, Wijnants P, De Groote J. Hepatic lymphangiomatosis. Report of a case and review of the literature. *Gastroenterology* 1985; **88**: 1968-1972 [PMID: [3888771](#) DOI: [10.1016/0016-5085\(85\)90028-9](#)]
- 14 **Lee HH**, Lee SY. Case report of solitary giant hepatic lymphangioma. *Korean J Hepatobiliary Pancreat Surg* 2016; **20**: 71-74 [PMID: [27212994](#) DOI: [10.14701/kjhbps.2016.20.2.71](#)]
- 15 **Alqahtani A**, Nguyen LT, Flageole H, Shaw K, Laberge JM. 25 years' experience with lymphangiomas in children. *J Pediatr Surg* 1999; **34**: 1164-1168 [PMID: [10442614](#) DOI: [10.1016/s0022-3468\(99\)90590-0](#)]
- 16 **Chernyak V**, Fowler KJ, Kamaya A, Kielar AZ, Elsayes KM, Bashir MR, Kono Y, Do RK, Mitchell DG, Singal AG, Tang A, Sirlin CB. Liver Imaging Reporting and Data System (LI-RADS) Version 2018: Imaging of Hepatocellular Carcinoma in At-Risk Patients. *Radiology* 2018; **289**: 816-830 [PMID: [30251931](#) DOI: [10.1148/radiol.2018181494](#)]
- 17 **Peña Ros E**, Candel Arenas MF, Pastor Pérez P, Albarracín Marín-Blázquez A. [Cystic hepatic lymphangioma: a rare cause of abdominal pain in the adult]. *Cir Esp* 2013; **91**: e11 [PMID: [22537898](#) DOI: [10.1016/j.ciresp.2011.08.010](#)]
- 18 **Ak SJ**, Park SK, Park HU. [A case of isolated hepatic lymphangioma]. *Korean J Gastroenterol* 2012; **59**: 189-192 [PMID: [22387840](#) DOI: [10.4166/kjg.2012.59.2.189](#)]
- 19 **Nakano T**, Hara Y, Shirokawa M, Shioiri S, Goto H, Yasuno M, Tanaka M. Hemorrhagic giant cystic lymphangioma of the liver in an adult female. *J Surg Case Rep* 2015; **2015** [PMID: [25832463](#) DOI: [10.1093/jscr/rjv033](#)]
- 20 **Stavropoulos M**, Vagianos C, Scopa CD, Dragotis C, Androulakis J. Solitary hepatic lymphangioma. A rare benign tumour: a case report. *HPB Surg* 1994; **8**: 33-36 [PMID: [7993862](#) DOI: [10.1155/1994/63638](#)]
- 21 **Zouari M**, Ben Dhaou M. Solitary hepatic lymphangioma in an 8-month-old child. *Pan Afr Med J* 2015; **20**: 440 [PMID: [26309472](#) DOI: [10.11604/pamj.2015.20.440.6111](#)]
- 22 **Liu Q**, Sui CJ, Li BS, Gao A, Lu JY, Yang JM. Solitary hepatic lymphangioma: a one-case report. *Springerplus* 2014; **3**: 314 [PMID: [25279280](#) DOI: [10.1186/2193-1801-3-314](#)]
- 23 **Huang L**, Li J, Zhou F, Yan J, Liu C, Zhou AY, Tang A, Yan Y. Giant cystic lymphangioma of the liver. *Hepatol Int* 2010; **4**: 784-787 [PMID: [21286352](#) DOI: [10.1007/s12072-010-9220-4](#)]
- 24 **Shahi KS**, Geeta B, Rajput P. Solitary hepatic lymphangioma in a 22-day-old infant. *J Pediatr Surg* 2009; **44**: E9-11 [PMID: [19635291](#) DOI: [10.1016/j.jpedsurg.2009.04.022](#)]
- 25 **Zeidan S**, Delarue A. Uncommon etiology of a cystic hepatic tumor. *Dig Surg* 2008; **25**: 10-11 [PMID: [18235190](#) DOI: [10.1159/000114195](#)]
- 26 **Nzegwu MA**, Ekenze SO, Okafor OC, Anyanwu PA, Odetunde OA, Olusina DB. Solitary hepatic lymphangioma in an infant. *J Perinat Med* 2007; **35**: 164-165 [PMID: [17302516](#) DOI: [10.1515/jpm.2007.022](#)]
- 27 **Clerici D**, Griffo B, Ceppi M, Basilico V, Milvio E. [Cystic lymphangioma of the liver. Presentation of a clinical case]. *Minerva Chir* 1989; **44**: 1139-1141 [PMID: [2747958](#)]
- 28 **Chan SC**, Huang SF, Lee WC, Wan YL. Solitary hepatic lymphangioma--a case report. *Int J Clin Pract Suppl* 2005; 100-102 [PMID: [15875640](#) DOI: [10.1111/j.1742-1241.2004.00276.x](#)]
- 29 **Koh CC**, Sheu JC. Hepatic lymphangioma--a case report. *Pediatr Surg Int* 2000; **16**: 515-516 [PMID: [11057556](#) DOI: [10.1007/s003839900327](#)]
- 30 **European Association for the Study of the Liver**. EASL Clinical Practice Guidelines: Management of hepatocellular carcinoma. *J Hepatol* 2018; **69**: 182-236 [PMID: [29628281](#) DOI: [10.1016/j.jhep.2018.03.019](#)]
- 31 **Roisman I**, Manny J, Fields S, Shiloni E. Intra-abdominal lymphangioma. *Br J Surg* 1989; **76**: 485-489 [PMID: [2660949](#) DOI: [10.1002/bjs.1800760519](#)]
- 32 **Kohashi T**, Itamoto T, Matsugu Y, Nishisaka T, Nakahara H. An adult case of lymphangioma of the hepatoduodenal ligament mimicking a hepatic cyst. *Surg Case Rep* 2017; **3**: 2 [PMID: [28050777](#) DOI: [10.1186/s40792-016-0280-0](#)]
- 33 **Kochin IN**, Miloh TA, Arnon R, Iyer KR, Suchy FJ, Kerker N. Benign liver masses and lesions in children: 53 cases over 12 years. *Isr Med Assoc J* 2011; **13**: 542-547 [PMID: [21991714](#)]
- 34 **Datz C**, Graziadei IW, Dietze O, Jaschke W, Königsrainer A, Sandhofer F, Margreiter R. Massive progression of diffuse hepatic lymphangiomatosis after liver resection and rapid deterioration after liver transplantation. *Am J Gastroenterol* 2001; **96**: 1278-1281 [PMID: [11316184](#) DOI: [10.1111/j.1572-0241.2001.03712.x](#)]

- 35 **Miller C**, Mazzaferro V, Makowka L, ChapChap P, Demetris J, Tzakis A, Esquivel CO, Iwatsuki S, Starzl TE. Orthotopic liver transplantation for massive hepatic lymphangiomatosis. *Surgery* 1988; **103**: 490-495 [PMID: [3281302](#)]
- 36 **Stunell H**, Ridgway PF, Torreggiani WC, Crotty P, Conlon KC. Hepatic lymphangioma: a rare cause of abdominal pain in a 30-year-old female. *Ir J Med Sci* 2009; **178**: 93-96 [PMID: [17955281](#) DOI: [10.1007/s11845-007-0094-y](#)]
- 37 **Ra SH**, Bradley RF, Fishbein MC, Busuttil RW, Lu DS, Lassman CR. Recurrent hepatic lymphangiomatosis after orthotopic liver transplantation. *Liver Transpl* 2007; **13**: 1593-1597 [PMID: [17969190](#) DOI: [10.1002/lt.21306](#)]
- 38 **Jiménez-Rivera C**, Avitzur Y, Fecteau AH, Jones N, Grant D, Ng VL. Sirolimus for pediatric liver transplant recipients with post-transplant lymphoproliferative disease and hepatoblastoma. *Pediatr Transplant* 2004; **8**: 243-248 [PMID: [15176961](#) DOI: [10.1111/j.1399-3046.2004.00156.x](#)]



Published by **Baishideng Publishing Group Inc**
7041 Koll Center Parkway, Suite 160, Pleasanton, CA 94566, USA

Telephone: +1-925-3991568

E-mail: bpgoffice@wjgnet.com

Help Desk: <https://www.f6publishing.com/helpdesk>

<https://www.wjgnet.com>

