

World Journal of *Clinical Cases*

World J Clin Cases 2020 October 26; 8(20): 4688-5069



MINIREVIEWS

- 4688** Relationship between non-alcoholic fatty liver disease and coronary heart disease
Arslan U, Yenercağ M

ORIGINAL ARTICLE

Retrospective Cohort Study

- 4700** Remission of hepatotoxicity in chronic pulmonary aspergillosis patients after lowering trough concentration of voriconazole
Teng GJ, Bai XR, Zhang L, Liu HJ, Nie XH

Retrospective Study

- 4708** Endoscopic submucosal dissection as alternative to surgery for complicated gastric heterotopic pancreas
Noh JH, Kim DH, Kim SW, Park YS, Na HK, Ahn JY, Jung KW, Lee JH, Choi KD, Song HJ, Lee GH, Jung HY
- 4719** Observation of the effects of three methods for reducing perineal swelling in children with developmental hip dislocation
Wang L, Wang N, He M, Liu H, Wang XQ
- 4726** Predictive value of serum cystatin C for risk of mortality in severe and critically ill patients with COVID-19
Li Y, Yang S, Peng D, Zhu HM, Li BY, Yang X, Sun XL, Zhang M
- 4735** Sleep quality of patients with postoperative glioma at home
Huang Y, Jiang ZJ, Deng J, Qi YJ
- 4743** Early complications of preoperative external traction fixation in the staged treatment of tibial fractures: A series of 402 cases
Yang JZ, Zhu WB, Li LB, Dong QR
- 4753** Retroperitoneal vs transperitoneal laparoscopic lithotripsy of 20-40 mm renal stones within horseshoe kidneys
Chen X, Wang Y, Gao L, Song J, Wang JY, Wang DD, Ma JX, Zhang ZQ, Bi LK, Xie DD, Yu DX
- 4763** Undifferentiated embryonal sarcoma of the liver: Clinical characteristics and outcomes
Zhang C, Jia CJ, Xu C, Sheng QJ, Dou XG, Ding Y
- 4773** Cerebral infarct secondary to traumatic internal carotid artery dissection
Wang GM, Xue H, Guo ZJ, Yu JL
- 4785** Home-based nursing for improvement of quality of life and depression in patients with postpartum depression
Zhuang CY, Lin SY, Cheng CJ, Chen XJ, Shi HL, Sun H, Zhang HY, Fu MA

Observational Study

- 4793** Cost-effectiveness of lutetium (^{177}Lu) oxodotreotide *vs* everolimus in gastroenteropancreatic neuroendocrine tumors in Norway and Sweden
Palmer J, Leeuwenkamp OR
- 4807** Factors related to improved American Spinal Injury Association grade of acute traumatic spinal cord injury
Tian C, Lv Y, Li S, Wang DD, Bai Y, Zhou F, Ma QB
- 4816** Intraoperative systemic vascular resistance is associated with postoperative nausea and vomiting after laparoscopic hysterectomy
Qu MD, Zhang MY, Wang GM, Wang Z, Wang X

META-ANALYSIS

- 4826** Underwater *vs* conventional endoscopic mucosal resection in treatment of colorectal polyps: A meta-analysis
Ni DQ, Lu YP, Liu XQ, Gao LY, Huang X

CASE REPORT

- 4838** Dehydrated patient without clinically evident cause: A case report
Palladino F, Fedele MC, Casertano M, Liguori L, Esposito T, Guarino S, Miraglia del Giudice E, Marzuillo P
- 4844** Intracranial malignant solitary fibrous tumor metastasized to the chest wall: A case report and review of literature
Usuda D, Yamada S, Izumida T, Sangen R, Higashikawa T, Nakagawa K, Iguchi M, Kasamaki Y
- 4853** End-of-life home care of an interstitial pneumonia patient supported by high-flow nasal cannula therapy: A case report
Goda K, Kenzaka T, Kuriyama K, Hoshijima M, Akita H
- 4858** Rupture of carotid artery pseudoaneurysm in the modern era of definitive chemoradiation for head and neck cancer: Two case reports
Kim M, Hong JH, Park SK, Kim SJ, Lee JH, Byun J, Ko YH
- 4866** Unremitting diarrhoea in a girl diagnosed anti-N-methyl-D-aspartate-receptor encephalitis: A case report
Onpoaree N, Veeravigrom M, Sanpavat A, Suratannon N, Sintusek P
- 4876** Paliperidone palmitate-induced facial angioedema: A case report
Srifueungfung M, Sukakul T, Liangcheep C, Viravan N
- 4883** Improvement of lenvatinib-induced nephrotic syndrome after adaptation to sorafenib in thyroid cancer: A case report
Yang CH, Chen KT, Lin YS, Hsu CY, Ou YC, Tung MC
- 4895** Adult metaplastic hutch diverticulum with robotic-assisted diverticulectomy and reconstruction: A case report
Yang CH, Lin YS, Ou YC, Weng WC, Huang LH, Lu CH, Hsu CY, Tung MC

- 4902** Thrombus straddling a patent foramen ovale and pulmonary embolism: A case report
Huang YX, Chen Y, Cao Y, Qiu YG, Zheng JY, Li TC
- 4908** Therapeutic experience of an 89-year-old high-risk patient with incarcerated cholecystolithiasis: A case report and literature review
Zhang ZM, Zhang C, Liu Z, Liu LM, Zhu MW, Zhao Y, Wan BJ, Deng H, Yang HY, Liao JH, Zhu HY, Wen X, Liu LL, Wang M, Ma XT, Zhang MM, Liu JJ, Liu TT, Huang NN, Yuan PY, Gao YJ, Zhao J, Guo XA, Liao F, Li FY, Wang XT, Yuan RJ, Wu F
- 4917** Woven coronary artery: A case report
Wei W, Zhang Q, Gao LM
- 4922** Idiopathic multicentric Castleman disease with pulmonary and cutaneous lesions treated with tocilizumab: A case report
Han PY, Chi HH, Su YT
- 4930** Perianorectal abscesses and fistula due to ingested jujube pit in infant: Two case reports
Liu YH, Lv ZB, Liu JB, Sheng QF
- 4938** Forniceal deep brain stimulation in severe Alzheimer's disease: A case report
Lin W, Bao WQ, Ge JJ, Yang LK, Ling ZP, Xu X, Jiang JH, Zuo CT, Wang YH
- 4946** Systemic autoimmune abnormalities complicated by cytomegalovirus-induced hemophagocytic lymphohistiocytosis: A case report
Miao SX, Wu ZQ, Xu HG
- 4953** Nasal mucosa pyoderma vegetans associated with ulcerative colitis: A case report
Yu SX, Cheng XK, Li B, Hao JH
- 4958** Amiodarone-induced hepatotoxicity — quantitative measurement of iodine density in the liver using dual-energy computed tomography: Three case reports
Lv HJ, Zhao HW
- 4966** Multisystem involvement Langerhans cell histiocytosis in an adult: A case report
Wang BB, Ye JR, Li YL, Jin Y, Chen ZW, Li JM, Li YP
- 4975** New mutation in EPCAM for congenital tufting enteropathy: A case report
Zhou YQ, Wu GS, Kong YM, Zhang XY, Wang CL
- 4981** Catastrophic vertebral artery and subclavian artery pseudoaneurysms caused by a fishbone: A case report
Huang W, Zhang GQ, Wu JJ, Li B, Han SG, Chao M, Jin K
- 4986** Anastomosing hemangioma arising from the left renal vein: A case report
Zheng LP, Shen WA, Wang CH, Hu CD, Chen XJ, Shen YY, Wang J
- 4993** Bladder perforation caused by long-term catheterization misdiagnosed as digestive tract perforation: A case report
Wu B, Wang J, Chen XJ, Zhou ZC, Zhu MY, Shen YY, Zhong ZX

- 4999** Primary pulmonary plasmacytoma accompanied by overlap syndrome: A case report and review of the literature
Zhou Y, Wang XH, Meng SS, Wang HC, Li YX, Xu R, Lin XH
- 5007** Gastrointestinal stromal tumor metastasis at the site of a totally implantable venous access port insertion: A rare case report
Yin XN, Yin Y, Wang J, Shen CY, Chen X, Zhao Z, Cai ZL, Zhang B
- 5013** Massive gastrointestinal bleeding caused by a Dieulafoy's lesion in a duodenal diverticulum: A case report
He ZW, Zhong L, Xu H, Shi H, Wang YM, Liu XC
- 5019** Plastic bronchitis associated with *Botrytis cinerea* infection in a child: A case report
Liu YR, Ai T
- 5025** Chest, pericardium, abdomen, and thigh penetrating injury by a steel rebar: A case report
Yang XW, Wang WT
- 5030** Monocular posterior scleritis presenting as acute conjunctivitis: A case report
Li YZ, Qin XH, Lu JM, Wang YP
- 5036** Choriocarcinoma with lumbar muscle metastases: A case report
Pang L, Ma XX
- 5042** Primary chondrosarcoma of the liver: A case report
Liu ZY, Jin XM, Yan GH, Jin GY
- 5049** Successful management of a tooth with endodontic-periodontal lesion: A case report
Alshawwa H, Wang JF, Liu M, Sun SF
- 5057** Rare imaging findings of hypersensitivity pneumonitis: A case report
Wang HJ, Chen XJ, Fan LX, Qi QL, Chen QZ
- 5062** Effective administration of cranial drilling therapy in the treatment of fourth degree temporal, facial and upper limb burns at high altitude: A case report
Shen CM, Li Y, Liu Z, Qi YZ

ABOUT COVER

Peer-reviewer of *World Journal of Clinical Cases*, Dr. Aleem Ahmed Khan is a Distinguished Scientist and Head of The Central Laboratory for Stem Cell Research and Translational Medicine, Centre for Liver Research and Diagnostics, Deccan College of Medical Sciences, Kanchanbagh, Hyderabad (India). Dr. Aleem completed his Doctorate from Osmania University, Hyderabad in 1998 and has since performed pioneering work in the treatment of acute liver failure and decompensated cirrhosis using hepatic stem cell transplantation. During his extensive research career he supervised 10 PhD students and published > 150 research articles, 7 book chapters, and 2 patents. His ongoing research involves developing innovative technologies for organ regeneration and management of advanced cancers. (L-Editor: Filipodia)

AIMS AND SCOPE

The primary aim of *World Journal of Clinical Cases* (*WJCC*, *World J Clin Cases*) is to provide scholars and readers from various fields of clinical medicine with a platform to publish high-quality clinical research articles and communicate their research findings online.

WJCC mainly publishes articles reporting research results and findings obtained in the field of clinical medicine and covering a wide range of topics, including case control studies, retrospective cohort studies, retrospective studies, clinical trials studies, observational studies, prospective studies, randomized controlled trials, randomized clinical trials, systematic reviews, meta-analysis, and case reports.

INDEXING/ABSTRACTING

The *WJCC* is now indexed in Science Citation Index Expanded (also known as SciSearch®), Journal Citation Reports/Science Edition, PubMed, and PubMed Central. The 2020 Edition of Journal Citation Reports® cites the 2019 impact factor (IF) for *WJCC* as 1.013; IF without journal self cites: 0.991; Ranking: 120 among 165 journals in medicine, general and internal; and Quartile category: Q3.

RESPONSIBLE EDITORS FOR THIS ISSUE

Production Editor: Ji-Hong Liu; Production Department Director: Xiang Li; Editorial Office Director: Jin-Lai Wang.

NAME OF JOURNAL

World Journal of Clinical Cases

ISSN

ISSN 2307-8960 (online)

LAUNCH DATE

April 16, 2013

FREQUENCY

Semimonthly

EDITORS-IN-CHIEF

Dennis A Bloomfield, Sandro Vento, Bao-Gan Peng

EDITORIAL BOARD MEMBERS

<https://www.wjgnet.com/2307-8960/editorialboard.htm>

PUBLICATION DATE

October 26, 2020

COPYRIGHT

© 2020 Baishideng Publishing Group Inc

INSTRUCTIONS TO AUTHORS

<https://www.wjgnet.com/bpg/gerinfo/204>

GUIDELINES FOR ETHICS DOCUMENTS

<https://www.wjgnet.com/bpg/GerInfo/287>

GUIDELINES FOR NON-NATIVE SPEAKERS OF ENGLISH

<https://www.wjgnet.com/bpg/gerinfo/240>

PUBLICATION ETHICS

<https://www.wjgnet.com/bpg/GerInfo/288>

PUBLICATION MISCONDUCT

<https://www.wjgnet.com/bpg/gerinfo/208>

ARTICLE PROCESSING CHARGE

<https://www.wjgnet.com/bpg/gerinfo/242>

STEPS FOR SUBMITTING MANUSCRIPTS

<https://www.wjgnet.com/bpg/GerInfo/239>

ONLINE SUBMISSION

<https://www.f6publishing.com>

Unremitting diarrhoea in a girl diagnosed anti-N-methyl-D-aspartate-receptor encephalitis: A case report

Norrapat Onpoaree, Montida Veeravigrom, Anapat Sanpavat, Narissara Suratannon, Palittiya Sintusek

ORCID number: Norrapat Onpoaree 0000-0002-0670-9454; Montida Veeravigrom 0000-0001-9913-8373; Anapat Sanpavat 0000-0002-6425-3379; Narissara Suratannon 0000-0003-1182-3611; Palittiya Sintusek 0000-0003-4441-0151.

Author contributions: Onpoaree N and Sintusek P reviewed the literature and drafted the manuscript; Veeravigrom M contributed to manuscript draft, interpreted the electroencephalography and made clinical correlation with brain images; Sanpavat A interpreted the histopathological data and provided the histopathology images; Suratannon N interpreted the immunologic study; Sintusek P performed endoscopy, provided the endoscopic images; and all authors approved the final manuscript.

Supported by The Pediatric Gastroenterology and Hepatology Research Unit, Thailand; Grants for Development of New Faculty Staff, Ratchadaphiseksomphot Endowment Fund, Thailand, No. RA63/012; and Thailand Research Fund Thailand Science Research and Innovation, Thailand, No. MRG6280190.

Informed consent statement: Informed written consent was obtained from the patient's

Norrapat Onpoaree, Faculty of Medicine, Chulalongkorn University, Bangkok 10330, Thailand

Montida Veeravigrom, Division of Neurology, Department of Pediatrics, Faculty of Medicine, Chulalongkorn University, Bangkok 10330, Thailand

Anapat Sanpavat, Division of Pathology, Faculty of Medicine, Chulalongkorn University, Bangkok 10330, Thailand

Narissara Suratannon, Division of Allergy, Department of Pediatrics, Faculty of Medicine, Chulalongkorn University, Bangkok 10330, Thailand

Palittiya Sintusek, Division of Gastroenterology and Pediatric Gastroenterology and Hepatology Research Unit, Department of Pediatrics, Faculty of Medicine, Chulalongkorn University, Bangkok 10330, Thailand

Corresponding author: Palittiya Sintusek, MD, MSc, Assistant Professor, Lecturer, Division of Gastroenterology and Pediatric Gastroenterology and Hepatology Research Unit, Department of Pediatrics, Faculty of Medicine, Chulalongkorn University, 1873, Rama 4 Road, Pathumwan, Bangkok 10330, Thailand. palittiya.s@chula.ac.th

Abstract

BACKGROUND

Asymptomatic cytomegalovirus (CMV) infection is common in children; in contrast, in children with a weakened immune system, invasive CMV can occur. This is the first case report of a severe manifestation of CMV esophago-enterocolitis in a girl diagnosed with anti-N-methyl-D-aspartate-receptor (anti-NMDAR) encephalitis who received only a moderate dose of corticosteroid therapy.

CASE SUMMARY

A 12-year-old-Thai girl presented with acute behavioural change and headache for 6 d. Electroencephalogram and positivity for NMDAR autoantibodies were compatible with anti-NMDAR encephalitis. Hence, she received pulse methylprednisolone 10 mg/kg per day for 4 d and continued with prednisolone 1.2 mg/kg per day. On day 42 of corticosteroid therapy, she developed unremitting vomiting and diarrhoea. Endoscopy showed multiple ulcers and erythematous mucosa along the gastrointestinal tract. Tissue CMV viral load and viral-infected cells confirmed CMV esophago-enterocolitis. Therefore, the patient received ganciclovir 5 mg/kg per dose every 12 h for 3 wk and then 5 mg/kg per

guardian (mother) for publication of this report and any accompanying images.

Conflict-of-interest statement: All authors declare that they have no conflict of interest.

CARE Checklist (2016) statement: The authors have read the CARE Checklist, and the manuscript was prepared and revised according to the CARE Checklist (2016).

Open-Access: This article is an open-access article that was selected by an in-house editor and fully peer-reviewed by external reviewers. It is distributed in accordance with the Creative Commons Attribution NonCommercial (CC BY-NC 4.0) license, which permits others to distribute, remix, adapt, build upon this work non-commercially, and license their derivative works on different terms, provided the original work is properly cited and the use is non-commercial. See: <http://creativecommons.org/licenses/by-nc/4.0/>

Manuscript source: Unsolicited manuscript

Received: April 11, 2020

Peer-review started: April 11, 2020

First decision: June 13, 2020

Revised: July 27, 2020

Accepted: September 25, 2020

Article in press: September 25, 2020

Published online: October 26, 2020

P-Reviewer: Fujino Y, Ueda H

S-Editor: Wang JL

L-Editor: A

P-Editor: Ma YJ



dose once daily for 3 wk. Unremitting diarrhoea slowly improved from stool output 1-4 L per day to 1-2 L per day after 3 wk of treatment. Pulse methylprednisolone 20 mg/kg for 5 d was initiated and continued with prednisolone 1 mg/kg per day. After this repeated pulse methylprednisolone treatment, surprisingly, diarrhoea subsided. Immunologic work-up was performed to rule out underlying immune deficiency with unremarkable results.

CONCLUSION

Unremitting diarrhoea from CMV esophago-enterocolitis subsided with antiviral and methylprednisolone therapy, implying the immune and NMDAR dysregulation in anti-NMDAR encephalitis.

Key Words: Diarrhoea; Vomiting; Autoimmune encephalitis; Children; Cytomegalovirus; Gastrointestinal; Case report

©The Author(s) 2020. Published by Baishideng Publishing Group Inc. All rights reserved.

Core Tip: We report a girl with behavioural change who was finally diagnosed with anti-N-methyl-D-aspartate-receptor (anti-NMDAR) encephalitis. She had unremitting vomiting and diarrhoea after 43 d of corticosteroid therapy and was later diagnosed with cytomegalovirus (CMV) esophago-enterocolitis. Surprisingly, these symptoms subsided after antiviral therapy followed by repeated pulse methylprednisolone targeting the anti-NMDAR encephalitis. CMV esophago-enterocolitis in a patient with anti-NMDAR encephalitis has not been reported before and is very rare in patients who receive only moderate-dose corticosteroids. We highlighted that immune dysregulation in autoimmune encephalitis and the linkage of anti-NMDAR receptors and the enteric nervous system might be the cause of severe gastrointestinal involvement.

Citation: Onpoaree N, Veeravigrom M, Sanpavat A, Suratannon N, Sintusek P. Unremitting diarrhoea in a girl diagnosed anti-N-methyl-D-aspartate-receptor encephalitis: A case report. *World J Clin Cases* 2020; 8(20): 4866-4875

URL: <https://www.wjgnet.com/2307-8960/full/v8/i20/4866.htm>

DOI: <https://dx.doi.org/10.12998/wjcc.v8.i20.4866>

INTRODUCTION

Cytomegalovirus (CMV) is a common viral pathogen infecting children. The majority of infected patients are asymptomatic. However, immunocompromised hosts, including individuals who underwent organ transplantation or those who received immunosuppressive drugs, have a high risk of experiencing symptoms of invasive CMV infection^[1]. CMV esophago-enterocolitis is a very rare condition in children, and the manifestation of unremitting vomiting and diarrhoea has not been reported in the literature before.

Anti-N-methyl-D-aspartate-receptor (anti-NMDAR) encephalitis has recently been recognized as a type of autoimmune encephalitis in children presenting with behavioural changes, seizures, psychiatric features and oromotor dyskinesia. The treatment outcome depends on prompt first- and second-line immunotherapy^[2,3]. Gastrointestinal (GI) manifestations in anti-NMDAR encephalitis patients have been reported in few studies as an autonomic dysregulation or complication of autoimmune encephalitis^[4,5]. The role of NMDA receptors in the enteric nervous system (ENS) of the GI tract has not yet been elucidated in patients with anti-NMDAR encephalitis.

Here, we present the case of a 12-year-old Thai girl with a diagnosis of anti-NMDAR encephalitis who developed abdominal bloating, feeding intolerance, and bilious vomiting concomitant with watery diarrhoea. Later, CMV esophago-enterocolitis was diagnosed by endoscopy with tissue histopathology and molecular techniques. Interestingly, the complete clinical response of these severe GI symptoms was successful after combination therapy for CMV infection and anti-NMDAR encephalitis.

CASE PRESENTATION

Chief complaints

A 12-year-old Thai girl who was previously healthy was referred to King Chulalongkorn Memorial Hospital due to behavioural change with fever and headache for 6 d.

History of present illness

Six day prior to referral to our hospital, the patient had bizarre behaviour. She had a conversation with herself and cried or laughed without explaining the reason. One day later, she had a fever and progressive headache. She has alteration of consciousness with waxing and waning in her consciousness. She had abnormal movements of her hands and could not write letters. She went to a nearby clinic and received roxithromycin, fexofenadine and paracetamol. She could not sleep at night and slept more during the daytime. Four days prior to admission, she started having aggressive behaviour with incomprehensible language. She did not sleep during the day or night. She had intermittent screaming with visual hallucination. Her visual hallucination was described as a moving snake or the death of relatives. She was admitted to Hua Hin Hospital. At the hospital, she still had a high-grade fever with intermittent episodes of screaming with aggressive behaviours. She underwent computed tomography scan (CT) brain and lumbar puncture. She received high-dose ceftriaxone, acyclovir, azithromycin and oseltamivir before referral to our hospital.

History of past illness

The patient did not have any other medical illness or history of any drug or substance abuse.

Personal and family history

There was no history of contagious diseases or neuropsychiatric conditions in the family. There was no history of consanguinity in the family.

Physical examination

On admission, the patient was well-grown and confused and had a low-grade fever with a body temperature of 38.4°C, a pulse rate of 110 beats per minute and a respiratory rate of 24 breaths per minute. The general physical examination was unremarkable. Neurological examination showed confusion with disorientation to time, place and person. Her Glasgow coma scale was E4M5V3. Her cranial nerve examination revealed 3 mm pupils that reacted to light bilaterally. She was incorporated with extraocular movement. Nasolabial folds were symmetric. The uvula was in the midline with a gag reflex present. She did not cooperate for motor examination. When she had aggressive behaviour, she moved all four extremities equally; oromotor dyskinesia and choreoathetosis were noted in bilateral extremities, reflex 3+ was noted in all extremities, Babinski's sign was equivocal and clonus was absent.

Laboratory examinations

Laboratory investigation revealed hemoglobin 123 g/L, white blood cell count (WBC) 4.83×10^9 /L (N 65, L28, M7%), platelet count 310×10^9 /L, sodium 140 mmol/L, potassium 3.8 mmol/L, chloride 104 mmol/L, bicarbonate 21.4 mmol/L, calcium 2.32 mmol/L, phosphorus 1.12 mmol/L, magnesium 0.97 mmol/L, glucose 5.1 mmol/L, TSH 3.35 μ U/mL, FT₄ 18 ng/L, anti-thyroglobulin < 10, anti-thyroid peroxidase < 9 IU/mL, C₃ 1.25 and C₄ 3.8 g/L. Cerebrospinal fluid (CSF) analysis revealed colourless fluid with WBC 13 cells/mm³ (100% mononuclear cells), protein 20.1 g/L and glucose 4.2 mmol/L. Gram staining and culture from CSF did not reveal any evidence of microorganisms. Infectious work-ups were all negative from nasopharyngeal swabs for respiratory syncytial virus and influenza A and B (Polymerase chain reaction, PCR); mycoplasma immunoglobulin (Ig) M and IgG; scrub typhus IgM and IgG; CSF for herpes simplex virus and enterovirus (PCR). Serum and CSF analysis showed that the patient was positive NMDAR autoantibodies. Electroencephalogram (EEG) monitoring showed an absent sleep-wake pattern with generalized slow waves 1-3 Hertz with maximum amplitude at the bilateral frontal area with a delta brush pattern. Ictal EEG demonstrated an abrupt onset of generalized rhythmic delta waves accompanied by clinical screaming and visual hallucination.

Imaging examinations

The CT brain scan from the local hospital showed small hypodense lesions in the left lentiform nucleus, and follow-up CT scans 8 d later were unremarkable.

This patient presented with fever, behavioural dysfunction, sleep-wake disturbance, oromotor dyskinesia, seizure and visual hallucination. These clinical symptoms suggest infection or inflammation of the central nervous system (CNS), especially in the limbic system, which includes the hypothalamus, hippocampus and amygdala. Based on our patient's clinical symptoms, the dysfunction also involved the frontal area and basal ganglia. The differential diagnoses were (1) infectious causes from viral, rickettsial or mycoplasma encephalitis or (2) noninfectious causes from autoimmune encephalitis or toxin/metabolic/Hashimoto's encephalopathy. Oromotor dyskinesia and delta brush EEG patterns are the key features leading to the suspicion of anti-NMDAR encephalitis, and CSF autoantibody results later confirmed our preliminary diagnosis.

The patient received pulse methylprednisolone 10 mg/kg per day for 4 d on the first day after she arrived at our hospital because of EEG delta brush patterns along with antimicrobial agents, phenytoin and risperidone. Her clinical condition did not respond, and she received 2 g/kg intravenous immunoglobulin divided into 5 d followed by plasmapheresis for a total of 10 d. After the first-line regimen, she received a maintenance dose of prednisolone of 1.2 mg/kg per day. During the hospital course, she developed superrefractory status epilepticus and was sent to the paediatric intensive care unit for close monitoring and seizure control. Second-line regimen, such as cyclophosphamide or rituximab, was not given due to septicemia.

On day 42 of prednisolone 1.2 mg/kg per day, her neurological status did not improve, and she developed upper gastrointestinal bleeding. The vomit was composed of coffee-ground content of 60 mL and bilious content of 30 mL. Her body temperature was 37.8°C. Abdominal examination revealed a distended and soft abdomen with hypoactive bowel sounds. She was consuming nothing orally, so a nasogastric tube was inserted, and intravenous fluid infusion and omeprazole intravenously 80 mg per day were initiated.

On days 43-50, the nasogastric fluid content remained bilious, with a volume of 250-1000 mL per day, and drooling occurred, with saliva content of up to 850 mL per day. There was a large volume of stool with an amount of 1-4 L per day despite no enteral feeding. The content was mostly greenish, watery and minimally mucous. The stool was sometimes mixed with old blood. Regarding the investigations, the haemoculture from the central line and arterial line revealed no microorganism growth. Stool examination revealed no white blood cells, red blood cells or evidence of suspected parasites. Stool culture revealed positive results for *Pseudomonas aeruginosa*. Imaging modalities were performed. The plain film acute abdomen series revealed decreased bowel gas from the fluid fill loop, and CT of the whole abdomen revealed circumferential wall thickening with mucosal hyperenhancement of the whole intestine, particularly the colon. The drooling from the saliva content could be inhibited with sublingual administration of atropine eye drops. Meropenem 120 mg/kg per day was started for *Pseudomonas aeruginosa* infection. Regarding intractable diarrhoea, antidiarrhoeal drugs were administered, including cholestyramine 80 mg/kg per dose every 8 h and octreotide 2 mcg/kg per dose subcutaneously every 12 h for many days without any improvement.

On day 50, the patient developed lower GI bleeding with a one-time amount of 400 mL.

Further diagnostic work-up

Then, we performed other stool test that revealed negative results for *Clostridium difficile* toxin, but the serum CMV PCR viral load revealed 5473 copies/mL. An esophagogastroduodenoscopy (EGD) and a colonoscopy showed whitish plaque on erythematous and breaking mucosa at the mid-distal oesophagus, erythematous mucosa in the stomach and first part of the duodenum, erythematous friable mucosa with debris and multiple aphthous ulcers at the terminal ileum, and multiple small shallow ulcers on mild erythematous mucosa in the caecum, ascending colon, transverse colon, descending colon, sigmoid and rectum (Figure 1). CMV viral load of the colonic tissue was > 500000 copies/mL.

Pathology examinations

The oesophageal, gastric, ileal and colonic biopsies show mixed inflammatory cells, including neutrophils, eosinophils, lymphocytes, and plasma cells. There were scattered viral-infected cells characterized by enlarged cells with intranuclear and

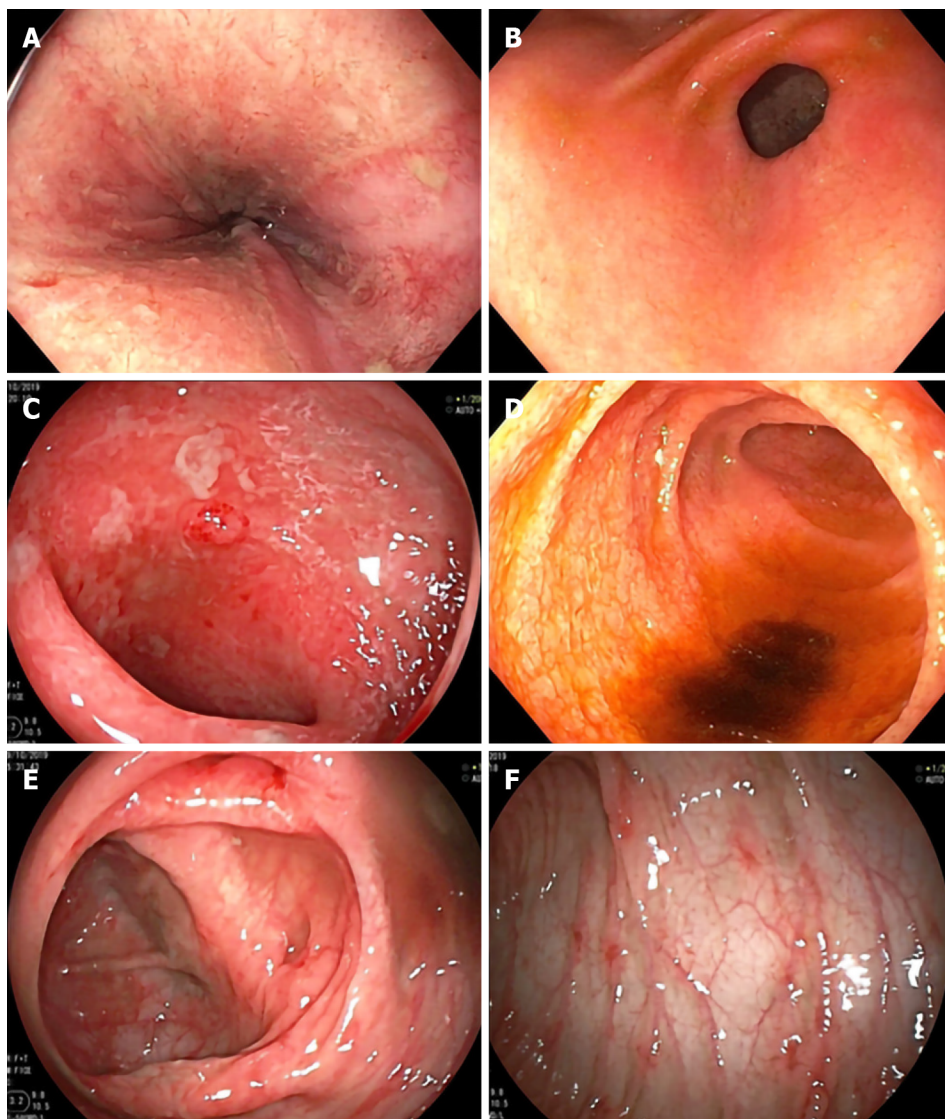


Figure 1 Esophagogastroduodenoscopy and colonoscopy demonstrated erythematous mucosae with multiple shallow ulcers and yellowish debris scattering along gastrointestinal tract. A: Lower oesophagus; B: Antrum; C: Duodenum; D: Terminal ileum; E: Transverse colon (hepatic flexure area); F: Descending colon.

intracytoplasmic inclusions in the oesophagus, ileum and colon. Immunohistochemistry for CMV was positive in these cells (Figure 2).

FINAL DIAGNOSIS

This patient was previously diagnosed with anti-NMDAR encephalitis and received immunosuppressive drugs with pulse methylprednisolone 10 mg/kg per day for 4 d, together with intravenous immunoglobulin 2 g/kg divided into 5 d. Subsequently, she was maintained on prednisolone 1.2 mg/kg per day until day 42 of this medication regimen, her neurological status did not improve, and she developed severe gastrointestinal problems with drooling, unremitting bilious vomiting and diarrhoea. The diarrhoea was a mix of blood, mucous and mainly watery content. The disease itself might cause hypersalivation, vomiting and diarrhoea as a result of autonomic disturbance. However, mucous bloody stool is less likely a GI presentation of anti-NMDAR encephalitis, so the infectious cause was explored. The EGD, colonoscopy and histopathology with immunohistochemistry staining and tissue CMV viral load confirmed the diagnosis of esophago-enterocolitis from invasive CMV infection.

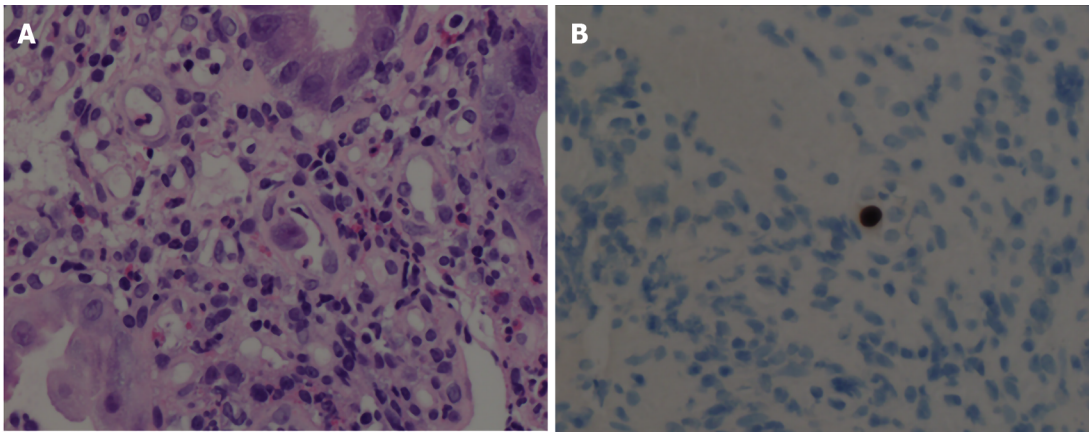


Figure 2 Histopathology demonstrates viral-infected cells. A: Hematoxylin and eosin stain of colonic tissue showed viral-infected cells (arrow) and mixed inflammatory cell infiltrate in lamina propria; B: Cytomegalovirus immunohistochemistry is positive.

TREATMENT

The patient was given ganciclovir 5 mg/kg per dose every 12 h for 3 wk and then shifted to ganciclovir 5 mg/kg per dose once daily for 3 wk. Unremitting diarrhoea slowly improved from stool output 1-4 L per day to 1-2 L per day after 3 wk of treatment and no content from the nasogastric tube. Due to her neurological status, pulse methylprednisolone 20 mg/kg for 5 d was initiated and continued with prednisolone 1 mg/kg per day. After this course of pulse methylprednisolone, surprisingly, diarrhoea subsided with a stool content of only 200-600 mg per day (Figure 3).

Due to the history of autoimmune encephalitis and invasive CMV esophago-enterocolitis, immunologic work-ups were performed to rule out an underlying immune deficiency. Serum IgG and IgM levels were transiently low: IgG 3.6 g/L (normal 6.98-11.94) and IgM 0.52 g/L (0.59-1) with normal IgA levels 0.34 g/L (0.22-2.74). However, the immunoglobulin levels were examined after 18 d of the second dose of pulse methylprednisolone. When the dose of corticosteroids was tapered or 35 d after the repeated dose of pulse methylprednisolone, serum IgG and IgM returned to normal: IgG 8.2 g/L (normal 6.98-11.94) and IgM 0.89 g/L (0.59-1). Flow cytometric analysis of lymphocyte populations was analysed only one time after she received the repeated dose of pulse methylprednisolone for 18 d. The results showed low numbers of total T lymphocytes (1127 cells/ μ L, 1400-2000), CD4⁺ T lymphocytes (647 cells/ μ L, 700-1100), CD8⁺ T lymphocytes (414 cells/ μ L, 600-900), NK lymphocytes (129 cells/ μ L, 27-693), and B lymphocytes (26, 300-500).

OUTCOME AND FOLLOW-UP

After 6 wk of ganciclovir and repeated doses of pulse methylprednisolone, EGD and colonoscopy were performed and showed normal mucosa of the oesophagus, stomach, duodenum, ileum and colon, and no virus-infected cells were seen from the histopathological specimen. Then, cyclophosphamide as the maintenance therapy for anti-NMDAR encephalitis was introduced. No serious infection or diarrhoea occurred after the course of cyclophosphamide. Otherwise, the patient gradually improved her neurological status. She remained stable during 10 mo of follow-up.

DISCUSSION

We reported a case of a 12-year-old Thai girl with a diagnosis of anti-NMDAR encephalitis who later presented with abdominal bloating, feeding intolerance due to drooling from hypersalivation, unremitting bilious vomiting and diarrhoea. Later, CMV esophago-enterocolitis was diagnosed. Severe gastrointestinal manifestations from invasive CMV are mostly described in heavily immunosuppressed patients, including HIV-infected patients, bone marrow or solid organ transplantation patients or patients with underlying primary immune deficiency. The present study

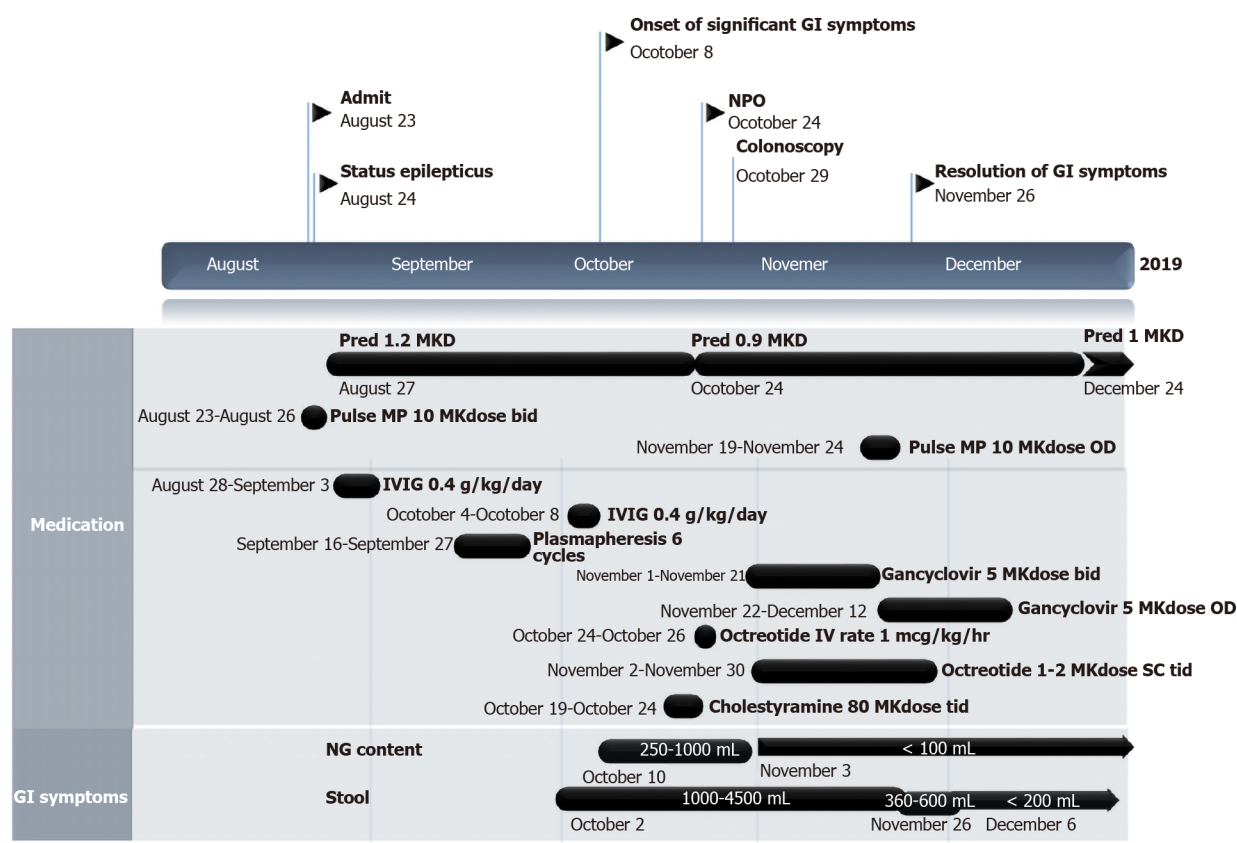


Figure 3 Clinical course of patient since the anti-N-methyl-D-aspartate-receptor encephalitis was diagnosed until severe gastrointestinal symptoms subsided. NPO: Nil per os; GI: Gastrointestinal; Pred: Prednisolone; MP: Methylprednisolone; IVIG: Intravenous immunoglobulin; MKdose: mg per kg per dose; MKD: mg per kg per day; IV: Intravenous; OD: Once a day; bid: Twice a day; tid: Three times a day; NG: Nasogastric; ALC: Absolute lymphocyte count; CMV: Cytomegalovirus.

demonstrated that an adolescent girl with anti-NMDAR encephalitis who received a moderate dose of corticosteroids presented with very severe invasive CMV infection of the GI system. Surprisingly, after CMV eradication, diarrhoea slowly improved but completely subsided after administering a higher dose of corticosteroid.

CMV, also known as human herpes virus 5, is one of the herpes viruses. It is highly host-specific to one species^[6]. Transmission occurs *via* direct person-to-person contact, such as contact with infected patient secretion including urine and saliva or sexual transmission. Other routes of transmission are *via* mother to child, antenatal, perinatal or postnatal routes and through blood product transfusion and organ transplantation. After one is exposed to the virus, CMV will remain in a latent form. Under some appropriate conditions, particularly impaired immune status, the virus can reactivate and cause symptoms. Infection occurs approximately 3 to 12 wk after blood transfusions^[6] and approximately 1 to 4 mo after organ transplantation^[6]. The pathogen can infect many targets including kidneys, pancreas, intestine, liver, heart, lung, tissue allograft, CNS or blood cells^[7], and, rarely, skin^[8]. The incubation period for horizontal transmission remains unknown. Clinical manifestations vary from asymptomatic, particularly in children, to symptomatic including infectious mononucleosis-like syndrome. In hosts with predominantly T-cell deficiency, it is possible to develop invasive CMV infection. GI involvement of CMV typically presents as mucous bloody diarrhoea, as the colon is mainly involved in up to 94% of cases^[9-11]. Several studies have reported the symptom of intractable diarrhoea that most likely occurs in the extremely aged population, infants^[12,13] and elderly individuals^[10,14]. To the best of our knowledge, this is a first case report of an adolescent girl diagnosed with autoimmune encephalitis who had both intractable diarrhoea and unremitting vomiting from CMV esophago-enterocolitis. The mechanism of secretory diarrhoea in this patient might be from the excessive stimulation of chloride-secretion by the release of tumor necrosis factor (TNF) and interleukin-6 (IL-6) from the CMV-infected monocytes and macrophages during the innate inflammatory response. According to one study, CMV was mainly detected by CD4 and toll-like receptor 2^[15], which are mainly expressed in monocytes and macrophages. The CMV-infected cells then undergo reprogramming of

gene expression involved in the innate immune response, lead to macrophage overactivation and massive inflammatory cytokine production, including TNF- α and IL-6^[16]. Moreover, the macrophages mostly reside in the GI mucosa^[16].

The potential risk factors for CMV esophago-enterocolitis based on our speculation include a moderate level of corticosteroid exposure. Interestingly, apart from reports on very severely immunocompromised hosts who underwent solid organ transplantation and on primary or secondary T-cell immunocompromised patients, there have been few reports of severe invasive CMV infection in patients who received pulse methylprednisolone or moderate dosage of prednisolone. Ozaki *et al*^[17] retrospectively studied 3733 patients with rheumatic disease and found only 9 patients who had CMV of the upper GI tract. Two patients received pulse methylprednisolone at doses of 0.5 and 1 g per day for 3 consecutive days followed by prednisolone at doses of 40 and 45 mg per day, respectively. Eight patients received more than 1 immunosuppressant (prednisolone, cyclophosphamide or methotrexate). Moreover, there have been 4 other case reports of rheumatic diseases^[18-21] in which 2 patients received pulse methylprednisolone followed by prednisolone, and 2 patients received only prednisolone therapy and developed CMV of upper GI tract. The significant risk factors for inactive CMV infection in a previous study of adults with rheumatic diseases were advanced age, lymphopenia and corticosteroid used^[22]. Regarding our patient, the girl received a moderate dose of corticosteroids and had secondary lymphopenia after that, which might reflect T-cell suppression leading to the invasive CMV infection. As there is no evidence of recurrent infections before this episode or family history of primary immunodeficiency and because the hypogammaglobulinemia was improved after the dose of corticosteroids was reduced, underlying immune deficiency in this patient was not likely. Evidently, serum immunoglobulins and numbers of lymphocyte subpopulations can decrease with corticosteroid administration^[23,24]. Consequently, our hypothesis is that anti-NMDAR encephalitis itself concomitant with temporary lymphopenia might have been another major factors in this severe CMV infection.

Previous studies in rats^[3,25,26] and humans^[27] have demonstrated the presence of NMDA receptors in the ENS, which are responsible for visceral hypersensitivity and the motor function of the ENS, leading to abdominal pain, diarrhoea or accelerated gastrointestinal transit time in the setting of colonic inflammation^[28]. In the clinical setting of patients with anti-NMDAR encephalitis, only 3 separate case reports have mentioned GI symptoms as the initial presentation or during disease treatment. Li-Ying Liu *et al*^[29] reported a 3-year-old boy who initially presented with severe vomiting and abdominal pain, developed a progressive alteration of mental status to delirium in 2 mo, developed progressive weakness and mutism and was later diagnosed with anti-NMDAR encephalitis. Another case reported by McCoy *et al*^[30] was a 6-year-old boy who presented with diarrhoea and vomiting followed by subacute progression of neuropsychiatric symptoms who was finally diagnosed with anti-NMDAR encephalitis. The last case was reported by Li *et al*^[4]: An 11-year-old girl who presented with acute alteration of consciousness, intermittent irrelevant speech and agitation at night. Diagnosis of anti-NMDAR encephalitis was made from detection of anti-NMDAR antibodies in both the serum and CSF. Two months after her admission, she experienced vomiting, abdominal pain and bleeding following intractable watery diarrhoea. Colonoscopy showed pancolitis, and unfortunately, she died from multiorgan failure 68 d after the symptom of unremitting diarrhoea. These case reports and our present case underscored GI involvement in patients with anti-NMDAR encephalitis. In our case report, we found invasive CMV infection along the GI tract, and severe GI symptoms exhibited a partial response after antiviral therapy and a complete response after the higher dose of immunosuppressant was used to treat anti-NMDAR encephalitis. The pathogenesis of invasive CMV infection in this patient is not exactly well understood. Immune dysfunction in this autoimmune encephalitis patient is unlikely, while complex immune dysregulation is continuing to be studied. The anti-NMDA receptors in the ENS might be stimulated by the inflammatory process following CMV infection, affecting motor function of the ENS and later causing severe GI motility disorders of intractable vomiting and diarrhoea. In general practice, once severe invasive CMV disease is confirmed, immunosuppressive agents should be decreased as much as possible to restore immune function, and initiation of antiviral therapy is merited. Most patients had a good clinical response to antiviral therapy within 1-3 wk of initiation^[31-34], which is not consistent with our case in which diarrhoea did not subside after 3 wk of therapy. Hence, we combined the treatment for CMV and anti-NMDAR encephalitis later because the clinical response was not satisfactory, as the immunosuppressant might restore the severe GI symptoms through the attenuation of the NMDA receptors in the ENS. Further studies on GI

manifestations or complications in patients with anti-NMDAR encephalitis are needed.

CONCLUSION

This case report highlighted GI involvement in a patient with anti-NMDAR encephalitis from invasive CMV, with partial response after antiviral therapy but complete response after a high dose of pulse methylprednisolone was provided as the first-line therapy for anti-NMDAR encephalitis. Immune dysregulation in autoimmune encephalitis and the relationship of NMDA receptors with ENS and GI symptoms should be further studied.

REFERENCES

- 1 **Vora SB**, Englund JA. Cytomegalovirus in immunocompromised children. *Curr Opin Infect Dis* 2015; **28**: 323-329 [PMID: [26098503](#) DOI: [10.1097/QCO.0000000000000174](#)]
- 2 **Goldberg EM**, Titulaer M, de Blank PM, Sievert A, Ryan N. Anti-N-methyl-D-aspartate receptor-mediated encephalitis in infants and toddlers: case report and review of the literature. *Pediatr Neurol* 2014; **50**: 181-184 [PMID: [24315538](#) DOI: [10.1016/j.pediatrneurol.2013.10.002](#)]
- 3 **Pruettarat N**, Netbamee W, Pattharathitkul S, Veeravigrom M. Clinical manifestations, treatment outcomes, and prognostic factors of pediatric anti-NMDAR encephalitis in tertiary care hospitals: A multicenter retrospective/prospective cohort study. *Brain Dev* 2019; **41**: 436-442 [PMID: [30639077](#) DOI: [10.1016/j.braindev.2018.12.009](#)]
- 4 **Li R**, Jiang L, Li XJ, Hong SQ, Zhong M, Hu Y. Analysis and discussion of the rare complication of autoimmune encephalitis: Two case reports. *Medicine (Baltimore)* 2018; **97**: e11202 [PMID: [29979382](#) DOI: [10.1097/MD.00000000000011202](#)]
- 5 **Pang LY**, Ding CH, Wang YY, Liu LY, Li QJ, Zou LP. Acute autonomic neuropathy with severe gastrointestinal symptoms in children: a case series. *BMC Neurol* 2017; **17**: 164 [PMID: [28841844](#) DOI: [10.1186/s12883-017-0943-x](#)]
- 6 **American Academy of Pediatrics**, Pickering LK. Red book: 2009 report of the Committee on Infectious Diseases. 28th ed. Elk Grove Village: American Academy of Pediatrics, 2009: 275-280
- 7 **Razonable RR**, Humar A; AST Infectious Diseases Community of Practice. Cytomegalovirus in solid organ transplantation. *Am J Transplant* 2013; **13** Suppl 4: 93-106 [PMID: [23465003](#) DOI: [10.1111/ajt.12103](#)]
- 8 **Trimarchi H**, Casas G, Jordan R, Martínez J, Schropp J, Freixas EA, Efrón E. Cytomegalovirus maculopapular eruption in a kidney transplant patient. *Transpl Infect Dis* 2001; **3**: 47-50 [PMID: [11429041](#) DOI: [10.1034/j.1399-3062.2001.003001047.x](#)]
- 9 **Patra S**, Samal SC, Chacko A, Mathan VI, Mathan MM. Cytomegalovirus infection of the human gastrointestinal tract. *J Gastroenterol Hepatol* 1999; **14**: 973-976 [PMID: [10530492](#) DOI: [10.1046/j.1440-1746.1999.01986.x](#)]
- 10 **Lee CY**, Chen YH, Lu PL. Reactivated cytomegalovirus proctitis in an immunocompetent patient presenting as nosocomial diarrhea: a case report and literature review. *BMC Infect Dis* 2017; **17**: 113 [PMID: [28143418](#) DOI: [10.1186/s12879-017-2218-y](#)]
- 11 **Fakhreddine AY**, Frenette CT, Konijeti GG. A Practical Review of Cytomegalovirus in Gastroenterology and Hepatology. *Gastroenterol Res Pract* 2019; **2019**: 6156581 [PMID: [30984257](#) DOI: [10.1155/2019/6156581](#)]
- 12 **Wang Y**, Huang Z, Ye Z, Zheng C, Jiang Z, Huang Y. Cytomegalovirus enteritis with intractable diarrhea in infants from a tertiary care center in China. *Scand J Gastroenterol* 2020; **55**: 55-61 [PMID: [31917930](#) DOI: [10.1080/00365521.2019.1706763](#)]
- 13 **Sue PK**, Salazar-Austin NM, McDonald OG, Rishi A, Cornish TC, Arav-Boger R. Cytomegalovirus Enterocolitis in Immunocompetent Young Children: A Report of Two Cases and Review of the Literature. *Pediatr Infect Dis J* 2016; **35**: 573-576 [PMID: [26862673](#) DOI: [10.1097/INF.0000000000001080](#)]
- 14 **John SG**, Dominguez C, Chandiramani V, Vemulapalli T. A rare case intractable diarrhea secondary to Clostridium difficile and cytomegalovirus coinfection. *Am J Case Rep* 2013; **14**: 498-501 [PMID: [24298304](#) DOI: [10.12659/AJCR.889700](#)]
- 15 **Compton T**, Kurt-Jones EA, Boehme KW, Belko J, Latz E, Golenbock DT, Finberg RW. Human cytomegalovirus activates inflammatory cytokine responses via CD14 and Toll-like receptor 2. *J Virol* 2003; **77**: 4588-4596 [PMID: [12663765](#) DOI: [10.1128/jvi.77.8.4588-4596.2003](#)]
- 16 **Redman TK**, Britt WJ, Wilcox CM, Graham MF, Smith PD. Human cytomegalovirus enhances chemokine production by lipopolysaccharide-stimulated lamina propria macrophages. *J Infect Dis* 2002; **185**: 584-590 [PMID: [11865414](#) DOI: [10.1086/339007](#)]
- 17 **Ozaki T**, Yamashita H, Kaneko S, Yorifuji H, Takahashi H, Ueda Y, Takahashi Y, Kaneko H, Kano T, Mimori A. Cytomegalovirus disease of the upper gastrointestinal tract in patients with rheumatic diseases: a case series and literature review. *Clin Rheumatol* 2013; **32**: 1683-1690 [PMID: [23942768](#) DOI: [10.1007/s10067-013-2363-7](#)]
- 18 **Henson D**. Cytomegalovirus inclusion bodies in the gastrointestinal tract. *Arch Pathol* 1972; **93**: 477-482 [PMID: [4337090](#)]
- 19 **Iwasaki T**. Alimentary tract lesions in cytomegalovirus infection. *Acta Pathol Jpn* 1987; **37**: 549-565 [PMID: [3039792](#) DOI: [10.1111/j.1440-1827.1987.tb00389.x](#)]
- 20 **Tokunaga N**, Sadahiro S, Kise Y, Suzuki T, Mukai M, Yasuda S, Ogoshi K, Tajima T, Makuuchi H. Gastrointestinal cytomegalovirus infection in collagen diseases. *Tokai J Exp Clin Med* 2003; **28**: 35-38

- [PMID: [12880302](#)]
- 21 **Panteris V**, Karakosta A, Merikas E, Peros G, Triantafyllidis JK. Gastric Outlet Obstruction due to Cytomegalovirus Infection in an Immunocompromised Patient. *Case Rep Gastroenterol* 2009; **3**: 280-285 [PMID: [21103242](#) DOI: [10.1159/000228895](#)]
 - 22 **Takizawa Y**, Inokuma S, Tanaka Y, Saito K, Atsumi T, Hirakata M, Kameda H, Hirohata S, Kondo H, Kumagai S, Tanaka Y. Clinical characteristics of cytomegalovirus infection in rheumatic diseases: multicentre survey in a large patient population. *Rheumatology (Oxford)* 2008; **47**: 1373-1378 [PMID: [18577548](#) DOI: [10.1093/rheumatology/ken231](#)]
 - 23 **Settipane GA**, Pudupakkam RK, McGowan JH. Corticosteroid effect on immunoglobulins. *J Allergy Clin Immunol* 1978; **62**: 162-166 [PMID: [681628](#) DOI: [10.1016/0091-6749\(78\)90101-x](#)]
 - 24 **Olmes MJ**, Kotliarov Y, Biancotto A, Cheung F, Chen J, Shi R, Zhou H, Wang E, Tsang JS, Nussenblatt R; CHI Consortium. Effects of Systemically Administered Hydrocortisone on the Human Immunome. *Sci Rep* 2016; **6**: 23002 [PMID: [26972611](#) DOI: [10.1038/srep23002](#)]
 - 25 **Park JH**, Moon HS. Cytomegalovirus colitis in immunocompetent patients. *Intest Res* 2018; **16**: 504-505 [PMID: [30090053](#) DOI: [10.5217/ir.2018.16.3.504](#)]
 - 26 **Ko JH**, Peck KR, Lee WJ, Lee JY, Cho SY, Ha YE, Kang CI, Chung DR, Kim YH, Lee NY, Kim KM, Song JH. Clinical presentation and risk factors for cytomegalovirus colitis in immunocompetent adult patients. *Clin Infect Dis* 2015; **60**: e20-e26 [PMID: [25452594](#) DOI: [10.1093/cid/ciu969](#)]
 - 27 **Qi Q**, Chen F, Zhang W, Wang P, Li Y, Zuo X. Colonic N-methyl-D-aspartate receptor contributes to visceral hypersensitivity in irritable bowel syndrome. *J Gastroenterol Hepatol* 2017; **32**: 828-836 [PMID: [27575648](#) DOI: [10.1111/jgh.13588](#)]
 - 28 **Zhou Q**, Nicholas Verne G. NMDA Receptors and Colitis: Basic Science and Clinical Implications. *Rev Analg* 2008; **10**: 33-43 [PMID: [20574552](#) DOI: [10.3727/154296108783994013](#)]
 - 29 **Liu LY**, Wang YY, Pang LY, Zhang GX, Zou LP. Anti-N-Methyl-D-Aspartate Receptor Encephalitis in a 3-Year-Old Toddler with the Involvement of Severe Autonomic Dysfunctions in Gastrointestinal System: A Case Report. *J Pediatr Neurol* 2019; **17**: 41-44 [DOI: [10.1055/s-0038-1623478](#)]
 - 30 **McCoy B**, Akiyama T, Widjaja E, Go C. Autoimmune limbic encephalitis as an emerging pediatric condition: case report and review of the literature. *J Child Neurol* 2011; **26**: 218-222 [PMID: [21183722](#) DOI: [10.1177/0883073810378536](#)]
 - 31 **Seo TH**, Kim JH, Ko SY, Hong SN, Lee SY, Sung IK, Park HS, Shim CS, Han HS. Cytomegalovirus colitis in immunocompetent patients: a clinical and endoscopic study. *Hepatogastroenterology* 2012; **59**: 2137-2141 [PMID: [23435132](#) DOI: [10.5754/hge10825](#)]
 - 32 **Yerushalmy-Feler A**, Padlipsky J, Cohen S. Diagnosis and Management of CMV Colitis. *Curr Infect Dis Rep* 2019; **21**: 5 [PMID: [30771028](#) DOI: [10.1007/s11908-019-0664-y](#)]
 - 33 **Jones A**, McCurdy JD, Loftus EV Jr, Bruining DH, Enders FT, Killian JM, Smyrk TC. Effects of antiviral therapy for patients with inflammatory bowel disease and a positive intestinal biopsy for cytomegalovirus. *Clin Gastroenterol Hepatol* 2015; **13**: 949-955 [PMID: [25283582](#) DOI: [10.1016/j.cgh.2014.09.042](#)]
 - 34 **Jain R**, Trehan A, Mishra B, Singh R, Saud B, Bansal D. Cytomegalovirus disease in children with acute lymphoblastic leukemia. *Pediatr Hematol Oncol* 2016; **33**: 239-247 [PMID: [27285991](#) DOI: [10.3109/08880018.2016.1173147](#)]



Published by **Baishideng Publishing Group Inc**
7041 Koll Center Parkway, Suite 160, Pleasanton, CA 94566, USA

Telephone: +1-925-3991568

E-mail: bpgoffice@wjgnet.com

Help Desk: <https://www.f6publishing.com/helpdesk>

<https://www.wjgnet.com>

