

# World Journal of *Clinical Cases*

*World J Clin Cases* 2020 November 6; 8(21): 5070-5495



## Contents

Semimonthly Volume 8 Number 21 November 6, 2020

## REVIEW

- 5070** Strategies and challenges in the treatment of chronic venous leg ulcers  
*Ren SY, Liu YS, Zhu GJ, Liu M, Shi SH, Ren XD, Hao YG, Gao RD*
- 5086** Peripheral nerve tumors of the hand: Clinical features, diagnosis, and treatment  
*Zhou HY, Jiang S, Ma FX, Lu H*

## MINIREVIEWS

- 5099** Treatment strategies for gastric cancer during the COVID-19 pandemic  
*Kang WZ, Zhong YX, Ma FH, Liu H, Ma S, Li Y, Hu HT, Li WK, Tian YT*

## ORIGINAL ARTICLE

## Retrospective Cohort Study

- 5104** Oncological impact of different distal ureter managements during radical nephroureterectomy for primary upper urinary tract urothelial carcinoma  
*Lai SC, Wu PJ, Liu JY, Seery S, Liu SJ, Long XB, Liu M, Wang JY*
- 5116** Clinical characteristics and survival of patients with normal-sized ovarian carcinoma syndrome: Retrospective analysis of a single institution 10-year experiment  
*Yu N, Li X, Yang B, Chen J, Wu MF, Wei JC, Li KZ*

## Retrospective Study

- 5128** Assessment of load-sharing thoracolumbar injury: A modified scoring system  
*Su QH, Li YC, Zhang Y, Tan J, Cheng B*
- 5139** Accuracy of endoscopic ultrasound-guided needle aspiration specimens for molecular diagnosis of non-small-cell lung carcinoma  
*Su W, Tian XD, Liu P, Zhou DJ, Cao FL*
- 5149** Application of hybrid operating rooms for clipping large or giant intracranial carotid-ophthalmic aneurysms  
*Zhang N, Xin WQ*
- 5159** Magnetic resonance imaging findings of carcinoma arising from anal fistula: A retrospective study in a single institution  
*Zhu X, Zhu TS, Ye DD, Liu SW*
- 5172** Efficacy and safety of S-1 maintenance therapy in advanced non-small-cell lung cancer patients  
*Cheng XW, Leng WH, Mu CL*

- 5180** Analysis of 234 cases of colorectal polyps treated by endoscopic mucosal resection  
*Yu L, Li N, Zhang XM, Wang T, Chen W*
- 5188** Epidemiological and clinical characteristics of fifty-six cases of COVID-19 in Liaoning Province, China  
*Wang JB, Wang HT, Wang LS, Li LP, Xu J, Xu C, Li XH, Wu YH, Liu HY, Li BJ, Yu H, Tian X, Zhang ZY, Wang Y, Zhao R, Liu JY, Wang W, Gu Y*
- 5203** Radiomics model for distinguishing tuberculosis and lung cancer on computed tomography scans  
*Cui EN, Yu T, Shang SJ, Wang XY, Jin YL, Dong Y, Zhao H, Luo YH, Jiang XR*
- 5213** Influence of transitional nursing on the compliance behavior and disease knowledge of children with purpura nephritis  
*Li L, Huang L, Zhang N, Guo CM, Hu YQ*
- Randomized Controlled Trial**
- 5221** Wavelet and pain rating index for inhalation anesthesia: A randomized controlled trial  
*Zhang JW, Lv ZG, Kong Y, Han CF, Wang BG*

**SYSTEMATIC REVIEWS**

- 5235** Essential phospholipids for nonalcoholic fatty liver disease associated with metabolic syndrome: A systematic review and network meta-analysis  
*Dajani AI, Popovic B*
- 5250** Cardiovascular impact of COVID-19 with a focus on children: A systematic review  
*Rodriguez-Gonzalez M, Castellano-Martinez A, Cascales-Poyatos HM, Perez-Reviriego AA*
- 5284** Anterior bone loss after cervical disc replacement: A systematic review  
*Wang XF, Meng Y, Liu H, Hong Y, Wang BY*

**CASE REPORT**

- 5296** Submicroscopic 11p13 deletion including the elongator acetyltransferase complex subunit 4 gene in a girl with language failure, intellectual disability and congenital malformations: A case report  
*Toral-Lopez J, González Huerta LM, Messina-Baas O, Cuevas-Covarrubias SA*
- 5304** Pancreatic panniculitis and elevated serum lipase in metastasized acinar cell carcinoma of the pancreas: A case report and review of literature  
*Miksch RC, Schiergens TS, Weniger M, Ilmer M, Kazmierczak PM, Guba MO, Angele MK, Werner J, D'Haese JG*
- 5313** Diffusion-weighted imaging might be useful for reactive lymphoid hyperplasia diagnosis of the liver: A case report  
*Tanaka T, Saito K, Yunaiyama D, Matsubayashi J, Nagakawa Y, Tanigawa M, Nagao T*
- 5320** Nafamostat mesylate-induced hyperkalemia in critically ill patients with COVID-19: Four case reports  
*Okajima M, Takahashi Y, Kaji T, Ogawa N, Mouri H*

- 5326** Arthroscopic treatment of iliopsoas tendinitis after total hip arthroplasty with acetabular cup malposition: Two case reports  
*Won H, Kim KH, Jung JW, Kim SY, Baek SH*
- 5334** Successful treatment of a high-risk nonseminomatous germ cell tumor using etoposide, methotrexate, actinomycin D, cyclophosphamide, and vincristine: A case report  
*Yun J, Lee SW, Lim SH, Kim SH, Kim CK, Park SK*
- 5341** Donepezil-related inadequate neuromuscular blockade during laparoscopic surgery: A case report  
*Jang EA, Kim TY, Jung EG, Jeong S, Bae HB, Lee S*
- 5347** Successful treatment of relapsed acute promyelocytic leukemia with arsenic trioxide in a hemodialysis-dependent patient: A case report  
*Lee HJ, Park SG*
- 5353** Treatment of afferent loop syndrome using fluoroscopic-guided nasointestinal tube placement: Two case reports  
*Hu HT, Ma FH, Wu ZM, Qi XH, Zhong YX, Xie YB, Tian YT*
- 5361** Emergency surgical workflow and experience of suspected cases of COVID-19: A case report  
*Wu D, Xie TY, Sun XH, Wang XX*
- 5371** Seven-year follow-up of the nonsurgical expansion of maxillary and mandibular arches in a young adult: A case report  
*Yu TT, Li J, Liu DW*
- 5380** Pancreatic cancer with ovarian metastases: A case report and review of the literature  
*Wang SD, Zhu L, Wu HW, Dai MH, Zhao YP*
- 5389** Early ultrasound diagnosis of conjoined twins at eight weeks of pregnancy: A case report  
*Liang XW, Cai YY, Yang YZ, Chen ZY*
- 5394** Supermicroscopy and arterio-venolization for digit replantation in young children after traumatic amputation: Two case reports  
*Chen Y, Wang ZM, Yao JH*
- 5401** Candidal periprosthetic joint infection after primary total knee arthroplasty combined with ipsilateral intertrochanteric fracture: A case report  
*Xin J, Guo QS, Zhang HY, Zhang ZY, Talmy T, Han YZ, Xie Y, Zhong Q, Zhou SR, Li Y*
- 5409** Aspiration pneumonia during general anesthesia induction after esophagectomy: A case report  
*Tang JX, Wang L, Nian WQ, Tang WY, Xiao JY, Tang XX, Liu HL*
- 5415** Large and unusual presentation of gallbladder adenoma: A case report  
*Cao LL, Shan H*
- 5420** Rare narrow QRS tachycardia with atrioventricular dissociation: A case report  
*Zhu C, Chen MX, Zhou GJ*

- 5426** Synchronous parathyroid adenoma, papillary thyroid carcinoma and thyroid adenoma in pregnancy: A case report  
*Li Q, Xu XZ, Shi JH*
- 5432** Pseudohyperkalemia caused by essential thrombocythemia in a patient with chronic renal failure: A case report  
*Guo Y, Li HC*
- 5439** Acute leukemic phase of anaplastic lymphoma kinase-anaplastic large cell lymphoma: A case report and review of the literature  
*Zhang HF, Guo Y*
- 5446** Chinese patient with cerebrotendinous xanthomatosis confirmed by genetic testing: A case report and literature review  
*Cao LX, Yang M, Liu Y, Long WY, Zhao GH*
- 5457** Incomplete Kawasaki disease complicated with acute abdomen: A case report  
*Wang T, Wang C, Zhou KY, Wang XQ, Hu N, Hua YM*
- 5467** Fanconi-Bickel syndrome in an infant with cytomegalovirus infection: A case report and review of the literature  
*Xiong LJ, Jiang ML, Du LN, Yuan L, Xie XL*
- 5474** Benign symmetric lipomatosis (Madelung's disease) with concomitant incarcerated femoral hernia: A case report  
*Li B, Rang ZX, Weng JC, Xiong GZ, Dai XP*
- 5480** Potential protection of indocyanine green on parathyroid gland function during near-infrared laparoscopic-assisted thyroidectomy: A case report and literature review  
*Peng SJ, Yang P, Dong YM, Yang L, Yang ZY, Hu XE, Bao GQ*
- 5487** New treatment of patellar instability after total knee arthroplasty: A case report and review of literature  
*Shen XY, Zuo JL, Gao JP, Liu T, Xiao JL, Qin YG*

**CORRECTION**

- 5494** Erratum: Author's Affiliation Correction. Type II human epidermal growth factor receptor heterogeneity is a poor prognosticator for type II human epidermal growth factor receptor positive gastric cancer (World J Clin Cases 2019; Aug 6; 7 (15): 1964-1977)  
*Kaito A, Kuwata T, Tokunaga M, Shitara K, Sato R, Akimoto T, Kinoshita T*



**ABOUT COVER**

Peer-reviewer for *World Journal of Clinical Cases*, Dr. Karayiannakis is Professor of Surgery at the Medical School of Democritus University of Thrace. He received his MD from the Medical Academy, Sofia, Bulgaria (1985), an MSc in Surgical Science from University of London (1996), and a PhD from National and Kapodistrian University of Athens (NKUA) (1993). After completing training at the NKUA Medical School in 1993, Dr. Karayiannakis undertook postgraduate training at St George's and Hammersmith Hospitals (London), the Institute for Digestive Diseases (Serbia), the University of Verona (Italy), and the Technical University of Munich (Germany). His clinical practice interests and research emphasis are in the field of hepato-pancreato-biliary diseases and gastrointestinal tract surgery, surgical oncology and laparoscopic surgery. (L-Editor: Filipodia)

**AIMS AND SCOPE**

The primary aim of *World Journal of Clinical Cases* (*WJCC*, *World J Clin Cases*) is to provide scholars and readers from various fields of clinical medicine with a platform to publish high-quality clinical research articles and communicate their research findings online.

*WJCC* mainly publishes articles reporting research results and findings obtained in the field of clinical medicine and covering a wide range of topics, including case control studies, retrospective cohort studies, retrospective studies, clinical trials studies, observational studies, prospective studies, randomized controlled trials, randomized clinical trials, systematic reviews, meta-analysis, and case reports.

**INDEXING/ABSTRACTING**

The *WJCC* is now indexed in Science Citation Index Expanded (also known as SciSearch®), Journal Citation Reports/Science Edition, PubMed, and PubMed Central. The 2020 Edition of Journal Citation Reports® cites the 2019 impact factor (IF) for *WJCC* as 1.013; IF without journal self cites: 0.991; Ranking: 120 among 165 journals in medicine, general and internal; and Quartile category: Q3.

**RESPONSIBLE EDITORS FOR THIS ISSUE**

Production Editor: Yan-Xia Xing; Production Department Director: Yun-Xiaojuan Wu; Editorial Office Director: Jin-Lai Wang.

**NAME OF JOURNAL**

*World Journal of Clinical Cases*

**ISSN**

ISSN 2307-8960 (online)

**LAUNCH DATE**

April 16, 2013

**FREQUENCY**

Semimonthly

**EDITORS-IN-CHIEF**

Dennis A Bloomfield, Sandro Vento, Bao-Gan Peng

**EDITORIAL BOARD MEMBERS**

<https://www.wjgnet.com/2307-8960/editorialboard.htm>

**PUBLICATION DATE**

November 6, 2020

**COPYRIGHT**

© 2020 Baishideng Publishing Group Inc

**INSTRUCTIONS TO AUTHORS**

<https://www.wjgnet.com/bpg/gerinfo/204>

**GUIDELINES FOR ETHICS DOCUMENTS**

<https://www.wjgnet.com/bpg/GerInfo/287>

**GUIDELINES FOR NON-NATIVE SPEAKERS OF ENGLISH**

<https://www.wjgnet.com/bpg/gerinfo/240>

**PUBLICATION ETHICS**

<https://www.wjgnet.com/bpg/GerInfo/288>

**PUBLICATION MISCONDUCT**

<https://www.wjgnet.com/bpg/gerinfo/208>

**ARTICLE PROCESSING CHARGE**

<https://www.wjgnet.com/bpg/gerinfo/242>

**STEPS FOR SUBMITTING MANUSCRIPTS**

<https://www.wjgnet.com/bpg/GerInfo/239>

**ONLINE SUBMISSION**

<https://www.f6publishing.com>



## Anterior bone loss after cervical disc replacement: A systematic review

Xiao-Fei Wang, Yang Meng, Hao Liu, Ying Hong, Bei-Yu Wang

**ORCID number:** Xiao-Fei Wang 0000-0002-7004-1911; Yang Meng 0000-0001-6879-2225; Hao Liu 0000-0002-6938-8774; Ying Hong 0000-0003-3141-0435; Bei-Yu Wang 0000-0002-3688-8959.

**Author contributions:** Liu H designed the research; Wang XF and Meng Y performed the research; Wang XF and Meng Y analyzed the data; Wang XF wrote the paper; Liu H, Wang BY and Hong Y supervised the paper; all authors read and approved the final manuscript.

**Supported by** West China Nursing Discipline Development Special Fund Project, Sichuan University, No. HXHL19016; and 1.3.5 Project for Disciplines of Excellence, West China Hospital, Sichuan University, No. ZYJC18029.

**Conflict-of-interest statement:** The authors declare they have no conflict of interest.

**PRISMA 2009 Checklist statement:** The authors have read the PRISMA 2009 Checklist, and the manuscript was prepared and revised according to the PRISMA 2009 Checklist.

**Open-Access:** This article is an open-access article which was selected by an in-house editor and fully peer-reviewed by external

**Xiao-Fei Wang, Yang Meng, Hao Liu, Bei-Yu Wang,** Department of Orthopaedic Surgery, West China Hospital, Sichuan University, Chengdu 610041, Sichuan Province, China

**Ying Hong,** Department of Anesthesia and Operation Center/West China School of Nursing, West China Hospital, Sichuan University, Chengdu 610041, Sichuan Province, China

**Corresponding author:** Hao Liu, MD, PhD, Professor, Surgeon, Department of Orthopaedic Surgery, West China Hospital, Sichuan University, No. 37 Guo Xue Xiang, Wuhou District, Chengdu 610041, Sichuan Province, China. [dr.liuhao6304@yahoo.com](mailto:dr.liuhao6304@yahoo.com)

### Abstract

#### BACKGROUND

Anterior bone loss (ABL) is a relatively easily neglected condition after cervical disc replacement (CDR). Whether this phenomenon is a radiological anomaly or a complication remains controversial. Several studies have reported the clinical characteristics of ABL and speculated on the pathogenic mechanism based on a certain type of artificial disc, while the overall understanding of ABL is lacking.

#### AIM

To describe the prevalence, impacts, and risk factors of ABL after CDR.

#### METHODS

We searched the PubMed, Cochrane Library, and Excerpta Medica databases using the terms “bone loss” or “bone remodeling” or “bone absorption” or “osteolysis” or “implant loosening” or “implant migration” or “hypersensitivity” or “hyperreactivity”, “cervical disc replacement” or “cervical disc arthroplasty” or “total disc replacement”. Eligible manuscripts on the prevalence and impacts of ABL were reviewed by the authors. Data extraction was performed using an established extraction form. The results of the included studies were described narratively.

#### RESULTS

Six studies met the inclusion and exclusion criteria. One was a prospective study and the others were retrospective studies. A total of 440 patients with 536 segments were included. The artificial cervical discs included Bryan, Baguera-C, Discocerv, and Mobi-C. The prevalence of ABL ranged from 3.13% to 91.89%, with a combined overall prevalence of 41.84%. ABL occurred within 6 mo and stopped 12 mo after surgery. Several cases were noted to have a self-healing process. Severe ABL resulted in segmental kyphosis, implant subsidence, and persistent

reviewers. It is distributed in accordance with the Creative Commons Attribution Non Commercial (CC BY-NC 4.0) license, which permits others to distribute, remix, adapt, build upon this work non-commercially, and license their derivative works on different terms, provided the original work is properly cited and the use is non-commercial. See: <http://creativecommons.org/licenses/by-nc/4.0/>

**Manuscript source:** Unsolicited manuscript

**Specialty type:** Medicine, research and experimental

**Country/Territory of origin:** China

**Peer-review report's scientific quality classification**

Grade A (Excellent): 0  
Grade B (Very good): 0  
Grade C (Good): 0  
Grade D (Fair): 0  
Grade E (Poor): 0

**Received:** May 6, 2020

**Peer-review started:** May 6, 2020

**First decision:** August 23, 2020

**Revised:** September 5, 2020

**Accepted:** September 16, 2020

**Article in press:** September 16, 2020

**Published online:** November 6, 2020

**P-Reviewer:** Mehren C

**S-Editor:** Zhang L

**L-Editor:** Webster JR

**P-Editor:** Ma YJ



neck pain. ABL may be related to heterotopic ossification. Multilevel surgery may be one of the risk factors for ABL.

## CONCLUSION

ABL is a common condition after CDR. The underlying mechanisms of ABL may include stress concentration and injury to nutrient vessels. ABL should be considered a complication after CDR as it was associated with neck pain, implant subsidence, and heterotopic ossification.

**Key Words:** Bone loss; Bone remodeling; Stress shielding; Risk factor; Systematic review

©The Author(s) 2020. Published by Baishideng Publishing Group Inc. All rights reserved.

**Core Tip:** Anterior bone loss (ABL) is a common condition after cervical disc replacement. Several studies have reported the clinical characteristics of ABL; however, it remains unclear whether this phenomenon is a radiological anomaly or a complication. In this review, we found that the prevalence of ABL after cervical disc replacement was related to the type of implant. ABL should be considered a complication after cervical disc replacement as it was associated with neck pain, implant subsidence, and heterotopic ossification. Fortunately, ABL did not progress after 12 mo postoperatively, and some cases showed a self-healing phenomenon. The underlying mechanisms of ABL may include stress concentration and injury to nutrient vessels.

**Citation:** Wang XF, Meng Y, Liu H, Hong Y, Wang BY. Anterior bone loss after cervical disc replacement: A systematic review. *World J Clin Cases* 2020; 8(21): 5284-5295

**URL:** <https://www.wjgnet.com/2307-8960/full/v8/i21/5284.htm>

**DOI:** <https://dx.doi.org/10.12998/wjcc.v8.i21.5284>

## INTRODUCTION

Anterior cervical discectomy and fusion (ACDF) is recognized as the standard procedure for cervical degenerative disc disease. However, concerns such as non-union, pseudarthrosis, and acceleration of adjacent segment degeneration have been raised<sup>[1-4]</sup>. Compared with ACDF, cervical disc replacement (CDR), a motion preservation technique, can reduce intervertebral disc pressure in adjacent levels and better simulate the physiological condition of the cervical spine<sup>[5,6]</sup>. Studies have shown that CDR and ACDF have equivalent efficiency in clinical outcomes such as symptom relief<sup>[7,8]</sup>. However, CDR is better in some respects, such as faster recovery, higher patient satisfaction, and is more cost-effective<sup>[9,10]</sup>.

Although CDR is widely performed and patients have benefited due to its satisfying results, it has some implant-related complications, such as heterotopic ossification (HO), implant migration, and implant subsidence<sup>[11-16]</sup>. With regard to these complications, in-depth studies have been performed to determine the potential risk factors and clinical impacts<sup>[17-20]</sup>. In contrast to excessive bone formation (which is HO), anterior bone loss (ABL) is another implant-related condition after CDR and has gained more attention in recent years<sup>[21]</sup>. ABL is the process of bone rebuilding in the ventral part of vertebral bodies, and can usually be recognized from lateral radiographs. Peri-prosthetic bone loss has been extensively described in large joint arthroplasty. However, ABL is easily ignored in cervical disc arthroplasty.

The prevalence of ABL after CDR varies from 3.13% to 91.89% and differs greatly among different types of artificial cervical discs<sup>[22-27]</sup>. Several studies have reported the clinical characteristics of ABL and speculated the pathogenic mechanism based on a certain type of artificial disc, while the overall understanding of ABL after CDR is lacking. In addition, it remains controversial whether ABL is a radiological anomaly or a complication. Therefore, we performed this systematic review of currently available clinical data to comprehensively describe the prevalence, impacts, and risk factors of ABL after CDR.



## MATERIALS AND METHODS

A comprehensive literature search was carried out in PubMed, Cochrane Library, and the Excerpta Medica databases. Studies before May 2019 were included. The following keywords were used in the search: “bone loss” or “bone remodeling” or “bone absorption” or “osteolysis” or “implant loosening” or “implant migration” or “hypersensitivity” or “hyperreactivity”, “cervical disc replacement” or “cervical disc arthroplasty” or “total disc replacement”. Articles published in English that involved peri-prosthetic bone absorption after CDR were specifically identified. The references of all identified papers were manually reviewed to identify further potentially relevant studies.

The search produced 1460 published articles. We then systematically assessed the selected articles. The inclusion criteria were as follows: (1) peri-prosthetic bone loss occurred in the surgical segment after CDR; and (2) bone remodeling occurred in the anterior/ventral part of vertebral bodies. The exclusion criteria were as follows: (1) Peri-prosthetic bone loss occurred in another part of the vertebral bodies, (2) Case reports, (3) Reviews, (4) Commentaries, and (5) Cadaveric or experimental studies. The results of the literature search are shown in [Figure 1](#).

The screening of titles and abstracts was performed by two reviewers (Wang XF and Meng Y) independently. Articles that met the eligibility criteria on the first screening were further assessed by reading the full text. After screening, six clinical studies were included in the systematic review. The two reviewers (Wang XF and Meng Y) then performed data extraction and rated the level of evidence of each article independently using the published guideline<sup>[28]</sup>. The results of this study were described narratively.

## RESULTS

One randomized controlled study and five retrospective studies were included in this review<sup>[22-27]</sup>. A total of 440 patients with 536 segments were included. The mean age of these patients ranged from 45.3 to 50.1 years, and the mean follow-up time ranged from 32.3 to 74.4 mo. The artificial cervical discs included Bryan, Baguera-C, Discocerv, and Mobi-C. The surgical procedure included single-level CDR, double-level CDR, triple-level CDR, and hybrid surgery. Study information and level of evidence are listed in [Table 1](#). Detailed information on ABL including the prevalence, course, effects, and outcomes are summarized in [Tables 2-4](#) and [Figure 2](#).

### Overview of ABL after cervical disc arthroplasty

ABL was identified on lateral X-rays in all six studies, and had the following two signs: first, the ventral-inferior part of the cranial vertebra or the ventral-superior part of the caudal vertebra at the arthroplasty level disappeared; second, the cortical bone margin of the ABL area still existed and shifted dorsally.

The prevalence of ABL ranged from 3.13% to 91.89%, with a combined overall prevalence of 41.84%, and it differed depending on the implant type. The Mobi-C showed the highest prevalence of ABL (91.89%), followed by the Baguera-C (60.42%-64.29%, 62.50% after combination), Discocerv (47.73%) and Bryan (3.13%-57.14%, 22.16% after combination). In the study by Kieser *et al*<sup>[26]</sup>, the cranial vertebra showed a higher ABL rate.

ABL occurred within 3-6 mo postoperatively and did not progress after 12 mo postoperatively in most cases. Kieser *et al*<sup>[26,27]</sup> reported a “self-healing phenomenon” of ABL in several cases, but they did not present other radiological evidence to prove that the self-healing was not caused by HO. In the study by Hacker, one patient with ABL received revision fusion surgery to relieve symptoms<sup>[23]</sup>.

### The grading system of ABL

Three studies reported the grading system of ABL based on the lateral radiographs ([Table 2](#)). Heo *et al*<sup>[25]</sup> divided the ABL into three grades: Grade 1 refers to a small part of the vertebra with ABL; Grade 2 indicates a larger portion of the vertebra with ABL compared with Grade 1, but the implant was not exposed; Grade 3 refers to significant bone loss with exposure of the implant. This non-quantitative grading method is ambiguous when classifying Grade 1 and 2 ABL. The authors then assigned Grade 1 and 2 ABL into the minor change Group (without exposure of implants), and assigned Grade 3 into the major change group (with implant exposure). The prevalence of ABL was 43.75% in the minor change group and 16.67% in the major change group. This grading system is not suitable for artificial discs with an anterior flange such as Bryan,

**Table 1 Studies included in the systematic review**

Ref.	Yr	Study type	Level of evidence	Number and type of artificial disc	Sex	Age (yr)	Follow-up
Ren <i>et al</i> <sup>[22]</sup>	2011	Prospective and nonrandomized study	3	Total (Bryan): 45 patients and 51 implants	19 Female; 26 Male	46 (31-50)	Mean 35 (24-70) mo
Hacker <i>et al</i> <sup>[23]</sup>	2013	Randomized controlled study	2	Total 51 patients; Bryan: 32 patients; Prestige-LP: 19 patients	27 Female; 24 Male	-	1, 6, 12, 24 wk and 12, 24, 48, 60 mo
Kim <i>et al</i> <sup>[24]</sup>	2015	Prospective registry with retrospective analysis	3	Total (Bryan): 37 patients	13 Female; 24 Male	45.4 (27-55)	1, 3, 6, 12, 24, 36 mo, mean 60.1 (42-113) mo
Heo <i>et al</i> <sup>[25]</sup>	2017	Retrospective observational study	3	Total (Baguera-C): 48 patients	30 Female; 18 Male	50.1 ± 7.4	1, 6, 12, 24 mo, mean 32.3 ± 3.3 mo
Kieser <i>et al</i> <sup>[26]</sup>	2018	Retrospective observational study	3	Total 145 patients and 193 implants; Bryan: 32 patients, 56 implants; Discocerv: 38 patients, 44 implants; Baguera-C: 44 patients, 56 caudal implants; Mobi-C: 31 patients, 37 implants	78 Female; 67 Male	45 (25-65)	3, 6, 12, 24, 36, 48, 60 mo, mean 6.2 (5-10) yr
Kieser <i>et al</i> <sup>[27]</sup>	2019	Retrospective observational study	3	Total 114 patients and 156 implants; Bryan: 32 patients, 56 implants; Discocerv: 38 patients, 44 implants; Baguera-C: 44 patients, 56 caudal implants	65 Female; 49 Male	45.3 (28-65)	6 wk, 3, 6, 9, 12, 24 mo, 5 yr, maximum 8 yr

**Table 2 Summary of the combined data of anterior bone loss in cervical disc replacement**

Implant	Prevalence	Course	Effect	Outcome
Total	41.84% (159/380)	Occur within 3 mo postop; Does not progress after 12 mo postop; Self-healing in several cases	Higher VAS score within 12 mo postop in severe cases; Exposure or subsidence of implants in severe cases	No significant difference compared with patients without bone loss at the last follow-up
Bryan	22.16% (39/176)			
Discocerv	47.73% (21/44)			
Baguera-C	62.50% (65/104)			
Mobi-C	91.89% (34/37)			

VAS: Visual analogue score; postop: Postoperatively.

because a small portion of ABL would cause implant exposure. Besides, an obvious ABL may be assigned to the minor change group due to the posteriorly positioned implant.

Kieser *et al*<sup>[26]</sup> introduced a quantitative grading method based on the lateral radiographs. They calculated the ratio of the bone loss distance and the initial length of the endplate and then divided the ABL into three groups: mild (ratio ≤ 5%), moderate (5% < ratio ≤ 10%), and severe (ratio > 10%). The prevalence of ABL was 48.7% in the mild group, 11.92% in the moderate group, and 3.11% in the severe group, respectively. Severe ABL caused implant exposure or subsidence.

In 2019, Kieser *et al*<sup>[27]</sup> slightly revised their grading system. They divided severe ABL into two subgroups: severe with endplate collapse (four patients), and severe without endplate collapse (one patient, who showed a self-healing process). However, in their grading system, there was no significant difference among the groups in terms of radiological or clinical outcomes. Therefore, this grading system is not instructive in clinical work.

### Outcomes of ABL

All patients with ABL achieved similar clinical outcomes at the last follow-up, compared with those who did not develop ABL. In the study by Ren *et al*<sup>[22]</sup>, three patients had ABL, and they did not complain of any subjective discomfort. Two patients had ABL < 2 mm and Grade 2 HO was observed in one of them; one patient

**Table 3 Summarized data of incidence and identification of anterior bone loss**

Ref.	Prevalence	Notification time	Course of ABL	Grading system
Ren <i>et al</i> <sup>[22]</sup>	Bryan: 5.88% more cases were noted from the figures	Within 6 mo postop	Stopped after 6 mo postop	Not reported; ABL distance: < 2 mm in 2 patients, > 2 mm in 1 patient
Hacker <i>et al</i> <sup>[23]</sup>	Total: 1.96%, Bryan: 3.13%; Prestige-LP: 0	6 wk postop	Not reported	Not reported
Kim <i>et al</i> <sup>[24]</sup>	Bryan: 8.11%	3-6 mo postop	Progressed within 6 mo postop; Self-limited	Not reported; Mean ABL distance: 2.57 mm (range 2.0-3.0 mm)
Heo <i>et al</i> <sup>[25]</sup>	Baguera-C: 60.42%	6 mo postop	Progressed within 12 mo postop; Self-limited	Grade 1, Minor, disappearance of the anterior osteophyte or small minor bone loss: 31.25%; Grade 2, Minor, bone loss of the anterior portion of the vertebral bodies at the operated segment without exposure of the implant: 12.5%; Grade 3, Major, significant bone loss with exposure of the anterior portion of the implant: 16.67%
Kieser <i>et al</i> <sup>[26]</sup>	Total: 63.73%; Cranial: 62.11%; Caudal: 48.7%; Bryan: 57.14%; Discocerv: 47.73%; Baguera-C: 64.29%; Mobi-C: 91.89%	Not reported	Self-limited within 12 mo postop	Mild, ABL ≤ 5%: 48.7%; Moderate, 5% < ABL ≤ 10%: 11.92%; Severe, ABL > 10%: 3.11%
Kieser <i>et al</i> <sup>[27]</sup>	Total: 57.05%; Cranial: 54.9%; Caudal: 42.31%; Bryan: 57.14%; Discocerv: 47.73%; Baguera-C: 64.29%	Within 3 mo postop	Benign course; progressed within 12 mo postop then stopped; self-healing in several cases	Grade 1, Mild, ABL ≤ 5%: 45.51%; Grade 2, Moderate, 5% < ABL ≤ 10%: 8.33%; Grade 3, Severe, ABL > 10% without endplate collapse: 0.64%; Grade 4, Severe, ABL > 10% with endplate collapse: 2.56%

ABL: Anterior bone loss; postop: Postoperatively.

had ABL > 2 mm, and grade 4 HO was noted in this patient. It is noteworthy that the authors only observed HO in three patients in this study.

Hacker *et al*<sup>[23]</sup> reported one patient with ABL who suffered from recurrent neck and arm pain after surgery for 52 mo. The shell angle was kyphosis at the last follow-up, as well as the functional spine unit angle. This patient received revision surgery, in which the Bryan disc was removed and two-level anterior cervical fusion was performed.

Kim *et al*<sup>[24]</sup> described the outcomes of ABL in three patients. The average distance of ABL was 2.57 mm (range 2.0-3.0 mm). These three patients achieved satisfying clinical outcomes without any change in symptoms during follow-up, and their pre- and post-operative read only memory were in the average range of this study. Ossification of the anterior longitudinal ligament (ALL) at the inferior adjacent level was noted in one patient at the two-year follow-up.

Heo *et al*<sup>[25]</sup> addressed the clinical effects of ABL. In their research, patients in the major change group (implant exposure) suffered from obvious neck pain postoperatively. The visual analogue scores for neck pain at 6 mo and 12 mo after surgery were  $5.3 \pm 2.0$  and  $4.7 \pm 1.7$ , respectively, in the major change group; and  $1.8 \pm 1.1$  and  $1.8 \pm 0.9$ , respectively, in the minor change group. Statistical differences were found between the two groups. The motion function was preserved at the last follow-up in the patients with ABL.

Table 4 Effects, outcomes, and risk factors of anterior bone loss

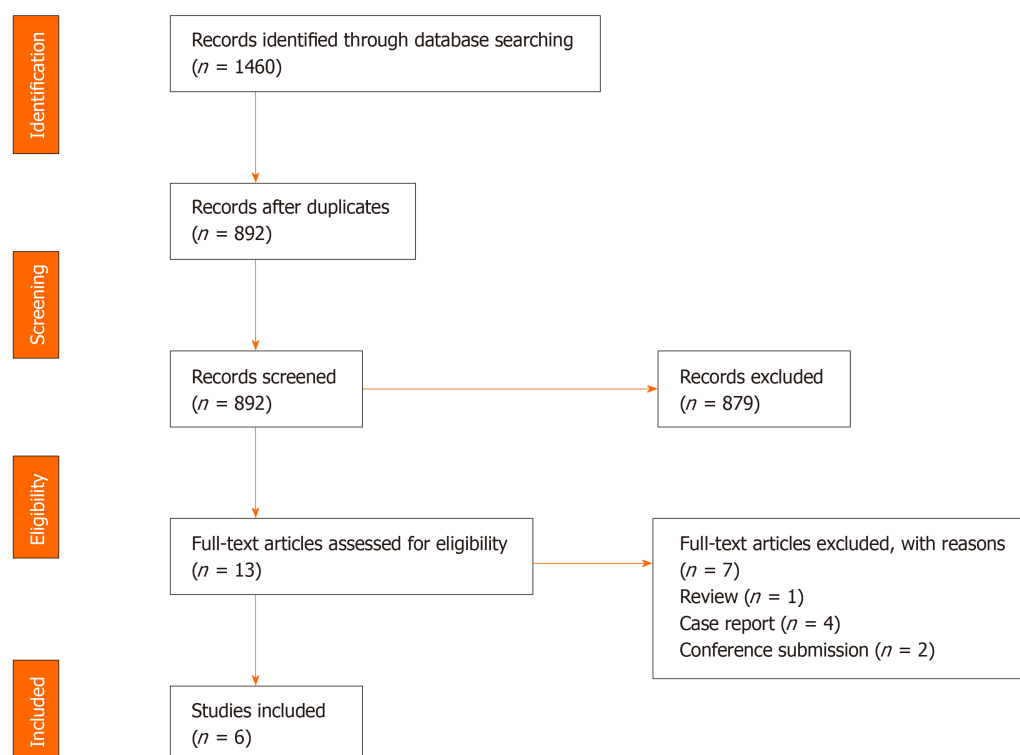
Ref.	Radiological effects	Clinical effects	Treatment	Potential risk factors
Ren <i>et al</i> <sup>[22]</sup>	Grade 4 HO in 1 patient with > 2 mm ABL distance, grade 2 HO in 1 patient; only 3 patients had HO in this study	No effect	Monitored	Micromovement of implant
Hacker <i>et al</i> <sup>[23]</sup>	Kyphosis of shell angle and FSU angle; Implant subsidence	Recurrent neck and arm pain persisting 52 mo postop	Revision fusion surgery at index and lower adjacent level	Low virulence bacterial infection of endplates at arthroplasty level
Kim <i>et al</i> <sup>[24]</sup>	Ossification of ALL at the inferior adjacent level in 1 patient	No effect	Monitored	Stress shielding; Friction and wear debris between the anterior flange and vertebra (less likely)
Heo <i>et al</i> <sup>[25]</sup>	No effect	Grade 3 ABL had significantly higher mean VAS score for neck pain at 6 mo (5.3 <i>vs</i> 1.8) and 12 mo (4.7 <i>vs</i> 1.8) postop	Monitored	Stress shielding; good motion function of implants
Kieser <i>et al</i> <sup>[26]</sup>	A significant relationship with HO	A lower NDI score 5 yr postop ( $P < 0.1$ )	Not reported	More operative levels; less of traction of ALL; surgical exposure
Kieser <i>et al</i> <sup>[27]</sup>	Exposure or subsidence of implant in severe ABL	No effect	Monitored	Grade 1-2: direct anterior vertebral injury including heat necrosis or resected ALL; Grade 3-4: avascular necrosis caused by injury to nutrient vessels

HO: Heterotopic ossification; FSU: Functional spine unit; ALL: Anterior longitudinal ligament; postop: Postoperatively; ABL: Anterior bone loss; VAS: Visual analogue score; NDI: Neck disability index.

Kieser *et al*<sup>[26,27]</sup> reported that ABL caused no statistical difference in visual analogue score for arm or neck pain at any time after surgery, although the neck disability index score showed a decreasing trend at the last follow-up in patients with ABL (18.9 in the non-ABL group, 11.2 in the mild group, 10.1 in the moderate group, and 9.0 in the severe group,  $P = 0.094$ ). Implant exposure or subsidence was observed in patients with severe ABL. Additionally, a significant relationship between Grade 4 HO and ABL was found in their research.

#### Potential risk factors and mechanism of ABL

Kieser *et al*<sup>[26,27]</sup> analyzed the potential risk factors for ABL. In their retrospective studies with a minimum follow-up of five years, they found that the number of levels operated was the only risk factor. Other variables including age, sex, cervical alignment, read only memory, and implant position were not related to ABL. They hypothesized that the extensive exposure and drilling of vertebra might cause a direct osteolytic insult, and the more the dissection and soft-tissue stripping during multilevel surgery, the greater the bone insult. In addition, Kieser found that the cranial endplate was exposed to a greater risk of ABL, which could be due to resection of the ALL. The ALL attaches tightly to the inferior portion of the ventral surface of the cervical vertebrae, and this region would be non-loaded and subsequently resorbed after resection of the ALL.



**Figure 1 Preferred reporting items for systematic reviews.** Preferred reporting items for systematic reviews flow diagram for selection of studies based on inclusion criteria during systematic review.

In 2019, Kieser *et al*<sup>[27]</sup> proposed the mechanism of ABL of different degrees. The direct heat necrosis of the vertebra and resection of the ALL may cause Grade 1-2 ABL. Injury to nutrient vessels of the vertebra and subsequent avascular necrosis may lead to grade 3-4 ABL.

Heo *et al*<sup>[25]</sup> considered that the stress shielding effects played an important role in ABL. They observed a complete cortical bone margin of the ABL area based on computed tomography scans, and did not find any radiolucent osteolytic lesion adjacent to the implants. This opinion was consistent with that of Kim *et al*<sup>[24]</sup>.

Kim *et al*<sup>[24]</sup> also speculated that the wear debris of artificial discs might induce the inflammatory response, and the inflammatory factors would recruit pre-osteoclasts and initiate the bone remodeling process.

Hacker *et al*<sup>[23]</sup> believed that low virulence bacterial infection of the endplate may account for the ABL in their case. They evaluated the tissue samples around the implant and did not find any pathological agent or culture except for macrophages.

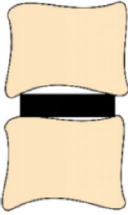
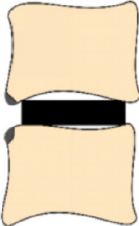
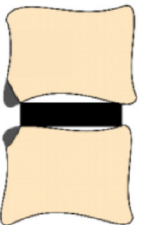
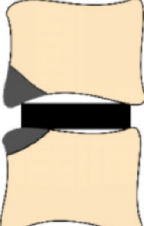

In contrast, Ren *et al*<sup>[22]</sup> thought that ABL did not look like a low-grade infection. They hypothesized that micromovement would cause mechanical damage to the adjacent vertebra and subsequent bone loss.

## DISCUSSION

Peri-implant bone loss has been widely reported in large joint arthroplasty<sup>[29-31]</sup>. However, studies on bone loss after CDR are lacking. By reviewing the literature, we classified the mechanism of ABL into three major hypotheses: stress shielding, micromovement, and injury to nutrient vessels.

The stress shielding effect has been documented as one of the factors of bone loss in hip and knee replacement<sup>[29]</sup>. In CDR, this term may be more accurately named as stress concentration. Physiologically, the axial loads transfer evenly and gently from one vertebra to the intervertebral disc, then to another vertebra. However, this mechanical system is altered after disc arthroplasty; the axial loads would transfer through the implant. Therefore, the stress would concentrate on where the implant is located. On the one hand, some artificial discs show obvious stress concentration in the anterior part of the endplates<sup>[32,33]</sup>. The hyper-pressure in the anterior region can



Radiograph	Heo <i>et al</i> <sup>[25]</sup>	Kieser <i>al</i> <sup>[26]</sup>	Kieser <i>al</i> <sup>[27]</sup>
	Grade 0	None	Grade 0
	Grade 1, disappearance of the anterior osteophyte or small minor bone loss	Mild, ABL ≤ 5%	Grade 1, ABL ≤ 5%
	Grade 2, bone loss of the anterior portion of the vertebral bodies at the operated segment without exposure of the implant	Moderate, 5% < ABL ≤ 10%	Grade 2, 5% < ABL ≤ 10%
	Grade 3, significant bone loss with exposure of the anterior portion of the implant	Severe, ABL > 10%	Grade 3, ABL > 10% without endplate collapse
	Significantly higher VAS score for neck pain at 6 mo (5.3 vs 1.8) and 12 mo (4.7 vs 1.8) postoperatively		Grade 4, Severe, ABL > 10% with endplate collapse

**Figure 2 Summarized grading systems of the included studies.** ABL: Anterior bone loss, colored in gray; VAS: Visual analogue score; NDI: Neck disability index.

activate the process of bone resorption<sup>[34]</sup>. On the other hand, the artificial disc does not cover the endplate sufficiently<sup>[35,36]</sup>. For the non-keel designed artificial disc, for instance, Discocerv and Baguera-C, the anterior part of the endplates cannot be covered, which may lead to hypo-pressure in this region. Based on Wolff's law, the anterior vertebral hypo-pressure from the artificial disc would initiate bone resorption. Consistent with this hypothesis, previous finite element studies showed that stress was distributed in the covered area of the endplates at the surgical level<sup>[37,38]</sup>. In addition, Wang *et al*<sup>[21]</sup> noted that patients with ABL showed a significantly more lordotic disc angle (which may shift the axial load posteriorly), compared with those who developed anterior HO. Accordingly, stress concentration may be one major reason for the development of ABL.

Micromovement of the implant into the vertebra may induce mechanical damage to the peri-implant bone and subsequent bone loss<sup>[22,23]</sup>. On the other hand, micromotion may cause artificial discs to produce friction and wear debris, which may induce an

inflammatory response and peri-implant bone loss<sup>[29,39,40]</sup>. Basic studies have proved that the wear debris can initiate bone loss *via* the RANK/RANKL/OPG pathway, and the inhibition of inflammation or RANK/RANKL pathway has protective effects on peri-implant osteolysis<sup>[41-43]</sup>. In addition, debris can also induce innervation and pain factor production<sup>[42]</sup>.

Although wear debris-induced osteolysis is widely accepted in large joint arthroplasty, this hypothesis is flawed with regard to two aspects in CDR. First, bone loss caused by wear debris is not confined to the anterior portion of the vertebra, but is around the surface of the implant. For instance, Devin *et al*<sup>[44]</sup> reported wear debris-induced bone loss after lumbar disc replacement. Massive osteolysis was noted in the central and posterior region of the vertebral body, and debris was scattered in the adjacent bones. Veruva *et al*<sup>[45]</sup> described the presence of osteolytic cysts distributed around artificial lumbar discs caused by the debris. These findings suggest that wear debris-induced bone loss is different to ABL in phenotype. Second, ABL was observed within 3 mo in most cases, and had a self-limited course. In contrast, debris-induced osteolysis may be evident on radiographs after a longer time and may be progressive, which was reported by Tumialán *et al*<sup>[46]</sup>. They described bone loss which was noted 9 mo after Prodisc-C implantation. The osteolytic process did not stop until the implant was removed. To sum up, wear debris is not a likely cause of ABL.

The third major hypothesis of ABL is the injury to nutrient vessels of the anterior vertebrae. The anatomic study by Dunbar *et al*<sup>[47]</sup> demonstrated the abundant nutrient blood supply in the anterior part of the cervical spine<sup>[48]</sup>. These vessels pass over the longus colli, and penetrate vertebrae mainly on the anterior surface of the cervical vertebrae. Usually, these nutrient vessels are coagulated to reduce intraoperative bleeding, and this may cause avascular necrosis of the anterior part of the endplate. The anterior nutrient foraminae are mainly located in the superior third of the vertebrae, leaving the inferior portion hypo-vascular. Therefore, theoretically, the inferior portion of vertebrae would be at a higher risk of avascular necrosis, and this is consistent with the clinical findings of Kieser *et al*<sup>[27]</sup>. Consequently, ABL may be related to avascular necrosis caused by injury to nutrient vessels.

Kieser *et al*<sup>[26]</sup> showed that the more levels operated, the higher the risk of developing ABL. A possible explanation for this might be that multilevel surgery would change the biomechanical properties of the cervical spine leading to hyper- or hypo-pressure in the anterior region of the vertebrae, as described earlier. Additionally, we believe the design of artificial discs is another risk factor in the development of ABL. The prevalence of ABL was different among artificial discs, and this could be attributed to the discrepancy in stress distribution of the endplates of different types of artificial discs.

Some authors consider that heat necrosis due to the burring and milling process could inactivate osteocytes of the anterior vertebra, and result in a direct osteolytic insult. However, the findings of Heo *et al*<sup>[25]</sup> and Kieser *et al*<sup>[26,27]</sup> do not support this assumption. Even though the anterior cortex of the vertebra was carefully preserved during surgery, ABL still occurred. In addition, Wang *et al*<sup>[21]</sup> found that the anterior milling ratio and milling angle were comparable between patients with ABL or anterior bone formation. Therefore, heat necrosis may not be the most important risk factor for ABL.

Usually, patients with ABL do not have clear clinical and radiological effects, while severe ABL may produce segmental kyphosis and local pain<sup>[23-25]</sup>. Due to the self-limited process, most cases do not require intervention. However, we hold the view that early interventions including rehabilitation exercise and pain relief are necessary for these patients. In our center, we have seen patients with ABL complain of persistent neck pain for one year after surgery. Early interventions can improve the satisfaction of surgery and quality of life. In addition, the impacts of ABL on the adjacent segments remain unknown. Further studies with long-term follow-up are needed to clarify the relationship between ABL and adjacent segment degeneration.

Currently, ABL is observed on lateral radiographs. Notwithstanding this method is simple and easy, but it may increase the false positive rate of ABL. Occasionally, the inappropriate irradiation direction of X-rays may give us a false impression that ABL has occurred. For this reason, computed tomography scans are better in evaluating the prevalence of ABL<sup>[25]</sup>. Moreover, to prevent and identify ABL early, further studies on the mechanism and risk factors of ABL after CDR are needed.

There are several limitations in our study. The major limitation is the small sample size of each included study. Studies with large sample size are needed to determine the precise prevalence of ABL. As diverse evaluation systems for ABL were used in the included studies, it is difficult to make accurate assessments on the impacts of ABL. In addition, most studies only used non-keeled artificial discs; thus, ABL in keeled

artificial discs, such as Prodisc-C and Prestige-LP, is unknown. Finally, we focused on prospective and retrospective studies, and may have missed a wider discussion on the underlying mechanism of ABL in some case reports or case series. Further studies are required to elucidate these limitations.

## CONCLUSION

ABL is common in CDR. ABL occurs within 3-6 mo, and stops 12 mo after surgery. Several cases were noted to have a self-healing process. ABL does not have obvious clinical or radiological effects in most patients, while severe ABL may result in segmental kyphosis and persistent pain. ABL may be related to HO; however further studies are required to confirm this. Multilevel surgery is recognized as a potential risk factor for ABL, and the underlying mechanisms include stress concentration and injury to nutrient vessels. ABL should be considered a complication after CDR as it was associated with neck pain, implant subsidence, and HO.

## ARTICLE HIGHLIGHTS

### **Research background**

Anterior bone loss (ABL) after cervical disc replacement (CDR) has attracted considerable concern in recent years. Whether ABL is a radiological anomaly or a complication remains unknown.

### **Research motivation**

Several studies have reported the prevalence, impacts, and outcomes of ABL. However, an overall understanding of ABL is lacking.

### **Research objectives**

This study aimed to comprehensively evaluate ABL after CDR.

### **Research methods**

A systematic review was performed according to the preferred reporting items for systematic reviews guideline.

### **Research results**

The prevalence of ABL ranges from 3.13% to 91.89%, and multilevel surgery may be one of the risk factors for ABL. ABL occurred within 6 mo postoperatively and stopped after 1 year. Severe cases may result in kyphosis, implant subsidence, and neck pain.

### **Research conclusions**

ABL is a common condition after CDR. ABL should be considered a complication after CDR due to its clinical impacts.

### **Research perspectives**

Further studies should clarify the relationship between ABL and adjacent segment degeneration. Further studies on the mechanism and risk factors for ABL are needed. The method used to measure ABL should be improved.

## ACKNOWLEDGEMENTS

We wish to thank Dr. Ying-Jun Guo and Dr. Jun-Bo He for advice on the discussion.

## REFERENCES

- 1 Liu Y, Qi M, Chen H, Yang L, Wang X, Shi G, Gao R, Wang C, Yuan W. Comparative analysis of complications of different reconstructive techniques following anterior decompression for multilevel cervical spondylotic myelopathy. *Eur Spine J* 2012; **21**: 2428-2435 [PMID: 22644433 DOI: 10.1007/s00586-012-2428-2]

- 10.1007/s00586-012-2323-y]
- 2 **Lee DH**, Cho JH, Hwang CJ, Lee CS, Cho SK, Kim C, Ha JK. What Is the Fate of Pseudarthrosis Detected 1 Year After Anterior Cervical Discectomy and Fusion? *Spine (Phila Pa 1976)* 2018; **43**: E23-E28 [PMID: 28146025 DOI: 10.1097/BRS.0000000000002077]
- 3 **Buttermann GR**. Anterior Cervical Discectomy and Fusion Outcomes over 10 Years: A Prospective Study. *Spine (Phila Pa 1976)* 2018; **43**: 207-214 [PMID: 28604488 DOI: 10.1097/BRS.0000000000002273]
- 4 **Dong L**, Xu Z, Chen X, Wang D, Li D, Liu T, Hao D. The change of adjacent segment after cervical disc arthroplasty compared with anterior cervical discectomy and fusion: a meta-analysis of randomized controlled trials. *Spine J* 2017; **17**: 1549-1558 [PMID: 28625479 DOI: 10.1016/j.spinee.2017.06.010]
- 5 **Jaumard NV**, Bauman JA, Guarino BB, Gokhale AJ, Lipschutz DE, Weisshaar CL, Welch WC, Winkelstein BA. ProDisc cervical arthroplasty does not alter facet joint contact pressure during lateral bending or axial torsion. *Spine (Phila Pa 1976)* 2013; **38**: E84-E93 [PMID: 23132537 DOI: 10.1097/BRS.0b013e31827b8a2d]
- 6 **Galbusera F**, Bellini CM, Brayda-Bruno M, Fornari M. Biomechanical studies on cervical total disc arthroplasty: a literature review. *Clin Biomech (Bristol, Avon)* 2008; **23**: 1095-1104 [PMID: 18635294 DOI: 10.1016/j.clinbiomech.2008.06.002]
- 7 **Kelly MP**, Eliasberg CD, Riley MS, Ajiboye RM, SooHoo NF. Reoperation and complications after anterior cervical discectomy and fusion and cervical disc arthroplasty: a study of 52,395 cases. *Eur Spine J* 2018; **27**: 1432-1439 [PMID: 29605899 DOI: 10.1007/s00586-018-5570-8]
- 8 **Gutman G**, Rosenzweig DH, Golan JD. Surgical Treatment of Cervical Radiculopathy: Meta-analysis of Randomized Controlled Trials. *Spine (Phila Pa 1976)* 2018; **43**: E365-E372 [PMID: 28700452 DOI: 10.1097/BRS.0000000000002324]
- 9 **Kim JS**, Dowdell J, Cheung ZB, Arvind V, Sun L, Jandhyala C, Ukogu C, Ranson W, Jacobs S, McAnany S, Cho SK. The Seven-Year Cost-Effectiveness of Anterior Cervical Discectomy and Fusion Versus Cervical Disc Arthroplasty: A Markov Analysis. *Spine (Phila Pa 1976)* 2018; **43**: 1543-1551 [PMID: 29642136 DOI: 10.1097/BRS.0000000000002665]
- 10 **Qureshi S**, Goz V, McAnany S, Cho SK, Hecht AC, Delamarter RB, Fehlings MG. Health state utility of patients with single-level cervical degenerative disc disease: comparison of anterior cervical discectomy and fusion with cervical disc arthroplasty. *J Neurosurg Spine* 2014; **20**: 475-479 [PMID: 24559462 DOI: 10.3171/2014.1.SPINE13718]
- 11 **Yang SD**, Zhu YB, Yan SZ, Di J, Yang DL, Ding WY. Anterior cervical discectomy and fusion surgery versus total disc replacement: A comparative study with minimum of 10-year follow-up. *Sci Rep* 2017; **7**: 16443 [PMID: 29180636 DOI: 10.1038/s41598-017-16670-1]
- 12 **Mehren C**, Heider F, Siepe CJ, Zillner B, Kothe R, Korge A, Mayer HM. Clinical and radiological outcome at 10 years of follow-up after total cervical disc replacement. *Eur Spine J* 2017; **26**: 2441-2449 [PMID: 28676980 DOI: 10.1007/s00586-017-5204-6]
- 13 **Gornet MF**, Burkus JK, Shaffrey ME, Schranck FW, Copay AG. Cervical disc arthroplasty: 10-year outcomes of the Prestige LP cervical disc at a single level. *J Neurosurg Spine* 2019; **31**: 317-325 [PMID: 31075769 DOI: 10.3171/2019.2.SPINE1956]
- 14 **Lavelle WF**, Riew KD, Levi AD, Florman JE. Ten-year Outcomes of Cervical Disc Replacement With the BRYAN Cervical Disc: Results From a Prospective, Randomized, Controlled Clinical Trial. *Spine (Phila Pa 1976)* 2019; **44**: 601-608 [PMID: 30325888 DOI: 10.1097/BRS.0000000000002907]
- 15 **Gornet MF**, Lanman TH, Burkus JK, Dryer RF, McConnell JR, Hodges SD, Schranck FW. Two-level cervical disc arthroplasty versus anterior cervical discectomy and fusion: 10-year outcomes of a prospective, randomized investigational device exemption clinical trial. *J Neurosurg Spine* 2019; 1-11 [PMID: 31226684 DOI: 10.3171/2019.4.SPINE19157]
- 16 **Ozbek Z**, Ozkara E, Arslantaş A. Implant Migration in Cervical Disk Arthroplasty. *World Neurosurg* 2017; **97**: 390-397 [PMID: 27756667 DOI: 10.1016/j.wneu.2016.10.023]
- 17 **Zhou F**, Ju KL, Zhao Y, Zhang F, Pan S, Heller JG, Sun Y. Progressive Bone Formation After Cervical Disc Replacement: Minimum of 5-Year Follow-up. *Spine (Phila Pa 1976)* 2018; **43**: E163-E170 [PMID: 28591077 DOI: 10.1097/BRS.0000000000002264]
- 18 **Nunley PD**, Cavanaugh DA, Kerr EJ 3rd, Utter PA, Campbell PG, Frank KA, Marshall KE, Stone MB. Heterotopic Ossification After Cervical Total Disc Replacement at 7 Years-Prevalence, Progression, Clinical Implications, and Risk Factors. *Int J Spine Surg* 2018; **12**: 352-361 [PMID: 30276092 DOI: 10.14444/5041]
- 19 **Li G**, Wang Q, Liu H, Yang Y. Postoperative Heterotopic Ossification After Cervical Disc Replacement Is Likely a Reflection of the Degeneration Process. *World Neurosurg* 2019; **125**: e1063-e1068 [PMID: 30780040 DOI: 10.1016/j.wneu.2019.01.244]
- 20 **Zeng J**, Liu H, Chen H, Rong X, Meng Y, Yang Y, Deng Y, Ding C. Effect of Prosthesis Width and Depth on Heterotopic Ossification After Cervical Disc Arthroplasty. *Spine (Phila Pa 1976)* 2019; **44**: 624-628 [PMID: 30395084 DOI: 10.1097/BRS.0000000000002915]
- 21 **Wang X**, Meng Y, Liu H, Hong Y, Wang B. Is Anterior Bone Loss the Opposite of Anterior Heterotopic Ossification in Prestige-LP Cervical Disc Replacement? *World Neurosurg* 2020; **136**: e407-e418 [PMID: 31931240 DOI: 10.1016/j.wneu.2020.01.022]
- 22 **Ren X**, Wang W, Chu T, Wang J, Li C, Jiang T. The intermediate clinical outcome and its limitations of Bryan cervical arthroplasty for treatment of cervical disc herniation. *J Spinal Disord Tech* 2011; **24**: 221-229 [PMID: 20634725 DOI: 10.1097/BSD.0b013e3181e9f309]
- 23 **Hacker FM**, Babcock RM, Hacker RJ. Very late complications of cervical arthroplasty: results of 2 controlled randomized prospective studies from a single investigator site. *Spine (Phila Pa 1976)* 2013; **38**: 2223-2226 [PMID: 24335628 DOI: 10.1097/BRS.0000000000000060]
- 24 **Kim SH**, Chung YS, Ropper AE, Min KH, Ahn TK, Won KS, Shin DA, Han IB. Bone loss of the superior adjacent vertebral body immediately posterior to the anterior flange of Bryan cervical disc. *Eur Spine J* 2015; **24**: 2872-2879 [PMID: 25787945 DOI: 10.1007/s00586-015-3849-6]
- 25 **Heo DH**, Lee DC, Oh JY, Park CK. Bone loss of vertebral bodies at the operative segment after cervical

- arthroplasty: a potential complication? *Neurosurg Focus* 2017; **42**: E7 [PMID: 28142258 DOI: 10.3171/2016.10.FOCUS16393]
- 26 **Kieser DC**, Cawley DT, Fujishiro T, Mazas S, Boissière L, Obeid I, Pointillart V, Vital JM, Gille O. Risk factors for anterior bone loss in cervical disc arthroplasty. *J Neurosurg Spine* 2018; **29**: 123-129 [PMID: 29799314 DOI: 10.3171/2018.1.SPINE171018]
  - 27 **Kieser DC**, Cawley DT, Fujishiro T, Tavolaro C, Mazas S, Boissiere L, Obeid I, Pointillart V, Vital JM, Gille O. Anterior Bone Loss in Cervical Disc Arthroplasty. *Asian Spine J* 2019; **13**: 13-21 [PMID: 30326692 DOI: 10.3161/asj.2018.0008]
  - 28 **CEBM**. 'The Oxford Levels of Evidence 2'. *Oxford Cent Evidence-Based Med [Internet]* 2016 Available from: <http://www.cebm.net/index.aspx?o=5653>
  - 29 **Gallo J**, Goodman SB, Kontinen YT, Wimmer MA, Holinka M. Osteolysis around total knee arthroplasty: a review of pathogenetic mechanisms. *Acta Biomater* 2013; **9**: 8046-8058 [PMID: 23669623 DOI: 10.1016/j.actbio.2013.05.005]
  - 30 **Huiskes R**, Weinans H, van Rietbergen B. The relationship between stress shielding and bone resorption around total hip stems and the effects of flexible materials. *Clin Orthop Relat Res* 1992; 124-134 [PMID: 1728998]
  - 31 **Dalat F**, Barnoud R, Fessy MH, Besse JL, French Association of Foot Surgery AFCP. Histologic study of periprosthetic osteolytic lesions after AES total ankle replacement. A 22 case series. *Orthop Traumatol Surg Res* 2013; **99**: S285-S295 [PMID: 23978711 DOI: 10.1016/j.otsr.2013.07.009]
  - 32 **Mo Z**, Zhao Y, Du C, Sun Y, Zhang M, Fan Y. Does location of rotation center in artificial disc affect cervical biomechanics? *Spine (Phila Pa 1976)* 2015; **40**: E469-E475 [PMID: 25868102 DOI: 10.1097/BRS.0000000000000818]
  - 33 **Mo Z**, Li Q, Jia Z, Yang J, Wong DW, Fan Y. Biomechanical consideration of prosthesis selection in hybrid surgery for bi-level cervical disc degenerative diseases. *Eur Spine J* 2017; **26**: 1181-1190 [PMID: 27652678 DOI: 10.1007/s00586-016-4777-9]
  - 34 **Frost HM**. From Wolff's law to the Utah paradigm: insights about bone physiology and its clinical applications. *Anat Rec* 2001; **262**: 398-419 [PMID: 11275971 DOI: 10.1002/ar.1049]
  - 35 **Dong L**, Tan MS, Yan QH, Yi P, Yang F, Tang XS, Hao QY. Footprint mismatch of cervical disc prostheses with Chinese cervical anatomic dimensions. *Chin Med J (Engl)* 2015; **128**: 197-202 [PMID: 25591562 DOI: 10.4103/0366-6999.149200]
  - 36 **Thaler M**, Hartmann S, Gstöttner M, Lechner R, Gabl M, Bach C. Footprint mismatch in total cervical disc arthroplasty. *Eur Spine J* 2013; **22**: 759-765 [PMID: 23184184 DOI: 10.1007/s00586-012-2594-3]
  - 37 **Lin CY**, Kang H, Rouleau JP, Hollister SJ, Marca FL. Stress analysis of the interface between cervical vertebrae end plates and the Bryan, Prestige LP, and ProDisc-C cervical disc prostheses: an in vivo image-based finite element study. *Spine (Phila Pa 1976)* 2009; **34**: 1554-1560 [PMID: 19564765 DOI: 10.1097/BRS.0b013e3181aa643b]
  - 38 **Yu CC**, Liu P, Huang DG, Jiang YH, Feng H, Hao DJ. A new cervical artificial disc prosthesis based on physiological curvature of end plate: a finite element analysis. *Spine J* 2016; **16**: 1384-1391 [PMID: 27345748 DOI: 10.1016/j.spinee.2016.06.019]
  - 39 **Hallab NJ**, Cunningham BW, Jacobs JJ. Spinal implant debris-induced osteolysis. *Spine (Phila Pa 1976)* 2003; **28**: S125-S138 [PMID: 14560184]
  - 40 **Veruva SY**, Lanman TH, Isaza JE, Freeman TA, Kurtz SM, Steinbeck MJ. Periprosthetic UHMWPE Wear Debris Induces Inflammation, Vascularization, and Innervation After Total Disc Replacement in the Lumbar Spine. *Clin Orthop Relat Res* 2017; **475**: 1369-1381 [PMID: 27488379 DOI: 10.1007/s11999-016-4996-8]
  - 41 **Hartmann ES**, Köhler MI, Huber F, Redeker JI, Schmitt B, Schmitt-Sody M, Summer B, Fottner A, Jansson V, Mayer-Wagner S. Factors regulating bone remodeling processes in aseptic implant loosening. *J Orthop Res* 2017; **35**: 248-257 [PMID: 27116254 DOI: 10.1002/jor.23274]
  - 42 **Punt IM**, Cleutjens JP, de Bruin T, Willems PC, Kurtz SM, van Rhijn LW, Schurink GW, van Ooij A. Periprosthetic tissue reactions observed at revision of total intervertebral disc arthroplasty. *Biomaterials* 2009; **30**: 2079-2084 [PMID: 19155064 DOI: 10.1016/j.biomaterials.2008.12.071]
  - 43 **Córdova LA**, Trichet V, Escriviou V, Rosset P, Amiaud J, Battaglia S, Charrier C, Berreur M, Brion R, Gouin F, Layrolle P, Passuti N, Heymann D. Inhibition of osteolysis and increase of bone formation after local administration of siRNA-targeting RANK in a polyethylene particle-induced osteolysis model. *Acta Biomater* 2015; **13**: 150-158 [PMID: 25462844 DOI: 10.1016/j.actbio.2014.10.042]
  - 44 **Devin CJ**, Myers TG, Kang JD. Chronic failure of a lumbar total disc replacement with osteolysis. Report of a case with nineteen-year follow-up. *J Bone Joint Surg Am* 2008; **90**: 2230-2234 [PMID: 18829921 DOI: 10.2106/JBJS.G.01712]
  - 45 **Veruva SY**, Lanman TH, Hanzlik JA, Kurtz SM, Steinbeck MJ. Rare complications of osteolysis and periprosthetic tissue reactions after hybrid and non-hybrid total disc replacement. *Eur Spine J* 2015; **24** Suppl 4: S494-S501 [PMID: 25163549 DOI: 10.1007/s00586-014-3535-0]
  - 46 **Tumialán LM**, Gluf WM. Progressive vertebral body osteolysis after cervical disc arthroplasty. *Spine (Phila Pa 1976)* 2011; **36**: E973-E978 [PMID: 21289567 DOI: 10.1097/BRS.0b013e3181fd863b]
  - 47 **Dunbar L**, Vidakovic H, Löffler S, Hammer N, Gille O, Boissiere L, Obeid I, Pointillart V, Vital JM, Kieser DC. Anterior cervical spine blood supply: a cadaveric study. *Surg Radiol Anat* 2019; **41**: 607-611 [PMID: 30937565 DOI: 10.1007/s00276-019-02236-5]
  - 48 **Harris RS**, Jones DM. The arterial supply to the adult cervical vertebral bodies. *J Bone Joint Surg Br* 1956; **38-B**: 922-927 [PMID: 13376680 DOI: 10.1302/0301-620x.38b4.922]





Published by **Baishideng Publishing Group Inc**  
7041 Koll Center Parkway, Suite 160, Pleasanton, CA 94566, USA

**Telephone:** +1-925-3991568

**E-mail:** [bpgoffice@wjgnet.com](mailto:bpgoffice@wjgnet.com)

**Help Desk:** <https://www.f6publishing.com/helpdesk>

<https://www.wjgnet.com>

