

World Journal of *Clinical Cases*

World J Clin Cases 2020 November 26; 8(22): 5496-5834



Contents

Semimonthly Volume 8 Number 22 November 26, 2020

EDITORIAL

- 5496 Is Dynesys dynamic stabilization system superior to posterior lumbar fusion in the treatment of lumbar degenerative diseases?

Peng BG, Gao CH

MINIREVIEWS

- 5501 COVID-19: A review of what radiologists need to know
- Tang L, Wang Y, Zhang Y, Zhang XY, Zeng XC, Song B
- 5513 Holistic care model of time-sharing management for severe and critical COVID-19 patients

Yang B, Gao Y, Kang K, Li J, Wang L, Wang H, Bi Y, Dai QQ, Zhao MY, Yu KJ

ORIGINAL ARTICLE

Case Control Study

- 5518 Bioequivalence of two esomeprazole magnesium enteric-coated formulations in healthy Chinese subjects
- Liu ZZ, Ren Q, Zhou YN, Yang HM
- 5529 Osteoprotegerin, interleukin and hepatocyte growth factor for prediction of diabetes and hypertension in the third trimester of pregnancy
- Huang SJ, Wang HW, Wu HF, Wei QY, Luo S, Xu L, Guan HQ

Retrospective Study

- 5535 High serum lactate dehydrogenase and dyspnea: Positive predictors of adverse outcome in critical COVID-19 patients in Yichang
- Lv XT, Zhu YP, Cheng AG, Jin YX, Ding HB, Wang CY, Zhang SY, Chen GP, Chen QQ, Liu QC
- 5547 Risk factors analysis of prognosis of adult acute severe myocarditis
- Zhang Q, Zhao R
- 5555 Sonographic features of umbilical vein recanalization for a Rex shunt on cavernous transformation of portal vein in children
- Zhang YQ, Wang Q, Wu M, Li Y, Wei XL, Zhang FX, Li Y, Shao GR, Xiao J

Clinical Trials Study

- 5564 Gemcitabine plus concurrent irreversible electroporation vs gemcitabine alone for locally advanced pancreatic cancer
- Ma YY, Leng Y, Xing YL, Li HM, Chen JB, Niu LZ

Observational Study

- 5576** No significant association between dipeptidyl peptidase-4 inhibitors and adverse outcomes of COVID-19
Zhou JH, Wu B, Wang WX, Lei F, Cheng X, Qin JJ, Cai JJ, Zhang X, Zhou F, Liu YM, Li HM, Zhu LH, She Z, Zhang X, Yang J, Li HL

META-ANALYSIS

- 5589** Interobserver agreement for contrast-enhanced ultrasound of liver imaging reporting and data system: A systematic review and meta-analysis
Li J, Chen M, Wang ZJ, Li SG, Jiang M, Shi L, Cao CL, Sang T, Cui XW, Dietrich CF

CASE REPORT

- 5603** CLAG-M chemotherapy followed by umbilical cord blood stem cell transplantation for primary refractory acute myeloid leukaemia in a child: A case report
Huang J, Yang XY, Rong LC, Xue Y, Zhu J, Fang YJ
- 5611** Multiple schwannomas with pseudoglandular element synchronously occurring under the tongue: A case report
Chen YL, He DQ, Yang HX, Dou Y
- 5618** Primary myelofibrosis with concurrent *CALR* and *MPL* mutations: A case report
Zhou FP, Wang CC, Du HP, Cao SB, Zhang J
- 5625** Endometrial stromal sarcoma extending to the pulmonary artery: A rare case report
Fan JK, Tang GC, Yang H
- 5632** Malignant acanthosis nigricans with Leser-Trélat sign and tripe palms: A case report
Wang N, Yu PJ, Liu ZL, Zhu SM, Zhang CW
- 5639** Gastric plexiform fibromyxoma: A case report
Pei JY, Tan B, Liu P, Cao GH, Wang ZS, Qu LL
- 5645** Rectoseminal vesicle fistula after radical surgery for rectal cancer: Four case reports and a literature review
Xia ZX, Cong JC, Zhang H
- 5657** Azacitidine decreases reactive oxygen species production in peripheral white blood cells: A case report
Hasunuma H, Shimizu N, Yokota H, Tatsuno I
- 5663** Oral granuloma in a pediatric patient with chronic graft-versus-host disease: A case report
Uesugi A, Tsushima F, Kodama M, Kuroshima T, Sakurai J, Harada H
- 5670** Intrahepatic biliary cystadenoma: A case report
Xu RM, Li XR, Liu LH, Zheng WQ, Zhou H, Wang XC
- 5678** Gene diagnosis of infantile neurofibromatosis type I: A case report
Li MZ, Yuan L, Zhuo ZQ

- 5684** Localized amyloidosis affecting the lacrimal sac managed by endoscopic surgery: A case report
Song X, Yang J, Lai Y, Zhou J, Wang J, Sun X, Wang D
- 5690** Endoscopic resection of benign esophageal schwannoma: Three case reports and review of literature
Li B, Wang X, Zou WL, Yu SX, Chen Y, Xu HW
- 5701** Bouveret syndrome masquerading as a gastric mass-unmasked with endoscopic luminal laser lithotripsy: A case report
Parvataneni S, Khara HS, Diehl DL
- 5707** Nonhypertensive male with multiple paragangliomas of the heart and neck: A case report
Wang Q, Huang ZY, Ge JB, Shu XH
- 5715** Completed atrioventricular block induced by atrial septal defect occluder unfolding: A case report
He C, Zhou Y, Tang SS, Luo LH, Feng K
- 5722** Clinical characteristics of adult-type annular pancreas: A case report
Yi D, Ding XB, Dong SS, Shao C, Zhao LJ
- 5729** Port-site metastasis of unsuspected gallbladder carcinoma with ossification after laparoscopic cholecystectomy: A case report
Gao KJ, Yan ZL, Yu Y, Guo LQ, Hang C, Yang JB, Zhang MC
- 5737** Gonadal dysgenesis in Turner syndrome with Y-chromosome mosaicism: Two case reports
Leng XF, Lei K, Li Y, Tian F, Yao Q, Zheng QM, Chen ZH
- 5744** Gastric mixed adenoma-neuroendocrine tumor: A case report
Kohno S, Aoki H, Kato M, Ogawa M, Yoshida K
- 5751** Sebaceous lymphadenocarcinoma of the parotid gland: A case report
Hao FY, Wang YL, Li SM, Xue LF
- 5758** Misdiagnosis of ligamentoid fibromatosis of the small mesenteric: A case report
Xu K, Zhao Q, Liu J, Zhou D, Chen YL, Zhu X, Su M, Huang K, Du W, Zhao H
- 5765** Intraoperative care of elderly patients with COVID-19 undergoing double lung transplantation: Two case reports
Wu Q, Wang Y, Chen HQ, Pan H
- 5773** Amelioration of cognitive impairment following growth hormone replacement therapy: A case report and review of literature
Liu JT, Su PH
- 5781** Early colon cancer with enteropathy-associated T-cell lymphoma involving the whole gastrointestinal tract: A case report
Zhang MY, Min CC, Fu WW, Liu H, Yin XY, Zhang CP, Tian ZB, Li XY

- 5790** Bleeding of two lumbar arteries caused by one puncture following percutaneous nephrolithotomy: A case report
Liu Q, Yang C, Lin K, Yang D
- 5795** Hemorrhagic fever with renal syndrome complicated with aortic dissection: A case report
Qiu FQ, Li CC, Zhou JY
- 5802** Robot-assisted laparoscopic pyeloureterostomy for ureteropelvic junction rupture sustained in a traffic accident: A case report
Kim SH, Kim WB, Kim JH, Lee SW
- 5809** Large leiomyoma of lower esophagus diagnosed by endoscopic ultrasonography-fine needle aspiration: A case report
Rao M, Meng QQ, Gao PJ
- 5816** Endoscopic reduction of colocolonic intussusception due to metastatic malignant melanoma: A case report
Kasuga K, Sakamoto T, Takamaru H, Sekiguchi M, Yamada M, Yamazaki N, Hashimoto T, Uraoka T, Saito Y
- 5821** Usefulness of ultrasonography to assess the response to steroidal therapy for the rare case of type 2b immunoglobulin G4-related sclerosing cholangitis without pancreatitis: A case report
Tanaka Y, Kamimura K, Nakamura R, Ohkoshi-Yamada M, Koseki Y, Mizusawa T, Ikarashi S, Hayashi K, Sato H, Sakamaki A, Yokoyama J, Terai S

LETTER TO THE EDITOR

- 5831** Is positivity for hepatitis C virus antibody predictive of lower risk of death in COVID-19 patients with cirrhosis?
Mangia A, Cenderello G, Verucchi G, Ciancio A, Fontana A, Piazzolla V, Minerva N, Squillante MM, Copetti M

ABOUT COVER

Peer-reviewer of *World Journal of Clinical Cases*, Dr. Galiatsatos Aristidis is an Associate Professor, Department of Biomedical Sciences, Division of Dental Technology, University of West Attica. After graduating from the Faculty of Dentistry of University of Thessaloniki in 1988, he completed his PhD in the Dental Prosthodontics Department of Athens University in 1996. From 1988 to 2005, he continued his professional training in the University of Athens as a Research Fellow in Prosthodontics. During the 1998-1999 academic year, he was hired as a paid research scientist in the same subject area. In 2009, he rose to Assistant and then Associate Professor in the University of West Attica. From September 2019, he has served as Director of the Division of Dental Technology. (L-Editor: Filipodia)

AIMS AND SCOPE

The primary aim of *World Journal of Clinical Cases* (*WJCC*, *World J Clin Cases*) is to provide scholars and readers from various fields of clinical medicine with a platform to publish high-quality clinical research articles and communicate their research findings online.

WJCC mainly publishes articles reporting research results and findings obtained in the field of clinical medicine and covering a wide range of topics, including case control studies, retrospective cohort studies, retrospective studies, clinical trials studies, observational studies, prospective studies, randomized controlled trials, randomized clinical trials, systematic reviews, meta-analysis, and case reports.

INDEXING/ABSTRACTING

The *WJCC* is now indexed in Science Citation Index Expanded (also known as SciSearch®), Journal Citation Reports/Science Edition, PubMed, and PubMed Central. The 2020 Edition of Journal Citation Reports® cites the 2019 impact factor (IF) for *WJCC* as 1.013; IF without journal self cites: 0.991; Ranking: 120 among 165 journals in medicine, general and internal; and Quartile category: Q3.

RESPONSIBLE EDITORS FOR THIS ISSUE

Production Editor: Ji-Hong Liu; Production Department Director: Xiang Li; Editorial Office Director: Jin-Lai Wang.

NAME OF JOURNAL

World Journal of Clinical Cases

ISSN

ISSN 2307-8960 (online)

LAUNCH DATE

April 16, 2013

FREQUENCY

Semimonthly

EDITORS-IN-CHIEF

Dennis A Bloomfield, Sandro Vento, Bao-Gan Peng

EDITORIAL BOARD MEMBERS

<https://www.wjgnet.com/2307-8960/editorialboard.htm>

PUBLICATION DATE

November 26, 2020

COPYRIGHT

© 2020 Baishideng Publishing Group Inc

INSTRUCTIONS TO AUTHORS

<https://www.wjgnet.com/bpg/gerinfo/204>

GUIDELINES FOR ETHICS DOCUMENTS

<https://www.wjgnet.com/bpg/GerInfo/287>

GUIDELINES FOR NON-NATIVE SPEAKERS OF ENGLISH

<https://www.wjgnet.com/bpg/gerinfo/240>

PUBLICATION ETHICS

<https://www.wjgnet.com/bpg/GerInfo/288>

PUBLICATION MISCONDUCT

<https://www.wjgnet.com/bpg/gerinfo/208>

ARTICLE PROCESSING CHARGE

<https://www.wjgnet.com/bpg/gerinfo/242>

STEPS FOR SUBMITTING MANUSCRIPTS

<https://www.wjgnet.com/bpg/GerInfo/239>

ONLINE SUBMISSION

<https://www.f6publishing.com>



Gastric plexiform fibromyxoma: A case report

Jin-Yu Pei, Bin Tan, Peng Liu, Guang-Hua Cao, Zu-Sen Wang, Lin-Lin Qu

ORCID number: Jin-Yu Pei 0000-0002-9101-5923; Bin Tan 0000-0002-1249-3637; Peng Liu 0000-0002-2522-2203; Guang-Hua Cao 0000-0003-3038-6613; Zu-Sen Wang 0000-0002-6250-6264; Lin-Lin Qu 0000-0002-8600-4074.

Author contributions: Pei JY contributed to the acquisition, analysis, and interpretation of patient data and drafting of the manuscript; Tan B, Liu P and Cao GH contributed to the acquisition of patient data and finalizing the manuscript; Qu LL and Wang ZS gave final approval of the article; all authors have read and approved the final manuscript.

Informed consent statement: Informed consent was obtained from the patient.

Conflict-of-interest statement: The authors declare that they have no conflicts of interest.

CARE Checklist (2016) statement: The authors have read the CARE Checklist (2016), and the manuscript was prepared and revised according to the CARE Checklist (2016).

Open-Access: This article is an open-access article that was selected by an in-house editor and fully peer-reviewed by external reviewers. It is distributed in accordance with the Creative Commons Attribution

Jin-Yu Pei, Bin Tan, Peng Liu, Guang-Hua Cao, Zu-Sen Wang, Lin-Lin Qu, Department of Hepatopancreatobiliary Surgery, The Affiliated Hospital of Qingdao University, Qingdao 266555, Shandong Province, China

Jin-Yu Pei, Peng Liu, Guang-Hua Cao, Medical College, Qingdao University, Qingdao 266071, Shandong Province, China

Corresponding author: Lin-Lin Qu, FRCS (Gen Surg), MD, PhD, Chief Doctor, Department of Hepatopancreatobiliary Surgery, The Affiliated Hospital of Qingdao University, No. 16 Jiangsu Road, Huangdao District, Qingdao 266555, Shandong Province, China. taxue9455@sina.com

Abstract

BACKGROUND

Plexiform fibromyxoma (PF) is a rare mesenchymal tumor of the stomach. The clinical features of PF frequently include upper abdominal pain, abdominal discomfort, hematemesis, melena, pyloric obstruction and an upper abdominal mass. We herein report a case of PF resected by laparoscopic radical distal gastrectomy plus Roux-en-Y gastrojejunostomy.

CASE SUMMARY

The patient was admitted to hospital, due to a 1-wk history of an abdominal space-occupying lesion identified during a health examination. He underwent complete resection by laparoscopic radical distal gastrectomy plus Roux-en-Y gastrojejunostomy. During the operation, the tumor was located in the anterior wall of the gastric antrum (approximately 7 cm × 6 cm × 5.5 cm) and did not show evidence of invasion of the serosa. Histology showed that the tumor cells were oval fibroblast-like and spindle-shaped cells, with numerous thin-walled blood vessels and abundant myxoid stroma. Cellular atypia and mitosis were both rare. Immunohistochemistry showed that the tumor cells were immunoreactive for smooth muscle actin, S-100 and CD-10, but were negative for CD-117, CD-34, DOG-1, and ALK. In this case, S-100 was positive and no significant disease was observed during the follow-up period.

CONCLUSION

The fact that PF is a rare tumor with only a few cases in this region can lead to misdiagnosis of this entity and pose a real diagnostic challenge for general surgeons and pathologists when encountering such patients and differentiating PF from other primary tumors of gastric mesenchymal origin. Our report may help increase awareness of this rare, but important new disease entity.

NonCommercial (CC BY-NC 4.0) license, which permits others to distribute, remix, adapt, build upon this work non-commercially, and license their derivative works on different terms, provided the original work is properly cited and the use is non-commercial. See: <http://creativecommons.org/licenses/by-nc/4.0/>

Manuscript source: Unsolicited manuscript

Specialty type: Medicine, research and experimental

Country/Territory of origin: China

Peer-review report's scientific quality classification

Grade A (Excellent): 0
Grade B (Very good): 0
Grade C (Good): C, C
Grade D (Fair): D
Grade E (Poor): 0

Received: May 30, 2020

Peer-review started: May 30, 2020

First decision: June 13, 2020

Revised: June 16, 2020

Accepted: September 12, 2020

Article in press: September 12, 2020

Published online: November 26, 2020

P-Reviewer: Handra-Luca A, Kawara F

S-Editor: Yan JP

L-Editor: Webster JR

P-Editor: Zhang YL



Key Words: Gastric plexiform fibromyxoma; Plexiform fibromyxoma; Immunohistochemistry; Operation; Mesenchymal tumors of stomach; Stomach; Case report

©The Author(s) 2020. Published by Baishideng Publishing Group Inc. All rights reserved.

Core Tip: Gastric plexiform fibromyxoma (PF) is a rare gastrointestinal mesenchymal tumor. We report a case of gastric PF, and the clinical manifestations and pathological characteristics of the tumor are summarized in conjunction with a literature review to improve the understanding of this tumor.

Citation: Pei JY, Tan B, Liu P, Cao GH, Wang ZS, Qu LL. Gastric plexiform fibromyxoma: A case report. *World J Clin Cases* 2020; 8(22): 5639-5644

URL: <https://www.wjgnet.com/2307-8960/full/v8/i22/5639.htm>

DOI: <https://dx.doi.org/10.12998/wjcc.v8.i22.5639>

INTRODUCTION

Gastric plexiform fibromyxoma (GPF) is a rare gastrointestinal mesenchymal tumor that most commonly occurs in the gastric antrum. GPF was first reported by Takahashi *et al*^[1] in 2007, but there have only been a few reports of GPF to date. In these cases, the boundary with surrounding gastric mucosa was unclear, and was plexiform or multinodular; GPF exhibits an invasive growth pattern underneath the mucous membranes and between muscles, and the intercellular substance is full of a mucus-like matrix. Immunohistochemical staining is negative for CD-117, DOG-1, CD-34 and S-100 protein, and Ki-67 staining commonly shows very low proliferation rates that are mostly < 5%. GPF can easily be misdiagnosed as gastrointestinal stromal tumor (GIST) and other mesenchymal tumors, leading to overtreatment. Here, we describe one case of GPF with regard to the current literature and discuss the diagnosis and treatment of the tumor.

CASE PRESENTATION

Chief complaints

A 45-year-old male patient presented due to a 1-wk history of an abdominal space-occupying lesion identified during a health examination.

History of present illness

The patient had no signs of jaundice, nausea, vomiting, or fever and was physically healthy.

Personal and family history

The patient had no medical history of malignancy.

Physical examination

The patient's physical examination was unremarkable.

Laboratory examinations

Laboratory findings were within normal limits, except for slightly higher total bilirubin (31.6 $\mu\text{mol/L}$; normal range: 3-22 $\mu\text{mol/L}$).

Imaging examinations

Abdominal computed tomography (CT) scan showed a soft tissue mass (approximately 6 cm \times 6.4 cm) in the upper right abdominal cavity, and the tumor showed heterogeneous density. Contrast-enhanced abdominal CT scan showed uneven delayed enhancement and a mass located at the gastric antrum of the lesser curvature (Figure 1). Based on the CT scan, GIST was considered highly likely.

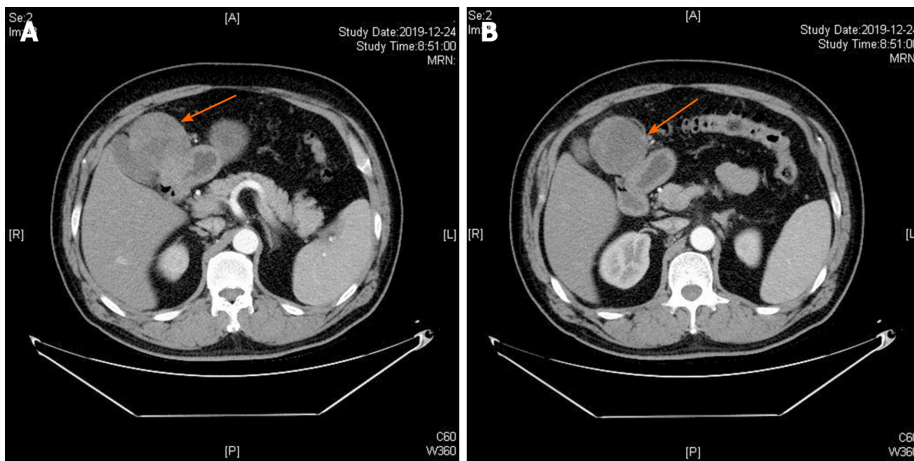


Figure 1 Contrast-enhanced computed tomography axial view revealed a tumor mass with an inhomogeneous enhancement in the arterial phase (A and B).

Clinical diagnosis

The patient was first diagnosed with GIST, which is commonly seen in the General Surgery Department.

Pathology and immunohistochemistry

On gross examination, the size of the submucosal tumor was 7 cm × 5.5 cm × 5 cm, and there was no capsule breakdown. In addition, the cut surface which was gray-red and gray-yellow contained translucent jelly, the quality was slightly tough, and no necrosis of the tumor. Under low-magnification microscopy, the tumor showed a multinodular plexiform growth pattern and was located in the submucosa, and it demonstrated interspersed growth in the smooth muscle and had a clear boundary on the serosal surface (Figure 2A). Under high-magnification microscopy, the tumor cells were oval fibroblast-like and spindle-shaped cells, and there were numerous thin-walled blood vessels and abundant myxoid stroma; cellular atypia and mitosis were both rare (Figure 2B). Immunohistochemically, the spindle cells were positive only for smooth muscle actin (SMA), S-100, and CD-10, but were negative for CD-117, CD-34, DOG-1, and ALK (Figure 3). The Ki-67 labeling index was 1%.

FINAL DIAGNOSIS

According to the results of pathology and immunohistochemistry, the tumor was diagnosed as GPF without lymph node metastasis.

TREATMENT

No tumor was found during physical examination one year previously. Considering the rapid growth of the tumor and the possibility of malignant tumor, the doctor did not perform preoperative biopsy and the patient underwent laparoscopic radical distal gastrectomy plus Roux-en-Y gastrojejunostomy.

OUTCOME AND FOLLOW-UP

After 8 d of treatment, the patient was discharged and had recovered well at 1 mo and 3 mo after surgery.

DISCUSSION

Plexus fibromyxoma (PF) is a rare gastric tumor. To date, 121 cases have been reported

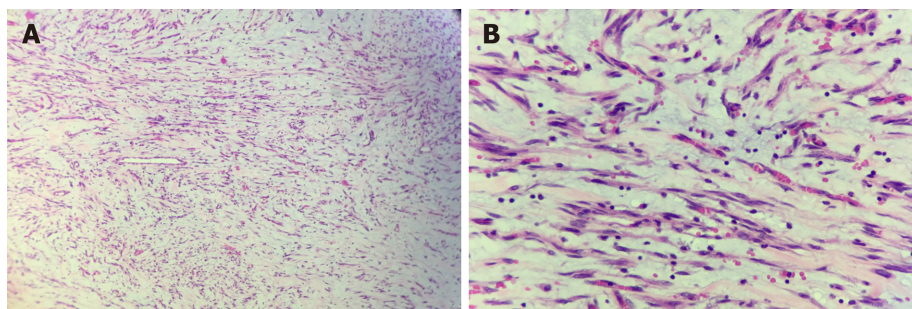


Figure 2 Microscopic examination showed that the tumor exhibited a multinodular plexiform growth pattern. These nodules consisted of bland-looking spindle cells admixed with abundant myxoid or fibromyxoid stroma rich in capillary-sized vessels (hematoxylin and eosin, A: $\times 100$; B: $\times 400$).

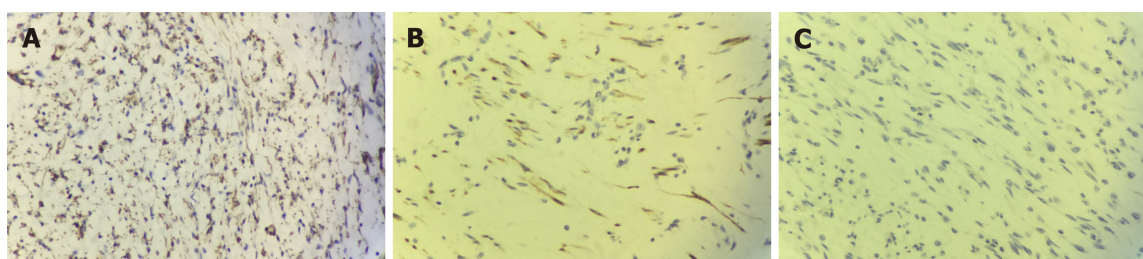


Figure 3 Immunohistochemical examinations of the tumor ($\times 400$). Tumor cells showed diffuse cytoplasmic positivity for smooth muscle actin (A) and S-100 (B), but were negative for CD117 (C).

worldwide^[2]. Takahashi *et al*^[1] reported this tumor for the first time in 2007 and named it plexiform angiomyxoid myofibroblastic tumor. In 2010, the World Health Organization adopted the opinion of Miettinen and others, and renamed the tumor PF^[3]. The onset of PF is more common during adulthood, but this tumor can also occur in children and adolescents, and there is no gender difference. PF is characterized by a unique cluster of spindle-shaped cell growth and a fine capillary network in a fibromyxoid stroma. PF mostly occurs in the gastric antrum and mainly invades the submucosa and muscularis. There have also been reports of PF in the esophagus, gallbladder, duodenum and colon^[4-7].

The clinical manifestations of PF are nonspecific, and this tumor often manifests with nonspecific gastrointestinal symptoms, such as upper abdominal pain, discomfort, hematemesis, melena, pyloric obstruction and an upper abdominal mass. A small number of patients have PF that is incidentally discovered during a health examination. Most fibrous myxomas are submucosal tumors that are smooth or concave and have erosions or ulcerations^[8]. Endoscopic ultrasound usually shows that the tumor originates from the muscular layer and is unevenly hypoechoic. CT and magnetic resonance imaging (MRI) are still important methods for the diagnosis of GPF, and these imaging modalities are helpful for tumor examination, staging and the development of surgical plans. Unfortunately, there are reports in the medical literature that most GPF are misdiagnosed as GISTs by ultrasonography and even intraoperative rapid pathology^[9].

Of 98 cases, the largest tumor diameter was reported to be 0.8-17 cm, with an average of 4.81 ± 3.30 cm and a median of 4.0 cm^[2]. On gross examination, the tumor was located under the mucous membrane and was a nodular or lobulated mass. The boundaries were clear, the surface mucosa was smooth and complete, and there may be small ulcers, depressions, and other features. The cut surface was gray-white, and some were translucent. On microscopy, the tumor appeared to grow in multiple sections, to contain numerous thin-walled blood vessels and to have an abundant myxoid stroma. Tumor cells were oval or fusiform, and cellular atypia and mitosis were both rare. Immunohistochemistry showed that tumor cells had some myofibroblast differentiation, and most PFs were SMA, MSA, and vimentin-positive and CD-34, CD-117, S-100 and DOG-1 negative^[10-12]. It is important to note that this patient was S-100 positive. The S-100 protein family consists of 25 known members that regulate a range of different cellular processes, including proliferation, differentiation, inflammation, migration, invasion, apoptosis, Ca^{2+} homeostasis and energy metabolism. The significance of S-100 expression in GPF requires further study.

GPF needs to be distinguished from primary tumors of gastric mesenchymal origin. (1) The most common tumors of gastric mesenchymal origin are GISTs. These tumors show nodular growth, and very few show mucinous degeneration^[8]. GISTs with mucinous degeneration are more difficult to distinguish from GPF^[9,13]. GISTs do not have the characteristic morphology of PF; in addition, the tumor cells are positive for CD-117, CD-34 and DOG-1, and a KIT gene mutation can be detected; however, a few cases of mesenchymoma are CD-117-negative and do not have KIT gene mutation, but a platelet-derived growth factor receptor α gene mutation can be detected^[14]; (2) Inflammatory myofibroblastic tumors are common in children and adolescents. These tumors are comprised of proliferating spindle-shaped fibroblasts and myofibroblasts arranged in bundles or swirls, with a large number of inflammatory cells in the intercellular space, and the immunohistochemical marker ALK-1 is positive^[15]; (3) Gastrointestinal schwannoma occurs predominantly in the stomach and is mainly composed of spindle cells, most of which form peripheral lymphatic sheaths and germinal centers, with chronic inflammatory cell infiltration and focal infiltrative growth at tumor boundaries, and the immunohistochemical marker S-100 is positive^[16]; (4) Leiomyoma cells have the characteristics of an eosinophilic cytoplasm and blunt ends of the nucleus; however, PF generally does not show an obvious bundled arrangement of tumor cells, and the cytoplasm is not as eosinophilic as in leiomyoma. The immunophenotype only shows partial smooth muscle differentiation; and (5) The tumor cells of fibromatosis are arranged in long bundles, and there is no plexiform growth feature. The tumor cells may have β -catenin-positive nuclei. At present, it is still difficult to diagnose the disease by clinical symptoms combined with auxiliary examinations, such as endoscopic ultrasound, CT and MRI. Preoperative aspiration biopsy and frozen section helps to increase the diagnostic rate of the disease, thereby reducing inappropriate treatment, such as imatinib chemotherapy, caused by misdiagnosis in the clinic.

At present, the treatment of this disease is still mainly based on surgical resection, and only a few cases of endoscopic resection have been reported^[12,17,18]. The literature suggests that the prognosis is good after surgery, and there is no recurrence or metastasis. This patient remains in good health after 3 mo of follow-up. PF is a benign tumor^[19]. However, no cases have confirmed that malignant transformation will not occur^[20]. Therefore, confirmation that PF is benign requires longitudinal observation and studies with a sufficient number of cases.

CONCLUSION

GPF is a rare gastric tumor, which has attracted increasing clinical attention and occurs mostly in the gastrointestinal tract. Typical clinical presentations are nonspecific gastrointestinal symptoms, or upper gastrointestinal bleeding. Needle aspiration biopsy is recommended for visualizing the microscopic features of GPF with benign cytological traits, and immunohistochemistry is required for diagnosis as well as for exclusion of GIST. Surgical excision is the main treatment.

REFERENCES

- 1 **Takahashi Y**, Shimizu S, Ishida T, Aita K, Toida S, Fukusato T, Mori S. Plexiform angiomyxoid myofibroblastic tumor of the stomach. *Am J Surg Pathol* 2007; **31**: 724-728 [PMID: [17460456](#) DOI: [10.1097/01.pas.0000213448.54643.2f](#)]
- 2 **Su HA**, Yen HH, Chen CJ. An Update on Clinicopathological and Molecular Features of Plexiform Fibromyxoma. *Can J Gastroenterol Hepatol* 2019; **2019**: 3960920 [PMID: [31360694](#) DOI: [10.1155/2019/3960920](#)]
- 3 **Miettinen M**, Fletcher CD, Kindblom LG. Mesenchymal tumours of the stomach. In: Bosman FT, Carneiro F, Hruban R. WHO classification of tumours of the digestive system. Lyon: IARC Press; 2010: 74-79
- 4 **Duckworth LV**, Gonzalez RS, Martelli M, Liu C, Coffin CM, Reith JD. Plexiform fibromyxoma: report of two pediatric cases and review of the literature. *Pediatr Dev Pathol* 2014; **17**: 21-27 [PMID: [24160555](#) DOI: [10.2350/13-09-1373-OA.1](#)]
- 5 **Moris D**, Spanou E, Sougioultzis S, Dimitrakellis N, Kalisperati P, Delladetsima I, Felekouras E. Duodenal plexiform fibromyxoma as a cause of obscure upper gastrointestinal bleeding: A case report. *Medicine (Baltimore)* 2017; **96**: e5883 [PMID: [28072751](#) DOI: [10.1097/MD.0000000000005883](#)]
- 6 **Daum O**, Jirasek T, Grossmann P, Mukensnabl P, Michal M. Plexiform fibroma of the colon. *Appl Immunohistochem Mol Morphol* 2010; **18**: 483-484 [PMID: [20436346](#) DOI: [10.1097/PAL.0b013e3181d84b69](#)]
- 7 **Fassan M**, Salmaso R, Saraggi D, Alaggio R, Guido M, Balsamo L, Carniato S, Gruppo M, Ninfo V, Bardini R, Rugge M. Plexiform fibromyxoma of the gallbladder. *Pathologica* 2015; **107**: 181-184 [PMID: [26946873](#)]

- 8 **Yoshida A**, Klimstra DS, Antonescu CR. Plexiform angiomyxoid tumor of the stomach. *Am J Surg Pathol* 2008; **32**: 1910-2; author reply 1912-3 [PMID: [18824895](#) DOI: [10.1097/PAS.0b013e3181838fd1](#)]
- 9 **Lai J**, Kresak JL, Cao D, Zhang D, Zhang S, Leon ME, Shenoy A, Liu W, Trevino J, Starostik P, Gonzalo DH, Wang H, Liu X, Fan X. Gastric Plexiform Fibromyxoma: A Great Mimic of Gastrointestinal Stromal Tumor (GIST) and Diagnostic Pitfalls. *J Surg Res* 2019; **239**: 76-82 [PMID: [30822694](#) DOI: [10.1016/j.jss.2019.01.062](#)]
- 10 **Lu B**, Ye W, Liu H. A Rare Gastric Tumor in a Young Woman. Gastric Plexiform Angiomyxoid Myofibroblastic Tumor. *Gastroenterology* 2015; **149**: 294-295 [PMID: [26119799](#) DOI: [10.1053/j.gastro.2015.03.050](#)]
- 11 **Akai H**, Kiryu S, Shinozaki M, Ohta Y, Nakano Y, Yasaka K, Ohtomo K. Computed tomography and magnetic resonance imaging of a plexiform angiomyxoid myofibroblastic tumor: a case report. *BMC Med Imaging* 2017; **17**: 7 [PMID: [28103839](#) DOI: [10.1186/s12880-017-0180-1](#)]
- 12 **Wang WY**, Li JN, Li GD. Plexiform angiomyxoid myofibroblastic tumour of the gastric fundus: successful diagnosis and treatment by endoscopy. *J Clin Pathol* 2010; **63**: 569-570 [PMID: [20498030](#) DOI: [10.1136/jcp.2010.076646](#)]
- 13 **Li B**, Zhang QF, Han YN, Ouyang L. Plexiform myxoid gastrointestinal stromal tumor: a potential diagnostic pitfall in pathological findings. *Int J Clin Exp Pathol* 2015; **8**: 13613-13618 [PMID: [26722584](#)]
- 14 **Miettinen M**, Makhoul HR, Sobin LH, Lasota J. Plexiform fibromyxoma: a distinctive benign gastric antral neoplasm not to be confused with a myxoid GIST. *Am J Surg Pathol* 2009; **33**: 1624-1632 [PMID: [19675452](#) DOI: [10.1097/PAS.0b013e3181ae666a](#)]
- 15 **Bjelovic M**, Micev M, Spica B, Babic T, Gunjic D, Djuric A, Pesko P. Primary inflammatory myofibroblastic tumor of the stomach in an adult woman: a case report and review of the literature. *World J Surg Oncol* 2013; **11**: 35 [PMID: [23374227](#) DOI: [10.1186/1477-7819-11-35](#)]
- 16 **James AW**, Shurell E, Singh A, Dry SM, Eilber FC. Malignant Peripheral Nerve Sheath Tumor. *Surg Oncol Clin N Am* 2016; **25**: 789-802 [PMID: [27591499](#) DOI: [10.1016/j.soc.2016.05.009](#)]
- 17 **Sing Y**, Subrayan S, Mqadi B, Ramdial PK, Reddy J, Moodley MS, Bux S. Gastric plexiform angiomyxoid myofibroblastic tumor. *Pathol Int* 2010; **60**: 621-625 [PMID: [20712648](#) DOI: [10.1111/j.1440-1827.2010.02569.x](#)]
- 18 **Kang Y**, Jung W, Do IG, Lee EJ, Lee MH, Kim KM, Choi J. Plexiform angiomyxoid myofibroblastic tumor of the stomach: report of two cases and review of the literature. *Korean J Pathol* 2012; **46**: 292-296 [PMID: [23110018](#) DOI: [10.4132/KoreanJPathol.2012.46.3.292](#)]
- 19 **Rau TT**, Hartmann A, Dietmaier W, Schmitz J, Hohenberger W, Hofstaedter F, Katenkamp K. Plexiform angiomyxoid myofibroblastic tumour: differential diagnosis of gastrointestinal stromal tumour in the stomach. *J Clin Pathol* 2008; **61**: 1136-1137 [PMID: [18820104](#) DOI: [10.1136/jcp.2008.059162](#)]
- 20 **Zhang WG**, Xu LB, Xiang YN, Duan CH. Plexiform fibromyxoma of the small bowel: A case report. *World J Clin Cases* 2018; **6**: 1067-1072 [PMID: [30568965](#) DOI: [10.12998/wjcc.v6.i15.1067](#)]



Published by **Baishideng Publishing Group Inc**
7041 Koll Center Parkway, Suite 160, Pleasanton, CA 94566, USA

Telephone: +1-925-3991568

E-mail: bpgoffice@wjgnet.com

Help Desk: <https://www.f6publishing.com/helpdesk>

<https://www.wjgnet.com>

