

World Journal of *Clinical Cases*

World J Clin Cases 2020 December 6; 8(23): 5835-6212



EDITORIAL

- 5835** Understanding the immunopathogenesis of COVID-19: Its implication for therapeutic strategy
Shimizu Y

OPINION REVIEW

- 5844** What is the gut feeling telling us about physical activity in colorectal carcinogenesis?
Cigrovski Berkovic M, Cigrovski V, Bilic-Curcic I, Mrzljak A

REVIEW

- 5852** Latest developments in chronic intestinal pseudo-obstruction
Zhu CZ, Zhao HW, Lin HW, Wang F, Li YX

ORIGINAL ARTICLE

Case Control Study

- 5866** Correlation between ductus venosus spectrum and right ventricular diastolic function in isolated single-umbilical-artery foetus and normal foetus in third trimester
Li TG, Nie F, Xu XY

Retrospective Cohort Study

- 5876** Clinical efficacy of integral theory-guided laparoscopic integral pelvic floor/ligament repair in the treatment of internal rectal prolapse in females
Yang Y, Cao YL, Zhang YY, Shi SS, Yang WW, Zhao N, Lyu BB, Zhang WL, Wei D

Retrospective Study

- 5887** Treatment of Kümmell's disease with sequential infusion of bone cement: A retrospective study
Zhang X, Li YC, Liu HP, Zhou B, Yang HL
- 5894** Application value analysis of magnetic resonance imaging and computed tomography in the diagnosis of intracranial infection after craniocerebral surgery
Gu L, Yang XL, Yin HK, Lu ZH, Geng CJ
- 5902** Focal intrahepatic strictures: A proposal classification based on diagnosis-treatment experience and systemic review
Zhou D, Zhang B, Zhang XY, Guan WB, Wang JD, Ma F
- 5918** Preliminary analysis of the effect of vagus nerve stimulation in the treatment of children with intractable epilepsy
Fang T, Xie ZH, Liu TH, Deng J, Chen S, Chen F, Zheng LL

- 5926** Scoring system for poor limb perfusion after limb fracture in children
Zhu T, Shi Y, Yu Q, Zhao YJ, Dai W, Chen Y, Zhang SS
- 5935** Overexpression of CD155 is associated with PD-1 and PD-L1 expression on immune cells, rather than tumor cells in the breast cancer microenvironment
Wang RB, Li YC, Zhou Q, Lv SZ, Yuan KY, Wu JP, Zhao YJ, Song QK, Zhu B
- 5944** Application of computer tomography-based 3D reconstruction technique in hernia repair surgery
Wang F, Yang XF
- 5952** Effect of methylprednisolone in severe and critical COVID-19: Analysis of 102 cases
Zhu HM, Li Y, Li BY, Yang S, Peng D, Yang X, Sun XL, Zhang M

Observational Study

- 5962** Genetic diagnosis history and osteoarticular phenotype of a non-transfusion secondary hemochromatosis
Ruan DD, Gan YM, Lu T, Yang X, Zhu YB, Yu QH, Liao LS, Lin N, Qian X, Luo JW, Tang FQ
- 5976** Abdominal ventral rectopexy with colectomy for obstructed defecation syndrome: An alternative option for selected patients
Wang L, Li CX, Tian Y, Ye JW, Li F, Tong WD
- 5988** Surgical treatment of multiple magnet ingestion in children: A single-center study
Cai DT, Shu Q, Zhang SH, Liu J, Gao ZG

Randomized Clinical Trial

- 5999** Efficacy and economic benefits of a modified Valsalva maneuver in patients with paroxysmal supraventricular tachycardia
Wang W, Jiang TF, Han WZ, Jin L, Zhao XJ, Guo Y

CASE REPORT

- 6009** Duodenal giant stromal tumor combined with ectopic varicose hemorrhage: A case report
Li DH, Liu XY, Xu LB
- 6016** Healthy neonate born to a SARS-CoV-2 infected woman: A case report and review of literature
Wang RY, Zheng KQ, Xu BZ, Zhang W, Si JG, Xu CY, Chen H, Xu ZY, Wu XM
- 6026** Pleomorphic adenoma of the trachea: A case report and review of the literature
Liao QN, Fang ZK, Chen SB, Fan HZ, Chen LC, Wu XP, He X, Yu HP
- 6036** Neoadjuvant targeted therapy for apocrine carcinoma of the breast: A case report
Yang P, Peng SJ, Dong YM, Yang L, Yang ZY, Hu XE, Bao GQ
- 6043** Huge encrusted ureteral stent forgotten for over 25 years: A case report
Kim DS, Lee SH

- 6048** Roxadustat for treatment of erythropoietin-hyporesponsive anemia in a hemodialysis patient: A case report
Yu WH, Li XJ, Yuan F
- 6056** Suspected SARS-CoV-2 infection with fever and coronary heart disease: A case report
Gong JR, Yang JS, He YW, Yu KH, Liu J, Sun RL
- 6064** Interpersonal psychotherapy-based psychological intervention for patient suffering from COVID-19: A case report
Hu CC, Huang JW, Wei N, Hu SH, Hu JB, Li SG, Lai JB, Huang ML, Wang DD, Chen JK, Zhou XY, Wang Z, Xu Y
- 6071** Optical coherence tomography angiography characteristics in Waldenström macroglobulinemia retinopathy: A case report
Li J, Zhang R, Gu F, Liu ZL, Sun P
- 6080** Forty-nine years old woman co-infected with SARS-CoV-2 and Mycoplasma: A case report
Gao ZA, Gao LB, Chen XJ, Xu Y
- 6086** Endoscopic fenestration in the diagnosis and treatment of delayed anastomotic submucosal abscess: A case report and review of literature
Zhang BZ, Wang YD, Liao Y, Zhang JJ, Wu YF, Sun XL, Sun SY, Guo JT
- 6095** Small-cell neuroendocrine carcinoma of the rectum — a rare tumor type with poor prognosis: A case report and review of literature
Chen ZZ, Huang W, Wei ZQ
- 6103** Laparoscopic left lateral sectionectomy in pediatric living donor liver transplantation by single-port approach: A case report
Li H, Wei L, Zeng Z, Qu W, Zhu ZJ
- 6110** Malignant meningioma with jugular vein invasion and carotid artery extension: A case report and review of the literature
Chen HY, Zhao F, Qin JY, Lin HM, Su JP
- 6122** Neuronal intranuclear inclusion disease mimicking acute cerebellitis: A case report
Guo JJ, Wang ZY, Wang M, Jiang ZZ, Yu XF
- 6130** Hemophagocytic lymphohistiocytosis caused by STAT1 gain-of-function mutation is not driven by interferon- γ : A case report
Liu N, Zhao FY, Xu XJ
- 6136** Single door laminoplasty plus posterior fusion for posterior atlantoaxial dislocation with congenital malformation: A case report and review of literature
Zhu Y, Wu XX, Jiang AQ, Li XF, Yang HL, Jiang WM
- 6144** Occipital nodular fasciitis easily misdiagnosed as neoplastic lesions: A rare case report
Wang T, Tang GC, Yang H, Fan JK

- 6150** Postoperative secondary aggravation of obstructive sleep apnea-hypopnea syndrome and hypoxemia with bilateral carotid body tumor: A case report
Yang X, He XG, Jiang DH, Feng C, Nie R
- 6158** Uncontrolled central hyperthermia by standard dose of bromocriptine: A case report
Ge X, Luan X
- 6164** Acute celiac artery occlusion secondary to blunt trauma: Two case reports
Li H, Zhao Y, Xu YA, Li T, Yang J, Hu P, Ai T
- 6172** Multiple ectopic goiter in the retroperitoneum, abdominal wall, liver, and diaphragm: A case report and review of literature
Qin LH, He FY, Liao JY
- 6181** Symptomatic and optimal supportive care of critical COVID-19: A case report and literature review
Pang QL, He WC, Li JX, Huang L
- 6190** Primary breast cancer patient with poliomyelitis: A case report
Wang XM, Cong YZ, Qiao GD, Zhang S, Wang LJ
- 6197** Discontinuous polyostotic fibrous dysplasia with multiple systemic disorders and unique genetic mutations: A case report
Lin T, Li XY, Zou CY, Liu WW, Lin JF, Zhang XX, Zhao SQ, Xie XB, Huang G, Yin JQ, Shen JN
- 6206** Novel triple therapy for hemorrhagic ascites caused by endometriosis: A case report
Han X, Zhang ST

ABOUT COVER

Peer-reviewer of *World Journal of Clinical Cases*, Dr. Mohamad Adam Bujang is a Research Officer at the Institute for Clinical Research, Ministry of Health, Malaysia. After receiving his Bachelor's degree in Statistics from MARA University of Technology in 2004, Dr. Adam undertook his postgraduate study at the same university, receiving his Master's degree (MBA) in 2008 and his PhD in Information Technology and Quantitative Sciences in 2017. Currently, he works as a biostatistician and researcher in the Clinical Research Centre, Sarawak General Hospital. His ongoing research interests involve such research methodologies as sampling techniques, sample size planning, and statistical analyses. Since 2016, he has served as an active member of the Malaysia Institute of Statistics and the Association of Clinical Registries Malaysia. (L-Editor: Filipodia)

AIMS AND SCOPE

The primary aim of *World Journal of Clinical Cases* (*WJCC*, *World J Clin Cases*) is to provide scholars and readers from various fields of clinical medicine with a platform to publish high-quality clinical research articles and communicate their research findings online.

WJCC mainly publishes articles reporting research results and findings obtained in the field of clinical medicine and covering a wide range of topics, including case control studies, retrospective cohort studies, retrospective studies, clinical trials studies, observational studies, prospective studies, randomized controlled trials, randomized clinical trials, systematic reviews, meta-analysis, and case reports.

INDEXING/ABSTRACTING

The *WJCC* is now indexed in Science Citation Index Expanded (also known as SciSearch®), Journal Citation Reports/Science Edition, PubMed, and PubMed Central. The 2020 Edition of Journal Citation Reports® cites the 2019 impact factor (IF) for *WJCC* as 1.013; IF without journal self cites: 0.991; Ranking: 120 among 165 journals in medicine, general and internal; and Quartile category: Q3.

RESPONSIBLE EDITORS FOR THIS ISSUE

Production Editor: Yan-Xia Xing; Production Department Director: Yun-Xiaojian Wu; Editorial Office Director: Jin-Lai Wang.

NAME OF JOURNAL

World Journal of Clinical Cases

ISSN

ISSN 2307-8960 (online)

LAUNCH DATE

April 16, 2013

FREQUENCY

Semimonthly

EDITORS-IN-CHIEF

Dennis A Bloomfield, Sandro Vento, Bao-gan Peng

EDITORIAL BOARD MEMBERS

<https://www.wjgnet.com/2307-8960/editorialboard.htm>

PUBLICATION DATE

December 6, 2020

COPYRIGHT

© 2020 Baishideng Publishing Group Inc

INSTRUCTIONS TO AUTHORS

<https://www.wjgnet.com/bpg/gerinfo/204>

GUIDELINES FOR ETHICS DOCUMENTS

<https://www.wjgnet.com/bpg/GerInfo/287>

GUIDELINES FOR NON-NATIVE SPEAKERS OF ENGLISH

<https://www.wjgnet.com/bpg/gerinfo/240>

PUBLICATION ETHICS

<https://www.wjgnet.com/bpg/GerInfo/288>

PUBLICATION MISCONDUCT

<https://www.wjgnet.com/bpg/gerinfo/208>

ARTICLE PROCESSING CHARGE

<https://www.wjgnet.com/bpg/gerinfo/242>

STEPS FOR SUBMITTING MANUSCRIPTS

<https://www.wjgnet.com/bpg/GerInfo/239>

ONLINE SUBMISSION

<https://www.f6publishing.com>

Forty-nine years old woman co-infected with SARS-CoV-2 and Mycoplasma: A case report

Zi-Ang Gao, Ling-Bao Gao, Xin-Jie Chen, Yu Xu

ORCID number: Zi-Ang Gao 0000-0002-7952-5058; Ling-Bao Gao 0000-0002-8297-9579; Xin-Jie Chen 0000-0002-3683-6489; Yu Xu 0000-0001-7751-6345.

Author contributions: Gao ZA and Gao LB contributed equally to this work and should be regarded as co-first authors; Gao ZA and Gao LB collected clinical data, discussed the details and wrote this article together; Chen XJ analyzed and interpreted the patient data regarding CoVID-19; Xu Y analyzed the data, modified the manuscript and was a major contributor in writing the manuscript; all authors read and approved the final manuscript.

Informed consent statement:

Written informed consent was obtained from the patient for publication of this case report and any accompanying images. A copy of the written consent is available for review from the Editor of this journal.

Conflict-of-interest statement: We declare that we have no conflict of interest.

CARE Checklist (2016) statement:

We have read the CARE Checklist (2016), and the manuscript was prepared and revised according to the CARE Checklist (2016).

Zi-Ang Gao, Yu Xu, Department of Otolaryngology-Head and Neck Surgery, Renmin Hospital of Wuhan University, Wuhan 430060, Hubei Province, China

Ling-Bao Gao, Department of Transfusion, Taizhou People's Hospital, Taizhou 225300, Jiangsu Province, China

Xin-Jie Chen, Department of Neurology, The Second Affiliated Hospital of Guangzhou University of Chinese Medicine, Guangzhou 510006, Guangdong Province, China

Corresponding author: Yu Xu, MD, PhD, Professor, Department of Otolaryngology-Head and Neck Surgery, Renmin Hospital of Wuhan University, No. 238 Jiefang Road, Wuhan 430060, Hubei Province, China. xuy@whu.edu.cn

Abstract

BACKGROUND

Severe acute respiratory syndrome coronavirus 2 (SARS-CoV-2) is a new virus responsible for the outbreak of respiratory illness known as coronavirus disease 2019 (CoVID-19). Mycoplasma is an uncommon co-infected pathogen with SARS-CoV-2 and has not yet been reported. Computed tomography (CT), used as an accessory examination, may play a more significant role in this co-infection.

CASE SUMMARY

A 49-year-old female presented with a cough, expectoration and chest congestion followed by elevated C-reactive protein and erythrocyte sedimentation rate. CT images showed ground-glass opacities in bilateral lower lobes and a patchy and striate shadow in the right upper lobe. Immunoglobulin M antibody of *Mycoplasma pneumoniae* was positive and real-time fluorescence polymerase chain reaction of sputum was positive for SARS-CoV-2 nucleic acid. The diagnosis of CoVID-19 was made based on laboratory results, chest CT images, clinical manifestations and epidemiologic characteristics. She was treated with combination therapy for 17 d and showed a marked reCoVery.

CONCLUSION

Co-infection with SARS-CoV-2 and Mycoplasma in CoVID-19 patients appears to be uncommon. CT is an acceptable method for the primary diagnosis and treatment should be initiated as soon as possible. Combination therapy with antiviral, anti-inflammatory, traditional Chinese herbal medicine and interferon inhalation may be a reference for further progress in treating this co-infection.

Open-Access: This article is an open-access article that was selected by an in-house editor and fully peer-reviewed by external reviewers. It is distributed in accordance with the Creative Commons Attribution NonCommercial (CC BY-NC 4.0) license, which permits others to distribute, remix, adapt, build upon this work non-commercially, and license their derivative works on different terms, provided the original work is properly cited and the use is non-commercial. See: <http://creativecommons.org/licenses/by-nc/4.0/>

Manuscript source: Unsolicited manuscript

Specialty type: Medicine, research and experimental

Country/Territory of origin: China

Peer-review report's scientific quality classification

Grade A (Excellent): 0
Grade B (Very good): B
Grade C (Good): C
Grade D (Fair): 0
Grade E (Poor): 0

Received: May 28, 2020

Peer-review started: May 28, 2020

First decision: September 23, 2020

Revised: October 6, 2020

Accepted: October 27, 2020

Article in press: October 27, 2020

Published online: December 6, 2020

P-Reviewer: Hossain MG, Phan T

S-Editor: Fan JR

L-Editor: Webster JR

P-Editor: Xing YX



Key Words: CoVID-19; SARS-CoV-2; Mycoplasma; Co-infection; Computed tomography; Infectious disease; Case report

©The Author(s) 2020. Published by Baishideng Publishing Group Inc. All rights reserved.

Core Tip: In this study, we evaluated the disease evolution of a 49-year-old lady co-infected with severe acute respiratory syndrome coronavirus 2 and Mycoplasma. This co-infection is rare and her computed tomography (CT) images showed both typical manifestations of coronavirus disease 2019 and untypical findings which suggested Mycoplasma infection. Although the disease developed rapidly, with early intervention and treatment, we successfully prevented her from becoming worse. Clinical improvement on CT images suggested that our combination therapy of antiviral, anti-inflammatory, traditional Chinese herbal medicine and interferon inhalation may be an effective early treatment and a reference for further progress in treating this co-infection.

Citation: Gao ZA, Gao LB, Chen XJ, Xu Y. Forty-nine years old woman co-infected with SARS-CoV-2 and Mycoplasma: A case report. *World J Clin Cases* 2020; 8(23): 6080-6085

URL: <https://www.wjgnet.com/2307-8960/full/v8/i23/6080.htm>

DOI: <https://dx.doi.org/10.12998/wjcc.v8.i23.6080>

INTRODUCTION

Coronavirus disease 2019 (CoVID-19) is a respiratory illness caused by severe acute respiratory syndrome coronavirus 2 (SARS-CoV-2) which has already infected over 70000 and killed more than 2000, especially in Wuhan, China. A study of 8274 samples showed that 5.8% of CoVID-19 infected and 18.4% of non-CoVID-19-infected patients had other infections^[1]. However, co-infection with SARS-CoV-2 and Mycoplasma has not been reported previously. We report the case of a 49-year-old female co-infected with SARS-CoV-2 and Mycoplasma.

CASE PRESENTATION

Chief complaints

A 49-year-old woman came to the Outpatient Service of our hospital complaining of a cough, chest discomfort and fatigue on January 20, 2020.

History of present illness

The patient's symptoms started 5 d ago with a cough, expectoration and chest congestion.

History of past illness

She mentioned a travel history to Wuhan one week ago, the center of this CoVID-19 outbreak.

Physical examination

On admission, symptoms of cough, expectoration of white sputum, chest congestion and fatigue were observed, but her body temperature was normal 37.0°C (98.6°F). Coarse breath sounds in both lungs with wet rales distributed at the base of both lungs were heard on auscultation.

Laboratory examinations

Laboratory studies showed a normal leukocyte count (white blood cell count, $5.58 \times 10^9/L$) and normal lymphocyte count (lymphocyte count, $1.47 \times 10^9/L$). The leukocyte differential count indicated 64.9% neutrophils, 26.3% lymphocytes, and 5.9% monocytes. There were elevated blood levels of C-reactive protein (12.50 mg/L) and

erythrocyte sedimentation rate (37 mm/h). Albumin (32.1 g/L) and serum calcium (3.26 mmol/L) were lower. Immunoglobulin M (IgM) antibody of *Mycoplasma pneumoniae* was positive (Table 1).

Imaging examinations

Unenhanced chest computed tomography (CT) showed ground-glass opacities in bilateral lower lobes and a patchy and striate shadow in the right upper lobe. According to these findings and due to her travel history to Wuhan, we speculated that she had *Mycoplasma* infection and suspected SARS-CoV-2 infection; therefore, we sent a throat swab for analysis and the results were expected to take several days. Considering her CT images and the rapid development of CoVID-19, we treated the patient with anti-inflammatory and empirical antiviral drugs in the first three days. CT images showed progressive manifestations.

Further diagnostic work-up

Three days later, real-time fluorescence polymerase chain reaction (RT-PCR) of sputum was positive for SARS-CoV-2 nucleic acid and her diagnosis of CoVID-19 was finally made based on laboratory results, chest CT images, clinical manifestations and epidemiologic characteristics. We were glad that we performed early intervention with antiviral therapy based on the previous CT manifestations.

CT showed multiple patchy ground-glass opacities and consolidated opacities in bilateral lower lobes (Figure 1) and a patchy and striate shadow of slightly high density in the upper right lung (Figure 2). This asymmetrical lesion in the upper right lobe was quite rare in the cases reported so far.

FINAL DIAGNOSIS

CoVID-19 and *Mycoplasma* infection.

TREATMENT

According to Chinese newest treatment guidelines for SARS-CoV-2, the patient was treated with antiviral drugs (Aluvia, Peramivir, Interferon- α 2b), anti-inflammatory drugs (Cefonicid Sodium, Azithromycin, Moxifloxacin) and traditional Chinese herbal medicine (Lianhuaqingwen), combined with supportive care and interferon inhalation from January 25, 2020 and she was discharged on February 10, 2020.

OUTCOME AND FOLLOW-UP

On the 7th day, her cough, expectoration, chest congestion and debilitation started to improve. Laboratory tests of SARS-CoV-2 nucleic acid, lymphocyte count, erythrocyte sedimentation rate, potassium, total calcium, lactate dehydrogenase, blood oxygen saturation and IgM antibody of *Mycoplasma pneumoniae* all showed that the patient had improved. A marked reCoVery was noted in this patient at the 2 wk follow-up.

DISCUSSION

The outbreak of CoVID-19 caused by SARS-CoV-2 has resulted in significant harm to human health globally, and has been declared a public health emergency of international concern by the WHO^[2].

CoVID-19 has spread in 43 countries, including South Korea, Japan, Italy, and the United States. Person-to-person transmission in hospital and family settings has been identified and more than 2600 lives have been lost. From up-to-date data, it can be seen that fever and cough are the most common symptoms, and both diarrhea and vomiting are rare. Most patients have lymphopenia and elevated levels of C-reactive protein on admission^[3]. Among 2745 CoVID-19 patients, 104 were positive for multiple respiratory pathogens and 6/104 had co-infection with coronavirus (3/104), influenza A virus (2/104), rhinovirus (2/104), and influenza A H3N2 (1/104)^[4]. Co-infection with SARS-CoV-2 and *Mycoplasma* is unusual and has not been reported previously.

Table 1 Laboratory findings of the patient co-infected with severe acute respiratory syndrome coronavirus 2 and Mycoplasma

Index	Result		Reference range
Blood leukocyte count ($10^9/L$)	4.29	-	3.5-9.5
Lymphocyte count ($10^9/L$)	0.94	↓	1.1-3.2
Platelet count ($10^9/L$)	214	-	125-350
Hemoglobin level (g/L)	138	-	115-150
C-reactive protein level (mg/L)	3.50	-	0-10
Procalcitonin level (ng)	0.031	-	0.000-0.500
Lactate dehydrogenase (U/L)	252	↑	120-250
Aspartate aminotransferase (U/L)	25	-	13-35
Alanine aminotransferase (U/L)	17	-	7-40
Total bilirubin ($\mu\text{mol/L}$)	13.9	-	0-23
Creatinine kinase (U/L)	52	-	0-145
Creatinine ($\mu\text{mol/L}$)	49.2	-	41-73
D-dimer ($\mu\text{g/L}$)	290	-	0-550
Sodium (mmol/L)	138.6	-	137-147
Potassium (mmol/L)	3.26	↓	3.5-5.3
Chloride (mmol/L)	102.8	-	99-110
Total calcium (mmol/L)	1.77	↓	2.11-2.52
Blood oxygen saturation (%)	95	-	95-98
Erythrocyte sedimentation rate (mm/h)	37	↑	0-20

Treatment protocols and prognosis are new with few references.

Imaging studies have shown that ground-glass opacity and bilateral patchy shadowing are the most common features on chest CT^[3-5]. In our patient, progressive changes in typical CT manifestations were seen in bilateral lower lobes which were thought to be caused by CoVID-19, but an atypical isolated shadow in the upper right lung was also seen. This was thought to be caused by Mycoplasma infection.

CONCLUSION

In conclusion, co-infection with SARS-CoV-2 and Mycoplasma should not be ignored in clinical diagnosis and treatment, especially in the early course as CoVID-19 is a rapidly developing disease. CT manifestations may be a better and quicker route to the diagnosis of CoVID-19 than nucleic acid testing using RT-PCR, and can result in timely treatment. Clinical improvement in CT images in our patient suggested that our novel combination therapy may be a reference for further progress in the treatment of this co-infection. As these pathogens are very infectious, doctors and nurses, particularly those on the first line, require personal protective equipment.

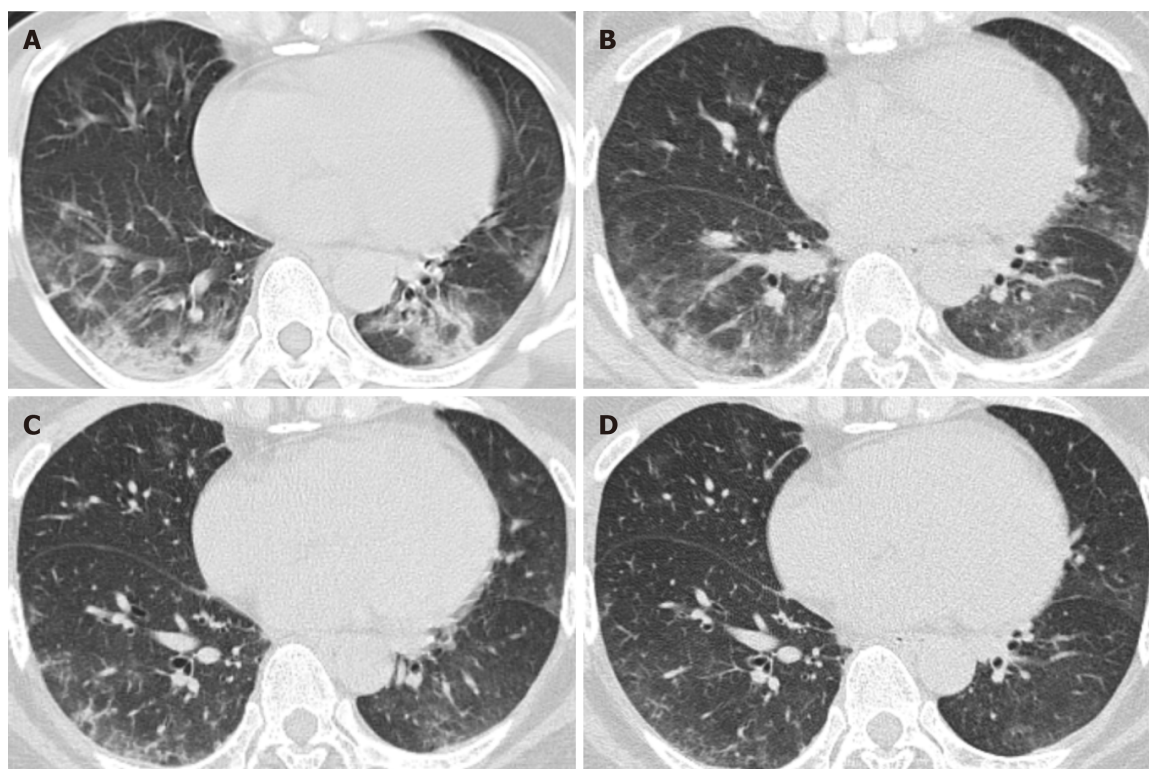


Figure 1 Unenhanced computed tomography images in a 49-year-old woman (axial imaging). Computed tomography (CT) radiographs show multiple patchy ground-glass opacities and consolidated opacities in bilateral lower lobes, the middle lobe of the right lung and the tongue segment of the upper left lung, as treatment progressed, CT manifestations showed improvement. A: Day 7 (2020.1.26) after the onset of symptoms; B: Day 12 (2020.1.31) after the onset of symptoms; C: Day 16 (2020.2.4) after the onset of symptoms; D: Day 21 (2020.2.9) after the onset of symptoms.

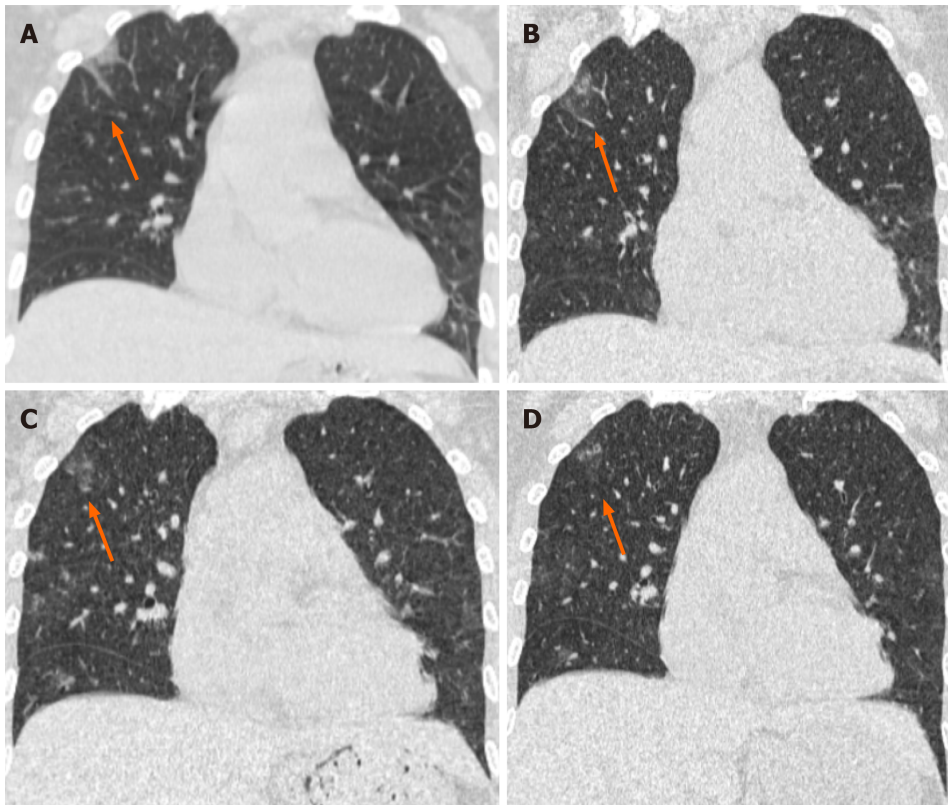


Figure 2 Unenhanced computed tomography images in a 49-year-old woman (coronal imaging). Computed tomography radiographs show a patchy and striate shadow of slightly high density in the upper right lung (arrows), as the treatment progressed, this asymmetrical lesion was gradually absorbed. A: Day 7 (2020.1.26) after the onset of symptoms; B: Day 12 (2020.1.31) after the onset of symptoms; C: Day 16 (2020.2.4) after the onset of symptoms; D: Day 21 (2020.2.9) after the onset of symptoms.

REFERENCES

- 1 Analysis of 8274 cases of novel coronavirus nucleic acid detection and co-infection in Wuhan. *Zhonghua Jianshan Yixue Zazhi* 2020; **43**: 341-345 [DOI: [10.3760/cma.j.cn114452-20200222-00106](https://doi.org/10.3760/cma.j.cn114452-20200222-00106)]
- 2 Zhu N, Zhang D, Wang W, Li X, Yang B, Song J, Zhao X, Huang B, Shi W, Lu R, Niu P, Zhan F, Ma X, Wang D, Xu W, Wu G, Gao GF, Tan W; China Novel Coronavirus Investigating and Research Team. A Novel Coronavirus from Patients with Pneumonia in China, 2019. *N Engl J Med* 2020; **382**: 727-733 [PMID: [31978945](https://pubmed.ncbi.nlm.nih.gov/31978945/) DOI: [10.1056/NEJMoa2001017](https://doi.org/10.1056/NEJMoa2001017)]
- 3 Guan WJ, Ni ZY, Hu Y, Liang WH, Ou CQ, He JX, Liu L, Shan H, Lei CL, Hui DSC, Du B, Li LJ, Zeng G, Yuen KY, Chen RC, Tang CL, Wang T, Chen PY, Xiang J, Li SY, Wang JL, Liang ZJ, Peng YX, Wei L, Liu Y, Hu YH, Peng P, Wang JM, Liu JY, Chen Z, Li G, Zheng ZJ, Qiu SQ, Luo J, Ye CJ, Zhu SY, Zhong NS; China Medical Treatment Expert Group for CoVid-19. Clinical Characteristics of Coronavirus Disease 2019 in China. *N Engl J Med* 2020; **382**: 1708-1720 [PMID: [32109013](https://pubmed.ncbi.nlm.nih.gov/32109013/) DOI: [10.1056/NEJMoa2002032](https://doi.org/10.1056/NEJMoa2002032)]
- 4 Chung M, Bernheim A, Mei X, Zhang N, Huang M, Zeng X, Cui J, Xu W, Yang Y, Fayad ZA, Jacobi A, Li K, Li S, Shan H. CT Imaging Features of 2019 Novel Coronavirus (2019-nCoV). *Radiology* 2020; **295**: 202-207 [PMID: [32017661](https://pubmed.ncbi.nlm.nih.gov/32017661/) DOI: [10.1148/radiol.202002030](https://doi.org/10.1148/radiol.202002030)]
- 5 Huang C, Wang Y, Li X, Ren L, Zhao J, Hu Y, Zhang L, Fan G, Xu J, Gu X, Cheng Z, Yu T, Xia J, Wei Y, Wu W, Xie X, Yin W, Li H, Liu M, Xiao Y, Gao H, Guo L, Xie J, Wang G, Jiang R, Gao Z, Jin Q, Wang J, Cao B. Clinical features of patients infected with 2019 novel coronavirus in Wuhan, China. *Lancet* 2020; **395**: 497-506 [PMID: [31986264](https://pubmed.ncbi.nlm.nih.gov/31986264/) DOI: [10.1016/S0140-6736\(20\)30183-5](https://doi.org/10.1016/S0140-6736(20)30183-5)]



Published by **Baishideng Publishing Group Inc**
7041 Koll Center Parkway, Suite 160, Pleasanton, CA 94566, USA

Telephone: +1-925-3991568

E-mail: bpgoffice@wjgnet.com

Help Desk: <https://www.f6publishing.com/helpdesk>

<https://www.wjgnet.com>

