

World Journal of *Clinical Cases*

World J Clin Cases 2020 December 26; 8(24): 6213-6545



MINIREVIEWS

- 6213 Role of gut microbiome in regulating the effectiveness of metformin in reducing colorectal cancer in type 2 diabetes

Huang QY, Yao F, Zhou CR, Huang XY, Wang Q, Long H, Wu QM

ORIGINAL ARTICLE

Retrospective Cohort Study

- 6229 Impact factors of lymph node retrieval on survival in locally advanced rectal cancer with neoadjuvant therapy

Mei SW, Liu Z, Wang Z, Pei W, Wei FZ, Chen JN, Wang ZJ, Shen HY, Li J, Zhao FQ, Wang XS, Liu Q

Retrospective Study

- 6243 Three-year follow-up of Coats disease treated with conbercept and 532-nm laser photocoagulation

Jiang L, Qin B, Luo XL, Cao H, Deng TM, Yang MM, Meng T, Yang HQ

- 6252 Virus load and virus shedding of SARS-CoV-2 and their impact on patient outcomes

Chen PF, Yu XX, Liu YP, Ren D, Shen M, Huang BS, Gao JL, Huang ZY, Wu M, Wang WY, Chen L, Shi X, Wang ZQ, Liu YX, Liu L, Liu Y

- 6264 Risk factors for *de novo* hepatitis B during solid cancer treatment

Sugimoto R, Furukawa M, Senju T, Aratake Y, Shimokawa M, Tanaka Y, Inada H, Noguchi T, Lee L, Miki M, Maruyama Y, Hashimoto R, Hisano T

- 6274 Cause analysis and reoperation effect of failure and recurrence after epiblepharon correction in children

Wang Y, Zhang Y, Tian N

Clinical Trials Study

- 6282 Effects of different acupuncture methods combined with routine rehabilitation on gait of stroke patients

Lou YT, Yang JJ, Ma YF, Zhen XC

Observational Study

- 6296 Application of endoscopic submucosal dissection in duodenal space-occupying lesions

Li XY, Ji KY, Qu YH, Zheng JJ, Guo YJ, Zhang CP, Zhang KP

- 6306 Early renal injury indicators can help evaluate renal injury in patients with chronic hepatitis B with long-term nucleos(t)ide therapy

Ji TT, Tan N, Lu HY, Xu XY, Yu YY

Prospective Study

- 6315** Neoadjuvant chemoradiotherapy plus surgery in the treatment of potentially resectable thoracic esophageal squamous cell carcinoma
Yan MH, Hou XB, Cai BN, Qu BL, Dai XK, Liu F

CASE REPORT

- 6322** Uterine rupture in patients with a history of multiple curettages: Two case reports
Deng MF, Zhang XD, Zhang QF, Liu J
- 6330** Pleural effusion and ascites in extrarenal lymphangiectasia caused by post-biopsy hematoma: A case report
Lin QZ, Wang HE, Wei D, Bao YF, Li H, Wang T
- 6337** Eighty-year-old man with rare chronic neutrophilic leukemia caused by CSF3R T618I mutation: A case report and review of literature
Li YP, Chen N, Ye XM, Xia YS
- 6346** Sigmoid colon duplication with ectopic immature renal tissue in an adult: A case report
Namgung H
- 6353** Paraplegia from spinal intramedullary tuberculosis: A case report
Qu LM, Wu D, Guo L, Yu JL
- 6358** Confocal laser endomicroscopy distinguishing benign and malignant gallbladder polyps during choledochoscopic gallbladder-preserving polypectomy: A case report
Tang BF, Dang T, Wang QH, Chang ZH, Han WJ
- 6364** Sclerosing stromal tumor of the ovary with masculinization, Meig's syndrome and CA125 elevation in an adolescent girl: A case report
Chen Q, Chen YH, Tang HY, Shen YM, Tan X
- 6373** Primary pulmonary malignant melanoma diagnosed with percutaneous biopsy tissue: A case report
Xi JM, Wen H, Yan XB, Huang J
- 6380** SRY-negative 45,X/46,XY adult male with complete masculinization and infertility: A case report and review of literature
Wu YH, Sun KN, Bao H, Chen YJ
- 6389** Refractory case of ulcerative colitis with idiopathic thrombocytopenic purpura successfully treated by Janus kinase inhibitor tofacitinib: A case report
Komeda Y, Sakurai T, Sakai K, Morita Y, Hashimoto A, Nagai T, Hagiwara S, Matsumura I, Nishio K, Kudo M
- 6396** Immunotherapies application in active stage of systemic lupus erythematosus in pregnancy: A case report and review of literature
Xiong ZH, Cao XS, Guan HL, Zheng HL

- 6408** Minimally invasive maxillary sinus augmentation with simultaneous implantation on an elderly patient: A case report
Yang S, Yu W, Zhang J, Zhou Z, Meng F, Wang J, Shi R, Zhou YM, Zhao J
- 6418** Congenital nephrogenic diabetes insipidus due to the mutation in *AVPR2* (c.541C>T) in a neonate: A case report
Lin FT, Li J, Xu BL, Yang XX, Wang F
- 6425** Primary gastric melanoma in a young woman: A case report
Long GJ, Ou WT, Lin L, Zhou CJ
- 6432** Extreme venous letting and cupping resulting in life-threatening anemia and acute myocardial infarction: A case report
Jang AY, Suh SY
- 6437** Novel conservative treatment for peritoneal dialysis-related hydrothorax: Two case reports
Dai BB, Lin BD, Yang LY, Wan JX, Pan YB
- 6444** Clinical characteristics of pulmonary cryptococcosis coexisting with lung adenocarcinoma: Three case reports
Zheng GX, Tang HJ, Huang ZP, Pan HL, Wei HY, Bai J
- 6450** Fracture of the scapular neck combined with rotator cuff tear: A case report
Chen L, Liu CL, Wu P
- 6456** Synchronous colonic mucosa-associated lymphoid tissue lymphoma found after surgery for adenocarcinoma: A case report and review of literature
Li JJ, Chen BC, Dong J, Chen Y, Chen YW
- 6465** Novel mutation in the *ASXL3* gene in a Chinese boy with microcephaly and speech impairment: A case report
Li JR, Huang Z, Lu Y, Ji QY, Jiang MY, Yang F
- 6473** Recurrent thrombosis in the lower extremities after thrombectomy in a patient with polycythemia vera: A case report
Jiang BP, Cheng GB, Hu Q, Wu JW, Li XY, Liao S, Wu SY, Lu W
- 6480** Status epilepticus as an initial manifestation of hepatic encephalopathy: A case report
Cui B, Wei L, Sun LY, Qu W, Zeng ZG, Liu Y, Zhu ZJ
- 6487** Delayed diagnosis of prosopagnosia following a hemorrhagic stroke in an elderly man: A case report
Yuan Y, Huang F, Gao ZH, Cai WC, Xiao JX, Yang YE, Zhu PL
- 6499** Oral myiasis after cerebral infarction in an elderly male patient from southern China: A case report
Zhang TZ, Jiang Y, Luo XT, Ling R, Wang JW
- 6504** Rare case of drain-site hernia after laparoscopic surgery and a novel strategy of prevention: A case report
Gao X, Chen Q, Wang C, Yu YY, Yang L, Zhou ZG

- 6511** Extracorporeal shock wave therapy treatment of painful hematoma in the calf: A case report
Jung JW, Kim HS, Yang JH, Lee KH, Park SB
- 6517** Takotsubo cardiomyopathy associated with bronchoscopic operation: A case report
Wu BF, Shi JR, Zheng LR
- 6524** Idiopathic adulthood ductopenia with elevated transaminase only: A case report
Zhang XC, Wang D, Li X, Hu YL, Wang C
- 6529** Successful endovascular treatment with long-term antibiotic therapy for infectious pseudoaneurysm due to *Klebsiella pneumoniae*: A case report
Wang TH, Zhao JC, Huang B, Wang JR, Yuan D
- 6537** Primary duodenal tuberculosis misdiagnosed as tumor by imaging examination: A case report
Zhang Y, Shi XJ, Zhang XC, Zhao XJ, Li JX, Wang LH, Xie CE, Liu YY, Wang YL

ABOUT COVER

Peer-Reviewer of *World Journal of Clinical Cases*, Dr. Adonis Protopapas is a gastroenterology Resident at the first Propaedeutic Department of Internal Medicine of the Aristotle University of Thessaloniki (Greece), located at the A.H.E.P.A Hospital. He earned his Bachelor's degree in 2015 from the Democritus University of Thrace, followed by three Master's of Science degrees, with specializations in clinic pharmacology, medical research methodology, and healthcare management. His research interests are mainly focused on the area of hepatology, although he also participates in various projects related to endoscopy and inflammatory bowel disease. He is particularly fascinated by research on cirrhosis and its complications. (L-Editor: Filipodia)

AIMS AND SCOPE

The primary aim of *World Journal of Clinical Cases* (*WJCC*, *World J Clin Cases*) is to provide scholars and readers from various fields of clinical medicine with a platform to publish high-quality clinical research articles and communicate their research findings online.

WJCC mainly publishes articles reporting research results and findings obtained in the field of clinical medicine and covering a wide range of topics, including case control studies, retrospective cohort studies, retrospective studies, clinical trials studies, observational studies, prospective studies, randomized controlled trials, randomized clinical trials, systematic reviews, meta-analysis, and case reports.

INDEXING/ABSTRACTING

The *WJCC* is now indexed in Science Citation Index Expanded (also known as SciSearch®), Journal Citation Reports/Science Edition, PubMed, and PubMed Central. The 2020 Edition of Journal Citation Reports® cites the 2019 impact factor (IF) for *WJCC* as 1.013; IF without journal self cites: 0.991; Ranking: 120 among 165 journals in medicine, general and internal; and Quartile category: Q3.

RESPONSIBLE EDITORS FOR THIS ISSUE

Production Editor: Ji-Hong Liu; Production Department Director: Xiang Li; Editorial Office Director: Jin-Lai Wang.

NAME OF JOURNAL

World Journal of Clinical Cases

ISSN

ISSN 2307-8960 (online)

LAUNCH DATE

April 16, 2013

FREQUENCY

Semimonthly

EDITORS-IN-CHIEF

Dennis A Bloomfield, Sandro Vento, Bao-gan Peng

EDITORIAL BOARD MEMBERS

<https://www.wjgnet.com/2307-8960/editorialboard.htm>

PUBLICATION DATE

December 26, 2020

COPYRIGHT

© 2020 Baishideng Publishing Group Inc

INSTRUCTIONS TO AUTHORS

<https://www.wjgnet.com/bpg/gerinfo/204>

GUIDELINES FOR ETHICS DOCUMENTS

<https://www.wjgnet.com/bpg/GerInfo/287>

GUIDELINES FOR NON-NATIVE SPEAKERS OF ENGLISH

<https://www.wjgnet.com/bpg/gerinfo/240>

PUBLICATION ETHICS

<https://www.wjgnet.com/bpg/GerInfo/288>

PUBLICATION MISCONDUCT

<https://www.wjgnet.com/bpg/gerinfo/208>

ARTICLE PROCESSING CHARGE

<https://www.wjgnet.com/bpg/gerinfo/242>

STEPS FOR SUBMITTING MANUSCRIPTS

<https://www.wjgnet.com/bpg/GerInfo/239>

ONLINE SUBMISSION

<https://www.f6publishing.com>

Refractory case of ulcerative colitis with idiopathic thrombocytopenic purpura successfully treated by Janus kinase inhibitor tofacitinib: A case report

Yoriaki Komeda, Toshiharu Sakurai, Kazuko Sakai, Yasuyoshi Morita, Arito Hashimoto, Tomoyuki Nagai, Satoru Hagiwara, Itaru Matsumura, Kazuto Nishio, Masatoshi Kudo

ORCID number: Yoriaki Komeda 0000-0002-0068-8461; Toshiharu Sakurai 0000-0002-7798-6862; Kazuko Sakai 0000-0003-1822-2720; Yasuyoshi Morita 0000-0001-7274-8649; Arito Hashimoto 0000-0002-3820-2981; Tomoyuki Nagai 0000-0001-5563-3233; Satoru Hagiwara 0000-0002-3412-4701; Itaru Matsumura 0000-0003-2818-4270; Kazuto Nishio 0000-0002-8275-0846; Masatoshi Kudo 0000-0002-4102-3474.

Author contributions: Komeda K and Sakurai T wrote the manuscript. Komeda K, Sakurai T, Morita Y and Hashimoto A was the patient's doctor in charge and was responsible for collecting medical history. Komeda Y, Sakurai T, Sakai K, Nagai T, Hagiwara S, Matsumura I, Nishio K and Kudo M contributed data analysis and interpretation of data.

Supported by JSPS KAKENHI, No. 17K09396, No. 17H06404, and No. 20K08368.

Informed consent statement: Written informed consent was obtained from the patient for publication of this report and any accompanying images. The study was approved by the relevant institutional review boards (#28-

Yoriaki Komeda, Toshiharu Sakurai, Arito Hashimoto, Tomoyuki Nagai, Satoru Hagiwara, Masatoshi Kudo, Department of Gastroenterology and Hepatology, Kindai University Faculty of Medicine, Osaka 589-8511, Japan

Kazuko Sakai, Kazuto Nishio, Department of Genome Biology, Kindai University Faculty of Medicine, Osaka 589-8511, Japan

Yasuyoshi Morita, Itaru Matsumura, Department of Hematology and Rheumatology, Kindai University Faculty of Medicine, Osaka 589-8511, Japan

Corresponding author: Toshiharu Sakurai, MD, PhD, Assistant Professor, Senior Lecturer, Department of Gastroenterology and Hepatology, Kindai University Faculty of Medicine, 377-2 Ohno-Higashi, Osaka 589-8511, Japan. sakurai@med.kindai.ac.jp

Abstract

BACKGROUND

Concomitant ulcerative colitis (UC) and idiopathic thrombocytopenic purpura (ITP) is a rare phenomenon. The management of UC with ITP can be challenging, since a decreased platelet count augments UC.

CASE SUMMARY

A 24-year-old man with UC and steroid-resistant ITP experienced UC flare. Although continuous infusion of cyclosporine was initiated, UC did not improve. The administration of tofacitinib subsequently led to the induction of remission. The patient has maintained remission of UC and ITP for over one year on tofacitinib treatment. Whole transcriptomic sequencing was performed for inflamed rectal mucosae obtained before and after the initiation of Janus kinase (JAK) inhibitor, suggesting that distinct molecular signatures seemed to be regulated by JAK inhibitors and other conventional therapies including tumor necrosis factor blockers.

CONCLUSION

Tofacitinib should be considered in refractory cases of UC with ITP.

Key Words: Ulcerative colitis; Idiopathic thrombocytopenic purpura; Tofacitinib; Whole

224).

Conflict-of-interest statement: The authors declare no conflicts of interest.

CARE Checklist (2016) statement:

The authors have read the CARE Checklist (2016), and the manuscript was prepared and revised according to the CARE Checklist (2016).

Open-Access: This article is an open-access article which was selected by an in-house editor and fully peer-reviewed by external reviewers. It is distributed in accordance with the Creative Commons Attribution Non Commercial (CC BY-NC 4.0) license, which permits others to distribute, remix, adapt, build upon this work non-commercially, and license their derivative works on different terms, provided the original work is properly cited and the use is non-commercial. See: <http://creativecommons.org/licenses/by-nc/4.0/>

Manuscript source: Unsolicited manuscript

Specialty type: Gastroenterology and hepatology

Country/Territory of origin: Japan

Peer-review report's scientific quality classification

Grade A (Excellent): 0
Grade B (Very good): B
Grade C (Good): C
Grade D (Fair): 0
Grade E (Poor): 0

Received: July 27, 2020

Peer-review started: July 27, 2020

First decision: August 8, 2020

Revised: October 29, 2020

Accepted: November 4, 2020

Article in press: November 4, 2020

Published online: December 26, 2020

P-Reviewer: Fu TL, Suppiah A

S-Editor: Liu M

L-Editor: A

P-Editor: Ma YJ

transcriptome analysis; Case report; Predictive biomarker

©The Author(s) 2020. Published by Baishideng Publishing Group Inc. All rights reserved.

Core Tip: We herein report a refractory case of ulcerative colitis associated with idiopathic thrombocytopenic purpura successfully treated with tofacitinib. The relationship between these two disease entities underscore treatment implications, given their potentially shared immunological pathway and responses to similar medications. To investigate changes in gene signatures during tofacitinib therapy, whole transcriptomic sequencing was performed for inflamed rectal mucosae obtained before and after the initiation of Janus kinase (JAK) inhibitor. Distinct molecular signatures seemed to be regulated by JAK inhibition and tumor necrosis factor blockade, suggesting that the identification of gene sets may be able to predict therapeutic responses to medications.

Citation: Komeda Y, Sakurai T, Sakai K, Morita Y, Hashimoto A, Nagai T, Hagiwara S, Matsumura I, Nishio K, Kudo M. Refractory case of ulcerative colitis with idiopathic thrombocytopenic purpura successfully treated by Janus kinase inhibitor tofacitinib: A case report. *World J Clin Cases* 2020; 8(24): 6389-6395

URL: <https://www.wjgnet.com/2307-8960/full/v8/i24/6389.htm>

DOI: <https://dx.doi.org/10.12998/wjcc.v8.i24.6389>

INTRODUCTION

Inflammatory bowel disease (IBD), including ulcerative colitis (UC) and Crohn's disease, is characterized by chronic relapsing inflammation of the gastrointestinal tract. The precise etiology of UC remains unknown. It has been associated with extraintestinal manifestations, including musculoskeletal diseases, mucocutaneous diseases, and hepatobiliary diseases^[1,2]. The association between UC and idiopathic thrombocytopenic purpura (ITP) has also been described. The proposed pathogenesis of the concurrence of UC and ITP is antigenic mimicry between luminal antigens and platelet surface antigens^[3]. The concurrence of UC with ITP adds complexity to the clinical course, since the number of bloody bowel movements is an important criterion for assessing the disease severity of UC. In addition, treatment of underlying UC flare can be challenging, since a decreased platelet count worsens the UC symptom, hematochezia. While treatment with anti-tumor necrosis factor (TNF) agents and cyclosporin as well as colectomy are acceptable options in refractory cases of UC associated with ITP^[4-6], there are currently no recommended therapeutic strategies. The Janus kinase (JAK) inhibitor tofacitinib was recently introduced for the treatment of refractory UC, but its effectiveness has not been determined for UC with ITP. We herein report a refractory case of UC associated with ITP successfully treated with tofacitinib.

CASE PRESENTATION

Chief complaints

A 24-year-old Japanese male presented to the Gastroenterology Department of our hospital with diarrhea and hematochezia.

History of present illness

The patient was diagnosed with UC in 2015. At the onset, the disease was localized to the entire colon, and the patient was initially treated with mesalazine (3600 mg/d) for one year. In 2016, following a relapse, he was hospitalized. He then presented with anemia (hemoglobin 4 g/L) and thrombocytopenia (platelet count $5 \times 10^4/\mu\text{L}$). Further examinations, including bone marrow puncture, led to a diagnosis of concurrence of UC and ITP. The patient then started on prednisolone (30 mg/d) and achieved clinical and endoscopic remission for UC. However, since ITP was resistant to steroid and



immunoglobulin treatments, he started oral cyclosporine and achieved remission for ITP. Thereafter, the patient maintained overall good health on oral mesalazine, prednisolone (5 mg/d), and cyclosporin (150 mg/d). His history was unremarkable. His family history was negative for hematological disease or inflammatory bowel disease.

In April 2019, the patient experienced a flare of UC characterized by six bowel movements/day of liquid and bloody stool and abdominal pain. The partial Mayo index score was 7, indicating severe disease. Laboratory exams revealed anemia but not thrombocytopenia (Table 1). After the exclusion of intestinal infections, oral cyclosporine initially changed to a continuous infusion of cyclosporine to control the blood concentration strictly. The patient reported little clinical benefit. He then started tofacitinib and achieved clinical remission (Figure 1A). The patient underwent colonoscopy in September 2019, which showed endoscopic remission (Figure 1B). Prednisolone was stopped, and the patient has maintained remission in UC and ITP for over one year on mesalazine and tofacitinib.

History of past illness

Past history is unremarkable except for UC and ITP.

Personal and family history

Personal and family history is unremarkable.

Physical examination

The patient did not have a fever. Physical examination showed slight tenderness in the left lower abdomen.

Laboratory examinations

Laboratory exams revealed anemia but not thrombocytopenia (Table 1).

Imaging examinations

To further analyze the molecular mechanism underlying tofacitinib therapy, whole transcriptomic sequencing was performed for inflamed rectal mucosae obtained before and after the initiation of JAK inhibitor (Supplementary Material). Compared with the gene expression before tofacitinib treatment, the top 10 downregulated genes during tofacitinib treatment were *REG1A*, *REG1B*, *REG3A*, *SPINK4*, *DUOXA2*, *TNIP3*, *DEFB4A*, *SAA2*, *CXCL5*, and *CXCL1*. In contrast, the top 10 upregulated genes after the initiation of tofacitinib treatment were *HMGS2*, *AQP8*, *SLC6A19*, *MT1H*, *UGT2A3*, *CLDN8*, *MT1M*, *SLC51A*, *PRKG2*, and *MT1G*.

FINAL DIAGNOSIS

A refractory case of ulcerative colitis with idiopathic thrombocytopenic purpura.

TREATMENT

The patient was successfully treated with tofacitinib.

OUTCOME AND FOLLOW-UP

The patient has maintained remission in UC and ITP for over one year on mesalazine and tofacitinib.

DISCUSSION

Major concerns of tofacitinib include the risk of hematologic toxicity, such as pancytopenia, agranulocytosis, and thrombocytopenia. The patient has maintained corticosteroid-free remission for UC and ITP for one year on tofacitinib treatment. The platelet count remained within the normal range despite stopping specific treatment for ITP. The relationship between these two entities underscore treatment implications,

Table 1 Serum laboratory values on before and after administration of tofacitinib

Laboratory test	Before tofacitinib	After tofacitinib
Albumin	3.6 g/dL	4.8 g/dL
C-reactive protein	3.9 mg/dL	0.0 mg/dL
White blood cell count	11200/ μ L	4500/ μ L
Erythrocyte sedimentation rate	20 mm	10 mm
Red blood cell count	413×10^4 / μ L	448×10^4 / μ L
Hemoglobin	12.4 g/dL	14.3 g/dL
Hematocrit	36.5%	41.7%
Platelet count	14.5×10^4 / μ L	25.2×10^4 / μ L

After Tofacitinib: 6 mo after the initiation of tofacitinib.

given their potentially shared immunological pathway and responses to similar medications. To our knowledge, this study is the first to report a UC patient with ITP who was successfully treated with tofacitinib.

REG1A and *REG1B* are upregulated in human colonic mucosa with UC^[7]. IL-22 stimulation of *REG1A* is based on the presence of IL-activatable elements of the *REG1A* promoter and may be mediated through STAT3 tyrosine phosphorylation, located downstream of the JAK signaling pathway^[8]. Consistently, the expression of these genes was substantially reduced through JAK inhibition in our case. Hyams *et al*^[9] reported that 33 genes were differentially expressed in the rectum of patients with moderate-to-severe UC who did and did not achieve corticosteroid-free remission after conventional treatments including anti-TNF therapy. The mucosal expression of *DEFB4A*, *KRT6B*, *SPRR1B*, *TCN1*, and *SAA4* was high in our case, a responder to tofacitinib, while the expression was reduced in responders to conventional UC treatments, including anti-TNF therapy, compared with non-responders^[9]. The expression of *CHP2*, *GUCA2A*, *CA1*, *SLC26A2*, *PCK1*, *GLRA2*, *HAVCR1*, and *ABCG2* was low in our case that was successfully treated with tofacitinib and high in responders to conventional UC treatments^[9]. In responders to tofacitinib, the expression of genes associated with resistance to conventional UC therapies was shown to be upregulated. The opposite trend in the signatures of genes related to the therapeutic response might be due to different mechanisms of action between JAK inhibitors and other therapies. Based on the findings of the present patient and another patient treated with anti-TNF antibodies who had RNA sequencing data, unsupervised hierarchical clustering of the gene panel and t-distributed Stochastic Neighbor Embedding visualization were defined (Figure 2). Consistently, distinct molecular signatures seemed to be regulated by JAK inhibition and TNF blockade, suggesting that the identification of gene sets may be able to predict therapeutic responses to medications. We have no data regarding biomarkers predicting the response to JAK inhibitors at present. Further investigations will be required to establish predictive biomarkers and personalized therapeutic strategies in IBD patients.

CONCLUSION

Tofacitinib should be considered in refractory cases of UC with ITP.

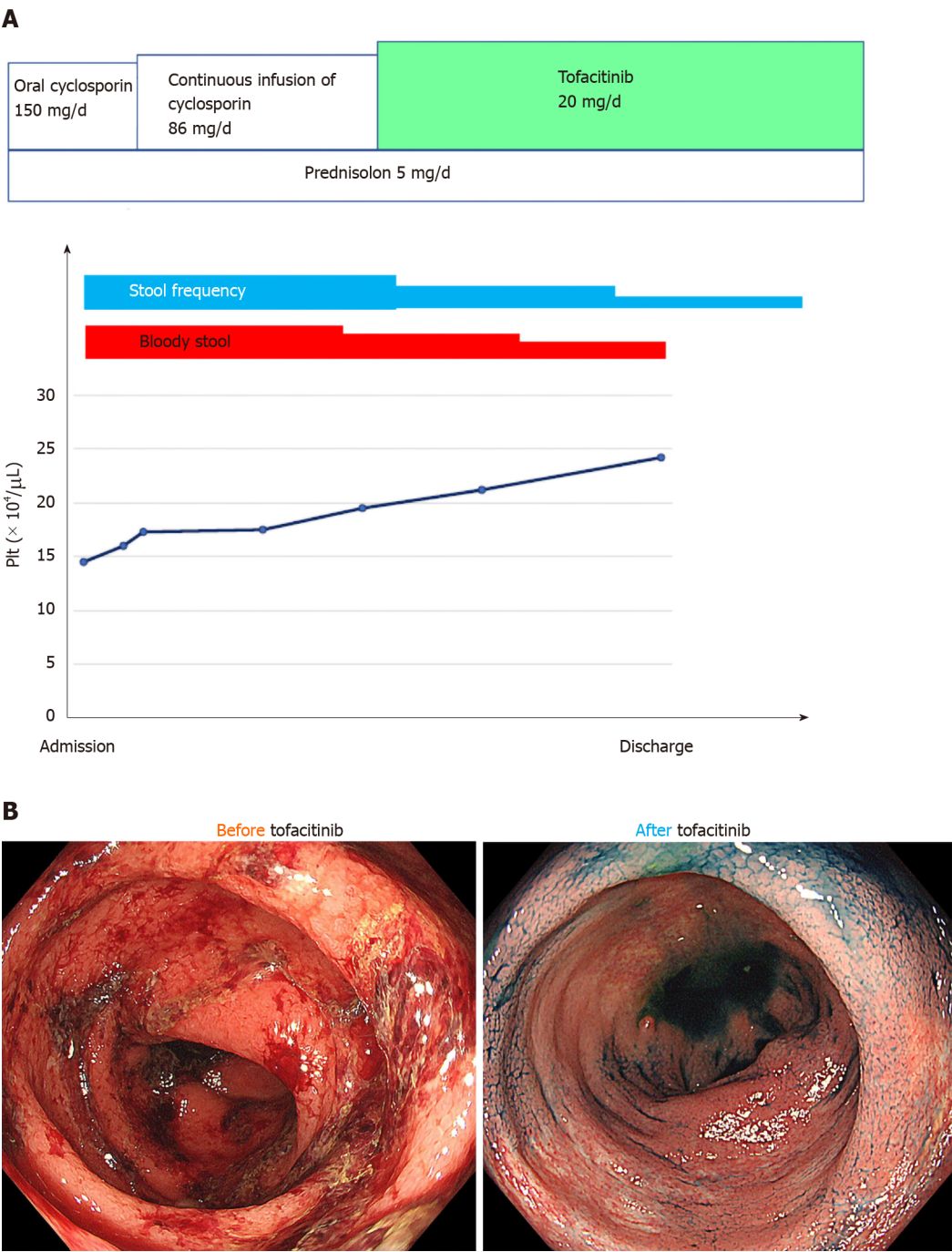


Figure 1 The administration of tofacitinib subsequently led to the induction of remission. A: The clinical course before and after tofacitinib therapy; B: Endoscopic aspects of the colon before and after tofacitinib treatment. There are spontaneous bleeding and ulcerations before tofacitinib treatment, and they improved after tofacitinib treatment.

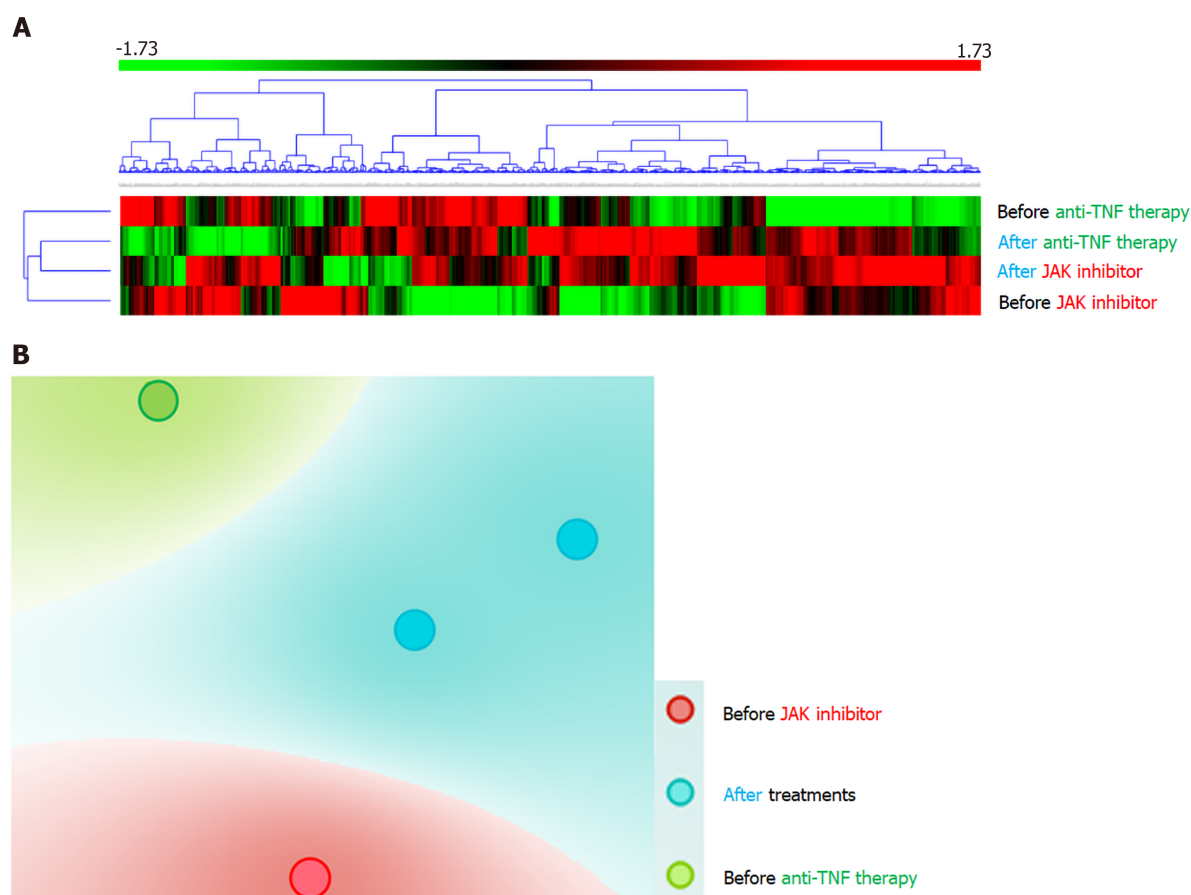


Figure 2 Distinct molecular signatures seemed to be regulated by Janus kinase

REFERENCES

- Greenstein AJ, Janowitz HD, Sachar DB. The extra-intestinal complications of Crohn's disease and ulcerative colitis: a study of 700 patients. *Medicine (Baltimore)* 1976; **55**: 401-412 [PMID: 957999 DOI: 10.1097/00005792-197609000-00004]
- Veloso FT, Carvalho J, Magro F. Immune-related systemic manifestations of inflammatory bowel disease. A prospective study of 792 patients. *J Clin Gastroenterol* 1996; **23**: 29-34 [PMID: 8835896 DOI: 10.1097/00004836-199607000-00009]
- Chandra S, Finn S, Obah E. Immune thrombocytopenic purpura in ulcerative colitis: a case report and systematic review. *J Community Hosp Intern Med Perspect* 2014; **4** [PMID: 24765254 DOI: 10.3402/jchimp.v4.23386]
- Hisada T, Miyamae Y, Mizuide M, Shibusawa N, Iida T, Masuo T, Okada S, Sagawa T, Ishizuka T, Kusano M, Mori M. Acute thrombocytopenia associated with preexisting ulcerative colitis successfully treated with colectomy. *Intern Med* 2006; **45**: 87-91 [PMID: 16484745 DOI: 10.2169/internalmedicine.45.1465]
- Mares WG, Gerver J, Masclee AA, Pierik M. Anti-TNF treatment of ulcerative colitis associated with idiopathic thrombocytopenic purpura. *Inflamm Bowel Dis* 2011; **17**: 864-865 [PMID: 20848499 DOI: 10.1002/ibd.21327]
- Iwasa T, Nakamura K, Ihara E, Aso A, Ito T. The Effective Treatment with Cyclosporine of a Ulcerative Colitis Patient with Concurrent Idiopathic Thrombocytopenic Purpura Who Subsequently Developed Spontaneous Pneumomediastinum. *Intern Med* 2017; **56**: 1331-1337 [PMID: 28566594 DOI: 10.2169/internalmedicine.56.7909]
- Tsuchida C, Sakuramoto-Tsuchida S, Taked M, Itaya-Hironaka A, Yamauchi A, Misu M, Shobatake R, Uchiyama T, Makino M, Pujol-Autonell I, Vives-Pi M, Ohbayashi C, Takasawa S. Expression of *REG* family genes in human inflammatory bowel diseases and its regulation. *Biochem Biophys Res* 2017; **12**: 198-205 [PMID: 29090282 DOI: 10.1016/j.bbrep.2017.10.003]
- Sekikawa A, Fukui H, Suzuki K, Karibe T, Fujii S, Ichikawa K, Tomita S, Imura J, Shiratori K, Chiba T, Fujimori T. Involvement of the IL-22/REG Ialpha axis in ulcerative colitis. *Lab Invest* 2010; **90**: 496-505 [PMID: 20065946 DOI: 10.1038/Labinvest.2009.147]
- Hyams JS, Davis Thomas S, Gotman N, Haberman Y, Karns R, Schirmer M, Mo A, Mack DR, Boyle B, Griffiths AM, LeLeiko NS, Sauer CG, Keljo DJ, Markowitz J, Baker SS, Rosh J, Baldassano RN,

Patel A, Pfefferkorn M, Otley A, Heyman M, Noe J, Oliva-Hemker M, Rufo PA, Strople J, Ziring D, Guthery SL, Sudel B, Benkov K, Wali P, Moulton D, Evans J, Kappelman MD, Marquis MA, Sylvester FA, Collins MH, Venkateswaran S, Dubinsky M, Tangpricha V, Spada KL, Saul B, Wang J, Serrano J, Hommel K, Marigorta UM, Gibson G, Xavier RJ, Kugathasan S, Walters T, Denson LA. Clinical and biological predictors of response to standardised paediatric colitis therapy (PROTECT): a multicentre inception cohort study. *Lancet* 2019; **393**: 1708-1720 [PMID: [30935734](#) DOI: [10.1016/S0140-6736\(18\)32592-3](#)]



Published by **Baishideng Publishing Group Inc**
7041 Koll Center Parkway, Suite 160, Pleasanton, CA 94566, USA

Telephone: +1-925-3991568

E-mail: bpgoffice@wjgnet.com

Help Desk: <https://www.f6publishing.com/helpdesk>

<https://www.wjgnet.com>

