

World Journal of *Clinical Cases*

World J Clin Cases 2020 February 6; 8(3): 487-651





REVIEW

- 487 Comprehensive review into the challenges of gastrointestinal tumors in the Gulf and Levant countries
Rare Tumors GI Group, Farhat F, Farsi AA, Mohieldin A, Bahrani BA, Sbaity E, Jaffar H, Kattan J, Rasul K, Saad K, Assi T, Morsi WE, Abood RA

CLINICAL AND TRANSLATIONAL RESEARCH

- 504 Novel zinc alloys for biodegradable surgical staples
Amano H, Miyake K, Hinoki A, Yokota K, Kinoshita F, Nakazawa A, Tanaka Y, Seto Y, Uchida H

CASE REPORT

- 517 Can cyclin-dependent kinase 4/6 inhibitors convert inoperable breast cancer relapse to operability? A case report
Palleschi M, Maltoni R, Barzotti E, Melegari E, Curcio A, Cecconetto L, Sarti S, Manunta S, Rocca A
- 522 Radiation recall dermatitis with dabrafenib and trametinib: A case report
Yilmaz M, Celik U, Hascicek S
- 527 Isolated vaginal metastasis from stage I colon cancer: A case report
Kwon SK, Yu CS, Lee SW, Kim J, Song I, Lee JL, Kim CW, Yoon YS, Park IJ, Lim SB, Kim JC
- 535 Ruptured splenic peliosis in a patient with no comorbidity: A case report
Rhu J, Cho J
- 540 Successful kidney transplantation from an expanded criteria donor with long-term extracorporeal membrane oxygenation treatment: A case report
Seo HW, Lee S, Lee HY, Park SC, Chung BH, Yang CW, Ban TH
- 546 Boarding issue in a commercial flight for patients with cavitary pulmonary tuberculosis: A case report
Jo W, Pak C, Jegal Y, Seo KW
- 552 Cytomegalovirus ileo-pancolitis presenting as toxic megacolon in an immunocompetent patient: A case report
Cho JH, Choi JH
- 560 Successful treatment of adult-onset still disease caused by pulmonary infection-associated hemophagocytic lymphohistiocytosis: A case report
Wang G, Jin XR, Jiang DX

- 568** Complex liver retransplantation to treat graft loss due to long-term biliary tract complication after liver transplantation: A case report
Li J, Guo QJ, Jiang WT, Zheng H, Shen ZY
- 577** Peutz-Jeghers syndrome with mesenteric fibromatosis: A case report and review of literature
Cai HJ, Wang H, Cao N, Wang W, Sun XX, Huang B
- 587** Cutaneous nodules and a novel *GNAS* mutation in a Chinese boy with pseudohypoparathyroidism type Ia: A case report and review of literature
Li YL, Han T, Hong F
- 594** Complete response to trastuzumab and chemotherapy in recurrent urothelial bladder carcinoma with *HER2* gene amplification: A case report
Jiang Q, Xie MX, Zhang XC
- 600** Large cutaneous epithelioid angiomatous nodules in a patient with nephrotic syndrome: A case report
Cheng DJ, Zheng XY, Tang SF
- 606** Clinicopathologic characteristics of prostatic stromal sarcoma with rhabdoid features: A case report
Li RG, Huang J
- 614** Erdheim-Chester disease with asymmetric talus involvement: A case report
Xia Q, Tao C, Zhu KW, Zhong WY, Li PL, Jiang Y, Mao MZ
- 624** Camrelizumab (SHR-1210) leading to reactive capillary hemangioma in the gingiva: A case report
Yu Q, Wang WX
- 630** Combined surgical and interventional treatment of tandem carotid artery and middle cerebral artery embolus: A case report
Zhang M, Hao JH, Lin K, Cui QK, Zhang LY
- 638** Sternal Hodgkin's lymphoma: A case report and review of literature
Yin YY, Zhao N, Yang B, Xin H
- 645** Esophageal tuberculosis complicated with intestinal tuberculosis: A case report
Mao L, Zhou XT, Li JP, Li J, Wang F, Ma HM, Su XL, Wang X

ABOUT COVER

Editorial Board Member of *World Journal of Clinical Cases*, Valerio D'Orazi, MD, PhD, Professor, Department of Surgical Sciences, Sapienza University of Rome, Rome 00161, Italy

AIMS AND SCOPE

The primary aim of *World Journal of Clinical Cases* (WJCC, *World J Clin Cases*) is to provide scholars and readers from various fields of clinical medicine with a platform to publish high-quality clinical research articles and communicate their research findings online.

WJCC mainly publishes articles reporting research results and findings obtained in the field of clinical medicine and covering a wide range of topics, including case control studies, retrospective cohort studies, retrospective studies, clinical trials studies, observational studies, prospective studies, randomized controlled trials, randomized clinical trials, systematic reviews, meta-analysis, and case reports.

INDEXING/ABSTRACTING

The WJCC is now indexed in PubMed, PubMed Central, Science Citation Index Expanded (also known as SciSearch®), and Journal Citation Reports/Science Edition. The 2019 Edition of Journal Citation Reports cites the 2018 impact factor for WJCC as 1.153 (5-year impact factor: N/A), ranking WJCC as 99 among 160 journals in Medicine, General and Internal (quartile in category Q3).

RESPONSIBLE EDITORS FOR THIS ISSUE

Responsible Electronic Editor: *Yan-Xia Xing*

Proofing Production Department Director: *Xiang Li*

NAME OF JOURNAL

World Journal of Clinical Cases

ISSN

ISSN 2307-8960 (online)

LAUNCH DATE

April 16, 2013

FREQUENCY

Semimonthly

EDITORS-IN-CHIEF

Dennis A Bloomfield, Bao-Gan Peng, Sandro Vento

EDITORIAL BOARD MEMBERS

<https://www.wjnet.com/2307-8960/editorialboard.htm>

EDITORIAL OFFICE

Jin-Lei Wang, Director

PUBLICATION DATE

February 6, 2020

COPYRIGHT

© 2020 Baishideng Publishing Group Inc

INSTRUCTIONS TO AUTHORS

<https://www.wjnet.com/bpg/gerinfo/204>

GUIDELINES FOR ETHICS DOCUMENTS

<https://www.wjnet.com/bpg/GerInfo/287>

GUIDELINES FOR NON-NATIVE SPEAKERS OF ENGLISH

<https://www.wjnet.com/bpg/gerinfo/240>

PUBLICATION MISCONDUCT

<https://www.wjnet.com/bpg/gerinfo/208>

ARTICLE PROCESSING CHARGE

<https://www.wjnet.com/bpg/gerinfo/242>

STEPS FOR SUBMITTING MANUSCRIPTS

<https://www.wjnet.com/bpg/GerInfo/239>

ONLINE SUBMISSION

<https://www.f6publishing.com>



Sternal Hodgkin's lymphoma: A case report and review of literature

Yi-Yu Yin, Nan Zhao, Bin Yang, Hua Xin

ORCID number: Yi-Yu Yin (0000-0003-0351-4077); Nan Zhao (0000-0001-6727-7117); Bin Yang (0000-0001-6839-638); Hua Xin (0000-0001-6144-1908).

Author contributions: Yin YY contributed to the conception of the study; Yin YY contributed significantly to analysis and manuscript preparation; Yin YY, Zhao N, Yang B, performed the data analyses and wrote the manuscript; Xin H helped perform the analysis with constructive discussions.

Informed consent statement: Informed written consent was obtained from the patient for publication of this report and any accompanying images.

Conflict-of-interest statement: The authors declare that they have no conflict of interest.

CARE Checklist (2016) statement: The authors have read the CARE Checklist (2016), and the manuscript was prepared and revised according to the CARE Checklist (2016).

Open-Access: This article is an open-access article that was selected by an in-house editor and fully peer-reviewed by external reviewers. It is distributed in accordance with the Creative Commons Attribution NonCommercial (CC BY-NC 4.0) license, which permits others to distribute, remix, adapt, build upon this work non-commercially, and license their derivative works on different terms, provided the original work is properly cited and the use is non-commercial. See: <http://creativecommons.org/licenses/by-nc/4.0/>

Yi-Yu Yin, Nan Zhao, Bin Yang, Hua Xin, Department of Thoracic Surgery, China-Japan Union Hospital of Jilin University, Changchun 130000, Jilin Province, China

Corresponding author: Hua Xin, MD, PhD, Chief Doctor, Professor, Department of Thoracic Surgery, China-Japan Union Hospital of Jilin University, 126 Xiantai Street, Changchun 130000, Jilin Province, China. yinjie17@mails.jlu.edu.cn

Abstract

BACKGROUND

Sternal tumors are difficult to diagnose, and usually need to be differentiated from other diseases such as tuberculosis, osteosarcoma, intrathoracic thyroid and thymoma. The sternum is a rare site of Hodgkin's lymphoma, which is often misdiagnosed as tuberculosis on routine histopathology.

CASE SUMMARY

We reported a 47-year-old female patient with chest pain in the upper sternum for 1 mo. Chest computed tomography found a mass in the upper sternum. Pathology and immunohistochemistry of the biopsy confirmed the diagnosis of typical Hodgkin's lymphoma (mixed cellularity subtype). Patient was diagnosed with primary sternal Hodgkin's lymphoma and administered 6 cycles of adriamycin, bleomycin, vinblastine, and dacarbazine chemotherapy. Patient had no tumor recurrence and progression at a follow-up visit 2 years later.

CONCLUSION

This study highlights the rarity of primary sternal Hodgkin's lymphoma and the challenges of its diagnosis. A PubMed and Web of Science search revealed 10 reported cases of sternal involvement in Hodgkin's lymphoma.

Key words: Sternum; Skeleton; Hodgkin's Lymphoma; Chest pain; Case report

©The Author(s) 2020. Published by Baishideng Publishing Group Inc. All rights reserved.

Core tip: Sternal tumors are difficult to diagnose, and usually need to be differentiated from other diseases. The sternum is a rare site of Hodgkin's lymphoma, which is usually misdiagnosed as tuberculosis on routine histopathology. We here report a 47-year-old female patient with chest pain in the upper sternum for 1 mo. The patient was diagnosed with primary sternal Hodgkin's lymphoma and administered 6 cycles of adriamycin, bleomycin, vinblastine, and dacarbazine chemotherapy. No tumor recurrence and progression at a follow-up visit 2 years later. This is a first case report about diagnosis at initial presentation with a primary lesion.

Manuscript source: Unsolicited manuscript

Received: October 28, 2019

Peer-review started: October 28, 2019

First decision: December 4, 2019

Revised: December 13, 2019

Accepted: December 22, 2019

Article in press: December 22, 2019

Published online: February 6, 2020

P-Reviewer: El-Razek AA, Yildiz K

S-Editor: Zhang L

L-Editor: MedE-Ma JY

E-Editor: Liu JH



Citation: Yin YY, Zhao N, Yang B, Xin H. Sternal Hodgkin's lymphoma: A case report and review of literature. *World J Clin Cases* 2020; 8(3): 638-644

URL: <https://www.wjgnet.com/2307-8960/full/v8/i3/638.htm>

DOI: <https://dx.doi.org/10.12998/wjcc.v8.i3.638>

INTRODUCTION

Lymphomas, both Hodgkin lymphomas (HL) and non-HL, comprise approximately 5% to 6% of all malignancies, approximately half of all newly diagnosed hematological tumors^[1,2]. HL is a type of lymphoma that originates from B lymphocytes and characteristically presents in a group of lymph nodes, most commonly in the cervical and supraclavicular lymph nodes (LN)^[3]. Extranodal HL, especially in sternum, is extremely rare. This study highlights the rarity of primary sternal Hodgkin's lymphoma and the challenges of its diagnosis.

CASE PRESENTATION

Chief complaints

Chest pain in the upper sternum for 1 mo in a 47-year-old woman.

History of present illness

The patient presented to our department with complaints of paroxysmal chest pain, radiating to the left side, and associated with fatigue, fever of 37.8 °C, and significant weight loss (6.5 kg over 3 mo), these symptoms gradually aggravated within 1 mo. Patient denied experiencing night sweats or other symptoms.

History of past illness

The patient had no history of other diseases.

Personal and family history

She had no history of cigarette smoking or alcohol use, and there were no similar cases in the family.

Physical examination upon admission

Physical examination after admission revealed the following: blood pressure of 110/70 mmHg, pulse of 80 beats/min and temperature of 37.5 °C. The general examination was unremarkable, and no palpable lymph nodules were found. Chest examination revealed a solid mass in the upper sternal segment. On palpation, the swelling was fixed, firm, and non-tender with smooth edges without redness and ulceration, and no obvious abnormality was found in other systemic examinations.

Laboratory examinations

Blood test results were as follows: Differential counts of neutrophils, 72.9%; lymphocytes, 19.8%; platelet counts, $257 \times 10^9/L$; lactate dehydrogenase level, 169.69 IU/L and human immunodeficiency virus was negative.

Imaging examinations

Chest contrast-enhanced computed tomography (CT) (**Figure 1**) showed a patellar low-density shadow in the upper sternum, surrounding a soft tissue mass measuring 3.9 cm × 2.8 cm with mild enhancement. The initial diagnosis was a mediastinal mass. We performed a technetium 99m-methyl diphosphonate (Tc^{99m}MDP) bone scintigraphy scan (**Figure 2**) to exclude other skeletal system tumors in the patient. The results revealed apparent fixation of the radiopharmaceuticals in the sternal manubrium and upper segment of the sternal body, and no involvement of other sites in the skeleton was found.

FINAL DIAGNOSIS

A histopathological biopsy (**Figure 3**) from the swelling revealed that most tissues were necrotic and contained inflammatory granulation, blood vessels, lymphocytes, plasma cells and a few large heterotypic cells (suspected to be Reed Sternberg cells).

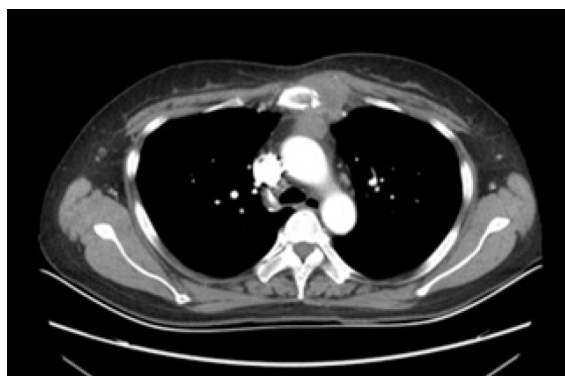

Figure 1 Chest contrast enhanced computed tomography scan. Patchy low-density shadows were seen in the upper sternum, and soft tissue mass formation was observed around the upper sternum, with a size of 3.9 cm × 2.8 cm and slight enhancement.

On immunohistochemistry (Figure 4): CD30 (+), Pax-5 (+), Ki67 (60%+), CD20 (-), and CD5 (-) were revealed, indicating a pattern typical of classical Hodgkin's lymphoma (mixed cellularity, MC).

TREATMENT

To prevent disease progression and relieve symptoms, patient was administered 6 cycles of the ABVD regimen (Adriamycin 25 mg/m², Bleomycin 10 mg/m², Vinblastine 6 mg/m², and Dacarbazine 375 mg/m² every 28 d). Patient's symptoms improved significantly after the treatment, and chest CT examination (Figure 5) revealed a 90% reduction in the size of the mass lesion.

OUTCOME AND FOLLOW-UP

Patient has achieved complete remission after treatment and followed up for 2 years without recurrence of the tumor or clinically detectable lymph nodes enlargement.

DISCUSSION

HL is a type of lymphoma that originates in B lymphocytes, which characteristically presents in a group of lymph nodes (LN), most commonly in the cervical and supraclavicular LN. Four typical subtypes of HL are defined: Lymphocytic predominance, nodular sclerosis, MC, and lymphocytic depletion^[3]. Extranodal HL is extremely rare and most commonly presents in the gastrointestinal tract, respiratory system, thyroid gland, skin, urogenital tract and central nervous system^[4]. HL initially manifesting in the skeleton is rare because bone involvement is a peculiarity of advanced HL and occurs in about 10%-20% of cases at some stages of the disease course^[5]. Although some cases of HL may initially appear with skeletal symptoms, other findings may eventually indicate the involvement of other areas, such as the mammary^[6], the supraclavicular^[7], the axillary^[8], and the inguinal LNs^[9]. Primary HL of the skeleton is extremely rare with an incidence of only 1%-4%.^[7] Biswas *et al*^[10] reported that the spine, pelvis, ribs, femur and clavicle are the most common sites of bone involvement in HL, while sternum involvement is distinctly uncommon. Primary bone lymphoma is defined as being limited to bone with or without an associated soft tissue component and no regional lymphadenopathy at diagnosis and during the 6-mo follow-up. Bone involvement is classified as stage IV HL, but primary solitary osseous HL is defined as stage IE according to the Ann Arbor staging^[4].

Sternal tumors confer certain difficulties in clinical diagnosis, and usually need to be differentiated from other diseases such as tuberculosis, eosinophilic granuloma, osteosarcoma, intrathoracic thyroid and thymoma. Therefore, patients often delay treatment or even die because of misdiagnosis. Hence, in such patients with sternal pain, HL should be cautiously considered, although HL involving the sternum is very rare. In our case, the patient was admitted to the hospital with complaints of chest

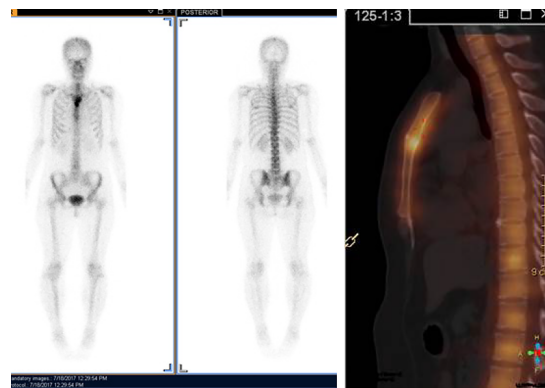

Figure 2 Bone scintigraphy scan with Tc^{99m}-MDP. Apparent fixation of the radiopharmaceuticals in the manubrium sternum and upper segment of the body of the sternum. No involvement of other sites of the skeleton was found.

pain for 1 mo, in view of the patients' age, symptoms, physical signs and imaging examination results, a mediastinal mass was considered as the primary diagnosis. For further diagnosis and treatment and to prevent misdiagnosis, the patient underwent a tissue biopsy and was finally diagnosed with sternal HL (MC) based on the pathological results. Following 6 cycles of chemotherapy, the patient achieved complete remission. Although CT, magnetic resonance imaging and positron emission tomography can be used for the diagnosis of chest wall or sternal tumors, careful clinical and comprehensive diagnostic workup is still needed in the treatment of such cases, which can improve the diagnosis rate, and avoid ultimate death due to misdiagnosis.

We conducted a search of PubMed and Web of Science using the key words "Hodgkin's, sternum" for papers published from 2000 to 2019 and summarized 11 articles in Table 1. Nine patients had involvements in the LNs, 3 had involvements at other skeletal sites, and 2 patients had isolated and primary sternal involvement. Men had a higher prevalence than women (6, 54.55%) and the mean age was 29 years (ranged from 7-82, R software 3.5.1 was used). Histological results were available in 7 articles, NS was the most common subtype, which accounted for 71.43%, and MC accounted for 28.57%. Five cases (45.45%) were initially misdiagnosed (most commonly with tuberculosis). Chemoradiotherapy was the most common treatment (5, 45.45%), followed by chemotherapy (4, 36.36%) and one patient was treated by stem cell transplantation. Based on the review, about half of the patients were misdiagnosed initially, and only 2 patients were diagnosed with primary sternal HL, but they both experienced relapses; thus, our case is the first reported case diagnosed at initial presentation with a primary lesion.

CONCLUSION

This study highlights the rarity of primary sternal Hodgkin's lymphoma and the challenges of its diagnosis. Because of the rarity of such tumors, we report this case to raise awareness of this disease.

Table 1 Literature review of sternal Hodgkin's lymphomas

Ref.	Country	Age (yr)	Sex	Initial diagnosis	Pathological type	Extra-sternal involvement regions	Stage	Treatment
Priola <i>et al</i> ^[9] , 2006	Italy	20	M	EG	NS	Supraclavicular LN	NA	CT and RT
Petkov <i>et al</i> ^[11] , 2006	Bulgaria	33	M	HL	NA	NA	IIB	CT and SCT
Karimi <i>et al</i> ^[12] , 2007	Iran	82	F	HL	NA	Chest wall, Thoracic inlet	NA	No treatment
Langley <i>et al</i> ^[13] , 2008	UK	7	M	TB	NA	L1 vertebra, left sacroiliac joint, right acetabulum	IVB	CT
Biswas <i>et al</i> ^[10] , 2008	India	21	M	TB	NS	Left cervical LN, liver, spleen, abdominal LN	IVB	CT and RT
Oshikawa <i>et al</i> ^[14] , 2009	Japan	28	M	HL	MC	Right ilium, left scapula, rib	IVB	CT and RT
Goyal <i>et al</i> ^[7] , 2015	India	25	F	LCH	NS	Axillary, supraclavicular, anterior diaphragmatic LN	IIBS	CT and RT
Singh <i>et al</i> ^[15] , 2015	India	30	F	TB	MC	Cervical LN, pre aortic LN	NA	CT
Jain <i>et al</i> ^[16] , 2016	India	30	F	HL	NS	NA	IEB	CT and RT
Li <i>et al</i> ^[17] , 2018	China	25	F	HL	NS	Right clavicle, axillary, mediastinal SN	NA	CT

M: Male; F: Female; EG: Eosinophilic granuloma; HL: Hodgkin's lymphoma; TB: Tuberculosis; LCH: Langerhan cell histiocytosis; NA: Not available; NS: Nodular sclerosis; MC: Mixed cellularity; LN: Lymph node; CT: Chemotherapy; RT: Radiotherapy; SCT: Stem cell transplantation.

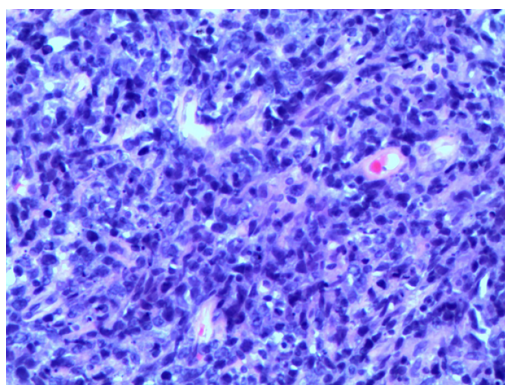


Figure 3 Hematoxylin and eosin staining (original magnification 200 ×). Lymphocytes, plasma cells and a few large heteromorphic cells (Suspected Reed Sternberg cells).

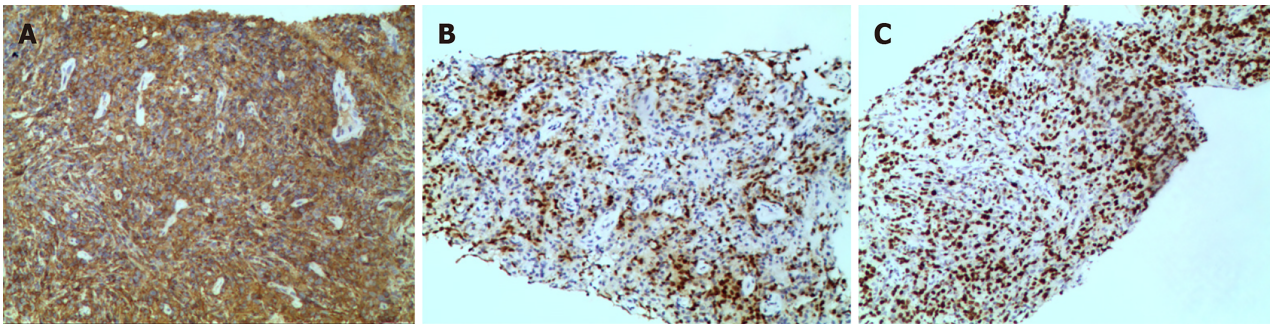


Figure 4 Immunohistochemical staining (original magnification 100 ×). A: CD 30(+); B: PAX-5(+); C: Ki-67(60%+).

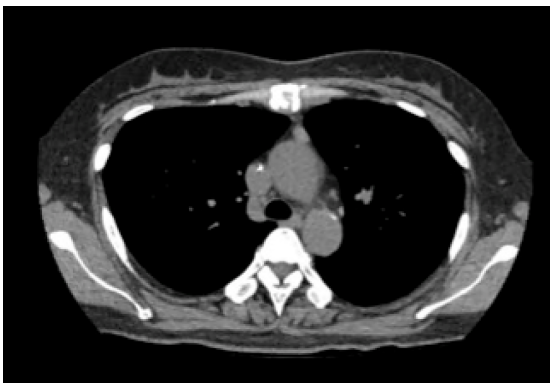

Figure 5 Chest computed tomography shows that the mass around the upper sternum was reduced obviously.

REFERENCES

- 1 Siegel RL, Miller KD, Jemal A. Cancer statistics, 2015. *CA Cancer J Clin* 2015; **65**: 5-29 [PMID: 25559415 DOI: 10.3322/caac.21254]
- 2 Razeq AAKA, Shamaa S, Lattif MA, Yousef HH. Inter-Observer Agreement of Whole-Body Computed Tomography in Staging and Response Assessment in Lymphoma: The Lugano Classification. *Pol J Radiol* 2017; **82**: 441-447 [PMID: 29662570 DOI: 10.12659/PJR.902370]
- 3 Zhu XZ, Li XQ. Interpretation of WHO classification of malignant lymphoma in 2008 – Hodgkin's lymphoma and others. *Linchuang Yu Shiyang Binglixue Zazhi* 2010; **26**: 10-13
- 4 Li Y, Wang XB, Tian XY, Li B, Li Z. Unusual primary osseous Hodgkin lymphoma in rib with associated soft tissue mass: a case report and review of literature. *Diagn Pathol* 2012; **7**: 64 [PMID: 22682578 DOI: 10.1186/1746-1596-7-64]
- 5 Ostrowski ML, Inwards CY, Strickler JG, Witzig TE, Wenger DE, Unni KK. Osseous Hodgkin disease. *Cancer* 1999; **85**: 1166-1178 [PMID: 10091803 DOI: 10.1002/(sici)1097-0142(19990301)85:5<1166::aid-cnrcr22>3.0.co;2-v]
- 6 Arnold HS, Meese EH, D'Amato NA, Maughon JS. Localized Hodgkin's disease presenting as a sternal tumor and treated by total sternectomy. *Ann Thorac Surg* 1966; **2**: 87-93 [PMID: 5924807 DOI: 10.1016/s0003-4975(10)66542-3]
- 7 Goyal S, Biswas A, Puri T, Gupta R, Julka PK. Osseous Hodgkin's lymphoma with sternal involvement at presentation: Diagnostic challenges. *Clin Cancer Investig J* 2015; **4**: 447-450 [DOI: 10.4103/2278-0513.154271]
- 8 Miano C, Lombardi A, Russo LA, Ceci A, Baronci C, Bonaldi U, Rosati D. [Hodgkin's lymphoma with nodular sclerosis. A report of a case with an unusual sternal location at the onset]. *Pediatr Med Chir* 1991; **13**: 639-640 [PMID: 1806925]
- 9 Priola SM, Priola AM, Cataldi A, Fava C. Nodular sclerosing Hodgkin disease presenting as a sternal mass. *Br J Haematol* 2006; **135**: 594 [PMID: 17107345 DOI: 10.1111/j.1365-2141.2006.06305.x]
- 10 Biswas A, Puri T, Goyal S, Haresh KP, Gupta R, Julka PK, Rath GK. Osseous Hodgkin's lymphoma-review of literature and report of an unusual case presenting as a large ulcerofungating sternal mass. *Bone* 2008; **43**: 636-640 [PMID: 18619936 DOI: 10.1016/j.bone.2008.05.020]
- 11 Petkov R, Nossikoff AV, Alexandrova K, Stanchev A, Ousheva R, Hadgiev E. A case of sternal involvement in an early relapse of hodgkin disease verified with ultrasound guided core needle biopsy. *Eur J Radiol Extra* 2006; **60**: 75-78 [DOI: 10.1016/j.ejrex.2006.08.001]
- 12 Karimi S, Mohammadi F, Pejhan S, Zahirifard S, Azari PA. An unusual presentation of Hodgkin's lymphoma as a chest wall abscess in association with old tuberculosis. *Tanaffos* 2007; **6**: 71-74
- 13 Langley CR, Garrett SJ, Urand J, Kohler J, Clarke NM. Primary multifocal osseous Hodgkin's lymphoma. *World J Surg Oncol* 2008; **6**: 34 [PMID: 18346271 DOI: 10.1186/1477-7819-6-34]
- 14 Oshikawa G, Arai A, Sasaki K, Ichinohasama R, Miura O. [Primary multifocal osseous Hodgkin lymphoma]. *Rinsho Ketsueki* 2009; **50**: 92-96 [PMID: 19265301]
- 15 Singh S, Jenaw RK, Jindal A, Bhandari C. Hodgkin's lymphoma presenting as lytic sternal swelling. *Lung*

- India* 2015; **32**: 410-412 [PMID: 26180401 DOI: 10.4103/0970-2113.159612]
- 16 **Jain A**, Gupta N. Primary Hodgkin's Lymphoma of the Sternum: Report of a Case and Review of the Literature. *J Clin Diagn Res* 2016; **10**: XE07-XE10 [PMID: 27504392 DOI: 10.7860/JCDR/2016/19666.8065]
- 17 **Li Y**, Qin Y, Zheng L, Liu H. Extranodal presentation of Hodgkin's lymphoma of the sternum: A case report and review of the literature. *Oncol Lett* 2018; **15**: 2079-2084 [PMID: 29434908 DOI: 10.3892/ol.2017.7546]



Published By Baishideng Publishing Group Inc
7041 Koll Center Parkway, Suite 160, Pleasanton, CA 94566, USA
Telephone: +1-925-3991568
E-mail: bpgoffice@wjgnet.com
Help Desk: <https://www.f6publishing.com/helpdesk>
<https://www.wjgnet.com>

