

World Journal of *Clinical Cases*

World J Clin Cases 2020 March 6; 8(5): 854-1001



**ORIGINAL ARTICLE****Clinical and Translational Research**

- 854** Repair mechanism of astrocytes and non-astrocytes in spinal cord injury
Liu XY, Guo JW, Kou JQ, Sun YL, Zheng XJ

Case Control Study

- 864** Study on the correlation and predictive value of serum pregnancy-associated plasma protein A, triglyceride and serum 25-hydroxyvitamin D levels with gestational diabetes mellitus
Ren Z, Zhe D, Li Z, Sun XP, Yang K, Lin L
- 874** Significance of ¹²⁵I radioactive seed implantation on growth differentiation factor and programmed death receptor-1 during treatment of oral cancer
Xue G, Feng Y, Li JB

Observational Study

- 887** Computed tomography-based score model/nomogram for predicting technical and midterm outcomes in transjugular intrahepatic portosystemic shunt treatment for symptomatic portal cavernoma
Niu XK, Das SK, Wu HL, Chen Y

META-ANALYSIS

- 900** Efficacy of totally laparoscopic compared with laparoscopic-assisted total gastrectomy for gastric cancer: A meta-analysis
Wang S, Su ML, Liu Y, Huang ZP, Guo N, Chen TJ, Zou ZH

CASE REPORT

- 912** Allograft artery mycotic aneurysm after kidney transplantation: A case report and review of literature
Bindi M, Ferraresso M, De Simeis ML, Raison N, Clementoni L, Delbue S, Perego M, Favi E
- 922** Oxcarbazepine for trigeminal neuralgia may induce lower extremity weakness: A case report
Song HG, Nahm FS
- 928** Acute thrombocytopenia after anticoagulation with rivaroxaban: A case report
He XY, Bai Y
- 932** Surgical resection of a large hypopharyngeal hemangioma in an adult using neodymium-doped yttrium aluminum garnet laser: A case report
Jin M, Wang CY, Da YX, Zhu W, Jiang H

- 939** Combining surgery with ¹²⁵I brachytherapy for recurrent mediastinal dedifferentiated liposarcoma: A case report and review of literature
Chen HG, Zhang K, Wu WB, Wu YH, Zhang J, Gu LJ, Li XJ
- 940** Combining surgery with ¹²⁵I brachytherapy for recurrent mediastinal dedifferentiated liposarcoma: A case report and review of literature
Chen HG, Zhang K, Wu WB, Wu YH, Zhang J, Gu LJ, Li XJ
- 946** Extrapontine myelinolysis caused by rapid correction of pituitrin-induced severe hyponatremia: A case report
Fang LJ, Xu MW, Zhou JY, Pan ZJ
- 947** Extrapontine myelinolysis caused by rapid correction of pituitrin-induced severe hyponatremia: A case report
Fang LJ, Xu MW, Zhou JY, Pan ZJ
- 954** Total endovascular repair of an intraoperative stent-graft deployed in the false lumen of Stanford type A aortic dissection: A case report
Li XR, Tong YH, Li XQ, Liu CJ, Liu C, Liu Z
- 955** Total endovascular repair of an intraoperative stent-graft deployed in the false lumen of Stanford type A aortic dissection: A case report
Li XR, Tong YH, Li XQ, Liu CJ, Liu C, Liu Z
- 963** Muscular involvement of extranodal natural killer/T cell lymphoma misdiagnosed as polymyositis: A case report and review of literature
Liu LH, Huang Q, Liu YH, Yang J, Fu H, Jin L
- 971** Two bone blocks sandwich technique for horizontal reconstruction of severely atrophic alveolar ridge in anterior maxilla: A case report
Xia HB, Zhang YF, Shi B, Wang M
- 980** Anomalous retinal artery associated with branch retinal artery occlusion and neovascular glaucoma: A case report
Yang WJ, Yang YN, Cai MG, Xing YQ
- 986** Misdiagnosis of primary intimal sarcoma of the pulmonary artery as chronic pulmonary embolism: A case report
Lu P, Yin BB
- 995** Late-onset multiple acyl-CoA dehydrogenase deficiency with cardiac syncope: A case report
Pan XQ, Chang XL, Zhang W, Meng HX, Zhang J, Shi JY, Guo JH

ABOUT COVER

Editorial Board Member of *World Journal of Clinical Cases*, Hitoshi Hirose, MD, PhD, Associate Professor, Department of Cardiothoracic Surgery, Thomas Jefferson University, Philadelphia, PA 19107, United States

AIMS AND SCOPE

The primary aim of *World Journal of Clinical Cases* (WJCC, *World J Clin Cases*) is to provide scholars and readers from various fields of clinical medicine with a platform to publish high-quality clinical research articles and communicate their research findings online.

WJCC mainly publishes articles reporting research results and findings obtained in the field of clinical medicine and covering a wide range of topics, including case control studies, retrospective cohort studies, retrospective studies, clinical trials studies, observational studies, prospective studies, randomized controlled trials, randomized clinical trials, systematic reviews, meta-analysis, and case reports.

INDEXING/ABSTRACTING

The WJCC is now indexed in PubMed, PubMed Central, Science Citation Index Expanded (also known as SciSearch®), and Journal Citation Reports/Science Edition. The 2019 Edition of Journal Citation Reports cites the 2018 impact factor for WJCC as 1.153 (5-year impact factor: N/A), ranking WJCC as 99 among 160 journals in Medicine, General and Internal (quartile in category Q3).

RESPONSIBLE EDITORS FOR THIS ISSUE

Responsible Electronic Editor: *Yan-Xia Xing*

Proofing Production Department Director: *Yun-Xiaojuan Wu*

NAME OF JOURNAL

World Journal of Clinical Cases

ISSN

ISSN 2307-8960 (online)

LAUNCH DATE

April 16, 2013

FREQUENCY

Semimonthly

EDITORS-IN-CHIEF

Dennis A Bloomfield, Bao-Gan Peng, Sandro Vento

EDITORIAL BOARD MEMBERS

<https://www.wjnet.com/2307-8960/editorialboard.htm>

EDITORIAL OFFICE

Jin-Lei Wang, Director

PUBLICATION DATE

March 6, 2020

COPYRIGHT

© 2020 Baishideng Publishing Group Inc

INSTRUCTIONS TO AUTHORS

<https://www.wjnet.com/bpg/gerinfo/204>

GUIDELINES FOR ETHICS DOCUMENTS

<https://www.wjnet.com/bpg/GerInfo/287>

GUIDELINES FOR NON-NATIVE SPEAKERS OF ENGLISH

<https://www.wjnet.com/bpg/gerinfo/240>

PUBLICATION MISCONDUCT

<https://www.wjnet.com/bpg/gerinfo/208>

ARTICLE PROCESSING CHARGE

<https://www.wjnet.com/bpg/gerinfo/242>

STEPS FOR SUBMITTING MANUSCRIPTS

<https://www.wjnet.com/bpg/GerInfo/239>

ONLINE SUBMISSION

<https://www.f6publishing.com>

Combining surgery with ¹²⁵I brachytherapy for recurrent mediastinal dedifferentiated liposarcoma: A case report and review of literature

Hui-Guo Chen, Kai Zhang, Wei-Bin Wu, Yong-Hui Wu, Jian Zhang, Li-Jia Gu, Xiao-Jun Li

ORCID number: Hui-Guo Chen (0000-0003-3905-5095); Kai Zhang (0000-0002-7877-4538); Wei-Bin Wu (0000-0002-2272-8735); Yong-Hui Wu (0000-0003-2392-1382); Jian Zhang (0000-0001-5000-6142); Li-Jia Gu (0000-0001-9351-8690); Xiao-Jun Li (0000-0001-7078-8241).

Author contributions: Chen HG and Zhang K were the patient's thoracic surgeon, reviewed the literature and contributed to manuscript drafting; Wu WB and Wu YH reviewed the literature and contributed to manuscript drafting; Zhang J and Gu LJ were the patient's thoracic surgeon; Li XJ was responsible for the revision of the manuscript; all authors issued final approval for the version to be submitted.

Informed consent statement: Informed written consent was obtained from the patient for publication of this report and accompanying images.

Conflict-of-interest statement: All authors declare that they have no conflict of interest.

CARE Checklist (2016) statement: The authors have read the CARE Checklist (2016), and the manuscript was prepared and revised according to the CARE Checklist (2016).

Open-Access: This article is an open-access article that was selected by an in-house editor and fully peer-reviewed by external reviewers. It is distributed in accordance with the Creative Commons Attribution NonCommercial (CC BY-NC 4.0)

Hui-Guo Chen, Kai Zhang, Wei-Bin Wu, Yong-Hui Wu, Jian Zhang, Li-Jia Gu, Xiao-Jun Li, Department of Cardiothoracic Surgery, the Third Affiliated Hospital of Sun Yat-sen University, Guangzhou 510630, Guangdong Province, China

Corresponding author: Xiao-Jun Li, MD, Doctor, Surgeon, Department of Cardiothoracic Surgery, the Third Affiliated Hospital of Sun Yat-sen University, 600 Tianhe Road, Guangzhou 510630, Guangdong Province, China. tjlixiaojun@163.com

Abstract

BACKGROUND

Dedifferentiated liposarcoma in the mediastinum is an extremely rare malignant neoplasm. A few previous case reports indicate that surgical resection is the major treatment, but frequent recurrence occurs locally. Due to its rarity, its clinical characteristics, optimal treatment and clinical outcomes remain unclear. Here, we report a case of multifocal recurrent dedifferentiated liposarcoma in the posterior mediastinum treated by combining surgery with ¹²⁵I brachytherapy, and summarize its clinical features, treatment and prognosis.

CASE SUMMARY

A 75-year-old man was admitted to our hospital with a history of gradual dysphagia for one year and aggravated dysphagia for 3 mo. Contrast-enhanced computed tomography (CT) revealed several large cystic-solid masses with lipomatous density, and calcification in the posterior-inferior mediastinum. The patient received a wide excision by video-assisted thoracoscopic surgery. Pathological analysis confirmed the tumors were dedifferentiated liposarcomas. The tumor locally relapsed 24 mo later, and another operation was performed by video-assisted thoracoscopic surgery. Fifteen months after the second surgery, the tumor recurred again, and the patient received CT-guided radioactive seeds ¹²⁵I implantation. After 8 mo, follow-up chest CT showed an enlarged tumor. Finally, his condition exacerbated with severe dysphagia and dyspnea, and he died of respiratory failure in July 2018.

CONCLUSION

We reviewed the literature, and suggest that surgical resection provides beneficial effects for dedifferentiated liposarcoma in the mediastinum, even in cases with local recurrence. ¹²⁵I brachytherapy may be beneficial for recurrent unresectable patients.

Key words: Dedifferentiated liposarcoma; Mediastinal neoplasms; Recurrence; Reoperation; ¹²⁵I brachytherapy; Case report

license, which permits others to distribute, remix, adapt, build upon this work non-commercially, and license their derivative works on different terms, provided the original work is properly cited and the use is non-commercial. See: <http://creativecommons.org/licenses/by-nc/4.0/>

Manuscript source: Unsolicited Manuscript

Received: October 9, 2019

Peer-review started: October 9, 2019

First decision: January 7, 2020

Revised: February 3, 2020

Accepted: February 12, 2020

Article in press: February 12, 2020

Published online: March 6, 2020

P-Reviewer: da Costa AC, Vermeersch P

S-Editor: Tang JZ

L-Editor: Filipodia

E-Editor: Xing YX



©The Author(s) 2020. Published by Baishideng Publishing Group Inc. All rights reserved.

Core tip: Dedifferentiated liposarcoma in the mediastinum is an extremely rare malignant neoplasm. Only a few cases have been reported, and its clinical characteristics, optimal treatment and clinical outcomes remain unclear. Here, we report a male patient with recurrent mediastinal dedifferentiated liposarcoma that was successfully treated by surgery combined with ¹²⁵I brachytherapy. A review of the literature is also provided to improve the overall awareness of this disease. To our knowledge, this literature review covers the largest number of cases as any prior, and is the first report on dedifferentiated liposarcomas treated by ¹²⁵I brachytherapy.

Citation: Chen HG, Zhang K, Wu WB, Wu YH, Zhang J, Gu LJ, Li XJ. Combining surgery with ¹²⁵I brachytherapy for recurrent mediastinal dedifferentiated liposarcoma: A case report and review of literature. *World J Clin Cases* 2020; 8(5): 939-945

URL: <https://www.wjnet.com/2307-8960/full/v8/i5/939.htm>

DOI: <https://dx.doi.org/10.12998/wjcc.v8.i5.939>

INTRODUCTION

Liposarcoma is a malignant adipocytic neoplasm with varying degrees of atypia. According to the 2019 NCCN classification, liposarcoma has been classified into four types: Well-differentiated, myxoid, pleomorphic, and dedifferentiated. Dedifferentiated liposarcoma is a common form of liposarcoma, accounting for the most pleomorphic sarcoma in the retroperitoneum^[1], but rarely occurs in the mediastinum, and the exact frequency is unknown^[2]. Thus far, limited cases of mediastinal dedifferentiated liposarcoma have been reported, and its clinical characteristics, optimal treatment and clinical outcomes remain unclear.

The present study reports a case of primary multifocal recurrent dedifferentiated liposarcomas in the posterior mediastinum treated by combining surgery with ¹²⁵I brachytherapy following recurrence. In addition, 38 cases of primary mediastinal dedifferentiated liposarcoma from the English literature are reviewed to illustrate the clinical characteristics, treatment and outcomes of the disease. To our knowledge, our literature review covers the largest number of cases compared to any prior reviews, and is the first report of dedifferentiated liposarcomas treated by ¹²⁵I brachytherapy.

CASE PRESENTATION

Chief complaints

Progressive dysphagia for one year.

History of present illness

A 75-year-old male was admitted in December 2013 due to gradually progressive dysphagia, and the symptoms became more aggravated 3 mo before admission. He had no chest pain, acid reflux or weight loss.

History of past illness

Atrial fibrillation had been diagnosed eight years prior, but had been left untreated. There was no history of trauma, thoracic disease, thoracic surgery or abdominal disease.

Physical examination

No remarkable abnormality was found upon physical examination, with the exception of atrial fibrillation with a heart rate of approximately 80 beats per minute.

Laboratory examinations

Tumor markers were in the normal range, including α-fetoprotein, carcinoembryonic antigen, β-human chorionic gonadotropin, cytokeratin 19-fragments (CYFRA21-1), neuron specific enolase, cancer antigens 19-9 and squamous cell carcinoma antigen.

Imaging examination

Chest contrast-enhance computed tomography (CT) revealed several large cystic-solid

masses that compressed the left atrium, left ventricular and esophagus in the posterior-inferior mediastinum. The largest mass was about 10.5 cm × 9 cm in size and had three attenuation components, namely a lipomatous element, a soft tissue density component and a high attenuation calcified area (Figure 1A and B). The other masses had only two attenuation components without calcification. All of the masses had a relatively distinct margin, and the CT value was 19 HU. A small amount of pericardial effusion and bilateral pleural effusion were present. No obvious enhancement was found in any of the stages after enhancement, and no obviously enlarged lymph nodes were found. The 18F-fluorodeoxyglucose positron emission tomography (PET) showed an maximum standardized uptake value (SUVmax) of 1.8 (Figure 1C) and no metastasis. Esophageal dynamic radiography and fibergastroscopy showed that the lower esophagus was significantly compressed. No obvious changes were observed on the mucosal surface of the esophagus, and no tumorous lesion was seen.

Preoperative diagnosis

Teratoma in the posterior mediastinum.

FINAL DIAGNOSIS

Grossly, all tumors had an integrated capsule, and there was some adipose tissues between adjacent tumors (Figure 2A). Within the tumor, the cut interface presented as variegated tan-yellow to brown, and had a partial myxoid appearance. Haematoxylin and eosin staining showed proliferating fat cells and well-differentiated liposarcoma, as well as spindle cell sarcoma with spindle nuclei and nuclear fission (Figure 2B and C). Immunohistochemical analysis showed that the tumor was positive for vimentin, S100 (Figure 2D), CD34, CD68 (diffused), and Desmin (partial), but negative for SMA, and the ki-67 index was 5%. Finally, a diagnosis of dedifferentiated liposarcoma was made.

TREATMENT

The patient immediately underwent wide excision by video-assisted thoracoscopic surgery, with a small incision (8 cm) made in the right thoracic cavity. The tumors presented as encapsulated and smooth, and occupied a large part of the left pleural cavity. There were mild adhesions, with fat tissue between tumors and lung, esophagus, descending aorta, left atrium, and left ventricular, but no direct invasion. Finally, a total of eight tumors were resected completely. The largest tumor was about 10.5 cm × 9 cm × 8.9 cm in size, and the smallest one was about 2 cm in diameter (Figure 2A).

OUTCOME AND FOLLOW-UP

The postoperative course was uneventful. The patient rejected adjuvant therapy, and chest CT was performed at a 6-mo interval for follow-up. The patient suffered from slight dysphagia again for 24 mo after the operation. Contrast-enhanced CT showed a mass (about 5 cm in diameter) in the posterior-inferior mediastinum-compressed esophagus, and the patient underwent re-operation by video-assisted thoracoscopic surgery. A total of five tumors were resected. Pathological analysis confirmed the diagnosis of dedifferentiated liposarcoma. The patient still rejected postoperative adjuvant chemotherapy or radiotherapy. Unfortunately, the chest CT showed tumor recurrence 15 mo after the re-operation. The condition of the disease was explained to the patient and his family, and the patient rejected repeat surgery and received CT-guided radioactive seeds ¹²⁵I implantation in another hospital. After 8 mo, follow-up chest CT showed an enlarged tumor. Finally, the patient rejected any treatment, and died from severe dysphagia and respiratory failure in July 2018.

DISCUSSION

Dedifferentiated liposarcoma is one type of liposarcoma that was first described by Evans in 1979^[3]. According to the World Health Organization, dedifferentiated liposarcoma is a malignant adipocytic neoplasm showing a transition from atypical lipomatous tumor/well-differentiated liposarcoma to non-lipogenic sarcoma of

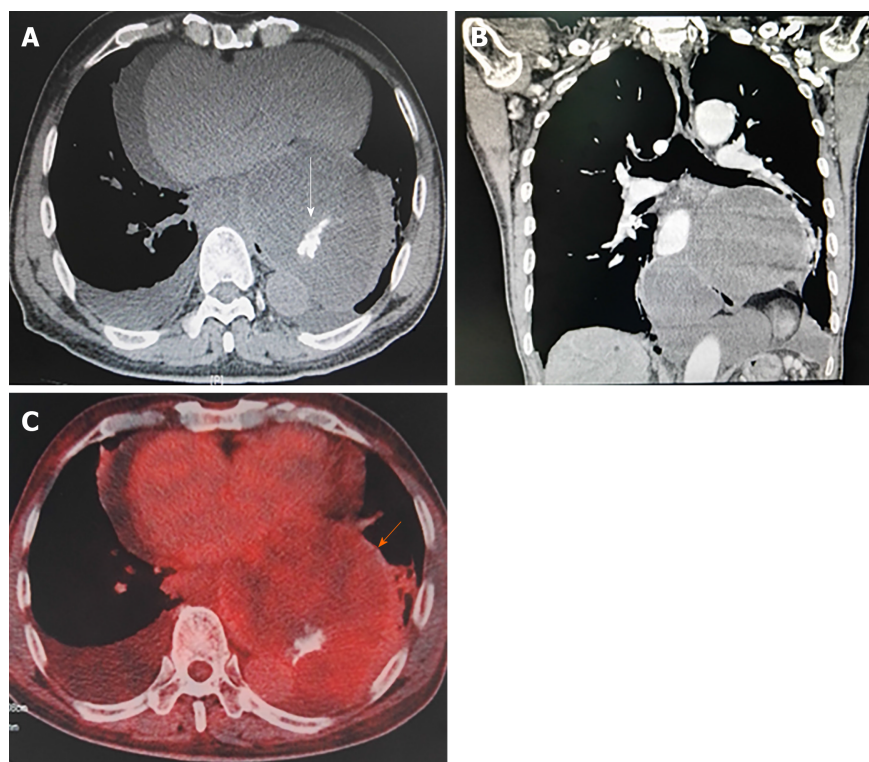


Figure 1 Imaging findings. A and B: Chest contrast-enhanced computed tomography scans showed several cystic-solid encapsulated masses in posterior-inferior mediastinum with well-defined margins, fatty density, soft tissue density, calcification and slight enhancement; C: 18F-fluorodeoxyglucose PET showed the maximum standardized uptake value (SUV_{ave}) of 1.8.

variable histological grade^[1]. Dedifferentiated liposarcoma most commonly occurs in the retroperitoneum, followed by extremities, and scrotum/spermatic cord, but its origin in the mediastinum is extremely rare^[4].

The present study reviewed the English literature in PubMed between 1950 and 2018 using the keywords: Dedifferentiated/de-differentiated, liposarcoma, mediastinum or mediastinal, and identified 39 cases of primary mediastinal dedifferentiated liposarcoma, including this case^[2,5-24]. In these cases, the tumors all occurred in adults, and the mean patient age was 62.9 years, with an age range of 34 years to 83 years, and a predilection for males (26 males and 13 females). Of the 39 cases, 24 were reported in American and European populations, and 15 cases in Asian populations. There were 24 cases describing symptom details: Sixteen with some symptoms and eight without symptoms. The common complaints included dyspnea (nine cases), cough (five cases), and dysphagia (five cases). The other symptoms included weight loss, hoarseness, chest pain and arm weakness. The tumor most frequently occurred in the anterior and posterior mediastinum (15 cases respectively), followed by the middle (three cases), and the anterior-middle mediastinum (one case). The tumor size varied from 6 cm to 61 cm. The mean size of the tumor was 18.5 cm, and only five cases exhibited a tumor of < 10 cm, meanwhile ten cases were > 20 cm in diameter. The mean SUV_{max} of the tumor was 3.7 in seven cases (range 1.8 to 9.2), and four cases exhibited < 2.5. Only four cases had reported tumor invasion of the surrounding structures, including pleura, pericardium and the phrenic nerve. Distant metastasis only occurred in four cases, and common metastasis occurred in the lung and pleura.

In terms of initial management, 30 patients underwent complete surgical resection, three patients received incomplete surgical resection, two patients received chemotherapy, one patient received neoadjuvant chemotherapy and three patients were unknown. Of the 34 surgical cases, three patients received adjuvant therapy after surgery (two for chemotherapy and one for radiotherapy). Unfortunately, the tumor recurred in 13 cases (13/34, 38.2%), and nine cases were further treated by repeat surgery, while the other patients received chemotherapy (one case), chemoradiotherapy (one case), and radiotherapy (one case). Six cases of repeat surgical patients were reported with the second relapse (6/9, 66.7%). The mean time of recurrence-free survival (RFS) was 24.5 mo for the first relapse (range 5 mo to 50 mo) and was 35.8 mo for the second relapse (range 8 mo to 96 mo). Median RFS was

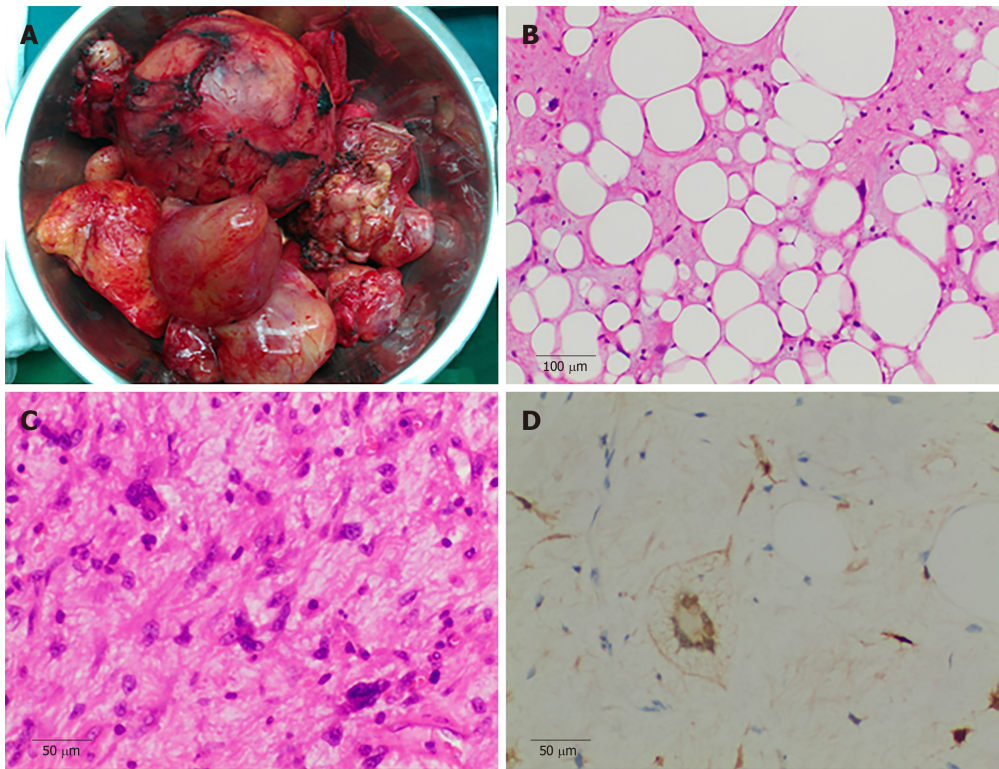


Figure 2 Pathological findings. A: Gross appearance showed the largest tumor was about 105 mm × 94 mm × 88 mm in size, and the smallest was about 20 mm in diameter; the tumors had integrated capsules; B and C: H&E staining showed a well-differentiated liposarcoma component and spindle cell component (× 100 and × 200, respectively); C: Immunohistochemical analysis showed the tumor was positive for S-100 protein in scattered cells (× 200).

24 mo for the first relapse and 14.5 mo for the second relapse. Of the 39 total patients, 21 cases were alive with no evidence of disease, five cases were alive with the disease, seven cases were dead (five cases dead of disease and two cases dead of other disease) and six cases were lost to follow-up. The longest survival time was 114 mo.

Since the first case reported by Evans *et al*^[22] in 1994, surgical resection was usually utilized in the management of mediastinal dedifferentiated liposarcoma. Based on previous reports, complete resection is the optimal method to eradicate the tumor^[2,5-9,11-21,23,24]. Hahn *et al*^[21] reported six cases of mediastinal dedifferentiated liposarcoma treated by complete resection, and three cases of them had a disease-free survival (DFS) of more than 50 mo. Recently, Miura *et al*^[2] reported five cases of mediastinal dedifferentiated liposarcoma, and reviewed 14 cases in the literature. They performed complete surgical resection in four patients, and claimed that complete surgical resection is the best treatment for mediastinal dedifferentiated liposarcoma. In our report, the patient underwent complete surgical resection and had an RFS of 24 mo. Although mediastinal dedifferentiated liposarcoma usually grows to be very large, the growth pattern tends to be of the expansive type rather than infiltrative type, and metastasis rarely occurs. Of the 39 cases, only one case showed metastasis and four cases had invaded surrounding structures at the time of the first visit. These conditions are conducive to complete surgical resection. However, 13 of 32 patients with complete resection developed local recurrence in the mediastinum, and it appeared that the tumor tended to recur after surgery. Although there was loose connective tissue between the tumor and surrounding structure, and the tumor did not invade surrounding organs, it is difficult to completely resect all of the fat tissue in the mediastinum. In addition, atypical cells were found in the peripheral fat tissue^[2]. These may explain the predisposition for recurrence. Fortunately, according to the literature review, repeat surgery is still valid for patients with recurrence, with a median RFS of 14.5 mo in seven cases of secondary relapse. Thus, despite a high risk of recurrence, we conclude that a complete resection is the best method to cure the tumor, even in patients with local recurrence.

As discussed above, repeat surgery is still valid for patients with recurrent mediastinal dedifferentiated liposarcoma, but some patients refused repeat surgery or were unsuitable for repeat surgery. External radiotherapy is an optional strategy used to treat these patients. Miura *et al*^[2] reported a patient with recurrent mediastinal dedifferentiated liposarcoma who was treated by radiotherapy, and the disease was well-controlled. Coulibaly *et al*^[19] reported a case of recurrent dedifferentiated

liposarcoma of the mediastinum treated by repeat surgery combined with adjuvant radiotherapy (60 Gy), and the patient had an RFS of 8 years. However, an adequate therapeutic dose of radiotherapy to the mediastinal tumor may damage the important adjacent organs, including lung, esophagus and heart, which are often radiosensitive and have a low radiation tolerance. ^{125}I brachytherapy can deliver a large total radiotherapy dose to the target tumor and overcome these problems. Radioactive seeds ^{125}I implantation was widely used in advanced hepatic carcinoma and soft tissue sarcoma with good outcomes^[25,26]. Yang *et al*^[25] reported CT-guided ^{125}I seed implantation for inoperable retroperitoneal, including eight cases of liposarcoma, and good local control was achieved. We consider ^{125}I brachytherapy to be effective because its application to locally recurrent tumors was effective in this case, with a PFS of 8 mo, although its efficacy has not been confirmed in dedifferentiated liposarcoma. To our knowledge, this is the first attempt to treat mediastinal dedifferentiated liposarcoma by CT-guided ^{125}I seed implantation. This approach needs to be further explored by large sample studies.

Due to its rarity, with only a few case reports, the long-term prognosis of mediastinal dedifferentiated liposarcoma is not clear. Coulibaly *et al*^[19] reported a patient with mediastinal dedifferentiated liposarcoma, who underwent complete surgery with a DFS of 15 mo. The patient received repeat surgery and adjuvant radiotherapy with a DFS of 96 mo, and died 3 mo later. The survival time of the patient was 114 mo. This is the longest survival time in the literature. Hahn *et al*^[21] studied 24 cases of mediastinal liposarcoma, including eight cases of dedifferentiated liposarcoma. In the last follow-up, four patients were alive with no evidence of disease with a median DFS of 51.5 mo, and one patient died of unrelated disease with a survival time of 5 mo. In this study, of the 39 cases, there were 21 cases alive with no evidence of disease with a mean DFS of 29.8 mo, and five patients died of the disease with a mean survival time of 42.3 mo. However, as mentioned above, local recurrence was common, with 13 (13/39, 33.3%) cases developing recurrent tumors after a mean interval of 24.5 mo. The mean tumor size of ten patients with recurrence was 24.5 ± 17.3 cm, and that of 16 patients without recurrence was 17.1 ± 9.6 cm. The difference was statistically significant between the two groups. According to our literature review, we speculated tumor size to be one of the risk factors for tumor recurrence, whereas gender, tumor location and symptoms are not. Therefore, we speculate that complete surgical resection and tumor size are associated with recurrence and prognosis, and complete resection should be attempted if possible.

PET/CT and SUVmax were widely used to evaluate the tumor characteristics. In this case, the SUVmax results of the tumor was 1.8 and relatively low. Miura *et al*^[2] reported two cases of mediastinal dedifferentiated liposarcoma with a low SUVmax result, and three cases with a high SUVmax result. Therefore, it seems that PET/CT cannot reliably identify mediastinal dedifferentiated liposarcoma. Meanwhile, we found the ki-67 index to be 5%, which was relatively low and consistent with the low SUVmax result. Thus, we speculate that SUVmax and Ki-67 may be used as prognostic indicators in mediastinal dedifferentiated liposarcoma.

CONCLUSION

In summary, we described a case of primary multifocal and recurrent mediastinal dedifferentiated liposarcoma treated by combining surgery with ^{125}I brachytherapy, as well as a review of the literature. We suggest that surgical resection provides beneficial effects for dedifferentiated liposarcoma in mediastinum, even in cases with local recurrence. ^{125}I brachytherapy may be beneficial for recurrent unresectable patients.

REFERENCES

- 1 **Dei Tos AP**, Pedetour F, Marino-Enriquez A, Rossi S. Dedifferentiated liposarcoma in World Health Organization classification of tumours pathology and genetics of tumours of soft tissue and bone. Fletcher CDM, Bridge JA, Hogendoorn PCW, Mertens F, editor. Lyon: IARC Press 2013; 39
- 2 **Miura K**, Hamanaka K, Matsuoka S, Takeda T, Agatsuma H, Hyogotani A, Ito KI, Nishimaki F, Koizumi T, Uehara T. Primary mediastinal dedifferentiated liposarcoma: Five case reports and a review. *Thorac Cancer* 2018; 9: 1733-1740 [PMID: 30329218 DOI: 10.1111/1759-7714.12888]
- 3 **Evans HL**. Liposarcoma: a study of 55 cases with a reassessment of its classification. *Am J Surg Pathol* 1979; 3: 507-523 [PMID: 534388 DOI: 10.1097/0000478-197912000-00004]
- 4 **Thway K**, Jones RL, Noujaim J, Zaidi S, Miah AB, Fisher C. Dedifferentiated Liposarcoma: Updates on Morphology, Genetics, and Therapeutic Strategies. *Adv Anat Pathol* 2016; 23: 30-40 [PMID: 26645460 DOI: 10.1097/PAP.000000000000101]
- 5 **Weaver HL**, Preston SD, Wong HH, Jani P, Coonar AS. Surgical resection of a massive primary

- mediastinal liposarcoma with cervical extension. *Ann R Coll Surg Engl* 2018; **100**: e22-e27 [PMID: 29182001 DOI: 10.1308/rcsann.2017.0163]
- 6 Soeroso NN, Pradana A, Djaka M, Ayudika M, Ngadimin S, Soeroso L. An unusual case of recurrent huge primary mediastinal dedifferentiated liposarcoma. *Int J Surg Case Rep* 2018; **50**: 140-143 [PMID: 30121443 DOI: 10.1016/j.ijscr.2018.07.037]
 - 7 Kim SY, Froelich JJ, Dawson H, Peters AA, Tappero C, Heverhagen JT. Inflammatory calcified dedifferentiated liposarcoma of the anterior mediastinum. *ANZ J Surg* 2019; **89**: 1326-1327 [PMID: 29885206 DOI: 10.1111/ans.14697]
 - 8 Sbrana F, Ugolini C, Taddei C, Ali G, Pasanisi EM. Mediastinal dedifferentiated liposarcoma. *Acta Cardiol* 2017; **72**: 499-500 [PMID: 28707566 DOI: 10.1080/00015385.2017.1335460]
 - 9 Muthukumar S, Rajendiran S, Damodharan J. Primary dedifferentiated massive mediastinal liposarcoma weighing 5.3 kg. *Asian Cardiovasc Thorac Ann* 2017; **25**: 472-473 [PMID: 27225397 DOI: 10.1177/0218492316652058]
 - 10 Mansuet-Lupo A, Lococo F, Larousserie F, Alifano M, Saliceti R. Dedifferentiated primary mediastinal liposarcoma mimicking a thymic tumor. *Pathologica* 2017; **109**: 401-404 [PMID: 29449733]
 - 11 Narasimman S, Jasjit SN, Navarasi SR, Premnath N. A dedifferentiated large posterior mediastinal liposarcoma - An incidental finding successfully resected. *Med J Malaysia* 2016; **71**: 201-202 [PMID: 27770120]
 - 12 Harth S, Litzlbauer HD, Behrens CB, Roller FC, Gamerding U, Burchert D, Krombach GA. Dedifferentiated Liposarcoma of the Anterior Mediastinum: A Rare Case. *Rofa* 2016; **188**: 95-97 [PMID: 26252913 DOI: 10.1055/s-0035-1553367]
 - 13 Hamanaka K, Ohashi M, Nakamura T. Primary mediastinal dedifferentiated liposarcoma resected by lateral thoracotomy with video-assisted thoracoscopic surgery. *J Surg Case Rep* 2016; **2016** [PMID: 26724326 DOI: 10.1093/jscr/rjv163]
 - 14 Fujimoto R, Sato M, Miyata R, Minakata K, Omasa M, Kubo T, Date H. Successful resection of recurrent mediastinal liposarcoma using preoperative evaluation of organ invasion by four-dimensional computed tomography. *Gen Thorac Cardiovasc Surg* 2016; **64**: 488-491 [PMID: 25528654 DOI: 10.1007/s11748-014-0510-y]
 - 15 Ortega P, Suster D, Falconieri G, Zambrano E, Moran CA, Morrison C, Suster S. Liposarcomas of the posterior mediastinum: clinicopathologic study of 18 cases. *Mod Pathol* 2015; **28**: 721-731 [PMID: 25475695 DOI: 10.1038/modpathol.2014.152]
 - 16 Chen M, Yang J, Zhu L, Zhou C, Zhao H. Primary intrathoracic liposarcoma: a clinicopathologic study and prognostic analysis of 23 cases. *J Cardiothorac Surg* 2014; **9**: 119 [PMID: 24993036 DOI: 10.1186/1749-8090-9-119]
 - 17 Boland JM, Colby TV, Folpe AL. Liposarcomas of the mediastinum and thorax: a clinicopathologic and molecular cytogenetic study of 24 cases, emphasizing unusual and diverse histologic features. *Am J Surg Pathol* 2012; **36**: 1395-1403 [PMID: 22895273 DOI: 10.1097/PAS.0b013e3182562bc1]
 - 18 Fukai R, Fukumura Y, Suzuki K. A dedifferentiated liposarcoma of the anterior mediastinum. *Int J Clin Oncol* 2009; **14**: 174-177 [PMID: 19390952 DOI: 10.1007/s10147-008-0819-6]
 - 19 Coulibaly B, Bouvier C, Payan MJ, Thomas P. Recurrent dedifferentiated liposarcoma of mediastinum involving lung and pleura. *Interact Cardiovasc Thorac Surg* 2009; **9**: 741-742 [PMID: 19589790 DOI: 10.1510/icvts.2009.209494]
 - 20 Hirai S, Hamanaka Y, Mitsui N, Uegami S, Matsuura Y. Surgical resection of primary liposarcoma of the anterior mediastinum. *Ann Thorac Cardiovasc Surg* 2008; **14**: 38-41 [PMID: 18292740]
 - 21 Hahn HP, Fletcher CD. Primary mediastinal liposarcoma: clinicopathologic analysis of 24 cases. *Am J Surg Pathol* 2007; **31**: 1868-1874 [PMID: 18043041 DOI: 10.1097/PAS.0b013e318093f925]
 - 22 Evans HL, Khurana KK, Kemp BL, Ayala AG. Heterologous elements in the dedifferentiated component of dedifferentiated liposarcoma. *Am J Surg Pathol* 1994; **18**: 1150-1157 [PMID: 7943536 DOI: 10.1097/00000478-199411000-00009]
 - 23 Benchetrit M, Hofman V, Vénissac N, Brennetot C, Italiano A, Aurias A, Padovani B, Pedetour F, Hofman P. Dedifferentiated liposarcoma of the pleura mimicking a malignant solitary fibrous tumor and associated with dedifferentiated liposarcoma of the mediastinum: usefulness of cytogenetic and molecular genetic analyses. *Cancer Genet Cytogenet* 2007; **179**: 150-155 [PMID: 18036404 DOI: 10.1016/j.cancergencyto.2007.09.006]
 - 24 Toda M, Izumi N, Tsukioka T, Komatsu H, Okada S, Hara K, Ito R, Shibata T, Nishiyama N. Huge mediastinal liposarcoma resected by clamshell thoracotomy: a case report. *Surg Case Rep* 2017; **3**: 16 [PMID: 28105611 DOI: 10.1186/s40792-017-0291-5]
 - 25 Yang B, Guo WH, Lan T, Yuan F, Liu GJ, Zan RY, You X, Tan QY, Liao ZY. CT-guided ¹²⁵I seed implantation for inoperable retroperitoneal sarcoma: A technique for delivery of local tumor brachytherapy. *Exp Ther Med* 2016; **12**: 3843-3850 [PMID: 28101168 DOI: 10.3892/etm.2016.3897]
 - 26 Mo Z, Zhang T, Zhang Y, Xiang Z, Yan H, Zhong Z, Gao F, Zhang F. Feasibility and clinical value of CT-guided ¹²⁵I brachytherapy for metastatic soft tissue sarcoma after first-line chemotherapy failure. *Eur Radiol* 2018; **28**: 1194-1203 [PMID: 28956119 DOI: 10.1007/s00330-017-5036-0]



Published By Baishideng Publishing Group Inc
7041 Koll Center Parkway, Suite 160, Pleasanton, CA 94566, USA
Telephone: +1-925-3991568
E-mail: bpgoffice@wjgnet.com
Help Desk: <https://www.f6publishing.com/helpdesk>
<https://www.wjgnet.com>

