

# World Journal of *Clinical Cases*

*World J Clin Cases* 2020 April 26; 8(8): 1343-1560





### GUIDELINES

- 1343** Prevention program for the COVID-19 in a children's digestive endoscopy center  
*Ma XP, Wang H, Bai DM, Zou Y, Zhou SM, Wen FQ, Dai DL*

### REVIEW

- 1350** Predictive factors for central lymph node metastases in papillary thyroid microcarcinoma  
*Wu X, Li BL, Zheng CJ, He XD*
- 1361** Probiotic mixture VSL#3: An overview of basic and clinical studies in chronic diseases  
*Cheng FS, Pan D, Chang B, Jiang M, Sang LX*

### MINIREVIEWS

- 1385** Hypertransaminasemia in the course of infection with SARS-CoV-2: Incidence and pathogenetic hypothesis  
*Zippi M, Fiorino S, Occhigrossi G, Hong W*
- 1391** Stability and infectivity of coronaviruses in inanimate environments  
*Ren SY, Wang WB, Hao YG, Zhang HR, Wang ZC, Chen YL, Gao RD*
- 1400** Status, challenges, and future prospects of stem cell therapy in pelvic floor disorders  
*Cheng J, Zhao ZW, Wen JR, Wang L, Huang LW, Yang YL, Zhao FN, Xiao JY, Fang F, Wu J, Miao YL*

### ORIGINAL ARTICLE

#### Retrospective Study

- 1414** Bedside score predicting retained common bile duct stone in acute biliary pancreatitis  
*Khoury T, Kadah A, Mahamid M, Mari A, Sbeit W*

#### Observational Study

- 1424** Clinicopathological differences and correlations between right and left colon cancer  
*Kalantzis I, Nonni A, Pavlakis K, Delicha EM, Miltiadou K, Kosmas C, Ziras N, Gkoumas K, Gakiopoulou H*
- 1444** Hemodynamic characteristics in preeclampsia women during cesarean delivery after spinal anesthesia with ropivacaine  
*Zhao N, Xu J, Li XG, Walline JH, Li YC, Wang L, Zhao GS, Xu MJ*

### CASE REPORT

- 1454** Mucosa-associated lymphoid tissue lymphoma simulating Crohn's disease: A case report  
*Stundiene I, Maksimaityte V, Liakina V, Valantinas J*

- 1463** Suicide attempt using potassium tablets for congenital chloride diarrhea: A case report  
*Iijima S*
- 1471** Embolization of pancreatic arteriovenous malformation: A case report  
*Yoon SY, Jeon GS, Lee SJ, Kim DJ, Kwon CI, Park MH*
- 1477** Novel frameshift mutation in the SACS gene causing spastic ataxia of charlevoix-saguenay in a consanguineous family from the Arabian Peninsula: A case report and review of literature  
*Al-Ajmi A, Shamsah S, Janicijevic A, Williams M, Al-Mulla F*
- 1489** Duodenal mature teratoma causing partial intestinal obstruction: A first case report in an adult  
*Chansoon T, Angkathunyakul N, Aroonroch R, Jirasiritham J*
- 1495** Rare anaplastic sarcoma of the kidney: A case report  
*Kao JL, Tsung SH, Shiao CC*
- 1502** Unusual association of Axenfeld-Rieger syndrome and wandering spleen: A case report  
*Chang YL, Lin J, Li YH, Tsao LC*
- 1507** Primary cutaneous mantle cell lymphoma: Report of a rare case  
*Zheng XD, Zhang YL, Xie JL, Zhou XG*
- 1515** Typical ulcerative colitis treated by herbs-partitioned moxibustion: A case report  
*Lin YY, Zhao JM, Ji YJ, Ma Z, Zheng HD, Huang Y, Cui YH, Lu Y, Wu HG*
- 1525** Bronchogenic cyst of the stomach: A case report  
*He WT, Deng JY, Liang H, Xiao JY, Cao FL*
- 1532** Laparoscopic umbilical trocar port site endometriosis: A case report  
*Ao X, Xiong W, Tan SQ*
- 1538** Unusual presentation of congenital radioulnar synostosis with osteoporosis, fragility fracture and nonunion: A case report and review of literature  
*Yang ZY, Ni JD, Long Z, Kuang LT, Tao SB*
- 1547** Hydatidiform mole in a scar on the uterus: A case report  
*Jiang HR, Shi WW, Liang X, Zhang H, Tan Y*
- 1554** Pulmonary contusion mimicking COVID-19: A case report  
*Chen LR, Chen ZX, Liu YC, Peng L, Zhang Y, Xu Q, Lin Q, Tao YM, Wu H, Yin S, Hu YJ*

**ABOUT COVER**

Editorial Board Member of *World Journal of Clinical Cases*, Steven M Schwarz, MD, Professor, Department of Pediatrics, SUNY-Downstate Medical Center, Brooklyn, NY 11203, United States

**AIMS AND SCOPE**

The primary aim of *World Journal of Clinical Cases* (WJCC, *World J Clin Cases*) is to provide scholars and readers from various fields of clinical medicine with a platform to publish high-quality clinical research articles and communicate their research findings online.

WJCC mainly publishes articles reporting research results and findings obtained in the field of clinical medicine and covering a wide range of topics, including case control studies, retrospective cohort studies, retrospective studies, clinical trials studies, observational studies, prospective studies, randomized controlled trials, randomized clinical trials, systematic reviews, meta-analysis, and case reports.

**INDEXING/ABSTRACTING**

The WJCC is now indexed in PubMed, PubMed Central, Science Citation Index Expanded (also known as SciSearch®), and Journal Citation Reports/Science Edition. The 2019 Edition of Journal Citation Reports cites the 2018 impact factor for WJCC as 1.153 (5-year impact factor: N/A), ranking WJCC as 99 among 160 journals in Medicine, General and Internal (quartile in category Q3).

**RESPONSIBLE EDITORS FOR THIS ISSUE**

Responsible Electronic Editor: Ji-Hong Liu

Proofing Production Department Director: Xiang Li

Responsible Editorial Office Director: Jin-Lai Wang

**NAME OF JOURNAL**

*World Journal of Clinical Cases*

**ISSN**

ISSN 2307-8960 (online)

**LAUNCH DATE**

April 16, 2013

**FREQUENCY**

Semimonthly

**EDITORS-IN-CHIEF**

Dennis A Bloomfield, Bao-Gan Peng, Sandro Vento

**EDITORIAL BOARD MEMBERS**

<https://www.wjgnet.com/2307-8960/editorialboard.htm>

**PUBLICATION DATE**

April 26, 2020

**COPYRIGHT**

© 2020 Baishideng Publishing Group Inc

**INSTRUCTIONS TO AUTHORS**

<https://www.wjgnet.com/bpg/gerinfo/204>

**GUIDELINES FOR ETHICS DOCUMENTS**

<https://www.wjgnet.com/bpg/GerInfo/287>

**GUIDELINES FOR NON-NATIVE SPEAKERS OF ENGLISH**

<https://www.wjgnet.com/bpg/gerinfo/240>

**PUBLICATION ETHICS**

<https://www.wjgnet.com/bpg/GerInfo/288>

**PUBLICATION MISCONDUCT**

<https://www.wjgnet.com/bpg/gerinfo/208>

**ARTICLE PROCESSING CHARGE**

<https://www.wjgnet.com/bpg/gerinfo/242>

**STEPS FOR SUBMITTING MANUSCRIPTS**

<https://www.wjgnet.com/bpg/GerInfo/239>

**ONLINE SUBMISSION**

<https://www.f6publishing.com>

## Hydatidiform mole in a scar on the uterus: A case report

Hao-Ru Jiang, Wen-Wei Shi, Xiao Liang, Hui Zhang, Yan Tan

**ORCID number:** Hao-Ru Jiang (0000-0003-1811-3241); Wen-Wei Shi (0000-0003-2173-2043); Xiao Liang (0000-0003-4809-0685); Hui Zhang (0000-0002-0565-0411); Yan Tan (0000-0002-7529-9807).

**Author contributions:** Shi WW collected the data; Jiang HR reviewed the literature and contributed to drafting the manuscript; Liang X performed the histopathological and immunohistochemical analyses; Zhang H and Tan Y revised the manuscript.

**Supported by** National Natural Science Foundation of China (General Program), No. 81971593, No. 81771824, and No. 81701681; Precision Medicine Key Innovation Team Project, No. YT1601; Social Development Projects of Key R&D Program in Shanxi Province, No. 201703D321016; and Youth Innovation Fund, No. YC1426.

**Informed consent statement:** Informed written consent was obtained from the patient for publication of this report and any accompanying images.

**Conflict-of-interest statement:** The authors declare that they have no conflict of interest.

**CARE Checklist (2016) statement:** The authors have read the CARE Checklist (2016), and the manuscript was prepared and revised according to the CARE Checklist (2016).

**Open-Access:** This article is an open-access article that was selected by an in-house editor and fully peer-reviewed by external reviewers. It is distributed in accordance with the Creative

**Hao-Ru Jiang, Wen-Wei Shi, Xiao Liang,** College of Medical Imaging, Shanxi Medical University, Taiyuan 030001, Shanxi Province, China

**Hui Zhang, Yan Tan,** Department of Radiology, First Clinical Medical College, Shanxi Medical University, Taiyuan 030001, Shanxi Province, China

**Corresponding author:** Yan Tan, MD, Professor, Department of Radiology, First Clinical Medical College, Shanxi Medical University, 85 Jiefang South Road, Taiyuan 030001, Shanxi Province, China. [tanyan123456@sina.com](mailto:tanyan123456@sina.com)

### Abstract

#### BACKGROUND

Cesarean scar molar pregnancy is extremely rare, but the incidence has been rising due to the continuous increase in the rate of cesarean section. The presence of a hydatidiform mole in the scar left on the uterus by the procedure may lead to severe complications. We performed a literature review and found only seven reported cases of cesarean scar molar pregnancy. Accurate diagnosis and appropriate treatment are extremely important for the patients' prognosis.

#### CASE SUMMARY

A 35-year-old woman, gravida 4, para 1, complained of vaginal bleeding lasting more than 1 mo and amenorrhea lasting more than 2 mo. The patient's serum human chorionic gonadotropin was 4287800 IU/L. Ultrasound showed a 11.5 cm × 7.5 cm mass at the anterior lower wall of the uterus. The patient underwent suction evacuation, and partial grape-like tissue mixed with blood clots was removed. Uterine arterial embolization was performed to control intraoperative and postoperative bleeding. Histological examination confirmed the presence of a hydatidiform mole in uterine scar. After surgery, there was still a mass with heterogeneous intensity near the isthmus of the uterus on magnetic resonance imaging. The patient then underwent chemotherapy. During the 6-mo follow-up period, the mass disappeared and the serum human chorionic gonadotropin level gradually decreased to normal level.

#### CONCLUSION

We report a case of cesarean scar molar pregnancy successfully cured by comprehensive treatment. We found that cesarean scar molar pregnancy was subject to intraoperative bleeding, and uterine arterial embolization before surgery may be helpful.

**Key words:** Hydatidiform mole; Cesarean scar pregnancy; Comprehensive treatment; Case report; Magnetic resonance imaging; Literature review



Commons Attribution  
NonCommercial (CC BY-NC 4.0)  
license, which permits others to  
distribute, remix, adapt, build  
upon this work non-commercially,  
and license their derivative works  
on different terms, provided the  
original work is properly cited and  
the use is non-commercial. See:  
<http://creativecommons.org/licenses/by-nc/4.0/>

**Manuscript source:** Invited  
Conference Manuscripts

**Received:** January 24, 2020

**Peer-review started:** January 24,  
2020

**First decision:** February 26, 2020

**Revised:** April 3, 2020

**Accepted:** April 8, 2020

**Article in press:** April 8, 2020

**Published online:** April 26, 2020

**P-Reviewer:** Isik A, Sel G,  
Vagholkar K

**S-Editor:** Wang YQ

**L-Editor:** Wang TQ

**E-Editor:** Zhang YL



©The Author(s) 2020. Published by Baishideng Publishing Group Inc. All rights reserved.

**Core tip:** We here report a case of cesarean scar molar pregnancy cured by comprehensive treatment including suction evacuation, uterine arterial embolization, and chemotherapy. We also performed a literature review and found that most cases of cesarean scar molar pregnancy were associated with intraoperative bleeding. Uterine arterial embolization might help prevent massive bleeding if used before surgery.

**Citation:** Jiang HR, Shi WW, Liang X, Zhang H, Tan Y. Hydatidiform mole in a scar on the uterus: A case report. *World J Clin Cases* 2020; 8(8): 1547-1553

**URL:** <https://www.wjgnet.com/2307-8960/full/v8/i8/1547.htm>

**DOI:** <https://dx.doi.org/10.12998/wjcc.v8.i8.1547>

## INTRODUCTION

Cesarean scar pregnancy is a rare type of ectopic pregnancy, which means that the gestational sac is implanted in the myometrium at the site of a previous cesarean section<sup>[1]</sup>. Hydatidiform mole pregnancy embedded in cesarean scars is also extremely rare<sup>[2-5]</sup>. It can lead to severe complications, such as uterine rupture, hemorrhage, and maternal death<sup>[6]</sup>. Here, we report a case of cesarean scar molar pregnancy cured by comprehensive treatment and summarize its clinicopathologic and imaging characteristics based on the previous literature.

## CASE PRESENTATION

### Chief complaints

A 35-year-old woman complained of vaginal bleeding lasting more than 1 mo and amenorrhea lasting more than 2 mo.

### History of present illness

The patient usually had a regular menstrual period lasting 7 d on a 26-d cycle with no dysmenorrhea. There was no obvious cause of continuous vaginal bleeding at any point in the 2 mo leading up to treatment. There were no early pregnancy reactions such as nausea or vomiting and no discomfort such as lower abdominal pain, dizziness, or fatigue. The patient had normal appetite, sleep, and urination despite the bleeding, and she had no weight loss.

### History of past illness

The patient had undergone three previous surgical terminations of pregnancy, 10, 6, and 2 years prior, respectively, and one cesarean delivery 10 years prior (gravida 4, para 1).

### Physical examination

Physical examination showed a markedly enlarged uterus.

### Laboratory examinations

Upon admission, the serum human chorionic gonadotropin (HCG) and  $\beta$ -HCG levels were 4287800 IU/L and 1512540 IU/L, respectively. After suction evacuation under ultrasound guidance and uterine arterial embolization, the HCG and  $\beta$ -HCG levels were 187780 and 66312 IU/L, respectively. Two weeks later, the patient underwent seven cycles of chemotherapy with fluorouracil (5-Fu) and kengshemycin (KSM) once every 3 wk. After the third cycle, the HCG and  $\beta$ -HCG levels were 29540 and 8869 IU/L, respectively. After the sixth cycle, the HCG and  $\beta$ -HCG levels were 381.8 and 115 IU/L, respectively. After the seventh cycle, the  $\beta$ -HCG level was 38.7 IU/L. The HCG/ $\beta$ -HCG level had dropped to normal after 6 wk.

### Imaging examinations

At admission, ultrasound indicated a 11.5 cm  $\times$  7.5 cm mass at the anterior lower wall of the uterus, in which an anechoic 5.1 cm  $\times$  2.8 cm area was noted inside; the echo of the myometrium was heterogeneous. Ten days after embolization, magnetic resonance imaging (MRI) (Figure 1) demonstrated that there was still a mass

measuring 6.7 cm × 6.5 cm × 6.0 cm in the proximal isthmus. The lesion showed heterogeneous intensity on both T1-weighted image (WI) and T2WI, heterogeneous hyperintensity on diffusion-weighted image, and hypointensity on apparent diffusion coefficient maps. The mass showed mild rim enhancement in the arterial phase and continued enhancement in the venous and delayed phases; multiple distorted vascular masses were seen in the anterior wall of the uterus. After the sixth cycle of chemotherapy, MRI (Figure 2) showed that the lesion was visibly diminished in size.

## FINAL DIAGNOSIS

Histological examination confirmed the diagnosis of hydatidiform mole in a uterine scar (Figure 3).

## TREATMENT

The patient underwent a suction evacuation using the No. 8 suction tube (MKL, Suzhou, China) under ultrasound guidance. Abundant grape-like tissue mixed with blood clots was shaved out, but there was a massive hemorrhage during and after the operation. Therefore, the patient was infused with concentrated erythrocyte 4 U and fresh frozen plasma 400 mL, and a Foley catheter balloon was used to restrain blood loss for more than 10 min. Also, emergency uterine arterial embolization was performed to control active bleeding. The Seldinger technique was applied to puncture and catheterize the bilateral internal iliac arteries through the right femoral artery, and the procedure was performed under local anaesthesia. Angiography confirmed that the vessels were uncomplete, tortuous, and disordered. Thus, superselective embolization of both uterine arteries was performed using gelatin sponge granules. Postembolization angiography showed no obvious bleeding. The hemoglobin level was 22 g/L and 48 g/L before and after the embolization, respectively. Then, the patient underwent seven cycles of chemotherapy with 5-Fu and KSM.

## OUTCOME AND FOLLOW-UP

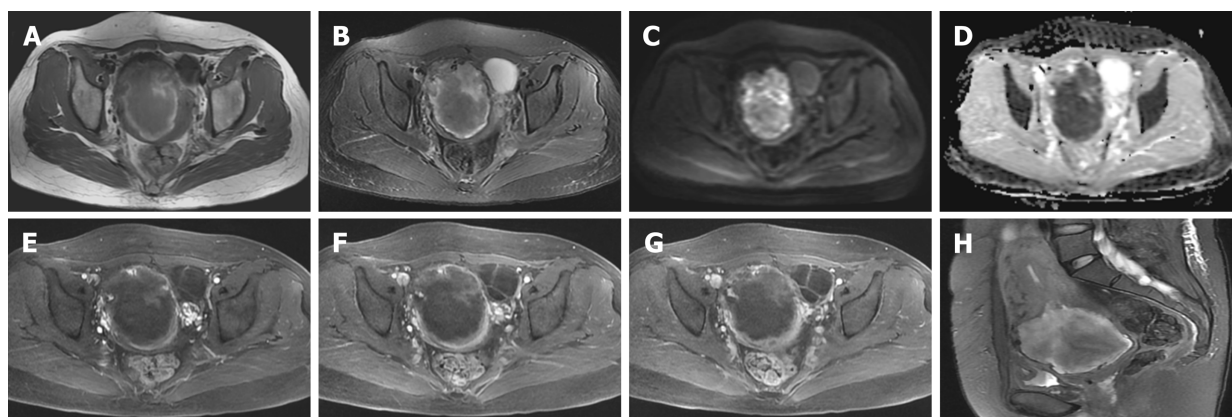
During the 6-mo follow-up period, the mass disappeared and the serum HCG gradually decreased to normal level, and the patient had no complaint.

## DISCUSSION

Cesarean scar molar pregnancy is extremely rare, but the incidence has been rising due to the continuous increase in the rate of cesarean section<sup>[2]</sup>. The myometrium of the uterus usually thins and merges with the thin and fibrous scar after caesarean section, so hydatidiform moles in the uterine scar may have severe complications, such as uterine rupture, hemorrhage, hysterectomy, and serious maternal morbidity<sup>[6]</sup>.

To our knowledge, only seven cases have been reported, including one case of cesarean scar invasive molar pregnancy<sup>[3]</sup>, four cases of partial molar pregnancy<sup>[2,4,5,7]</sup>, one case of complete molar pregnancy<sup>[8]</sup>, and one case in which the author did not specify the type<sup>[9]</sup>. Clinicopathological features of the eight cases including our case are listed in Table 1. Among these cases, the median maternal age was 34 years (range from 28 to 44 years) with a median gravidity of 4 (range from 2 to 8) and at least one parity. All patients had at least two prior uterine curettages. The concentration of HCG/ $\beta$ -HCG also increased abnormally. The clinical manifestations were not fully identical, but the most common symptom was vaginal bleeding for more than 1 mo (6/8 cases, 75%). Other presentations include symptoms of pregnancy<sup>[2]</sup>, abdominal pain<sup>[3]</sup>, and amenorrhea<sup>[5]</sup>, and only one patient was asymptomatic on admission<sup>[8]</sup>.

To date, MRI has not been used very often in the diagnosis of hydatidiform mole embedded in the scar on the uterus. Only two cases have been reported: One was an ectopic molar pregnancy, which showed isointensity on T1WI, hyperintensity on T2WI, and distinct contrast enhancement<sup>[10]</sup>, and the other was a cesarean scar molar pregnancy, which showed a low signal on T1WI and heterogeneous high signal on T2WI, and the myometrium of the anterior wall of the uterine isthmus incision was not continuous<sup>[5]</sup>. All three cases showed different signals on T1WI and T2WI, which could be caused by hemorrhage or cystic components. Ash *et al*<sup>[6]</sup> stated that MRI could be used to show the gestational sac embedded in the anterior lower uterine



**Figure 1** Magnetic resonance imaging demonstrated an irregular mass in the proximal isthmus. A: The lesion was hypointense to hyperintense on T1-weighted image; B: The lesion was hypointense to hyperintense on T2-weighted image; C: Heterogeneous hyperintensity was seen on diffusion-weighted image; D: The lesion was hypointense on apparent diffusion coefficient maps; E: Gadolinium-enhanced magnetic resonance imaging indicated that the edge of the mass was enhanced in the arterial phase; F and G: The edge of the mass was persistently enhanced in the venous and delayed phases; H: Sagittal T2-weighted image showing localized widening of the upper cervical canal.

segment, evaluate pelvic anatomy, improve intra-operative orientation, and assess the possibility of myometrial invasion. Whether MRI is available to the application of hydatidiform mole in the scar of uterus remains to be further studied.

In histopathology, invasive mole often presents molar villi in the myometrium and vascular permeation, while hydatidiform mole usually presents mildly or markedly hydropic villous swelling with central cistern formation<sup>[11]</sup>. Missaoui *et al*<sup>[12]</sup> found that p57 KIP2 expression was present in partial hydatidiform mole, and the expression of p53 and Ki-67 could reflect the pathological development of hydatidiform mole. This may be helpful to the diagnosis of hydatidiform moles. Among all cases, only one patient underwent immunohistochemical examination with positive p57 expression and proliferation index (Ki-67) of trophocytes of 10%<sup>[9]</sup>.

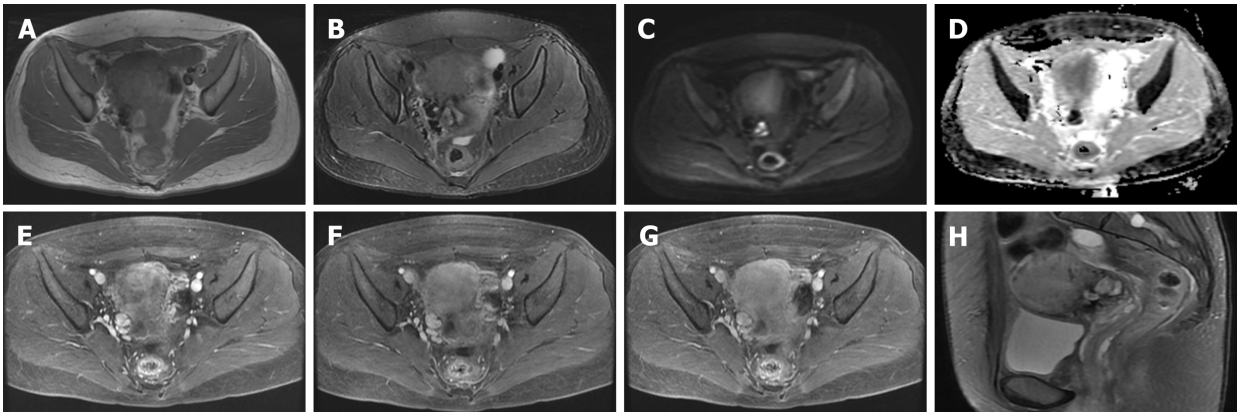
Gestational trophoblastic disease (GTD) includes the tumour spectrum of hydatidiform mole (complete and partial), invasive mole, choriocarcinoma, and placental-site trophoblastic tumour. Recently, the majority of all the reported cases of cesarean scar GTD are molar pregnancy, and only two cases of cesarean scar choriocarcinoma have been described. Sorbi *et al*<sup>[13]</sup> reported a case of cervical choriocarcinoma that had been misdiagnosed as a cesarean scar ectopic pregnancy in 2013. The patient was admitted to hospital for irregular vaginal bleeding of 10 d duration and suprapubic pain. Qian *et al*<sup>[14]</sup> revealed a second case of cesarean scar choriocarcinoma, which was also misdiagnosed as a normal cesarean scar pregnancy in 2014. The patient complained amenorrhea for 47 d and irregular vaginal bleeding for half a month. The rarity and non-specific clinical signs and symptoms of this disease highlight the importance of early consideration of choriocarcinoma when suspecting a GTD in the cesarean scar.

So far, there has been no definitive consensus regarding the treatment of cesarean scar molar pregnancy<sup>[2]</sup>. Based on our literature review, two cases were treated by suction evacuation, one case was managed with methotrexate, one case was treated with methotrexate and hysterectomy, two cases were cured by suction evacuation and uterine arterial embolization, one case was treated by hysterectomy, and our patient was treated by suction evacuation, uterine arterial embolization, and chemotherapy. In all cases, except for one patient who was lost to follow-up<sup>[9]</sup>, the levels of HCG/ $\beta$ -HCG returned to normal and no corresponding complications occurred. In our case, the HCG decreased visibly after surgery and declined to normal after subsequent chemotherapy. However, intraoperative hemorrhage took place. This involves a high risk of hysterectomy and maternal death, and subsequent uterine arterial embolization was performed.

## CONCLUSION

In conclusion, we have documented a case of cesarean scar molar pregnancy successfully cured by comprehensive treatment including suction evacuation, uterine arterial embolization, and chemotherapy. We also performed a literature review and found that MRI was only rarely used in the diagnosis of hydatidiform moles. We also found that most cases of cesarean scar molar pregnancy are associated with





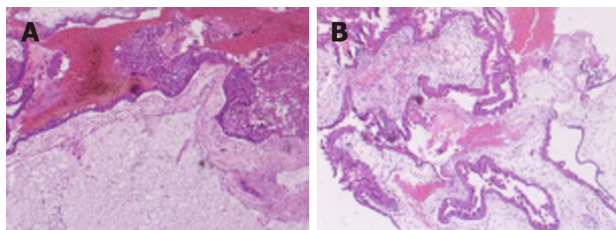
**Figure 2 Magnetic resonance imaging of the lesion after treatment.** The mass was obviously diminished after treatment (compared with [Figure 1](#)). A: The lesion was isointense to hyperintense on T1-weighted image; B: The lesion was isointense on T2-weighted image; C: Heterogeneous hyperintensity was seen on diffusion-weighted image; D: The lesion was obviously hypointense on apparent diffusion coefficient maps; E: Gadolinium-enhanced MRI indicated that the lesion was enhanced in the arterial phase; F and G: The edge of the lesion was still persistently enhanced in the venous and delayed phases; H: Sagittal T2-weighted image displaying localized widening of the upper cervical canal.

intraoperative bleeding, and uterine arterial embolization before surgery might help to prevent massive bleeding.

**Table 1** Summary of reported cases of molar pregnancy in prior cesarean scar

Ref.	Age (yr)	Presentation	Gravida/para	HCG (IU/L)	Diagnostic method	Treatment
Wu <i>et al</i> <sup>[4]</sup> , 2006	31	Persistent symptoms	8/1	61798 (β-HCG)	Ultrasound, pathology	Dilation and curettage
Michener <i>et al</i> <sup>[9]</sup> , 2009	33	Vaginal hemorrhage	5/3	161 (β-HCG)	Emergency hysterectomy	Intragastric sac MTX injection
Jin <i>et al</i> <sup>[7]</sup> , 2011	44	Vaginal bleeding, lower abdominal pain	4/2	94724 (β-HCG)	Transvaginal sonography, pathology	Suction curettage
Ko <i>et al</i> <sup>[2]</sup> , 2012	34	Persistent symptoms of pregnancy	4/2	21925 (HCG)	Ultrasound, pathology	Suction evacuation, uterine arterial embolization
Kaluarachchi <i>et al</i> <sup>[8]</sup> , 2013	40	Asymptomatic	4/2	6743 (β-HCG)	Laparotomy	Hysterectomy
Vimercati <i>et al</i> <sup>[3]</sup> , 2016	34	Abdominal pain and vaginal bleeding	4/1	51547 (β-HCG)	Ultrasound, pathology	Local and systemic MTX, resection of the uterine
Ling <i>et al</i> <sup>[5]</sup> , 2018	28	Abdominal pain, vaginal bleeding, amenorrhea	3/1	7984 (HCG)	Ultrasound, MRI, pathology	Uterine arterial embolization, suction evacuation
Present case	35	Vaginal bleeding, menopause	4/1	1515540 (β-HCG)	Ultrasound, MRI, pathology	Suction evacuation, uterine arterial embolization, chemotherapy

HCG: Human chorionic gonadotropin; MRI: Magnetic resonance imaging; MTX: Methotrexate.



**Figure 3** Pathological images. A: Hematoxylin-eosin staining revealed mild or moderate hyperplasia of placental villus trophoblasts (magnification, ×100); B: Hematoxylin-eosin staining showed interstitial edema and central pool formation (magnification, ×100).

## ACKNOWLEDGEMENTS

We thank the Gynaecology and Obstetrics Department of the First Hospital of Shanxi Medical University for providing the case information and the assistance of the patient.

## REFERENCES

- Sel G, Sucu S, Harma M, Harma Mİ. Successful management of cesarean scar pregnancy with vacuum extraction under ultrasound guidance. *Acute Med Surg* 2018; **5**: 358-361 [PMID: 30338082 DOI: 10.1002/ams2.362]
- Ko JK, Wan HL, Ngu SF, Cheung VY, Ng EH. Cesarean scar molar pregnancy. *Obstet Gynecol* 2012; **119**: 449-451 [PMID: 22270435 DOI: 10.1097/AOG.0b013e3182322f31]
- Vimercati A, de Gennaro AC, Resta L, Cormio G, Cicinelli E. Sonographic and Power Doppler Evaluation of an Invasive Mole Located in a Cesarean Scar Pregnancy. *J Ultrasound Med* 2016; **35**: 1608-1612 [PMID: 27353688 DOI: 10.7863/ultra.15.08010]
- Wu CF, Hsu CY, Chen CP. Ectopic molar pregnancy in a cesarean scar. *Taiwan J Obstet Gynecol* 2006; **45**: 343-345 [PMID: 17175496 DOI: 10.1016/S1028-4559(09)60257-6]
- Ling C, Zhao J, Qi X. Partial molar pregnancy in the cesarean scar: A case report and literature review. *Medicine (Baltimore)* 2018; **97**: e11312 [PMID: 29953018 DOI: 10.1097/MD.00000000000011312]
- Ash A, Smith A, Maxwell D. Caesarean scar pregnancy. *BJOG* 2007; **114**: 253-263 [PMID: 17313383]

- DOI: [10.1111/j.1471-0528.2006.01237.x](https://doi.org/10.1111/j.1471-0528.2006.01237.x)]
- 7 **Jin FS**, Ding DC, Wu GJ, Hwang KS. Molar Pregnancy in a Cesarean Section Scar of Uterus. *J Med Sci* 2011; **31**: 173-176. Available from: <https://www.researchgate.net/publication/266421166>
  - 8 **Kaluarachchi C**, Tissera A, Gananatha Karunaratna S. Cesarean scar site complete molar pregnancy. *Sri Lanka J Obstet Gynaecol* 2013; **35**: 62-64 [DOI: [10.4038/sljog.v35i2.6162](https://doi.org/10.4038/sljog.v35i2.6162)]
  - 9 **Michener C**, Dickinson JE. Cesarean scar ectopic pregnancy: a single centre case series. *Aust N Z J Obstet Gynaecol* 2009; **49**: 451-455 [PMID: [19780724](https://pubmed.ncbi.nlm.nih.gov/19780724/) DOI: [10.1111/j.1479-828X.2009.01067.x](https://doi.org/10.1111/j.1479-828X.2009.01067.x)]
  - 10 **Yamada Y**, Ohira S, Yamazaki T, Shiozawa T. Ectopic Molar Pregnancy: Diagnostic Efficacy of Magnetic Resonance Imaging and Review of the Literature. *Case Rep Obstet Gynecol* 2016; **2016**: 7618631 [PMID: [27648323](https://pubmed.ncbi.nlm.nih.gov/27648323/) DOI: [10.1155/2016/7618631](https://doi.org/10.1155/2016/7618631)]
  - 11 **Cheung AN**. Pathology of gestational trophoblastic diseases. *Best Pract Res Clin Obstet Gynaecol* 2003; **17**: 849-868 [PMID: [14614885](https://pubmed.ncbi.nlm.nih.gov/14614885/) DOI: [10.1016/s1521-6934\(03\)00094-4](https://doi.org/10.1016/s1521-6934(03)00094-4)]
  - 12 **Missaoui N**, Landolsi H, Mestiri S, Essakly A, Abdessayed N, Hmissa S, Mokni M, Yacoubi MT. Immunohistochemical analysis of c-erbB-2, Bcl-2, p53, p21<sup>WAF1/Cip1</sup>, p63 and Ki-67 expression in hydatidiform moles. *Pathol Res Pract* 2019; **215**: 446-452 [PMID: [30558966](https://pubmed.ncbi.nlm.nih.gov/30558966/) DOI: [10.1016/j.prp.2018.12.015](https://doi.org/10.1016/j.prp.2018.12.015)]
  - 13 **Sorbi F**, Sisti G, Pieralli A, Di Tommaso M, Livi L, Buccoliero AM, Fambrini M. Cervicoisthmic choriocarcinoma mimicking cesarean section scar ectopic pregnancy. *J Res Med Sci* 2013; **18**: 914-917 [PMID: [24497867](https://pubmed.ncbi.nlm.nih.gov/24497867/)]
  - 14 **Qian ZD**, Zhu XM. Cesarean scar choriocarcinoma: a case report and review of the literature. *Eur J Med Res* 2014; **19**: 25 [PMID: [24887563](https://pubmed.ncbi.nlm.nih.gov/24887563/) DOI: [10.1186/2047-783X-19-25](https://doi.org/10.1186/2047-783X-19-25)]



Published By Baishideng Publishing Group Inc  
7041 Koll Center Parkway, Suite 160, Pleasanton, CA 94566, USA  
Telephone: +1-925-3991568  
E-mail: [bpgoffice@wjgnet.com](mailto:bpgoffice@wjgnet.com)  
Help Desk: <https://www.f6publishing.com/helpdesk>  
<https://www.wjgnet.com>

