

World Journal of *Clinical Cases*

World J Clin Cases 2020 May 6; 8(9): 1561-1755





REVIEW

- 1561** Nutrition management in acute pancreatitis: Clinical practice consideration
Lakananurak N, Gramlich L

MINIREVIEWS

- 1574** Bone disease in chronic pancreatitis
Ahmed A, Deep A, Kothari DJ, Sheth SG
- 1580** Role of microRNAs in the predisposition to gastrointestinal malignancies
Baz M, Ibrahim T
- 1586** Recurrent anal fistulas: When, why, and how to manage?
Emile SH

ORIGINAL ARTICLE

Case Control Study

- 1592** Removal of biofilm is essential for long-term ventilation tube retention
Ma Q, Wang H, Chen ZN, Wu YQ, Yu DZ, Wang PJ, Shi HB, Su KM

Retrospective Cohort Study

- 1600** Neutrophil gelatinase-associated lipocalin does not predict acute kidney injury in heart failure
Ferrari F, Scalzotto E, Esposito P, Samoni S, Mistrorigo F, Rizo Topete LM, De Cal M, Virzi GM, Corradi V, Torregrossa R, Valle R, Bianzina S, Aspromonte N, Floris M, Fontanelli A, Brendolan A, Ronco C
- 1608** Prognosis factors of advanced gastric cancer according to sex and age
Alshehri A, Alanezi H, Kim BS

Observational Study

- 1620** Attitudes, knowledge levels and behaviors of Islamic religious officials about organ donation in Turkey: National survey study
Akbulut S, Ozer A, Firinci B, Saritas H, Demyati K, Yilmaz S
- 1632** Serotonin transporter and cholecystokinin in diarrhea-predominant irritable bowel syndrome: Associations with abdominal pain, visceral hypersensitivity and psychological performance
Qin G, Zhang Y, Yao SK

CASE REPORT

- 1642** Cholesteryl ester storage disease of clinical and genetic characterisation: A case report and review of literature
Rashu EB, Junker AE, Danielsen KV, Dahl E, Hamberg O, Borgwardt L, Christensen VB, Wewer Albrechtsen NJ, Gluud LL
- 1651** Seroconversion of HBsAG coincides super-infection with hepatitis A: A case report
Beisel C, Addo MM, zur Wiesch JS
- 1656** Liver cirrhosis in a child associated with Castleman's disease: A case report
Kobayashi S, Inui A, Tsunoda T, Umetsu S, Sogo T, Mori M, Shinkai M, Fujisawa T
- 1666** Granulocyte colony-stimulating factor-producing squamous cell carcinoma of the tongue exhibiting characteristic fluorine-18 deoxyglucose accumulation on positron emission tomography-computed tomography: A case report
Shimamoto H, Hirota Y, Kashima Y, Kinoshita N, Yokokawa M, Ikeda T, Harada H
- 1674** Expander implantation for correction of high-riding nipple with enlarged nipple-areola complex using revision mastopexy: A case report
Qin F, Yu NZ, Yang E, Zeng A, Hao Y, Zhu L, Wang XJ
- 1679** Pyoderma gangrenosum confused with congenital preauricular fistula infection: A case report
Zhao Y, Fang RY, Feng GD, Cui TT, Gao ZQ
- 1685** Central nervous system relapse in a pediatric anaplastic large cell lymphoma patient with CLTC/ALK translocation treated with alectinib: A case report
Yang J, Li J, Gu WY, Jin L, Duan YL, Huang S, Zhang M, Wang XS, Liu Y, Zhou CJ, Gao C, Zheng HY, Zhang YH
- 1693** Colonic perforation in a nasopharyngeal carcinoma patient treated with fluorouracil: A case report
Lu WJ, Li G, Gao L
- 1698** Thoracoscopic resection of a huge esophageal dedifferentiated liposarcoma: A case report
Ye YW, Liao MY, Mou ZM, Shi XX, Xie YC
- 1705** COVID-19 managed with early non-invasive ventilation and a bundle pharmacotherapy: A case report
Peng M, Ren D, Liu XY, Li JX, Chen RL, Yu BJ, Liu YF, Meng X, Lyu YS
- 1713** Application of curved ablation in liver cancer with special morphology or location: Report of two cases
Cao N, Cai HJ, Sun XX, Liu DL, Huang B
- 1721** Giant ventral hernia simultaneously containing the spleen, a portion of the pancreas and the left hepatic lobe: A case report
Luo XG, Lu C, Wang WL, Zhou F, Yu CZ

- 1729** Endoscopic ultrasonography elastography in the diagnosis of intrapancreatic ectopic spleen: A case report
Ge N, Sun SY
- 1735** Mesonephric adenocarcinoma of the uterine cervix with rare lung metastases: A case report and review of the literature
Jiang LL, Tong DM, Feng ZY, Liu KR
- 1745** Portal hypertension in a patient with biliary hamartomas: A case report
Li QQ, Guo XZ, Li HY, Qi XS

LETTER TO THE EDITOR

- 1752** Rare primary lymphoepithelioma-like carcinoma of the renal pelvis
Lai SC, Seery S, Diao TX, Wang JY, Liu M

ABOUT COVER

Editorial Board Member of *World Journal of Clinical Cases*, Paul E Sijens, PhD, Associate Professor, Department of Radiology, University Medical Center Groningen and University of Groningen, Groningen 9713 GZ, Netherlands

AIMS AND SCOPE

The primary aim of *World Journal of Clinical Cases* (WJCC, *World J Clin Cases*) is to provide scholars and readers from various fields of clinical medicine with a platform to publish high-quality clinical research articles and communicate their research findings online.

WJCC mainly publishes articles reporting research results and findings obtained in the field of clinical medicine and covering a wide range of topics, including case control studies, retrospective cohort studies, retrospective studies, clinical trials studies, observational studies, prospective studies, randomized controlled trials, randomized clinical trials, systematic reviews, meta-analysis, and case reports.

INDEXING/ABSTRACTING

The WJCC is now indexed in PubMed, PubMed Central, Science Citation Index Expanded (also known as SciSearch®), and Journal Citation Reports/Science Edition. The 2019 Edition of Journal Citation Reports cites the 2018 impact factor for WJCC as 1.153 (5-year impact factor: N/A), ranking WJCC as 99 among 160 journals in Medicine, General and Internal (quartile in category Q3).

RESPONSIBLE EDITORS FOR THIS ISSUE

Responsible Electronic Editor: *Yan-Xia Xing*

Proofing Production Department Director: *Yun-Xiaojuan Wu*

Responsible Editorial Office Director: *Jin-Lai Wang*

NAME OF JOURNAL

World Journal of Clinical Cases

ISSN

ISSN 2307-8960 (online)

LAUNCH DATE

April 16, 2013

FREQUENCY

Semimonthly

EDITORS-IN-CHIEF

Dennis A Bloomfield, Bao-Gan Peng, Sandro Vento

EDITORIAL BOARD MEMBERS

<https://www.wjgnet.com/2307-8960/editorialboard.htm>

PUBLICATION DATE

May 6, 2020

COPYRIGHT

© 2020 Baishideng Publishing Group Inc

INSTRUCTIONS TO AUTHORS

<https://www.wjgnet.com/bpg/gerinfo/204>

GUIDELINES FOR ETHICS DOCUMENTS

<https://www.wjgnet.com/bpg/GerInfo/287>

GUIDELINES FOR NON-NATIVE SPEAKERS OF ENGLISH

<https://www.wjgnet.com/bpg/gerinfo/240>

PUBLICATION ETHICS

<https://www.wjgnet.com/bpg/GerInfo/288>

PUBLICATION MISCONDUCT

<https://www.wjgnet.com/bpg/gerinfo/208>

ARTICLE PROCESSING CHARGE

<https://www.wjgnet.com/bpg/gerinfo/242>

STEPS FOR SUBMITTING MANUSCRIPTS

<https://www.wjgnet.com/bpg/GerInfo/239>

ONLINE SUBMISSION

<https://www.f6publishing.com>

Case Control Study

Removal of biofilm is essential for long-term ventilation tube retention

Qiang Ma, Hui Wang, Zheng-Nong Chen, Ya-Qin Wu, Dong-Zhen Yu, Peng-Jun Wang, Hai-Bo Shi, Kai-Ming Su

ORCID number: Qiang Ma (0000-0002-2367-9998); Hui Wang (0000-0003-4196-997X); Zheng-Nong Chen (0000-0001-7774-441X); Ya-Qin Wu (0000-0002-8184-9748); Dong-Zhen Yu (0000-0002-1302-3450); Peng-Jun Wang (0000-0003-1871-2746); Hai-Bo Shi (0000-0003-1998-3281); Kai-Ming Su (0000-0002-1965-6777).

Author contributions: Ma Q wrote the manuscript draft; Wang PJ and Shi HB collected the clinical data; Shi HB designed the study; Wang PJ revised the manuscript; Chen ZN, Wu YQ, and Wang H performed the treatments; Su KM and Yu DZ evaluated the efficacy of the method; all authors read and approved the final manuscript.

Supported by Shanghai Leadership Talent Training Plan, No. 2017062; the Key Project of Shanghai Jiao Tong University Medicine Science and Engineering Interdisciplinary Foundation, No. YG2016ZD02; Shanghai Municipal Education Commission-Gaofeng Clinical Medicine Grant Support, No. 20152233; Multi-Center Clinical Research Plan of Medical College of Shanghai Jiao Tong University, No. DLY201823; the Clinical Research Plan of Shanghai Shen Kang Hospital Development Center, No. 16CR4022A and No. 16CR3041A; and National Natural Science Foundation of China, No. 81974142.

Institutional review board

statement: The study was approved by the Ethics Committee of Shanghai Sixth People's

Qiang Ma, Hui Wang, Zheng-Nong Chen, Ya-Qin Wu, Dong-Zhen Yu, Peng-Jun Wang, Hai-Bo Shi, Kai-Ming Su, Department of Otorhinolaryngology-Head & Neck Surgery, the Sixth People's Hospital Affiliated to Shanghai Jiaotong University, Shanghai 200233, China

Hai-Bo Shi, Shanghai Key Laboratory of Sleep Disordered Breathing, Shanghai 200233, China

Corresponding author: Peng-Jun Wang, MD, Doctor, Department of Otorhinolaryngology-Head & Neck Surgery, the Sixth People's Hospital Affiliated to Shanghai Jiaotong University, 600 Yishan Road, Shanghai 200233, China. wangpj@sjtu.edu.cn

Abstract

BACKGROUND

Although long-term retention of a ventilation tube is required in many ear diseases, spontaneous removal of conventional ventilation tube is observed in patients within 3 to 12 mo. To address this issue, we aimed to determine a new method for long-term retention of the ventilation tube.

AIM

To explore the value of removing the biofilm for long-term retention of tympanostomy ventilation tubes.

METHODS

A case-control study design was used to evaluate the safety and effectiveness of long-term tube retention by directly removing the biofilm (*via* surgical exfoliation) in patients who underwent myringotomy with ventilation tube placement. The patients were randomly divided into two groups: Control group and treatment group. Patients in the treatment group underwent regular biofilm exfoliation surgery in the clinic, whereas those in the control group did not have their biofilm removed. Only conventional ventilation tubes were placed in this study. Outcome measures were tube position and patency. Tube retention time and any complications were documented.

RESULTS

Eight patients with biofilm removal and eight patients without biofilm removal as a control group were enrolled in the study. The tympanostomy tube retention time was significantly longer in the treatment group (43.5 ± 26.4 mo) than in the control group (9.5 ± 6.9 mo) ($P = 0.003$). More tympanostomy tubes were found to be patent and in correct position in the treatment group during the follow-up intervals than in the control group ($P = 0.01$).

Hospital (YS-2018-101).

Informed consent statement: All patients gave informed consent.

Conflict-of-interest statement: The authors declare that they have no competing interests.

Data sharing statement: No additional data are available.

STROBE statement: The authors have read the STROBE Statement, and the manuscript was prepared and revised according to the STROBE Statement.

Open-Access: This article is an open-access article that was selected by an in-house editor and fully peer-reviewed by external reviewers. It is distributed in accordance with the Creative Commons Attribution NonCommercial (CC BY-NC 4.0) license, which permits others to distribute, remix, adapt, build upon this work non-commercially, and license their derivative works on different terms, provided the original work is properly cited and the use is non-commercial. See: <http://creativecommons.org/licenses/by-nc/4.0/>

Manuscript source: Invited Manuscript

Received: December 16, 2019

Peer-review started: December 16, 2019

First decision: February 20, 2020

Revised: March 4, 2020

Accepted: April 15, 2020

Article in press: April 15, 2020

Published online: May 6, 2020

P-Reviewer: Chhabra N, Ozcan C

S-Editor: Wang J

L-Editor: Wang TQ

E-Editor: Xing YX



CONCLUSION

Despite the use of short-term ventilation tubes, direct biofilm removal can be a well-tolerated and effective treatment for long-term tube retention of tympanostomy ventilation tubes in patients who underwent myringotomy.

Key words: Tympanostomy tubes; Biofilm; Complication management; Long-term retention; Ménière disease; Refractory otitis media with effusion

©The Author(s) 2020. Published by Baishideng Publishing Group Inc. All rights reserved.

Core tip: Long-term ventilation tube retention is necessary in many diseases, such as refractory otitis media with effusion and eustachian tube dysfunction, as well as with the use of Meniett therapy for Ménière disease. However, conventional ventilation tubes are expelled spontaneously within 3 to 12 mo because of tube extrusion or obstruction. Therefore, patients have to undergo two or more myringotomy with ventilation tube placement procedures, along with the risks of anesthesia and surgery, excessive injury to the tympanic membrane and external auditory canal, medical care costs, and impact on school or work. The biofilm plays a crucial role in the development of extrusion or obstruction after myringotomy with ventilation tube placement. It was revealed that, despite the use of short-term tube, biofilm removal has been proven to be a safe and effective treatment for long-term tube retention.

Citation: Ma Q, Wang H, Chen ZN, Wu YQ, Yu DZ, Wang PJ, Shi HB, Su KM. Removal of biofilm is essential for long-term ventilation tube retention. *World J Clin Cases* 2020; 8(9): 1592-1599

URL: <https://www.wjgnet.com/2307-8960/full/v8/i9/1592.htm>

DOI: <https://dx.doi.org/10.12998/wjcc.v8.i9.1592>

INTRODUCTION

Myringotomy with ventilation tube placement (M&T) was first described by Viennese otologist Politzer in 1868 for the treatment of otitis media catarrhalis and was popularized by Armstrong in 1954^[1]. Since then, the basic principles of myringotomy with tube placement have remained unchanged, although various surgical procedures have been developed. M&T plays an important role in the treatment of refractory otitis media with effusion (ROME) and eustachian tube dysfunction by maintaining continuous ventilation and pressure balance and promoting secretion drainage in the middle ear^[2]. Ninety percent of children develop otitis media at least once before the age of 2 years; thus, M&T is the most common outpatient operation for children younger than 15 years^[3].

In cases of ROME and eustachian tube dysfunction, as well as with the use of Meniett therapy for Ménière disease, the ventilation tube needs to be retained for a relatively long time. However, conventional ventilation tube is expelled spontaneously within 3 to 12 mo because of tube extrusion or obstruction^[4], and in such cases, patients have to undergo two or more M&T procedures. Although M&T is a minimally invasive procedure, there is a need to minimize the number of operations for long-term maintenance of an indwelling tube, considering the risks of anesthesia and surgery, excessive injury to the tympanic membrane and external auditory canal, medical care costs, and impact on school or work^[5].

Many “permanent” tubes have been developed in an attempt to provide longer-lasting middle ear ventilation, but such tubes are still subject to problems with unplanned extrusion^[6]. In this study, we aimed to identify a safe and effective method for long-term retention with the conventional ventilation tube in patients requiring an indwelling tube.

MATERIALS AND METHODS

Patients

Sixteen consecutive adult patients who underwent M&T and required an indwelling

tube over a long period were recruited from the Sixth People's Hospital (Affiliated to Shanghai Jiaotong University) between January 2011 and September 2019. The patients were randomly divided into two groups: Control group and treatment group. During the same period, patients in the treatment group underwent regular biofilm exfoliation surgery in the clinic, whereas those in the control group did not have their biofilm removed. General characteristics, such as age, sex, follow-up interval, and retention time, were collected (Table 1). All patients provided written informed consent in accordance with the Declaration of Helsinki^[7]. The study protocol was reviewed and approved by the Ethics Committee of Shanghai Sixth People's Hospital (YS-2018-101).

Treatment procedure

All patients underwent M&T. Only conventional ventilation tubes were used in this study (Medtronic, United States) and retained for more than 1 year depending on the needs of treatment. Follow-up intervals were 4 wk, 8 wk, 6 mo, and 1 year after M&T, which were mainly conducted to examine the state of the ventilation tube and the treatment effects for primary diseases. The follow-up period was determined according to the speed of accumulation of the exfoliated epithelium (biofilm), which was mostly located at the vertical junction of the circular edge of the indwelling tube (Figure 1). For regular biofilm exfoliation surgery, the biofilm of the ventilation tube was immersed in ofloxacin ear drops for 20-30 min. Then, under a microscope, the biofilm was cut off and cleared with an improvised miniature suction or hook. Finally, the migrated tube was reset (Figure 2). The control group did not undergo biofilm removal.

Effect assessment

Tube position and patency were the outcome measures. Patency was defined as < 50% blockage in the ventilation tube; position was indicated by a distance < 0.3 cm between the ventilation tube and the tympanic membrane. Any complications, such as obstruction, granulomatosis, myringosclerosis, retraction, cholesteatoma, and tympanic membrane perforation, were documented. The tube retention time was calculated in the control and treatment groups (Figure 3).

Statistical analysis

SPSS for Windows version 22.0 (IBM, United States) was used for data analyses. Independent *t*-test was used to compare mean difference between the two values, and a Chi-square test (χ^2) was used for the comparison of two or more rates. A *P* value < 0.05 was considered statistically significant.

RESULTS

Patients' information

A total of 16 participants (56.3% men and 43.7% women) with a mean age of 53.3 ± 15.0 years (Table 1) were enrolled in the study. The treatment and control groups included eight patients each. The reason for long-term ventilation tube retention included MD and ROME (Table 1).

Retention time of tympanostomy tube

Univariate analysis revealed that the retention time of the tympanostomy tube was significantly longer in the treatment group (43.5 ± 26.4 mo) than in the control group (9.5 ± 6.9 mo) ($P = 0.003$). No statistically significant difference in sex ($P = 0.619$) or age ($P = 0.140$) was found between the treatment and control groups (Table 2).

State of tympanostomy tube

More tympanostomy tubes were found to be in position and patent in the treatment group in the follow-up intervals compared with those in the control group ($P = 0.01$). During the course of tube retention, there was no complication in either group (Table 3).

DISCUSSION

In this study, we identified a safe and effective method for long-term retention of conventional ventilation tube in patients requiring an indwelling tube. The treatment group had longer tympanostomy tube retention time than the control group.

Long-term ventilation tube retention is necessary in many diseases. Otitis media

Table 1 Characteristics of study participants

No.	Sex/age (yr)	Diagnosis	Follow-up intervals (mo)	Retention time (mo)
1	F/72	MD	2	24
2	M/37	MD	12	84
3	F/42	MD	1	12
4	M/55	ROME	6	24
5	M/60	ROME	6	24
6	F/39	MD	1.5	42
7	M/25	MD	12	72
8	M/51	MD	12	60
9	F/55	ROME	/	24
10	M/63	ROME	/	9
11	M/79	ROME	/	5
12	F/46	ROME	/	8
13	M/64	ROME	/	12
14	F/49	ROME	/	4
15	F/75	ROME	/	2
16	F/40	ROME	/	12

M: Male; F: Female; MD: Meniere disease; ROME: Refractory otitis media with effusion.

with effusion is more common in children with cleft palate or cleft lip and palate, with incidence rates of 70%-90%^[8]. Although M&T is expected to alleviate tympanic effusion, the rate of reimplantation is 21.9%, owing to recurrent attacks or premature extrusion caused by middle ear inflammation^[9]. Because of persistent eustachian tube dysfunction in persons with Down syndrome, middle ear aeration *via* tympanostomy tubes may be required throughout the preschool years to prevent otologic and developmental complications associated with otitis media with effusion. However, in 38.4% of the patients, the tube needs to be replaced because of repeated removal, and the average number of tube replacements per individual is 3.5^[10]. Yaman *et al*^[11] showed that the longer the tympanostomy tube retention time, the lower the recurrence rate of ROME. Comparison of three groups in their study showed higher recurrence rates with a retention time < 6 mo (36.54%) than with retention times between 6 and 12 mo (17.74%) and > 12 mo (9.1%).

Biofilm removal is essential for long-term ventilation tube retention in Meniett therapy. The Meniett device is a safe, nondestructive treatment for patients refractory to medical therapy for Meniere disease^[12]. It does not function in the presence of an intact tympanic membrane, requiring the maintenance of a patent myringotomy tube. In Mattox's study, in eight patients using the device between 3 and 5.25 years, there were 29 separate conventional tube insertions or 3.6 tube insertions per patient^[13]. With the same therapy, our six patients with Meniere disease had six separate conventional tube insertions or one tube insertion per patient during an average of 4 years of treatment. Therefore, our new method for long-term ventilation tube retention appears to be a suitable alternative to repeated tympanostomy tube placement in selected patients.

The biofilm plays a crucial role in the development of complications after M&T. Otorrhea and obstruction are the two most common complications after tympanic membrane catheterization. In one study, the risk of otorrhea ranged from 0.5% to 11%, and the incidence of tube obstruction ranged from 6.9% to 36%^[14]. There is growing evidence to support the role of biofilms in the development of complications after M&T. Previous reports have described strategies to inhibit the development of bacterial biofilms in tympanostomy tubes. Among these strategies are antibiotic-coated tympanostomy tubes, silver oxide-impregnated tympanostomy tubes^[15], polyvinylpyrrolidone-coated silicone tympanostomy tubes^[16], phosphorylcholine antibacterial coating, and ion-bombarded silicone and fluoroplastic tympanostomy tubes^[17]. Each of these strategies has its own limitations. Antibiotic coatings are likely to cause an increase in antibiotic resistance; silver oxide-impregnated and phosphorylcholine antibacterial-coated tympanostomy tubes do not inhibit biofilm formation; and ion-bombarded tympanostomy tubes do not completely inhibit bacterial attachment^[18]. Since the role of biofilm in the development of complications is clear, our treatment should also be effective in theory.

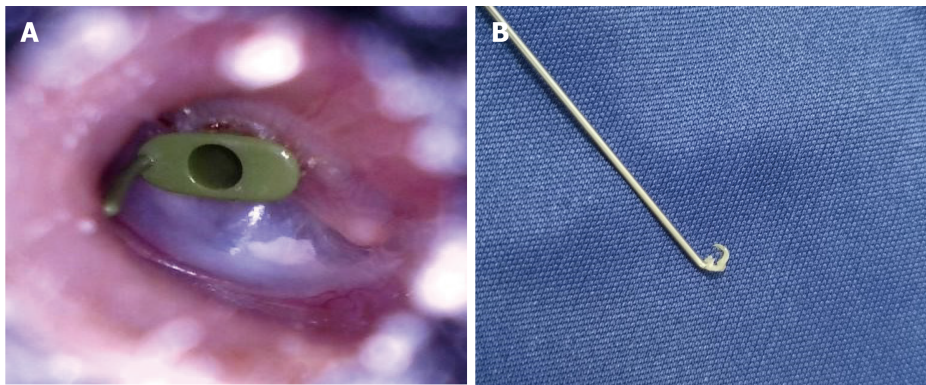


Figure 1 Exfoliated epithelium. A: Exfoliated epithelium at the vertical junction of the circular edge of the indwelling tube; B: Exfoliated epithelium cut off and cleared with an improvised miniature suction or hook.

An obvious shortcoming of our study is its retrospective nature. Although this study investigated several factors that might affect tube retention time, not all potential variables were included. Considering the small sample size, further study is necessary to determine whether biofilm removal is a suitable alternative to repeated tympanostomy tube placement in selected patients. In conclusion, despite the use of short-term tube, biofilm removal has been proven to be a safe and effective treatment for long-term tube retention.

Table 2 Univariate analysis

	Total (n = 16)	Treatment (n = 8)	Control (n = 8)	P value
Sex				0.619
Male	9 (56.25)	5 (62.5)	3 (37.5)	
Female	7 (43.75)	3 (37.5)	5 (62.5)	
Age (yr)	53.3 ± 15.0	47.6 ± 14.9	58.9 ± 13.9	0.140

Values are presented as *n* (%) or mean ± standard deviation.

Table 3 State of tympanostomy tube in the two groups

	Total	Treatment	Control	P value
Position				0.010
Yes	8	7	7	
No	8	1	1	
Patency				0.010
Yes	8	7	7	
No	8	1	1	

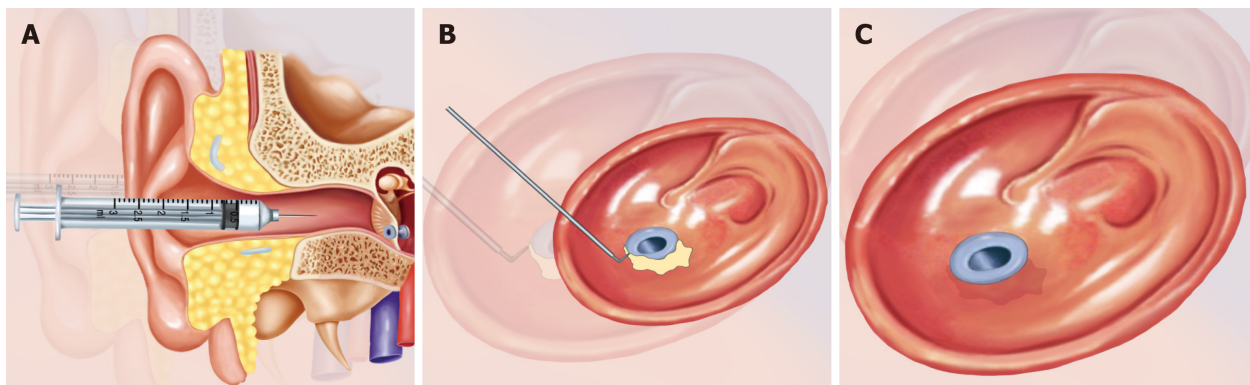


Figure 2 Biofilm exfoliation surgery. A: Immersion of the biofilm of the ventilation tube in ofloxacin ear drops for 20-30 min; B: Under a microscope, the biofilm is cut off and cleared with a self-made miniature suction or hook; C: The reset migrated tube.

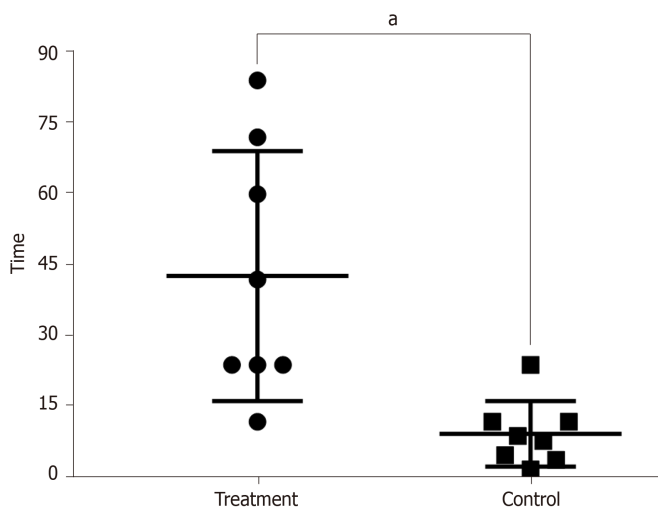


Figure 3 Retention time of the ventilation tube. The tympanostomy tube retention time of the treatment group was significantly longer than that of the control group. ^a*P* < 0.01.

ARTICLE HIGHLIGHTS

Research background

Myringotomy with ventilation tube placement (M&T) plays an important role in the treatment of refractory otitis media by maintaining continuous ventilation and pressure balance and promoting secretion drainage in the middle ear. Long-term ventilation tube retention is necessary in many diseases, such as refractory otitis media with effusion and eustachian tube dysfunction, as well as with the use of Meniett therapy for Ménière disease. However, conventional ventilation tubes are expelled spontaneously within 3 to 12 mo because of tube extrusion or obstruction. Therefore, patients have to undergo two or more M&T procedures, which have the concomitant risks of anesthesia and surgery, excessive injury to the tympanic membrane and external auditory canal, medical care costs, and impact on school or work.

Research motivation

The biofilm plays a crucial role in the development of extrusion or obstruction after M&T. Previous reports described strategies designed to inhibit the development of bacterial biofilms on tympanostomy tubes, such as antibiotic-coated, ion-bombarded silicone, and fluoroplastic tympanostomy tubes, which had been proved to be incapable of completely inhibiting bacterial attachment. However, studies about biofilms are still lacking, and it is uncertain whether directly removing the biofilm can be a well-tolerated and effective treatment for long-term tube retention of tympanostomy ventilation tubes.

Research objectives

In this study, directly removing the biofilm was performed to maintain tube position and patency as well as control complications. Our study aimed to explore the value of directly removing the biofilm for long-term ventilation tube retention.

Research methods

A case-control study design was used to evaluate the safety and effectiveness of long-term tube retention by directly removing the biofilm (*via* surgical exfoliation) in patients who underwent M&T. Patients in the treatment group underwent regular biofilm exfoliation surgery in the clinic, whereas the control group did not undergo biofilm removal. Only conventional ventilation tubes were placed in this study. Outcome measures were tube position and patency. Tube retention time and any complications were documented.

Research results

In this study, we identified a safe and effective method for long-term retention of conventional ventilation tube in patients requiring an indwelling tube. Tympanostomy tube retention time was longer in the treatment group than in the control group. More tympanostomy tubes were found to be in position and patent in the treatment group in the follow-up intervals than in the control group. Furthermore, during the course of tube retention, there was no complication in either group.

Research conclusions

Biofilm removal has been proven to be a safe and effective treatment for long-term tube retention, even with the use of short-term tube. It is expected to provide a new treatment method for many diseases that necessitate long-term ventilation tube retention.

Research perspectives

Considering the small sample size, further study is needed to determine whether biofilm removal is a suitable alternative to repeated tympanostomy tube placement in selected patients.

REFERENCES

- 1 **Paradise JL**, Bluestone CD. Consultation with the specialist: tympanostomy tubes: a contemporary guide to judicious use. *Pediatr Rev* 2005; **26**: 61-66 [PMID: 15687476 DOI: 10.1542/pir.26-2-61]
- 2 **Smith N**, Greinwald J. To tube or not to tube: indications for myringotomy with tube placement. *Curr Opin Otolaryngol Head Neck Surg* 2011; **19**: 363-366 [PMID: 21804383 DOI: 10.1097/MOO.0b013e3283499fa8]
- 3 **Schraff SA**. Contemporary indications for ventilation tube placement. *Curr Opin Otolaryngol Head Neck Surg* 2008; **16**: 406-411 [PMID: 18797280 DOI: 10.1097/MOO.0b013e3283095046]
- 4 **Principi N**, Marchisio P, Esposito S. Otitis media with effusion: benefits and harms of strategies in use for treatment and prevention. *Expert Rev Anti Infect Ther* 2016; **14**: 415-423 [PMID: 26853095 DOI: 10.1586/14787210.2016.1150781]
- 5 **Huyett P**, Sturm JJ, Shaffer AD, Kitsko DJ, Chi DH. Second tympanostomy tube placement in children with recurrent acute otitis media. *Laryngoscope* 2018; **128**: 1476-1479 [PMID: 28990661 DOI: 10.1002/lary.26926]
- 6 **Poe DS**, Metson RB, Kujawski O. Laser eustachian tuboplasty: a preliminary report. *Laryngoscope* 2003; **113**: 583-591 [PMID: 12671411 DOI: 10.1097/00005537-200304000-00001]
- 7 **World Medical Association**. World Medical Association Declaration of Helsinki: ethical principles for medical research involving human subjects. *JAMA* 2013; **310**: 2191-2194 [PMID: 24141714 DOI: 10.1001/jama.2013.281053.]
- 8 **Flynn T**, Möller C, Jönsson R, Lohmander A. The high prevalence of otitis media with effusion in children with cleft lip and palate as compared to children without clefts. *Int J Pediatr Otorhinolaryngol*

- 2009; **73**: 1441-1446 [PMID: [19709760](#) DOI: [10.1016/j.ijporl.2009.07.015](#)]
- 9 **Huang CY**, Wu CS, Tang CH, Wang MC, Kuo TY, Tu TY. Palatoplasty decreases the re-insertion rate of middle ear ventilation tube in cleft palate children-A population-based birth cohort study. *Acta Otolaryngol* 2016; **136**: 768-774 [PMID: [27067029](#) DOI: [10.3109/00016489.2016.1165352](#)]
- 10 **Bernardi GF**, Pires CTF, Oliveira NP, Nisihara R. Prevalence of pressure equalization tube placement and hearing loss in children with down syndrome. *Int J Pediatr Otorhinolaryngol* 2017; **98**: 48-52 [PMID: [28583503](#) DOI: [10.1016/j.ijporl.2017.04.041](#)]
- 11 **Yaman H**, Yilmaz S, Guclu E, Subasi B, Alkan N, Ozturk O. Otitis media with effusion: recurrence after tympanostomy tube extrusion. *Int J Pediatr Otorhinolaryngol* 2010; **74**: 271-274 [PMID: [20044147](#) DOI: [10.1016/j.ijporl.2009.11.035](#)]
- 12 **Ahsan SF**, Standing R, Wang Y. Systematic review and meta-analysis of Meniett therapy for Meniere's disease. *Laryngoscope* 2015; **125**: 203-208 [PMID: [24913022](#) DOI: [10.1002/lary.24773](#)]
- 13 **Mattox DE**, Reichert M. Meniett device for Ménière's disease: use and compliance at 3 to 5 years. *Otol Neurotol* 2008; **29**: 29-32 [PMID: [18199955](#) DOI: [10.1097/MAO.0b013e31815dbac4](#)]
- 14 **Wang JC**, Hamood AN, Saadeh C, Cunningham MJ, Yim MT, Cordero J. Strategies to prevent biofilm-based tympanostomy tube infections. *Int J Pediatr Otorhinolaryngol* 2014; **78**: 1433-1438 [PMID: [25060938](#) DOI: [10.1016/j.ijporl.2014.05.025](#)]
- 15 **Vlastarakos PV**, Nikolopoulos TP, Maragoudakis P, Tzagaroulakis A, Ferekidis E. Biofilms in ear, nose, and throat infections: how important are they? *Laryngoscope* 2007; **117**: 668-673 [PMID: [17415138](#) DOI: [10.1097/MLG.0b013e318030e422](#)]
- 16 **Antonelli PJ**, Sampson EM, Ojano-Dirain C. Biofilm formation on silicone tympanostomy tubes with polyvinylpyrrolidone coating. *Arch Otolaryngol Head Neck Surg* 2011; **137**: 19-23 [PMID: [21242541](#) DOI: [10.1001/archoto.2010.205](#)]
- 17 **Licameli G**, Johnston P, Luz J, Daley J, Kenna M. Phosphorylcholine-coated antibiotic tympanostomy tubes: are post-tube placement complications reduced? *Int J Pediatr Otorhinolaryngol* 2008; **72**: 1323-1328 [PMID: [18635268](#) DOI: [10.1016/j.ijporl.2008.05.018](#)]
- 18 **Wang JC**, Tran PL, Hanes R, Cordero J, Marchbanks J, Reid TW, Colmer-Hamood JA, Hamood AN. Inhibition of otopathogenic biofilms by organoselenium-coated tympanostomy tubes. *JAMA Otolaryngol Head Neck Surg* 2013; **139**: 1009-1016 [PMID: [24030785](#) DOI: [10.1001/jamaoto.2013.4690](#)]



Published By Baishideng Publishing Group Inc
7041 Koll Center Parkway, Suite 160, Pleasanton, CA 94566, USA
Telephone: +1-925-3991568
E-mail: bpgoffice@wjgnet.com
Help Desk: <https://www.f6publishing.com/helpdesk>
<https://www.wjgnet.com>

