

World Journal of *Clinical Cases*

World J Clin Cases 2021 January 6; 9(1): 1-290



Contents

Thrice Monthly Volume 9 Number 1 January 6, 2021

OPINION REVIEW

- 1 Necessary problems in re-emergence of COVID-19
Chen S, Ren LZ, Ouyang HS, Liu S, Zhang LY

REVIEW

- 8 COVID-19: An overview and a clinical update
Krishnan A, Hamilton JP, Alqahtani SA, Woreta TA

ORIGINAL ARTICLE

Retrospective Cohort Study

- 24 Log odds of positive lymph nodes is a better prognostic factor for oesophageal signet ring cell carcinoma than N stage
Wang F, Gao SG, Xue Q, Tan FW, Gao YS, Mao YS, Wang DL, Zhao J, Li Y, Yu XY, Cheng H, Zhao CG, Mu JW
- 36 Modified procedure for prolapse and hemorrhoids: Lower recurrence, higher satisfaction
Chen YY, Cheng YF, Wang QP, Ye B, Huang CJ, Zhou CJ, Cai M, Ye YK, Liu CB
- 47 Angiotensin converting enzymes inhibitors or angiotensin receptor blockers should be continued in COVID-19 patients with hypertension
Tian C, Li N, Bai Y, Xiao H, Li S, Ge QG, Shen N, Ma QB

Retrospective Study

- 61 Massively prolapsed intervertebral disc herniation with interlaminar endoscopic spine system Delta endoscope: A case series
Meng SW, Peng C, Zhou CL, Tao H, Wang C, Zhu K, Song MX, Ma XX
- 71 Primary lung cancer with radioiodine avidity: A thyroid cancer cohort study
Lu YL, Chen ST, Ho TY, Chan WH, Wong RJ, Hsueh C, Lin SF
- 81 Is traumatic meniscal lesion associated with acute fracture morphology changes of tibia plateau? A series of arthroscopic analysis of 67 patients
Chen YD, Chen SX, Liu HG, Zhao XS, Ou WH, Li HX, Huang HX

Observational Study

- 91 Role of relaxin in diastasis of the pubic symphysis peripartum
Wang Y, Li YQ, Tian MR, Wang N, Zheng ZC

SYSTEMATIC REVIEWS

- 102 Chinese medicine formulas for nonalcoholic fatty liver disease: Overview of systematic reviews
Dai L, Zhou WJ, Zhong LLD, Tang XD, Ji G

- 118 Comparative profile for COVID-19 cases from China and North America: Clinical symptoms, comorbidities and disease biomarkers

Badawi A, Vasileva D

META-ANALYSIS

- 133 Polymerase chain reaction-based tests for detecting *Helicobacter pylori* clarithromycin resistance in stool samples: A meta-analysis

Gong RJ, Xu CX, Li H, Liu XM

CASE REPORT

- 148 Surgery-first for a patient with mild hemifacial microsomia: A case report and review of literature

Song JY, Yang H, He X, Gao S, Wu GM, Hu M, Zhang Y

- 163 Late-onset non-islet cell tumor hypoglycemia: A case report

Matsumoto S, Yamada E, Nakajima Y, Yamaguchi N, Okamura T, Yajima T, Yoshino S, Horiguchi K, Ishida E, Yoshikawa M, Nagaoka J, Sekiguchi S, Sue M, Okada S, Fukuda I, Shirabe K, Yamada M

- 170 Risk of group aggregative behavior during COVID-19 outbreak: A case report

Zuo H, Hu ZB, Zhu F

- 175 Low-grade fibromyxoid sarcoma of the liver: A case report

Dugalic V, Ignjatovic II, Kovac JD, Ilic N, Sopta J, Ostojic SR, Vasin D, Bogdanovic MD, Dumic I, Milovanovic T

- 183 Treatment of Stanford type A aortic dissection with triple pre-fenestration, reduced diameter, and three-dimensional-printing techniques: A case report

Zhang M, Tong YH, Liu C, Li XQ, Liu CJ, Liu Z

- 190 Hyperprolactinemia due to pituitary metastasis: A case report

Liu CY, Wang YB, Zhu HQ, You JL, Liu Z, Zhang XF

- 197 Pulmonary thromboembolism after distal ulna and radius fractures surgery: A case report and a literature review

Lv B, Xue F, Shen YC, Hu FB, Pan MM

- 204 Myeloid neoplasm with eosinophilia and rearrangement of platelet-derived growth factor receptor beta gene in children: Two case reports

Wang SC, Yang WY

- 211 Sclerosing angiomatoid nodular transformation of the spleen: A case report and literature review

Li SX, Fan YH, Wu H, Lv GY

- 218 Late recurrence of papillary thyroid cancer from needle tract implantation after core needle biopsy: A case report

Kim YH, Choi IH, Lee JE, Kim Z, Han SW, Hur SM, Lee J

- 224** Atypical adult-onset Still's disease with an initial and sole manifestation of liver injury: A case report and review of literature
Yu F, Qin SY, Zhou CY, Zhao L, Xu Y, Jia EN, Wang JB
- 232** Type A aortic dissection developed after type B dissection with the presentation of shoulder pain: A case report
Yin XB, Wang XK, Xu S, He CY
- 236** Hemosuccus pancreaticus caused by gastroduodenal artery pseudoaneurysm associated with chronic pancreatitis: A case report and review of literature
Cui HY, Jiang CH, Dong J, Wen Y, Chen YW
- 245** Endoscopic treatment for acute appendicitis with coexistent acute pancreatitis: Two case reports
Du ZQ, Ding WJ, Wang F, Zhou XR, Chen TM
- 252** Residual tumor and central lymph node metastasis after thermal ablation of papillary thyroid carcinoma: A case report and review of literature
Hua Y, Yang JW, He L, Xu H, Huo HZ, Zhu CF
- 262** Endoscopic salvage treatment of histoacryl after stent application on the anastomotic leak after gastrectomy: A case report
Kim HS, Kim Y, Han JH
- 267** Immunosuppressant treatment for IgG4-related sclerosing cholangitis: A case report
Kim JS, Choi WH, Lee KA, Kim HS
- 274** Intraparenchymal hemorrhage after surgical decompression of an epencephalon arachnoid cyst: A case report
Wang XJ
- 278** Krukenberg tumor with concomitant ipsilateral hydronephrosis and spermatic cord metastasis in a man: A case report
Tsao SH, Chuang CK
- 284** Simultaneous bilateral acromial base fractures after staged reverse total shoulder arthroplasty: A case report
Kim DH, Kim BS, Cho CH

ABOUT COVER

Editorial Board Member of *World Journal of Clinical Cases*, Dr. Antonio Corvino is a PhD in the Motor Science and Wellness Department of University of Naples "Parthenope". After obtaining his MD degree from the School of Medicine, Second University of Naples (2008), he completed a residency in Radiology at the University of Naples Federico II (2014). Following post-graduate training at the Catholic University of Rome, yielding a second level Master's degree in "Internal Ultrasound Diagnostic and Echo-Guided Therapies" (2015), he served on the directive board of Young Directive of Italian Society of Ultrasound in Medicine and Biology (2016-2018). His ongoing research interests involve ultrasound and ultrasound contrast media in abdominal and non-abdominal applications, mainly in gastrointestinal, hepatic, vascular, and musculoskeletal imaging. (L-Editor: Filipodia)

AIMS AND SCOPE

The primary aim of *World Journal of Clinical Cases* (*WJCC*, *World J Clin Cases*) is to provide scholars and readers from various fields of clinical medicine with a platform to publish high-quality clinical research articles and communicate their research findings online.

WJCC mainly publishes articles reporting research results and findings obtained in the field of clinical medicine and covering a wide range of topics, including case control studies, retrospective cohort studies, retrospective studies, clinical trials studies, observational studies, prospective studies, randomized controlled trials, randomized clinical trials, systematic reviews, meta-analysis, and case reports.

INDEXING/ABSTRACTING

The *WJCC* is now indexed in Science Citation Index Expanded (also known as SciSearch®), Journal Citation Reports/Science Edition, PubMed, and PubMed Central. The 2020 Edition of Journal Citation Reports® cites the 2019 impact factor (IF) for *WJCC* as 1.013; IF without journal self cites: 0.991; Ranking: 120 among 165 journals in medicine, general and internal; and Quartile category: Q3.

RESPONSIBLE EDITORS FOR THIS ISSUE

Production Editor: Yan-Xia Xing; Production Department Director: Yun-Xiaojuan Wu; Editorial Office Director: Jin-Lai Wang.

NAME OF JOURNAL

World Journal of Clinical Cases

ISSN

ISSN 2307-8960 (online)

LAUNCH DATE

April 16, 2013

FREQUENCY

Thrice Monthly

EDITORS-IN-CHIEF

Dennis A Bloomfield, Sandro Vento, Bao-gan Peng

EDITORIAL BOARD MEMBERS

<https://www.wjgnet.com/2307-8960/editorialboard.htm>

PUBLICATION DATE

January 6, 2021

COPYRIGHT

© 2021 Baishideng Publishing Group Inc

INSTRUCTIONS TO AUTHORS

<https://www.wjgnet.com/bpg/gerinfo/204>

GUIDELINES FOR ETHICS DOCUMENTS

<https://www.wjgnet.com/bpg/GerInfo/287>

GUIDELINES FOR NON-NATIVE SPEAKERS OF ENGLISH

<https://www.wjgnet.com/bpg/gerinfo/240>

PUBLICATION ETHICS

<https://www.wjgnet.com/bpg/GerInfo/288>

PUBLICATION MISCONDUCT

<https://www.wjgnet.com/bpg/gerinfo/208>

ARTICLE PROCESSING CHARGE

<https://www.wjgnet.com/bpg/gerinfo/242>

STEPS FOR SUBMITTING MANUSCRIPTS

<https://www.wjgnet.com/bpg/GerInfo/239>

ONLINE SUBMISSION

<https://www.f6publishing.com>



Residual tumor and central lymph node metastasis after thermal ablation of papillary thyroid carcinoma: A case report and review of literature

Yu Hua, Jia-Wen Yang, Liu He, Hua Xu, Hai-Zhong Huo, Chen-Fang Zhu

ORCID number: Yu Hua 0000-0002-3567-991X; Jia-Wen Yang 0000-0002-4035-1687; Liu He 0000-0002-9847-7450; Hua Xu 0000-0002-9193-0021; Hai-Zhong Huo 0000-0002-1573-9655; Chen-Fang Zhu 0000-0003-1588-4905.

Author contributions: All authors conceived the manuscript, supervised the findings of this work, discussed the results, and contributed to the final manuscript; Hua Y processed the data, drafted the manuscript, and designed the figures; Zhu CF was directly responsible for performing the operation, revising the paper, and supervising the work; Yang JW contributed to analysis and manuscript preparation; He L, Xu H, and Huo HZ analyzed data and prepared figures; All authors have read and approved the final manuscript.

Supported by the Shanghai Municipal Administrator of Traditional Chinese Medicine, No. 2018ZY03005.

Informed consent statement: Written informed consent was obtained from the patient for publication of this report and any accompanying images.

Conflict-of-interest statement: The

Yu Hua, Jia-Wen Yang, Liu He, Hua Xu, Hai-Zhong Huo, Chen-Fang Zhu, Department of General Surgery, Shanghai Ninth People's Hospital, Shanghai Jiao Tong University School of Medicine, Discipline Construction Research Center of China Hospital Development Institute, Shanghai Jiao Tong University, Shanghai 200011, China

Corresponding author: Chen-Fang Zhu, MD, PhD, Doctor, Department of General Surgery, Shanghai Ninth People's Hospital, Shanghai Jiao Tong University School of Medicine, Discipline Construction Research Center of China Hospital Development Institute, Shanghai Jiao Tong University, No. 639 Zhizaoju Road, Huangpu District, Shanghai 200011, China. sammizz1977@126.com

Abstract

BACKGROUND

Debate exists regarding the use of thermal ablation (TA) to treat papillary thyroid carcinoma (PTC). Some studies have recommended TA as a new, efficient and safe technology for PTC. In this article, we report one case of a residual tumor and central lymph node metastasis (CLNM) after TA for PTC.

CASE SUMMARY

A 63-year-old female underwent bilateral ultrasound (US)-guided radiofrequency ablation for PTC. Three months later, she was diagnosed as thyroid cancer with suspected CLNM by US and contrast-enhanced computed tomography. The subsequent fine-needle aspiration (FNA) biopsies were negative. Due to her strong personal preference, she underwent total thyroidectomy and central lymph node dissection. Local tissue adhesion and a difficult dissection were noted during the operation. The pathology of the frozen sections during the operation was still negative. The final pathology results of paraffin-embedded sections revealed residual tumor cells at the edge of the PTC and CLNM.

CONCLUSION

TA may lead to a residual tumor in patients with PTC. Follow-up using US and FNA biopsy may not be adequate to evaluate the residual tumor. TA should be carefully considered in PTC treatment.

Key Words: Papillary thyroid carcinoma; Thermal ablation; Residual tumor; Central lymph node metastasis; Follow-up; Case report

authors declare that there is no conflict of interests regarding this article.

CARE Checklist (2016) statement:

The authors have read the CARE Checklist (2016), and the manuscript was prepared and revised according to the CARE Checklist (2016).

Open-Access: This article is an open-access article that was selected by an in-house editor and fully peer-reviewed by external reviewers. It is distributed in accordance with the Creative Commons Attribution NonCommercial (CC BY-NC 4.0) license, which permits others to distribute, remix, adapt, build upon this work non-commercially, and license their derivative works on different terms, provided the original work is properly cited and the use is non-commercial. See: <http://creativecommons.org/licenses/by-nc/4.0/>

Manuscript source: Unsolicited manuscript

Specialty type: Medicine, research and experimental

Country/Territory of origin: China

Peer-review report's scientific quality classification

Grade A (Excellent): A

Grade B (Very good): 0

Grade C (Good): 0

Grade D (Fair): 0

Grade E (Poor): 0

Received: September 12, 2020

Peer-review started: September 12, 2020

First decision: September 24, 2020

Revised: October 6, 2020

Accepted: October 27, 2020

Article in press: October 27, 2020

Published online: January 6, 2021

P-Reviewer: Wang Y

S-Editor: Chen XF

L-Editor: Filipodia

P-Editor: Wang LL



©The Author(s) 2020. Published by Baishideng Publishing Group Inc. All rights reserved.

Core Tip: Thermal ablation may lead to a residual tumor in patients with papillary thyroid carcinoma. Follow-up using ultrasound and fine-needle-aspiration biopsy may not be adequate to evaluate the residual tumor. Therefore, thermal ablation of papillary thyroid carcinoma should be carefully considered.

Citation: Hua Y, Yang JW, He L, Xu H, Huo HZ, Zhu CF. Residual tumor and central lymph node metastasis after thermal ablation of papillary thyroid carcinoma: A case report and review of literature. *World J Clin Cases* 2021; 9(1): 252-261

URL: <https://www.wjgnet.com/2307-8960/full/v9/i1/252.htm>

DOI: <https://dx.doi.org/10.12998/wjcc.v9.i1.252>

INTRODUCTION

Recently, thermal ablation (TA) has become an acceptable treatment for benign thyroid nodules, and it has also been used to treat distant metastasis and locoregional recurrence of thyroid cancer. TA was described as an alternative treatment for primary papillary thyroid carcinoma (PTC), particularly in patients who were unwilling or unable to undergo surgery^[1-6], and TA was considered an efficacious and safe treatment with rare reports of residual tumor cells, recurrence, and metastasis. In this article, we report one patient with PTC who presented with a residual tumor and central lymph node metastasis (CLNM) after TA.

CASE PRESENTATION

Chief complaints

A 63-year-old female who presented with neck discomfort was admitted to our hospital.

History of present illness

She was diagnosed as bilateral PTC and received bilateral radiofrequency ablation (RFA) at another hospital on March 1, 2019. Prior to RFA, she received ultrasound (US) and fine-needle aspiration (FNA). US showed bilateral multiple thyroid nodules. The nodule in the left lobe was 4.2 mm × 5.2 mm × 4 mm in size, with irregular margins and calcification, and was classified as Thyroid Imaging Reporting and Data System (TI-RADS) 4a. The nodule in the right lobe, which was 11.6 mm × 6.4 mm × 9.3 mm in size, was classified as TI-RADS 3. No lymph node metastasis was detected. FNA biopsy revealed bilateral PTC. She was diagnosed as PTC (T₁N₀M₀), and she subsequently received bilateral RFA.

History of past illness

No special history of past illness was recorded.

Personal and family history

The patient denied family history of thyroid disease or malignancy.

Physical examination

No obviously palpable thyroid nodules and suspected lymph nodes could be touched on physical examination.

Laboratory examinations

No abnormal Laboratory examinations, including thyroid function, were detected.

Imaging examinations

Both US and contrast-enhanced computed tomography performed at our hospital showed bilateral suspected thyroid cancer with CLNM (Figure 1). The nodule in the

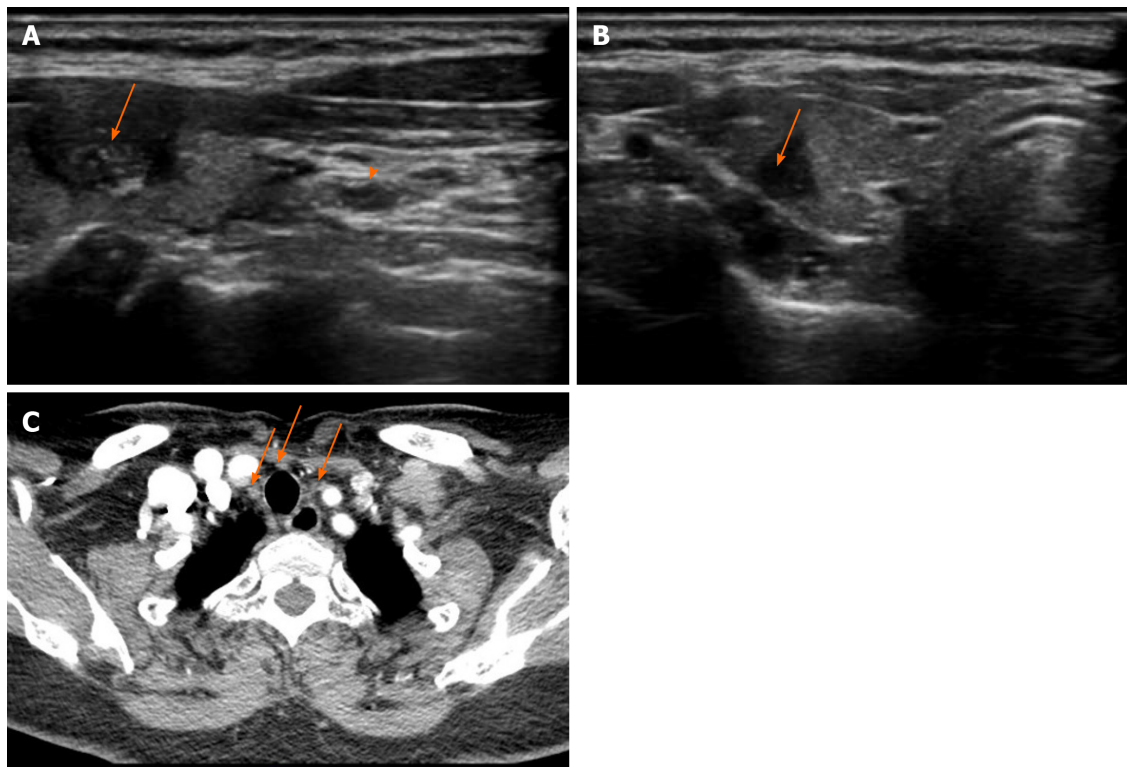


Figure 1 Ultrasound and contrast-enhanced computed tomography images obtained 3 mo after radiofrequency ablation for papillary thyroid carcinoma. A: The left thyroid nodule (arrow) (6 mm × 8 mm × 12 mm) with hypoechogenicity, unclear margins, and scattered small calcifications on ultrasound was classified as Thyroid Imaging Reporting and Data System stage 4c. Metastatic central lymph nodes (arrowhead) were also detected; B: The right thyroid nodule (5 mm × 5 mm × 7 mm) with hypoechogenicity and unclear margins on ultrasound was classified as Thyroid Imaging Reporting and Data System stage 4a; C: Central lymph node metastasis was detected using contrast-enhanced computed tomography.

left lobe (6 mm × 8 mm × 12 mm) with irregular margins and calcification was classified as TI-RADS 4c, and the nodule in the right lobe (5 mm × 5 mm × 7 mm) with unclear margins was classified as TI-RADS 4a by US.

Cytology

The patient underwent FNA biopsy again, but no PTC cells were detected.

Diagnosis procedure

Based on the patient's strong willingness to undergo a subsequent operation, she underwent total thyroidectomy with central lymph node dissection. In the operation, the thyroid tissue was extensively adhered to the surrounding tissue, and the thyroid tissue, parathyroid tissue, and recurrent laryngeal nerve were relatively difficult to be dissected. The pathology of frozen sections obtained during the operation still revealed no residual PTC cells.

FINAL DIAGNOSIS

The final pathology of paraffin-embedded sections revealed residual tumor cells along the edge of the tumor and CLNM (4/14+) (Figure 2). The patient was diagnosed as bilateral PTC with CLNM, stage I (T₁N₁M₀) after operation.

TREATMENT

The patient was treated with levothyroxine suppression therapy after surgery.

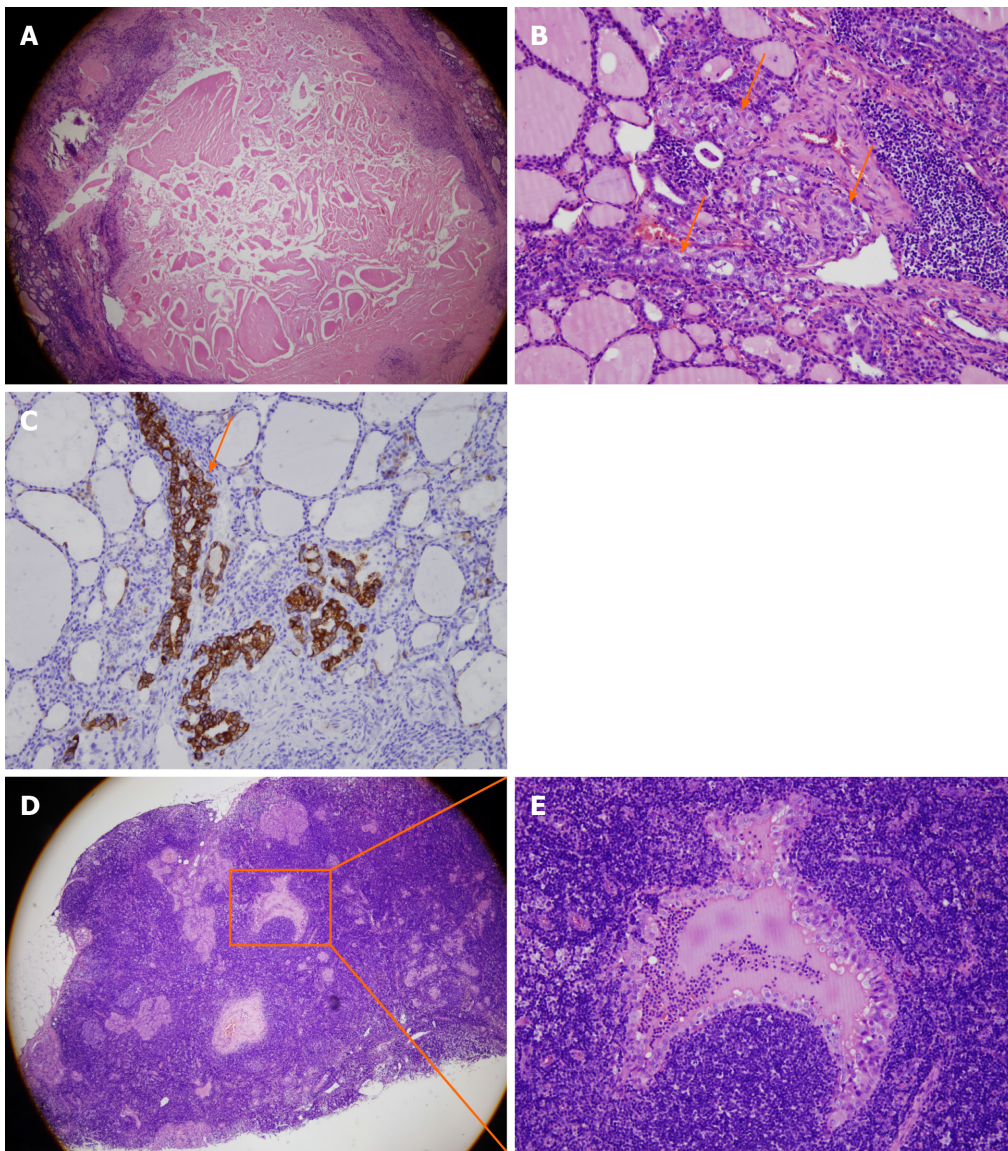


Figure 2 The images of pathological specimens showed residual papillary thyroid carcinoma and central lymph node metastasis. A: The middle part of the tumor was completely ablated, 50 × magnification; B: Residual tumor cells were detected at the edge of the tumor, 200 × magnification; C: Immunohistochemical staining showed residual tumor cells, 200 × magnification; D: Central lymph node metastasis, 50 × magnification. The boxed region is shown at higher magnification in E; E: Image of the box shown in D at 4 × magnification.

OUTCOME AND FOLLOW-UP

The patient was discharged from the hospital when her condition was stable. No recurrences or metastases were reported at the time of manuscript submission.

DISCUSSION

The Medline (PubMed) and Cochrane Library were searched using the following search terms: “Papillary thyroid carcinoma”, “radiofrequency ablation”, “thermal ablation”, “laser ablation”, “microwave ablation”, and/or “residual tumor”. This search was performed independently by two reviewers. Regions were not limited. The languages of reference were only English and Chinese, and the references published before April 1, 2020 were collected in this study.

Since the 1990s, TA, including RFA, laser ablation (LA), and microwave ablation (MWA), has been used to treat solid organ tumors, such as liver carcinoma^[7], renal cancer^[8], lung cancer^[9], and prostate cancer^[10]. To date, TA has been adopted by National Comprehensive Cancer Network guidelines for some solid tumors. Regarding the use of ablation for thyroid tumors, Pacella *et al*^[11] first reported the use

of LA to treat two patients with autonomously functioning thyroid nodules in 2000. Dupuy *et al*^[12] used RFA to treat the regional recurrence of well-differentiated thyroid cancer in 2001. Kim *et al*^[13] first succeeded in using RFA to treat benign thyroid nodules in 2006. Jeong *et al*^[14] showed an 84.1% shrinkage in the average volume of benign thyroid nodules after RFA in 236 patients. Zhang *et al*^[11] reported a prospective study of 98 papillary thyroid microcarcinomas (PTMCs) in 92 patients that explored the efficacy and safety of US-guided RFA for the treatment of low-risk PTMC. No residual tumors, recurrence, or metastasis was detected during the 18-mo follow-up using US, contrast-enhanced US (CEUS), or core-needle biopsy (CNB).

The 2017 Thyroid Radiofrequency Ablation guidelines in Korea^[15] recommended the use of RFA for patients with benign thyroid nodules complaining of symptomatic or cosmetic problems, patients with recurrent thyroid cancer at high surgical risk or who refused surgery, and, alternatively, patients with primary thyroid cancer who refused surgery or were unable to undergo an operation. The Italian consensus statement on minimally invasive treatments for benign thyroid nodules^[16] suggested that TA may be proposed as a first-line treatment for solid non-functioning thyroid nodules that are benign according to cytology when they cause symptoms. The 2015 American Thyroid Association guidelines^[17] proposed TA as a choice for patients with PTC presenting with metastatic disease and suggested that responsiveness to TA is associated with improved survival in patients with distant metastases to various organs; the guidelines also proposed that RFA shows high efficacy in treating individual distant metastases of advanced thyroid cancer with relatively few side effects. A 2018 Chinese expert consensus^[18] recommended TA as a treatment for benign thyroid nodules, but the routine use of TA for papillary thyroid microcarcinoma has not been established due to insufficient medical evidence. China also permits TA to be conducted by experienced doctors with more than 2 years of experience performing TA in the thyroid. The preliminary common indications include the following: A thyroid nodule diameter less than 5 mm (or less than 10 mm without invasion of the capsule), PTC confirmed by FNA biopsy before surgery, no cervical lymph node metastasis or distant metastasis, no history of neck irradiation, and anxiety or a desire for minimally invasive treatment.

Numerous studies have been conducted to explore the efficacy and safety of TA for PTC. The PubMed database was searched to identify publications on thermal ablation in treating PTC. The following search terms were used: [(papillary thyroid carcinoma) AND (radiofrequency ablation OR laser ablation OR microwave ablation OR thermal ablation)]. The detailed characteristics of the searched studies are shown in Table 1. Four of them are randomized controlled trials. Eight studies investigated RFA^[1,2,19-24], four explored LA^[25-28], and six studied MWA^[5,6,29-32]. The cohort sizes ranged from six to 421 patients, with the numbers of PTC nodules ranging from six to 440 total nodules. All TA-treated subjects included were ineligible for surgery or refused surgery, except in the study by Luo *et al*^[20] (the inclusion criteria were not mentioned). The main follow-up examinations included US, CEUS, computed tomography, and FNA biopsy or CNB. Yue *et al*^[5] reported three cases of immediate thyroidectomy after MWA, and complete necrosis of the tumor was confirmed. The follow-up periods in these studies ranged from 2 mo to 104 mo. The results from eight studies^[1,2,5,6,19,22,23,29] were satisfactory, with no residual cancer cells, recurrences, or metastases. Furthermore, comparisons of the efficacy and safety of RFA, LA, or MWA and surgery for the treatment of PTMC showed that the performance of TA was not inferior to surgery regarding the therapeutic effect, incidence of complications, recurrences, metastases, and disease-free survival^[28,29,31,33]. According to recently published reviews and meta-analyses, all types of TA had reasonable safety and efficacy profiles for the treatment of PTMC^[34-38]. Choi *et al*^[37] reported that LA was less effective than RFA at reducing the volume of PTMC. Cho *et al*^[38] concluded that TA provides excellent local tumor control in low-risk patients with PTMC, but strict inclusion criteria and technical expertise are required to obtain favorable results. However, the limitations of these studies include an insufficient evidence level, inaccurate comparisons due to different baseline data of the enrolled patients, inconsistent parameters for US-guided ablation, short follow-up durations, and ambiguous clinical risk stratification of PTMC due to insufficient prognostic factors.

Few articles have reported problems after TA, such as a residual tumor, needle track seeding, incidental papillary microfoci, lymph node micrometastasis, and possible carcinogenic effects. Incomplete ablation was observed in one RFA study and three LA studies, and second ablations were conducted^[21,25-27]. A biopsy confirmed that recurrences and cervical lymph node metastases occurred after the use of all three techniques^[20,24,26-28,30-32]. The shortest follow-up durations during which recurrence and cervical lymph node metastasis were detected were 1 mo^[30] and 6 mo^[31], respectively.

Table 1 Characteristics of selected studies

Technique	Ref.	No. of patients/tumors	Follow-up periods/mo, mean \pm SD (range)	Follow-up examinations	No. of incomplete ablation	No. of recurrence/mo, post-TA	No. of cervical lymph node metastasis/mo, post-TA
RFA	Zhang <i>et al</i> ^[1] , 2016	92/98	7.8 \pm 2.9 (3-18)	US, CEUS, and CNB	0	0	0
RFA	Kim <i>et al</i> ^[19] , 2017	6/6	48.5 \pm 12.3 (36-65)	FNA and CNB	0	0	0
RFA	Luo <i>et al</i> ^[20] , 2017	421/440	N/A (12-36)	US, CEUS and biopsy	0	4 proven; 5 suspicious (N/A)	4 (N/A)
RFA	Jeong <i>et al</i> ^[21] , 2018	6/7	19.3 \pm 3.5 (15-24)	US and CT	1	0	0
RFA	Zhang <i>et al</i> ^[22] , 2019	60/60	N/A (18-60)	US, CEUS, and CNB	0	0	0
RFA	Ding <i>et al</i> ^[23] , 2019	37/38	N/A (1-18)	CEUS and CT	0	0	0
RFA	Lim <i>et al</i> ^[2] , 2019	133/152	39 \pm 25 (6-104)	US, CT, and biopsy	0	0	0
RFA ¹	Zhang <i>et al</i> ^[24] , 2020	94/94	64.2 \pm 2.8 (median \pm SD)	US, CEUS, CNB, CT, PET, and bone scan	0	1 (N/A)	0
LA	Zhou <i>et al</i> ^[25] , 2017	30/30	13.2 (12-24)	US, CEUS, chest X-ray or CT, and FNA	1	0	0
LA	Zhang <i>et al</i> ^[26] , 2018	64/64	25.7 \pm 8.2 (12-42)	US, CEUS, and FNA	2	0	1 (30)
LA	Ji <i>et al</i> ^[27] , 2019	37/37	16.5 \pm 6.9 (12-24)	US, CEUS, and chest radiographs or CT	8	0	1 (24)
LA ¹	Zhou <i>et al</i> ^[28] , 2019	36/36	49.2 \pm 4.5 (30-54)	US, chest X-ray or CT, and FNA	0	1 (42)	1 (30)
MWA	Yue <i>et al</i> ^[5] , 2014	21/21	11 (3-22)	US, chest X-ray or CT, and biopsy	0	0	0
MWA ¹	Li <i>et al</i> ^[29] , 2018	46/46	42	US, CEUS, and biopsy	0	0	0
MWA	Teng <i>et al</i> ^[6] , 2018	15/21	N/A (36-48)	US, CT, and FNA	0	0	0
MWA	Teng <i>et al</i> ^[30] , 2019	185/206	20.7 \pm 8.8 (12-36)	US and FNA	0	1 (1)	0
MWA ¹	Li <i>et al</i> ^[31] , 2019	168/168	25.1 \pm 17.3 (2-60)	US and FNA	0	2 (36-44)	5 (6-44)
MWA	Yue <i>et al</i> ^[32] , 2020	119/119	37.2 \pm 20.9 (12-101)	US, CEUS, CNB, and CT	0	0	1 (26)

¹Randomized controlled trials. CEUS: Contrast-enhanced ultrasound; CNB: Core-needle biopsy; CT: Computed tomography; FNA: Fine-needle aspiration;

LA: Laser ablation; MWA: Microwave ablation; N/A: Not available; PET: Positron emission tomography; RFA: Radiofrequency ablation; SD: Standard deviation; TA: Thermal ablation; US: Ultrasound.

Notably, the 1 mo recurrence was another small nodule that had not been detected before MWA. Patients with recurrence or cervical lymph node metastases underwent a second RFA or surgery. Ma *et al*^[39] reported 11 patients with PTC treated with RFA and one patient with PTC treated with MWA who were surgically confirmed to have residual PTC cells (12/12) and lymph node metastases (8/12). In the study by Kim *et al*^[40], one patient underwent robotic thyroid surgery after incomplete RFA for PTC, but the patient had not been diagnosed before RFA. Lee *et al*^[41] observed needle track PTC seeding after a second RFA for thyroid cancer that appeared benign. Ruzzenente *et al*^[42] and Koda *et al*^[43] also reported needle track seeding and rapid tumor progression after RFA for hepatocellular carcinoma. Valcavi *et al*^[44] found two cases of incidental papillary microfoci and one case of lymph node micrometastasis during immediate thyroidectomy surgery after LA for PTMC. Ergul *et al*^[44] reported a rare case of mixed papillary and medullary thyroid carcinoma, which might have occurred due to LA for a benign thyroid nodule 2 years previously.

In our case, tumor shrinkage of bilateral PTC was also detected on follow-up US, but the TI-RADS classifications of the bilateral nodules after TA were still 4. The pathology of the sample obtained through repeated FNA biopsy was negative. However, residual tumor cells were detected at the edge of the PTC. Therefore, we should consider whether US, CEUS, and biopsy are adequate to evaluate the thoroughness of TA. Actually, changes in the tumor size or disappearance on US should not be used to confirm the complete ablation of the tumor. Moreover, the middle portions of the bilateral tumors were completely ablated, while residual tumor cells were mainly located along the edges. In US-guided TA, doctors may generally focus on the middle portion of the nodules. This focus may explain why the pathology results of the FNA biopsy and frozen sections were negative. Metastatic lymph nodes were only detected 3 mo later and may be due to a missed diagnosis before TA or the progression of residual cancer cells after TA. The diagnostic accuracy of US for cervical lymph node metastases in patients with PTC, depending on the experience of the radiologist, was reported to range from 55.8% to 95.2%^[45-50]. US showed worse performance in identifying CLNM than lateral lymph node metastases^[51]. Therefore, the use of US alone to determine the presence of lymph node metastasis before TA is not sufficient. In addition, because TA exacerbated the adhesion of the thyroid tissue to the surrounding tissue, the dissection of the thyroid tissue, parathyroid tissue, and recurrent laryngeal nerve was difficult. The complication rate might be relatively higher after thyroidectomy. In summary, the efficacy and safety of TA for PTC must be carefully considered. The use of US, CEUS, and CNB or FNA biopsy as follow-up assessments for the efficiency of TA may be insufficient. Additional prospective, multi-center, randomized controlled studies with large populations and longer follow-up periods are necessary in the future.

CONCLUSION

In conclusion, TA is unable to guarantee complete PTMC ablation or resolve cervical lymph node metastases, the current follow-up methods are not reliable, and subsequent surgery is more difficult after TA. Therefore, TA is not recommended as a routine treatment for PTMC.

REFERENCES

- 1 **Zhang M**, Luo Y, Zhang Y, Tang J. Efficacy and Safety of Ultrasound-Guided Radiofrequency Ablation for Treating Low-Risk Papillary Thyroid Microcarcinoma: A Prospective Study. *Thyroid* 2016; **26**: 1581-1587 [PMID: 27445090 DOI: 10.1089/thy.2015.0471]
- 2 **Lim HK**, Cho SJ, Baek JH, Lee KD, Son CW, Son JM, Baek SM. US-Guided Radiofrequency Ablation for Low-Risk Papillary Thyroid Microcarcinoma: Efficacy and Safety in a Large Population. *Korean J Radiol* 2019; **20**: 1653-1661 [PMID: 31854153 DOI: 10.3348/kjr.2019.0192]
- 3 **Papini E**, Guglielmi R, Gharib H, Misichi I, Graziano F, Chianelli M, Crescenzi A, Bianchini A, Valle D, Bizzarri G. Ultrasound-guided laser ablation of incidental papillary thyroid microcarcinoma: a potential therapeutic approach in patients at surgical risk. *Thyroid* 2011; **21**: 917-920 [PMID: 21811111 DOI: 10.1089/thy.2010.0311]

- 21595556 DOI: [10.1089/thy.2010.0447](https://doi.org/10.1089/thy.2010.0447)]
- 4 **Valcavi R**, Piana S, Bortolan GS, Lai R, Barbieri V, Negro R. Ultrasound-guided percutaneous laser ablation of papillary thyroid microcarcinoma: a feasibility study on three cases with pathological and immunohistochemical evaluation. *Thyroid* 2013; **23**: 1578-1582 [PMID: [23978269](https://pubmed.ncbi.nlm.nih.gov/23978269/) DOI: [10.1089/thy.2013.0279](https://doi.org/10.1089/thy.2013.0279)]
 - 5 **Yue W**, Wang S, Yu S, Wang B. Ultrasound-guided percutaneous microwave ablation of solitary T1N0M0 papillary thyroid microcarcinoma: initial experience. *Int J Hyperthermia* 2014; **30**: 150-157 [PMID: [24571178](https://pubmed.ncbi.nlm.nih.gov/24571178/) DOI: [10.3109/02656736.2014.885590](https://doi.org/10.3109/02656736.2014.885590)]
 - 6 **Teng D**, Sui G, Liu C, Wang Y, Xia Y, Wang H. Long-term efficacy of ultrasound-guided low power microwave ablation for the treatment of primary papillary thyroid microcarcinoma: a 3-year follow-up study. *J Cancer Res Clin Oncol* 2018; **144**: 771-779 [PMID: [29427209](https://pubmed.ncbi.nlm.nih.gov/29427209/) DOI: [10.1007/s00432-018-2607-7](https://doi.org/10.1007/s00432-018-2607-7)]
 - 7 **Rossi S**, Di Stasi M, Buscarini E, Cavanna L, Quaretti P, Squassante E, Garbagnati F, Buscarini L. Percutaneous radiofrequency interstitial thermal ablation in the treatment of small hepatocellular carcinoma. *Cancer J Sci Am* 1995; **1**: 73-81 [PMID: [9166457](https://pubmed.ncbi.nlm.nih.gov/9166457/)]
 - 8 **Zlotta AR**, Wildschutz T, Raviv G, Peny MO, van Gansbeke D, Noel JC, Schulman CC. Radiofrequency interstitial tumor ablation (RITA) is a possible new modality for treatment of renal cancer: ex vivo and in vivo experience. *J Endourol* 1997; **11**: 251-258 [PMID: [9376843](https://pubmed.ncbi.nlm.nih.gov/9376843/) DOI: [10.1089/end.1997.11.251](https://doi.org/10.1089/end.1997.11.251)]
 - 9 **Dupuy DE**, Zagoria RJ, Akerley W, Mayo-Smith WW, Kavanagh PV, Safran H. Percutaneous radiofrequency ablation of malignancies in the lung. *AJR Am J Roentgenol* 2000; **174**: 57-59 [PMID: [10628454](https://pubmed.ncbi.nlm.nih.gov/10628454/) DOI: [10.2214/ajr.174.1.1740057](https://doi.org/10.2214/ajr.174.1.1740057)]
 - 10 **Chin JL**, Billia M, Relle J, Roethke MC, Popeneciu IV, Kuru TH, Hatiboglu G, Mueller-Wolf MB, Motsch J, Romagnoli C, Kassam Z, Harle CC, Hafron J, Nandalur KR, Chronik BA, Burtnyk M, Schlemmer HP, Pahernik S. Magnetic Resonance Imaging-Guided Transurethral Ultrasound Ablation of Prostate Tissue in Patients with Localized Prostate Cancer: A Prospective Phase I Clinical Trial. *Eur Urol* 2016; **70**: 447-455 [PMID: [26777228](https://pubmed.ncbi.nlm.nih.gov/26777228/) DOI: [10.1016/j.eururo.2015.12.029](https://doi.org/10.1016/j.eururo.2015.12.029)]
 - 11 **Pacella CM**, Bizzarri G, Guglielmi R, Anelli V, Bianchini A, Crescenzi A, Pacella S, Papini E. Thyroid tissue: US-guided percutaneous interstitial laser ablation-a feasibility study. *Radiology* 2000; **217**: 673-677 [PMID: [11110927](https://pubmed.ncbi.nlm.nih.gov/11110927/) DOI: [10.1148/radiology.217.3.r00dc09673](https://doi.org/10.1148/radiology.217.3.r00dc09673)]
 - 12 **Dupuy DE**, Monchik JM, Decrea C, Pisharodi L. Radiofrequency ablation of regional recurrence from well-differentiated thyroid malignancy. *Surgery* 2001; **130**: 971-977 [PMID: [11742325](https://pubmed.ncbi.nlm.nih.gov/11742325/) DOI: [10.1067/msy.2001.118708](https://doi.org/10.1067/msy.2001.118708)]
 - 13 **Kim YS**, Rhim H, Tae K, Park DW, Kim ST. Radiofrequency ablation of benign cold thyroid nodules: initial clinical experience. *Thyroid* 2006; **16**: 361-367 [PMID: [16646682](https://pubmed.ncbi.nlm.nih.gov/16646682/) DOI: [10.1089/thy.2006.16.361](https://doi.org/10.1089/thy.2006.16.361)]
 - 14 **Jeong WK**, Baek JH, Rhim H, Kim YS, Kwak MS, Jeong HJ, Lee D. Radiofrequency ablation of benign thyroid nodules: safety and imaging follow-up in 236 patients. *Eur Radiol* 2008; **18**: 1244-1250 [PMID: [18286289](https://pubmed.ncbi.nlm.nih.gov/18286289/) DOI: [10.1007/s00330-008-0880-6](https://doi.org/10.1007/s00330-008-0880-6)]
 - 15 **Kim JH**, Baek JH, Lim HK, Ahn HS, Baek SM, Choi YJ, Choi YJ, Chung SR, Ha EJ, Hahn SY, Jung SL, Kim DS, Kim SJ, Kim YK, Lee CY, Lee JH, Lee KH, Lee YH, Park JS, Park H, Shin JH, Suh CH, Sung JY, Sim JS, Youn I, Choi M, Na DG; Guideline Committee for the Korean Society of Thyroid Radiology (KSThR) and Korean Society of Radiology. 2017 Thyroid Radiofrequency Ablation Guideline: Korean Society of Thyroid Radiology. *Korean J Radiol* 2018; **19**: 632-655 [PMID: [29962870](https://pubmed.ncbi.nlm.nih.gov/29962870/) DOI: [10.3348/kjr.2018.19.4.632](https://doi.org/10.3348/kjr.2018.19.4.632)]
 - 16 **Papini E**, Pacella CM, Solbiati LA, Achille G, Barbaro D, Bernardi S, Cantisani V, Cesareo R, Chiti A, Cozzaglio L, Crescenzi A, De Cobelli F, Deandrea M, Fugazzola L, Gambelunghe G, Garberoglio R, Giugliano G, Luzi L, Negro R, Persani L, Raggiunti B, Sardanelli F, Seregni E, Sollini M, Spiezia S, Stacul F, Van Doorne D, Sconfienza LM, Mauri G. Minimally-invasive treatments for benign thyroid nodules: a Delphi-based consensus statement from the Italian minimally-invasive treatments of the thyroid (MITT) group. *Int J Hyperthermia* 2019; **36**: 376-382 [PMID: [30909759](https://pubmed.ncbi.nlm.nih.gov/30909759/) DOI: [10.1080/02656736.2019.1575482](https://doi.org/10.1080/02656736.2019.1575482)]
 - 17 **Haugen BR**, Alexander EK, Bible KC, Doherty GM, Mandel SJ, Nikiforov YE, Pacini F, Randolph GW, Sawka AM, Schlumberger M, Schuff KG, Sherman SI, Sosa JA, Steward DL, Tuttle RM, Wartofsky L. 2015 American Thyroid Association Management Guidelines for Adult Patients with Thyroid Nodules and Differentiated Thyroid Cancer: The American Thyroid Association Guidelines Task Force on Thyroid Nodules and Differentiated Thyroid Cancer. *Thyroid* 2016; **26**: 1-133 [PMID: [26462967](https://pubmed.ncbi.nlm.nih.gov/26462967/) DOI: [10.1089/thy.2015.0020](https://doi.org/10.1089/thy.2015.0020)]
 - 18 **Thyroid Tumor Ablation Experts Group of Chinese Medical Doctor Association**, Chinese Association of Thyroid Oncology, Interventional Ultrasound Committee of Chinese College of Interventionalists, Tumor Ablation Committee of Chinese College of Interventionalists, The Society of Interventional Therapy of China Anti-cancer Association, The Society of Minimally Invasive Therapy in Cancer of China Anti-cancer Association. Expert Consensus on Thermal Ablation for Thyroid Benign Nodules, Microcarcinoma and Metastatic Cervical Lymph Nodes (2018 Edition). *Zhongguo Zhongliu* 2018; **27**: 768-773 [DOI: [10.11735/j.issn.1004-0242.2018.10.A006](https://doi.org/10.11735/j.issn.1004-0242.2018.10.A006)]
 - 19 **Kim JH**, Baek JH, Sung JY, Min HS, Kim KW, Hah JH, Park DJ, Kim KH, Cho BY, Na DG. Radiofrequency ablation of low-risk small papillary thyroidcarcinoma: preliminary results for patients ineligible for surgery. *Int J Hyperthermia* 2017; **33**: 212-219 [PMID: [27590679](https://pubmed.ncbi.nlm.nih.gov/27590679/) DOI: [10.1080/02656736.2016.1230893](https://doi.org/10.1080/02656736.2016.1230893)]

- 20 **Luo YK**, Zhang MB. Ultrasound-Guided Radiofrequency Ablation of Low-Risk Papillary Thyroid Microcarcinoma: a Prospective Study. *Ultrasound in Med & Biol* 2017; **43**: S240-S241 [DOI: [10.1016/j.ultrasmedbio.2017.08.1841](https://doi.org/10.1016/j.ultrasmedbio.2017.08.1841)]
- 21 **Jeong SY**, Baek JH, Choi YJ, Chung SR, Sung TY, Kim WG, Kim TY, Lee JH. Radiofrequency ablation of primary thyroid carcinoma: efficacy according to the types of thyroid carcinoma. *Int J Hyperthermia* 2018; **34**: 611-616 [PMID: [29322881](https://pubmed.ncbi.nlm.nih.gov/29322881/) DOI: [10.1080/02656736.2018.1427288](https://doi.org/10.1080/02656736.2018.1427288)]
- 22 **Zhang Y**, Zhang MB, Luo YK, Li J, Zhang Y, Tang J. Effect of chronic lymphocytic thyroiditis on the efficacy and safety of ultrasound-guided radiofrequency ablation for papillary thyroid microcarcinoma. *Cancer Med* 2019; **8**: 5450-5458 [PMID: [31359613](https://pubmed.ncbi.nlm.nih.gov/31359613/) DOI: [10.1002/cam4.2406](https://doi.org/10.1002/cam4.2406)]
- 23 **Ding M**, Tang X, Cui D, Chi J, Shi Y, Wang T, Zhai B, Li P. Clinical outcomes of ultrasound-guided radiofrequency ablation for the treatment of primary papillary thyroid microcarcinoma. *Clin Radiol* 2019; **74**: 712-717 [PMID: [31253420](https://pubmed.ncbi.nlm.nih.gov/31253420/) DOI: [10.1016/j.crad.2019.05.012](https://doi.org/10.1016/j.crad.2019.05.012)]
- 24 **Zhang M**, Tufano RP, Russell JO, Zhang Y, Zhang Y, Qiao Z, Luo Y. Ultrasound-Guided Radiofrequency Ablation Versus Surgery for Low-Risk Papillary Thyroid Microcarcinoma: Results of Over 5 Years' Follow-Up. *Thyroid* 2020; **30**: 408-417 [PMID: [31910107](https://pubmed.ncbi.nlm.nih.gov/31910107/) DOI: [10.1089/thy.2019.0147](https://doi.org/10.1089/thy.2019.0147)]
- 25 **Zhou W**, Jiang S, Zhan W, Zhou J, Xu S, Zhang L. Ultrasound-guided percutaneous laser ablation of unifocal T1N0M0 papillary thyroid microcarcinoma: Preliminary results. *Eur Radiol* 2017; **27**: 2934-2940 [PMID: [27853812](https://pubmed.ncbi.nlm.nih.gov/27853812/) DOI: [10.1007/s00330-016-4610-1](https://doi.org/10.1007/s00330-016-4610-1)]
- 26 **Zhang L**, Zhou W, Zhan W, Peng Y, Jiang S, Xu S. Percutaneous Laser Ablation of Unifocal Papillary Thyroid Microcarcinoma: Utility of Conventional Ultrasound and Contrast-Enhanced Ultrasound in Assessing Local Therapeutic Response. *World J Surg* 2018; **42**: 2476-2484 [PMID: [29488064](https://pubmed.ncbi.nlm.nih.gov/29488064/) DOI: [10.1007/s00268-018-4500-6](https://doi.org/10.1007/s00268-018-4500-6)]
- 27 **Ji L**, Wu Q, Gu J, Deng X, Zhou W, Fan X, Zhou F. Ultrasound-guided percutaneous laser ablation for papillary thyroid microcarcinoma: a retrospective analysis of 37 patients. *Cancer Imaging* 2019; **19**: 16 [PMID: [30894228](https://pubmed.ncbi.nlm.nih.gov/30894228/) DOI: [10.1186/s40644-019-0204-x](https://doi.org/10.1186/s40644-019-0204-x)]
- 28 **Zhou W**, Ni X, Xu S, Zhang L, Chen Y, Zhan W. Ultrasound-guided laser ablation versus surgery for solitary papillary thyroid microcarcinoma: a retrospective study. *Int J Hyperthermia* 2019; **36**: 897-904 [PMID: [31464140](https://pubmed.ncbi.nlm.nih.gov/31464140/) DOI: [10.1080/02656736.2019.1649475](https://doi.org/10.1080/02656736.2019.1649475)]
- 29 **Li J**, Liu Y, Liu J, Qian L. Ultrasound-guided percutaneous microwave ablation versus surgery for papillary thyroid microcarcinoma. *Int J Hyperthermia* 2018; **34**: 653-659 [PMID: [29637797](https://pubmed.ncbi.nlm.nih.gov/29637797/) DOI: [10.1080/02656736.2018.1453092](https://doi.org/10.1080/02656736.2018.1453092)]
- 30 **Teng DK**, Li HQ, Sui GQ, Lin YQ, Luo Q, Fu P, Du JR, Jin CX, Wang H. Preliminary report of microwave ablation for the primary papillary thyroid microcarcinoma: a large-cohort of 185 patients feasibility study. *Endocrine* 2019; **64**: 109-117 [PMID: [30771153](https://pubmed.ncbi.nlm.nih.gov/30771153/) DOI: [10.1007/s12020-019-01868-2](https://doi.org/10.1007/s12020-019-01868-2)]
- 31 **Li J**, Liu Y, Liu J, Yang P, Hu X, Qian L. A comparative study of short-term efficacy and safety for thyroid micropapillary carcinoma patients after microwave ablation or surgery. *Int J Hyperthermia* 2019; **36**: 640-646 [PMID: [31244350](https://pubmed.ncbi.nlm.nih.gov/31244350/) DOI: [10.1080/02656736.2019.1626492](https://doi.org/10.1080/02656736.2019.1626492)]
- 32 **Yue WW**, Qi L, Wang DD, Yu SJ, Wang XJ, Xu HX, Wang SR. US-guided Microwave Ablation of Low-Risk Papillary Thyroid Microcarcinoma: Longer-Term Results of a Prospective Study. *J Clin Endocrinol Metab* 2020; **105**: dgaa128 [PMID: [32198508](https://pubmed.ncbi.nlm.nih.gov/32198508/) DOI: [10.1210/clinem/dgaa128](https://doi.org/10.1210/clinem/dgaa128)]
- 33 **Xu B**, Zhou NM, Cao WT, Gu SY. Comparative study on operative trauma between microwave ablation and surgical treatment for papillary thyroid microcarcinoma. *World J Clin Cases* 2018; **6**: 936-943 [PMID: [30568949](https://pubmed.ncbi.nlm.nih.gov/30568949/) DOI: [10.12998/wjcc.v6.i15.936](https://doi.org/10.12998/wjcc.v6.i15.936)]
- 34 **Radzina M**, Cantisani V, Rauda M, Nielsen MB, Ewertsen C, D'Ambrosio F, Prieditis P, Sorrenti S. Update on the role of ultrasound guided radiofrequency ablation for thyroid nodule treatment. *Int J Surg* 2017; **41** Suppl 1: S82-S93 [PMID: [28506420](https://pubmed.ncbi.nlm.nih.gov/28506420/) DOI: [10.1016/j.ijso.2017.02.010](https://doi.org/10.1016/j.ijso.2017.02.010)]
- 35 **Tong M**, Li S, Li Y, Li Y, Feng Y, Che Y. Efficacy and safety of radiofrequency, microwave and laser ablation for treating papillary thyroid microcarcinoma: a systematic review and meta-analysis. *Int J Hyperthermia* 2019; **36**: 1278-1286 [PMID: [31826684](https://pubmed.ncbi.nlm.nih.gov/31826684/) DOI: [10.1080/02656736.2019.1700559](https://doi.org/10.1080/02656736.2019.1700559)]
- 36 **Chen J**, Cao J, Qiu F, Huang P. The Efficacy and The Safety of Ultrasound-guided Ablation Therapy for Treating Papillary Thyroid Microcarcinoma. *J Cancer* 2019; **10**: 5272-5282 [PMID: [31602278](https://pubmed.ncbi.nlm.nih.gov/31602278/) DOI: [10.7150/jca.36289](https://doi.org/10.7150/jca.36289)]
- 37 **Choi Y**, Jung SL. Efficacy and Safety of Thermal Ablation Techniques for the Treatment of Primary Papillary Thyroid Microcarcinoma: A Systematic Review and Meta-Analysis. *Thyroid* 2020; **30**: 720-731 [PMID: [31801432](https://pubmed.ncbi.nlm.nih.gov/31801432/) DOI: [10.1089/thy.2019.0707](https://doi.org/10.1089/thy.2019.0707)]
- 38 **Cho SJ**, Baek JH, Chung SR, Choi YJ, Lee JH. Thermal Ablation for Small Papillary Thyroid Cancer: A Systematic Review. *Thyroid* 2019; **29**: 1774-1783 [PMID: [31739738](https://pubmed.ncbi.nlm.nih.gov/31739738/) DOI: [10.1089/thy.2019.0377](https://doi.org/10.1089/thy.2019.0377)]
- 39 **Ma B**, Wei W, Xu W, Wang Y, Guan H, Fan J, Zhao Z, Wen D, Yang S, Wang Y, Chang B, Ji Q. Surgical Confirmation of Incomplete Treatment for Primary Papillary Thyroid Carcinoma by Percutaneous Thermal Ablation: A Retrospective Case Review and Literature Review. *Thyroid* 2018; **28**: 1134-1142 [PMID: [29962285](https://pubmed.ncbi.nlm.nih.gov/29962285/) DOI: [10.1089/thy.2017.0558](https://doi.org/10.1089/thy.2017.0558)]
- 40 **Kim HY**, Ryu WS, Woo SU, Son GS, Lee ES, Lee JB, Bae JW. Primary papillary thyroid carcinoma previously treated incompletely with radiofrequency ablation. *J Cancer Res Ther* 2010; **6**: 310-312 [PMID: [21119260](https://pubmed.ncbi.nlm.nih.gov/21119260/) DOI: [10.4103/0973-1482.73328](https://doi.org/10.4103/0973-1482.73328)]
- 41 **Lee CU**, Kim SJ, Sung JY, Park SH, Chong S, Baek JH. Needle track tumor seeding after radiofrequency ablation of a thyroid tumor. *Jpn J Radiol* 2014; **32**: 661-663 [PMID: [25135827](https://pubmed.ncbi.nlm.nih.gov/25135827/) DOI: [10.1007/s11404-014-9661-1](https://doi.org/10.1007/s11404-014-9661-1)]

- 10.1007/s11604-014-0350-9]
- 42 **Ruzzenente A**, Manzoni GD, Molfetta M, Pachera S, Genco B, Donatiggio M, Guglielmi A. Rapid progression of hepatocellular carcinoma after Radiofrequency Ablation. *World J Gastroenterol* 2004; **10**: 1137-1140 [PMID: [15069713](#) DOI: [10.3748/wjg.v10.i8.1137](#)]
 - 43 **Koda M**, Murawaki Y, Hirooka Y, Kitamoto M, Ono M, Sakaeda H, Joko K, Sato S, Tamaki K, Yamasaki T, Shibata H, Shimoe T, Matsuda T, Toshikuni N, Fujioka S, Ohmoto K, Nakamura S, Kariyama K, Aikata H, Kobayashi Y, Tsutsui A. Complications of radiofrequency ablation for hepatocellular carcinoma in a multicenter study: An analysis of 16,346 treated nodules in 13,283 patients. *Hepatol Res* 2012; **42**: 1058-1064 [PMID: [22583706](#) DOI: [10.1111/j.1872-034X.2012.01025.x](#)]
 - 44 **Ergul E**, Gozetic EO. Does percutaneous thyroid laser ablation induce mixed papillary and medullary thyroid carcinoma? *Acta Chir Belg* 2010; **110**: 228-231 [PMID: [20514841](#) DOI: [10.1080/00015458.2010.11680605](#)]
 - 45 **Shimamoto K**, Satake H, Sawaki A, Ishigaki T, Funahashi H, Imai T. Preoperative staging of thyroid papillary carcinoma with ultrasonography. *Eur J Radiol* 1998; **29**: 4-10 [PMID: [9934552](#) DOI: [10.1016/s0720-048x\(97\)00184-8](#)]
 - 46 **Stulak JM**, Grant CS, Farley DR, Thompson GB, van Heerden JA, Hay ID, Reading CC, Charboneau JW. Value of preoperative ultrasonography in the surgical management of initial and reoperative papillary thyroid cancer. *Arch Surg* 2006; **141**: 489-494 [PMID: [16702521](#) DOI: [10.1001/archsurg.141.5.489](#)]
 - 47 **Kim E**, Park JS, Son KR, Kim JH, Jeon SJ, Na DG. Preoperative diagnosis of cervical metastatic lymph nodes in papillary thyroid carcinoma: comparison of ultrasound, computed tomography, and combined ultrasound with computed tomography. *Thyroid* 2008; **18**: 411-418 [PMID: [18358074](#) DOI: [10.1089/thy.2007.0269](#)]
 - 48 **Choi YJ**, Yun JS, Kook SH, Jung EC, Park YL. Clinical and imaging assessment of cervical lymph node metastasis in papillary thyroid carcinomas. *World J Surg* 2010; **34**: 1494-1499 [PMID: [20372903](#) DOI: [10.1007/s00268-010-0541-1](#)]
 - 49 **Lee DW**, Ji YB, Sung ES, Park JS, Lee YJ, Park DW, Tae K. Roles of ultrasonography and computed tomography in the surgical management of cervical lymph node metastases in papillary thyroid carcinoma. *Eur J Surg Oncol* 2013; **39**: 191-196 [PMID: [22863305](#) DOI: [10.1016/j.ejso.2012.07.119](#)]
 - 50 **Wei Q**, Wu D, Luo H, Wang X, Zhang R, Liu Y. Features of lymph node metastasis of papillary thyroid carcinoma in ultrasonography and CT and the significance of their combination in the diagnosis and prognosis of lymph node metastasis. *J BUON* 2018; **23**: 1041-1048 [PMID: [30358209](#)]
 - 51 **Zhao H**, Li H. Meta-analysis of ultrasound for cervical lymph nodes in papillary thyroid cancer: Diagnosis of central and lateral compartment nodal metastases. *Eur J Radiol* 2019; **112**: 14-21 [PMID: [30777203](#) DOI: [10.1016/j.ejrad.2019.01.006](#)]



Published by **Baishideng Publishing Group Inc**
7041 Koll Center Parkway, Suite 160, Pleasanton, CA 94566, USA

Telephone: +1-925-3991568

E-mail: bpgoffice@wjgnet.com

Help Desk: <https://www.f6publishing.com/helpdesk>

<https://www.wjgnet.com>

