

# World Journal of *Clinical Cases*

*World J Clin Cases* 2021 April 6; 9(10): 2160-2418



### MINIREVIEWS

- 2160** Tertiary peritonitis: A disease that should not be ignored  
*Marques HS, Araújo GRL, da Silva FAF, de Brito BB, Versiani PVD, Caires JS, Milet TC, de Melo FF*
- 2170** SARS-CoV-2, surgeons and surgical masks  
*Khalil MI, Banik GR, Mansoor S, Alqahtani AS, Rashid H*

### ORIGINAL ARTICLE

#### Case Control Study

- 2181** Igaratimod promotes transformation of mononuclear macrophages in elderly patients with rheumatoid arthritis by nuclear factor- $\kappa$ B pathway  
*Liu S, Song LP, Li RB, Feng LH, Zhu H*

#### Retrospective Study

- 2192** Factors associated with overall survival in early gastric cancer patients who underwent additional surgery after endoscopic submucosal dissection  
*Zheng Z, Bu FD, Chen H, Yin J, Xu R, Cai J, Zhang J, Yao HW, Zhang ZT*
- 2205** Epidemiological and clinical characteristics of 65 hospitalized patients with COVID-19 in Liaoning, China  
*Zhang W, Ban Y, Wu YH, Liu JY, Li XH, Wu H, Li H, Chen R, Yu XX, Zheng R*
- 2218** Comprehensive clinicopathologic characteristics of intraabdominal neurogenic tumors: Single institution experience  
*Simsek C, Uner M, Ozkara F, Akman O, Akyol A, Kav T, Sokmensuer C, Gedikoglu G*
- 2228** Distribution and drug resistance of pathogens in burn patients in China from 2006 to 2019  
*Chen H, Yang L, Cheng L, Hu XH, Shen YM*

#### Observational Study

- 2238** Impact of simethicone on bowel cleansing during colonoscopy in Chinese patients  
*Zhang H, Liu J, Ma SL, Huang ML, Fan Y, Song M, Yang J, Zhang XX, Song QL, Gong J, Huang PX, Zhang H*

#### Prospective Study

- 2247** Effect of suspension training on neuromuscular function, postural control, and knee kinematics in anterior cruciate ligament reconstruction patients  
*Huang DD, Chen LH, Yu Z, Chen QJ, Lai JN, Li HH, Liu G*

### CASE REPORT

- 2259** Turner syndrome with positive SRY gene and non-classical congenital adrenal hyperplasia: A case report  
*He MN, Zhao SC, Li JM, Tong LL, Fan XZ, Xue YM, Lin XH, Cao Y*

- 2268** Mechanical thrombectomy for acute occlusion of the posterior inferior cerebellar artery: A case report  
*Zhang HB, Wang P, Wang Y, Wang JH, Li Z, Li R*
- 2274** Bilateral retrocorneal hyaline scrolls secondary to asymptomatic congenital syphilis: A case report  
*Jin YQ, Hu YP, Dai Q, Wu SQ*
- 2281** Recurrent undifferentiated embryonal sarcoma of the liver in adult patient treated by pembrolizumab: A case report  
*Yu XH, Huang J, Ge NJ, Yang YF, Zhao JY*
- 2289** Adult onset type 2 familial hemophagocytic lymphohistiocytosis with *PRF1* c.65delC/c.163C>T compound heterozygous mutations: A case report  
*Liu XY, Nie YB, Chen XJ, Gao XH, Zhai LJ, Min FL*
- 2296** Salvage of vascular graft infections *via* vacuum sealing drainage and rectus femoris muscle flap transposition: A case report  
*Zhang P, Tao FL, Li QH, Zhou DS, Liu FX*
- 2302** Innovative chest wall reconstruction with a locking plate and cement spacer after radical resection of chondrosarcoma in the sternum: A case report  
*Lin CW, Ho TY, Yeh CW, Chen HT, Chiang IP, Fong YC*
- 2312** Changes in sleep parameters following biomimetic oral appliance therapy: A case report  
*Singh GD, Kherani S*
- 2320** Bone remodeling in sigmoid sinus diverticulum after stenting for transverse sinus stenosis in pulsatile tinnitus: A case report  
*Qiu XY, Zhao PF, Ding HY, Li XS, Lv H, Yang ZH, Gong SS, Jin L, Wang ZC*
- 2326** Prolonged use of bedaquiline in two patients with pulmonary extensively drug-resistant tuberculosis: Two case reports  
*Gao JT, Xie L, Ma LP, Shu W, Zhang LJ, Ning YJ, Xie SH, Liu YH, Gao MQ*
- 2334** Low-grade mucinous appendiceal neoplasm mimicking an ovarian lesion: A case report and review of literature  
*Borges AL, Reis-de-Carvalho C, Chorão M, Pereira H, Djokovic D*
- 2344** Granulomatosis with polyangiitis presenting as high fever with diffuse alveolar hemorrhage and otitis media: A case report  
*Li XJ, Yang L, Yan XF, Zhan CT, Liu JH*
- 2352** Primary intramedullary melanoma of lumbar spinal cord: A case report  
*Sun LD, Chu X, Xu L, Fan XZ, Qian Y, Zuo DM*
- 2357** Proliferative glomerulonephritis with monoclonal immunoglobulin G deposits in a young woman: A case report  
*Xu ZG, Li WL, Wang X, Zhang SY, Zhang YW, Wei X, Li CD, Zeng P, Luan SD*

- 2367** *Nocardia cyriacigeorgica* infection in a patient with pulmonary sequestration: A case report  
*Lin J, Wu XM, Peng MF*
- 2373** Long-term control of melanoma brain metastases with co-occurring intracranial infection and involuntary drug reduction during COVID-19 pandemic: A case report  
*Wang Y, Lian B, Cui CL*
- 2380** Solitary bone plasmacytoma of the upper cervical spine: A case report  
*Li RJ, Li XF, Jiang WM*
- 2386** Two-stage transcrestal sinus floor elevation-insight into replantation: Six case reports  
*Lin ZZ, Xu DQ, Ye ZY, Wang GG, Ding X*
- 2394** Programmed cell death protein-1 inhibitor combined with chimeric antigen receptor T cells in the treatment of relapsed refractory non-Hodgkin lymphoma: A case report  
*Niu ZY, Sun L, Wen SP, Song ZR, Xing L, Wang Y, Li JQ, Zhang XJ, Wang FX*
- 2400** Pancreatic cancer secondary to intraductal papillary mucinous neoplasm with collision between gastric cancer and B-cell lymphoma: A case report  
*Ma YH, Yamaguchi T, Yasumura T, Kuno T, Kobayashi S, Yoshida T, Ishida T, Ishida Y, Takaoka S, Fan JL, Enomoto N*
- 2409** Acquired haemophilia in patients with malignant disease: A case report  
*Krašek V, Kotnik A, Zavrtanik H, Klen J, Zver S*



**ABOUT COVER**

Editorial Board Member of *World Journal of Clinical Cases*, Deb Sanjay Nag, Senior Consultant, Department of Anaesthesiology, Tata Main Hospital, C-Road (West), Bistupur, Jamshedpur 831 001, India. ds.nag@tatasteel.com

**AIMS AND SCOPE**

The primary aim of *World Journal of Clinical Cases* (WJCC, *World J Clin Cases*) is to provide scholars and readers from various fields of clinical medicine with a platform to publish high-quality clinical research articles and communicate their research findings online.

WJCC mainly publishes articles reporting research results and findings obtained in the field of clinical medicine and covering a wide range of topics, including case control studies, retrospective cohort studies, retrospective studies, clinical trials studies, observational studies, prospective studies, randomized controlled trials, randomized clinical trials, systematic reviews, meta-analysis, and case reports.

**INDEXING/ABSTRACTING**

The WJCC is now indexed in Science Citation Index Expanded (also known as SciSearch®), Journal Citation Reports/Science Edition, Scopus, PubMed, and PubMed Central. The 2020 Edition of Journal Citation Reports® cites the 2019 impact factor (IF) for WJCC as 1.013; IF without journal self cites: 0.991; Ranking: 120 among 165 journals in medicine, general and internal; and Quartile category: Q3. The WJCC's CiteScore for 2019 is 0.3 and Scopus CiteScore rank 2019: General Medicine is 394/529.

**RESPONSIBLE EDITORS FOR THIS ISSUE**

**Production Editor:** Yan-Xia Xing; **Production Department Director:** Yun-Xiaoqian Wu; **Editorial Office Director:** Jin-Li Wang.

**NAME OF JOURNAL**

*World Journal of Clinical Cases*

**ISSN**

ISSN 2307-8960 (online)

**LAUNCH DATE**

April 16, 2013

**FREQUENCY**

Thrice Monthly

**EDITORS-IN-CHIEF**

Dennis A Bloomfield, Sandro Vento, Bao-Gan Peng

**EDITORIAL BOARD MEMBERS**

<https://www.wjgnet.com/2307-8960/editorialboard.htm>

**PUBLICATION DATE**

April 6, 2021

**COPYRIGHT**

© 2021 Baishideng Publishing Group Inc

**INSTRUCTIONS TO AUTHORS**

<https://www.wjgnet.com/bpg/gerinfo/204>

**GUIDELINES FOR ETHICS DOCUMENTS**

<https://www.wjgnet.com/bpg/GerInfo/287>

**GUIDELINES FOR NON-NATIVE SPEAKERS OF ENGLISH**

<https://www.wjgnet.com/bpg/gerinfo/240>

**PUBLICATION ETHICS**

<https://www.wjgnet.com/bpg/GerInfo/288>

**PUBLICATION MISCONDUCT**

<https://www.wjgnet.com/bpg/gerinfo/208>

**ARTICLE PROCESSING CHARGE**

<https://www.wjgnet.com/bpg/gerinfo/242>

**STEPS FOR SUBMITTING MANUSCRIPTS**

<https://www.wjgnet.com/bpg/GerInfo/239>

**ONLINE SUBMISSION**

<https://www.f6publishing.com>



## *Nocardia cyriacigeorgica* infection in a patient with pulmonary sequestration: A case report

Jian Lin, Xiao-Mai Wu, Min-Fei Peng

**ORCID number:** Jian Lin 0000-0003-2510-9064; Xiao-Mai Wu 0000-0002-3115-3988; Min-Fei Peng 0000-0002-5446-2986.

**Author contributions:** Peng MF and Lin J designed this case report; Lin J and Wu XM wrote the manuscript.

**Informed consent statement:** The patient provided informed written consent.

**Conflict-of-interest statement:** The authors declare that they have no conflicts of interest.

**CARE Checklist (2016) statement:** The authors have read the CARE Checklist (2016), and the manuscript was prepared and revised according to the CARE Checklist (2016).

**Open-Access:** This article is an open-access article that was selected by an in-house editor and fully peer-reviewed by external reviewers. It is distributed in accordance with the Creative Commons Attribution NonCommercial (CC BY-NC 4.0) license, which permits others to distribute, remix, adapt, build upon this work non-commercially, and license their derivative works on different terms, provided the original work is properly cited and the use is non-commercial. See: <http://creativecommons.org/licenses/by-nc/4.0/>

**Jian Lin, Xiao-Mai Wu,** Department of Respiratory and Critical Care Medicine, Taizhou Hospital of Zhejiang Province Affiliated to Wenzhou Medical University, Linhai 317000, Zhejiang Province, China

**Min-Fei Peng,** Department of Clinical Laboratory, Taizhou Hospital of Zhejiang Province Affiliated to Wenzhou Medical University, Linhai 317000, Zhejiang Province, China

**Corresponding author:** Min-Fei Peng, MD, Associate Chief Technician, Department of Clinical Laboratory, Taizhou Hospital of Zhejiang Province Affiliated to Wenzhou Medical University, No. 150 Ximen Road, Linhai 317000, Zhejiang Province, China. [pengmf@enzemed.com](mailto:pengmf@enzemed.com)

### Abstract

#### BACKGROUND

*Nocardia cyriacigeorgica* (*N. cyriacigeorgica*) infection is uncommon in clinical practice. Pulmonary sequestration complicated with *N. cyriacigeorgica* has not been reported in the literature. Here, we present a case of pulmonary sequestration complicated with *N. cyriacigeorgica* infection in an immunocompetent woman.

#### CASE SUMMARY

A 37-year-old woman complaining of a recurrent cough was admitted to our hospital. Pulmonary sequestration in the lower lobe of the left lung was diagnosed by enhanced computed tomography. Bronchoalveolar lavage fluid was then collected, which showed gram positive bacilli with weakly positive modified acid-fast staining. The pathogen was identified as *N. cyriacigeorgica* after bacterial culture and mass spectrometry analysis. The patient was diagnosed with pulmonary sequestration complicated with *N. cyriacigeorgica* infection, and her symptoms quickly improved following anti-infective therapy.

#### CONCLUSION

Nocardiosis is considered to be an opportunistic infection. This is the first report of pulmonary sequestration complicated with *N. cyriacigeorgica* infection in a patient with normal immunity.

**Key Words:** Nocardia; Infection; Pulmonary sequestration; *Nocardia cyriacigeorgica*; Lung; Case report

©The Author(s) 2021. Published by Baishideng Publishing Group Inc. All rights reserved.

[p://creativecommons.org/licenses/by-nc/4.0/](https://creativecommons.org/licenses/by-nc/4.0/)

**Manuscript source:** Unsolicited manuscript

**Specialty type:** Medicine, research and experimental

**Country/Territory of origin:** China

**Peer-review report's scientific quality classification**

Grade A (Excellent): 0

Grade B (Very good): B

Grade C (Good): 0

Grade D (Fair): 0

Grade E (Poor): 0

**Received:** December 1, 2020

**Peer-review started:** December 1, 2020

**First decision:** December 21, 2020

**Revised:** December 23, 2020

**Accepted:** January 26, 2021

**Article in press:** January 26, 2021

**Published online:** April 6, 2021

**P-Reviewer:** Parra-Medina R

**S-Editor:** Zhang L

**L-Editor:** Filipodia

**P-Editor:** Zhang YL



**Core Tip:** *Nocardia cyriacigeorgica* (*N. cyriacigeorgica*) infection is uncommon in clinical practice. There are few reports of *Nocardia* infection in patients with pulmonary sequestration. We report an immunocompetent young woman who was diagnosed with pulmonary sequestration by enhanced computed tomography. Bronchoalveolar lavage was performed for further pathogenic examination, which revealed *N. cyriacigeorgica* infection in the lesion. This is the first case of pulmonary sequestration complicated with *N. cyriacigeorgica* infection reported in the literature.

**Citation:** Lin J, Wu XM, Peng MF. *Nocardia cyriacigeorgica* infection in a patient with pulmonary sequestration: A case report. *World J Clin Cases* 2021; 9(10): 2367-2372

**URL:** <https://www.wjgnet.com/2307-8960/full/v9/i10/2367.htm>

**DOI:** <https://dx.doi.org/10.12998/wjcc.v9.i10.2367>

## INTRODUCTION

*Nocardia* is an opportunistic pathogen, which is frequently seen in immunosuppressed individuals<sup>[1-3]</sup>. More than 50 *Nocardia* species have been identified<sup>[1,4]</sup>, including *Nocardia asteroides*, *Nocardia brasiliensis*, *Nocardia farcinica*, and *Nocardia otitidiscaviarum*, which are the main species causing disease in humans, and *Nocardia cyriacigeorgica* (*N. cyriacigeorgica*) is a relatively rare pathogen<sup>[5]</sup>. *N. cyriacigeorgica* infection has been reported in organ transplant recipients, long-term glucocorticoid users, and patients with several chronic pulmonary diseases<sup>[2,5-8]</sup>. There are few reports of *Nocardia* infection in patients with pulmonary sequestration. Here, we report a case of pulmonary sequestration complicated with *N. cyriacigeorgica* infection diagnosed in our hospital.

## CASE PRESENTATION

### Chief complaints

A 37-year-old woman was admitted to our hospital on September 15, 2020 due to recurrent cough for more than 10 mo.

### History of present illness

The patient developed a paroxysmal cough accompanied by a small amount of white sputum 10 mo ago. She had no chills, fever, chest pain, hemoptysis, or shortness of breath. She received symptomatic treatment such as anti-infection at a local hospital but her symptoms persisted during this period. The above symptoms recurred 1 mo ago with a little yellow sputum. Fever and hemoptysis were absent. The patient was admitted to our hospital for further treatment.

### Physical examination

The patient was thin and weighed only 40 kg (Body mass index: 15.6). Her temperature was 37.4 °C, pulse rate was 99 bpm, respiratory rate was 19 breaths/min, and blood pressure was 100/63 mmHg. No clubbing of fingers, icterus, or generalized lymphadenopathy were observed. Clinical examinations of the cardiovascular, gastrointestinal, and nervous systems were normal, but crackles were found in the lower lobe of the left lung during lung auscultation.

### Laboratory examinations

Laboratory studies showed normal white blood cells ( $8.6 \times 10^9/L$ ), and the neutrophil ratio was 83.0%. Erythrocyte sedimentation rate was 26 mm/h (normal value < 15 mm/h), and high-sensitivity C-reactive protein was 8.2 mg/L (normal value < 8.0 mg/L). Arterial partial pressure of oxygen was 91 mmHg (partial pressure of oxygen/fraction of inspiration  $O_2$  433.3 mmHg), and arterial partial pressure of carbon dioxide was 41 mmHg. The 1,3- $\beta$ -D-glucan test and galactomannan test were both negative.

### Imaging examinations

Enhanced computed tomography images revealed a honeycomb lesion in the lower lobe of the left lung, and an enhanced vascular shadow was seen in the descending aorta, which was consistent with pulmonary sequestration (Figure 1).

### Further diagnostic work-up

We also performed bronchoscopic alveolar lavage in the posterior basal segment of the left lower lobe. Gram-positive bacilli were detected in the bronchoalveolar lavage fluid (BALF) (Figure 2). The modified acid-fast staining of BALF was weakly positive, and the possible presence of *Nocardia* species was considered. Following culture of BALF, *N. cyriacigeorgica* was identified (Figure 3), which was confirmed by matrix-assisted laser desorption/ionization-time of flight mass spectrometry (matrix-assisted laser desorption/ionization-time of flight; VITEK MS, bioMérieux, Craponne, France) (Supplementary Figure 1).

---

## FINAL DIAGNOSIS

The patient was diagnosed with pulmonary sequestration in the lower lobe of the left lung complicated by *N. cyriacigeorgica* infection.

---

## TREATMENT

She was started on treatment with trimethoprim-sulfamethoxazole (TMP-SMX) (4.32 g/d) and amikacin (0.4 g/d).

---

## OUTCOME AND FOLLOW-UP

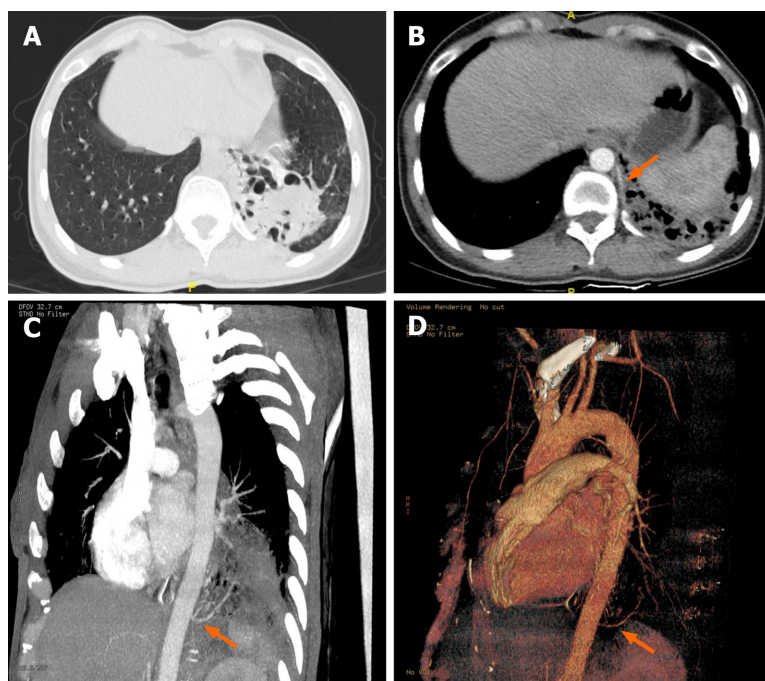
Her symptoms gradually improved, and she was discharged on September 25, 2020.

---

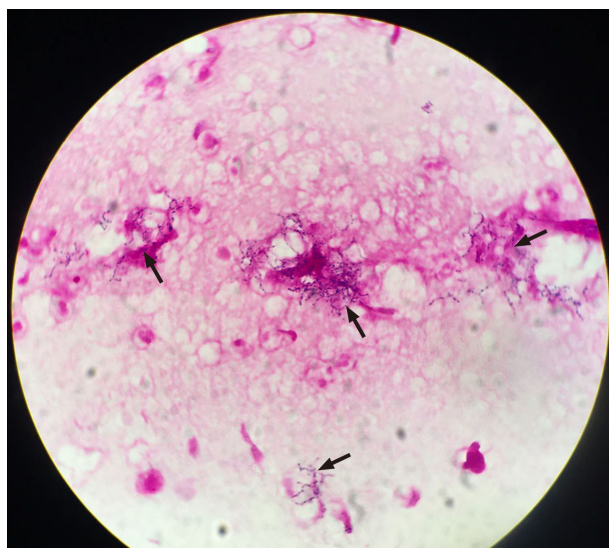
## DISCUSSION

*Nocardia* is an aerobic, gram-positive, and modified acid-fast stain-positive bacillus that belongs in Actinomycetes. It is widely found in natural environments and frequently causes opportunistic infections in patients with impaired immunity, but one-third of infections can also be seen in patients with normal immunity<sup>[1]</sup>. *N. cyriacigeorgica*, an uncommon type of *Nocardia*, was first described in 2001, and was subsequently reported in Europe, Asia, and North America<sup>[9]</sup>. Microscopic examination revealed typical bacilli, and positive modified acid-fast staining was helpful for the diagnosis. The identification of *Nocardia* species by mass spectrometry after bacterial culture is the “gold standard” for determining different subtypes of *Nocardia*<sup>[8,10]</sup>. Sputum is the most commonly used respiratory tract specimen for *Nocardia* isolation<sup>[2,3,8,10]</sup>, and BALF or fine needle aspiration biopsy is sometimes used as an invasive method to obtain specimens<sup>[3]</sup>. BALF has the advantages of simple operation and collection, the specimens are relatively less contaminated, and the results are relatively reliable. Percutaneous lung puncture biopsy is generally not the first choice for the risk of pneumothorax or bleeding. In our case, *Nocardia* was initially suspected when gram-positive bacilli were found in BALF smears. The pathogen was identified as *N. cyriacigeorgica* after bacterial culture and mass spectrometry analysis. Thus, the clinical evidence was conclusive.

*Nocardia* infection usually occurs due to exogenous inhalation or direct invasion through injured skin; therefore, the lungs and skin are the most common organs involved. Disseminated nocardiosis is frequently seen in immunocompromised patients<sup>[1,11]</sup>, and mortality is high when the brain is involved<sup>[3]</sup>. In patients without cellular immune deficiency, the use of systemic glucocorticoids in chronic obstructive pulmonary disease is considered to cause pulmonary nocardiosis<sup>[1]</sup>. In addition to chronic obstructive pulmonary disease, there are reports in the literature that patients with structural lung diseases such as bronchiectasis, allergic bronchopulmonary aspergillosis, and nontuberculous mycobacterial pulmonary disease can also be complicated with *N. cyriacigeorgica* infection<sup>[2,8,12]</sup>. Pulmonary sequestration is a rare



**Figure 1 Computed tomography images.** A: High-resolution computed tomography revealed bronchiectasis with honeycomb changes in the lower lobe of the left lung; B: Enhanced scan displayed a vessel from the descending aorta entering the lesion (orange arrow); C: Maximum intensity projection image showed an independent blood vessel originate from the descending aorta (orange arrow); D: Volume rendering image confirmed that the lesions were supplied by an independent vessel (orange arrow).

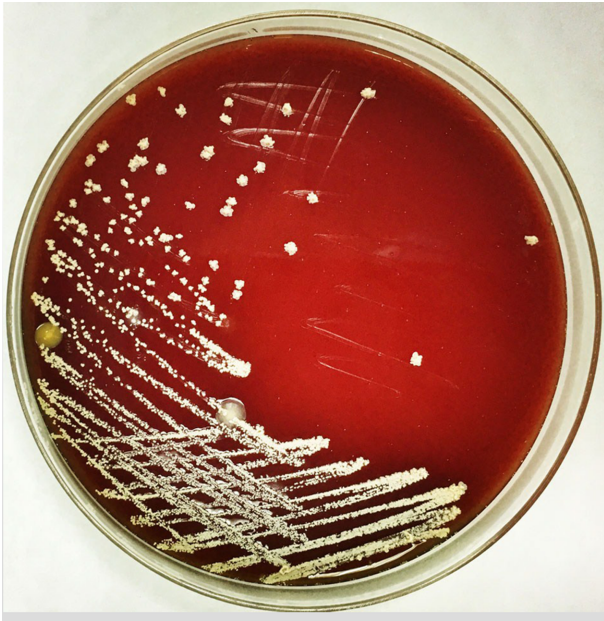

**Figure 2 Bronchoalveolar lavage fluid examination.** Gram-positive bacilli (black arrow) were found in bronchoalveolar lavage fluid (magnification × 1000).

congenital pulmonary malformation where part of the lung tissue is directly supplied by the systemic circulation, which forms a cystic mass<sup>[13]</sup>. This part of the lung tissue is prone to recurrent localized infections<sup>[14]</sup>. Therefore, pulmonary sequestration is also a “special” structural lung disease. Kilpatrick *et al*<sup>[15]</sup> reported the first case of pulmonary sequestration complicated with *Nocardia* infection in 1976, but it was impossible to distinguish *N. brasiliensis* from *N. asteroides* due to technical limitations at that time. Shibli *et al*<sup>[16]</sup> and colleagues reported another case with *N. asteroides* infection and pulmonary sequestration in 2002. Foucrier *et al*<sup>[17]</sup> reported the imaging findings of another case of pulmonary sequestration with *Nocardia* infection (the article did not mention the type of *Nocardia* species). This is the first report of pulmonary sequestration complicated with *N. cyriacigeorgica* infection in a young immunocompetent woman.

Nocardiosis involves chronic suppurative inflammation, and TMP-SMX is the first





**Figure 3 Culture of *Nocardia cyriacigeorgica*.** Colonies of *Nocardia cyriacigeorgica* grew on blood agar plates.

choice for treatment. Critically ill patients often require combination therapy. The drugs that can be combined include aminoglycosides, carbapenems, quinolones, *etc.*, and the course of treatment usually lasts more than 6 mo. Patients with central nervous system involvement may need a longer course of treatment<sup>[1]</sup>. The clinical symptoms in our patient were relatively mild and improved after treatment with TMP-SMX combined with amikacin. Pulmonary sequestration itself was considered to have surgical indications after thoracic surgery consultation. However, the patient was recommended to choose the timing of surgery after adequate anti-infective treatment due to the presence of *N. cyriacigeorgica* infection.

## CONCLUSION

In summary, we report a case of pulmonary sequestration complicated by with *N. cyriacigeorgica* infection in an immunocompetent female patient. The pathogen was confirmed by BALF examination. In addition to common bacteria, rare pathogens such as *Nocardia* should be considered in patients with pulmonary sequestration.

## REFERENCES

- 1 **Wilson JW.** Nocardiosis: updates and clinical overview. *Mayo Clin Proc* 2012; **87**: 403-407 [PMID: 22469352 DOI: 10.1016/j.mayocp.2011.11.016]
- 2 **Yagi K,** Ishii M, Namkoong H, Asami T, Fujiwara H, Nishimura T, Saito F, Kimizuka Y, Asakura T, Suzuki S, Kamo T, Tasaka S, Gonoi T, Kamei K, Betsuyaku T, Hasegawa N. Pulmonary nocardiosis caused by *Nocardia cyriacigeorgica* in patients with Mycobacterium avium complex lung disease: two case reports. *BMC Infect Dis* 2014; **14**: 684 [PMID: 25491030 DOI: 10.1186/s12879-014-0684-z]
- 3 **Chen J,** Zhou H, Xu P, Zhang P, Ma S, Zhou J. Clinical and radiographic characteristics of pulmonary nocardiosis: clues to earlier diagnosis. *PLoS One* 2014; **9**: e90724 [PMID: 24594890 DOI: 10.1371/journal.pone.0090724]
- 4 **Schlaberg R,** Huard RC, Della-Latta P. *Nocardia cyriacigeorgica*, an emerging pathogen in the United States. *J Clin Microbiol* 2008; **46**: 265-273 [PMID: 18003809 DOI: 10.1128/JCM.00937-07]
- 5 **Benek HB,** Akcay E, Yilmaz H, Yis R, Yurt A. *Nocardia cyriacigeorgica* brain abscess with Pempfigus vulgaris: first report. *Br J Neurosurg* 2020; 1-2 [PMID: 31996031 DOI: 10.1080/02688697.2020.1716943]
- 6 **Freiberg JA,** Saharia KK, Morales MK. An unusual case of *Nocardia cyriacigeorgica* presenting with spinal abscesses in a renal transplant recipient and a review of the literature. *Transpl Infect Dis* 2019; **21**: e13025 [PMID: 30414295 DOI: 10.1111/tid.13025]
- 7 **Akcaglar S,** Yilmaz E, Heper Y, Alver O, Akalin H, Ener B, Tore O, Ersoy C, Imamoglu S. *Nocardia cyriacigeorgica*: pulmonary infection in a patient with Basedow-Graves disease and a short review of

- reported cases. *Int J Infect Dis* 2008; **12**: 335-338 [PMID: [18023385](#) DOI: [10.1016/j.ijid.2007.06.014](#)]
- 8 **Wu J**, Wu Y, Zhu Z. Pulmonary infection caused by *Nocardia cyriacigeorgica* in a patient with allergic bronchopulmonary aspergillosis: A case report. *Medicine (Baltimore)* 2018; **97**: e13023 [PMID: [30412142](#) DOI: [10.1097/MD.00000000000013023](#)]
- 9 **Yassin AF**, Rainey FA, Steiner U. *Nocardia cyriacigeorgica* sp. nov.. *Int J Syst Evol Microbiol* 2001; **51**: 1419-1423 [PMID: [11491341](#) DOI: [10.1099/00207713-51-4-1419](#)]
- 10 **Liu C**, Feng M, Zhu J, Tao Y, Kang M, Chen L. Severe pneumonia due to *Nocardia otitidiscaviarum* identified by mass spectroscopy in a cotton farmer: A case report and literature review. *Medicine (Baltimore)* 2017; **96**: e6526 [PMID: [28353613](#) DOI: [10.1097/MD.00000000000006526](#)]
- 11 **Martínez R**, Reyes S, Menéndez R. Pulmonary nocardiosis: risk factors, clinical features, diagnosis and prognosis. *Curr Opin Pulm Med* 2008; **14**: 219-227 [PMID: [18427245](#) DOI: [10.1097/MCP.0b013e3282f85dd3](#)]
- 12 **Ercibengoa M**, Càmarà J, Tubau F, García-Somoza D, Galar A, Martín-Rabadán P, Marin M, Mateu L, García-Olivé I, Prat C, Cilloniz C, Torres A, Pedro-Botet ML, Ardanuy C, Muñoz P, Marimón JM. A multicentre analysis of *Nocardia* pneumonia in Spain: 2010-2016. *Int J Infect Dis* 2020; **90**: 161-166 [PMID: [31693939](#) DOI: [10.1016/j.ijid.2019.10.032](#)]
- 13 **Chaves JJ**, Nieto FP, Gómez-Gómez M, Rodríguez DF, García-Concha D, Parra-Medina R. Pulmonary Sequestration Associated with Actinomycosis: A Case Report. *Antibiotics (Basel)* 2020; **9** [PMID: [33050328](#) DOI: [10.3390/antibiotics9100687](#)]
- 14 **Elia S**, Alifano M, Gentile M, Somma P, D'Armiento FP, Ferrante G. Infection with *Mycobacterium tuberculosis* complicating a pulmonary sequestration. *Ann Thorac Surg* 1998; **66**: 566-567 [PMID: [9725412](#) DOI: [10.1016/s0003-4975\(98\)00476-7](#)]
- 15 **Kilpatrick GR Jr**, Koontz CH, Nelson RA. *Nocardia* infection in a bronchopulmonary sequestration. *Chest* 1976; **69**: 786-788 [PMID: [1277901](#) DOI: [10.1378/chest.69.6.786](#)]
- 16 **Shibli M**, Connery C, Shapiro JM. Intralobar and extralobar bronchopulmonary sequestration complicated by *Nocardia asteroides* infection. *South Med J* 2003; **96**: 78-80 [PMID: [12602723](#) DOI: [10.1097/01.SMJ.0000048224.73476.EC](#)]
- 17 **Foucrier A**, Woerther PL, Le Dorze M, Ruimy R, Laissy JP, Castier Y, Mourvillier B. Pulmonary sequestration syndrome diagnosed from a *Nocardia* infection. *Am J Respir Crit Care Med* 2012; **186**: 288 [PMID: [22855542](#) DOI: [10.1164/rccm.201112-2111IM](#)]



Published by **Baishideng Publishing Group Inc**  
7041 Koll Center Parkway, Suite 160, Pleasanton, CA 94566, USA

**Telephone:** +1-925-3991568

**E-mail:** [bpgoffice@wjgnet.com](mailto:bpgoffice@wjgnet.com)

**Help Desk:** <https://www.f6publishing.com/helpdesk>

<https://www.wjgnet.com>

