


World Journal of *Clinical Cases*

World J Clin Cases 2021 April 16; 9(11): 2419-2695



MINIREVIEWS

- 2419 Current status of radical laparoscopy for treating hepatocellular carcinoma with portal hypertension
Shen ZF, Liang X

ORIGINAL ARTICLE**Retrospective Cohort Study**

- 2433 Impact of type 2 diabetes on adenoma detection in screening colonoscopies performed in disparate populations
Joseph DF, Li E, Stanley III SL, Zhu YC, Li XN, Yang J, Ottaviano LF, Bucobo JC, Buscaglia JM, Miller JD, Veluvolu R, Follen M, Grossman EB

- 2446 Early colonoscopy and urgent contrast enhanced computed tomography for colonic diverticular bleeding reduces risk of rebleeding
Ochi M, Kamoshida T, Hamano Y, Ohkawara A, Ohkawara H, Kakinoki N, Yamaguchi Y, Hirai S, Yanaka A

Retrospective Study

- 2458 Relationship between mismatch repair protein, *RAS*, *BRAF*, *PIK3CA* gene expression and clinicopathological characteristics in elderly colorectal cancer patients
Fan JZ, Wang GF, Cheng XB, Dong ZH, Chen X, Deng YJ, Song X

Clinical Trials Study

- 2469 Possible effect of blonanserin on gambling disorder: A clinical study protocol and a case report
Shiina A, Hasegawa T, Iyo M

Observational Study

- 2478 Parents' experience of caring for children with type 1 diabetes in mainland China: A qualitative study
Tong HJ, Qiu F, Fan L
- 2487 Differences in dietary habits of people with vs without irritable bowel syndrome and their association with symptom and psychological status: A pilot study
Meng Q, Qin G, Yao SK, Fan GH, Dong F, Tan C

SCIENTOMETRICS

- 2503 Prognostic nomograms for predicting overall survival and cause-specific survival of signet ring cell carcinoma in colorectal cancer patients
Kou FR, Zhang YZ, Xu WR

CASE REPORT

- 2519** Cerebellar artery infarction with sudden hearing loss and vertigo as initial symptoms: A case report
Wang XL, Sun M, Wang XP
- 2524** Three-dimensional-printed custom-made patellar endoprosthesis for recurrent giant cell tumor of the patella: A case report and review of the literature
Wang J, Zhou Y, Wang YT, Min L, Zhang YQ, Lu MX, Tang F, Luo Y, Zhang YH, Zhang XL, Tu CQ
- 2533** Gastrointestinal-type chemotherapy prolongs survival in an atypical primary ovarian mucinous carcinoma: A case report
Wang Q, Niu XY, Feng H, Wu J, Gao W, Zhang ZX, Zou YW, Zhang BY, Wang HJ
- 2542** Neoadjuvant chemoradiotherapy followed by laparoscopic distal gastrectomy in advanced gastric cancer: A case report and review of literature
Liu ZN, Wang YK, Li ZY
- 2555** Extraosseous spinal epidural plasmocytoma associated with multiple myeloma: Two case reports
Cui JF, Sun LL, Liu H, Gao CP
- 2562** Endoscopic diagnosis of early-stage primary esophageal small cell carcinoma: Report of two cases
Er LM, Ding Y, Sun XF, Ma WQ, Yuan L, Zheng XL, An NN, Wu ML
- 2569** Nemaline myopathy with dilated cardiomyopathy and severe heart failure: A case report
Wang Q, Hu F
- 2576** Immunoglobulin D- λ/λ biclonal multiple myeloma: A case report
He QL, Meng SS, Yang JN, Wang HC, Li YM, Li YX, Lin XH
- 2584** Point-of-care ultrasound for the early diagnosis of emphysematous pyelonephritis: A case report and literature review
Xing ZX, Yang H, Zhang W, Wang Y, Wang CS, Chen T, Chen HJ
- 2595** Minimally invasive treatment of forearm double fracture in adult using Acumed forearm intramedullary nail: A case report
Liu JC, Huang BZ, Ding J, Mu XJ, Li YL, Piao CD
- 2602** *Klebsiella pneumoniae* infection secondary to spontaneous renal rupture that presents only as fever: A case report
Zhang CG, Duan M, Zhang XY, Wang Y, Wu S, Feng LL, Song LL, Chen XY
- 2611** Eltrombopag-related renal vein thromboembolism in a patient with immune thrombocytopenia: A case report
Wu C, Zhou XM, Liu XD
- 2619** *Cryptococcus* infection with asymptomatic diffuse pulmonary disease in an immunocompetent patient: A case report
Li Y, Fang L, Chang FQ, Xu FZ, Zhang YB

- 2627** Triple administration of osimertinib followed by chemotherapy for advanced lung adenocarcinoma: A case report
Hu XY, Fei YC, Zhou WC, Zhu JM, Lv DL
- 2634** Anesthetic management of a child with double outlet right ventricle and severe polycythemia: A case report
Tan LC, Zhang WY, Zuo YD, Chen HY, Jiang CL
- 2641** Combined immune checkpoint inhibitors of CTLA4 and PD-1 for hepatic melanoma of unknown primary origin: A case report
Cheng AC, Lin YJ, Chiu SH, Shih YL
- 2649** Cholangiojejunostomy for multiple biliary ducts in living donor liver transplantation: A case report
Xiao F, Sun LY, Wei L, Zeng ZG, Qu W, Liu Y, Zhang HM, Zhu ZJ
- 2655** Surgical therapy for hemangioma of the azygos vein arch under thoracoscopy: A case report
Wang ZX, Yang LL, Xu ZN, Lv PY, Wang Y
- 2662** Calcium pyrophosphate deposition disease of the temporomandibular joint invading the middle cranial fossa: Two case reports
Tang T, Han FG
- 2671** Rare histological subtype of invasive micropapillary carcinoma in the ampulla of Vater: A case report
Noguchi H, Higashi M, Idichi T, Kurahara H, Mataka Y, Tasaki T, Kitazono I, Ohtsuka T, Tanimoto A
- 2679** Contrast-enhanced ultrasound using SonoVue mixed with oral gastrointestinal contrast agent to evaluate esophageal hiatal hernia: Report of three cases and a literature review
Wang JY, Luo Y, Wang WY, Zheng SC, He L, Xie CY, Peng L
- 2688** Melatonin for an obese child with MC4R gene variant showing epilepsy and disordered sleep: A case report
Ge WR, Wan L, Yang G

ABOUT COVER

Editorial Board Member of *World Journal of Clinical Cases*, Hong-Tao Xu, MD, PhD, Chief Physician, Professor, Department of Pathology, The First Affiliated Hospital and College of Basic Medical Sciences of China Medical University, Shenyang 110001, Liaoning Province, China. xuht@cmu.edu.cn

AIMS AND SCOPE

The primary aim of *World Journal of Clinical Cases* (WJCC, *World J Clin Cases*) is to provide scholars and readers from various fields of clinical medicine with a platform to publish high-quality clinical research articles and communicate their research findings online.

WJCC mainly publishes articles reporting research results and findings obtained in the field of clinical medicine and covering a wide range of topics, including case control studies, retrospective cohort studies, retrospective studies, clinical trials studies, observational studies, prospective studies, randomized controlled trials, randomized clinical trials, systematic reviews, meta-analysis, and case reports.

INDEXING/ABSTRACTING

The WJCC is now indexed in Science Citation Index Expanded (also known as SciSearch®), Journal Citation Reports/Science Edition, Scopus, PubMed, and PubMed Central. The 2020 Edition of Journal Citation Reports® cites the 2019 impact factor (IF) for WJCC as 1.013; IF without journal self cites: 0.991; Ranking: 120 among 165 journals in medicine, general and internal; and Quartile category: Q3. The WJCC's CiteScore for 2019 is 0.3 and Scopus CiteScore rank 2019: General Medicine is 394/529.

RESPONSIBLE EDITORS FOR THIS ISSUE

Production Editor: Jia-Hui Li; Production Department Director: Yun-Jie Ma; Editorial Office Director: Jin-Lai Wang.

NAME OF JOURNAL

World Journal of Clinical Cases

ISSN

ISSN 2307-8960 (online)

LAUNCH DATE

April 16, 2013

FREQUENCY

Thrice Monthly

EDITORS-IN-CHIEF

Dennis A Bloomfield, Sandro Vento, Bao-Gan Peng

EDITORIAL BOARD MEMBERS

<https://www.wjnet.com/2307-8960/editorialboard.htm>

PUBLICATION DATE

April 16, 2021

COPYRIGHT

© 2021 Baishideng Publishing Group Inc

INSTRUCTIONS TO AUTHORS

<https://www.wjnet.com/bpg/gerinfo/204>

GUIDELINES FOR ETHICS DOCUMENTS

<https://www.wjnet.com/bpg/GerInfo/287>

GUIDELINES FOR NON-NATIVE SPEAKERS OF ENGLISH

<https://www.wjnet.com/bpg/gerinfo/240>

PUBLICATION ETHICS

<https://www.wjnet.com/bpg/GerInfo/288>

PUBLICATION MISCONDUCT

<https://www.wjnet.com/bpg/gerinfo/208>

ARTICLE PROCESSING CHARGE

<https://www.wjnet.com/bpg/gerinfo/242>

STEPS FOR SUBMITTING MANUSCRIPTS

<https://www.wjnet.com/bpg/GerInfo/239>

ONLINE SUBMISSION

<https://www.f6publishing.com>

Surgical therapy for hemangioma of the azygos vein arch under thoracoscopy: A case report

Zhen-Xing Wang, Liang-Liang Yang, Zhe-Nan Xu, Pei-Yun Lv, Yue Wang

ORCID number: Zhen-Xing Wang 0000-0002-9395-0341; Liang-Liang Yang 0000-0001-7779-2681; Zhe-Nan Xu 0000-0002-4827-0312; Pei-Yun Lv 0000-0001-7193-7720; Yue Wang 0000-0001-8740-8989.

Author contributions: Wang ZX and Yang LL designed the work and wrote the manuscript; Xu ZN and Lv PY researched the bibliography; Wang Y conceived the idea of publishing the case and supervised and corrected the manuscript.

Supported by Science and Technology Development Plan Project of Jilin Province, China, No. JJKH20201060KJ.

Informed consent statement: Informed written consent was obtained from the patient for publication of this report and any accompanying images.

Conflict-of-interest statement: No potential conflicts of interest relevant to this article are reported.

CARE Checklist (2016) statement: The authors have read the CARE Checklist (2016), and the manuscript was prepared and revised according to the CARE Checklist (2016).

Open-Access: This article is an open-access article that was

Zhen-Xing Wang, Liang-Liang Yang, Zhe-Nan Xu, Pei-Yun Lv, Yue Wang, Department of Thoracic Surgery, China-Japan Union Hospital of Jilin University, Changchun 130033, Jilin Province, China

Corresponding author: Yue Wang, MD, PhD, Chief Physician, Professor, Department of Thoracic Surgery, China-Japan Union Hospital of Jilin University, No. 126 Xiantai Street, Erdao District, Changchun 130033, Jilin Province, China. w_yue@jlu.edu.cn

Abstract

BACKGROUND

Azygos vein aneurysms are extremely rare, and their pathogenesis is not clear. The overwhelming majority of patients have no obvious clinical symptoms and are found to have the disease by physical examination or by chance. There are few reports on the diagnosis of and treatment strategy for this disease. Moreover, the choice of therapeutic schedule and the treatment window are controversial.

CASE SUMMARY

We report a case of azygos vein arch aneurysm in a 53-year-old woman. The patient had symptoms of back pain, chest tightness, and choking. Enhanced chest computed tomography showed a soft-tissue mass in the right posterior mediastinum, which was connected to the superior vena cava. The enhancement degree in the venous phase was the same as that of the superior vena cava. The patient received video-assisted thoracoscopic surgery. After the operation, her back pain disappeared, and her dysphagia and chest tightness were also significantly relieved. The postoperative pathology confirmed hemangioma. The patient was discharged on the seventh day after surgery without any complications.

CONCLUSION

Some patients with hemangioma of the azygos vein arch may experience dysphagia and chest tightness caused by the tumor compressing the esophagus and trachea. Enhanced computed tomography scanning is vital for the diagnosis of azygos vein aneurysms. In addition, despite the difficulty and risk of surgery, thoracoscopic surgery for azygos vein aneurysms is completely feasible.

Key Words: Azygos vein aneurysm; Hemangioma of the azygos vein arch; Mediastinal tumor; Thoracoscopic surgery; Case report

selected by an in-house editor and fully peer-reviewed by external reviewers. It is distributed in accordance with the Creative Commons Attribution NonCommercial (CC BY-NC 4.0) license, which permits others to distribute, remix, adapt, build upon this work non-commercially, and license their derivative works on different terms, provided the original work is properly cited and the use is non-commercial. See: <http://creativecommons.org/licenses/by-nc/4.0/>

Manuscript source: Unsolicited manuscript

Specialty type: Medicine, research and experimental

Country/Territory of origin: China

Peer-review report's scientific quality classification

Grade A (Excellent): 0
Grade B (Very good): B, B
Grade C (Good): 0
Grade D (Fair): 0
Grade E (Poor): 0

Received: December 13, 2020

Peer-review started: December 13, 2020

First decision: December 24, 2020

Revised: January 3, 2021

Accepted: February 22, 2021

Article in press: February 22, 2021

Published online: April 16, 2021

P-Reviewer: Zhu F

S-Editor: Gao CC

L-Editor: Wang TQ

P-Editor: Yuan YY



©The Author(s) 2021. Published by Baishideng Publishing Group Inc. All rights reserved.

Core Tip: Azygos vein aneurysms are extremely rare. We present a patient with hemangioma of the azygos vein arch who experienced dysphagia and chest tightness caused by a tumor compressing the esophagus and trachea. The patient received video-assisted thoracoscopic surgery. We herein report the first case of a patient with choking symptoms due to the esophagus being compressed by an azygos vein aneurysm.

Citation: Wang ZX, Yang LL, Xu ZN, Lv PY, Wang Y. Surgical therapy for hemangioma of the azygos vein arch under thoracoscopy: A case report. *World J Clin Cases* 2021; 9(11): 2655-2661

URL: <https://www.wjgnet.com/2307-8960/full/v9/i11/2655.htm>

DOI: <https://dx.doi.org/10.12998/wjcc.v9.i11.2655>

INTRODUCTION

Azygos vein aneurysms are extremely rare. There are few cases of the diagnosis and therapy of this disease in the medical literature. We report a case of hemangioma of the azygos vein arch in a 53-year-old woman. The patient had symptoms of back pain, chest tightness, and choking. To the best of our knowledge, this is the first case of a patient with choking symptoms due to compression of the esophagus by an azygos vein aneurysm. The enhanced chest computed tomography (CT) showed a soft-tissue mass in the right posterior mediastinum, which was connected to the superior vena cava. The enhancement degree in the venous phase was the same as that of the superior vena cava. The patient received video-assisted thoracoscopic surgery. After the operation, her back pain disappeared, and her dysphagia and chest tightness were also significantly relieved. The postoperative pathology confirmed hemangioma. The patient was discharged on the seventh day after surgery without any complications. Despite the difficulty and risk of surgery, it is completely feasible for azygos venous arch aneurysms to be repaired by thoracoscopic surgery.

CASE PRESENTATION

Chief complaints

A 53-year-old woman experienced choking, chest tightness, and back pain.

History of present illness

The patient had experienced choking and chest tightness 2 years prior without any causation and had experienced back pain 1 year ago. Recently, the above symptoms had gradually been aggravated. The patient underwent gastroscopy that showed normal findings.

History of past illness

The patient had no other past illness except choking, chest tightness, and back pain.

Personal and family history

The patient had no remarkable personal and family history.

Physical examination

The physical examination was unremarkable.

Laboratory examinations

The patient was previously healthy and showed no abnormalities in the laboratory examinations.

Imaging examinations

CT revealed a soft-tissue mass approximately 4.2 cm × 3.7 cm × 2.6 cm in the right

posterior mediastinum, for which the boundary between some areas and the esophagus was unclear, and the trachea was also compressed (Figure 1A). In the enhanced CT scan, a contrast agent was injected into the right upper limb. In the early arterial stage, the superior vena cava and the azygos vein arch were filled with the contrast agent, and the azygos vein arch was nodular. The density did not decrease in the venous phase, and there seemed to be a blood shadow during coronary reconstruction. The posterior mediastinal tumor showed delayed enhancement, and its internal density was not homogeneous. No definite filling defect was found. The tumor was connected to the superior vena cava, whose degree of enhancement was the same as that of the superior vena cava, and the boundary between the tumor and the esophagus was clear. The azygos vein valve was observed. The esophagus was compressed by an azygos vein aneurysm (Figure 1B). These findings indicated that there was a giant hemangioma originating from the azygos vein arch.

Pathological findings

The tumor was dissected, which revealed enlarged and dilated thin-walled blood vessels with intact endothelial cells on the wall, in which the medial muscle layer was thinned; a large number of red blood cells were found outside the lumen. Multiple red blood cells were observed in the expanded blood vessel wall, composing the mural thrombus. Postoperative pathology confirmed hemangiomas (Figure 2).

MULTIDISCIPLINARY EXPERT CONSULTATION

A multidisciplinary consultation recommended surgical resection.

FINAL DIAGNOSIS

These results led us to a definitive diagnosis of hemangioma (Figure 2).

TREATMENT

The patient received thoracoscopic surgery. During the operation, it was found that the azygos vein arch was enlarged abnormally, showing dark purple cystic changes, and the mass was slightly adherent to the surrounding tissues. The azygos vein arch was ligated with silk thread near the superior vena cava (Figure 3A), and then the distal vessel of the tumor was ligated (Figure 3B). Finally, the tumor was resected completely (Figure 3C and D).

OUTCOME AND FOLLOW-UP

After the operation, the patient's back pain disappeared immediately, and her symptoms of dysphagia and chest tightness were also evidently relieved. The patient recovered well and was discharged on the seventh postoperative day. After careful follow-up for 10 mo, the patient was doing well without any discomfort.

DISCUSSION

Azygos vein aneurysms are rare clinical problems. They can be divided into primary and secondary azygos vein aneurysms. Hitherto, the pathogenesis of primary azygos vein aneurysms has not been clarified. Watanabe *et al*^[1] speculated that the venous wall is congenitally weak or degenerative due to abnormal connective tissue at the anastomotic site between the proximal segment of the posterior main vein and the right superior main vein in the embryonic stage and then progresses to abnormally form azygos vein aneurysms. There are many secondary causes, including pseudo-aneurysms caused by traumatic disruption, infection, portal hypertension, inferior vena cava occlusion, venous valve insufficiency, and local thrombosis^[2-4]. Guo *et al*^[5] reported a case of a giant azygos vein aneurysm caused by resection and embolization of a cavernous hemangioma of the chest wall and back. They believed that the

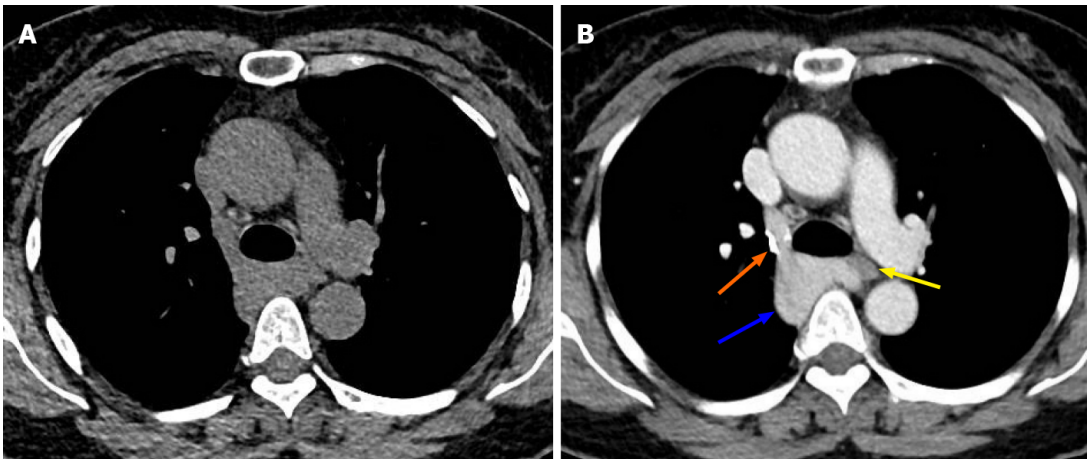


Figure 1 Tumor imaging by chest computed tomography. A: Chest computed tomography showed a soft-tissue mass in the right posterior mediastinum; the mass was approximately 4.2 cm × 3.7 cm × 2.6 cm in size and showed unclear boundaries with the esophagus and compression of the trachea; B: Enhanced scanning showed that the azygos vein arch widened, the contrast agent remained in the azygos vein arch, the tumor exhibited delayed enhancement, and the internal density was uneven (blue arrow). In the venous phase, the tumor was connected to the superior vena cava, and the degree of enhancement was the same as that of the superior vena cava. The boundary between the tumor and the esophagus was clear. Note the azygos vein valve (orange arrow). The esophagus was compressed by the azygos vein aneurysm (yellow arrow).

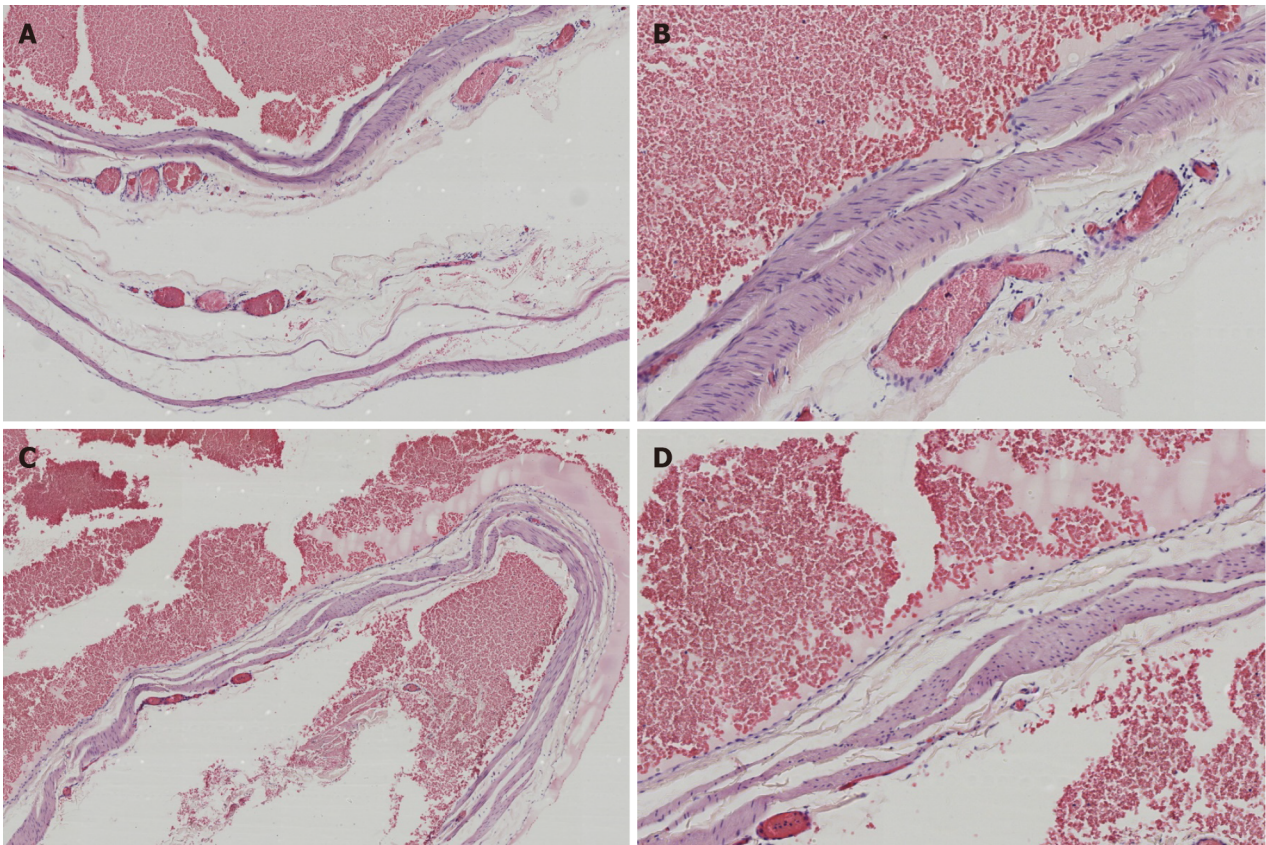


Figure 2 Hematoxylin and eosin staining. A and B: There were enlarged and dilated thin-walled blood vessels with intact endothelial cells on the wall, in which the medial muscle layer was thinned, and a large number of red blood cells were found outside the lumen (A: 40 ×; B: 100 ×); C and D: Multiple red blood cells were observed in the expanded blood vessel wall, composing the mural thrombus (C: 40 ×; D: 100 ×).

pressure and volume load of the azygos vein were increased by surgery, which led to the expansion of the azygos vein.

The overwhelming majority of patients with azygos vein aneurysms have no obvious clinical symptoms and are found to have the disease by physical examination or by chance^[4,6-8]. A few patients have symptoms such as chest pain, choking, and cough^[2,9]. However, our patient developed symptoms of back pain, chest tightness,

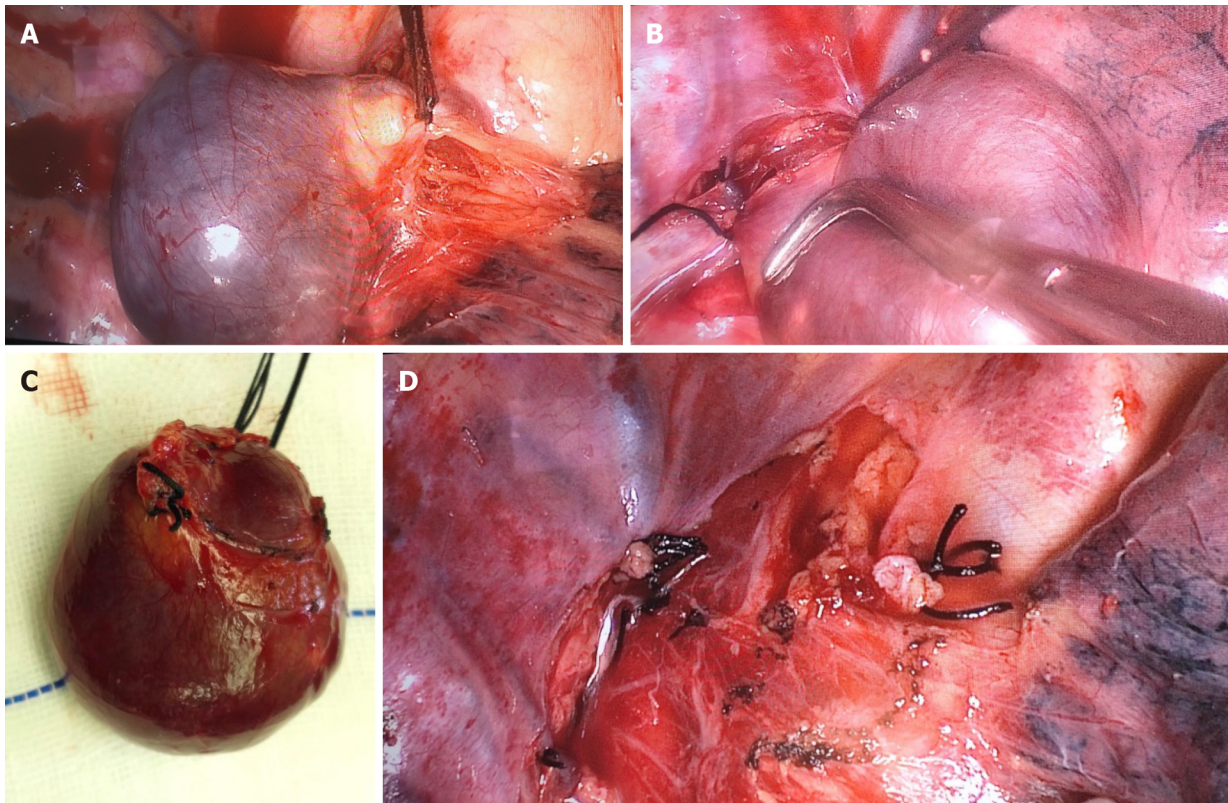


Figure 3 Intraoperative management. A: The azygos vein arch was enlarged and showed dark purple cystic changes. The tumor was slightly adherent to the surrounding tissues. The azygos vein was ligated at the connection of the superior vena cava with silk thread; B: The distal vessel was ligated; C: A complete resection of the azygos vein aneurysm was performed; D: Shown is the intraoperative wound of the right posterior mediastinum.

and choking, probably because the esophagus and trachea were compressed by the azygos vein aneurysm, as shown by chest CT. After surgical resection, the abovementioned symptoms were evidently relieved, which forcefully confirmed our point of view. To the best of our knowledge, no such cases have been described in the literature; we report the first case of a patient with choking symptoms due to esophageal compression by an azygos vein aneurysm.

Azygos vein aneurysms should be differentiated from other mediastinal tumors, such as lymphomas, bronchial cysts, fibromas, and paragangliomas. Valuable examinations include chest CT scanning, enhanced CT scanning, angiography, nuclear magnetic resonance, nuclear magnetic resonance enhancement, *etc.* Some scholars believe that endobronchial ultrasound can show the blood flow of tumors more clearly, which is helpful for a definite diagnosis^[10]. Interestingly, enhanced CT scanning of our patient showed nodular filling of contrast medium into the mediastinum of the azygos vein arch area. First, this was mistaken for lymph node calcification or old thrombus calcification in the azygos vein. After the analysis of CT scanning images by three-dimensional reconstruction, we found that the nodularity was due to the contrast agent flowing back into the azygos vein arch through the superior vena cava, but the contrast agent density did not decrease in the venous phase. This was considered to indicate the residual contrast agent in the azygos vein valve area. Ichikawa *et al*^[11] reported that when a contrast agent was injected at high speed during enhanced CT scanning, the phenomenon of reflux of contrast medium from the superior vena cava to the azygos vein arch may sometimes be observed, resulting in residual contrast agent in the azygos vein arch valve. This phenomenon can also occur in the normal population, and it is more likely to occur when the contrast agent is injected into the right upper limb. In summary, the right posterior mediastinal tumor should be identified carefully before the operation, and the possibility of an azygos vein aneurysm should be considered to avoid the risk of bleeding caused by puncture biopsy.

It is generally believed that azygos vein aneurysms do not require special treatment^[2,6], but some scholars believe that tumor rupture with the progression of the disease^[12] and thrombosis may lead to pulmonary embolism^[2,7]. In addition, tumors in this area also pose potential malignant risks. Dasika *et al*^[13] and De Palma *et al*^[14]

reported cases of leiomyosarcoma of the azygos vein and epithelioid hemangio-endothelioma, respectively, and they advocated aggressive surgical therapy. Savu *et al*^[15] reported that in cases of azygos venous aneurysm with complete thrombosis, surgery was recommended and must be performed with extreme care in order to prevent intraoperative embolism. Our patient had symptoms of back pain, chest tightness, and choking. It was believed that the tumor was caused by compression of the esophagus and trachea, so we actively adopted surgical therapy. After the operation, we observed that the blood vessel wall of the tumor became thinner, and mural thrombosis was found inside. We speculate that this may have been due to the formation of vortices in the blood flow through the hemangioma, where the blood flow slowed down, leading to thrombosis, which also confirms Nakamura *et al*^[2]'s point of view. Therefore, we believe that it is necessary for azygos vein aneurysms to be treated by surgical resection.

The wall of the azygos vein aneurysm is weak, and there is a risk of rupture and bleeding during the operation. Traditional thoracotomy or endoscopic-assisted small incisions were adopted previously^[16]. With the progress of endoscopic technology, totally thoracoscopic surgery has also been reported in recent years^[4,6]. Ma and his colleagues^[4] described the performance of thoracoscopic surgery, including avoiding unnecessary manipulation (pinching or pressing) of the masses to prevent bleeding complications. The proximal end of the hemangioma should be treated first to prevent the thrombus from entering the superior vena cava and right atrium and forming pulmonary embolism. We learned from their experience during the operation and achieved good therapeutic effects.

CONCLUSION

In conclusion, a right posterior mediastinal mass should be considered for the possibility of an azygos vein aneurysm. Some patients may experience dysphagia and chest tightness due to esophageal and tracheal compression caused by the tumors. Enhanced CT scanning is vital for the diagnosis of azygos vein aneurysms. In addition, despite the difficulty and risk of the operation, thoracoscopic surgery for azygos vein aneurysms is completely feasible.

ACKNOWLEDGEMENTS

We thank Professor Liu YX and Dr. Zhang LC for their help during the research process.

REFERENCES

- 1 **Watanabe A**, Kusajima K, Aisaka N, Sugawara H, Tsunematsu K. Idiopathic saccular azygos vein aneurysm. *Ann Thorac Surg* 1998; **65**: 1459-1461 [PMID: [9594893](#) DOI: [10.1016/s0003-4975\(98\)00167-2](#)]
- 2 **Nakamura Y**, Nakano K, Nakatani H, Fukuda T, Honda K, Homma N. Surgical exclusion of a thrombosed azygos vein aneurysm causing pulmonary embolism. *J Thorac Cardiovasc Surg* 2007; **133**: 834-835 [PMID: [17320608](#) DOI: [10.1016/j.jtcvs.2006.11.012](#)]
- 3 **Das KM**, Ahmed AM, Aljubab A, Alzoum MA. Multidetector computed tomography evaluation of cavernous haemangioma of the azygous vein. *Interact Cardiovasc Thorac Surg* 2013; **17**: 436-437 [PMID: [23660735](#) DOI: [10.1093/icvts/ivt126](#)]
- 4 **Husai M**, Yixin C, Ni Z, Wenxin W, Xiangning F. Thoracoscopic Resection of a Rare Case of Hemangioma of the Azygos Venous Arch. *Case Rep Surg* 2017; **2017**: 1693912 [PMID: [28367348](#) DOI: [10.1155/2017/1693912](#)]
- 5 **Guo B**, Guo D, Fu W, Shi Z. A giant azygos venous aneurysm caused by the resection of hemangioma. *J Vasc Surg Venous Lymphat Disord* 2014; **2**: 328 [PMID: [26993395](#) DOI: [10.1016/j.jvsv.2014.01.002](#)]
- 6 **Lee DH**, Keum DY, Park CK, Kim JB, Rho BH. Azygos Vein Aneurysm - A Case for Elective Resection by Video-assisted Thoracic Surgery. *Korean J Thorac Cardiovasc Surg* 2011; **44**: 304-306 [PMID: [22263176](#) DOI: [10.5090/kjcs.2011.44.4.304](#)]
- 7 **Choi J**, Song J, Huh J, Kang IS, Yang JH, Jun TG. Complicated Azygos Vein Aneurysm in an Infant Presenting with Acute Pulmonary Thromboembolism. *Korean Circ J* 2016; **46**: 264-267 [PMID: [27014359](#) DOI: [10.4070/kcj.2016.46.2.264](#)]
- 8 **Kreibich M**, Siepe M, Grohmann J, Pache G, Beyersdorf F. Aneurysms of the azygos vein. *J Vasc*

- Surg Venous Lymphat Disord* 2017; **5**: 576-586 [PMID: 28624000 DOI: 10.1016/j.jysv.2016.12.012]
- 9 **Choudhary AK**, Moore M. Radiological features of azygous vein aneurysm. *Del Med J* 2014; **86**: 117-120 [PMID: 25000644]
 - 10 **Yamanaka S**, Sakurada A, Matsumura Y, Endo C, Sato M, Kondo T. A rare case of hemangioma arising from the azygos vein: Informative procedure with endobronchial ultrasonography. *J Thorac Cardiovasc Surg* 2004; **127**: 294-295 [PMID: 14752455 DOI: 10.1016/j.jtcvs.2003.08.025]
 - 11 **Ichikawa T**, Endo J, Koizumi J, Ro A, Kobayashi M, Saito M, Kawada S, Hashimoto T, Imai Y. Visualization of the azygos arch valves on multidetector-row computed tomography. *Heart Vessels* 2008; **23**: 118-123 [PMID: 18389337 DOI: 10.1007/s00380-007-1009-6]
 - 12 **Gomez MA**, Delhommais A, Presicci PF, Besson M, Roger R, Alison D. Partial thrombosis of an idiopathic azygos vein aneurysm. *Br J Radiol* 2004; **77**: 342-343 [PMID: 15107328 DOI: 10.1259/bjr/28611372]
 - 13 **Dasika U**, Shariati N, Brown JM 3rd. Resection of a leiomyosarcoma of the azygos vein. *Ann Thorac Surg* 1998; **66**: 1405 [PMID: 9800844 DOI: 10.1016/s0003-4975(98)00718-8]
 - 14 **De Palma A**, Pagliarulo V, Ardò N, Loizzi D. Surgical treatment of a rare case of epithelioid hemangioendothelioma of the azygos vein. *Interact Cardiovasc Thorac Surg* 2012; **14**: 91-93 [PMID: 22108950 DOI: 10.1093/icvts/ivr064]
 - 15 **Savu C**, Melinte A, Balescu I, Bacalbasa N. Azygos Vein Aneurysm Mimicking a Mediastinal Mass. *In Vivo* 2020; **34**: 2135-2140 [PMID: 32606194 DOI: 10.21873/invivo.12019]
 - 16 **Zhang C**, Luo W, Ma L, Ni Y. Venous hemangioma of the azygos arch. *Eur J Cardiothorac Surg* 2007; **32**: 669-670 [PMID: 17681805 DOI: 10.1016/j.ejcts.2007.06.029]



Published by **Baishideng Publishing Group Inc**
7041 Koll Center Parkway, Suite 160, Pleasanton, CA 94566, USA

Telephone: +1-925-3991568

E-mail: bpgoffice@wjgnet.com

Help Desk: <https://www.f6publishing.com/helpdesk>

<https://www.wjgnet.com>

