

World Journal of *Clinical Cases*

World J Clin Cases 2021 April 26; 9(12): 2696-2950



MINIREVIEWS

- 2696** Standardization of critical care management of non-critically ill patients with COVID-19
Wang CS, Gao Y, Kang K, Fei DS, Meng XL, Liu HT, Luo YP, Yang W, Dai QQ, Gao Y, Zhao MY, Yu KJ
- 2703** Mediastinal lymphadenopathy in COVID-19: A review of literature
Taweasedt PT, Surani S
- 2711** Polycystic ovary syndrome: Pathways and mechanisms for possible increased susceptibility to COVID-19
Ilias I, Goulas S, Zabuliene L

ORIGINAL ARTICLE

Clinical and Translational Research

- 2721** Circulating tumor cells with epithelial-mesenchymal transition markers as potential biomarkers for the diagnosis of lung cancer
Jiang SS, Mao CG, Feng YG, Jiang B, Tao SL, Tan QY, Deng B

Retrospective Study

- 2731** Management and implementation strategies of pre-screening triage in children during coronavirus disease 2019 pandemic in Guangzhou, China
Shi X, Cai YT, Cai X, Wen XL, Wang JY, Ma WC, Shen J, Wu JX, Liu HY, Sun J, He PQ, Lin Y, Zhao DY, Li PQ
- 2739** Clinicopathological features of superficial CD34-positive fibroblastic tumor
Ding L, Xu WJ, Tao XY, Zhang L, Cai ZG
- 2751** Application of a rapid exchange extension catheter technique in type B2/C nonocclusive coronary intervention *via* a transradial approach
Wang HC, Lu W, Gao ZH, Xie YN, Hao J, Liu JM

SYSTEMATIC REVIEWS

- 2763** Paradoxical relationship between proton pump inhibitors and COVID-19: A systematic review and meta-analysis
Zippi M, Fiorino S, Budriesi R, Micucci M, Corazza I, Pica R, de Biase D, Gallo CG, Hong W

META-ANALYSIS

- 2778** Predictive risk factors for recollapse of cemented vertebrae after percutaneous vertebroplasty: A meta-analysis
Ma YH, Tian ZS, Liu HC, Zhang BY, Zhu YH, Meng CY, Liu XJ, Zhu QS

CASE REPORT

- 2791** Malignant pheochromocytoma with cerebral and skull metastasis: A case report and literature review
Chen JC, Zhuang DZ, Luo C, Chen WQ
- 2801** Unresectable esophageal cancer treated with multiple chemotherapies in combination with chemoradiotherapy: A case report
Yura M, Koyanagi K, Hara A, Hayashi K, Tajima Y, Kaneko Y, Fujisaki H, Hirata A, Takano K, Hongo K, Yo K, Yoneyama K, Tamai Y, Dehari R, Nakagawa M
- 2811** Role of positron emission tomography in primary carcinoma ex pleomorphic adenoma of the bronchus: A case report
Yang CH, Liu NT, Huang TW
- 2816** Positive reverse transcription-polymerase chain reaction assay results in patients recovered from COVID-19: Report of two cases
Huang KX, He C, Yang YL, Huang D, Jiang ZX, Li BG, Liu H
- 2823** Laryngeal myxoma: A case report
Yu TT, Yu H, Cui Y, Liu W, Cui XY, Wang X
- 2830** Prostate stromal tumor with prostatic cysts after transurethral resection of the prostate: A case report
Zhao LW, Sun J, Wang YY, Hua RM, Tai SC, Wang K, Fan Y
- 2838** Intramuscular hematoma in rhabdomyolysis patients treated with low-molecular-weight heparin: Report of two cases
Yuan SY, Xie KF, Yang J
- 2845** Partial response to Chinese patent medicine Kangliu pill for adult glioblastoma: A case report and review of the literature
Sun G, Zhuang W, Lin QT, Wang LM, Zhen YH, Xi SY, Lin XL
- 2854** Behcet's disease manifesting as esophageal variceal bleeding: A case report
Xie WX, Jiang HT, Shi GQ, Yang LN, Wang H
- 2862** Successful endoscopic surgery for emphysematous pyelonephritis in a non-diabetic patient with autosomal dominant polycystic kidney disease: A case report
Jiang Y, Lo R, Lu ZQ, Cheng XB, Xiong L, Luo BF
- 2868** Robotically assisted removal of pelvic splenosis fifty-six years after splenectomy: A case report
Tognarelli A, Faggioni L, Erba AP, Faviana P, Durante J, Manassero F, Selli C
- 2874** Pulmonary alveolar proteinosis complicated with nocardiosis: A case report and review of the literature
Wu XK, Lin Q
- 2884** Detection of EGFR-SEPT14 fusion in cell-free DNA of a patient with advanced gastric cancer: A case report
Kim B, Kim Y, Park I, Cho JY, Lee KA

- 2890** Timing of convalescent plasma therapy-tips from curing a 100-year-old COVID-19 patient using convalescent plasma treatment: A case report
Liu B, Ren KK, Wang N, Xu XP, Wu J
- 2899** Torsades de pointes episode in a woman with high-grade fever and inflammatory activation: A case report
Qiu H, Li HW, Zhang SH, Zhou XG, Li WP
- 2908** Salivary duct carcinoma of the submandibular gland presenting a diagnostic challenge: A case report
Uchihashi T, Kodama S, Sugauchi A, Hiraoka S, Hirose K, Usami Y, Tanaka S, Kogo M
- 2916** Allogeneic hematopoietic stem cell transplantation in a 3-year-old boy with congenital pyruvate kinase deficiency: A case report
Ma ZY, Yang X
- 2923** Congenital bilateral cryptorchidism in an infant conceived after maternal breast cancer treatment: A case report
Hu WK, Liu J, Liu RX, Liu XW, Yin CH
- 2930** Sclerosing polycystic adenosis of the submandibular gland: Two case reports
Wu L, Wang Y, Hu CY, Huang CM
- 2937** Budd-Chiari syndrome associated with liver cirrhosis: A case report
Ye QB, Huang QF, Luo YC, Wen YL, Chen ZK, Wei AL
- 2944** Separated root tip formation associated with a fractured tubercle of dens evaginatus: A case report
Wu ZF, Lu LJ, Zheng HY, Tu Y, Shi Y, Zhou ZH, Fang LX, Fu BP

ABOUT COVER

Editorial Board Member of *World Journal of Clinical Cases*, Jing Liu, MD, PhD, Chief Doctor, Professor, Department of Neonatology and NICU, Beijing Chaoyang District Maternal and Child Healthcare Hospital, Beijing 100021, China. liujingbj@live.cn

AIMS AND SCOPE

The primary aim of *World Journal of Clinical Cases* (WJCC, *World J Clin Cases*) is to provide scholars and readers from various fields of clinical medicine with a platform to publish high-quality clinical research articles and communicate their research findings online.

WJCC mainly publishes articles reporting research results and findings obtained in the field of clinical medicine and covering a wide range of topics, including case control studies, retrospective cohort studies, retrospective studies, clinical trials studies, observational studies, prospective studies, randomized controlled trials, randomized clinical trials, systematic reviews, meta-analysis, and case reports.

INDEXING/ABSTRACTING

The WJCC is now indexed in Science Citation Index Expanded (also known as SciSearch®), Journal Citation Reports/Science Edition, Scopus, PubMed, and PubMed Central. The 2020 Edition of Journal Citation Reports® cites the 2019 impact factor (IF) for WJCC as 1.013; IF without journal self cites: 0.991; Ranking: 120 among 165 journals in medicine, general and internal; and Quartile category: Q3. The WJCC's CiteScore for 2019 is 0.3 and Scopus CiteScore rank 2019: General Medicine is 394/529.

RESPONSIBLE EDITORS FOR THIS ISSUE

Production Editor: Ji-Hong Lin; Production Department Director: Xiang Li; Editorial Office Director: Jin-Lai Wang.

NAME OF JOURNAL

World Journal of Clinical Cases

ISSN

ISSN 2307-8960 (online)

LAUNCH DATE

April 16, 2013

FREQUENCY

Thrice Monthly

EDITORS-IN-CHIEF

Dennis A Bloomfield, Sandro Vento, Bao-Gan Peng

EDITORIAL BOARD MEMBERS

<https://www.wjgnet.com/2307-8960/editorialboard.htm>

PUBLICATION DATE

April 26, 2021

COPYRIGHT

© 2021 Baishideng Publishing Group Inc

INSTRUCTIONS TO AUTHORS

<https://www.wjgnet.com/bpg/gerinfo/204>

GUIDELINES FOR ETHICS DOCUMENTS

<https://www.wjgnet.com/bpg/GerInfo/287>

GUIDELINES FOR NON-NATIVE SPEAKERS OF ENGLISH

<https://www.wjgnet.com/bpg/gerinfo/240>

PUBLICATION ETHICS

<https://www.wjgnet.com/bpg/GerInfo/288>

PUBLICATION MISCONDUCT

<https://www.wjgnet.com/bpg/gerinfo/208>

ARTICLE PROCESSING CHARGE

<https://www.wjgnet.com/bpg/gerinfo/242>

STEPS FOR SUBMITTING MANUSCRIPTS

<https://www.wjgnet.com/bpg/GerInfo/239>

ONLINE SUBMISSION

<https://www.f6publishing.com>

Clinical and Translational Research

Circulating tumor cells with epithelial-mesenchymal transition markers as potential biomarkers for the diagnosis of lung cancer

Sha-Sha Jiang, Chun-Guo Mao, Yong-Geng Feng, Bin Jiang, Shao-Lin Tao, Qun-You Tan, Bo Deng

ORCID number: Sha-Sha Jiang 0000-0001-6371-9934; Chun-Guo Mao 0000-0002-3270-530X; Yong-Geng Feng 0000-0001-9562-0453; Bin Jiang 0000-0002-3793-5550; Shao-Lin Tao 0000-0003-2213-7967; Qun-You Tan 0000-0001-9519-4888; Bo Deng 0000-0002-5112-9221.

Author contributions: Jiang SS and Mao CG performed the research and wrote the paper; Feng YG and Jiang B designed the research and supervised the study; Tao SL and Tan QY designed the research and contributed to the analyses; Deng B provided clinical advice and supervised the report.

Supported by National Natural Science Foundation of China, No. 81572285; The Natural Science Foundation of Chongqing City, No. cstc2018jcyjAX0592; and The Army Medical University Clinical Medical Research Talent Training Program, No. 2018XLC3062.

Institutional review board

statement: The study protocol was reviewed and approved by the Ethics Committee of Daping Hospital, Army Medical University 2019, No. 183.

Clinical trial registration statement:

This study is registered at <https://clinicaltrials.gov/>. The registration identification number

Sha-Sha Jiang, Chun-Guo Mao, Yong-Geng Feng, Bin Jiang, Shao-Lin Tao, Qun-You Tan, Bo Deng, Department of Thoracic Surgery, Institute of Surgery Research, Daping Hospital, Army Medical University, Chongqing 400042, China

Corresponding author: Bo Deng, MD, PhD, Professor, Surgeon, Department of Thoracic Surgery, Institute of Surgery Research, Daping Hospital, Army Medical University, No. 10 Changjiang Branch Street, Yuzhong District, Chongqing 400042, China. dengbo@tmmu.edu.cn

Abstract

BACKGROUND

Circulating tumor cells (CTCs) can be clustered into three subtypes according to epithelial-mesenchymal transition (EMT) markers: CTCs with epithelial markers (E-CTCs), CTCs with mesenchymal markers (M-CTCs), and CTCs with both markers (E&M-CTCs). CTC detection has clinical implications in the diagnosis of lung cancer (LC).

AIM

To clarify the diagnostic value of CTCs categorized by EMT markers in LC.

METHODS

The study included 106 patients with lung adenocarcinoma, including 42 ground-glass opacities (GGO) and 64 solid lesions, who underwent surgery between July 2015 and December 2019. Eleven patients with benign tumors and seventeen healthy controls were included. CTCs in peripheral blood and associated EMT markers were detected preoperatively using the CanPatrol™ technique. The diagnostic power of CTCs for discriminating LC cases from controls was analyzed by the receiver operating characteristic (ROC) curve. The CytoploRare technique was used in 20 cases and 18 controls for validation, and Kappa values were calculated to evaluate consistency between techniques.

RESULTS

Of the 106 LC cases, 94 (89.6%) had at least one CTC. CTCs were detectable in 35 (83.3%) of 42 GGO cases. Total CTCs and E&M-CTCs were significantly more frequent in LC cases than in benign or healthy controls. The proportion of M-CTCs plus E&M-CTCs increased gradually from healthy controls, to benign controls, to LC cases. The area under the ROC curve of total CTCs and E&M-CTCs was > 0.8 and > 10.75, respectively. The combined sensitivity of total-CTCs and E&M-CTCs was 85.85% for LC patients (80.95% for GGO patients) and the

is NCT02951897.

Informed consent statement: All patients who agreed to participate in the study signed an informed consent.

Conflict-of-interest statement: The authors declare that they have no financial relationships to disclose.

Data sharing statement: No additional data are available.

Open-Access: This article is an open-access article that was selected by an in-house editor and fully peer-reviewed by external reviewers. It is distributed in accordance with the Creative Commons Attribution NonCommercial (CC BY-NC 4.0) license, which permits others to distribute, remix, adapt, build upon this work non-commercially, and license their derivative works on different terms, provided the original work is properly cited and the use is non-commercial. See: <http://creativecommons.org/licenses/by-nc/4.0/>

Manuscript source: Unsolicited manuscript

Specialty type: Medicine, research and experimental

Country/Territory of origin: China

Peer-review report's scientific quality classification

Grade A (Excellent): 0
Grade B (Very good): B, B
Grade C (Good): C
Grade D (Fair): D, D
Grade E (Poor): 0

Received: November 20, 2020

Peer-review started: November 20, 2020

First decision: February 12, 2021

Revised: February 19, 2021

Accepted: March 4, 2021

Article in press: March 4, 2021

Published online: April 26, 2021

P-Reviewer: Brody AR, Pasini L, Ullah M

S-Editor: Fan JR

L-Editor: Filipodia

P-Editor: Yuan YY

specificity was 78.57%. The Kappa value was 0.415, indicating relative consistency between CanPatrol™ and CytoploRare.

CONCLUSION

CTC detection is valuable for distinguishing LC from controls, and particularly E&M-CTC detection warrants further study.

Key Words: Circulating tumor cells; Epithelial-to-mesenchymal transition; Diagnosis; Lung cancer; Ground-glass opacities; CanPatrol

©The Author(s) 2021. Published by Baishideng Publishing Group Inc. All rights reserved.

Core Tip: Circulating tumor cells (CTCs) with epithelial markers (E-CTCs), CTCs with mesenchymal markers (M-CTCs), and CTCs with both markers (E&M-CTCs) are three subtypes of CTCs. Detection of E&M-CTCs have good diagnostic value for distinguishing lung cancer from controls.

Citation: Jiang SS, Mao CG, Feng YG, Jiang B, Tao SL, Tan QY, Deng B. Circulating tumor cells with epithelial-mesenchymal transition markers as potential biomarkers for the diagnosis of lung cancer. *World J Clin Cases* 2021; 9(12): 2721-2730

URL: <https://www.wjgnet.com/2307-8960/full/v9/i12/2721.htm>

DOI: <https://dx.doi.org/10.12998/wjcc.v9.i12.2721>

INTRODUCTION

Circulating tumor cells (CTCs) destroy the integrity of the base membrane, detach from the primary site, and spread through the peripheral blood, and they have the potential to form distant metastases in the appropriate microenvironment^[1].

The epithelial-to-mesenchymal transition (EMT), which is characterized by the upregulation of mesenchymal markers (*e.g.*, cytokeratin [CK] 8, 18, and 19 and epithelial cell adhesion molecule [EpCAM]) and downregulation of epithelial markers (*e.g.*, vimentin and Twist), can lead to the transformation of epithelial cells into mesenchymal cells^[2]. This process can also promote tumor progression, metastasis, and chemotherapy resistance^[3]. CTCs include a variety of subtypes and are divided into groups according to the expression of EMT markers^[4]. Recent studies suggest that restricted EMT can generate hybrid CTCs with both epithelial and mesenchymal markers, as well as enhance their survival and carcinogenic abilities^[5]. The EMT process in these CTCs may lead to cancer metastasis and poor prognosis^[3,6]. CTCs are used as biomarkers for the diagnosis of lung cancer (LC), pancreatic cancer, and gastric cancer^[7-9]. A meta-analysis found that the sensitivity and specificity (95% confidence interval [CI]) of CTCs for the diagnosis of LC is 75% (95%CI: 54-88) and 92% (95%CI: 82-97), respectively^[8]. A pilot study from our group found that CTCs can be detected in early-stage lung adenocarcinoma (LUAD)^[10].


Herein, we clarified the diagnostic value of CTCs categorized by the expression of EMT markers in LC.

MATERIALS AND METHODS

Patients

The study protocol was reviewed and approved by the Ethics Committee of Daping Hospital, Army Medical University 2019, No. 183, and all patients who agreed to participate in the study signed an informed consent.

The study was performed between July 2015 and December 2019 and included 106 patients with LUAD. Computed tomography (CT) performed before thoracoscopic surgery indicated that 42 patients had ground glass opacity (GGO) and 64 had solid lesions. A total of 28 controls were recruited, including 11 benign tumor cases (benign controls) and 17 healthy controls who underwent physical and radiographical examination to exclude the possibility of an occult tumor. Postoperative pathological



results were reviewed by professional pathologists. Subjects with bronchiectasis, viral hepatitis, or ischemic cardiac or cerebrovascular disease were excluded from the study. Demographic-clinical data of patients and controls are shown in [Table 1](#).

Detection of CTCs and associated EMT markers by the CanPatrol™ technique

At 1 or 2 d prior to surgery, 10 mL peripheral blood was collected from the median cubital vein of patients and controls and transferred into a sample preservation tube containing ammonium chloride dissolution buffer (Surexam Biotechnology, Guangzhou, China). The samples were incubated for 30 min at room temperature. CTCs and associated EMT markers were detected using CanPatrol™ as follows^[1,11]. (1) Red blood cells were lysed and removed using red blood cell lysis buffer, and cluster of differentiation-positive (CD45+) leukocytes were depleted from blood samples using magnetic beads; (2) CTCs were enriched using a calibrated 8 µm pore membrane filter; and (3) RNA *in situ* hybridization (ISH) was used to identify CTCs using the branched DNA signal amplification assay and EMT markers such as CK 8, 18, and 19, EpCAM, vimentin, and Twist were detected according to a recently published protocol^[12].

Detection of folate receptor-positive CTCs using CytoploRare validation

Peripheral blood (3 mL) was collected before surgery and stored in a vacuum tube containing ethylenediamine tetraacetic acid. Red blood cell lysis buffer was used to lyse erythrocytes, and magnetic beads were used to deplete CD45+ leukocytes. The folate receptor, which is only expressed on tumor cells, and a synthesized oligo-nucleotide were used to label the CTCs. The conjugate was annealed and extended using a reverse transcriptase primer prior to amplification. The enriched CTCs were stained by immunofluorescence. Cells expressing the folate ligand and cytokeratin, which were stained with the nuclear stain 4',6-diamidino-2-phenylindole, were defined as folate receptor positive (FR+) CTCs. These procedures were completed within 1 h^[13,14]. The threshold for positivity was an FR+ CTC value ≥ 8.7 FU/3 mL^[13,14].

Data analysis

The Student-Newman-Keuls test was used to analyze the variance among groups. Positive rates were compared using the χ^2 test, and comparisons between two groups were performed using the Kappa Concordance Test. Cutoff values were determined using receiver operating characteristic (ROC) curves. Statistical analyses were performed using SPSS Version 23.0 software for Windows (SPSS, Inc., Chicago, IL, United States). A value of $P < 0.05$ (two-sided) was considered statistically significant.

Sensitivity = True positive / (true positive + false negative), Specificity = True negative / (true negative + false positive).

RESULTS

Distribution of CTCs in patients and controls

As shown in [Figure 1A](#), epithelial (E) and mesenchymal (M), and E&M markers were detected in CTCs. Therefore, CTCs were divided into three subtypes according to the associated markers, *i.e.* E-CTCs, M-CTCs and E&M-CTCs.

Of the 106 LC cases, 94 (88.6%) had at least one CTC, whereas CTCs were only detectable in 4 of 11 benign controls and 6 of 17 healthy controls. The detection rate of CTCs was significantly higher in LC cases than in benign or healthy controls ([Figure 1B](#)). E-CTCs were detected in 53 (53/106) LC cases, 3 benign controls (3/11), and 5 healthy controls (5/17) ([Figure 1B](#)). There was no significant difference in the incidence of E-CTCs among LC cases, benign cases, and healthy controls. The incidence of M-CTCs was significantly higher in LC cases than in healthy controls (52/106 *vs* 0/17; $P < 0.05$), whereas there was no significant difference between LC cases and benign controls (52/106 *vs* 3/11). The incidence of E&M-CTCs was significantly higher in LC cases than in benign controls (74/106 *vs* 4/11; $P < 0.05$) and in healthy controls (74/106 *vs* 1/17; $P < 0.01$). CTCs were detectable in 35 (83.3%) of 42 GGO cases including E-CTCs in 20 cases, M-CTCs in 19 cases, and E&M-CTCs in 28 cases. There was no significant correlation between CTC number and pathological and demographic features such as tumor size, age, and gender (data not shown).

The number of CTCs, M-CTCs, and E&M-CTCs was significantly higher in LC cases than in healthy controls ($P < 0.05$), whereas there was no difference between LC cases and benign controls ([Figure 1C](#)). The proportions of M-CTCs plus E&M-CTCs

Table 1 Demographic and clinical data of cases and controls

Subjects	Gender (n)	Mean age in yr	Pathologic features (n)	Stage (n)	Size in cm
Lung cancer patients (n = 106)	Male (47), Female (59)	59	AAH (1) AIS (10) MIA (11) IAC (83)	Ia (84) Ib (10) IIa (2) IIb (7) III (3)	2.03 ± 1.06
Benign controls (n = 11)	Male (4), Female (7)	49	IPT (6) ¹ Tuberculoma (2) Hamartoma (1) Fibroma (1) Pleural tumor (1)	NA	
Healthy controls (n = 17)	Male (10), Female (7)	31	NA	NA	NA

¹One inflammatory pseudotumor and one pleural tumor cases presented as ground-glass opacity. AAH: Atypical adenomatous hyperplasia; AIS: Adenocarcinoma *in situ*; IAC: Invasive adenocarcinoma; IPT: Inflammatory pseudotumor; MIA: Minimally invasive adenocarcinoma; NA: Not available.

increased gradually from healthy controls, to benign controls, to LC cases (LC *vs* benign controls: $P = 0.405$; benign controls *vs* healthy controls: $P = 0.086$; LC *vs* healthy controls: $P < 0.05$) (Figure 1D). The proportion of M-CTCs plus E&M-CTCs in GGO cases was similar to that in other LC cases.

Cut-off and diagnostic value of CTCs determined by ROC curve analysis

As shown in Figure 2 and Table 2, the area under the ROC curve (AUC) of total CTCs and E&M-CTCs was > 0.8 and > 0.75 , respectively, indicating their potential diagnostic value for discriminating LC cases from controls. Compared to GGO *vs* controls, the AUC of total CTCs or E&M-CTCs remained > 0.75 .

The most effective cut-off for positivity according to the AUC was determined to be total CTCs $\geq 2/5$ mL and E&M-CTCs $\geq 1/5$ mL (Table 2). These cut-off values were used to determine the sensitivity of total CTCs and E&M-CTCs for diagnosing LUAD, which showed that their sensitivity was higher than that of E-CTCs and M-CTCs (Table 2). After defining either total CTCs $\geq 2/5$ mL or E&M-CTCs $\geq 1/5$ mL for positivity, the sensitivity was 85.85% for LC patients and 80.95% for GGO patients, and the specificity was 78.57%.

Validation of CanPatrol™ using CytoploRare

The Canpatrol™ method was validated using CytoploRare in 20 LC cases, 7 benign cases, and 11 healthy controls. As shown in Table 3, the Kappa values reached 0.415, indicating that the detection rate of total CTCs and E&M-CTCs was comparable to that of FR+ CTCs (detected by CytoploRare). Although M-CTCs also had a P value of < 0.05 compared with FR+ CTCs, this index was excluded because of the low Kappa value (data not shown).

DISCUSSION

Detection and measurement of CTCs is a noninvasive liquid biopsy method that can provide reliable information on the diagnostic, prognostic, and/or predictive biomarkers of different types of cancer compared with invasive diagnostic modalities^[15]. CTC detection is performed in two steps: enrichment and identification. CTC enrichment is based on distinguishing tumor cell morphology and sorting cell surface markers. For example, CellSearch enriches CTCs by sorting the surface marker EpCAM using magnetic beads. ISET is a method of enriching cells by filtering cells through filter membranes based on cell size. Ficoll separation enriches cells by density gradient centrifugation based on different cell densities^[16]. CTC identification is achieved using polymerase chain reaction (PCR), immunofluorescence, and ISH^[17].

Table 2 Area under the receiver operating characteristic curve, *P* value, sensitivity and specificity of circulating tumor cells

Subjects	All lung cancer patients, <i>n</i> = 106			Lung cancer patients presenting as GGO, <i>n</i> = 42			
	AUC	<i>P</i> value	Sensitivity	AUC	<i>P</i> value	Sensitivity	Specificity
Total CTCs	0.828	< 0.0001	79.24%	0.7963	< 0.0001	71.42%	82.14%
E-CTCs	0.6193	0.0527	50.00%	0.6029	0.1469	47.62%	71.43%
M-CTCs	0.6892	0.0021	49.05%	0.6722	0.0152	42.85%	89.29%
E&M-CTCs	0.7648	< 0.0001	69.80%	0.7504	0.0004	66.67%	82.14%
Total CTCs and E&M-CTCs			85.85%			80.95%	78.57%

AUC: Area under the ROC curve; CTCs: Circulating tumor cells; E-CTCs: CTCs with epithelial markers; E&M-CTCs: CTCs with both markers; GGO: Ground-glass opacities; M-CTCs: CTCs with mesenchymal markers; ROC: Receiver operating characteristic.

Table 3 Validation of Canpatrol™ by CytoploRare in 20 lung cancer cases and 18 controls

		Total CTCs detected by Canpatrol™		E&M-CTCs detected by CytoploRare	
		Positive, <i>n</i>	Negative, <i>n</i>	Positive, <i>n</i>	Negative, <i>n</i>
FR-CTCs	Positive, <i>n</i>	16	4	17	6
	Negative, <i>n</i>	7	11	6	9
Kappa/ <i>P</i> value		0.415/0.010		0.339/0.037	

CTCs: Circulating tumor cells; E&M-CTCs: CTCs with both markers; FR: Folate receptor.

Most of the methods currently used in the clinic provide simultaneous enrichment and identification of CTCs. In this study, CanPatrol™ was used to enrich CTCs through an 8-micron filter membrane, and RNA ISH was used to identify and characterize the enriched cells based on branch DNA signal amplification technology. In addition, the expanded lanes in the CanPatrol™ system allow the detection of EMT markers such as EpCAM, CK 8, 18, and 19, vimentin, and Twist. The expression of these markers allows the classification of CTCs into different subtypes, namely, E-CTCs, M-CTCs, and E&M-CTCs^[12]. A recent study^[18] reported that the sensitivity and specificity of total CTCs detected by CanPatrol™ technology for the diagnosis of LC is 81.6% and 86.8%, respectively, which is consistent with the present results.

We used a widely used method, CytoploRare, to validate the CanPatrol™ results. The FR is a glycoprotein that is highly expressed on the cell surface and can be detected on lung and ovarian cancer cells^[19]. Samples consisting of 3 mL peripheral blood were used to enrich FR+ CTCs; white blood cells were removed using immunomagnetic beads, and FR, a tumor-specific ligand, as well as a synthesized oligonucleotide were labeled on the cells. Quantitative PCR was used to analyze the conjugates. FR CTCs were defined as cells expressing folate ligands and cytokeratin with positive nuclear staining^[13]. The sensitivity and specificity of this technology for the detection of FR+ CTCs is 81.94% and 73.08%, respectively^[20]. Kappa values indicated a relatively similar detection efficacy for CanPatrol™ and CytoploRare, suggesting acceptable consistency. However, further studies with a larger sample size are necessary to confirm these results.

Another advantage of CanPatrol™ is that it can identify CTCs based on mesenchymal markers, whereas current CTCs monitoring methods, including CellSearch and MACS, are based on the detection of EpCAM, and thereby do not detect M-CTCs or E&M-CTCs. CTCs undergoing EMT should receive increased attention because they are characterized by higher aggressiveness and carcinogenicity^[21,22]. Tumor cells are more likely to form E&M-CTCs than M-CTCs to obtain both mesenchymal and epithelial cell characteristics^[5].

TelomeScan F35, which uses a telomerase-specific replication-selective adenovirus (OBP-1101) to detect CTCs using EMT markers, was used to show that CTCs with EMT-markers are effective for the early diagnosis of non-small cell lung cancer [mean sensitivity: 69.1% (59.6%, 40.0%, 85.7%, and 75.0% for stage I, II, III, and IV, respectively)]^[23].

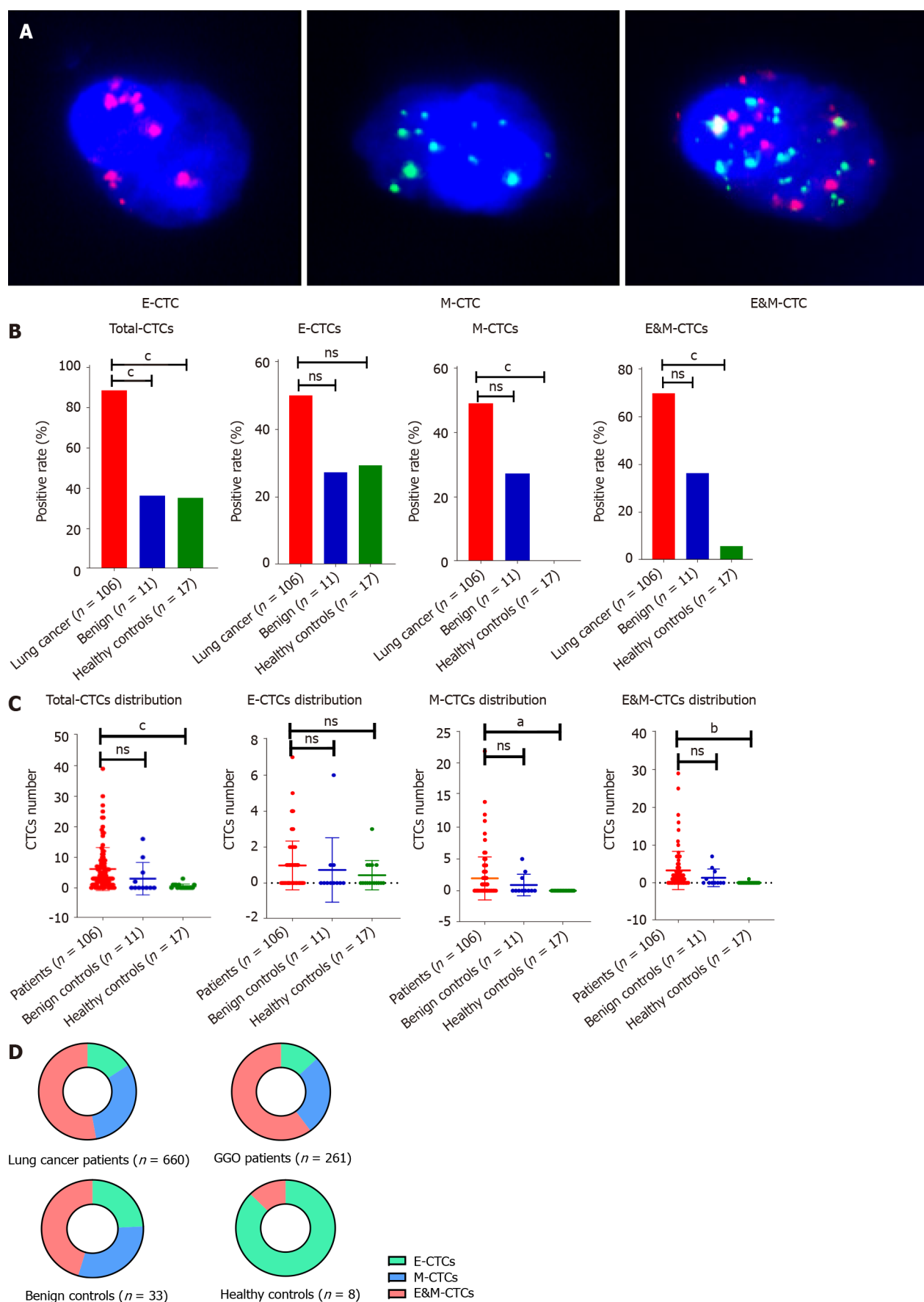


Figure 1 Distribution of circulating tumor cells in lung cancer patients and controls. A: Circulating tumor cells (CTCs) with epithelial markers, CTCs with mesenchymal markers (M-CTCs), and CTCs with both marker (E&M-CTCs) can be identified in one CTC; B: Positive rate of CTCs in lung cancer cases was significantly higher than those in benign or healthy controls; C: The numbers of CTCs, M-CTCs, and E&M-CTCs in lung cancer cases were significantly higher than

those in healthy controls ($P < 0.05$); however, there was no disparity between lung cancer and benign controls; D: The proportions of M-CTCs plus E&M-CTCs increased gradually in healthy controls, benign controls, and lung cancer cases. ^a $P < 0.05$; ^b $P < 0.01$; ^c $P < 0.001$. GGO: Ground-glass opacities.

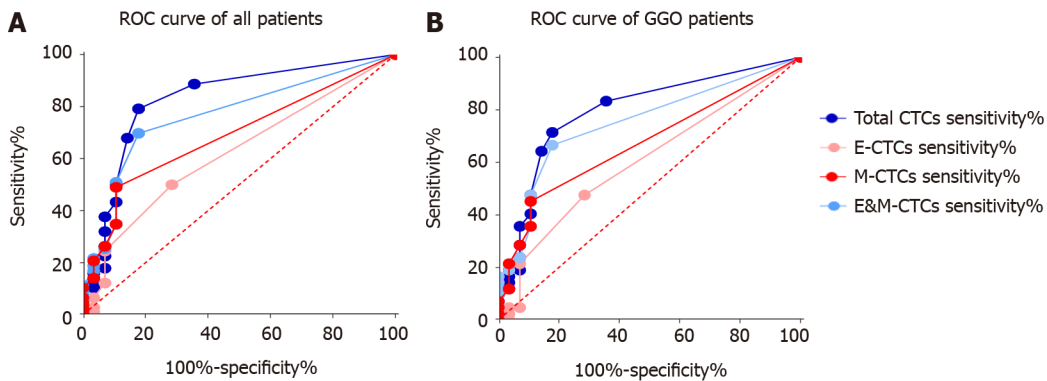


Figure 2 Receiver operating characteristic curve of all lung cancer patients and ground-glass opacities patients. A: Area under the receiver operating characteristic curve (AUC) of total circulating tumor cells (CTCs) and CTCs with both markers (E&M-CTCs) for lung cancer diagnosis were 0.828 and 0.7648, respectively; B: AUCs of total CTCs and E&M-CTCs for ground-glass opacity (GGO) diagnosis were 0.7963 and 0.7504, respectively.

In this study, we found that E&M-CTCs had a greater discriminative power for the diagnosis of LC than E-CTCs or M-CTCs. In addition, we showed that CTCs can be present in benign and healthy controls. However, E&M-CTCs were detected in one case in the control group that corresponded to a smoker. Similarly, CTCs can be recognized as a “sentinel” in cases associated with inflammatory diseases such as chronic obstructive pulmonary disease^[24]. In patients with benign colon diseases, CTCs can also be detected with both the CellSearch system (11.3%) and the CK19-EPISPOT assay (18.9%), because inflammatory epithelial cells from these benign lesions may enter the peripheral blood^[25]. In 232 patients with benign breast diseases, the CTC detection rate reached 15.95%^[26]. Herein, we hypothesized that tumor cells or debris, which can be shed from the benign tumor into the peripheral blood, are captured and recognized as CTCs by CanPatrol™. However, we cannot completely rule out that these CTCs in the controls were not malignant because CTCs may appear at a very early stage of cancer development, even if the lesion is undetectable by systemic physical and radiological examinations. Whether these “benign” tumors or diseases were in a premalignant stage requires long-term follow-up.

In this study, the proportions of M-CTCs and E&M-CTCs were highest in LC patients compared with benign and healthy controls, supporting the critical role of the EMT process in CTCs in promoting tumor invasion, migration, and metastatic growth.

Detection of E&M-CTCs is effective for distinguishing LC, including GGO and solid lesions, from controls, thus providing a new method for discriminating between malignant and benign pulmonary nodes in clinical practice. Because the study only included two benign cases presented as GGO, we were unable to determine the diagnostic value of E&M-CTCs for discriminating between malignant and benign GGO. Intriguingly, fibrosis can be found in either benign or malignant lung GGO^[27,28]. However, very few published studies have focused on CTCs and GGO, not to mention CTCs and fibrosis. Furthermore, pathological reports from our hospital did not clearly describe the fibrosis condition of these GGO cases. Therefore, we are going to design further clinical trials regarding CTCs in GGO, which will consider the fibrosis condition and the expressions of relevant biomarkers, *e.g.*, CXCL4 and LECT2^[29,30]. Additional studies with a large sample size and a multicenter design are warranted in the near future.

CONCLUSION

In conclusion, after defining total CTCs $\geq 2/5$ mL or E&M-CTCs $\geq 1/5$ mL as the cut-off for positivity, the sensitivity and specificity for LC diagnosis were 85.85% and 78.57%, respectively. CTC detection is valuable for distinguishing LC from controls.

ARTICLE HIGHLIGHTS

Research background

Circulating tumor cells (CTCs) can be clustered into three subtypes according to surface biomarkers. CTC detection has clinical implications in the diagnosis of lung cancer (LC).

Research motivation

CTCs categorized by epithelial-mesenchymal transition (EMT) markers have diagnostic value in LC and ground-glass opacities (GGO) patients.

Research objectives

To clarify the diagnostic value of CTCs categorized by the expression of EMT markers in LC and GGO patients

Research methods

Of the 106 patients with lung adenocarcinoma comprising the study cohort, 42 had GGO and 64 had solid lesions; 11 patients with benign tumors and 17 healthy controls were included as controls. Total CTCs and CTCs with both markers (E&M-CTCs) of these patients were detected, the diagnostic value of CTCs categorized by the expression of EMT markers. CytoploRare technique was used in 20 cases and 18 controls for validation.

Research results

Total CTCs and E&M-CTCs were significantly more frequent in LC cases than in benign or healthy controls. The area under the receiver operating characteristic curve of total CTCs and E&M-CTCs was > 0.8 and > 0.75 , respectively. The combined sensitivity of total-CTCs and E&M-CTCs was 85.85% for LC patients (80.95% for GGO patients) and the specificity was 78.57%.

Research conclusions

CTC detection is valuable for distinguishing LC as well as GGO patients from controls.

Research perspectives

Epithelial (E)-, mesenchymal (M)-, and E&M markers can be identified in CTC. Therefore, CTCs were clustered into three subtypes, as *per* the markers on CTC, *i.e.* E-CTC, M-CTC and E&M-CTC. Detection of E&M-CTC has good diagnostic value in distinguishing lung cancer, providing a new method to discriminate between malignant and benign pulmonary node in clinical practice.

ACKNOWLEDGEMENTS

We thank Dr. Xu-Rui Jin for reviewing the statistical methods of this study.

REFERENCES

- 1 Wu S, Liu Z, Liu S, Lin L, Yang W, Xu J. Enrichment and enumeration of circulating tumor cells by efficient depletion of leukocyte fractions. *Clin Chem Lab Med* 2015; **53**: 337 [PMID: 25568985 DOI: 10.1515/cclm-2015-5000]
- 2 Cao Z, Livas T, Kyprianou N. Anoikis and EMT: Lethal "Liaisons" during Cancer Progression. *Crit Rev Oncog* 2016; **21**: 155-168 [PMID: 27915969 DOI: 10.1615/CritRevOncog.2016016955]
- 3 Yin W, Han YM, Li ZL, Huang ZX, Huang L, Zhong XG. Clinical significance of perioperative EMT-CTC in rectal cancer patients receiving open/laparoscopic surgery. *Neoplasma* 2020; **67**: 1131-1138 [PMID: 32412772 DOI: 10.4149/neo_2020_190709N611]
- 4 Zhao XH, Wang ZR, Chen CL, Di L, Bi ZF, Li ZH, Liu YM. Molecular detection of epithelial-mesenchymal transition markers in circulating tumor cells from pancreatic cancer patients: Potential role in clinical practice. *World J Gastroenterol* 2019; **25**: 138-150 [PMID: 30643364 DOI: 10.3748/wjg.v25.i1.138]
- 5 Liu X, Li J, Cadilha BL, Markota A, Voigt C, Huang Z, Lin PP, Wang DD, Dai J, Kranz G, Krandick A, Libl D, Zitzelsberger H, Zagorski I, Braselmann H, Pan M, Zhu S, Huang Y, Niedermeyer S, Reichel CA, Uhl B, Briukhovetska D, Suárez J, Kobold S, Gires O, Wang H. Epithelial-type systemic breast carcinoma cells with a restricted mesenchymal transition are a major source of metastasis. *Sci*

- Adv* 2019; **5**: eaav4275 [PMID: 31223646 DOI: 10.1126/sciadv.aav4275]
- 6 **Liu DG**, Xue L, Li J, Yang Q, Peng JZ. Epithelial-mesenchymal transition and GALC expression of circulating tumor cells indicate metastasis and poor prognosis in non-small cell lung cancer. *Cancer Biomark* 2018; **22**: 417-426 [PMID: 29758927 DOI: 10.3233/CBM-170995]
- 7 **Zhou J**, Ma X, Bi F, Liu M. Clinical significance of circulating tumor cells in gastric cancer patients. *Oncotarget* 2017; **8**: 25713-25720 [PMID: 28147337 DOI: 10.18632/oncotarget.14879]
- 8 **Huang H**, Shi Y, Huang J, Wang X, Zhang R, Chen H. Circulating tumor cells as a potential biomarker in diagnosis of lung cancer: a systematic review and meta-analysis. *Clin Respir J* 2018; **12**: 639-645 [PMID: 27778482 DOI: 10.1111/crj.12573]
- 9 **Xie ZB**, Yao L, Jin C, Fu DL. Circulating tumor cells in pancreatic cancer patients: efficacy in diagnosis and value in prognosis. *Discov Med* 2016; **22**: 121-128 [PMID: 27755967]
- 10 **Jin XR**, Zhu LY, Qian K, Feng YG, Zhou JH, Wang RW, Bai L, Deng B, Liang N, Tan QY. Circulating tumor cells in early stage lung adenocarcinoma: a case series report and literature review. *Oncotarget* 2017; **8**: 23130-23141 [PMID: 28423562 DOI: 10.18632/oncotarget.15506]
- 11 **Liu YK**, Hu BS, Li ZL, He X, Li Y, Lu LG. An improved strategy to detect the epithelial-mesenchymal transition process in circulating tumor cells in hepatocellular carcinoma patients. *Hepatol Int* 2016; **10**: 640-646 [PMID: 27115761 DOI: 10.1007/s12072-016-9732-7]
- 12 **Wu S**, Liu S, Liu Z, Huang J, Pu X, Li J, Yang D, Deng H, Yang N, Xu J. Classification of circulating tumor cells by epithelial-mesenchymal transition markers. *PLoS One* 2015; **10**: e0123976 [PMID: 25909322 DOI: 10.1371/journal.pone.0123976]
- 13 **Chen X**, Zhou F, Li X, Yang G, Zhang L, Ren S, Zhao C, Deng Q, Li W, Gao G, Li A, Zhou C. Folate Receptor-Positive Circulating Tumor Cell Detected by LT-PCR-Based Method as a Diagnostic Biomarker for Non-Small-Cell Lung Cancer. *J Thorac Oncol* 2015; **10**: 1163-1171 [PMID: 26200270 DOI: 10.1097/JTO.0000000000000606]
- 14 **Yu Y**, Chen Z, Dong J, Wei P, Hu R, Zhou C, Sun N, Luo M, Yang W, Yao R, Gao Y, Li J, Yang G, He W, He J. Folate receptor-positive circulating tumor cells as a novel diagnostic biomarker in non-small cell lung cancer. *Transl Oncol* 2013; **6**: 697-702 [PMID: 24466372 DOI: 10.1593/tlo.13535]
- 15 **Deng CJ**, Dai FQ, Qian K, Tan QY, Wang RW, Deng B, Zhou JH. Clinical updates of approaches for biopsy of pulmonary lesions based on systematic review. *BMC Pulm Med* 2018; **18**: 146 [PMID: 30176840 DOI: 10.1186/s12890-018-0713-6]
- 16 **Geeurickx E**, Hendrix A. Targets, pitfalls and reference materials for liquid biopsy tests in cancer diagnostics. *Mol Aspects Med* 2020; **72**: 100828 [PMID: 31711714 DOI: 10.1016/j.mam.2019.10.005]
- 17 **Liu X**, Zhang Z, Zhang B, Zheng Y, Zheng C, Liu B, Zheng S, Dong K, Dong R. Circulating tumor cells detection in neuroblastoma patients by EpCAM-independent enrichment and immunostaining-fluorescence in situ hybridization. *EBioMedicine* 2018; **35**: 244-250 [PMID: 30104180 DOI: 10.1016/j.ebiom.2018.08.005]
- 18 **Li J**, Liao Y, Ran Y, Wang G, Wu W, Qiu Y, Liu J, Wen N, Jing T, Wang H, Zhang S. Evaluation of sensitivity and specificity of CanPatrol™ technology for detection of circulating tumor cells in patients with non-small cell lung cancer. *BMC Pulm Med* 2020; **20**: 274 [PMID: 33081780 DOI: 10.1186/s12890-020-01314-4]
- 19 **Zhou Q**, Geng Q, Wang L, Huang J, Liao M, Li Y, Ding Z, Yang S, Zhao H, Shen Q, Pan C, Lou J, Lu S, Chen C, Luo Q. Value of folate receptor-positive circulating tumour cells in the clinical management of indeterminate lung nodules: A non-invasive biomarker for predicting malignancy and tumour invasiveness. *EBioMedicine* 2019; **41**: 236-243 [PMID: 30872130 DOI: 10.1016/j.ebiom.2019.02.028]
- 20 **Xue Y**, Cong W, Xie S, Shu J, Feng G, Gao H. Folate-receptor-positive circulating tumor cells as an efficacious biomarker for the diagnosis of small pulmonary nodules. *J Cancer Res Ther* 2018; **14**: 1620-1626 [PMID: 30589049 DOI: 10.4103/jcrt.JCRT_905_17]
- 21 **Yu M**, Bardia A, Wittner BS, Stott SL, Smas ME, Ting DT, Isakoff SJ, Ciciliano JC, Wells MN, Shah AM, Concannon KF, Donaldson MC, Sequist LV, Brachtel E, Sgroi D, Baselga J, Ramaswamy S, Toner M, Haber DA, Maheswaran S. Circulating breast tumor cells exhibit dynamic changes in epithelial and mesenchymal composition. *Science* 2013; **339**: 580-584 [PMID: 23372014 DOI: 10.1126/science.1228522]
- 22 **Effenberger KE**, Schroeder C, Hanssen A, Wolter S, Eulenburg C, Tachezy M, Gebauer F, Izbicki JR, Pantel K, Bockhorn M. Improved Risk Stratification by Circulating Tumor Cell Counts in Pancreatic Cancer. *Clin Cancer Res* 2018; **24**: 2844-2850 [PMID: 29559560 DOI: 10.1158/1078-0432.CCR-18-0120]
- 23 **Togo S**, Katagiri N, Namba Y, Tulafu M, Nagahama K, Kadoya K, Takamochi K, Oh S, Suzuki K, Sakurai F, Mizuguchi H, Urata Y, Takahashi K. Sensitive detection of viable circulating tumor cells using a novel conditionally telomerase-selective replicating adenovirus in non-small cell lung cancer patients. *Oncotarget* 2017; **8**: 34884-34895 [PMID: 28432274 DOI: 10.18632/oncotarget.16818]
- 24 **Ilie M**, Hofman V, Long-Mira E, Selva E, Vignaud JM, Padovani B, Mouroux J, Marquette CH, Hofman P. "Sentinel" circulating tumor cells allow early diagnosis of lung cancer in patients with chronic obstructive pulmonary disease. *PLoS One* 2014; **9**: e111597 [PMID: 25360587 DOI: 10.1371/journal.pone.0111597]
- 25 **Pantel K**, Denève E, Nocca D, Coffy A, Vendrell JP, Maudelonde T, Riethdorf S, Alix-Panabières C. Circulating epithelial cells in patients with benign colon diseases. *Clin Chem* 2012; **58**: 936-940 [PMID: 22205690 DOI: 10.1373/clinchem.2011.175570]

- 26 **Jin L**, Zhao W, Zhang J, Chen W, Xie T, Wang L, Fan W, Xie S, Shen J, Zheng H, Hu W, Wei Q, Dong M, Wang Q, Liu Y. Evaluation of the diagnostic value of circulating tumor cells with CytoSorter® CTC capture system in patients with breast cancer. *Cancer Med* 2020; **9**: 1638-1647 [PMID: [31908156](#) DOI: [10.1002/cam4.2825](#)]
- 27 **Qin Y**, Xu Y, Ma D, Tian Z, Huang C, Zhou X, He J, Liu L, Guo C, Wang G, Zhang J, Wang Y, Liu H. Clinical characteristics of resected solitary ground-glass opacities: Comparison between benign and malignant nodules. *Thorac Cancer* 2020; **11**: 2767-2774 [PMID: [32844603](#) DOI: [10.1111/1759-7714.13575](#)]
- 28 **Lv YG**, Bao JH, Xu DU, Yan QH, Li YJ, Yuan DL, Ma JH. Characteristic analysis of pulmonary ground-glass lesions with the help of 64-slice CT technology. *Eur Rev Med Pharmacol Sci* 2017; **21**: 3212-3217 [PMID: [28770963](#)]
- 29 **van Bon L**, Affandi AJ, Broen J, Christmann RB, Marijnissen RJ, Stawski L, Farina GA, Stifano G, Mathes AL, Cossu M, York M, Collins C, Wenink M, Huijbens R, Hesselstrand R, Saxne T, DiMarzio M, Wuttge D, Agarwal SK, Reveille JD, Assassi S, Mayes M, Deng Y, Drenth JP, de Graaf J, den Heijer M, Kallenberg CG, Bijl M, Loof A, van den Berg WB, Joosten LA, Smith V, de Keyser F, Scorza R, Lunardi C, van Riel PL, Vonk M, van Heerde W, Meller S, Homey B, Beretta L, Roest M, Trojanowska M, Lafyatis R, Radstake TR. Proteome-wide analysis and CXCL4 as a biomarker in systemic sclerosis. *N Engl J Med* 2014; **370**: 433-443 [PMID: [24350901](#) DOI: [10.1056/NEJMoa1114576](#)]
- 30 **Xu M**, Xu HH, Lin Y, Sun X, Wang LJ, Fang ZP, Su XH, Liang XJ, Hu Y, Liu ZM, Cheng Y, Wei Y, Li J, Li L, Liu HJ, Cheng Z, Tang N, Peng C, Li T, Liu T, Qiao L, Wu D, Ding YQ, Zhou WJ. LECT2, a Ligand for Tie1, Plays a Crucial Role in Liver Fibrogenesis. *Cell* 2019; **178**: 1478-1492. e20 [PMID: [31474362](#) DOI: [10.1016/j.cell.2019.07.021](#)]



Published by **Baishideng Publishing Group Inc**
7041 Koll Center Parkway, Suite 160, Pleasanton, CA 94566, USA

Telephone: +1-925-3991568

E-mail: bpgoffice@wjgnet.com

Help Desk: <https://www.f6publishing.com/helpdesk>

<https://www.wjgnet.com>

