

World Journal of *Clinical Cases*

World J Clin Cases 2021 April 26; 9(12): 2696-2950



Contents

Thrice Monthly Volume 9 Number 12 April 26, 2021

MINIREVIEWS

- 2696** Standardization of critical care management of non-critically ill patients with COVID-19
Wang CS, Gao Y, Kang K, Fei DS, Meng XL, Liu HT, Luo YP, Yang W, Dai QQ, Gao Y, Zhao MY, Yu KJ
- 2703** Mediastinal lymphadenopathy in COVID-19: A review of literature
Taweasedt PT, Surani S
- 2711** Polycystic ovary syndrome: Pathways and mechanisms for possible increased susceptibility to COVID-19
Ilias I, Goulas S, Zabuliene L

ORIGINAL ARTICLE

Clinical and Translational Research

- 2721** Circulating tumor cells with epithelial-mesenchymal transition markers as potential biomarkers for the diagnosis of lung cancer
Jiang SS, Mao CG, Feng YG, Jiang B, Tao SL, Tan QY, Deng B

Retrospective Study

- 2731** Management and implementation strategies of pre-screening triage in children during coronavirus disease 2019 pandemic in Guangzhou, China
Shi X, Cai YT, Cai X, Wen XL, Wang JY, Ma WC, Shen J, Wu JX, Liu HY, Sun J, He PQ, Lin Y, Zhao DY, Li PQ
- 2739** Clinicopathological features of superficial CD34-positive fibroblastic tumor
Ding L, Xu WJ, Tao XY, Zhang L, Cai ZG
- 2751** Application of a rapid exchange extension catheter technique in type B2/C nonocclusive coronary intervention *via* a transradial approach
Wang HC, Lu W, Gao ZH, Xie YN, Hao J, Liu JM

SYSTEMATIC REVIEWS

- 2763** Paradoxical relationship between proton pump inhibitors and COVID-19: A systematic review and meta-analysis
Zippi M, Fiorino S, Budriesi R, Micucci M, Corazza I, Pica R, de Biase D, Gallo CG, Hong W

META-ANALYSIS

- 2778** Predictive risk factors for recollapse of cemented vertebrae after percutaneous vertebroplasty: A meta-analysis
Ma YH, Tian ZS, Liu HC, Zhang BY, Zhu YH, Meng CY, Liu XJ, Zhu QS

CASE REPORT

- 2791** Malignant pheochromocytoma with cerebral and skull metastasis: A case report and literature review
Chen JC, Zhuang DZ, Luo C, Chen WQ
- 2801** Unresectable esophageal cancer treated with multiple chemotherapies in combination with chemoradiotherapy: A case report
Yura M, Koyanagi K, Hara A, Hayashi K, Tajima Y, Kaneko Y, Fujisaki H, Hirata A, Takano K, Hongo K, Yo K, Yoneyama K, Tamai Y, Dehari R, Nakagawa M
- 2811** Role of positron emission tomography in primary carcinoma ex pleomorphic adenoma of the bronchus: A case report
Yang CH, Liu NT, Huang TW
- 2816** Positive reverse transcription-polymerase chain reaction assay results in patients recovered from COVID-19: Report of two cases
Huang KX, He C, Yang YL, Huang D, Jiang ZX, Li BG, Liu H
- 2823** Laryngeal myxoma: A case report
Yu TT, Yu H, Cui Y, Liu W, Cui XY, Wang X
- 2830** Prostate stromal tumor with prostatic cysts after transurethral resection of the prostate: A case report
Zhao LW, Sun J, Wang YY, Hua RM, Tai SC, Wang K, Fan Y
- 2838** Intramuscular hematoma in rhabdomyolysis patients treated with low-molecular-weight heparin: Report of two cases
Yuan SY, Xie KF, Yang J
- 2845** Partial response to Chinese patent medicine Kangliu pill for adult glioblastoma: A case report and review of the literature
Sun G, Zhuang W, Lin QT, Wang LM, Zhen YH, Xi SY, Lin XL
- 2854** Behcet's disease manifesting as esophageal variceal bleeding: A case report
Xie WX, Jiang HT, Shi GQ, Yang LN, Wang H
- 2862** Successful endoscopic surgery for emphysematous pyelonephritis in a non-diabetic patient with autosomal dominant polycystic kidney disease: A case report
Jiang Y, Lo R, Lu ZQ, Cheng XB, Xiong L, Luo BF
- 2868** Robotically assisted removal of pelvic splenosis fifty-six years after splenectomy: A case report
Tognarelli A, Faggioni L, Erba AP, Faviana P, Durante J, Manassero F, Selli C
- 2874** Pulmonary alveolar proteinosis complicated with nocardiosis: A case report and review of the literature
Wu XK, Lin Q
- 2884** Detection of EGFR-SEPT14 fusion in cell-free DNA of a patient with advanced gastric cancer: A case report
Kim B, Kim Y, Park I, Cho JY, Lee KA

- 2890** Timing of convalescent plasma therapy-tips from curing a 100-year-old COVID-19 patient using convalescent plasma treatment: A case report
Liu B, Ren KK, Wang N, Xu XP, Wu J
- 2899** Torsades de pointes episode in a woman with high-grade fever and inflammatory activation: A case report
Qiu H, Li HW, Zhang SH, Zhou XG, Li WP
- 2908** Salivary duct carcinoma of the submandibular gland presenting a diagnostic challenge: A case report
Uchihashi T, Kodama S, Sugauchi A, Hiraoka S, Hirose K, Usami Y, Tanaka S, Kogo M
- 2916** Allogeneic hematopoietic stem cell transplantation in a 3-year-old boy with congenital pyruvate kinase deficiency: A case report
Ma ZY, Yang X
- 2923** Congenital bilateral cryptorchidism in an infant conceived after maternal breast cancer treatment: A case report
Hu WK, Liu J, Liu RX, Liu XW, Yin CH
- 2930** Sclerosing polycystic adenosis of the submandibular gland: Two case reports
Wu L, Wang Y, Hu CY, Huang CM
- 2937** Budd-Chiari syndrome associated with liver cirrhosis: A case report
Ye QB, Huang QF, Luo YC, Wen YL, Chen ZK, Wei AL
- 2944** Separated root tip formation associated with a fractured tubercle of dens evaginatus: A case report
Wu ZF, Lu LJ, Zheng HY, Tu Y, Shi Y, Zhou ZH, Fang LX, Fu BP

ABOUT COVER

Editorial Board Member of *World Journal of Clinical Cases*, Jing Liu, MD, PhD, Chief Doctor, Professor, Department of Neonatology and NICU, Beijing Chaoyang District Maternal and Child Healthcare Hospital, Beijing 100021, China. liujingbj@live.cn

AIMS AND SCOPE

The primary aim of *World Journal of Clinical Cases* (WJCC, *World J Clin Cases*) is to provide scholars and readers from various fields of clinical medicine with a platform to publish high-quality clinical research articles and communicate their research findings online.

WJCC mainly publishes articles reporting research results and findings obtained in the field of clinical medicine and covering a wide range of topics, including case control studies, retrospective cohort studies, retrospective studies, clinical trials studies, observational studies, prospective studies, randomized controlled trials, randomized clinical trials, systematic reviews, meta-analysis, and case reports.

INDEXING/ABSTRACTING

The WJCC is now indexed in Science Citation Index Expanded (also known as SciSearch®), Journal Citation Reports/Science Edition, Scopus, PubMed, and PubMed Central. The 2020 Edition of Journal Citation Reports® cites the 2019 impact factor (IF) for WJCC as 1.013; IF without journal self cites: 0.991; Ranking: 120 among 165 journals in medicine, general and internal; and Quartile category: Q3. The WJCC's CiteScore for 2019 is 0.3 and Scopus CiteScore rank 2019: General Medicine is 394/529.

RESPONSIBLE EDITORS FOR THIS ISSUE

Production Editor: Ji-Hong Lin; Production Department Director: Xiang Li; Editorial Office Director: Jin-Lai Wang.

NAME OF JOURNAL

World Journal of Clinical Cases

ISSN

ISSN 2307-8960 (online)

LAUNCH DATE

April 16, 2013

FREQUENCY

Thrice Monthly

EDITORS-IN-CHIEF

Dennis A Bloomfield, Sandro Vento, Bao-Gan Peng

EDITORIAL BOARD MEMBERS

<https://www.wjgnet.com/2307-8960/editorialboard.htm>

PUBLICATION DATE

April 26, 2021

COPYRIGHT

© 2021 Baishideng Publishing Group Inc

INSTRUCTIONS TO AUTHORS

<https://www.wjgnet.com/bpg/gerinfo/204>

GUIDELINES FOR ETHICS DOCUMENTS

<https://www.wjgnet.com/bpg/GerInfo/287>

GUIDELINES FOR NON-NATIVE SPEAKERS OF ENGLISH

<https://www.wjgnet.com/bpg/gerinfo/240>

PUBLICATION ETHICS

<https://www.wjgnet.com/bpg/GerInfo/288>

PUBLICATION MISCONDUCT

<https://www.wjgnet.com/bpg/gerinfo/208>

ARTICLE PROCESSING CHARGE

<https://www.wjgnet.com/bpg/gerinfo/242>

STEPS FOR SUBMITTING MANUSCRIPTS

<https://www.wjgnet.com/bpg/GerInfo/239>

ONLINE SUBMISSION

<https://www.f6publishing.com>

Predictive risk factors for recollapse of cemented vertebrae after percutaneous vertebroplasty: A meta-analysis

Yi-Hang Ma, Zhi-Sen Tian, Hao-Chuan Liu, Bo-Yin Zhang, Yu-Hang Zhu, Chun-Yang Meng, Xiang-Ji Liu, Qing-San Zhu

ORCID number: Yi-Hang Ma 0000-0002-1123-844X; Zhi-Sen Tian 0000-0002-7986-9416; Hao-Chuan Liu 0000-0002-0813-2134; Bo-Yin Zhang 0000-0002-5273-2145; Yu-Hang Zhu 0000-0002-0866-8588; Chun-Yang Meng 0000-0001-9025-8272; Xiang-Ji Liu 0000-0003-0203-9358; Qing-San Zhu 0000-0002-9403-832X.

Author contributions: Ma YH, Liu HC, and Zhu QS conceived the study idea; Meng CY, Tian ZS, and Zhang BY designed the study protocol; Ma YH and Zhu YH managed the literature search and data acquisition; Liu XJ and Zhu YH performed data analysis; Ma YH drafted the initial manuscript; Meng CY, Liu HC, Liu XJ, Tian ZS, and Zhang BY critically revised the manuscript for important intellectual content; Zhu QS resolved ambiguities during the study and gave final approval of the manuscript.

Conflict-of-interest statement: The authors deny any conflict of interest.

PRISMA 2009 Checklist statement: The authors have read the PRISMA 2009 Checklist, and the manuscript was prepared and revised according to the PRISMA 2009 Checklist.

Open-Access: This article is an

Yi-Hang Ma, Zhi-Sen Tian, Hao-Chuan Liu, Bo-Yin Zhang, Yu-Hang Zhu, Chun-Yang Meng, Xiang-Ji Liu, Qing-San Zhu, Department of Spine Surgery, China-Japan Union Hospital of Jilin University, Changchun 130033, Jilin Province, China

Corresponding author: Qing-San Zhu, MD, PhD, Professor, Surgeon, Department of Spine Surgery, China-Japan Union Hospital of Jilin University, No. 126 Xiantai Street, Changchun 130033, Jilin Province, China. zhuqs@jlu.edu.cn

Abstract

BACKGROUND

As one of the most common complications of osteoporosis, osteoporotic vertebral compression fracture (OVCF) increases the risk of disability and mortality in elderly patients. Percutaneous vertebroplasty (PVP) is considered to be an effective, safe, and minimally invasive treatment for OVCFs. The recollapse of cemented vertebrae is one of the serious complications of PVP. However, the risk factors associated with recollapse after PVP remain controversial.

AIM

To identify risk factors for the recollapse of cemented vertebrae after PVP in patients with OVCFs.

METHODS

A systematic search in EMBASE, MEDLINE, the Cochrane Library, and PubMed was conducted for relevant studies from inception until March 2020. Studies investigating risk factors for the recollapse of cemented vertebrae after PVP without additional trauma were selected for analysis. Odds ratios (ORs) or standardized mean differences with 95% confidence interval (CI) were calculated and heterogeneity was assessed by both the chi-squared test and the *I*-squared test. The methodological quality of the included studies was assessed according to the Newcastle-Ottawa Scale.

RESULTS

A total of nine case-control studies were included in our meta-analysis comprising 300 cases and 2674 controls. The significant risk factors for the recollapse of cemented vertebrae after PVP in OVCF patients were fractures located at the thoracolumbar junction (OR = 2.09; 95%CI: 1.30 to 3.38; *P* = 0.002), preoperative intravertebral cleft (OR = 2.97; 95%CI: 1.93 to 4.57; *P* < 0.00001), and solid lump

open-access article that was selected by an in-house editor and fully peer-reviewed by external reviewers. It is distributed in accordance with the Creative Commons Attribution NonCommercial (CC BY-NC 4.0) license, which permits others to distribute, remix, adapt, build upon this work non-commercially, and license their derivative works on different terms, provided the original work is properly cited and the use is non-commercial. See: <http://creativecommons.org/licenses/by-nc/4.0/>

Manuscript source: Unsolicited manuscript

Specialty type: Orthopedics

Country/Territory of origin: China

Peer-review report's scientific quality classification

Grade A (Excellent): A

Grade B (Very good): B

Grade C (Good): 0

Grade D (Fair): 0

Grade E (Poor): 0

Received: January 21, 2021

Peer-review started: January 21, 2021

First decision: February 11, 2021

Revised: February 18, 2021

Accepted: March 11, 2021

Article in press: March 11, 2021

Published online: April 26, 2021

P-Reviewer: Santiago F

S-Editor: Zhang H

L-Editor: Wang TQ

P-Editor: Liu JH



distribution pattern of the cement (OR = 3.11; 95%CI: 1.91 to 5.07; $P < 0.00001$). The analysis did not support that age, gender, lumbar bone mineral density, preoperative visual analogue scale score, injected cement volume, intradiscal cement leakage, or vertebral height restoration could increase the risk for cemented vertebra recollapse after PVP in OVCFs.

CONCLUSION

This meta-analysis suggests that thoracolumbar junction fractures, preoperative intravertebral cleft, and solid lump cement distribution pattern are associated with the recollapse of cemented vertebrae after PVP in OVCF patients.

Key Words: Vertebroplasty; Osteoporotic vertebral compression fracture; Risk factors; Recollapse; Cemented vertebrae; Meta-analysis

©The Author(s) 2021. Published by Baishideng Publishing Group Inc. All rights reserved.

Core Tip: The predictive risk factors associated with recollapse after percutaneous vertebroplasty (PVP) in osteoporotic vertebral compression fractures (OVCFs) remain controversial. To our knowledge, this is the first meta-analysis pooling all relevant published data to identify risk factors that may lead to the recollapse of cemented vertebrae after PVP. Three predictive risk factors, including fractures located at the thoracolumbar junction, preoperative intravertebral cleft, and solid lump cement distribution pattern, were associated with the recollapse of cemented vertebrae after PVP in OVCFs. Patients with these conditions should be treated more cautiously, and close follow-up is necessary for surgeons to detect failed PVP early.

Citation: Ma YH, Tian ZS, Liu HC, Zhang BY, Zhu YH, Meng CY, Liu XJ, Zhu QS. Predictive risk factors for recollapse of cemented vertebrae after percutaneous vertebroplasty: A meta-analysis. *World J Clin Cases* 2021; 9(12): 2778-2790

URL: <https://www.wjgnet.com/2307-8960/full/v9/i12/2778.htm>

DOI: <https://dx.doi.org/10.12998/wjcc.v9.i12.2778>

INTRODUCTION

Osteoporosis is characterized by reduced bone mass and bone microstructure degeneration. The immediate consequence of osteoporosis is the occurrence of osteoporotic fractures, especially in areas where cancellous bone is abundant such as the vertebra and hip^[1]. An osteoporotic vertebral compression fracture (OVCF) is one of the most common complications of osteoporosis. As the global population ages, the absolute number of elderly patients and the incidence of OVCF are increasing^[2]. OVCFs can not only cause pain and kyphosis, compromising the quality of life, but also increase the risk of disability and mortality to some extent^[3]. As a minimally invasive technique for treating OVCFs, percutaneous vertebroplasty (PVP) involves inserting a needle under radiation control and injecting bone cement into the fractured vertebra, and this procedure has been widely used due to its good therapeutic efficacy^[4]. Even so, several studies^[5-7] have reported the recollapse of cemented vertebrae during follow-up with no additional trauma, leading to a decrease in vertebral height and aggravation of kyphosis. Recollapse is regarded as an insufficiency fracture of the treated vertebra, which can be assessed through medical history, clinical symptoms, and imaging findings. When the treated patient reappears with intractable back pain or neurological symptoms, combined with severe kyphosis in imaging finding, it should be required further treatments after excluding new injuries. Hence, we need to determine the predictive risk factors for the recollapse of cemented vertebrae after PVP in OVCFs.

In recent decades, many risk factors for the recollapse of cemented vertebrae have been reported in previous studies, and they can be summarized in three categories. The first is the physical condition of patients, which includes risk factors such as lumbar bone mineral density (BMD), body mass index (BMI), gender, and old age. The second is the classification of differences in the effects of trauma on individuals, which

includes the local kyphotic angle, location of the fractured vertebra, occurrence of an intravertebral cleft (IVC), and fracture type. The third category represents risk factors related to the PVP procedure, such as the injected cement volume, the cement distribution pattern, intradiscal cement leakage, and vertebral height restoration (VHR). However, high-quality and large-scale studies concerning these risk factors are scarce. Most studies lacked sufficient sample sizes and did not evaluate each potential risk factor systematically.

As far as we could see from the literature, the predictive risk factors vary across studies, and no consensus on this problem has been reached. Based on this, a meta-analysis was conducted to pool all relevant published data for the first time to identify risk factors that might lead to the recollapse of cemented vertebrae after PVP.

MATERIALS AND METHODS

Search strategy

We searched electronic databases including the CENTRAL (Cochrane Central Register of Controlled Trials), MEDLINE, Excerpta Medica (EMBASE), and National Library of Medicine (PubMed) for original articles published up to March 2020. Medical subject heading terms ["vertebroplasty" (MeSH)] combined with the following free words were selected to perform searches using Boolean operators: "Percutaneous vertebroplasty", "PVP", "recollapse", "recompression", "refracture", "recurrent fracture", "subsequent fracture", "height loss", "height decrease", "cemented vertebrae", "augmented vertebrae", "treated vertebrae", and "same vertebrae". Additionally, the citation lists of the retrieved articles and recent reviews were scanned to identify additional relevant studies. There were no limitations imposed regarding the language of the included articles.

Eligibility criteria

Studies were considered eligible for this meta-analysis if they met the following criteria: (1) Randomized controlled trials (RCTs) or cohort, cross-sectional, and case-control studies; (2) adult patients with a diagnosis of OVCF; (3) studies that must investigate risk factors for the recollapse of cemented vertebrae after PVP without additional trauma; (4) completion of at least 12 mo of follow-up; and (5) sufficient published data to estimate a standardized mean difference (SMD) or odds ratio (OR) with a 95% confidence interval (CI).

The exclusion criteria were as follows: (1) Case reports, letters, reviews, editorials, abstracts, or meeting proceedings; (2) studies without a clear description of the design; (3) studies lacking comparable results; and (4) repeated reports of previous studies.

Study selection and data extraction

The titles and abstracts of studies that were initially screened out were evaluated by two independent investigators (Ma YH and Zhu YH). After omitting the obviously unrelated studies, the full-texts of the potentially eligible studies were searched for final inclusion. Then, two investigators (Ma YH and Zhu YH) independently read the full-texts and extracted the available data from each study for analysis. The extracted data from all eligible studies included characteristics of the study (author, study design, year of publication, country of origin, study period, and all included variables) and demographics of the patients (sample size, mean age, gender ratio, incidence of recollapse, and follow-up duration). Data that could not be acquired directly from the texts were recalculated. Any disagreement was solved through discussion between two investigators (Ma YH and Zhu YH). If no consensus was reached, a senior author (Zhu QS) was consulted for a final decision.

Assessment of methodological quality

The methodological quality of the included studies was independently assessed by two investigators (Ma YH and Zhu YH) according to the Newcastle-Ottawa Scale (NOS)^[8]. This scale concerning object selection, comparability, and exposure objectively evaluates the risk of bias. The maximum score of the scale is 9, and studies with a score ≥ 7 were considered high quality. Disagreements were resolved through consultation and discussion with a senior author (Zhu QS).

Statistical analysis

The software Review Manager Version 5.3 (The Cochrane Collaboration, Oxford,

United Kingdom) was used for all statistical analyses. Pooling of the data was only conducted when at least three studies reported on the outcome of interest. We calculated SMDs for continuous variables and ORs for dichotomous variables, both with a 95%CI. Heterogeneity across studies was evaluated by chi-squared tests and I^2 -squared (I^2) statistics. If the P value was < 0.1 and the I^2 value was $> 50\%$, the heterogeneity among studies was considered significant. When heterogeneity obviously existed, a random-effect model was used to calculate pooled ORs or SMDs^[9]; otherwise, a fixed-effect model was applied. All results are summarized graphically using a forest plot. Since the number of included studies was less than 10, publication bias was not analyzed in this meta-analysis^[10].

The statistical methods of this study were reviewed by Kou CG from the Department of Health Statistics, School of Public Health, Jilin University.

RESULTS

Study selection process

As shown in [Figure 1](#), the database search of CENTRAL, MEDLINE, EMBASE, and PubMed yielded 158 studies, and another five studies were identified from the reference lists of previous reviews. A total of 82 studies remained after eliminating duplicates. Of these, 30 were discarded during the title and abstract review. A total of 43 studies were abandoned after reviewing the full-texts for the following reasons: The treatment in 19 studies included both percutaneous kyphoplasty (PKP) and PVP; 21 studies provided no outcomes of interest; and three studies lacked sufficient data. Ultimately, a total of nine studies^[11-19] were included in the final meta-analysis.

Study characteristics and methodological quality

The basic characteristics of the nine studies^[11-19] are presented in [Table 1](#). All selected studies were case-control studies published between 2008 and 2018, and no RCTs were published on this subject. Of these studies, three were conducted in China^[17-19], three in Taiwan^[11,13,15], and three in Korea^[12,14,16]. The sample sizes ranged from 44 to 1800, and together, the studies included a total of 2974 patients. Recollapse of cemented vertebrae after PVP occurred in 300 cases, and did not occur in 2674 cases. The recollapse rate in each study ranged from 0.6% to 63.3% and the pooled incidence was 10.1%. The mean follow-up duration for each study was no less than 12 mo. Additional details are shown in [Table 1](#). Numerous potential risk factors were evaluated in the included studies; however, we only selected the risk factors reported in at least three studies. The potential risk factors for recollapse involved in all included studies are depicted in [Table 2](#).

For the nine case-control studies, methodological quality was assessed in accordance with the NOS. Among them, one single study had a score of 9 points^[13], six studies had a score of 8 points^[11,12,15,17-19], and two studies had a score of 7 points^[14,16]. Therefore, all included studies could be regarded as relatively high quality, and the scoring results are listed in [Table 1](#).

Risk factors involving the physical condition of patients

Three eligible factors concerning the physical condition of patients were selected for meta-analysis. Of these, age was evaluated as a predictive risk factor for the recollapse of cemented vertebrae after PVP in seven studies^[11-14,17-19] containing 1130 patients. A fixed-effect model was used due to the heterogeneity test ($\chi^2 = 4.00$; $P = 0.68$; $I^2 = 0\%$). The results of age exhibited no significant differences between the recollapse group and the well-maintained group (SMD = 0.05; 95%CI: -0.10 to 0.20; $P = 0.52$) ([Figure 2A](#)). All the nine studies^[11-19] assessed the potential effect of gender (female). Because of the low heterogeneity among the included studies, a fixed-effect model was utilized ($\chi^2 = 8.28$; $P = 0.41$; $I^2 = 3\%$). The difference in gender did not reach statistical significance (OR = 0.88; 95%CI: 0.61 to 1.28; $P = 0.51$) ([Figure 2B](#)). A total of five studies^[12,14,17-19] containing 951 patients recorded comparable results for lumbar BMD. The test for heterogeneity was significant ($\chi^2 = 8.02$; $P = 0.09$; $I^2 = 50\%$). Using a random-effect model, the aggregated results of the five studies showed that there were no significant differences between them (SMD = -0.23; 95%CI: -0.49 to 0.03; $P = 0.09$) ([Figure 2C](#)).

Risk factors involving differences in the effects of trauma on individuals

Three eligible factors concerning this aspect were selected for meta-analysis. With respect to the location of the fractured vertebra, five studies^[11,13-15,19] consisting of 2191

Table 1 Basic characteristics of the included studies

Ref.	Publication year	Country	Study period	Design	Sample size (case/control)	Incidence of recollapse (%)	Mean age (yr)	Sex (M:F)	Mean follow-up (mo)	NOS score
Lin <i>et al</i> ^[11]	2008	Taiwan, China	2001-2005	Case-control study	98 (62/36)	63.3	72.6	8:90	26.9	8
Heo <i>et al</i> ^[12]	2009	Korea	2002-2006	Case-control study	343 (11/332)	3.2	68.06	82:261	12	8
Lin <i>et al</i> ^[13]	2010	Taiwan, China	2004-2007	Case-control study	81 (46/35)	56.8	74.3	16:73	23.0	9
Kang <i>et al</i> ^[14]	2011	Korea	2008-2010	Case-control study	60 (20/40)	33.3	70	10:50	12	7
Chen <i>et al</i> ^[15]	2011	Taiwan, China	2001-2008	Case-control study	1800 (10/1790)	0.6	77.7	323:1477	24	8
Oh <i>et al</i> ^[16]	2016	Korea	2012-2013	Case-control study	44 (22/22)	50	76.1	26:18	16.5	7
Zhang <i>et al</i> ^[17]	2017	China	2008-2013	Case-control study	172 (50/122)	29.1	88.65	88:84	≥ 12	8
He <i>et al</i> ^[18]	2018	China	2012-2015	Case-control study	224 (37/187)	16.5	71.9	39:185	16.5	8
Yu <i>et al</i> ^[19]	2019	China	2011-2014	Case-control study	152 (42/110)	27.6	70.22	15:137	≥ 24	8

NOS: Newcastle-Ottawa Scale.

patients were pooled for this outcome by a fixed-effect model due to low heterogeneity ($\chi^2 = 3.56$; $P = 0.47$; $I^2 = 0\%$). The pooled results suggested that OVCFs located at the thoracolumbar junction (T10-L2) were associated with a significant increase in the incidence of the recollapse of cemented vertebrae after PVP (OR = 2.09; 95%CI: 1.30 to 3.38; $P = 0.002$) (Figure 2D). Five studies^[11,13,14,16,19] consisting of 435 patients investigated the association between preoperative IVC and the risk of recollapse after PVP. A fixed-effect model was adopted as the studies had low heterogeneity ($\chi^2 = 2.41$; $P = 0.66$; $I^2 = 0\%$). The aggregated results demonstrated a statistically significant difference between the two groups (OR = 2.97; 95%CI: 1.93 to 4.57; $P < 0.00001$) (Figure 2E). Data on preoperative visual analogue scale scores were available for analysis from three studies containing 436 patients^[14,18,19], and the studies were considered heterogeneous ($\chi^2 = 6.21$; $P = 0.04$; $I^2 = 68\%$). Therefore, a random-effect model was applied to evaluate the effect. However, the results showed no significant differences between the recollapse group and the well-maintained group (SMD = 0.14; 95%CI: -0.27 to 0.56; $P = 0.50$) (Figure 2F).

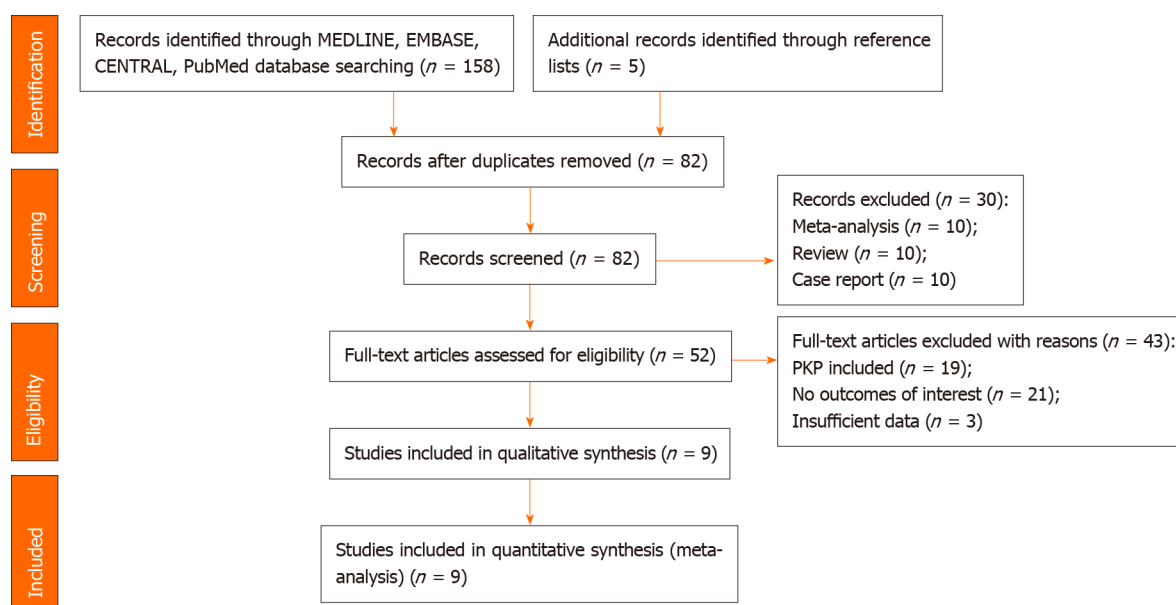
Risk factors involving the PVP procedure

Four eligible factors related to the PVP procedure were selected for meta-analysis. A total of seven^[11-14,17-19] out of nine studies containing 1130 patients were pooled to analyze the effect of injected cement volume. The heterogeneity among the studies was high, so a random-effect model was used ($\chi^2 = 19.01$; $P = 0.004$; $I^2 = 68\%$). The results demonstrated that the injected cement volume was not associated with the recollapse of cemented vertebrae (SMD = 0.11; 95%CI: -0.18 to 0.39; $P = 0.46$) (Figure 2G). In a total of six studies^[13-17,19] containing 2309 patients, the data of intradiscal cement leakage were evaluated. A fixed-effect model was employed because of the low heterogeneity ($\chi^2 = 3.65$; $P = 0.60$; $I^2 = 0\%$). Consequently, intradiscal cement leakage was not significantly different between the two groups (OR = 1.25; 95%CI: 0.76 to 2.05; $P = 0.37$) (Figure 2H). Regarding the cement distribution pattern, the data of 2236

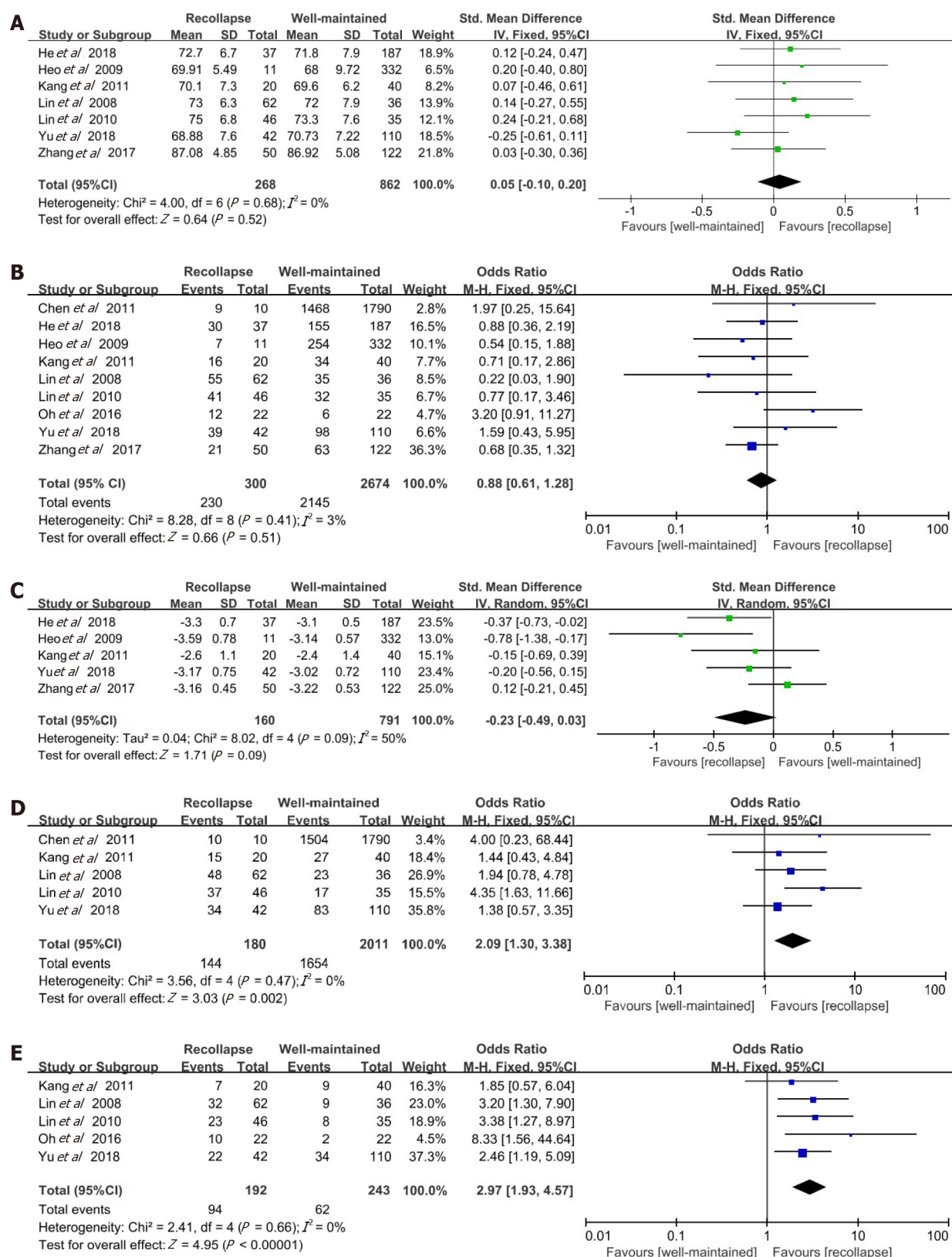
Table 2 Summary of potential risk factors for recollapse involved in all included studies

Ref.	Publication year	Predictive factor
Lin <i>et al</i> ^[11]	2008	Age, gender, body weight and height, lumbar BMD, location of fractured vertebrae, gas-containing vertebrae, pedicle approach, cement volume, VHR
Heo <i>et al</i> ^[12]	2009	Age, gender, lumbar BMD, cement volume, vertebrae with osteonecrosis, vertebral compression rate, location of fractured vertebrae, VHR, chemotherapy history, trauma history, medical history
Lin <i>et al</i> ^[13]	2010	Age, gender, body weight and height, lumbar BMD, location of fractured vertebrae, gas-containing vertebrae, fracture type, cement volume, cement leakage, signal intensity of fractured vertebrae on magnetic resonance imaging, volume ratio of fractured vertebrae
Kang <i>et al</i> ^[14]	2011	Age, gender, body weight and height, BMI, lumbar BMD, preoperative VAS score, gas-containing vertebrae, location of fractured vertebrae, preoperative LKA, Cobb angle, sagittal index, cement volume, cement leakage, cement distribution pattern, height of vertebral body
Chen <i>et al</i> ^[15]	2011	Age, gender, cement volume, location of fractured vertebrae, vertebrae with osteonecrosis, pedicle approach, cement leakage, cement distribution pattern, VHR, LKA correction
Oh <i>et al</i> ^[16]	2016	Age, gender, lumbar BMD, BMI, location of fractured vertebrae, cement volume, cement leakage, preoperative IVC
Zhang <i>et al</i> ^[17]	2017	Age, gender, lumbar BMD, cement volume, cement leakage, duration of symptoms, vertebral compression rate, VHR, dispersion of bone cement
He <i>et al</i> ^[18]	2018	Age, gender, weight and height of body, BMI, lumbar BMD, LKA correction, VHR, cement volume, pedicle approach, preoperative VAS score, cement distribution pattern
Yu <i>et al</i> ^[19]	2019	Age, gender, lumbar BMD, location of fractured vertebrae, preoperative IVC, fracture type, cement volume, cement leakage, cement distribution pattern, VHR, reduction angle, preoperative and postoperative VAS score

BMD: Bone mineral density; VHR: Vertebral height restoration; BMI: Body mass index; LKA: Local kyphotic angle; IVC: Intravertebral cleft; VAS: Visual Analogue Scale.

**Figure 1** Flow diagram of literature search. PKP: Percutaneous kyphoplasty.

patients from four studies^[14,15,18,19] were pooled in the analysis. A fixed-effect model was adopted as the heterogeneity among the included studies was relatively low ($\chi^2 = 3.52$; $P = 0.32$; $I^2 = 15\%$). The solid lump distribution pattern of the cement was associated with an increase in the risk of recollapse of cemented vertebrae (OR = 3.11; 95%CI: 1.91 to 5.07; $P < 0.00001$) (Figure 2I). Four studies^[11,12,17,19] consisting of 765 patients estimated the risk factor of VHR. Pooling these studies using a random-effect model showed that no significant differences were found between the two groups (SMD = 0.58; 95%CI: -0.21 to 1.37; $P = 0.15$), with high heterogeneity ($\chi^2 = 44.53$; $P < 0.00001$; $I^2 = 93\%$) (Figure 2J).



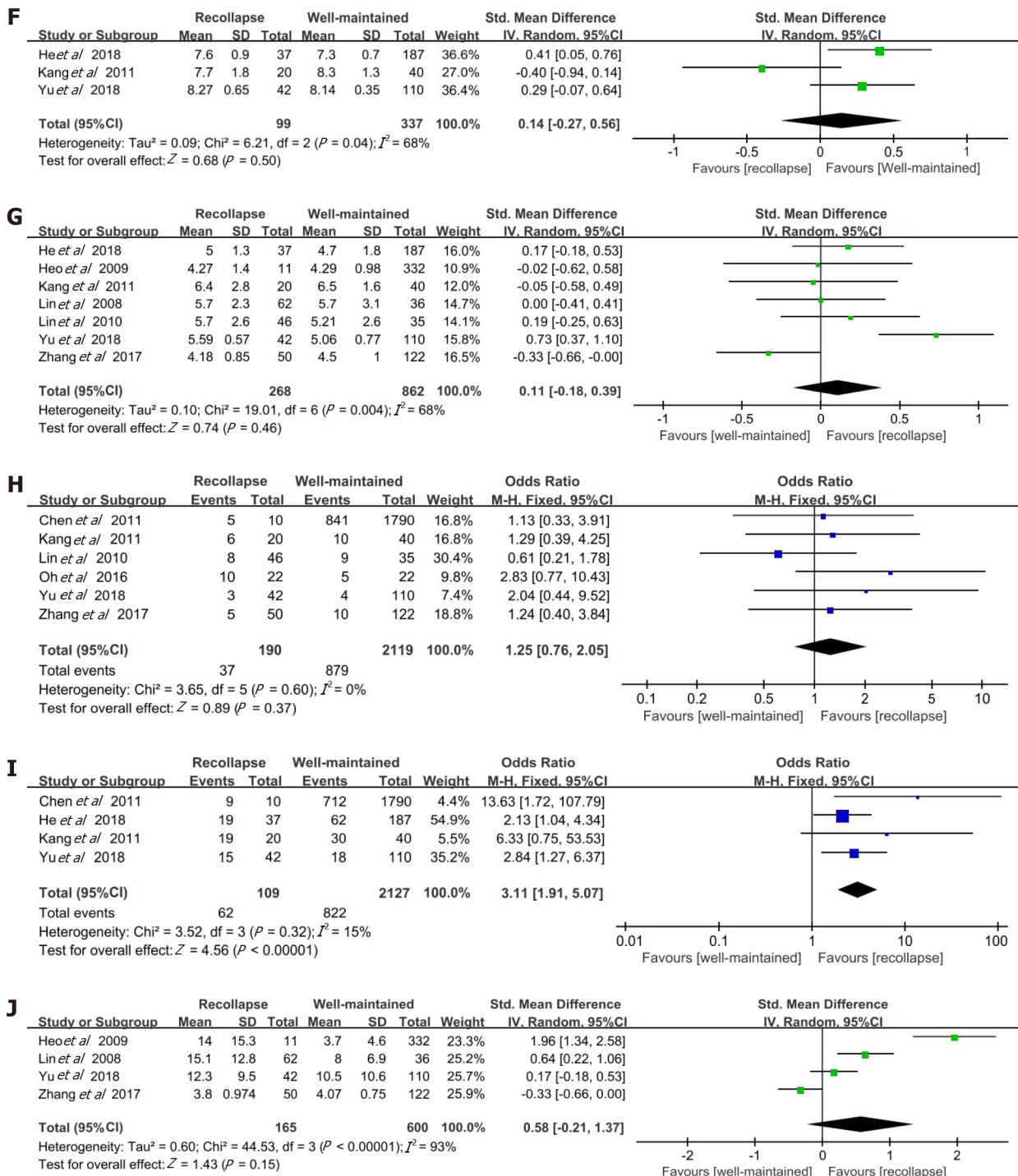


Figure 2 Forest plots of meta-analysis for age, gender (female), lumbar bone mineral density, fractures located at the thoracolumbar junction, preoperative intravertebral cleft, preoperative visual analogue scale scores, injected cement volume, intradiscal cement leakage, cement distribution pattern, and vertebral height restoration. A: Age; B: Gender (female); C: Lumbar bone mineral density; D: Fractures located at the thoracolumbar junction; E: Preoperative intravertebral cleft; F: Preoperative visual analogue scale scores; G: Injected cement volume; H: Intradiscal cement leakage; I: Cement distribution pattern; J: Vertebral height restoration. CI: Confidence interval; SD: Standard deviation.

DISCUSSION

In 1997, Jensen *et al*^[20] first proposed that PVP was a valuable tool in the treatment of painful OVCs, as it provided acute pain relief and early mobilization. As the safety and efficacy of PVP were gradually recognized by spine surgeons, this treatment was widely used in clinical practice. Recently, an increasing number of cases with the recollapse of cemented vertebrae after PVP without additional trauma have been reported^[21,22]. This recollapse is considered a further insufficiency fracture that results in more severe symptoms, deserving our attention. According to our literature review,

this is the first meta-analysis covering all relevant studies in a search of the risk factors for the recollapse of cemented vertebrae after PVP in the treatment of OVCFs. A previous meta-analysis^[6] evaluated risk factors for the recollapse of augmented vertebrae after percutaneous vertebral augmentation including PVP and PKP. Besides the three risk factors identified through our analysis including fractures located at the thoracolumbar junction (T10-L2), preoperative IVC, and solid lump distribution pattern of the cement, higher VHR and preoperative severe kyphosis were also considered to associate with the cemented vertebra recollapse in the previous work. Reasons for the differences were due to the details of the two techniques. PKP with balloon may better restore the height of fractured vertebrae but at the cost of partially destroying cancellous bones. In PVP, the bone cement penetrates evenly throughout the remaining trabeculae, which makes the stress distribution of the cemented vertebrae more balanced. This interlocking between trabeculae and cement is effective in restoring vertebral stability, but not as significant for vertebral height as PKP. On the other hand, preoperative severe kyphosis is usually accompanied by significant height loss of vertebral body, however, this condition may not be a standard indication for PVP^[23]. Therefore, it is more appropriate to explore the risk factors associated with PVP separately.

It is well known that flexion and extension of the spine are greatest at the thoracolumbar junction^[24]. Relatively high mobility means a greater chance of injury. Moreover, early after PVP, higher mobility may lead to poor vertebral healing. An unhealed fracture appearing as an intravertebral cleft has been reported to occur frequently in thoracolumbar fractures^[25,26]. Additionally, the thoracolumbar junction is a transition area where the spine changes from thoracic kyphotic curve to lumbar lordotic curve^[27]. This region bears great load when it is subjected to external force from different directions. In addition, PVP can only fill the fractured vertebra with bone cement but has little expansion effect on the compressed vertebral body. This treatment is thought to preserve local deformity to some extent. Due to the special morphology of the thoracolumbar junction, the center of gravity passes only in front of the anterior half of the vertebral body. Thus, persistent uncompensated sagittal imbalance is deemed a true risk factor for progressive collapse after PVP^[28]. A retrospective study^[29] in 2014 demonstrated that the thoracolumbar junction was the most frequent region undergoing delayed vertebral collapse after PVP. All of these findings may explain the high incidence of recollapse at the thoracolumbar junction.

We also found that the recollapse of cemented vertebrae could be attributed to the presence of preoperative IVC, which was considered a sign of intravertebral instability^[30]. The formation of IVC may be related to partial avascular necrosis in the vertebral body and is significantly associated with the anatomical characteristics of blood supply. In addition to the paired segmental arteries that correspond to a vertebra, the dorsum of the vertebral body can be supplied by collateral blood flow, while the ventral part could not^[31]. However, the most frequently damaged portion in OVCFs is the ventral part of the vertebral body. When segmental arteries are impaired, a cleft presenting with a “vacuum” sign on plain radiography develops in the vertebral body due to ischemia. In particular, osteoporotic vertebrae accompanied by severe demineralization may be more susceptible to developing posttraumatic IVCs due to poor blood supply and pre-existing microfractures. These clefts are similar to pseudarthrosis and are connected by fibrocartilaginous tissue with significant motion^[32], which indicates instability within the fracture. The dynamic mobility of vertebrae with IVC can be evaluated by flexion and extension radiographs or supine cross-lateral radiographs^[33]. Even after PVP, persistent IVCs as weak regions of the vertebral body might further lead to the progressive collapse of cemented vertebrae. One study by Fang *et al.*^[34] reported that a high incidence of recollapse could be observed in treated vertebrae with IVC through at least 2 years of follow-up. Similarly, it was suggested that the presence of preoperative IVC, whether with PVP or PKP, was considered high risk for the recollapse of cemented vertebrae^[6].

In addition, a solid lump distribution pattern of the cement was also shown to be a predictive risk factor for the recollapse of cemented vertebrae after PVP. It has been reported^[18] that the distribution patterns of cement injected into fractured vertebrae are mainly divided into two types: Solid lump and trabecular. As bone cement is directly injected into the vertebral body, the optimum status is that cement interdigitates throughout the fractured vertebrae so that the loads are transferred through the cement column exactly between the vertebral endplates^[35]. However, this condition may not be guaranteed for some objective and operational reasons. For example, when injecting bone cement into the osteonecrosis region in osteoporotic vertebrae, a lump-shaped distribution will result after cement solidification^[15], where the stiffness of the cemented vertebrae is lower than that in a trabecular cement distribution pattern. The

solid lump cement in vertebrae made surrounding non-cemented cancellous bones without load transfer, acting as a stress-shielding effect similar to PKP^[36]. The trabecular structure of this stress-shielded area can be destroyed by a round mass congregation of bone cement in daily activities. Due to the osteoporotic nature of vertebrae, a vicious cycle forms to induce recollapse. Differently, the trabecular pattern allows the vertebral body to withstand external forces more evenly, avoiding the stress-shielding effect. Moreover, the interlocking between bone cement and cancellous bone is weakened in the solid lump distribution pattern^[18], which leads to insufficient mechanical strength of the vertebral body. Consistent with our findings, Yang *et al.*^[37] concluded that lump-shaped cement distribution increased the incidence of recollapse of cemented vertebrae after PVP.

The recollapse of cemented vertebrae may lead to recurrent intractable back pain with no response to conservative treatment, which results from changes in loads over the facet joints along with progressive collapse. This situation seriously affects the quality of life of patients, resulting in certain psychological and physical burden. Not only that, the treatment of vertebral recollapse after PVP seems to be troublesome, which may require repeated PVP or revision surgery depending on the situation^[29,38-40]. Thus, if predictive risk factors for recollapse are identified preoperatively, surgical fixation and restoration can be used as the initial treatment option for patients whose physical conditions permit. Furthermore, if patients have undergone PVP with the presence of these conditions, surgeons should take the potential risk of recollapse seriously. Regardless of the surgical techniques, regular postoperative follow-up and systematic treatment of osteoporosis are necessary. Once diagnosed, further treatment should be provided by experienced surgeons timely to avoid more serious consequences.

Nevertheless, certain limitations cannot be ignored in this meta-analysis. First, the subjects in these nine studies were Asian, and we thus could not predict whether the results are applicable to patients from other regions. Second, the incidence of recollapse in the included studies might have been affected by the different follow-up periods, which were considered heterogeneous among the studies. Third, some other potential risk factors, such as BMI, steroid usage, vertebral compression rate, and pedicle approach (unilateral or bilateral), were not included in this meta-analysis because of insufficient published data. Finally, the formation of recollapse might result from the interaction of multiple factors; however, the results from the univariate analysis were not able to reveal the effect of an interaction.

CONCLUSION

This meta-analysis suggests that three risk factors, including fractures located at the thoracolumbar junction (T10-L2), preoperative IVC, and solid lump distribution pattern of the cement, are associated with the recollapse of cemented vertebrae after PVP. To the best of our knowledge, this is the first meta-analysis to explore the predictive risk factors for recollapse by synthesizing the available information, and the results will assist surgeons in identifying risk factors both preoperatively and intraoperatively. When treating patients with these conditions, a more comprehensive treatment plan should be developed; moreover, regular and detailed follow-up is necessary for surgeons to detect PVP failure in a timely manner. Prospective multicenter studies with large cohorts should be encouraged to evaluate these results further as well as to clarify the unexplored factors.

ARTICLE HIGHLIGHTS

Research background

Osteoporotic vertebral compression fracture (OVCF) is one of the most common complications of osteoporosis. As a minimally invasive technique for treating OVCFs, percutaneous vertebroplasty (PVP) has been widely used due to its good therapeutic efficacy and safety. However, there have been reports of the cemented vertebra recollapse after PVP, which deserves our attention.

Research motivation

To the best of our knowledge, studies with high-quality and large-scale exploring these risk factors are scarce. The predictive risk factors associated with the recollapse

of cemented vertebrae after PVP in OVCFs remain controversial.

Research objectives

We performed this meta-analysis pooling all relevant published data to identify risk factors that might lead to the cemented vertebra recollapse after PVP in OVCFs.

Research methods

A systematic search in EMBASE, MEDLINE, the Cochrane Library, and PubMed was conducted for original articles published up to March 2020. Ten independent variables (age, gender, lumbar bone mineral density, location of the fractured vertebra, preoperative intravertebral cleft, preoperative visual analogue scale score, injected cement volume, intradiscal cement leakage, cement distribution pattern, and vertebral height restoration) were extracted for assessment from the included studies. Review Manager 5.3 was applied for calculating odds ratios (ORs) or standardized mean differences with 95% confidence interval (CI), as well as assessing the heterogeneity by both the chi-squared test and the *I*-squared test.

Research results

A total of nine case-control studies published between 2008 and 2018 were included in our meta-analysis comprising 300 cases and 2674 controls. The significant risk factors for the recollapse of cemented vertebrae after PVP in OVCFs were fractures located at the thoracolumbar junction (OR = 2.09; 95%CI: 1.30 to 3.38; *P* = 0.002), preoperative intravertebral cleft (OR = 2.97; 95%CI: 1.93 to 4.57; *P* < 0.00001), and solid lump distribution pattern of the cement (OR = 3.11; 95%CI: 1.91 to 5.07; *P* < 0.00001). Furthermore, there was no significant correlation between age, gender, lumbar bone mineral density, preoperative visual analogue scale score, injected cement volume, intradiscal cement leakage, or vertebral height restoration and the cemented vertebra recollapse.

Research conclusions

This meta-analysis supports that three risk factors, including fractures located at the thoracolumbar junction (T10-L2), preoperative IVC, and solid lump distribution pattern of the cement, are associated with the recollapse of cemented vertebrae after PVP in OVCFs.

Research perspectives

This is the first meta-analysis pooling all relevant published data to identify risk factors that may lead to the recollapse of cemented vertebrae after PVP in OVCFs. These findings through analysis can provide valuable information for current clinical work. Also, some other potential risk factors, such as body mass index, steroid usage, vertebral compression rate, and pedicle approach (unilateral or bilateral), need to be evaluated in the future.

ACKNOWLEDGEMENTS

The authors are grateful to Professor Kou CG from the Department of Health Statistics, School of Public Health, Jilin University for his kind help in reviewing the statistical methods and procedures in this meta-analysis.

REFERENCES

- 1 **Chen H**, Kubo KY. Bone three-dimensional microstructural features of the common osteoporotic fracture sites. *World J Orthop* 2014; **5**: 486-495 [PMID: 25232524 DOI: 10.5312/wjo.v5.i4.486]
- 2 **Vandenbroucke A**, Luyten FP, Flamaing J, Gielen E. Pharmacological treatment of osteoporosis in the oldest old. *Clin Interv Aging* 2017; **12**: 1065-1077 [PMID: 28740372 DOI: 10.2147/CIA.S131023]
- 3 **Agarwal R**, García AJ. Biomaterial strategies for engineering implants for enhanced osseointegration and bone repair. *Adv Drug Deliv Rev* 2015; **94**: 53-62 [PMID: 25861724 DOI: 10.1016/j.addr.2015.03.013]
- 4 **Buchbinder R**, Johnston RV, Rischin KJ, Homik J, Jones CA, Golmohammadi K, Kallmes DF. Percutaneous vertebroplasty for osteoporotic vertebral compression fracture. *Cochrane Database Syst Rev* 2018; **4**: CD006349 [PMID: 29618171 DOI: 10.1002/14651858.CD006349.pub3]

- 5 **Li YX**, Guo DQ, Zhang SC, Liang, Yuan K, Mo GY, Li DX, Guo HZ, Tang Y, Luo PJ. Risk factor analysis for re-collapse of cemented vertebrae after percutaneous vertebroplasty (PVP) or percutaneous kyphoplasty (PKP). *Int Orthop* 2018; **42**: 2131-2139 [PMID: [29464371](#) DOI: [10.1007/s00264-018-3838-6](#)]
- 6 **Yu W**, Xu W, Jiang X, Liang, Jian W. Risk Factors for Recollapse of the Augmented Vertebrae After Percutaneous Vertebral Augmentation: A Systematic Review and Meta-Analysis. *World Neurosurg* 2018; **111**: 119-129 [PMID: [29253703](#) DOI: [10.1016/j.wneu.2017.12.019](#)]
- 7 **Gaughen JR Jr**, Jensen ME, Schweickert PA, Marx WF, Kallmes DF. The therapeutic benefit of repeat percutaneous vertebroplasty at previously treated vertebral levels. *AJNR Am J Neuroradiol* 2002; **23**: 1657-1661 [PMID: [12427618](#)]
- 8 **Stang A**. Critical evaluation of the Newcastle-Ottawa scale for the assessment of the quality of nonrandomized studies in meta-analyses. *Eur J Epidemiol* 2010; **25**: 603-605 [PMID: [20652370](#) DOI: [10.1007/s10654-010-9491-z](#)]
- 9 **Lau J**, Ioannidis JP, Schmid CH. Quantitative synthesis in systematic reviews. *Ann Intern Med* 1997; **127**: 820-826 [PMID: [9382404](#) DOI: [10.7326/0003-4819-127-9-199711010-00008](#)]
- 10 **Lau J**, Ioannidis JP, Terrin N, Schmid CH, Olkin I. The case of the misleading funnel plot. *BMJ* 2006; **333**: 597-600 [PMID: [16974018](#) DOI: [10.1136/bmj.333.7568.597](#)]
- 11 **Lin WC**, Lee YC, Lee CH, Kuo YL, Cheng YF, Lui CC, Cheng TT. Refractures in cemented vertebrae after percutaneous vertebroplasty: a retrospective analysis. *Eur Spine J* 2008; **17**: 592-599 [PMID: [18204942](#) DOI: [10.1007/s00586-007-0564-y](#)]
- 12 **Heo DH**, Chin DK, Yoon YS, Kuh SU. Recollapse of previous vertebral compression fracture after percutaneous vertebroplasty. *Osteoporos Int* 2009; **20**: 473-480 [PMID: [18636218](#) DOI: [10.1007/s00198-008-0682-3](#)]
- 13 **Lin WC**, Lu CH, Chen HL, Wang HC, Yu CY, Wu RW, Cheng YF, Lui CC. The impact of preoperative magnetic resonance images on outcome of cemented vertebrae. *Eur Spine J* 2010; **19**: 1899-1906 [PMID: [20607571](#) DOI: [10.1007/s00586-010-1434-6](#)]
- 14 **Kang SK**, Lee CW, Park NK, Kang TW, Lim JW, Cha KY, Kim JH. Predictive risk factors for refracture after percutaneous vertebroplasty. *Ann Rehabil Med* 2011; **35**: 844-851 [PMID: [22506213](#) DOI: [10.5535/arm.2011.35.6.844](#)]
- 15 **Chen LH**, Hsieh MK, Liao JC, Lai PL, Niu CC, Fu TS, Tsai TT, Chen WJ. Repeated percutaneous vertebroplasty for refracture of cemented vertebrae. *Arch Orthop Trauma Surg* 2011; **131**: 927-933 [PMID: [21191607](#) DOI: [10.1007/s00402-010-1236-7](#)]
- 16 **Oh HS**, Kim TW, Kim HG, Park KH. Gradual Height Decrease of Augmented Vertebrae after Vertebroplasty at the Thoracolumbar Junction. *Korean J Neurotrauma* 2016; **12**: 18-21 [PMID: [27182497](#) DOI: [10.13004/kjnt.2016.12.1.18](#)]
- 17 **Zhang L**, Wang Q, Wang L, Shen J, Zhang Q, Sun C. Bone cement distribution in the vertebral body affects chances of recompression after percutaneous vertebroplasty treatment in elderly patients with osteoporotic vertebral compression fractures. *Clin Interv Aging* 2017; **12**: 431-436 [PMID: [28260871](#) DOI: [10.2147/CIA.S113240](#)]
- 18 **He D**, Lou C, Yu W, Zhu K, Wu Z, Liu F, Chen M, Zheng L, Chen Z, Fan S. Cement Distribution Patterns Are Associated with Recompression in Cemented Vertebrae After Percutaneous Vertebroplasty: A Retrospective Study. *World Neurosurg* 2018; **120**: e1-e7 [PMID: [29945011](#) DOI: [10.1016/j.wneu.2018.06.113](#)]
- 19 **Yu WB**, Jiang XB, Liang D, Xu WX, Ye LQ, Wang J. Risk factors and score for recollapse of the augmented vertebrae after percutaneous vertebroplasty in osteoporotic vertebral compression fractures. *Osteoporos Int* 2019; **30**: 423-430 [PMID: [30368576](#) DOI: [10.1007/s00198-018-4754-8](#)]
- 20 **Jensen ME**, Evans AJ, Mathis JM, Kallmes DF, Cloft HJ, Dion JE. Percutaneous polymethylmethacrylate vertebroplasty in the treatment of osteoporotic vertebral body compression fractures: technical aspects. *AJNR Am J Neuroradiol* 1997; **18**: 1897-1904 [PMID: [9403451](#)]
- 21 **Nagoshi N**, Fukuda K, Shioda M, Machida M. Anterior spinal fixation for recollapse of cemented vertebrae after percutaneous vertebroplasty. *BMJ Case Rep* 2016; **2016** [PMID: [26994051](#) DOI: [10.1136/bcr-2016-214510](#)]
- 22 **Choi SS**, Hur WS, Lee JJ, Oh SK, Lee MK. Repeat vertebroplasty for the subsequent refracture of procedured vertebra. *Korean J Pain* 2013; **26**: 94-97 [PMID: [23342217](#) DOI: [10.3344/kjp.2013.26.1.94](#)]
- 23 **Navarro-Navarro R**, Fernández-Varela T, Montesdeoca-Ara A, Lorenzo-Rivero JA. Outcomes of vertebroplasty in osteoporotic vertebral fractures with limited indication. *Rev Esp Cir Ortop Traumatol* 2020; **64**: 4-12 [PMID: [31786100](#) DOI: [10.1016/j.recot.2019.09.010](#)]
- 24 **Izzo R**, Guarnieri G, Guglielmi G, Muto M. Biomechanics of the spine. Part I: spinal stability. *Eur J Radiol* 2013; **82**: 118-126 [PMID: [23088879](#) DOI: [10.1016/j.ejrad.2012.07.024](#)]
- 25 **Kim DY**, Lee SH, Jang JS, Chung SK, Lee HY. Intravertebral vacuum phenomenon in osteoporotic compression fracture: report of 67 cases with quantitative evaluation of intravertebral instability. *J Neurosurg* 2004; **100**: 24-31 [PMID: [14748570](#) DOI: [10.3171/spi.2004.100.1.0024](#)]
- 26 **Mirovsky Y**, Anekstein Y, Shalmon E, Peer A. Vacuum clefts of the vertebral bodies. *AJNR Am J Neuroradiol* 2005; **26**: 1634-1640 [PMID: [16091506](#)]
- 27 **Katsuura Y**, Osborn JM, Cason GW. The epidemiology of thoracolumbar trauma: A meta-analysis. *J Orthop* 2016; **13**: 383-388 [PMID: [27504058](#) DOI: [10.1016/j.jor.2016.06.019](#)]
- 28 **Mazel C**, Ajavon L. Malunion of post-traumatic thoracolumbar fractures. *Orthop Traumatol Surg Res* 2018; **104**: S55-S62 [PMID: [29191468](#) DOI: [10.1016/j.otsr.2017.04.018](#)]

- 29 **Chou KN**, Lin BJ, Wu YC, Liu MY, Hueng DY. Progressive kyphosis after vertebroplasty in osteoporotic vertebral compression fracture. *Spine (Phila Pa 1976)* 2014; **39**: 68-73 [PMID: 24108287 DOI: 10.1097/BRS.0000000000000042]
- 30 **Yu W**, Jiang X, Liang, Yao Z, Qiu T, Ye L, Zhang S, Jin D. Intravertebral Vacuum Cleft and Its Varied Locations within Osteoporotic Vertebral Compression Fractures: Effect on Therapeutic Efficacy. *Pain Physician* 2017; **20**: E979-E986 [PMID: 28934802]
- 31 **Kim YC**, Kim YH, Ha KY. Pathomechanism of intravertebral clefts in osteoporotic compression fractures of the spine. *Spine J* 2014; **14**: 659-666 [PMID: 24055039 DOI: 10.1016/j.spinee.2013.06.106]
- 32 **Hasegawa K**, Takahashi HE, Koga Y, Kawashima T, Hara T, Tanabe Y, Tanaka S. Mechanical properties of osteopenic vertebral bodies monitored by acoustic emission. *Bone* 1993; **14**: 737-743 [PMID: 8268048 DOI: 10.1016/8756-3282(93)90205-o]
- 33 **Cho JH**, Shin SI, Lee JH, Yeom JS, Chang BS, Lee CK. Usefulness of prone cross-table lateral radiographs in vertebral compression fractures. *Clin Orthop Surg* 2013; **5**: 195-201 [PMID: 24009905 DOI: 10.4055/cios.2013.5.3.195]
- 34 **Fang X**, Yu F, Fu S, Song H. Intravertebral clefts in osteoporotic compression fractures of the spine: incidence, characteristics, and therapeutic efficacy. *Int J Clin Exp Med* 2015; **8**: 16960-16968 [PMID: 26629251]
- 35 **Kurutz M**, Varga P, Jakab G. Prophylactic vertebroplasty versus kyphoplasty in osteoporosis: A comprehensive biomechanical matched-pair study by in vitro compressive testing. *Med Eng Phys* 2019; **65**: 46-56 [PMID: 30733174 DOI: 10.1016/j.medengphy.2019.01.004]
- 36 **Kim YY**, Rhyu KW. Recompression of vertebral body after balloon kyphoplasty for osteoporotic vertebral compression fracture. *Eur Spine J* 2010; **19**: 1907-1912 [PMID: 20559850 DOI: 10.1007/s00586-010-1479-6]
- 37 **Yang DH**, Cho KH, Chung YS, Kim YR. Effect of vertebroplasty with bone filler device and comparison with balloon kyphoplasty. *Eur Spine J* 2014; **23**: 2718-2725 [PMID: 24875381 DOI: 10.1007/s00586-014-3379-7]
- 38 **Yang SC**, Chen WJ, Yu SW, Tu YK, Kao YH, Chung KC. Revision strategies for complications and failure of vertebroplasties. *Eur Spine J* 2008; **17**: 982-988 [PMID: 18446385 DOI: 10.1007/s00586-008-0680-3]
- 39 **Miyagi R**, Sakai T, Bhatia NN, Sairoyo K, Katoh S, Chikawa T. Anterior thoracolumbar reconstruction surgery for late collapse following vertebroplasty: report of three cases. *J Med Invest* 2011; **58**: 148-153 [PMID: 21372500 DOI: 10.2152/jmi.58.148]
- 40 **Ha KY**, Kim YH, Chang DG, Son IN, Kim KW, Kim SE. Causes of late revision surgery after bone cement augmentation in osteoporotic vertebral compression fractures. *Asian Spine J* 2013; **7**: 294-300 [PMID: 24353846 DOI: 10.4184/asj.2013.7.4.294]



Published by **Baishideng Publishing Group Inc**
7041 Koll Center Parkway, Suite 160, Pleasanton, CA 94566, USA

Telephone: +1-925-3991568

E-mail: bpgoffice@wjgnet.com

Help Desk: <https://www.f6publishing.com/helpdesk>

<https://www.wjgnet.com>

