

World Journal of *Clinical Cases*

World J Clin Cases 2021 April 26; 9(12): 2696-2950



Contents

Thrice Monthly Volume 9 Number 12 April 26, 2021

MINIREVIEWS

- 2696** Standardization of critical care management of non-critically ill patients with COVID-19
Wang CS, Gao Y, Kang K, Fei DS, Meng XL, Liu HT, Luo YP, Yang W, Dai QQ, Gao Y, Zhao MY, Yu KJ
- 2703** Mediastinal lymphadenopathy in COVID-19: A review of literature
Taweasedt PT, Surani S
- 2711** Polycystic ovary syndrome: Pathways and mechanisms for possible increased susceptibility to COVID-19
Ilias I, Goulas S, Zabuliene L

ORIGINAL ARTICLE

Clinical and Translational Research

- 2721** Circulating tumor cells with epithelial-mesenchymal transition markers as potential biomarkers for the diagnosis of lung cancer
Jiang SS, Mao CG, Feng YG, Jiang B, Tao SL, Tan QY, Deng B

Retrospective Study

- 2731** Management and implementation strategies of pre-screening triage in children during coronavirus disease 2019 pandemic in Guangzhou, China
Shi X, Cai YT, Cai X, Wen XL, Wang JY, Ma WC, Shen J, Wu JX, Liu HY, Sun J, He PQ, Lin Y, Zhao DY, Li PQ
- 2739** Clinicopathological features of superficial CD34-positive fibroblastic tumor
Ding L, Xu WJ, Tao XY, Zhang L, Cai ZG
- 2751** Application of a rapid exchange extension catheter technique in type B2/C nonocclusive coronary intervention *via* a transradial approach
Wang HC, Lu W, Gao ZH, Xie YN, Hao J, Liu JM

SYSTEMATIC REVIEWS

- 2763** Paradoxical relationship between proton pump inhibitors and COVID-19: A systematic review and meta-analysis
Zippi M, Fiorino S, Budriesi R, Micucci M, Corazza I, Pica R, de Biase D, Gallo CG, Hong W

META-ANALYSIS

- 2778** Predictive risk factors for recollapse of cemented vertebrae after percutaneous vertebroplasty: A meta-analysis
Ma YH, Tian ZS, Liu HC, Zhang BY, Zhu YH, Meng CY, Liu XJ, Zhu QS

CASE REPORT

- 2791** Malignant pheochromocytoma with cerebral and skull metastasis: A case report and literature review
Chen JC, Zhuang DZ, Luo C, Chen WQ
- 2801** Unresectable esophageal cancer treated with multiple chemotherapies in combination with chemoradiotherapy: A case report
Yura M, Koyanagi K, Hara A, Hayashi K, Tajima Y, Kaneko Y, Fujisaki H, Hirata A, Takano K, Hongo K, Yo K, Yoneyama K, Tamai Y, Dehari R, Nakagawa M
- 2811** Role of positron emission tomography in primary carcinoma ex pleomorphic adenoma of the bronchus: A case report
Yang CH, Liu NT, Huang TW
- 2816** Positive reverse transcription-polymerase chain reaction assay results in patients recovered from COVID-19: Report of two cases
Huang KX, He C, Yang YL, Huang D, Jiang ZX, Li BG, Liu H
- 2823** Laryngeal myxoma: A case report
Yu TT, Yu H, Cui Y, Liu W, Cui XY, Wang X
- 2830** Prostate stromal tumor with prostatic cysts after transurethral resection of the prostate: A case report
Zhao LW, Sun J, Wang YY, Hua RM, Tai SC, Wang K, Fan Y
- 2838** Intramuscular hematoma in rhabdomyolysis patients treated with low-molecular-weight heparin: Report of two cases
Yuan SY, Xie KF, Yang J
- 2845** Partial response to Chinese patent medicine Kangliu pill for adult glioblastoma: A case report and review of the literature
Sun G, Zhuang W, Lin QT, Wang LM, Zhen YH, Xi SY, Lin XL
- 2854** Behcet's disease manifesting as esophageal variceal bleeding: A case report
Xie WX, Jiang HT, Shi GQ, Yang LN, Wang H
- 2862** Successful endoscopic surgery for emphysematous pyelonephritis in a non-diabetic patient with autosomal dominant polycystic kidney disease: A case report
Jiang Y, Lo R, Lu ZQ, Cheng XB, Xiong L, Luo BF
- 2868** Robotically assisted removal of pelvic splenosis fifty-six years after splenectomy: A case report
Tognarelli A, Faggioni L, Erba AP, Faviana P, Durante J, Manassero F, Selli C
- 2874** Pulmonary alveolar proteinosis complicated with nocardiosis: A case report and review of the literature
Wu XK, Lin Q
- 2884** Detection of EGFR-SEPT14 fusion in cell-free DNA of a patient with advanced gastric cancer: A case report
Kim B, Kim Y, Park I, Cho JY, Lee KA

- 2890** Timing of convalescent plasma therapy-tips from curing a 100-year-old COVID-19 patient using convalescent plasma treatment: A case report
Liu B, Ren KK, Wang N, Xu XP, Wu J
- 2899** Torsades de pointes episode in a woman with high-grade fever and inflammatory activation: A case report
Qiu H, Li HW, Zhang SH, Zhou XG, Li WP
- 2908** Salivary duct carcinoma of the submandibular gland presenting a diagnostic challenge: A case report
Uchihashi T, Kodama S, Sugauchi A, Hiraoka S, Hirose K, Usami Y, Tanaka S, Kogo M
- 2916** Allogeneic hematopoietic stem cell transplantation in a 3-year-old boy with congenital pyruvate kinase deficiency: A case report
Ma ZY, Yang X
- 2923** Congenital bilateral cryptorchidism in an infant conceived after maternal breast cancer treatment: A case report
Hu WK, Liu J, Liu RX, Liu XW, Yin CH
- 2930** Sclerosing polycystic adenosis of the submandibular gland: Two case reports
Wu L, Wang Y, Hu CY, Huang CM
- 2937** Budd-Chiari syndrome associated with liver cirrhosis: A case report
Ye QB, Huang QF, Luo YC, Wen YL, Chen ZK, Wei AL
- 2944** Separated root tip formation associated with a fractured tubercle of dens evaginatus: A case report
Wu ZF, Lu LJ, Zheng HY, Tu Y, Shi Y, Zhou ZH, Fang LX, Fu BP

ABOUT COVER

Editorial Board Member of *World Journal of Clinical Cases*, Jing Liu, MD, PhD, Chief Doctor, Professor, Department of Neonatology and NICU, Beijing Chaoyang District Maternal and Child Healthcare Hospital, Beijing 100021, China. liujingbj@live.cn

AIMS AND SCOPE

The primary aim of *World Journal of Clinical Cases* (WJCC, *World J Clin Cases*) is to provide scholars and readers from various fields of clinical medicine with a platform to publish high-quality clinical research articles and communicate their research findings online.

WJCC mainly publishes articles reporting research results and findings obtained in the field of clinical medicine and covering a wide range of topics, including case control studies, retrospective cohort studies, retrospective studies, clinical trials studies, observational studies, prospective studies, randomized controlled trials, randomized clinical trials, systematic reviews, meta-analysis, and case reports.

INDEXING/ABSTRACTING

The WJCC is now indexed in Science Citation Index Expanded (also known as SciSearch®), Journal Citation Reports/Science Edition, Scopus, PubMed, and PubMed Central. The 2020 Edition of Journal Citation Reports® cites the 2019 impact factor (IF) for WJCC as 1.013; IF without journal self cites: 0.991; Ranking: 120 among 165 journals in medicine, general and internal; and Quartile category: Q3. The WJCC's CiteScore for 2019 is 0.3 and Scopus CiteScore rank 2019: General Medicine is 394/529.

RESPONSIBLE EDITORS FOR THIS ISSUE

Production Editor: Ji-Hong Lin; Production Department Director: Xiang Li; Editorial Office Director: Jin-Lai Wang.

NAME OF JOURNAL

World Journal of Clinical Cases

ISSN

ISSN 2307-8960 (online)

LAUNCH DATE

April 16, 2013

FREQUENCY

Thrice Monthly

EDITORS-IN-CHIEF

Dennis A Bloomfield, Sandro Vento, Bao-Gan Peng

EDITORIAL BOARD MEMBERS

<https://www.wjgnet.com/2307-8960/editorialboard.htm>

PUBLICATION DATE

April 26, 2021

COPYRIGHT

© 2021 Baishideng Publishing Group Inc

INSTRUCTIONS TO AUTHORS

<https://www.wjgnet.com/bpg/gerinfo/204>

GUIDELINES FOR ETHICS DOCUMENTS

<https://www.wjgnet.com/bpg/GerInfo/287>

GUIDELINES FOR NON-NATIVE SPEAKERS OF ENGLISH

<https://www.wjgnet.com/bpg/gerinfo/240>

PUBLICATION ETHICS

<https://www.wjgnet.com/bpg/GerInfo/288>

PUBLICATION MISCONDUCT

<https://www.wjgnet.com/bpg/gerinfo/208>

ARTICLE PROCESSING CHARGE

<https://www.wjgnet.com/bpg/gerinfo/242>

STEPS FOR SUBMITTING MANUSCRIPTS

<https://www.wjgnet.com/bpg/GerInfo/239>

ONLINE SUBMISSION

<https://www.f6publishing.com>

Budd-Chiari syndrome associated with liver cirrhosis: A case report

Qiao-Bo Ye, Qin-Feng Huang, Yao-Chang Luo, Yi-Lei Wen, Zi-Kun Chen, Ai-Ling Wei

ORCID number: Qiao-Bo Ye 0000-0003-1751-9397; Qin-Feng Huang 0000-0003-3465-0258; Yao-Chang Luo 0000-0001-9370-0345; Yi-Lei Wen 0000-0002-4078-2460; Zi-Kun Chen 0000-0001-6112-8612; Ai-Ling Wei 0000-0002-8322-3589.

Author contributions: Wei AL conceived and designed the study; Ye QB and Huang QF acquired the data, drafted and edited the manuscript; Luo YC and Wen YL provided technical and material support; Chen ZK analyzed and interpreted the data; all authors read and approved the final version of the manuscript.

Supported by National Natural Science Foundation of China, No. 81760851; and Doctoral Research Start-up Fund of Guangxi University of Chinese Medicine, No. 2019BS035.

Informed consent statement: Informed written consent was obtained from the patient for publication of this report and any accompanying images.

Conflict-of-interest statement: The authors declare that they have no conflicts of interest related to this manuscript.

CARE Checklist (2016) statement: The authors have read the CARE Checklist (2016), and the manuscript was prepared and revised according to the CARE

Qiao-Bo Ye, Basic Medical College, Chengdu University of Traditional Chinese Medicine, Chengdu 611137, Sichuan Province, China

Qin-Feng Huang, Department of Oncology, The First Affiliated Hospital, Guangxi University of Chinese Medicine, Nanning 530023, Guangxi Zhuang Autonomous Region, China

Yao-Chang Luo, Department of Intervention, The First Affiliated Hospital, Guangxi University of Chinese Medicine, Nanning 530023, Guangxi Zhuang Autonomous Region, China

Yi-Lei Wen, Department of Pathology, The First Affiliated Hospital, Guangxi University of Chinese Medicine, Nanning 530023, Guangxi Zhuang Autonomous Region, China

Zi-Kun Chen, Graduate School, Guangxi University of Chinese Medicine, Nanning 530200, Guangxi Zhuang Autonomous Region, China

Ai-Ling Wei, Department of Liver Disease, The First Affiliated Hospital, Guangxi University of Chinese Medicine, Nanning 530023, Guangxi Zhuang Autonomous Region, China

Corresponding author: Ai-Ling Wei, MD, Chief Physician, Dean, Professor, Department of Liver Disease, The First Affiliated Hospital, Guangxi University of Chinese Medicine, No. 89-9 Dongge Road, Nanning 530023, Guangxi Zhuang Autonomous Region, China.
weial@gxcmu.edu.cn

Abstract

BACKGROUND

Budd-Chiari syndrome (BCS) is a rare heterogeneous liver disease characterized by obstruction of the hepatic venous outflow tract. The incidence of BCS is so low that it is difficult to detect in general practice and difficult to include within the scope of routine diagnosis. The clinical manifestations of BCS are not specific; hence, BCS tends to be misdiagnosed.

CASE SUMMARY

We report the case of a 33-year-old Chinese woman who presented with progressive distension in the upper abdomen. She was initially misdiagnosed with liver cirrhosis (LC) due to abnormalities on an upper abdominal computed tomography scan. Although she was taking standard anti-cirrhosis therapy, her symptoms did not improve. Magnetic resonance imaging showed caudate lobe hypertrophy; and dilated lumbar and hemiazygos veins. Venography revealed membranous obstruction of the inferior vena cava owing to congenital vascular malformation. A definitive diagnosis of BCS was made. Balloon angioplasty was performed to recanalize the obstructed inferior vena cava and the patient's

Checklist (2016).

Open-Access: This article is an open-access article that was selected by an in-house editor and fully peer-reviewed by external reviewers. It is distributed in accordance with the Creative Commons Attribution NonCommercial (CC BY-NC 4.0) license, which permits others to distribute, remix, adapt, build upon this work non-commercially, and license their derivative works on different terms, provided the original work is properly cited and the use is non-commercial. See: <http://creativecommons.org/licenses/by-nc/4.0/>

Manuscript source: Unsolicited manuscript

Specialty type: Medicine, research and experimental

Country/Territory of origin: China

Peer-review report's scientific quality classification

Grade A (Excellent): 0
Grade B (Very good): B
Grade C (Good): C
Grade D (Fair): 0
Grade E (Poor): 0

Received: December 31, 2020

Peer-review started: December 31, 2020

First decision: January 17, 2021

Revised: January 27, 2021

Accepted: February 8, 2021

Article in press: February 8, 2021

Published online: April 26, 2021

P-Reviewer: Kadriyan H

S-Editor: Gao CC

L-Editor: Webster JR

P-Editor: Wu YXJ



symptoms were completely resolved.

CONCLUSION

BCS lacks specific clinical features and can eventually lead to LC. Clinicians and radiologists must carefully differentiate BCS from LC. Correct diagnosis and timely treatment are vital to the patient's health.

Key Words: Budd-Chiari syndrome; Liver cirrhosis; Venography; Balloon angioplasty; Inferior vena cava; Case report

©The Author(s) 2021. Published by Baishideng Publishing Group Inc. All rights reserved.

Core Tip: Budd-Chiari syndrome (BCS) is a rare heterogeneous liver disease characterized by obstruction of the hepatic venous outflow tract. We report a case of BCS initially misdiagnosed as liver cirrhosis due to the abnormalities visible on an upper abdominal computed tomography scan. Further examinations were performed to establish a diagnosis. Magnetic resonance imaging revealed a narrowed inferior vena cava. Liver biopsy and pathological analysis showed hepatocyte degeneration, bridging fibrosis, sinusoidal dilatation, and areas of fibrous tissue with substantial hyperplasia, suggesting that BCS was the cause of liver cirrhosis.

Citation: Ye QB, Huang QF, Luo YC, Wen YL, Chen ZK, Wei AL. Budd-Chiari syndrome associated with liver cirrhosis: A case report. *World J Clin Cases* 2021; 9(12): 2937-2943

URL: <https://www.wjgnet.com/2307-8960/full/v9/i12/2937.htm>

DOI: <https://dx.doi.org/10.12998/wjcc.v9.i12.2937>

INTRODUCTION

Budd-Chiari syndrome (BCS) is a rare heterogeneous liver disease that is characterized by obstruction of the hepatic venous outflow tract, which may occur anywhere from the small hepatic veins (HVs) to the inferior vena cava (IVC) and right atrium^[1]. According to the location of the obstruction, BCS can be classified as involving the small HVs, large HVs, IVC, or arbitrary combinations of these^[2]. BCS can eventually lead to sinusoidal congestion, portal hypertension, liver cell injury, centrilobular fibrosis, and ultimately, cirrhosis^[3]. The incidence rate of BCS varies among countries. In China, the annual incidence rate of BCS in the five areas with the highest prevalence is estimated to be 0.88 per million^[4]. The rate of liver cirrhosis (LC) caused by BCS is approximately 4%^[5]. Due to its low incidence, BCS is difficult to detect in general practice and to include within the scope of routine diagnosis. Moreover, the clinical manifestations of BCS are abdominal pain, hepatomegaly, and ascites, which are also frequently seen in LC; thus, BCS tends to be misdiagnosed.

Here, we report a case of BCS associated with cirrhosis, which was initially misdiagnosed.

CASE PRESENTATION

Chief complaints

A 33-year-old Chinese woman was admitted to our medical institution on May 21, 2018, owing to progressive distension in the upper abdomen.

History of present illness

Two weeks before admission, she was diagnosed with LC, portal hypertension and splenomegaly, based on an upper abdominal computed tomography (CT) scan at another hospital. Although she was taking prescribed medication that exerted effects such as anti-hepatic fibrosis, inhibition of gastric acid secretion, and protection of the stomach, her symptoms did not improve. She developed progressive distension in the upper abdomen with sour regurgitation. There was no nausea, vomiting, diarrhea, or

abdominal pain.

History of past illness

The patient had a history of thrombocytopenia going back more than 10 years and she had undergone surgery for an ovarian cyst on the left side in 2011.

Personal and family history

No special personal and family history.

Physical examination

Physical examination revealed dark discoloration and mild tenderness in the left lower abdomen; other examinations were normal.

Laboratory examinations

Complete blood cell count showed a reduced white blood cell count $3.1 \times 10^9/L$ (normal range $3.5-9.5 \times 10^9/L$) and platelet count $74 \times 10^9/L$ (normal range $125-350 \times 10^9/L$). Liver and renal functions, coagulation, and tumor markers were normal. Serum electrolytes were within the normal range. The levels of protein C, protein S, immunoglobulin (Ig) G, IgA, and IgM were also within normal limits. Serology for hepatitis B surface antigen, hepatitis C antibody, anticardiolipin antibodies, and lupus anticoagulant was negative. No other obvious abnormalities were discovered.

Imaging examinations

Gastroscopy showed mild esophageal varices. Magnetic resonance imaging (MRI) revealed caudate lobe hypertrophy, cirrhosis, and dilated lumbar and hemiazygos veins (Figure 1A). Dilated azygos veins and narrowed IVC were present (Figure 1B). Hypersplenotrophy and dilated veins in the lower esophagus and surrounding the hilus lienis were also observed.

Pathological examination

To confirm the diagnosis of BCS, liver biopsy was performed under CT guidance. Histochemical staining (hematoxylin-eosin and Masson trichrome) showed hepatocyte degeneration, bridging fibrosis, sinusoidal dilatation, and areas of fibrous tissue with substantial hyperplasia (Figure 2).

FINAL DIAGNOSIS

The definitive diagnosis in this patient was BCS, compensated LC, and thrombopenia.

TREATMENT

Venography of the HVs and IVC *via* the femoral vein and internal jugular vein revealed complete occlusion of the IVC with the formation of numerous collateral branches (Figure 1C). Balloon angioplasty was performed to recanalize the obstructed IVC (Figure 1D) on June 19, 2018. The administration of anti-hepatic fibrosis medication was continued. Three months after balloon angioplasty, the patient again presented with upper abdominal distension and pain and was readmitted to our hospital. MRI showed HV stenosis with ectopic tissue (Figure 1E). The obstructed IVC was treated with balloon dilation angioplasty (Figure 1F and G) on October 23, 2018.

OUTCOME AND FOLLOW-UP

Six months after balloon angioplasty, the patient's MRI revealed that dilation of the lumbar and hemiazygos veins and caudate lobe hypertrophy were improved (Figure 1H). In addition, venography of the IVC combined with hepatic venous pressure measurement was performed. The results showed that the pressure was 12 mmHg. Furthermore, liver function tests were normal.

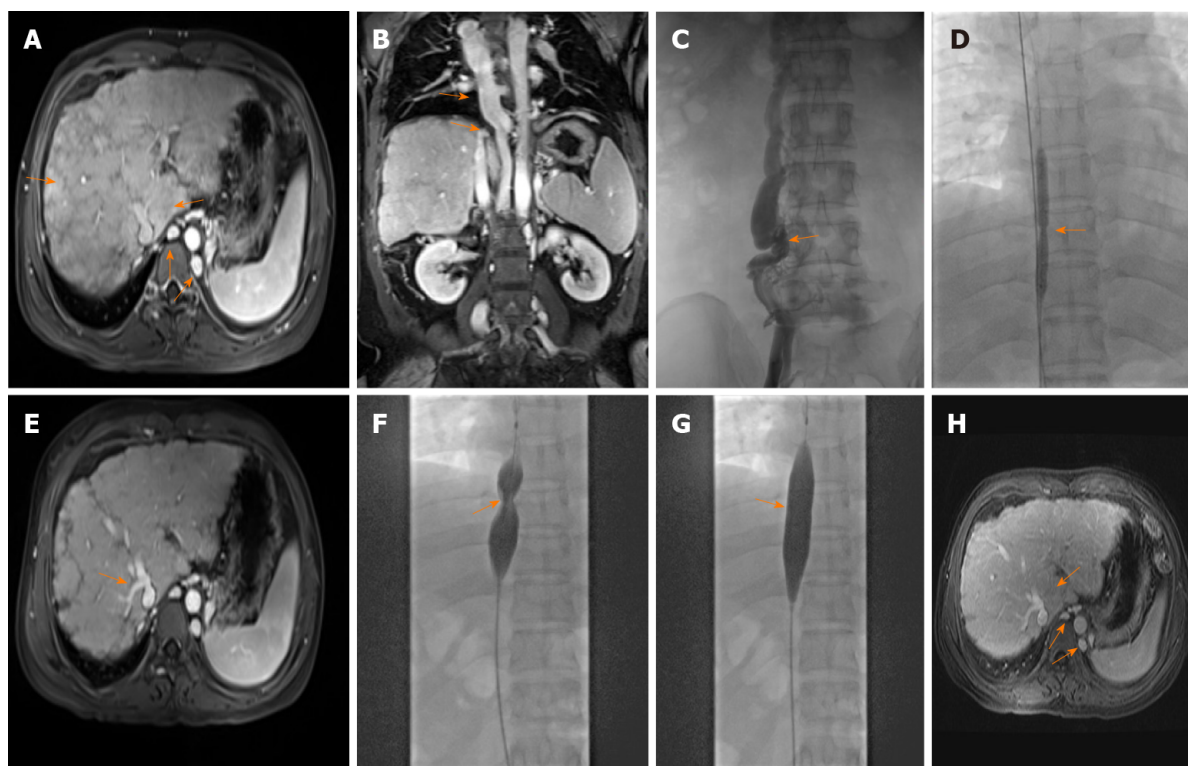


Figure 1 Imaging findings of Budd-Chiari syndrome with membranous obstruction of the inferior vena cava. A: Magnetic resonance imaging (MRI) showed caudate lobe hypertrophy, cirrhosis, and dilated lumbar vein and hemiazygos veins on June 13, 2018; B: MRI revealed dilated azygos veins and narrowed inferior vena cava (IVC) on June 13, 2018; C: Venography of hepatic veins and IVC revealed complete occlusion of the IVC with the formation of numerous collateral branches on June 19, 2018; D: Balloon angioplasty was performed to recanalize the obstructed IVC on June 19, 2018; E: MRI revealed hepatic vein stenosis with ectopic tissue 3 mo after balloon angioplasty; F and G: Before and after balloon angioplasty of the IVC; H: Six months after balloon angioplasty, MRI revealed that dilation of the lumbar and hemiazygos veins and caudate lobe hypertrophy were improved.

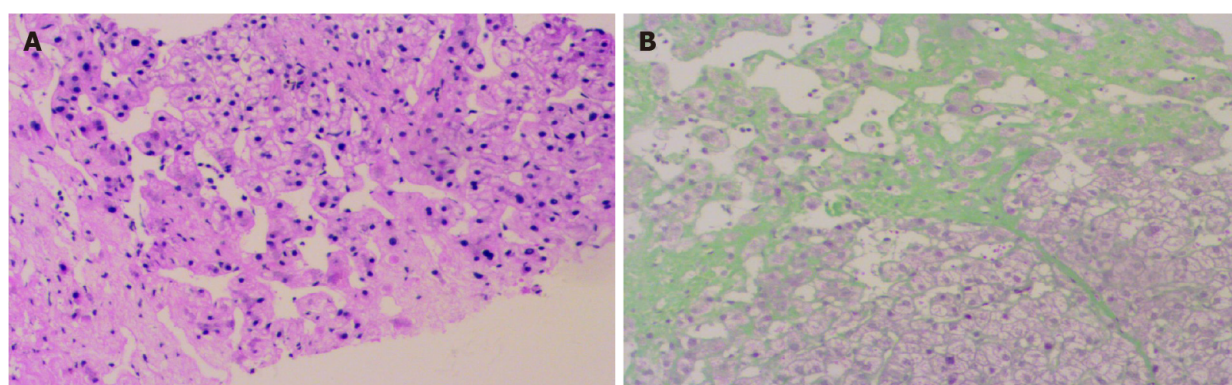


Figure 2 Liver biopsy sample. A: Hepatocyte degeneration, and sinusoidal dilatation (hematoxylin-eosin stain, × 100); B: Bridging fibrosis, areas of fibrous tissue with substantial hyperplasia (Masson trichrome stain, × 100).

DISCUSSION

BCS is a relatively rare vascular disorder among liver diseases. It is characterized by obstruction of the hepatic venous outflow tract and may lead to congestion in the liver. Chronic hepatic congestion can eventually result in liver fibrosis, cirrhosis, and hepatocellular carcinoma. BCS is divided into four classifications involving small HVs, large HVs, the IVC, and arbitrary combinations of these according to the venous stenosis site. The distribution of BCS varies geographically. IVC with or without HV obstruction is predominant in Asia, whereas HV obstruction predominates in Western countries^[6]. In terms of age and sex, BCS tends to be more common in females than males and to mostly appear at the age of 20-39 years^[7].

A number of causes of BCS have been identified. According to etiology, BCS can be divided into primary BCS and secondary BCS. Risk factors for the former include

hypercoagulable states and thrombosis, which may be caused by myeloproliferative disorders, antiphospholipid syndrome, oral contraceptive use, pregnancy, hyperhomocysteinemia, Behçet disease, protein C deficiency, and protein S deficiency, among others. Risk factors for secondary BCS are predominantly tumoral invasion, abscesses, and cysts^[8]. Vascular thrombosis is the most common element resulting in obstruction of the HV system, as reported in a long-term follow-up study^[9]. However, more potential risk factors or causes of BCS should be investigated clinically.

Classical clinical manifestations of BCS include abdominal pain, ascites, hepatomegaly, jaundice, and leg swelling^[10,11]. Up to 20% of patients with BCS are asymptomatic^[12]. In our report, the main complaint in this patient was upper abdominal distension and pain. Nevertheless, this finding was not specific; these symptoms or other classical clinical manifestations may be observed in progressive liver diseases. Hence, in addition to symptoms and signs, diagnostic techniques and the skill of the physician are important in the diagnosis of BCS.

There are various auxiliary examinations for diagnosing BCS. In some cases, serum aminotransferases and bilirubin can be obviously increased, and albumin is decreased. However, laboratory findings may also show that liver function or other indicators are normal. Under these circumstances, radiological methods are helpful for further diagnosis. Doppler ultrasound, CT, and MRI are the main diagnostic methods. Although the sensitivity of ultrasound is as high as 87%^[13], BCS can be excluded relatively easily using ultrasound in comparison with CT/MRI, which can reveal abnormal changes in vessels of the liver. CT is limited owing to its uncertain results in nearly 50% of cases^[14]. In fact, most patients with BCS can be diagnosed if the radiologist and clinician carefully examine the imaging features of BCS. MRI along with intravenous gadolinium injection has an advantage in the visualization of HVs, IVC, large intrahepatic or comma-shaped collateral vessels, and spider web networks. Thus, MRI is a reasonable choice for the diagnosis of BCS.

Liver biopsy is not a routine diagnostic requirement. However, when imaging does not show the obstruction of venous outflow or BCS is suspected, liver biopsy is required. Liver biopsy may demonstrate liver cell loss, congestion, and fibrosis. In addition, liver biopsy is helpful for differentiating between BCS and veno-occlusive disease. It should be noted that congestion can be found in constrictive pericarditis and cardiac failure, and fibrosis can indicate other diseases, such as diabetes. These similar clinical characteristics should be identified.

Venography can be considered as a diagnostic procedure when the diagnosis of BCS remains unclear. At the same time, valuable information, including the degree of thrombosis, assessment of HVs, and caval pressures, can be provided by venography, to help in the choice of optimal treatment. The portal vein can also be evaluated in this procedure. Venous pressure measurements are conducive to treatment options under various circumstances. For example, to relieve cirrhosis, dilation of HV stenosis is performed to reduce pressure of the HV. Transjugular intrahepatic portosystemic shunt (TIPS) is performed to decrease pressure of the portal vein, which is conducive to the regression of ascites and can effectively prevent bleeding *via* embolization of varicose collateral vessels in the same sitting. Furthermore, venous pressure measurements are helpful for assessing the patient's condition in postoperative follow-up.

BCS has a standard management and appraisal system based on guidelines. Specifically, the first-line therapy is medical treatment, which is administered to patients with a hypercoagulable state, portal hypertension, basic diseases, or related complications. The second-line therapy is angioplasty or stenting, which is appropriate for patients with short-length stenosis after medical therapy failure. The next step in management is TIPS, which is suitable for patients who do not respond to medical, angioplasty, or stenting treatment. Liver transplant is the last step in management and has strict requirements, being suitable only for patients with LC, advanced liver dysfunction, or fulminant hepatic failure^[15]. It has been reported that the long-term survival rate of liver transplant is approximately 84%^[16].

In our patient, the causes and classical clinical features of BCS were not recognized. BCS was diagnosed by MRI findings, which showed a narrowed IVC, caudate lobe hypertrophy, and dilated lumbar vein, azygos veins, and hemiazygos veins. Cavography confirmed IVC obstruction in this patient. Short-length stenosis is found in approximately 60% of patients with obstructive IVC^[17]. In theory, patients with segmental or focal block of the HV outflow tract are suitable for recanalization. Recanalization of the IVC with balloon angioplasty can improve the clinical presentation. The short-term effect is satisfactory, but the restenosis rate is as high as 50% at 2 years after angioplasty^[18]. Therapy using stents could prolong the long-term patency rates^[19]. Stent implantation should be considered for patients with an

unsatisfactory curative effect or recurrent restenosis. However, the disadvantage of stent treatment should not be underestimated. The clinician should choose the best therapy according to the patient's condition.

The ultimate therapeutic purpose of various clinical treatment methods is to remove the diseased HV/IVC; restore normal blood flow; relieve portal hypertension, stasis cirrhosis, or IVC hypertension syndrome; improve the quality of life of patients; and prolong survival. Balloon angioplasty is one of the procedures used to recanalize the obstruction of the hepatic venous outflow tract. However, the occurrence of postoperative restenosis has serious effects on the long-term curative effects. In our report, with regard to the possible cause of the first three-month re-stenosis, we concluded that the following causes were possible. First, the diameter of the balloon catheter used in balloon angioplasty was not optimal, and the medical community has not yet set a standard for the size of the balloon in balloon angioplasty. Second, inductive vascular repair after balloon angioplasty resulted in thickening of the intima and proliferation of vascular smooth muscle cells in the media. To prevent recurrence, we should maximize treatment efficacy. Specifically, selection of the balloon diameter is key. It affects the clinical efficacy and the recurrence of postoperative lesions. Selection of the appropriate balloon diameter should be fully evaluated in preoperative planning. During the operation, the surgeon should fully dilate the stenosis or occlusion of the IVC, tear the septum, and loosen the thickened venous wall and extravascular fibrous connective tissue to improve the efficacy and reduce the postoperative recurrence rate.

One point that should be noted is that LC was secondary to BCS in this case, as the common causes of cirrhosis had been ruled out. Owing to its rarity as a cause of LC, a diagnosis of BCS may be overlooked by inexperienced clinicians. A detailed medical history, clinical presentations, physical examination, and imaging findings or liver biopsy should be used to make a diagnosis. Moreover, BCS should be differentiated from other similar diseases, such as congestive hepatopathy. Correct diagnosis will avoid missing the optimal therapy time and prolonging the condition. Theoretically, chronic liver congestion in patients with BCS is the main factor leading to the development of LC. Greater attention is needed for the timely treatment of BCS before its progression to LC.

CONCLUSION

We describe a case of BCS, in which the obstruction site was the IVC. BCS is relatively easy to misdiagnose or overlook owing to its rarity. Clinicians and radiologists must carefully differentiate BCS from LC. Particularly when patients with LC present with unknown causes and normal liver function, the possibility of BCS should be considered. Correct diagnosis and timely treatment can affect the therapeutic efficacy. Furthermore, recanalization before the formation of hepatocirrhosis is vital to prevent or reverse hepatic fibrosis.

ACKNOWLEDGEMENTS

We thank the patient and her family for their support.

REFERENCES

- 1 Valla DC. The diagnosis and management of the Budd-Chiari syndrome: consensus and controversies. *Hepatology* 2003; **38**: 793-803 [PMID: 14512865 DOI: 10.1053/jhep.2003.50415]
- 2 Ludwig J, Hashimoto E, McGill DB, van Heerden JA. Classification of hepatic venous outflow obstruction: ambiguous terminology of the Budd-Chiari syndrome. *Mayo Clin Proc* 1990; **65**: 51-55 [PMID: 2296212 DOI: 10.1016/s0025-6196(12)62109-0]
- 3 Menon KV, Shah V, Kamath PS. The Budd-Chiari syndrome. *N Engl J Med* 2004; **350**: 578-585 [PMID: 14762185 DOI: 10.1056/NEJMra020282]
- 4 Zhang W, Qi X, Zhang X, Su H, Zhong H, Shi J, Xu K. Budd-Chiari Syndrome in China: A Systematic Analysis of Epidemiological Features Based on the Chinese Literature Survey. *Gastroenterol Res Pract* 2015; **2015**: 738548 [PMID: 26504461 DOI: 10.1155/2015/738548]
- 5 Wang X, Lin SX, Tao J, Wei XQ, Liu YT, Chen YM, Wu B. Study of liver cirrhosis over ten consecutive years in Southern China. *World J Gastroenterol* 2014; **20**: 13546-13555 [PMID: 25309085 DOI: 10.3748/wjg.v20.i37.13546]

- 6 **Valla DC.** Hepatic venous outflow tract obstruction etiopathogenesis: Asia vs the West. *J Gastroenterol Hepatol* 2004; **19**: S204-S211 [DOI: [10.1111/j.1440-1746.2004.03642.x](https://doi.org/10.1111/j.1440-1746.2004.03642.x)]
- 7 **Seijo S**, Plessier A, Hoekstra J, Dell'era A, Mandair D, Rifai K, Trebicka J, Morard I, Lasser L, Abralles JG, Darwish Murad S, Heller J, Hadengue A, Primignani M, Elias E, Janssen HL, Valla DC, Garcia-Pagan JC; European Network for Vascular Disorders of the Liver. Good long-term outcome of Budd-Chiari syndrome with a step-wise management. *Hepatology* 2013; **57**: 1962-1968 [PMID: [23389867](https://pubmed.ncbi.nlm.nih.gov/23389867/) DOI: [10.1002/hep.26306](https://doi.org/10.1002/hep.26306)]
- 8 **DeLeve LD**, Valla DC, Garcia-Tsao G; American Association for the Study Liver Diseases. Vascular disorders of the liver. *Hepatology* 2009; **49**: 1729-1764 [PMID: [19399912](https://pubmed.ncbi.nlm.nih.gov/19399912/) DOI: [10.1002/hep.22772](https://doi.org/10.1002/hep.22772)]
- 9 **Harmanci O**, Kav T, Peynircioglu B, Buyukasik Y, Sokmensuer C, Bayraktar Y. Long-term follow-up study in Budd-Chiari syndrome: single-center experience in 22 years. *J Clin Gastroenterol* 2013; **47**: 706-712 [PMID: [22495815](https://pubmed.ncbi.nlm.nih.gov/22495815/) DOI: [10.1097/MCG.0b013e31824ffd63](https://doi.org/10.1097/MCG.0b013e31824ffd63)]
- 10 **Okuda H**, Yamagata H, Obata H, Iwata H, Sasaki R, Imai F, Okudaira M, Ohbu M, Okuda K. Epidemiological and clinical features of Budd-Chiari syndrome in Japan. *J Hepatol* 1995; **22**: 1-9 [PMID: [7751574](https://pubmed.ncbi.nlm.nih.gov/7751574/) DOI: [10.1016/0168-8278\(95\)80252-5](https://doi.org/10.1016/0168-8278(95)80252-5)]
- 11 **Darwish Murad S**, Valla DC, de Groen PC, Zeitoun G, Hopmans JA, Haagsma EB, van Hoek B, Hansen BE, Rosendaal FR, Janssen HL. Determinants of survival and the effect of portosystemic shunting in patients with Budd-Chiari syndrome. *Hepatology* 2004; **39**: 500-508 [PMID: [14768004](https://pubmed.ncbi.nlm.nih.gov/14768004/) DOI: [10.1002/hep.20064](https://doi.org/10.1002/hep.20064)]
- 12 **Hadengue A**, Poliquin M, Vilgrain V, Belghiti J, Degott C, Erlinger S, Benhamou JP. The changing scene of hepatic vein thrombosis: recognition of asymptomatic cases. *Gastroenterology* 1994; **106**: 1042-1047 [PMID: [8143970](https://pubmed.ncbi.nlm.nih.gov/8143970/) DOI: [10.1016/0016-5085\(94\)90765-x](https://doi.org/10.1016/0016-5085(94)90765-x)]
- 13 **Bolondi L**, Gaiani S, Li Bassi S, Zironi G, Bonino F, Brunetto M, Barbara L. Diagnosis of Budd-Chiari syndrome by pulsed Doppler ultrasound. *Gastroenterology* 1991; **100**: 1324-1331 [PMID: [2013376](https://pubmed.ncbi.nlm.nih.gov/2013376/) DOI: [10.1016/0016-5085\(91\)70020-X](https://doi.org/10.1016/0016-5085(91)70020-X)]
- 14 **Gupta S**, Barter S, Phillips GW, Gibson RN, Hodgson HJ. Comparison of ultrasonography, computed tomography and 99mTc liver scan in diagnosis of Budd-Chiari syndrome. *Gut* 1987; **28**: 242-247 [PMID: [3552905](https://pubmed.ncbi.nlm.nih.gov/3552905/) DOI: [10.1136/gut.28.3.242](https://doi.org/10.1136/gut.28.3.242)]
- 15 **Ringe B**, Lang H, Oldhafer KJ, Gebel M, Flemming P, Georgii A, Borst HG, Pichlmayr R. Which is the best surgery for Budd-Chiari syndrome: venous decompression or liver transplantation? *Hepatology* 1995; **21**: 1337-1344 [PMID: [7737640](https://pubmed.ncbi.nlm.nih.gov/7737640/) DOI: [10.1002/hep.1840210518](https://doi.org/10.1002/hep.1840210518)]
- 16 **Srinivasan P**, Rela M, Prachalias A, Muiesan P, Portmann B, Mufti GJ, Pagliuca A, O'Grady J, Heaton N. Liver transplantation for Budd-Chiari syndrome. *Transplantation* 2002; **73**: 973-977 [PMID: [11923703](https://pubmed.ncbi.nlm.nih.gov/11923703/) DOI: [10.1097/00007890-200203270-00026](https://doi.org/10.1097/00007890-200203270-00026)]
- 17 **Okuda K.** Inferior vena cava thrombosis at its hepatic portion (obliterative hepatocavopathy). *Semin Liver Dis* 2002; **22**: 15-26 [PMID: [11928076](https://pubmed.ncbi.nlm.nih.gov/11928076/) DOI: [10.1055/s-2002-23203](https://doi.org/10.1055/s-2002-23203)]
- 18 **Xu K**, He FX, Zhang HG, Zhang XT, Han MJ, Wang CR, Kaneko M, Takahashi M, Okawada T. Budd-Chiari syndrome caused by obstruction of the hepatic inferior vena cava: immediate and 2-year treatment results of transluminal angioplasty and metallic stent placement. *Cardiovasc Intervent Radiol* 1996; **19**: 32-36 [PMID: [8653743](https://pubmed.ncbi.nlm.nih.gov/8653743/) DOI: [10.1007/BF02560144](https://doi.org/10.1007/BF02560144)]
- 19 **Zhang CQ**, Fu LN, Xu L, Zhang GQ, Jia T, Liu JY, Qin CY, Zhu JR. Long-term effect of stent placement in 115 patients with Budd-Chiari syndrome. *World J Gastroenterol* 2003; **9**: 2587-2591 [PMID: [14606103](https://pubmed.ncbi.nlm.nih.gov/14606103/) DOI: [10.3748/wjg.v9.i11.2587](https://doi.org/10.3748/wjg.v9.i11.2587)]



Published by **Baishideng Publishing Group Inc**
7041 Koll Center Parkway, Suite 160, Pleasanton, CA 94566, USA

Telephone: +1-925-3991568

E-mail: bpgoffice@wjgnet.com

Help Desk: <https://www.f6publishing.com/helpdesk>

<https://www.wjgnet.com>

