

World Journal of *Clinical Cases*

World J Clin Cases 2021 May 6; 9(13): 2951-3226



Contents

Thrice Monthly Volume 9 Number 13 May 6, 2021

REVIEW

- 2951 Patients with cirrhosis during the COVID-19 pandemic: Current evidence and future perspectives
Su HY, Hsu YC

MINIREVIEWS

- 2969 Immunotherapy for pancreatic cancer
Yoon JH, Jung YJ, Moon SH

ORIGINAL ARTICLE

Retrospective Study

- 2983 Scrotal septal flap and two-stage operation for complex hypospadias: A retrospective study
Chen S, Yang Z, Ma N, Wang WX, Xu LS, Liu QY, Li YQ
- 2994 Clinical diagnosis of severe COVID-19: A derivation and validation of a prediction rule
Tang M, Yu XX, Huang J, Gao JL, Cen FL, Xiao Q, Fu SZ, Yang Y, Xiong B, Pan YJ, Liu YX, Feng YW, Li JX, Liu Y
- 3008 Prognostic value of hemodynamic indices in patients with sepsis after fluid resuscitation
Xu HP, Zhuo XA, Yao JJ, Wu DY, Wang X, He P, Ouyang YH

Observational Study

- 3014 Updated Kimura-Takemoto classification of atrophic gastritis
Kotelevets SM, Chekh SA, Chukov SZ

SYSTEMATIC REVIEWS

- 3024 Systematic review and meta-analysis of the impact of deviations from a clinical pathway on outcomes following pancreatoduodenectomy
Karunakaran M, Jonnada PK, Barreto SG

META-ANALYSIS

- 3038 Early vs late cholecystectomy in mild gall stone pancreatitis: An updated meta-analysis and review of literature
Walayat S, Baig M, Puli SR

CASE REPORT

- 3048 Effects of intravascular laser phototherapy on delayed neurological sequelae after carbon monoxide intoxication as evaluated by brain perfusion imaging: A case report and review of the literature
Liu CC, Hsu CS, He HC, Cheng YY, Chang ST

- 3056** *Crumbs homolog 2* mutation in two siblings with steroid-resistant nephrotic syndrome: Two case reports
Lu J, Guo YN, Dong LQ
- 3063** Intracortical chondroma of the metacarpal bone: A case report
Yoshida Y, Anazawa U, Watanabe I, Hotta H, Aoyama R, Suzuki S, Nagura T
- 3070** Vancomycin-related convulsion in a pediatric patient with neuroblastoma: A case report and review of the literature
Ye QF, Wang GF, Wang YX, Lu GP, Li ZP
- 3079** Pulmonary arterial hyper-tension in a patient with hereditary hemorrhagic telangiectasia and family gene analysis: A case report
Wu J, Yuan Y, Wang X, Shao DY, Liu LG, He J, Li P
- 3090** Misdiagnosed dystrophic epidermolysis bullosa pruriginosa: A case report
Wang Z, Lin Y, Duan XW, Hang HY, Zhang X, Li LL
- 3095** Spontaneous coronary dissection should not be ignored in patients with chest pain in autosomal dominant polycystic kidney disease: A case report
Qian J, Lai Y, Kuang LJ, Chen F, Liu XB
- 3102** Sarcomatoid carcinoma of the pancreas — multimodality imaging findings with serial imaging follow-up: A case report and review of literature
Lim HJ, Kang HS, Lee JE, Min JH, Shin KS, You SK, Kim KH
- 3114** Acute pancreatitis and small bowel obstruction caused by a migratory gastric bezoar after dissolution therapy: A case report
Wang TT, He JJ, Liu J, Chen WW, Chen CW
- 3120** Intracardiac, pulmonary cement embolism in a 67-year-old female after cement-augmented pedicle screw instrumentation: A case report and review of literature
Liang TZ, Zhu HP, Gao B, Peng Y, Gao WJ
- 3130** Acute urinary retention in the first and second-trimester of pregnancy: Three case reports
Zhuang L, Wang XY, Sang Y, Xu J, He XL
- 3140** Sarcoidosis mimicking metastases in an echinoderm microtubule-associated protein-like 4 anaplastic lymphoma kinase positive non-small-lung cancer patient: A case report
Chen X, Wang J, Han WL, Zhao K, Chen Z, Zhou JY, Shen YH
- 3147** Three-dimensional printed talar prosthesis with biological function for giant cell tumor of the talus: A case report and review of the literature
Yang QD, Mu MD, Tao X, Tang KL
- 3157** Successful upgrade to cardiac resynchronization therapy for cardiac implantation-associated left subclavian vein occlusion: A case report
Zhong JY, Zheng XW, Li HD, Jiang LF

- 3163** Sodium-glucose co-transporter-2 inhibitor-associated euglycemic diabetic ketoacidosis that prompted the diagnosis of fulminant type-1 diabetes: A case report
Yasuma T, Okano Y, Tanaka S, Nishihama K, Eguchi K, Inoue C, Maki K, Uchida A, Uemura M, Suzuki T, D'Alessandro-Gabazza CN, Gabazza EC, Yano Y
- 3170** Perioperative massive cerebral stroke in thoracic patients: Report of three cases
Jian MY, Liang F, Liu HY, Han RQ
- 3177** Renal artery embolization in the treatment of urinary fistula after renal duplication: A case report and review of literature
Yang T, Wen J, Xu TT, Cui WJ, Xu J
- 3185** Clinical characteristics of intrahepatic biliary papilloma: A case report
Yi D, Zhao LJ, Ding XB, Wang TW, Liu SY
- 3194** Association between scrub typhus encephalitis and diffusion tensor tractography detection of Papez circuit injury: A case report
Kwon HG, Yang JH, Kwon JH, Yang D
- 3200** Alström syndrome with a novel mutation of *ALMS1* and Graves' hyperthyroidism: A case report and review of the literature
Zhang JJ, Wang JQ, Sun MQ, Xu D, Xiao Y, Lu WL, Dong ZY
- 3212** Laparoscopic uncontained power morcellation-induced dissemination of ovarian endodermal sinus tumors: A case report
Oh HK, Park SN, Kim BR
- 3219** Treatment of acute severe ulcerative colitis using accelerated infliximab regimen based on infliximab trough level: A case report
Garate ALSV, Rocha TB, Almeida LR, Quera R, Barros JR, Baima JP, Saad-Hossne R, Sassaki LY

ABOUT COVER

Editorial Board Member of *World Journal of Clinical Cases*, Rama R Vunnam, MBBS, MD, Assistant Professor, Department of Medicine, Penn State Health Milton S. Hershey Medical Center, Hershey, PA 17033, United States. rvunnam@pennstatehealth.psu.edu

AIMS AND SCOPE

The primary aim of *World Journal of Clinical Cases* (WJCC, *World J Clin Cases*) is to provide scholars and readers from various fields of clinical medicine with a platform to publish high-quality clinical research articles and communicate their research findings online.

WJCC mainly publishes articles reporting research results and findings obtained in the field of clinical medicine and covering a wide range of topics, including case control studies, retrospective cohort studies, retrospective studies, clinical trials studies, observational studies, prospective studies, randomized controlled trials, randomized clinical trials, systematic reviews, meta-analysis, and case reports.

INDEXING/ABSTRACTING

The WJCC is now indexed in Science Citation Index Expanded (also known as SciSearch®), Journal Citation Reports/Science Edition, Scopus, PubMed, and PubMed Central. The 2020 Edition of Journal Citation Reports® cites the 2019 impact factor (IF) for WJCC as 1.013; IF without journal self cites: 0.991; Ranking: 120 among 165 journals in medicine, general and internal; and Quartile category: Q3. The WJCC's CiteScore for 2019 is 0.3 and Scopus CiteScore rank 2019: General Medicine is 394/529.

RESPONSIBLE EDITORS FOR THIS ISSUE

Production Editor: Yan-Xia Xing, Production Department Director: Yun-Xiaoqian Wu, Editorial Office Director: Jin-Lai Wang.

NAME OF JOURNAL

World Journal of Clinical Cases

ISSN

ISSN 2307-8960 (online)

LAUNCH DATE

April 16, 2013

FREQUENCY

Thrice Monthly

EDITORS-IN-CHIEF

Dennis A Bloomfield, Sandro Vento, Bao-Gan Peng

EDITORIAL BOARD MEMBERS

<https://www.wjgnet.com/2307-8960/editorialboard.htm>

PUBLICATION DATE

May 6, 2021

COPYRIGHT

© 2021 Baishideng Publishing Group Inc

INSTRUCTIONS TO AUTHORS

<https://www.wjgnet.com/bpg/gerinfo/204>

GUIDELINES FOR ETHICS DOCUMENTS

<https://www.wjgnet.com/bpg/GerInfo/287>

GUIDELINES FOR NON-NATIVE SPEAKERS OF ENGLISH

<https://www.wjgnet.com/bpg/gerinfo/240>

PUBLICATION ETHICS

<https://www.wjgnet.com/bpg/GerInfo/288>

PUBLICATION MISCONDUCT

<https://www.wjgnet.com/bpg/gerinfo/208>

ARTICLE PROCESSING CHARGE

<https://www.wjgnet.com/bpg/gerinfo/242>

STEPS FOR SUBMITTING MANUSCRIPTS

<https://www.wjgnet.com/bpg/GerInfo/239>

ONLINE SUBMISSION

<https://www.f6publishing.com>



Vancomycin-related convulsion in a pediatric patient with neuroblastoma: A case report and review of the literature

Qiao-Feng Ye, Guang-Fei Wang, Yi-Xue Wang, Guo-Ping Lu, Zhi-Ping Li

ORCID number: Qiao-Feng Ye 0000-0001-5310-5306; Guang-Fei Wang 0000-0001-5132-9197; Yi-Xue Wang 0000-0002-2720-5415; Guo-Ping Lu 0000-0002-5244-3781; Zhi-Ping Li 0000-0001-6194-023X.

Author contributions: Ye QF and Wang GF visualized the data, reviewed the literature and drafted the manuscript; Wang YX and Lu GP contributed to the treatment of this patient and provided the patient's medical data; Li ZP reviewed the literature and revised the manuscript; All authors issued final approval for the version to be submitted; Ye QF and Wang GF are co-first authors of this work.

Supported by National Natural Science Foundation of China, No. 81874325; Key Innovative Team of Shanghai Top-Level University Capacity Building in Clinical Pharmacy and Regulatory Science at Shanghai Medical College, Fudan University, No. HJW-R-2019-66-19; Science and Technology Commission of Shanghai Municipality, No. 18DZ1910604, No. 19DZ1910703 and No. 19XD1400900.

Informed consent statement: Written informed consent was obtained from the patient for publication of this report and any accompanying data.

Qiao-Feng Ye, Guang-Fei Wang, Zhi-Ping Li, Department of Clinical Pharmacy, National Children's Medical Center, Children's Hospital of Fudan University, Shanghai 201102, China

Yi-Xue Wang, Guo-Ping Lu, Department of Pediatric Intensive Care Unit, National Children's Medical Center, Children's Hospital of Fudan University, Shanghai 201102, China

Corresponding author: Zhi-Ping Li, PhD, Chief Pharmacist, Department of Clinical Pharmacy, National Children's Medical Center, Children's Hospital of Fudan University, No. 399 Wanyuan Road, Shanghai 201102, China. zpli@fudan.edu.cn

Abstract

BACKGROUND

Vancomycin is often used as an anti-infective drug in patients receiving anti-tumor chemotherapy. There are concerns about its adverse drug reactions during treatment, such as nephrotoxicity, ototoxicity, hypersensitivity reactions, *etc.* However, potential convulsion related to high plasma concentrations of vancomycin in children receiving chemotherapy has not been reported.

CASE SUMMARY

A 3.9-year-old pediatric patient with neuroblastoma receiving vancomycin to treat post-chemotherapy infection developed an unexpected convulsion. No other potential disease conditions could explain the occurrence of the convulsion. The subsequently measured overly high plasma concentrations of vancomycin could possibly provide a clue to the occurrence of this convulsion. The peak and trough plasma concentrations of vancomycin were 59.5 mg/L and 38.6 mg/L, respectively, which were much higher than the safe range. Simulation with the Bayesian approach using MwPharm software showed that the area under the concentration-time curve over 24 h was 1086.6 mg · h/L. Therefore, vancomycin was immediately stopped and teicoplanin was administered instead combined with meropenem and fluconazole as the anti-infective treatment strategy.

CONCLUSION

Unexpected convulsion occurring in a patient after chemotherapy is probably due to toxicity caused by abnormal pharmacokinetics of vancomycin. Overall evaluation and close therapeutic drug monitoring should be conducted to determine the underlying etiology and to take the necessary action as soon as possible.

Conflict-of-interest statement: The authors declare that they have no conflict of interest.

CARE Checklist (2016) statement: The authors have read the CARE Checklist (2016), and the manuscript was prepared and revised according to the CARE Checklist (2016).

Open-Access: This article is an open-access article that was selected by an in-house editor and fully peer-reviewed by external reviewers. It is distributed in accordance with the Creative Commons Attribution NonCommercial (CC BY-NC 4.0) license, which permits others to distribute, remix, adapt, build upon this work non-commercially, and license their derivative works on different terms, provided the original work is properly cited and the use is non-commercial. See: <http://creativecommons.org/licenses/by-nc/4.0/>

Manuscript source: Unsolicited manuscript

Specialty type: Medicine, research and experimental

Country/Territory of origin: China

Peer-review report's scientific quality classification

Grade A (Excellent): 0
Grade B (Very good): 0
Grade C (Good): 0
Grade D (Fair): 0
Grade E (Poor): 0

Received: October 20, 2020

Peer-review started: October 20, 2020

First decision: January 7, 2021

Revised: January 11, 2021

Accepted: February 22, 2021

Article in press: February 22, 2021

Published online: May 6, 2021

P-Reviewer: Kupeli S

S-Editor: Zhang L

L-Editor: Webster JR

P-Editor: Liu JH



Key Words: Vancomycin; Neuroblastoma; Convulsion; Children; Adverse drug reaction; Case report

©The Author(s) 2021. Published by Baishideng Publishing Group Inc. All rights reserved.

Core Tip: Vancomycin is often used as an anti-infective drug in patients receiving anti-tumor chemotherapy. We present a rare case of sudden onset of convulsion related to vancomycin treatment in a pediatric patient with neuroblastoma. This case demonstrates that unexpected convulsion occurring in patients after chemotherapy is probably due to the toxicity caused by abnormal pharmacokinetics of vancomycin. Close therapeutic drug monitoring is recommended to ensure the plasma concentration of vancomycin is within the normal range. A model-based Bayesian estimation tool could be used to estimate the area under the concentration-time curve and help health care practitioners create an individualized dosing plan.

Citation: Ye QF, Wang GF, Wang YX, Lu GP, Li ZP. Vancomycin-related convulsion in a pediatric patient with neuroblastoma: A case report and review of the literature. *World J Clin Cases* 2021; 9(13): 3070-3078

URL: <https://www.wjgnet.com/2307-8960/full/v9/i13/3070.htm>

DOI: <https://dx.doi.org/10.12998/wjcc.v9.i13.3070>

INTRODUCTION

Neuroblastoma is an embryonal malignancy derived from primitive cells in the sympathetic nervous system and often appears in early childhood^[1,2]. It can cause abnormal development of the adrenal medulla and paraspinal ganglia^[3]. The molecular characteristics of neuroblastoma, as shown by extensive studies, include changes at the genome, epigenome, and transcriptome levels^[1]. Neuroblastoma usually occurs sporadically, and its etiology is not exactly clear^[4]. There is an association between a genetic variation in chromosome 6p22 and sporadic neuroblastoma^[5]. Familial cases can be caused by *ALK* and *PHOX2B* germline mutations^[6]. Neuroblastoma is the second most common solid central nervous system tumor occurring in childhood worldwide^[7]. It has a complex clinical course from metastatic spread to spontaneous regression without therapy which can occur at the primary or metastatic site^[2]. Chemotherapy based on a biology- and response-based algorithm can help improve the outcome of patients^[8-10]. The backbone of the induction chemo-therapeutic regimen commonly used to treat neuroblastoma includes cycles of cisplatin and etoposide alternating with vincristine (VCR), doxorubicin (DOX), and cyclophosphamide (CPM), as was developed at the Memorial Sloan-Kettering Cancer Center^[11]. Later, the Children's Oncology Group added topotecan (TOPO), which showed anti-neuroblastoma activity, to the induction regimen^[12,13]. To prevent or treat potential infections caused by compromised immune function after chemotherapy, anti-infective drugs are often administered to patients with tumors^[14]. Careful consideration of the anti-microbial strategy should be given to this special population as there is an increase in antimicrobial-resistant pathogens^[14].

Vancomycin is a tricyclic glycopeptide antibiotic which inhibits the biosynthesis of the bacterial cell wall^[15]. It was first used clinically in 1958, and was mainly used to treat gram-positive bacterial infection resistant to beta-lactam antibiotics, such as methicillin-resistant *Staphylococcus aureus*, coagulase-negative *Staphylococci*, etc.^[15,16]. Vancomycin is poorly absorbed orally, and thus it is administered intravenously in clinical applications^[17]. It is a hydrophilic molecule with plasma protein binding less than 50%^[18] and is mainly excreted by the kidney (80% to 90%)^[19]. Its penetration into cerebrospinal fluid (CSF) is poor with CSF-to-plasma ratios of 0.07-0.30, but has increased variation in patients with meningitis where the CSF-to-plasma ratios range from 0.06 to 0.81^[16,20]. The anti-bacterial effect of vancomycin is time-dependent. The area under the concentration-time curve over 24 h to minimum inhibitory concentration ratio (AUC/MIC) is recognized as the index to evaluate its pharmacodynamic effect, with an AUC/MIC of ≥ 400 as the treatment target^[21]. There are some adverse drug reactions (ADRs) related to vancomycin. Nephrotoxicity is the

major concern associated with its use^[21]. Other adverse effects include hypotension, tachycardia, phlebitis, ototoxicity, hypersensitivity reactions, exanthema, chills, fever, *etc.*^[17]. Rare ADRs of the nervous system that can be caused by vancomycin are mononeuritis multiplex^[22] and encephalopathy^[23], which have been documented in two case reports, respectively. Vancomycin-induced hypertension along with transient blindness and generalized seizure were reported by Caglayan *et al.*^[24]. However, the plasma concentration of vancomycin was not measured in that case and it is unknown if this ADR was caused by abnormal pharmacokinetics of vancomycin.

Here, we report a rare case of sudden onset of convulsion related to vancomycin treatment in a pediatric patient with neuroblastoma.

CASE PRESENTATION

Chief complaints

A 3.9-year-old female patient with a body weight of 16 kg and a height of 104.0 cm, presented to the Department of Oncology at the Children's Hospital of Fudan University to start Cycle 2 chemotherapy for neuroblastoma. During her presentation in the Department of Oncology, she had a sudden onset of convulsion in the left limbs on day 22 in hospital. The patient was transferred to the Pediatric Intensive Care Unit (PICU).

History of present illness

Four months ago, the patient had repeated fever with swelling, weakness and a limp in her right leg. Ultrasound and computed tomography (CT) indicated a space-occupying mass in the retroperitoneum, with routine blood examination showing C reactive protein > 160 mg/L (normal range < 8 mg/L) and hemoglobin 73 g/L (normal range 110-160 g/L). Biopsy of the mass confirmed poorly differentiated neuroblastoma with a medium mitosis-karyorrhexis index, MYCN-non-amplified and Shimada classification as unfavorable histology and Schwannian stroma-poor. Folliculus lymphaticus structure could be seen between tumor cells, indicating the possibility of lymph node metastasis. Nuclear medicine imaging showed multiple osteopathy and hence the possibility of bone metastasis. Using the International Neuroblastoma Staging System^[25], the patient was classified as stage IV.

Induction chemotherapy for the high-risk group was administered to the patient, comprising CPM (230 mg) and TOPO (0.7 mg) for five days. One month later, the second induction chemotherapy consisting of CPM (290 mg) and TOPO (0.8 mg) was started and lasted for five days. The third chemotherapy regimen, which was given one month after the second regimen, included 1385 mg CPM for two days, 0.4 mg VCR for three days, and 16.5 mg DOX for three days. A combination of fluconazole, meropenem, and vancomycin was given to treat infection.

This hospitalization was for the purpose of receiving the fourth chemotherapy regimen.

History of past illness

The patient had no previous medical history.

Personal and family history

The patient had no significant personal or family history.

Physical examination

During convulsion onset, the patient did not respond to sound. Physical examination revealed equally sized and shaped pupils with sensitive reflex to light. Frothing at the lips was noticed. Her left limbs had high muscular tension with continuous shaking. Her blood oxygen saturation was 100% and heart rate was 185-190 bpm. Three minutes after sedation, the convulsion gradually stopped.

On day 27, an electroencephalogram showed slower than normal blood flow in the middle cerebral artery, and mildly insufficient blood supply. Other electroencephalogram parameters were within the normal range.

Laboratory examinations

Before Cycle 2 of chemotherapy was started, laboratory tests showed C reactive protein 23 mg/L (normal range < 8 mg/L), hemoglobin 89 g/L (normal range 110-160 g/L), platelet count $265 \times 10^9/L$ [normal range (100-400) $\times 10^9/L$], red blood cell count

$2.71 \times 10^{12}/L$ [normal range $(4.0-5.5) \times 10^{12}/L$], and white blood cell count $5.4 \times 10^9/L$ [normal range $(4.0-10.0) \times 10^9/L$].

On day 23 (the day after convulsion onset), an 0.8 mL sample of CSF was collected and tested, which showed a clear colorless appearance, negative Pandy's reaction for detecting protein levels, $1 \times 10^6/L$ cell count, and no growth of bacteria or fungi.

On day 24, the plasma concentrations of vancomycin were measured with the peak concentration of 59.5 mg/L (normal range 20-40 mg/L) and the trough concentration of 38.6 mg/L (normal range 5-10 mg/L), which were higher than normal.

Imaging examinations

CT scan of the brain on day 22 revealed widened sulcus fissure and full supratentorial ventricle. There were no abnormal dense shadows in the cerebral parenchyma. Thickening of the nasal sinus mucosa was seen. Magnetic resonance imaging was conducted on day 23 to further evaluate the brain. The results showed that the splenium of the corpus callosum had an abnormal patchy signal shadow on T1 weighted image, T2 total internal reflection fluorescence microscopy and T2 weighted image images. No other abnormal signals in the rest of the brain were observed.

FINAL DIAGNOSIS

Convulsion with unknown cause, chemotherapy for tumor treatment, retroperitoneal tumor (neuroblastoma post-biopsy; IV stage; MYCN-non-amplified), and hypertension.

TREATMENT

Cycle 2 chemotherapy, including 1380 mg CPM for two days, 16.5 mg DOX for three days, and 0.4 mg VCR for three days, was started on day 2 in hospital. On day 5, intravenous cefoperazone-sulbactam 800 mg every 8 h (q8h) for 7 d was administered for anti-infection. On day 12, a stool test showed rotavirus infection, and intravenous meropenem 300 mg q8h was prescribed. On day 15, vancomycin 200 mg q8h with an infusion duration of 40 min and fluconazole 48 mg daily (qd) were prescribed as anti-infective treatment considering her continuous fever. On day 17, the fever recurred with a peak body temperature as high as 39.2°C, and symptomatic treatment lowered the temperature but fever recurred. Intravenous immunoglobulin was added to the treatment plan and anti-infective medication prescriptions continued.

On day 22, during convulsion onset, chloral hydrate and phenobarbital were given for sedation. 250 mL physiological saline solution was infused for fluid expansion.

When the patient was transferred to the PICU, midazolam was infused at a rate of 1 µg/(kg · min), and deslanoside was administered to control her heart rate. Mannitol and glycerol fructose were used alternatively to lower intracranial pressure.

On day 24, the plasma concentrations of vancomycin were reported to be abnormally high; thus, vancomycin administration was stopped. Teicoplanin was given instead and combined with meropenem and fluconazole as the anti-infective treatment strategy. The patient's blood pressure increased to 125-140/70-90 mmHg and nicardipine was prescribed to lower her blood pressure.

OUTCOME AND FOLLOW-UP

On day 26, the plasma concentration of vancomycin was measured again and was 20.5 mg/L, which was lower than two days previously. On day 30, the patient was transferred back to the Department of Oncology and the anti-infective treatment combination was changed to meropenem only. On day 32, the patient was discharged. Follow-up at one month, two months, and six months later revealed no further convulsion, and due to the previous abnormally high plasma concentrations, the patient did not receive vancomycin.

DISCUSSION

The common etiology of convulsion can be divided into two major categories^[26-29]: Infective and non-infective. Infective causes include purulent meningitis and infective toxic encephalopathy. Non-infective causes include intracranial disorders (epilepsy, space-occupying lesion such as intracranial hemorrhage, and atelencephalia) and extracranial disorders (toxicity caused by a prescription drug overdose, blood glucose and electrolytes disorders, such as hypoglycemia, hyponatremia, hypocalcemia, *etc.*, and genetic metabolic diseases, such as organic acidemia, aminoacidopathy and lipodystrophia).

Differential diagnosis was conducted to determine the underlying cause of the convulsion that led to PICU admission. The patient had myelosuppression after chemotherapy, presenting with low red blood cell, white blood cell and platelet counts. Infection secondary to chemotherapy was possible, but purulent meningitis was ruled out by lumbar puncture, which showed no bacterial growth in the CSF culture. Infective toxic encephalopathy caused by severe infection such as sepsis can also lead to convulsion. However, the patient had no fever and no symptoms of systemic intoxication at that time, and the blood culture results did not show any signs of bacterial growth within five days. Therefore, the unexpected convulsion was most likely caused by non-infective conditions. The patient had no history of epilepsy. Although the patient had a history of asphyxia and anoxia, intracranial hemorrhage was ruled out by CT. Magnetic resonance imaging did not reveal signs of atelecephalia. The patient had no electrolyte or blood glucose abnormalities, and no genetic metabolic disease was detected.

The only abnormal phenomenon noted during the treatment process was the high plasma concentration of vancomycin. The patient started vancomycin on day 15 at a dose of 200 mg q8h and an infusion duration of approximately 40 min, which was within the normal dosing range of 40-60 mg/(kg · d) divided every 6 to 8 h^[15,21]. On day 22, the convulsion occurred and the patient was transferred to the PICU. The timeline of medications and laboratory test results are shown in [Figure 1](#). The concentrations of vancomycin were not measured until day 24, and warning values of both peak and trough concentrations were reported, which were 59.5 mg/L and 38.6 mg/L, respectively. Simulation with the Bayesian approach using MwPharm software (Version 1.6.1.128, Mediware, Prague, Czech Republic) showed that the area under the concentration-time curve over 24 h (AUC_{0-24h}) was 1086.6 mg · h/L. Assuming the minimum inhibitory concentration was 1 mg/L, the AUC/MIC was 1086.6. The simulated curve is displayed in [Figure 2](#).

According to previous research, when the AUC is over 600 mg · h /L, the risk of acute kidney injury (AKI) increases^[30]. A meta-analysis of 10 studies in pediatric populations by Fiorito *et al*^[31] reported that a vancomycin trough concentration of ≥ 15 mg/L increased the odds ratio of AKI by 2.7-fold. In our patient, the creatinine clearance (CLCR) estimated by the Schwartz formula of $CLCR = (0.413 \times \text{Height}) / \text{Creatinine}$ ^[32], indicated potential impairment of renal function from the beginning of hospitalization, the changes of which are shown in [Figure 3](#). There was a significant decrease in CLCR on day 18 with the value of 33.3 mL/(min · 1.73 m²). The sudden decrease in renal function was probably due to the increased vancomycin concentration. On the other hand, the decreased renal function facilitated the accumulation of vancomycin in the patient's body, thus forming the vicious cycle between the vancomycin concentration and renal function. Moreover, it was likely that the concentration of vancomycin was already over the normal therapeutic window before the unexpected convulsion occurred. Researchers have found no correlation between dose and CSF concentration^[33], meaning the patient could have a high CSF concentration of vancomycin even when on a normal dose of vancomycin. High plasma vancomycin concentration could indicate a high CSF concentration, thus leading to central nervous symptoms such convulsion as in this patient. According to a previous report of an infant receiving intrathecal vancomycin administration, the elimination half-life of vancomycin in the CSF can be as long as 77.7 h^[34]. Another report showed that an anephric child had accumulated concentrations of vancomycin during oral therapy for *Clostridium difficile* pseudomembranous colitis^[23]. The documented serum vancomycin level was 34.0 mg/L and the CSF level was 4.2 mg/L when the patient presented with unexplained fever and encephalopathy, which were resolved by discontinuation of vancomycin and hemodialysis. Therefore, in our case, vancomycin could have accumulated in the CSF and eventually led to the sudden convulsion during vancomycin treatment. Unfortunately, the concentration of vancomycin in CSF was not measured before or after the convulsion, which should be considered in future clinical practice when the plasma concentration of vancomycin is

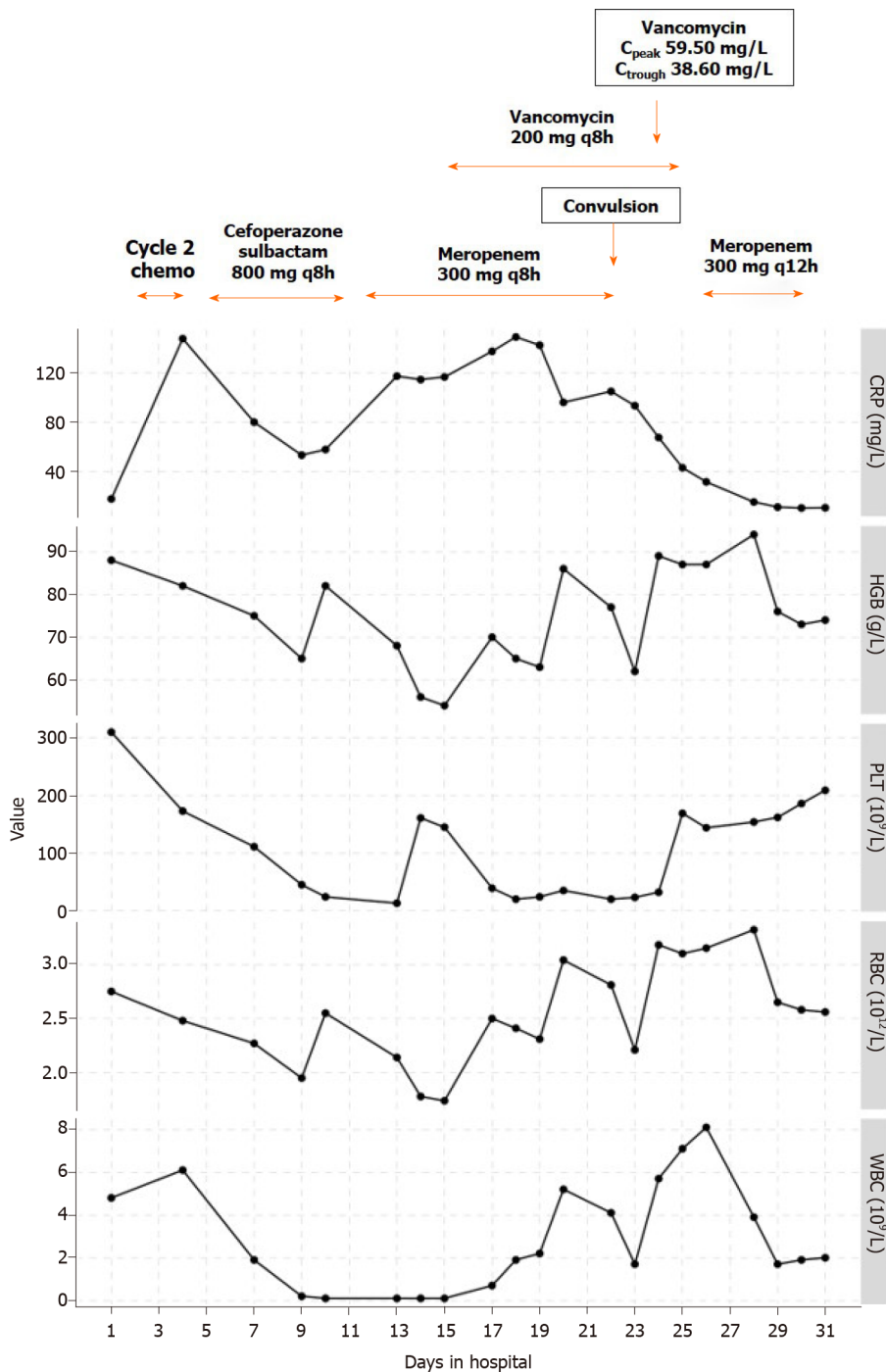


Figure 1 Timeline of medications and blood examination results. Normal ranges: C-reactive protein concentration: < 8 mg/L; Hemoglobin concentration: 110-160 g/L; Platelet count: $(100-400) \times 10^9/L$; Red blood cell count: $4.0-5.5 \times 10^{12}/L$; White blood cell count: $(4.0-10.0) \times 10^9/L$. CRP: C-reactive protein; HGB: Hemoglobin; PLT: Platelet; RBC: Red blood cell; WBC: White blood cell.

overly high.

Of note, this patient had neuroblastoma and received four cycles of high-risk group chemotherapy. The blood-brain barrier in this patient may have been altered due to the disease state or cytotoxic medications^[35]; thus, vancomycin could more easily enter the central nervous system and induce the convulsion. To replace vancomycin as part of the anti-infective treatment plan in patients receiving chemotherapy, teicoplanin can be considered as it has a high plasma protein binding rate (90%-95%) and its penetration into the CSF is lower compared with vancomycin^[36,37]. Moreover, teicoplanin has a lower incidence of adverse effects including nephrotoxicity than vancomycin^[38]. Teicoplanin is also a better choice for patients with insufficient renal function.

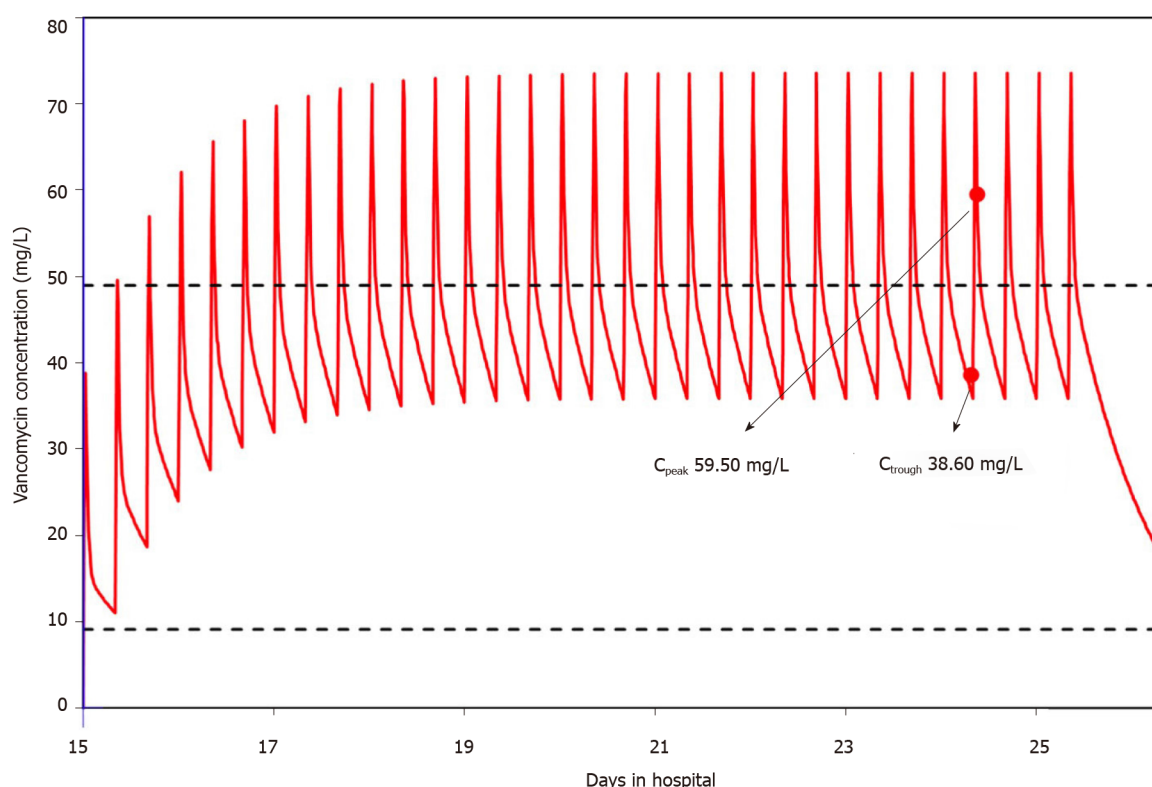


Figure 2 Vancomycin concentration simulation with the Bayesian method using MwPharm.

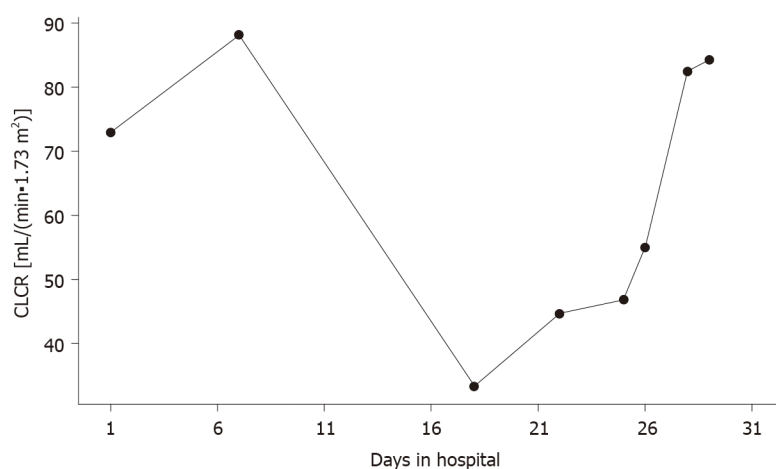


Figure 3 Changes in creatinine clearance during hospitalization. CLCR: Creatinine clearance.

CONCLUSION

A rare case of vancomycin-related convulsion in a pediatric patient with neuroblastoma receiving chemotherapy is reported. Physiological conditions in children with tumors and receiving anti-tumor chemotherapy may be different to other patients. The dosing strategy of antibiotics, especially those with a narrow therapeutic window and greater toxicity, should be chosen with caution in this special patient group. Thorough evaluation and close monitoring should be conducted throughout the treatment process to decide if dosage adjustment is necessary. When unexpected convulsion occurs but cannot be explained by other causes, plasma and CSF drug concentrations should be measured to determine if the patient is intoxicated by prescribed drugs. Further research into the pharmacokinetics of vancomycin in pediatric patients receiving anti-tumor chemotherapy is warranted to generate more reliable evidence for better clinical practice.

REFERENCES

- 1 **Tsubota S**, Kadomatsu K. Origin and initiation mechanisms of neuroblastoma. *Cell Tissue Res* 2018; **372**: 211-221 [PMID: [29445860](#) DOI: [10.1007/s00441-018-2796-z](#)]
- 2 **Brodeur GM**. Neuroblastoma: biological insights into a clinical enigma. *Nat Rev Cancer* 2003; **3**: 203-216 [PMID: [12612655](#) DOI: [10.1038/nrc1014](#)]
- 3 **Maris JM**. Recent advances in neuroblastoma. *N Engl J Med* 2010; **362**: 2202-2211 [PMID: [20558371](#) DOI: [10.1056/NEJMra0804577](#)]
- 4 **Sharma R**, Mer J, Lion A, Vik TA. Clinical Presentation, Evaluation, and Management of Neuroblastoma. *Pediatr Rev* 2018; **39**: 194-203 [PMID: [29610427](#) DOI: [10.1542/pir.2017-0087](#)]
- 5 **Maris JM**, Mosse YP, Bradfield JP, Hou C, Monni S, Scott RH, Asgharzadeh S, Attiye EF, Diskin SJ, Laudenslager M, Winter C, Cole KA, Glessner JT, Kim C, Frackelton EC, Casalunovo T, Eckert AW, Capasso M, Rappaport EF, McConville C, London WB, Seeger RC, Rahman N, Devoto M, Grant SF, Li H, Hakonarson H. Chromosome 6p22 Locus associated with clinically aggressive neuroblastoma. *N Engl J Med* 2008; **358**: 2585-2593 [PMID: [18463370](#) DOI: [10.1056/NEJMoa0708698](#)]
- 6 **Aygun N**. Biological and Genetic Features of Neuroblastoma and Their Clinical Importance. *Curr Pediatr Rev* 2018; **14**: 73-90 [PMID: [29380702](#) DOI: [10.2174/1573396314666180129101627](#)]
- 7 **Ward E**, DeSantis C, Robbins A, Kohler B, Jemal A. Childhood and adolescent cancer statistics, 2014. *CA Cancer J Clin* 2014; **64**: 83-103 [PMID: [24488779](#) DOI: [10.3322/caac.21219](#)]
- 8 **Twist CJ**, Schmidt ML, Naranjo A, London WB, Tenney SC, Marachelian A, Shimada H, Collins MH, Esiasvili N, Adkins ES, Mattei P, Handler M, Katzenstein H, Attiye E, Hogarty MD, Gastier-Foster J, Wagner E, Matthay KK, Park JR, Maris JM, Cohn SL. Maintaining Outstanding Outcomes Using Response- and Biology-Based Therapy for Intermediate-Risk Neuroblastoma: A Report From the Children's Oncology Group Study ANBL0531. *J Clin Oncol* 2019; **37**: 3243-3255 [PMID: [31386611](#) DOI: [10.1200/JCO.19.00919](#)]
- 9 **Ladenstein R**, Pötschger U, Pearson ADJ, Brock P, Luksch R, Castel V, Yaniv I, Papadakis V, Laureys G, Malis J, Balwierz W, Ruud E, Kogner P, Schroeder H, de Lacerda AF, Beck-Popovic M, Bician P, Garami M, Trahair T, Canete A, Ambros PF, Holmes K, Gaze M, Schreier G, Garaventa A, Vassal G, Michon J, Valteau-Couanet D; SIOP Europe Neuroblastoma Group (SIOPEN). Busulfan and melphalan vs carboplatin, etoposide, and melphalan as high-dose chemotherapy for high-risk neuroblastoma (HR-NBL1/SIOPEN): an international, randomised, multi-arm, open-label, phase 3 trial. *Lancet Oncol* 2017; **18**: 500-514 [PMID: [28259608](#) DOI: [10.1016/S1470-2045\(17\)30070-0](#)]
- 10 **Twist CJ**, Naranjo A, Schmidt ML, Tenney SC, Cohn SL, Meany HJ, Mattei P, Adkins ES, Shimada H, London WB, Park JR, Matthay KK, Maris JM. Defining Risk Factors for Chemotherapeutic Intervention in Infants With Stage 4S Neuroblastoma: A Report From Children's Oncology Group Study ANBL0531. *J Clin Oncol* 2019; **37**: 115-124 [PMID: [30444686](#) DOI: [10.1200/JCO.18.00419](#)]
- 11 **Kushner BH**, LaQuaglia MP, Bonilla MA, Lindsley K, Rosenfield N, Yeh S, Eddy J, Gerald WL, Heller G, Cheung NK. Highly effective induction therapy for stage 4 neuroblastoma in children over 1 year of age. *J Clin Oncol* 1994; **12**: 2607-2613 [PMID: [7527454](#) DOI: [10.1200/JCO.1994.12.12.2607](#)]
- 12 **London WB**, Frantz CN, Campbell LA, Seeger RC, Brumback BA, Cohn SL, Matthay KK, Castleberry RP, Diller L. Phase II randomized comparison of topotecan plus cyclophosphamide vs topotecan alone in children with recurrent or refractory neuroblastoma: a Children's Oncology Group study. *J Clin Oncol* 2010; **28**: 3808-3815 [PMID: [20660830](#) DOI: [10.1200/JCO.2009.27.5016](#)]
- 13 **Rujkijyanont P**, Photia A, Traivaree C, Monsereenusorn C, Anurathapan U, Seksarn P, Sosothikul D, Techavichit P, Sanpakit K, Phuakpet K, Wiangnon S, Chotsampancharoen T, Chainansamit SO, Kanjanapongkul S, Meekaewkunchorn A, Hongeng S. Clinical outcomes and prognostic factors to predict treatment response in high risk neuroblastoma patients receiving topotecan and cyclophosphamide containing induction regimen: a prospective multicenter study. *BMC Cancer* 2019; **19**: 961 [PMID: [31619207](#) DOI: [10.1186/s12885-019-6186-z](#)]
- 14 **Millan X**, Muggia V, Ostrowsky B. Antimicrobial agents, drug adverse reactions and interactions, and cancer. *Cancer Treat Res* 2014; **161**: 413-462 [PMID: [24706233](#) DOI: [10.1007/978-3-319-04220-6_14](#)]
- 15 **Dehority W**. Use of vancomycin in pediatrics. *Pediatr Infect Dis J* 2010; **29**: 462-464 [PMID: [20431384](#) DOI: [10.1097/INF.0b013e3181db7398](#)]
- 16 **Sullins AK**, Abdel-Rahman SM. Pharmacokinetics of antibacterial agents in the CSF of children and adolescents. *Paediatr Drugs* 2013; **15**: 93-117 [PMID: [23529866](#) DOI: [10.1007/s40272-013-0017-5](#)]
- 17 **Bruniera FR**, Ferreira FM, Savioli LR, Bacci MR, Feder D, da Luz Gonçalves Pedreira M, Sorgini Peterlini MA, Azzalis LA, Campos Junqueira VB, Fonseca FL. The use of vancomycin with its therapeutic and adverse effects: a review. *Eur Rev Med Pharmacol Sci* 2015; **19**: 694-700 [PMID: [25753888](#)]
- 18 **Nau R**, Sörgel F, Eiffert H. Penetration of drugs through the blood-cerebrospinal fluid/blood-brain barrier for treatment of central nervous system infections. *Clin Microbiol Rev* 2010; **23**: 858-883 [PMID: [20930076](#) DOI: [10.1128/CMR.00007-10](#)]
- 19 **Rybak MJ**. The pharmacokinetic and pharmacodynamic properties of vancomycin. *Clin Infect Dis* 2006; **42** Suppl 1: S35-S39 [PMID: [16323118](#) DOI: [10.1086/491712](#)]
- 20 **Beach JE**, Perrott J, Turgeon RD, Ensom MHH. Penetration of Vancomycin into the Cerebrospinal Fluid: A Systematic Review. *Clin Pharmacokinet* 2017; **56**: 1479-1490 [PMID: [28528396](#) DOI: [10.1007/s40262-017-0548-y](#)]

- 21 **Rybak MJ**, Le J, Lodise TP, Levine DP, Bradley JS, Liu C, Mueller BA, Pai MP, Wong-Beringer A, Rotschafer JC, Rodvold KA, Maples HD, Lomaestro BM. Therapeutic monitoring of vancomycin for serious methicillin-resistant *Staphylococcus aureus* infections: A revised consensus guideline and review by the American Society of Health-System Pharmacists, the Infectious Diseases Society of America, the Pediatric Infectious Diseases Society, and the Society of Infectious Diseases Pharmacists. *Am J Health Syst Pharm* 2020; **77**: 835-864 [PMID: [32191793](#) DOI: [10.1093/ajhp/zxaa036](#)]
- 22 **Leibowitz G**, Golan D, Jeshurun D, Brezis M. Mononeuritis multiplex associated with prolonged vancomycin treatment. *BMJ* 1990; **300**: 1344 [PMID: [2164433](#) DOI: [10.1136/bmj.300.6735.1344-b](#)]
- 23 **Thompson CM Jr**, Long SS, Gilligan PH, Prebis JW. Absorption of oral vancomycin - possible associated toxicity. *Int J Pediatr Nephrol* 1983; **4**: 1-4 [PMID: [6853034](#)]
- 24 **Caglayan S**, Ozdogru E, Aksit S, Kansoy S, Senturk H. Vancomycin-induced hypertension with transient blindness and generalized seizure. *Acta Paediatr Jpn* 1992; **34**: 90-91 [PMID: [1580160](#) DOI: [10.1111/j.1442-200x.1992.tb00932.x](#)]
- 25 **Brodeur GM**, Pritchard J, Berthold F, Carlsen NL, Castel V, Castelberry RP, De Bernardi B, Evans AE, Favrot M, Hedborg F. Revisions of the international criteria for neuroblastoma diagnosis, staging, and response to treatment. *J Clin Oncol* 1993; **11**: 1466-1477 [PMID: [8336186](#) DOI: [10.1200/jco.1993.11.8.1466](#)]
- 26 **Gavvala JR**, Schuele SU. New-Onset Seizure in Adults and Adolescents: A Review. *JAMA* 2016; **316**: 2657-2668 [PMID: [28027373](#) DOI: [10.1001/jama.2016.18625](#)]
- 27 **Kotsopoulos I**, de Krom M, Kessels F, Lodder J, Troost J, Twellaar M, van Merode T, Knottnerus A. Incidence of epilepsy and predictive factors of epileptic and non-epileptic seizures. *Seizure* 2005; **14**: 175-182 [PMID: [15797352](#) DOI: [10.1016/j.seizure.2005.01.005](#)]
- 28 **Mehta A**, Zusman BE, Choxi R, Shutter LA, Yassin A, Antony A, Thirumala PD. Seizures After Intracerebral Hemorrhage: Incidence, Risk Factors, and Impact on Mortality and Morbidity. *World Neurosurg* 2018; **112**: e385-e392 [PMID: [29355799](#) DOI: [10.1016/j.wneu.2018.01.052](#)]
- 29 **Leung H**, Man CB, Hui AC, Kwan P, Wong KS. Prognosticating acute symptomatic seizures using two different seizure outcomes. *Epilepsia* 2010; **51**: 1570-1579 [PMID: [20002147](#) DOI: [10.1111/j.1528-1167.2009.02409.x](#)]
- 30 **Suzuki Y**, Kawasaki K, Sato Y, Tokimatsu I, Itoh H, Hiramatsu K, Takeyama M, Kadota J. Is peak concentration needed in therapeutic drug monitoring of vancomycin? *Chemotherapy* 2012; **58**: 308-312 [PMID: [23147106](#) DOI: [10.1159/000343162](#)]
- 31 **Fiorito TM**, Luther MK, Dennehy PH, LaPlante KL, Matson KL. Nephrotoxicity With Vancomycin in the Pediatric Population: A Systematic Review and Meta-Analysis. *Pediatr Infect Dis J* 2018; **37**: 654-661 [PMID: [29280786](#) DOI: [10.1097/INF.0000000000001882](#)]
- 32 **Mian AN**, Schwartz GJ. Measurement and Estimation of Glomerular Filtration Rate in Children. *Adv Chronic Kidney Dis* 2017; **24**: 348-356 [PMID: [29229165](#) DOI: [10.1053/j.ackd.2017.09.011](#)]
- 33 **Jorgenson L**, Reiter PD, Freeman JE, Winston KR, Fish D, McBride LA, Handler MH. Vancomycin disposition and penetration into ventricular fluid of the central nervous system following intravenous therapy in patients with cerebrospinal devices. *Pediatr Neurosurg* 2007; **43**: 449-455 [PMID: [17992031](#) DOI: [10.1159/000108786](#)]
- 34 **Pau AK**, Smego RA Jr, Fisher MA. Intraventricular vancomycin: observations of tolerance and pharmacokinetics in two infants with ventricular shunt infections. *Pediatr Infect Dis* 1986; **5**: 93-96 [PMID: [3945581](#)]
- 35 **Banks WA**. From blood-brain barrier to blood-brain interface: new opportunities for CNS drug delivery. *Nat Rev Drug Discov* 2016; **15**: 275-292 [PMID: [26794270](#) DOI: [10.1038/nrd.2015.21](#)]
- 36 **Stahl JP**, Croize J, Wolff M, Garaud JJ, Leclercq P, Vachon F, Micoud M. Poor penetration of teicoplanin into cerebrospinal fluid in patients with bacterial meningitis. *J Antimicrob Chemother* 1987; **20**: 141-142 [PMID: [2957347](#) DOI: [10.1093/jac/20.1.141](#)]
- 37 **Byrne CJ**, Roberts JA, McWhinney B, Fennell JP, O'Byrne P, Deasy E, Egan S, Desmond R, Enright H, Ryder SA, D'Arcy DM, McHugh J. Variability in Trough Total and Unbound Teicoplanin Concentrations and Achievement of Therapeutic Drug Monitoring Targets in Adult Patients with Hematological Malignancy. *Antimicrob Agents Chemother* 2017; **61** [PMID: [28320714](#) DOI: [10.1128/AAC.02466-16](#)]
- 38 **Cavalcanti AB**, Goncalves AR, Almeida CS, Bugano DD, Silva E. Teicoplanin vs vancomycin for proven or suspected infection. *Cochrane Database Syst Rev* 2010: CD007022 [PMID: [20556772](#) DOI: [10.1002/14651858.CD007022.pub2](#)]



Published by **Baishideng Publishing Group Inc**
7041 Koll Center Parkway, Suite 160, Pleasanton, CA 94566, USA

Telephone: +1-925-3991568

E-mail: bpgoffice@wjgnet.com

Help Desk: <https://www.f6publishing.com/helpdesk>

<https://www.wjgnet.com>

