

# World Journal of *Clinical Cases*

*World J Clin Cases* 2021 May 6; 9(13): 2951-3226



## Contents

Thrice Monthly Volume 9 Number 13 May 6, 2021

## REVIEW

- 2951 Patients with cirrhosis during the COVID-19 pandemic: Current evidence and future perspectives  
*Su HY, Hsu YC*

## MINIREVIEWS

- 2969 Immunotherapy for pancreatic cancer  
*Yoon JH, Jung YJ, Moon SH*

## ORIGINAL ARTICLE

## Retrospective Study

- 2983 Scrotal septal flap and two-stage operation for complex hypospadias: A retrospective study  
*Chen S, Yang Z, Ma N, Wang WX, Xu LS, Liu QY, Li YQ*
- 2994 Clinical diagnosis of severe COVID-19: A derivation and validation of a prediction rule  
*Tang M, Yu XX, Huang J, Gao JL, Cen FL, Xiao Q, Fu SZ, Yang Y, Xiong B, Pan YJ, Liu YX, Feng YW, Li JX, Liu Y*
- 3008 Prognostic value of hemodynamic indices in patients with sepsis after fluid resuscitation  
*Xu HP, Zhuo XA, Yao JJ, Wu DY, Wang X, He P, Ouyang YH*

## Observational Study

- 3014 Updated Kimura-Takemoto classification of atrophic gastritis  
*Kotelevets SM, Chekh SA, Chukov SZ*

## SYSTEMATIC REVIEWS

- 3024 Systematic review and meta-analysis of the impact of deviations from a clinical pathway on outcomes following pancreatoduodenectomy  
*Karunakaran M, Jonnada PK, Barreto SG*

## META-ANALYSIS

- 3038 Early vs late cholecystectomy in mild gall stone pancreatitis: An updated meta-analysis and review of literature  
*Walayat S, Baig M, Puli SR*

## CASE REPORT

- 3048 Effects of intravascular laser phototherapy on delayed neurological sequelae after carbon monoxide intoxication as evaluated by brain perfusion imaging: A case report and review of the literature  
*Liu CC, Hsu CS, He HC, Cheng YY, Chang ST*

- 3056** *Crumbs homolog 2* mutation in two siblings with steroid-resistant nephrotic syndrome: Two case reports  
*Lu J, Guo YN, Dong LQ*
- 3063** Intracortical chondroma of the metacarpal bone: A case report  
*Yoshida Y, Anazawa U, Watanabe I, Hotta H, Aoyama R, Suzuki S, Nagura T*
- 3070** Vancomycin-related convulsion in a pediatric patient with neuroblastoma: A case report and review of the literature  
*Ye QF, Wang GF, Wang YX, Lu GP, Li ZP*
- 3079** Pulmonary arterial hyper-tension in a patient with hereditary hemorrhagic telangiectasia and family gene analysis: A case report  
*Wu J, Yuan Y, Wang X, Shao DY, Liu LG, He J, Li P*
- 3090** Misdiagnosed dystrophic epidermolysis bullosa pruriginosa: A case report  
*Wang Z, Lin Y, Duan XW, Hang HY, Zhang X, Li LL*
- 3095** Spontaneous coronary dissection should not be ignored in patients with chest pain in autosomal dominant polycystic kidney disease: A case report  
*Qian J, Lai Y, Kuang LJ, Chen F, Liu XB*
- 3102** Sarcomatoid carcinoma of the pancreas — multimodality imaging findings with serial imaging follow-up: A case report and review of literature  
*Lim HJ, Kang HS, Lee JE, Min JH, Shin KS, You SK, Kim KH*
- 3114** Acute pancreatitis and small bowel obstruction caused by a migratory gastric bezoar after dissolution therapy: A case report  
*Wang TT, He JJ, Liu J, Chen WW, Chen CW*
- 3120** Intracardiac, pulmonary cement embolism in a 67-year-old female after cement-augmented pedicle screw instrumentation: A case report and review of literature  
*Liang TZ, Zhu HP, Gao B, Peng Y, Gao WJ*
- 3130** Acute urinary retention in the first and second-trimester of pregnancy: Three case reports  
*Zhuang L, Wang XY, Sang Y, Xu J, He XL*
- 3140** Sarcoidosis mimicking metastases in an echinoderm microtubule-associated protein-like 4 anaplastic lymphoma kinase positive non-small-lung cancer patient: A case report  
*Chen X, Wang J, Han WL, Zhao K, Chen Z, Zhou JY, Shen YH*
- 3147** Three-dimensional printed talar prosthesis with biological function for giant cell tumor of the talus: A case report and review of the literature  
*Yang QD, Mu MD, Tao X, Tang KL*
- 3157** Successful upgrade to cardiac resynchronization therapy for cardiac implantation-associated left subclavian vein occlusion: A case report  
*Zhong JY, Zheng XW, Li HD, Jiang LF*

- 3163** Sodium-glucose co-transporter-2 inhibitor-associated euglycemic diabetic ketoacidosis that prompted the diagnosis of fulminant type-1 diabetes: A case report  
*Yasuma T, Okano Y, Tanaka S, Nishihama K, Eguchi K, Inoue C, Maki K, Uchida A, Uemura M, Suzuki T, D'Alessandro-Gabazza CN, Gabazza EC, Yano Y*
- 3170** Perioperative massive cerebral stroke in thoracic patients: Report of three cases  
*Jian MY, Liang F, Liu HY, Han RQ*
- 3177** Renal artery embolization in the treatment of urinary fistula after renal duplication: A case report and review of literature  
*Yang T, Wen J, Xu TT, Cui WJ, Xu J*
- 3185** Clinical characteristics of intrahepatic biliary papilloma: A case report  
*Yi D, Zhao LJ, Ding XB, Wang TW, Liu SY*
- 3194** Association between scrub typhus encephalitis and diffusion tensor tractography detection of Papez circuit injury: A case report  
*Kwon HG, Yang JH, Kwon JH, Yang D*
- 3200** Alström syndrome with a novel mutation of *ALMS1* and Graves' hyperthyroidism: A case report and review of the literature  
*Zhang JJ, Wang JQ, Sun MQ, Xu D, Xiao Y, Lu WL, Dong ZY*
- 3212** Laparoscopic uncontained power morcellation-induced dissemination of ovarian endodermal sinus tumors: A case report  
*Oh HK, Park SN, Kim BR*
- 3219** Treatment of acute severe ulcerative colitis using accelerated infliximab regimen based on infliximab trough level: A case report  
*Garate ALSV, Rocha TB, Almeida LR, Quera R, Barros JR, Baima JP, Saad-Hossne R, Sassaki LY*

**ABOUT COVER**

Editorial Board Member of *World Journal of Clinical Cases*, Rama R Vunnam, MBBS, MD, Assistant Professor, Department of Medicine, Penn State Health Milton S. Hershey Medical Center, Hershey, PA 17033, United States. [rvunnam@pennstatehealth.psu.edu](mailto:rvunnam@pennstatehealth.psu.edu)

**AIMS AND SCOPE**

The primary aim of *World Journal of Clinical Cases* (WJCC, *World J Clin Cases*) is to provide scholars and readers from various fields of clinical medicine with a platform to publish high-quality clinical research articles and communicate their research findings online.

WJCC mainly publishes articles reporting research results and findings obtained in the field of clinical medicine and covering a wide range of topics, including case control studies, retrospective cohort studies, retrospective studies, clinical trials studies, observational studies, prospective studies, randomized controlled trials, randomized clinical trials, systematic reviews, meta-analysis, and case reports.

**INDEXING/ABSTRACTING**

The WJCC is now indexed in Science Citation Index Expanded (also known as SciSearch®), Journal Citation Reports/Science Edition, Scopus, PubMed, and PubMed Central. The 2020 Edition of Journal Citation Reports® cites the 2019 impact factor (IF) for WJCC as 1.013; IF without journal self cites: 0.991; Ranking: 120 among 165 journals in medicine, general and internal; and Quartile category: Q3. The WJCC's CiteScore for 2019 is 0.3 and Scopus CiteScore rank 2019: General Medicine is 394/529.

**RESPONSIBLE EDITORS FOR THIS ISSUE**

Production Editor: Yan-Xia Xing, Production Department Director: Yun-Xiaoqian Wu, Editorial Office Director: Jin-Lai Wang.

**NAME OF JOURNAL**

*World Journal of Clinical Cases*

**ISSN**

ISSN 2307-8960 (online)

**LAUNCH DATE**

April 16, 2013

**FREQUENCY**

Thrice Monthly

**EDITORS-IN-CHIEF**

Dennis A Bloomfield, Sandro Vento, Bao-Gan Peng

**EDITORIAL BOARD MEMBERS**

<https://www.wjgnet.com/2307-8960/editorialboard.htm>

**PUBLICATION DATE**

May 6, 2021

**COPYRIGHT**

© 2021 Baishideng Publishing Group Inc

**INSTRUCTIONS TO AUTHORS**

<https://www.wjgnet.com/bpg/gerinfo/204>

**GUIDELINES FOR ETHICS DOCUMENTS**

<https://www.wjgnet.com/bpg/GerInfo/287>

**GUIDELINES FOR NON-NATIVE SPEAKERS OF ENGLISH**

<https://www.wjgnet.com/bpg/gerinfo/240>

**PUBLICATION ETHICS**

<https://www.wjgnet.com/bpg/GerInfo/288>

**PUBLICATION MISCONDUCT**

<https://www.wjgnet.com/bpg/gerinfo/208>

**ARTICLE PROCESSING CHARGE**

<https://www.wjgnet.com/bpg/gerinfo/242>

**STEPS FOR SUBMITTING MANUSCRIPTS**

<https://www.wjgnet.com/bpg/GerInfo/239>

**ONLINE SUBMISSION**

<https://www.f6publishing.com>



## Clinical characteristics of intrahepatic biliary papilloma: A case report

Dan Yi, Li-Jing Zhao, Xiao-Bo Ding, Tai-Wei Wang, Song-Yang Liu

**ORCID number:** Dan Yi 0000-0002-2626-3517; Li-Jing Zhao 0000-0002-3190-7399; Xiao-Bo Ding 0000-0001-8902-7207; Tai-Wei Wang 0000-0002-6164-9132; Song-Yang Liu 0000-0002-4202-5850.

**Author contributions:** Yi D was a major contributor to data acquisition, literature retrieval and manuscript writing; Ding XB contributed to the acquisition of screening and imaging data; Wang TW contributed to the analysis of materials and the modification of the manuscript; Zhao LJ and Liu SY made important modifications to the manuscript; All authors read and approved the final manuscript.

**Informed consent statement:** All included patients gave written and oral informed consent for publication.

**Conflict-of-interest statement:** The authors declare no conflicts of interest.

**CARE Checklist (2016) statement:** The authors have read the CARE Checklist (2016), and the manuscript was prepared and revised according to the CARE Checklist (2016).

**Open-Access:** This article is an open-access article that was selected by an in-house editor and fully peer-reviewed by external

**Dan Yi, Song-Yang Liu,** Department of Hepatobiliary and Pancreatic Surgery, The First Hospital of Jilin University, Changchun 130012, Jilin Province, China

**Li-Jing Zhao, Tai-Wei Wang,** Department of Rehabilitation, School of Nursing, Jilin University, Changchun 130012, Jilin Province, China

**Xiao-Bo Ding,** Department of Radiology, The First Hospital of Jilin University, Changchun 130012, Jilin Province, China

**Corresponding author:** Song-Yang Liu, MD, PhD, Chief Physician, Professor, Department of Hepatobiliary and Pancreatic Surgery, The First Hospital of Jilin University, No. 71 Xinmin Street, Changchun 130021, China. [liusongyang@126.com](mailto:liusongyang@126.com)

### Abstract

#### BACKGROUND

Intrahepatic bile duct papilloma (IPNB) is a rare benign tumour from the bile duct epithelium and has a high malignant transformation rate. Early radical resection can obviously improve the prognosis of patients, but it is difficult to be sure of the diagnosis of IPNB before operating.

#### CASE SUMMARY

This study included 28 patients with intraductal papilloma admitted to the First Hospital of Jilin University from January 2010 to November 2020 and recorded their clinical manifestations, imaging features, complications and prognosis. There were 12 males and 16 females with an average age of  $61.36 \pm 8.03$  years. Most patients had symptoms of biliary obstruction. Biliary dilatation and cystic mass could be seen on imaging. After surgery, IPNB was diagnosed by pathology.

#### CONCLUSION

IPNB is a rare benign tumour in the bile duct. Early diagnosis and timely R0 resection can improve the prognosis of IPNB.

**Key Words:** Intrahepatic bile duct; Papillary tumour; Biliary obstruction; Mural nodules; Case report

©The Author(s) 2021. Published by Baishideng Publishing Group Inc. All rights reserved.

reviewers. It is distributed in accordance with the Creative Commons Attribution NonCommercial (CC BY-NC 4.0) license, which permits others to distribute, remix, adapt, build upon this work non-commercially, and license their derivative works on different terms, provided the original work is properly cited and the use is non-commercial. See: <http://creativecommons.org/licenses/by-nc/4.0/>

**Manuscript source:** Unsolicited manuscript

**Specialty type:** Gastroenterology and hepatology

**Country/Territory of origin:** China

**Peer-review report's scientific quality classification**

Grade A (Excellent): 0  
Grade B (Very good): 0  
Grade C (Good): C, C  
Grade D (Fair): D  
Grade E (Poor): 0

**Received:** December 10, 2020

**Peer-review started:** December 10, 2020

**First decision:** January 27, 2021

**Revised:** January 30, 2021

**Accepted:** February 25, 2021

**Article in press:** February 25, 2021

**Published online:** May 6, 2021

**P-Reviewer:** Hokuto D, Jabi R, Minaga K

**S-Editor:** Zhang H

**L-Editor:** Filipodia

**P-Editor:** Li JH



**Core Tip:** Intrahepatic bile duct papilloma (IPNB) is a rare benign tumour in the bile duct. An early radical operation can improve the prognosis. This study analysed the clinical manifestations, imaging features, complications and prognosis of IPNB. IPNB should be considered in patients with bile duct recurrent infection, cholestasis and biliary obstruction, if imaging examination shows cystic dilatation of the bile duct, if there are mural nodules or papillary tumours with delayed enhancement, if the cystic-solid tumours communicate with the bile duct and if the upstream and downstream bile ducts dilate.

**Citation:** Yi D, Zhao LJ, Ding XB, Wang TW, Liu SY. Clinical characteristics of intrahepatic biliary papilloma: A case report. *World J Clin Cases* 2021; 9(13): 3185-3193

**URL:** <https://www.wjgnet.com/2307-8960/full/v9/i13/3185.htm>

**DOI:** <https://dx.doi.org/10.12998/wjcc.v9.i13.3185>

## INTRODUCTION

Intrabiliary papilloma is a rare benign tumour from the bile duct epithelium that has been gradually recognized by surgeons in recent years. In 2019, the World Health Organization defined it as “a grossly visible premalignant neoplasm with intraductal papillary or villous growth of biliary-type epithelium”<sup>[1]</sup>. Therefore, intrahepatic bile duct papilloma (IPNB) is a precancerous lesion or early tumour lesion that is characterized by an intraluminal papillary tumour with a fibrovascular core in the dilated bile duct<sup>[2]</sup>. However, it has been reported that the malignant transformation rate of IPNB can be as high as 41%-83%<sup>[3]</sup>. Because it takes 1-2 years for precancerous lesions to transform into invasive carcinoma, there is sufficient time for surgical treatment.

Kim *et al*<sup>[4]</sup> showed that the 3-year overall survival rate of patients with IPNB who underwent R0 surgery was 91.3%, and the 5-year overall survival rate was as high as 68.8%. Therefore, early diagnosis, active R0 resection and avoidance of positive biliary tract margins are the primary ways to ensure long-term survival in patients with IPNB<sup>[1]</sup>. However, it is difficult to diagnose IPNB before surgery, and it is often misdiagnosed as cholangiocarcinoma before surgery, which leads to increased fear of patients and their families, poor willingness to actively treat and even the opportunity for surgical treatment. Therefore, patients with IPNB lose the best treatment time, and at the same time, their quality of life and survival time are reduced.

This study summarized and analysed the clinical data of 28 patients diagnosed with IPNB for the first time at the First Hospital of Jilin University from January 2010 to November 2020 to improve doctors' understanding of IPNB and improve the preoperative diagnosis rate.

## CASE PRESENTATION

### Chief complaints

Eighteen patients (64.29%) showed epigastric pain, and three of them had yellow staining of the skin and sclera. Another 4 patients (14.29%) only showed yellow staining of the skin and sclera. Five patients (17.86%) had no obvious clinical manifestations.

### History of present illness

Five patients (17.86%) came to see a doctor because of abdominal diseases found in physical examination.

Seven patients (25%) were referred to our hospital for jaundice reduction due to obstructive jaundice. Among them, 5 patients (17.86%) underwent ultrasound-guided intrahepatic bile duct puncture and drainage in local hospitals, and 2 patients (7.14%) underwent endoscopic retrograde cholangiopancreatography nasobiliary drainage in local hospitals. The other 16 patients (57.14%) did not receive other treatment, and they visited our hospital for the first time.

**History of past illness**

Four patients (14.29%) had undergone cholecystectomy for gallstones. One patient had undergone laparoscopic cholecystectomy for choledocholithiasis. One patient (3.57%) had undergone a radical operation for colon cancer.

**Personal and family history**

All patients had no personal family history.

**Physical examination**

Eighteen patients (28.57%) had upper abdominal tenderness. Seven patients (25%) had yellow staining of the skin and sclera.

**Laboratory examinations**

The CA19-9 of 13 patients was higher than normal, among which 12 patients (92.3%) were diagnosed as IPNB invasive carcinoma and 1 patient (7.7%) was IPNB high-grade intraepithelial neoplasia. The total bilirubin level of 11 patients (39.29%) increased.

**Imaging examinations**

Twenty-six patients underwent abdominal enhanced computed tomography (CT) examination. Ten patients (35.71%) were examined by cholangiography. According to the results of the imaging examination, 12 cases (42.86%) showed cystic and solid tumours communicating with the bile duct, 8 cases (28.57%) showed soft tissue nodules, and 23 cases (82.14%) showed obvious dilatation of the bile duct. However, only 4 patients (14.29%) were diagnosed as intrahepatic bile duct papilloma by imaging doctor before operation. Seventeen cases (60.71%) were considered cholangiocarcinoma or liver cancer, 4 cases (14.29%) as bile duct dilatation, 1 case (3.57%) as bile duct cystadenocarcinoma, and 1 case (3.57%) as intrahepatic bile duct stones.

---

**ACCOMPANYING RELATED DISEASES**

---

Thirteen patients (46.43%) had bile duct stones, 7 patients (25%) had hepatitis, 3 patients (10.71%) had gallstones, 2 patients (7.14%) had sclerosing cholangitis, and 1 patient (3.57%) had bile duct cysts.

---

**FINAL DIAGNOSIS**

---

All cases were confirmed as papillary tumours of the intrahepatic bile duct by postoperative pathology. Among them, 11 cases (39.29%) were high-grade intraepithelial neoplasia, and 17 cases (60.71%) were IPNB invasive carcinoma (Figure 1).

---

**TREATMENT**

---

All patients underwent radical surgical resection. Rapid pathological examination was performed during operation to realize R0 resection. Choledochoscopy was performed in some patients during operation (Table 1 and Figure 2).

---

**OUTCOME AND FOLLOW-UP**

---

Patients were followed up for 3 years after discharge. Three patients died of multifunctional organ failure. The other patients had no recurrence and a good quality of life. The 3-year survival rate was 89.3%.

---

**DISCUSSION**

---

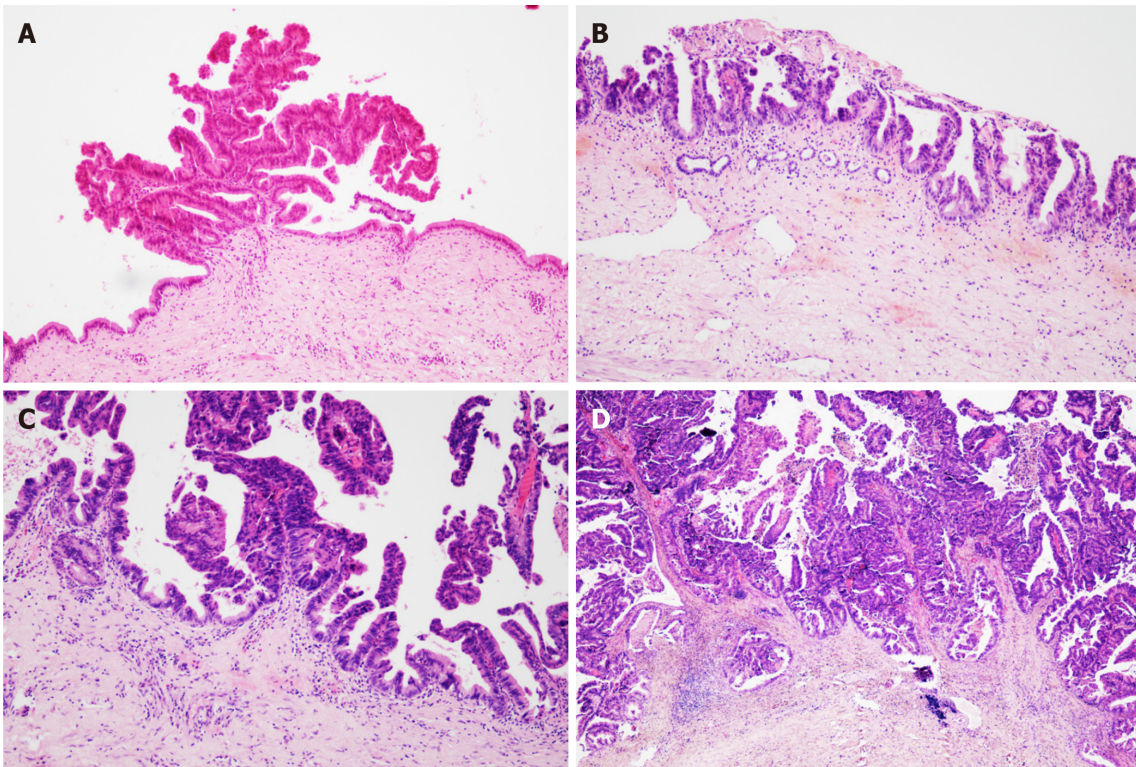
IPNB is a rare benign tumour in the bile duct that can secrete mucin in different

Table 1 General information

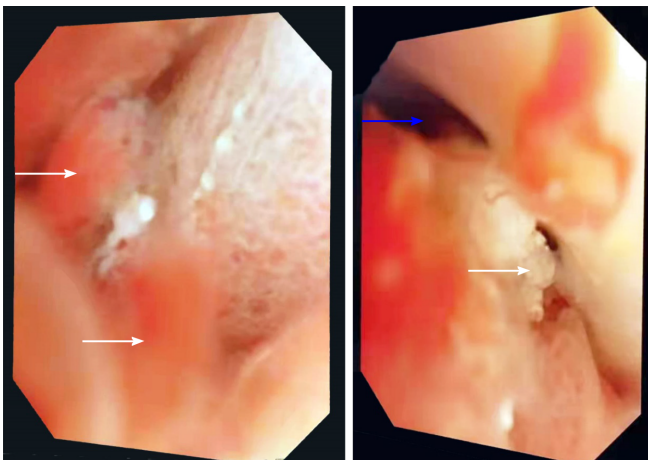
Number	Gender	Age	CA19-9	CEA	Chief complaint			Accompanying diseases	Pathological classification	Operation mode
					Abdominal pain	Jaundice	No symptoms			
1	Female	71	Normal	Normal	+	+			I	1234
2	Female	65	Normal	Normal	+			a	II	1
3	Female	74	↑	↑	+			ab	II	1234
4	Male	45	↑	Normal			+	b	II	1234
5	Male	71	↑	Normal			+		II	1235
6	Female	66	Normal	Normal	+			a	II	1235
7	Female	62	Normal	Normal	+			b	I	1246
8	Male	63	↑	Normal		+			II	1246
9	Male	57	Normal	Normal		+		e	I	135
10	Female	58	Normal	Normal	+				I	1246
11	Female	82	↑	Normal	+			b	II	1235
12	Female	67	Normal	Normal		+		ab	I	1246
13	Female	65	Normal	Normal	+				I	1
14	Male	52	↑	Normal	+	+		abe	II	1246
15	Female	60	Normal	Normal	+			b	II	1235
16	Male	59	Normal	Normal	+	+		b	II	1235
17	Female	70	Normal	Normal			+		I	12
18	Female	60	↑	Normal	+			b	II	124
19	Male	60	Normal	Normal			+	c	II	12
20	Female	58	↑	Normal	+			ab	II	14
21	Male	52	Normal	Normal			+		I	1246
22	Male	57	↑	Normal	+			b	II	123
23	Female	61	↑	Normal	+			b	II	135
24	Male	57	↑	Normal	+				II	1
25	Female	50	↑	Normal		+		c	II	1246
26	Male	51	Normal	Normal	+			ab	I	135
27	Female	58	Normal	Normal				d	I	1246
28	Male	67	↑	↑	+			c	I	1246

1: Partial hepatectomy; 2: Cholecystectomy; 3: Exploration of biliary tract; 4: Biliary-intestinal anastomosis; 5: T tube drainage; 6: Excision of upper segment of common bile duct; I: Intrahepatic bile duct papilloma (IPNB)'s high-grade intraepithelial neoplasia; II: IPN-B's invasive cancer; a: Hepatitis; b: Calculus of bile duct; c: Gallbladder stone; d: Biliary cyst; e: Sclerosing cholangitis. CA 19-9: Carbohydrate antigen 19-9; CEA: Carcinoembryonic antigen.

proportions. It is considered the counterpart in the biliary system of the pancreas intraductal papilloma<sup>[5]</sup>, which can affect any part of the biliary system, but it has been reported that it occurs in the hilar region<sup>[6]</sup>. In this study, 11 patients' lesions occurred in the intrahepatic bile duct combined with the hilar region, and 16 patients' lesions were only located in the left intrahepatic bile duct but did not invade the hilar region, which may be due to the fluidity of mucus secreted by IPNB and the dynamic evolution of the disease. According to the covered epithelial cells, IPNB can be divided into gastric type, intestinal type, pancreaticobiliary type and eosinophilic type<sup>[1]</sup>. According to pathological results, it can be divided into low-grade intraepithelial neoplasia, high-grade intraepithelial neoplasia and invasive tumour, and the former two are precancerous lesions. Wan-Joon Kim *et al*<sup>[4]</sup> others believe that this is a dynamic transition process from benign to malignant. According to the location, size



**Figure 1 Pathological images.** A: Intrahepatic bile duct papilloma (IPNB)'s atypical hyperplasia; B: IPNB's intraepithelial neoplasia; C: IPNB's focal carcinomatosis; D: IPNB's correlation with invasive cancer.



**Figure 2 Cholangioscope images.** White arrows indicate papillary nodules or bulges. The blue arrow indicates that myxoid bile is attached to the bile duct wall in a strip shape.

and mucin secretion degree of IPNB, some patients have biliary obstruction symptoms to different degrees, such as abdominal pain, yellow skin and sclera, fever, *etc.*<sup>[7]</sup>, and some patients have no obvious symptoms. The patients collected in this study are consistent with the above literature reports.

The pathogenesis of IPNB is not clear, but it may be related to repeated infection of the biliary tract and cholestasis<sup>[3]</sup>. It is worth mentioning that bile duct stones, *Clonorchis sinensis* infection, primary sclerosing cholangitis and biliary malformation are risk factors for IPNB<sup>[8]</sup>. Among the cases included in this study, 13 patients suffered from bile duct stones, 2 patients suffered from sclerosing cholangitis and 1 patient suffered from bile duct cysts. Long-term stimulation of the above factors can lead to hyperplasia of bile duct epithelial columnar cells and heterotopic tissues and further lead to papillary hyperplasia and the formation of papilloma.

The preoperative diagnosis of IPNB is mainly based on magnetic resonance imaging, CT and magnetic resonance cholangiopancreatography. Because of the different locations, sizes, shapes and mucin secretions of intrahepatic bile duct tumours, they present different imaging manifestations<sup>[6]</sup>, such as: (1) A tumour that is cystic in appearance, in which polypoid, lobulated or coral-like wall nodules can be seen, while in some patients, lump-like or papillary lesions can be seen; (2) The downstream bile duct is obviously dilated; and (3) Slight dilatation of the upstream bile duct is observed, which is also the characteristic manifestation of IPNB in CT examination<sup>[4,9]</sup>. However, in a few patients, nodule-like lesions are not obvious and are difficult to find by preoperative CT examination, which is also why preoperative diagnosis is difficult at present<sup>[6,10]</sup>. Siripongsakun *et al*<sup>[11]</sup> and other studies show that magnetic resonance imaging, as the most sensitive preoperative examination method of IPNB, has the following imaging features: (1) Cystic dilatation of the bile duct and small nodules in the catheter is observed; and (2) The lesion communicates with the bile duct, and the nodule grows into the bile duct cavity and is connected with the bile duct wall through the fibrovascular stalk<sup>[2,12]</sup>, showing a floating sign<sup>[13]</sup> (Figure 3).

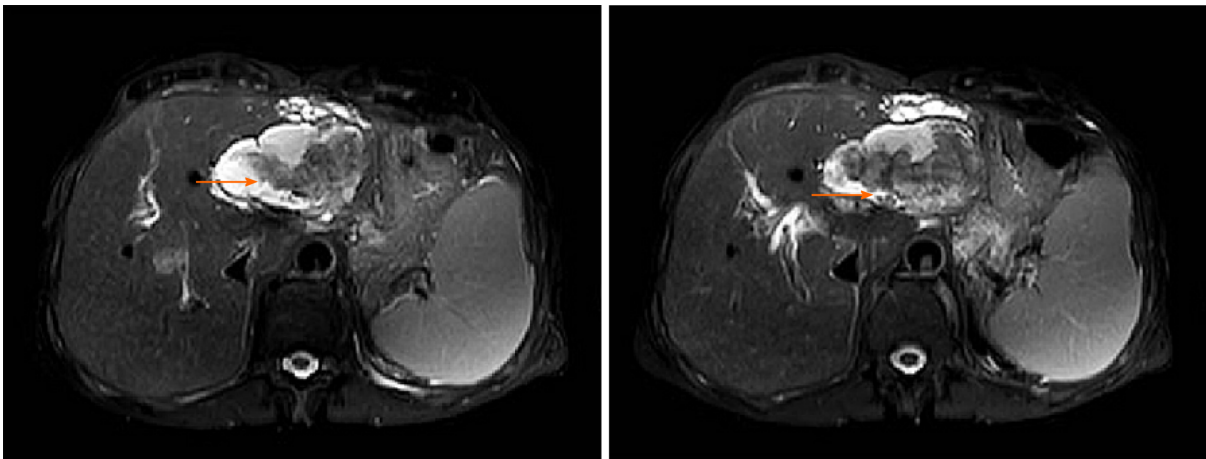
The imaging characteristics of the patients included in this study are consistent with the above report. CT showed that the cystic solid tumour had a smooth cystic wall in which the wall nodules distributed along the bile duct wall projected into the lumen but not out of the bile duct wall. The enhancement of parietal nodules was delayed, the enhancement of papilla was not obvious in the arterial phase, and the enhancement was delayed in the portal phase. Cystic components were not enhanced. Enlargement of the proximal and distal bile ducts was apparent. Magnetic resonance cholangiopancreatography and CT three-dimensional reconstruction characteristically showed that the tumour communicated with the bile duct (Figures 4 and 5). The mucus of the tumour can be distributed in any part of the bile duct, which leads to poor circulation of bile and dilatation of the bile duct, but the mucus cannot completely block all bile ducts, so there is communication with the bile duct. However, because cholangiocarcinoma can cause bile duct dilatation, the bile in the dilated bile duct is difficult to distinguish from IPNB mucus, so preoperative diagnosis is often misdiagnosed as space-occupying lesions of the bile duct.

To improve the accuracy of preoperative diagnosis, IPNB should be differentiated from cholangiocarcinoma and mucinous cystic tumours of the liver. Cholangiocarcinoma is characterized by an ill-defined mass invading into the liver, the distal bile duct showing dead tree-like changes and the tumour showing delayed enhancement<sup>[14]</sup> (Figure 5). Mucinous cystic tumours of the liver (MCN) tend to occur in women<sup>[15]</sup>, and most of these MCN do not communicate with the bile duct and have ovarian stroma<sup>[3]</sup> (Figure 6). In contrast, IPNB communicates with the bile duct and lacks ovarian stroma.

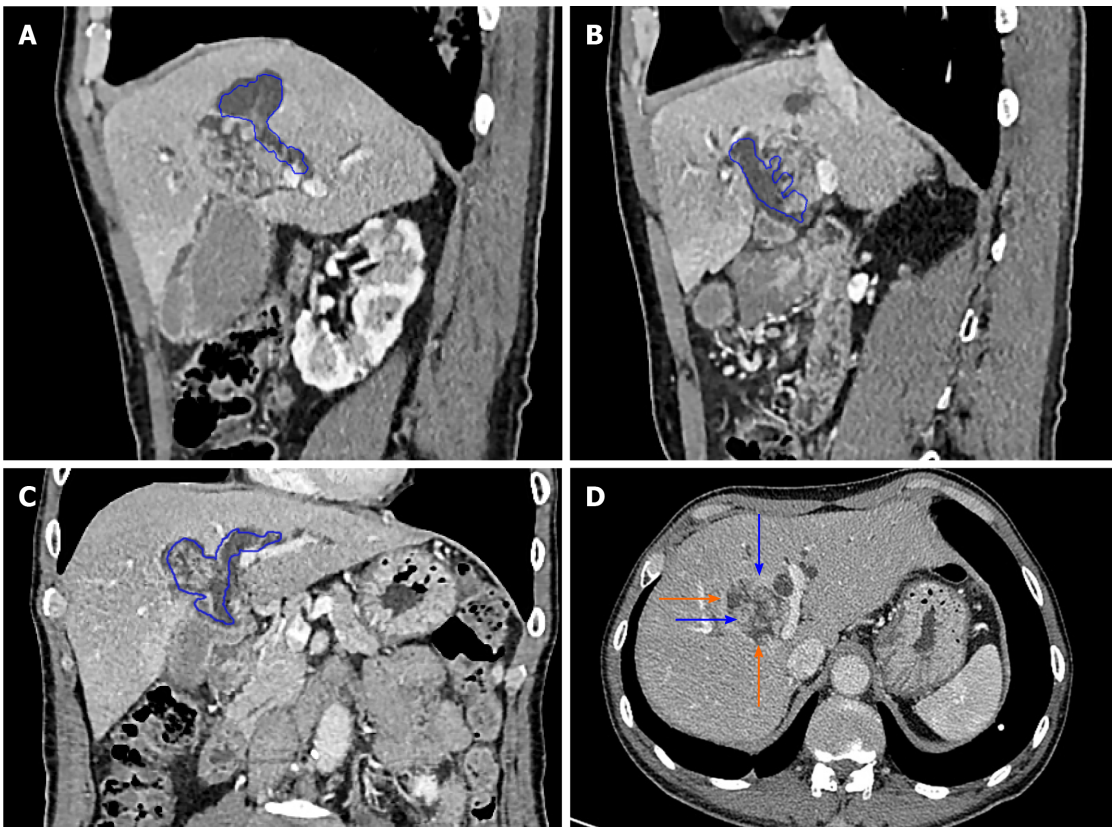
The level of serum carbohydrate antigen 19-9 (CA19-9) is increased in malignant tumours of the bile duct<sup>[16,17]</sup>. In this study, 70.59% of patients with IPNB invasive carcinoma had higher CA19-9 than normal. The CA19-9 of 9.09% patients with IPNB high-grade intraepithelial neoplasia was higher than the normal level (Chi-square test,  $P < 0.05$ ); therefore CA19-9 level in patients with IPNB invasive cancer is usually higher than normal level.

## CONCLUSION

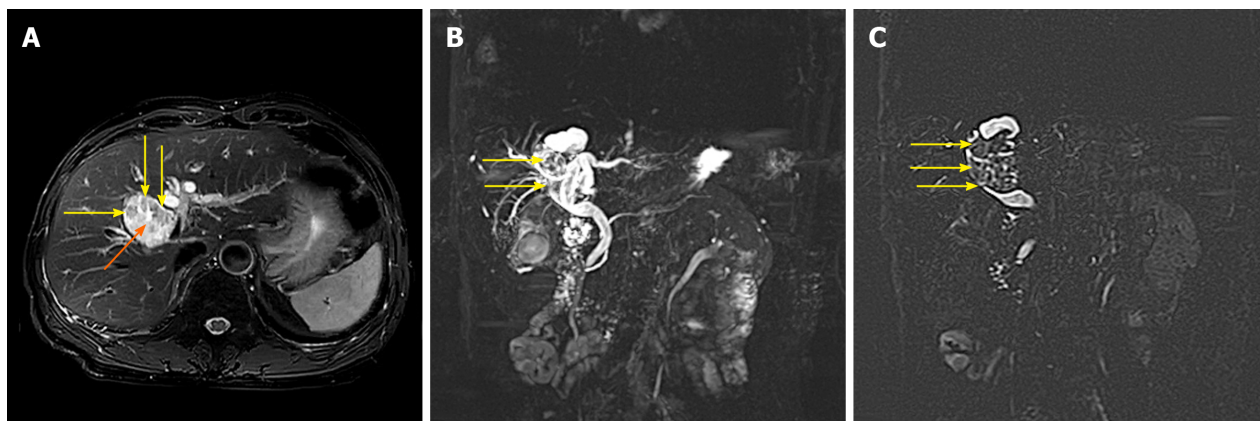
In summary, when patients have the following characteristics, doctors should be aware of the possibility of IPNB: (1) Symptoms of biliary obstruction; (2) Other diseases related to repeated infection of the biliary tract and cholestasis; and (3) Cystic dilatation of the bile duct in which wall nodules or papillary masses with delayed enhancement can be seen, cystic solid masses communicate with the bile duct and the upstream and downstream bile ducts are dilated. R0 surgery should be performed actively for patients with IPNB to obtain a good prognosis.



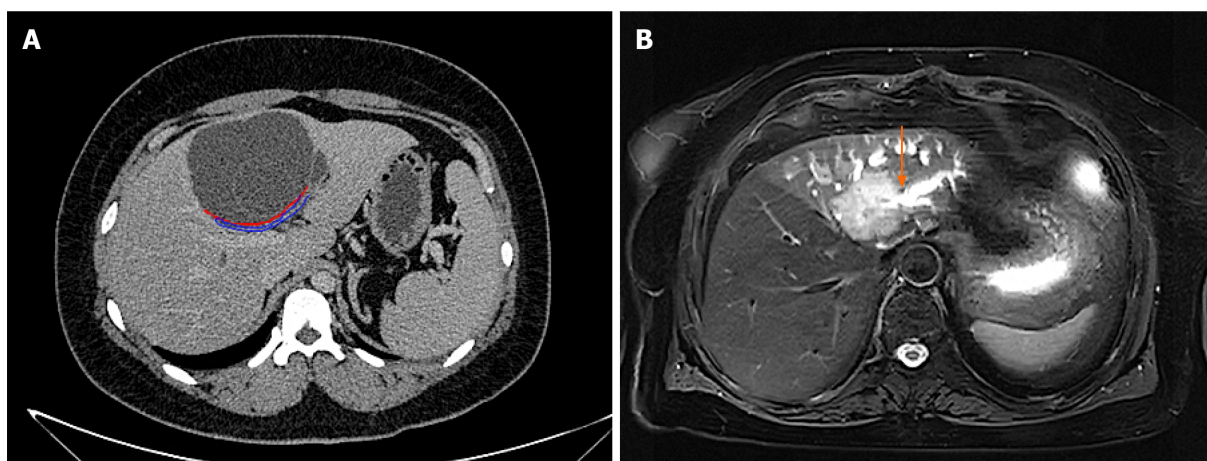
**Figure 3** Magnetic resonance imaging of patients with intrahepatic bile duct papilloma. Orange arrows indicate solid components floating in cystic lesions.



**Figure 4** Intrahepatic bile duct papilloma whole abdominal plain scan and enhanced computed tomography scan. A-C: Blue depicts that the tumour communicates with the bile duct, and bile duct dilatation can be seen; D: The orange arrow indicates a mucinous tumour, and the blue arrow indicates a mural nodule.



**Figure 5** Magnetic resonance cholangiopancreatography images of patients with intrahepatic bile duct papilloma. A: The tumour is cystic and solid, with a smooth wall, yellow arrow indicating a wall nodule and orange arrow indicating a mucinous tumour; B and C: The yellow arrow indicates that the tumour communicates with the bile duct.



**Figure 6** Differential diagnosis instructions. A: Computed tomography image of mucinous cystic tumour of liver. It can be seen that the tumour does not communicate with bile duct. The orange arrow indicates the boundary of the tumour, and the blue arrow shows the bile duct compressed by the tumour; B: Magnetic resonance imaging image of cholangiocarcinoma. It can be seen that the boundary is not clear and smooth, and it invades into the liver, and the distal bile duct expands like a twig. The orange arrow indicates that the bile duct is out of shape and cut off at the lesion

## ACKNOWLEDGEMENTS

The authors thank all the patients who participated in the survey.

## REFERENCES

- 1 Uemura S, Higuchi R, Yazawa T, Izumo W, Matsunaga Y, Shiihara M, Ota T, Furukawa T, Yamamoto M. Prognostic Factors for Surgically Resected Intraductal Papillary Neoplasm of the Bile Duct: A Retrospective Cohort Study. *Ann Surg Oncol* 2021; **28**: 826-834 [PMID: [32651697](#) DOI: [10.1245/s10434-020-08835-6](#)]
- 2 Matono R, Ninomiya M, Morita K, Tomino T, Oshiro Y, Yokota T, Nishizaki T. Branch-type intraductal papillary neoplasm of the bile duct treated with laparoscopic anatomical resection: a case report. *Surg Case Rep* 2020; **6**: 103 [PMID: [32415464](#) DOI: [10.1186/s40792-020-00864-3](#)]
- 3 Pattarapuntakul T, Ovtarlarnporn B, Sottisuporn J. Mucinous cystic neoplasm of the liver with extrahepatic growth presenting with ascending cholangitis diagnosed by endoscopic ultrasound features: a case report. *J Med Case Rep* 2018; **12**: 33 [PMID: [29444709](#) DOI: [10.1186/s13256-017-1560-4](#)]
- 4 Kim WJ, Hwang S, Lee YJ, Kim KH, Park KM, Ahn CS, Moon DB, Ha TY, Song GW, Jung DH, Park GC, Kim MH, Lee SK, Seo DW, Park DH, Lee SS, Lee SG. Clinicopathological Features and Long-Term Outcomes of Intraductal Papillary Neoplasms of the Intrahepatic Bile Duct. *J Gastrointest Surg* 2016; **20**: 1368-1375 [PMID: [26873016](#) DOI: [10.1007/s11605-016-3103-5](#)]
- 5 Matsumoto T, Kubota K, Hachiya H, Sakuraoaka Y, Shiraki T, Shimizu T, Mori S, Iso Y, Kato M,

- Yamagishi H, Imai Y, Aoki T. Impact of Tumor Location on Postoperative Outcome of Intraductal Papillary Neoplasm of the Bile Duct. *World J Surg* 2019; **43**: 1313-1322 [PMID: [30659344](#) DOI: [10.1007/s00268-019-04913-3](#)]
- 6 **Park HJ**, Kim SY, Kim HJ, Lee SS, Hong GS, Byun JH, Hong SM, Lee MG. Intraductal Papillary Neoplasm of the Bile Duct: Clinical, Imaging, and Pathologic Features. *AJR Am J Roentgenol* 2018; **211**: 67-75 [PMID: [29629808](#) DOI: [10.2214/AJR.17.19261](#)]
  - 7 **Jabbour E**, Garcia-Manero G, Ravandi F, Faderl S, O'Brien S, Fullmer A, Cortes JE, Wierda W, Kantarjian H. Prognostic factors associated with disease progression and overall survival in patients with myelodysplastic syndromes treated with decitabine. *Clin Lymphoma Myeloma Leuk* 2013; **13**: 131-138 [PMID: [23260600](#) DOI: [10.1016/j.clml.2012.11.001](#)]
  - 8 **Aslam A**, Wasnik AP, Shi J, Sahai V, Mendiratta-Lala M. Intraductal papillary neoplasm of the bile duct (IPNB): CT and MRI appearance with radiology-pathology correlation. *Clin Imaging* 2020; **66**: 10-17 [PMID: [32438236](#) DOI: [10.1016/j.clinimag.2020.04.036](#)]
  - 9 **Komori T**, Inoue D, Zen Y, Yoneda N, Kitao A, Kozaka K, Yokka A, Toshima F, Matsubara T, Kobayashi S, Gabata T. CT imaging comparison between intraductal papillary neoplasms of the bile duct and papillary cholangiocarcinomas. *Eur Radiol* 2019; **29**: 3132-3140 [PMID: [30519930](#) DOI: [10.1007/s00330-018-5841-0](#)]
  - 10 **Zaccari P**, Cardinale V, Severi C, Pedica F, Carpino G, Gaudio E, Doglioni C, Petrone MC, Alvaro D, Arcidiacono PG, Capurso G. Common features between neoplastic and preneoplastic lesions of the biliary tract and the pancreas. *World J Gastroenterol* 2019; **25**: 4343-4359 [PMID: [31496617](#) DOI: [10.3748/wjg.v25.i31.4343](#)]
  - 11 **Siripongsakun S**, Sapthanakorn W, Mekraksak P, Vichitpant S, Chonyuen S, Seetasarn J, Bhumiwat S, Sricharunrat T, Srittanapong S. Premalignant lesions of cholangiocarcinoma: characteristics on ultrasonography and MRI. *Abdom Radiol (NY)* 2019; **44**: 2133-2146 [PMID: [30820627](#) DOI: [10.1007/s00261-019-01951-2](#)]
  - 12 **Kim JR**, Jang KT, Jang JY, Lee K, Kim JH, Kim H, Kim SW, Kwon W, Choi DW, Heo J, Han IW, Hwang S, Kim WJ, Hong SM, Kim DS, Yu YD, Kim JY, Nah YW, Park HW, Choi HJ, Han HS, Yoon YS, Park SJ, Hong EK, Seo HI, Park DY, Kang KJ, Kang YN, Yu HC, Moon WS, Lim CS, Bae JM, Jo S, Lee W, Roh YH, Jeong JS, Jeong CY, Lee JS, Song IS, Kim KH, Kim HG, Cho CH, Joo SH, Won KY, Kim HJ, Choi JH, Chu CW, Lee JH, Park IY, Lee H, Lee SE, Kim HS, Lee HK, Cho MS, Han KM. Clinicopathologic analysis of intraductal papillary neoplasm of bile duct: Korean multicenter cohort study. *HPB (Oxford)* 2020; **22**: 1139-1148 [PMID: [31837945](#) DOI: [10.1016/j.hpb.2019.11.007](#)]
  - 13 **Zhang H**, Zhong Z, Kong G, Khan J, Zou L, Jiang Y, Liu X, Tang Y, Jiang B, Peng C, Song Y, Liu S. Clinicopathological findings and imaging features of intraductal papillary neoplasms in bile ducts. *PeerJ* 2020; **8**: e10040 [PMID: [33062441](#) DOI: [10.7717/peerj.10040](#)]
  - 14 **Joo I**, Lee JM, Yoon JH. Imaging Diagnosis of Intrahepatic and Perihilar Cholangiocarcinoma: Recent Advances and Challenges. *Radiology* 2018; **288**: 7-13 [PMID: [29869969](#) DOI: [10.1148/radiol.2018171187](#)]
  - 15 **Frezin J**, Komuta M, Zech F, Annet L, Horsmans Y, Gigot JF, Jouret-Mourin A, Hubert C. Mucin-producing hepatic cystic neoplasms: an uncommon but challenging disease often misdiagnosed and mismanaged. *Acta Chir Belg* 2020; **120**: 6-15 [PMID: [30388391](#) DOI: [10.1080/00015458.2018.1532706](#)]
  - 16 **Fang T**, Wang H, Wang Y, Lin X, Cui Y, Wang Z. Clinical Significance of Preoperative Serum CEA, CA125, and CA19-9 Levels in Predicting the Resectability of Cholangiocarcinoma. *Dis Markers* 2019; **2019**: 6016931 [PMID: [30863466](#) DOI: [10.1155/2019/6016931](#)]
  - 17 **Zheng BH**, Yang LX, Sun QM, Fan HK, Duan M, Shi JY, Wang XY, Zhou J, Fan J, Ma ZY, Gao Q. A New Preoperative Prognostic System Combining CRP and CA199 For Patients with Intrahepatic Cholangiocarcinoma. *Clin Transl Gastroenterol* 2017; **8**: e118 [PMID: [28981082](#) DOI: [10.1038/ctg.2017.45](#)]



Published by **Baishideng Publishing Group Inc**  
7041 Koll Center Parkway, Suite 160, Pleasanton, CA 94566, USA

**Telephone:** +1-925-3991568

**E-mail:** [bpgoffice@wjgnet.com](mailto:bpgoffice@wjgnet.com)

**Help Desk:** <https://www.f6publishing.com/helpdesk>

<https://www.wjgnet.com>

