

World Journal of *Clinical Cases*

World J Clin Cases 2021 May 16; 9(14): 3227-3486



Contents

Thrice Monthly Volume 9 Number 14 May 16, 2021

MINIREVIEWS

- 3227 Non-invasive physical therapy as salvage measure for ischemic skin flap: A literature review
Zheng YH, Yin LQ, Xu HK, Gong X
- 3238 Prediction models for development of hepatocellular carcinoma in chronic hepatitis B patients
Guo J, Gao XS

ORIGINAL ARTICLE

Retrospective Cohort Study

- 3252 Burden of atrial fibrillation in patients with rheumatic diseases
Khan MZ, Patel K, Patel KA, Doshi R, Shah V, Adalja D, Waqar Z, Franklin S, Gupta N, Gul MH, Jesani S, Kutalek S, Figueredo V

Retrospective Study

- 3265 Observation of the effect of one-to-one education on high-risk cases of diabetic foot
Fu XJ, Hu SD, Peng YF, Zhou LY, Shu T, Song DD
- 3273 Pediatric Wilson disease presenting as acute liver failure: Prognostic indices
Fang WY, Abuduxikuer K, Shi P, Qiu YL, Zhao J, Li YC, Zhang XY, Wang NL, Xie XB, Lu Y, Knisely AS, Wang JS
- 3287 Positive psychological intervention for anxiety, depression and coping in subjects addicted to online games
Gao XJ, Sun JJ, Xiang M

SYSTEMATIC REVIEWS

- 3294 Cluster headache due to structural lesions: A systematic review of published cases
Long RJ, Zhu YS, Wang AP

META-ANALYSIS

- 3308 Comparison of smear cytology with liquid-based cytology in pancreatic lesions: A systematic review and meta-analysis
Zhang XH, Ma SY, Liu N, Wei ZC, Gao X, Hao YJ, Liu YX, Cai YQ, Wang JH

CASE REPORT

- 3320 Bronchial glomus tumor with calcification: A case report
Zhang Y, Zhang QP, Ji YQ, Xu J

- 3327** Acute flaccid paralysis and neurogenic respiratory failure associated with enterovirus D68 infection in children: Report of two cases
Zhang Y, Wang SY, Guo DZ, Pan SY, Lv Y
- 3334** Skeletal muscle metastases of hepatocellular carcinoma: A case report and literature review
Song Q, Sun XF, Wu XL, Dong Y, Wang L
- 3342** Bone cement implantation syndrome during hip replacement in a patient with pemphigus and Parkinson's disease: A case report
Zhou W, Zhang WJ, Zhao GQ, Li K
- 3350** Novel intergenic *KIF5B-MET* fusion variant in a patient with gastric cancer: A case report
Wu ZW, Sha Y, Chen Q, Hou J, Sun Y, Lu WK, Chen J, Yu LJ
- 3356** Recurrent perimesencephalic nonaneurysmal subarachnoid hemorrhage within a short period of time: A case report
Li J, Fang X, Yu FC, Du B
- 3365** Incremental value of three-dimensional and contrast echocardiography in the evaluation of endocardial fibroelastosis and multiple cardiovascular thrombi: A case report
Sun LJ, Li Y, Qiao W, Yu JH, Ren WD
- 3372** Floating elbow combining ipsilateral distal multiple segmental forearm fractures: A case report
Huang GH, Tang JA, Yang TY, Liu Y
- 3379** Acute cholangitis detected ectopic ampulla of Vater in the antrum incidentally: A case report
Lee HL, Fu CK
- 3385** Almitrine for COVID-19 critically ill patients – a vascular therapy for a pulmonary vascular disease: Three case reports
Huette P, Abou Arab O, Jounieaux V, Guilbart M, Belhout M, Haye G, Dupont H, Beyls C, Mahjoub Y
- 3394** Tenosynovial giant cell tumor involving the cervical spine: A case report
Zhu JH, Li M, Liang Y, Wu JH
- 3403** Primary bone anaplastic lymphoma kinase positive anaplastic large-cell lymphoma: A case report and review of the literature
Zheng W, Yin QQ, Hui TC, Wu WH, Wu QQ, Huang HJ, Chen MJ, Yan R, Huang YC, Pan HY
- 3411** Acute spontaneous thoracic epidural hematoma associated with intraspinal lymphangioma: A case report
Chia KJ, Lin LH, Sung MT, Su TM, Huang JF, Lee HL, Sung WW, Lee TH
- 3418** Change in neoadjuvant chemotherapy could alter the prognosis of patients with pancreatic adenocarcinoma: A case report
Meyer A, Carvalho BJ, Medeiros KA, Pipek LZ, Nascimento FS, Suzuki MO, Munhoz JV, Iuamoto LR, Carneiro-D'Albuquerque LA, Andraus W
- 3424** Laparoscopic cholecystectomy for gangrenous cholecystitis in around nineties: Two case reports
Inoue H, Ochiai T, Kubo H, Yamamoto Y, Morimura R, Ikoma H, Otsuji E

- 3432** Radiological insights of ectopic thyroid in the porta hepatis: A case report and review of the literature
Chooah O, Ding J, Fei JL, Xu FY, Yue T, Pu CL, Hu HJ
- 3442** Successful treatment of infantile hepatitis B with lamivudine: A case report
Zhang YT, Liu J, Pan XB, Gao YD, Hu YF, Lin L, Cheng HJ, Chen GY
- 3449** Pure large cell neuroendocrine carcinoma originating from the endometrium: A case report
Du R, Jiang F, Wang ZY, Kang YQ, Wang XY, Du Y
- 3458** Diabetic mastopathy in an elderly woman misdiagnosed as breast cancer: A case report and review of the literature
Chen XX, Shao SJ, Wan H
- 3466** Cronkhite-Canada syndrome with steroid dependency: A case report
Jiang D, Tang GD, Lai MY, Huang ZN, Liang ZH
- 3472** Extremely rare case of necrotizing gastritis in a patient with autoimmune hepatitis: A case report
Moon SK, Yoo JJ, Kim SG, Kim YS
- 3478** Paget's disease of bone: Report of 11 cases
Miao XY, Wang XL, Lyu ZH, Ba JM, Pei Y, Dou JT, Gu WJ, Du J, Guo QH, Chen K, Mu YM

ABOUT COVER

Editorial Board Member of *World Journal of Clinical Cases*, Nicola Montemurro, MD, PhD, Assistant Professor, Consultant Physician-Scientist, Neurosurgeon, Surgeon, Surgical Oncologist, Department of Translational Research and New Technologies in Medicine and Surgery, University of Pisa, Pisa 56126, Italy. nicola.montemurro@unipi.it

AIMS AND SCOPE

The primary aim of *World Journal of Clinical Cases* (WJCC, *World J Clin Cases*) is to provide scholars and readers from various fields of clinical medicine with a platform to publish high-quality clinical research articles and communicate their research findings online.

WJCC mainly publishes articles reporting research results and findings obtained in the field of clinical medicine and covering a wide range of topics, including case control studies, retrospective cohort studies, retrospective studies, clinical trials studies, observational studies, prospective studies, randomized controlled trials, randomized clinical trials, systematic reviews, meta-analysis, and case reports.

INDEXING/ABSTRACTING

The WJCC is now indexed in Science Citation Index Expanded (also known as SciSearch®), Journal Citation Reports/Science Edition, Scopus, PubMed, and PubMed Central. The 2020 Edition of Journal Citation Reports® cites the 2019 impact factor (IF) for WJCC as 1.013; IF without journal self cites: 0.991; Ranking: 120 among 165 journals in medicine, general and internal; and Quartile category: Q3. The WJCC's CiteScore for 2019 is 0.3 and Scopus CiteScore rank 2019: General Medicine is 394/529.

RESPONSIBLE EDITORS FOR THIS ISSUE

Production Editor: Jia-Hui Li; Production Department Director: Yun-Jie Ma; Editorial Office Director: Jin-Lei Wang.

NAME OF JOURNAL

World Journal of Clinical Cases

ISSN

ISSN 2307-8960 (online)

LAUNCH DATE

April 16, 2013

FREQUENCY

Thrice Monthly

EDITORS-IN-CHIEF

Dennis A Bloomfield, Sandro Vento, Bao-Gan Peng

EDITORIAL BOARD MEMBERS

<https://www.wjgnet.com/2307-8960/editorialboard.htm>

PUBLICATION DATE

May 16, 2021

COPYRIGHT

© 2021 Baishideng Publishing Group Inc

INSTRUCTIONS TO AUTHORS

<https://www.wjgnet.com/bpg/gerinfo/204>

GUIDELINES FOR ETHICS DOCUMENTS

<https://www.wjgnet.com/bpg/gerinfo/287>

GUIDELINES FOR NON-NATIVE SPEAKERS OF ENGLISH

<https://www.wjgnet.com/bpg/gerinfo/240>

PUBLICATION ETHICS

<https://www.wjgnet.com/bpg/gerinfo/288>

PUBLICATION MISCONDUCT

<https://www.wjgnet.com/bpg/gerinfo/208>

ARTICLE PROCESSING CHARGE

<https://www.wjgnet.com/bpg/gerinfo/242>

STEPS FOR SUBMITTING MANUSCRIPTS

<https://www.wjgnet.com/bpg/gerinfo/239>

ONLINE SUBMISSION

<https://www.f6publishing.com>

Bronchial glomus tumor with calcification: A case report

Ying Zhang, Qiu-Ping Zhang, Ying-Qun Ji, Jian Xu

ORCID number: Ying Zhang 0000-0002-1758-6330; Qiu-Ping Zhang 0000-0002-1720-7687; Ying-Qun Ji 0000-0002-6212-3829; Jian Xu 0000-0003-0743-6045.

Author contributions: Zhang Y and Ji YQ were the patient's respiratory physicians, reviewed the literature and contributed to manuscript drafting; Zhang QP performed the pathological analyses and interpretation and contributed to manuscript drafting; Ji YQ and Xu J were responsible for the revision of the manuscript for important intellectual content; all authors issued final approval for the version to be submitted.

Supported by The Study on the Diagnosis and Treatment of COPD Complications Complicated With Diseases, China, No. 2016YFC1304500.

Informed consent statement:

Informed written consent was obtained from the patient for publication of this report and any accompanying images.

Conflict-of-interest statement: The authors declare that there is no conflict of interest.

CARE Checklist (2016) statement:

The authors have read the CARE Checklist (2016), and the manuscript was prepared and revised according to the CARE Checklist (2016).

Ying Zhang, Ying-Qun Ji, Department of Pulmonary and Critical Care Medicine, The First Affiliated Hospital of Dalian Medical University, Dalian 116011, Liaoning Province, China

Qiu-Ping Zhang, Department of Pathology, The First Affiliated Hospital of Dalian Medical University, Dalian 116011, Liaoning Province, China

Ying-Qun Ji, Department of Pulmonary and Critical Care Medicine, Shanghai East Hospital, Tongji University School of Medicine, Shanghai 200120, China

Jian Xu, Department of Pulmonary and Critical Care Medicine, Dalian Municipal Central Hospital Affiliated of Dalian Medical University, Dalian 116033, Liaoning Province, China

Corresponding author: Ying-Qun Ji, MD, PhD, Doctor, Department of Pulmonary and Critical Care Medicine, Shanghai East Hospital, Tongji University School of Medicine, No. 150 Jimo Road, Pudong District, Shanghai 200120, China. jiyingqun@163.com

Abstract

BACKGROUND

Glomus tumors (GTs), defined by modified smooth cells and normal glomus body cells, usually present with a small mass occurring in the soft tissue or dermis of an extremity, especially in the subungual region. However, other unusual sites, such as the respiratory tract, have also been reported. They are usually sporadic. Their imaging findings are usually nonspecific and likely to appear as a well-delineated round mass that usually lacks calcification. To our knowledge, we report the first case of bronchial GTs with calcification, reminding clinicians and radiologists that GT is one of the differential diagnoses when a calcified nodular mass is found.

CASE SUMMARY

We report a case of a 33-yr-old Chinese man with cough and sputum for 11 d and hemoptysis for 5 d. Chest computed tomography revealed a calcified nodular lesion on the compressed posterior wall of the lower left main bronchus and bronchiectasis in the lower lobe of the left lung. To confirm the characteristics of calcified nodules, we performed fiberoptic bronchoscopy. The tumor tissue from the biopsy of bronchial mucosal lesions established the diagnosis of GT. Because the patient had no life-threatening symptoms, he was not treated with surgery. Clinical follow-up for 25 mo showed that the patient survived well without any discomfort.

CONCLUSION

Bronchial GTs are usually not accompanied by calcification on computed tomography scans. To our knowledge, we report the first calcified bronchial GT.

Open-Access: This article is an open-access article that was selected by an in-house editor and fully peer-reviewed by external reviewers. It is distributed in accordance with the Creative Commons Attribution NonCommercial (CC BY-NC 4.0) license, which permits others to distribute, remix, adapt, build upon this work non-commercially, and license their derivative works on different terms, provided the original work is properly cited and the use is non-commercial. See: <http://creativecommons.org/licenses/by-nc/4.0/>

Manuscript source: Unsolicited manuscript

Specialty type: Radiology, nuclear medicine and medical imaging

Country/Territory of origin: China

Peer-review report's scientific quality classification

Grade A (Excellent): 0
Grade B (Very good): 0
Grade C (Good): C
Grade D (Fair): 0
Grade E (Poor): 0

Received: October 13, 2020

Peer-review started: October 13, 2020

First decision: February 12, 2021

Revised: February 26, 2021

Accepted: March 23, 2021

Article in press: March 23, 2021

Published online: May 16, 2021

P-Reviewer: Spartalis M

S-Editor: Zhang H

L-Editor: Filipodia

P-Editor: Li JH



We recommend that clinicians consider GT as a possible differential diagnosis when a calcified mass of the bronchi is found.

Key Words: Glomus tumor; Imaging; Calcified tumor; Bronchus; Case report

©The Author(s) 2021. Published by Baishideng Publishing Group Inc. All rights reserved.

Core Tip: Bronchial glomus tumors (GTs) are rare soft tissue neoplasms. The imaging features of GTs are well-defined masses or nodules without calcification on plain computed tomography scans. On dynamic contrast-enhanced computed tomography images, the tumors were enhanced significantly. In this report, we present a case of bronchial GT with calcification, reminding clinicians that they should consider GT as a differential diagnosis when finding calcified masses in the bronchus.

Citation: Zhang Y, Zhang QP, Ji YQ, Xu J. Bronchial glomus tumor with calcification: A case report. *World J Clin Cases* 2021; 9(14): 3320-3326

URL: <https://www.wjgnet.com/2307-8960/full/v9/i14/3320.htm>

DOI: <https://dx.doi.org/10.12998/wjcc.v9.i14.3320>

INTRODUCTION

The World Health Organization defines glomus tumors (GTs) as benign tumors with perivascular cells[1]. GT is a distinctive neoplasm originating from modified smooth muscle cells, *i.e.*, glomocytes of the neuromyoarterial glomus or the normal glomus body, which is a specialized structure involving temperature regulation[2]. They are usually located in the subcutis of the subungual region or dermis[3]. Several unusual sites have also been reported including the gastrointestinal tract, bone, cervix, mediastinum, stomach and respiratory tract[3]. Treatment options for tracheobronchial GTs include thoracotomy, bronchoscopic electrocautery, Nd: YAG laser and cryotherapy[3]. In terms of imaging, radiological imaging of GTs of visceral organs is limited due to its rarity, and no direct imaging technique is routinely used for the diagnosis of GTs[2]. On chest computed tomography (CT), GT is likely to appear as a well-delineated round mass without calcification[4]. To date, no calcified bronchial GT has been reported. We searched PubMed with the keywords “glomus tumor and calcified tumor” or “glomus tumor and calcification” and found only six cases of GT with calcification; none of which occurred in the respiratory system. Here, we present a case of a 33-yr-old patient with calcified bronchial GT.

CASE PRESENTATION

Chief complaints

A Chinese man aged 33 yrs was admitted to our hospital in January 2019 due to cough and sputum for 11 d and hemoptysis for 5 d.

History of present illness

The patient had no obvious cause of cough and yellow sputum or fever 11 d ago. The highest body temperature was 39.4°C. There was no other obvious discomfort. After taking cephalosporin, his body temperature returned to normal. However, 5 d ago, he had hemoptysis.

History of past illness

The patient had no history of prior illness.

Personal and family history

No personal or family history of benign or malignant tumors exist.

Physical examination

His temperature was 36.8°C, resting respiratory rate 15 breaths/min, heart rate 78 bpm and blood pressure 130/90 mmHg. Physical examinations were normal except for vesicular breath sounds.

Laboratory examinations

Laboratory examination showed a white blood cell count of $6.04 \times 10^9/L$, with 66% neutrophils, 165 g/L hemoglobin, $275 \times 10^9/L$ platelets, erythrocyte sedimentation rate 2 mm/h and normal range of routine urine tests, routine fecal tests and occult blood test, electrolyte profile and blood biochemistry. In addition, the human immunodeficiency virus antibody test, carcinoembryonic antigen, neuron specific enolase, cytokeratin 19 fragment, squamous cell carcinoma antigen, blood coagulation and immune indexes were all negative.

Imaging examinations

Chest CT revealed the presence of a 1.20 cm \times 0.88 cm calcified nodular lesion on the compressed posterior wall of the lower left main bronchus (Figure 1). CT also showed bronchiectasis in the lower lobe of the left lung. Bronchial GT and carcinoid carcinoma were considered as possible diagnoses. However, it was difficult to distinguish one from another on the radiographic findings alone because they often have similar imaging features. GTs could be differentiated from carcinoids by tumor biopsy and immunohistochemistry.

Further diagnostic work-up

To confirm the characteristics of calcified nodules in the lower left main bronchus, fiberoptic bronchoscopy was performed, which showed a yellow-white, hard mass obstructing the entrance to the basal segment of the lower left lobe (Figure 2). Lateral to the entrance of the basal segment of the lower left lobe, neoplasms with multiple nodular ridges and superficial hyperemia were observed (Figure 2). Mucosal biopsy using a fiberoptic bronchoscopy was performed. The neoplasm was prone to bleeding.

Pathology

Microscopically, the tumor cells were uniformly round with smooth nuclear contours, fine chromatin and a modest amount of pink cytoplasm. They were arranged in sheet-like patterns between small blood vessels (Figure 3A). Smooth muscle actin (Figure 3B) and actin (Figure 3C) immunohistochemical staining were positive, and synaptophysin immunohistochemical staining was weakly positive. In contrast, CD56 (NK-1), chromogranin A, cytokeratins 5/6, cytokeratin 7, napsin-A, P40, thyroid transcription factor-1, cytokeratin, neuron specific enolase, S-100 and Ki-67 (<1%) immunohistochemical staining were negative. The histological characteristics and immunohistochemical staining patterns of the tumor were consistent with the diagnosis of GT. The clinical and pathological data of the patient are presented in Table 1.

FINAL DIAGNOSIS

Therefore, this patient was diagnosed with bronchial GT and bronchiectasis.

TREATMENT

Most bronchial GTs have a good prognosis because they are benign. Only a small proportion are malignant. However, if hemoptysis and asphyxia are caused by bronchial GTs, surgical resection or tracheoscopic resection is still recommended, even for benign GTs. Because our patient was diagnosed with benign bronchial GT without life-threatening symptoms, such as massive hemoptysis, he opted for conservative treatment. The hemoptysis was quickly relieved after intravenous administration of 2 U agkistrodon, which was then discontinued. At the same time, piperacillin-tazobactam 4.5g twice daily and erdosteine 0.3g twice daily were used for bronchiectasis for 9 d. The symptoms of cough and sputum were relieved.

Table 1 Clinical and pathological data of the patient

| Project | Content |
|----------------------------------|--|
| Biographical data | 33-yr-old man |
| Family history | No |
| Personal or family history | No |
| Chief complaint | Cough and sputum for 11 d and hemoptysis for 5 d |
| Physical examination of the lung | Normal except for vesicular breath sounds |
| Chest computed tomography | 1.20 cm × 0.88 cm calcified nodular lesion was found on the compressed posterior wall of the lower left main bronchus (Figure 1). Bronchiectasis in the lower lobe of the left lung was found. |
| Fiberoptic bronchoscopy | Yellow-white, slightly hard mass was found obstructing the entrance to the basal segment of the lower left lobe (Figure 2). Neoplasms with multiple nodular ridges and superficial hyperemia were observed in the lateral to the entrance of the basal segment of the lower left lobe (Figure 2). Mucosal biopsy using a fiberoptic bronchoscopy is prone to bleeding. |
| Pathology | Microscopically, the tumor cells were uniformly round with smooth nuclear contours, fine chromatin and a modest amount of pink cytoplasm. They were arranged in sheet-like patterns between small blood vessels (Figure 3A). Left main bronchial glomus tumor with immunohistochemistry results of SMA(+) (Figure 3B) and actin(+) (Figure 3C), CD56 (NK-1)(-), CgA(-), CK5/6(-), CK7(-), napsin-A(-), P40(-), TTF-1(-), CK(-), NSE(-), S-100(-) and Ki-67 (< 1%), and Syn immunohistochemical staining was weakly positive. |
| Final diagnosis | Bronchial glomus tumor and bronchiectasis |
| Treatment | Conservative treatment. Piperacillin-tazobactam 4.5 g twice daily and erdosteine 0.3 g twice daily for 9 d. Intravenous administration of Agkistrodon 2 U once. |
| Follow-up | Clinical follow-up for 25 mo showed that the patient had no symptoms. |

SMA: Smooth muscle actin; CgA: Chromogranin A; CK5/6: Cytokeratin5/6; CK7: Cytokeratin7; TTF-1: Thyroid transcription factor-1; CK: Cytokeratin; NSE: Neuron specific enolase; Syn: Synaptophysin.

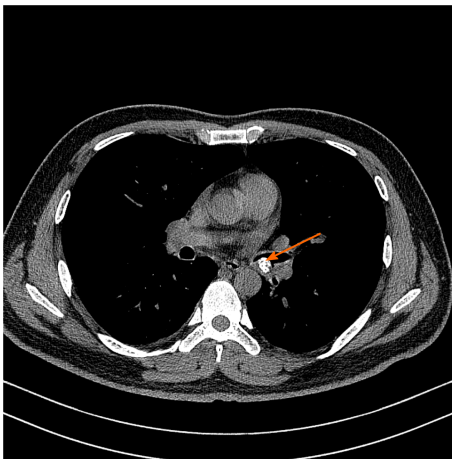


Figure 1 Chest computed tomography. A 1.20 cm × 0.88 cm calcified nodular lesion on the compressed posterior wall of the lower left main bronchus (orange arrow).

OUTCOME AND FOLLOW-UP

The patient exhibited no symptoms during long-term follow-up of 25 mo. As the patient was asymptomatic, he was not followed up with chest CT or fiberoptic bronchoscopy.

DISCUSSION

GTs are rare neoplasms that originate from the glomus apparatus, which is a specialized form of arteriovenous shunt involved in thermoregulation[5]. GTs show no gender predilection, but respiratory tract lesions are more prevalent in men, while

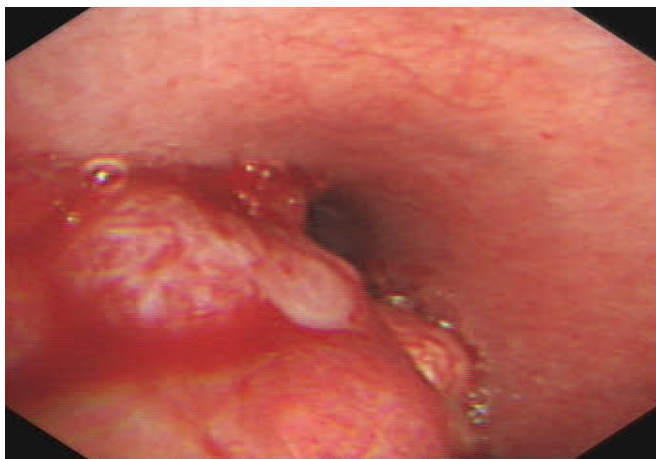

Figure 2 Bronchoscopic view of basal segment of the lower left lobe. A yellow-white mass obstructed the entrance to the basal segment of the lower left lobe. Lateral to the entrance of the basal segment of the lower left lobe, neoplasms with multiple nodular ridges and superficial hyperemia were observed.

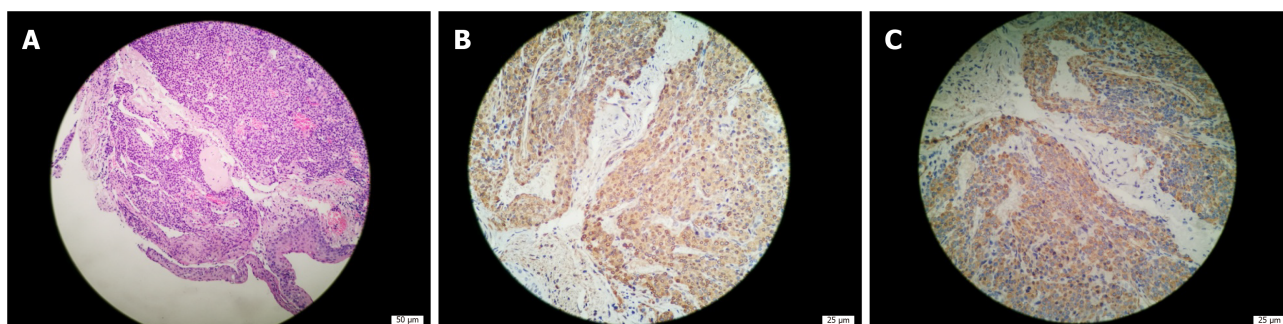


Figure 3 Bronchial glomus tumor histopathology. A: Tumor cells were uniformly round with smooth nuclear contours, fine chromatin and a modest amount of pink cytoplasm. They were arranged in sheet-like patterns between small blood vessels (hematoxylin-eosin staining, 200 \times); B: Tumor cells were positive for smooth muscle actin (immunohistochemical staining, 400 \times); C: Tumor cells were positive for actin (immunohistochemical staining, 400 \times).

subungual lesions are more prevalent in women[6]. The most common discomforts in respiratory symptomatic GTs are dyspnea (52.86%), cough (51.43%), hemoptysis (45.71%), chest pain (8.57%), fever and hoarseness (7.14%)[1].

CT and magnetic resonance imaging (MRI) findings of thoracic GTs are generally nonspecific. One study maintained that CT is the best modality to diagnose GTs arising from the chest wall, mediastinum, lungs or respiratory tract[7]. On chest CT, both malignant and benign GTs are likely to appear as well-delineated round masses[8]. Chest CT has revealed that the size of published pulmonary GTs ranges from 1.0 to 9.7 cm, with an average of 3.6 cm[8]. The tumors are described as either pulmonary nodules or masses, occasionally with the term coin lesion, as noted in some cases[8]. There is usually no calcification or fat decay[4]. On dynamic contrast-enhanced CT images, the tumors were enhanced significantly due to their rich vasculature. The chest X-rays might be normal[7].

MRI has proven to be a sensitive diagnostic method for GTs of the hand. GTs of the hand show a variety of MRI findings, and the appearances of GTs on MRI are decreased signal intensity, isointensity, increased signal intensity or inhomogeneous signal intensity in T1-weighted images and increased signal intensity in T2-weighted images[9]. After injection of gadolinium contrast agent, T1-weighted images are significantly enhanced[9]. These signals depend on the main cells of the tumor, including the following three types: Vascular, myxoid and solid[9]. However, to date, MRI manifestations of thoracic GTs have rarely been reported. In some cases, the mass center shows high intensity on both T1- and T2-weighted images[10]. With dynamic contrast-enhanced MRI, the mass might show strong, early-phase peripheral enhancement that expands in a centripetal direction with time[10]. The abundant vasculature of tumors is considered the most potent contributor to strong enhancement, which can provide additional information to isolate the nature of pulmonary nodules[10]. Because the MRI data of thoracic GTs are too limited, the MRI performance, sensitivity and specificity of thoracic GTs require more data analysis.

It is worth noting that none of the previous bronchial GTs reported internal calcification at imaging. Through a literature search, we found only six cases of GT with calcification, which were in the thigh[11], shoulder[12], musculotendinous junction of the rotator cuff[13], intracranial portion of a glomus jugular tumor[10], stomach[14] and thyroid gland[2]. To our knowledge, our case is the first reported GT with calcification in the respiratory tract.

The ideal management of tracheobronchial GT remains unclear[3]. In general, surgery may be the first choice for treating GTs that cause life-threatening airway obstruction and bleeding[15]. When the tumor arises from a lobar bronchus involving the origin or the main bronchus intraoperatively, a bronchoplastic procedure is needed[16]. When the patient is too weak to tolerate surgery or refuses to accept it, we prefer bronchoscopy. High-frequency electrocoagulation, laser resection and argon plasma coagulation are common endobronchial therapy techniques, but biopsy should be avoided due to the rich blood supply of GTs[1]. The advantages of conservative treatment for the patient in this case report were no surgical risk, avoidance of potential surgical complications and no financial pressure. The limitations of conservative treatment are that the GT may rupture, hemorrhage, transform malignantly, enlarge or even obstruct the airway. Therefore, it is necessary to closely monitor blood pressure and hemoptysis with follow-up chest CT and fiberoptic bronchoscopy.

CONCLUSION

According to the reported literature, bronchial GTs are described as either pulmonary nodules or masses, usually not accompanied by calcification on CT scans. We found only six cases of GT with calcification. To our knowledge, our case is the seventh case of GT with calcification and the first reported GT of the respiratory tract with calcification. We recommend that clinicians consider GT as a possible differential diagnosis when a calcified mass of the bronchi is found.

REFERENCES

- 1 Wang C, Ma Y, Zhao X, Sun PL, Zhang YM, Huang M, Zhu Y, Jin SX. Glomus tumors of the trachea: 2 case reports and a review of the literature. *J Thorac Dis* 2017; **9**: E815-E826 [PMID: 29221350 DOI: 10.21037/jtd.2017.08.54]
- 2 Chung DH, Kim NR, Kim T, Ahn J, Lee S, Lee YD, Cho HY. Malignant glomus tumor of the thyroid gland where is heretofore an unreported organ: a case report and literature review. *Endocr Pathol* 2015; **26**: 37-44 [PMID: 25544269 DOI: 10.1007/s12022-014-9352-5]
- 3 Guo L, Wang K, Zhu H, Liu N, Zhu D. Treatment of primary tracheal glomus tumors: Two case reports and a literature review. *Medicine (Baltimore)* 2018; **97**: e0374 [PMID: 29642190 DOI: 10.1097/MD.00000000000010374]
- 4 Ueno M, Nakashima O, Mishima M, Yamada M, Kikuno M, Nasu K, Kudo S. Pulmonary glomus tumor: CT and MRI findings. *J Thorac Imaging* 2004; **19**: 131-134 [PMID: 15071335 DOI: 10.1097/00005382-200404000-00015]
- 5 Haro GJ, Seeley EJ, Jablons DM, Kratz JR. Central Airway Obstruction Due to Tracheal Glomus Tumor. *Thorac Cardiovasc Surg Rep* 2018; **7**: e43-e45 [PMID: 30464882 DOI: 10.1055/s-0038-1675411]
- 6 Yun JS, Song SY, Na KJ, Kim S, Choi YD. Synchronous primary glomus tumor in a patient with adenocarcinoma of the ipsilateral lung. *Thorac Cancer* 2019; **10**: 1280-1284 [PMID: 30951255 DOI: 10.1111/1759-7714.13067]
- 7 Aryan Z, Zaki KS, Machuzak M, Mehta AC. Glomus tumor of the trachea. *Clin Respir J* 2016; **10**: 537-539 [PMID: 25425558 DOI: 10.1111/crj.12238]
- 8 Cunningham JD, Plodkowski AJ, Giri DD, Hwang S. Case report of malignant pulmonary parenchymal glomus tumor: imaging features and review of the literature. *Clin Imaging* 2016; **40**: 144-147 [PMID: 26498485 DOI: 10.1016/j.clinimag.2015.09.017]
- 9 Yijun S, Jianming H, Qi M, Hu X. [Application of MRI in the diagnosis of glomus tumor]. *Zhonghua Zheng Xing Wai Ke Za Zhi* 2015; **31**: 259-262 [PMID: 26665924]
- 10 Moddy DM, Ghatak NR, Kelly DL Jr. Extensive calcification in a tumor of the glomus jugulare. *Neuroradiology* 1976; **12**: 131-135 [PMID: 187982 DOI: 10.1007/BF00341857]
- 11 Dabadie A, Fernandez C, Gorincour G, Panuel M, Petit P. A rare case of a calcified glomus tumour in the thigh of an adolescent. *Pediatr Radiol* 2013; **43**: 1045-1048 [PMID: 23417232 DOI: 10.1007/s00247-013-2640-2]
- 12 Boretto JG, Lazerges C, Coulet B, Baldet P, Chammas M. Calcified glomus tumor of the shoulder. A case report. *Chir Main* 2008; **27**: 183-186 [PMID: 18757229 DOI: 10.1016/j.main.2008.07.004]

- 13 **Yoshikawa G**, Murakami M, Ishizawa M, Matsumoto K, Hukuda S. Glomus tumor of the musculotendinous junction of the rotator cuff. A case report. *Clin Orthop Relat Res* 1996; 250-253 [PMID: 8620650 DOI: 10.1097/00003086-199605000-00031]
- 14 **Park SH**, Han JK, Kim TK, Lee JW, Kim SH, Kim YI, Choi BI, Yeon KM, Han MC. Unusual gastric tumors: radiologic-pathologic correlation. *Radiographics* 1999; **19**: 1435-1446 [PMID: 10555667 DOI: 10.1148/radiographics.19.6.g99no051435]
- 15 **Obata T**, Miyazaki T, Yamasaki N, Tsuchiya T, Matsumoto K, Hatachi G, Kitamura Y, Tabata K, Nagayasu T. Successful Resection of locally infiltrative Glomus Tumor without pulmonary resection. *Int J Surg Case Rep* 2017; **41**: 191-193 [PMID: 29096341 DOI: 10.1016/j.ijscr.2017.09.015]
- 16 **Singh V**, Kumar V, Singh H, Kakkar N. Primary pulmonary glomus tumour: a diagnostic challenge. *BMJ Case Rep* 2020; **13** [PMID: 32060108 DOI: 10.1136/bcr-2019-231926]



Published by **Baishideng Publishing Group Inc**
7041 Koll Center Parkway, Suite 160, Pleasanton, CA 94566, USA

Telephone: +1-925-3991568

E-mail: bpgoffice@wjgnet.com

Help Desk: <https://www.f6publishing.com/helpdesk>

<https://www.wjgnet.com>

