

# World Journal of *Clinical Cases*

*World J Clin Cases* 2021 May 16; 9(14): 3227-3486



## Contents

Thrice Monthly Volume 9 Number 14 May 16, 2021

## MINIREVIEWS

- 3227 Non-invasive physical therapy as salvage measure for ischemic skin flap: A literature review  
*Zheng YH, Yin LQ, Xu HK, Gong X*
- 3238 Prediction models for development of hepatocellular carcinoma in chronic hepatitis B patients  
*Guo J, Gao XS*

## ORIGINAL ARTICLE

## Retrospective Cohort Study

- 3252 Burden of atrial fibrillation in patients with rheumatic diseases  
*Khan MZ, Patel K, Patel KA, Doshi R, Shah V, Adalja D, Waqar Z, Franklin S, Gupta N, Gul MH, Jesani S, Kutalek S, Figueredo V*

## Retrospective Study

- 3265 Observation of the effect of one-to-one education on high-risk cases of diabetic foot  
*Fu XJ, Hu SD, Peng YF, Zhou LY, Shu T, Song DD*
- 3273 Pediatric Wilson disease presenting as acute liver failure: Prognostic indices  
*Fang WY, Abuduxikuer K, Shi P, Qiu YL, Zhao J, Li YC, Zhang XY, Wang NL, Xie XB, Lu Y, Knisely AS, Wang JS*

## Observational Study

- 3287 Positive psychological intervention for anxiety, depression and coping in subjects addicted to online games  
*Gao XJ, Sun JJ, Xiang M*

## SYSTEMATIC REVIEWS

- 3294 Cluster headache due to structural lesions: A systematic review of published cases  
*Long RJ, Zhu YS, Wang AP*

## META-ANALYSIS

- 3308 Comparison of smear cytology with liquid-based cytology in pancreatic lesions: A systematic review and meta-analysis  
*Zhang XH, Ma SY, Liu N, Wei ZC, Gao X, Hao YJ, Liu YX, Cai YQ, Wang JH*

## CASE REPORT

- 3320 Bronchial glomus tumor with calcification: A case report  
*Zhang Y, Zhang QP, Ji YQ, Xu J*

- 3327** Acute flaccid paralysis and neurogenic respiratory failure associated with enterovirus D68 infection in children: Report of two cases  
*Zhang Y, Wang SY, Guo DZ, Pan SY, Lv Y*
- 3334** Skeletal muscle metastases of hepatocellular carcinoma: A case report and literature review  
*Song Q, Sun XF, Wu XL, Dong Y, Wang L*
- 3342** Bone cement implantation syndrome during hip replacement in a patient with pemphigus and Parkinson's disease: A case report  
*Zhou W, Zhang WJ, Zhao GQ, Li K*
- 3350** Novel intergenic *KIF5B-MET* fusion variant in a patient with gastric cancer: A case report  
*Wu ZW, Sha Y, Chen Q, Hou J, Sun Y, Lu WK, Chen J, Yu LJ*
- 3356** Recurrent perimesencephalic nonaneurysmal subarachnoid hemorrhage within a short period of time: A case report  
*Li J, Fang X, Yu FC, Du B*
- 3365** Incremental value of three-dimensional and contrast echocardiography in the evaluation of endocardial fibroelastosis and multiple cardiovascular thrombi: A case report  
*Sun LJ, Li Y, Qiao W, Yu JH, Ren WD*
- 3372** Floating elbow combining ipsilateral distal multiple segmental forearm fractures: A case report  
*Huang GH, Tang JA, Yang TY, Liu Y*
- 3379** Acute cholangitis detected ectopic ampulla of Vater in the antrum incidentally: A case report  
*Lee HL, Fu CK*
- 3385** Almitrine for COVID-19 critically ill patients – a vascular therapy for a pulmonary vascular disease: Three case reports  
*Huette P, Abou Arab O, Jounieaux V, Guilbart M, Belhout M, Haye G, Dupont H, Beyls C, Mahjoub Y*
- 3394** Tenosynovial giant cell tumor involving the cervical spine: A case report  
*Zhu JH, Li M, Liang Y, Wu JH*
- 3403** Primary bone anaplastic lymphoma kinase positive anaplastic large-cell lymphoma: A case report and review of the literature  
*Zheng W, Yin QQ, Hui TC, Wu WH, Wu QQ, Huang HJ, Chen MJ, Yan R, Huang YC, Pan HY*
- 3411** Acute spontaneous thoracic epidural hematoma associated with intraspinal lymphangioma: A case report  
*Chia KJ, Lin LH, Sung MT, Su TM, Huang JF, Lee HL, Sung WW, Lee TH*
- 3418** Change in neoadjuvant chemotherapy could alter the prognosis of patients with pancreatic adenocarcinoma: A case report  
*Meyer A, Carvalho BJ, Medeiros KA, Pipek LZ, Nascimento FS, Suzuki MO, Munhoz JV, Iuamoto LR, Carneiro-D'Albuquerque LA, Andraus W*
- 3424** Laparoscopic cholecystectomy for gangrenous cholecystitis in around nineties: Two case reports  
*Inoue H, Ochiai T, Kubo H, Yamamoto Y, Morimura R, Ikoma H, Otsuji E*

- 3432** Radiological insights of ectopic thyroid in the porta hepatis: A case report and review of the literature  
*Chooah O, Ding J, Fei JL, Xu FY, Yue T, Pu CL, Hu HJ*
- 3442** Successful treatment of infantile hepatitis B with lamivudine: A case report  
*Zhang YT, Liu J, Pan XB, Gao YD, Hu YF, Lin L, Cheng HJ, Chen GY*
- 3449** Pure large cell neuroendocrine carcinoma originating from the endometrium: A case report  
*Du R, Jiang F, Wang ZY, Kang YQ, Wang XY, Du Y*
- 3458** Diabetic mastopathy in an elderly woman misdiagnosed as breast cancer: A case report and review of the literature  
*Chen XX, Shao SJ, Wan H*
- 3466** Cronkhite-Canada syndrome with steroid dependency: A case report  
*Jiang D, Tang GD, Lai MY, Huang ZN, Liang ZH*
- 3472** Extremely rare case of necrotizing gastritis in a patient with autoimmune hepatitis: A case report  
*Moon SK, Yoo JJ, Kim SG, Kim YS*
- 3478** Paget's disease of bone: Report of 11 cases  
*Miao XY, Wang XL, Lyu ZH, Ba JM, Pei Y, Dou JT, Gu WJ, Du J, Guo QH, Chen K, Mu YM*

**ABOUT COVER**

Editorial Board Member of *World Journal of Clinical Cases*, Nicola Montemurro, MD, PhD, Assistant Professor, Consultant Physician-Scientist, Neurosurgeon, Surgeon, Surgical Oncologist, Department of Translational Research and New Technologies in Medicine and Surgery, University of Pisa, Pisa 56126, Italy. nicola.montemurro@unipi.it

**AIMS AND SCOPE**

The primary aim of *World Journal of Clinical Cases* (WJCC, *World J Clin Cases*) is to provide scholars and readers from various fields of clinical medicine with a platform to publish high-quality clinical research articles and communicate their research findings online.

WJCC mainly publishes articles reporting research results and findings obtained in the field of clinical medicine and covering a wide range of topics, including case control studies, retrospective cohort studies, retrospective studies, clinical trials studies, observational studies, prospective studies, randomized controlled trials, randomized clinical trials, systematic reviews, meta-analysis, and case reports.

**INDEXING/ABSTRACTING**

The WJCC is now indexed in Science Citation Index Expanded (also known as SciSearch®), Journal Citation Reports/Science Edition, Scopus, PubMed, and PubMed Central. The 2020 Edition of Journal Citation Reports® cites the 2019 impact factor (IF) for WJCC as 1.013; IF without journal self cites: 0.991; Ranking: 120 among 165 journals in medicine, general and internal; and Quartile category: Q3. The WJCC's CiteScore for 2019 is 0.3 and Scopus CiteScore rank 2019: General Medicine is 394/529.

**RESPONSIBLE EDITORS FOR THIS ISSUE**

Production Editor: Jia-Hui Li; Production Department Director: Yun-Jie Ma; Editorial Office Director: Jin-Lei Wang.

**NAME OF JOURNAL**

*World Journal of Clinical Cases*

**ISSN**

ISSN 2307-8960 (online)

**LAUNCH DATE**

April 16, 2013

**FREQUENCY**

Thrice Monthly

**EDITORS-IN-CHIEF**

Dennis A Bloomfield, Sandro Vento, Bao-Gan Peng

**EDITORIAL BOARD MEMBERS**

<https://www.wjgnet.com/2307-8960/editorialboard.htm>

**PUBLICATION DATE**

May 16, 2021

**COPYRIGHT**

© 2021 Baishideng Publishing Group Inc

**INSTRUCTIONS TO AUTHORS**

<https://www.wjgnet.com/bpg/gerinfo/204>

**GUIDELINES FOR ETHICS DOCUMENTS**

<https://www.wjgnet.com/bpg/gerinfo/287>

**GUIDELINES FOR NON-NATIVE SPEAKERS OF ENGLISH**

<https://www.wjgnet.com/bpg/gerinfo/240>

**PUBLICATION ETHICS**

<https://www.wjgnet.com/bpg/gerinfo/288>

**PUBLICATION MISCONDUCT**

<https://www.wjgnet.com/bpg/gerinfo/208>

**ARTICLE PROCESSING CHARGE**

<https://www.wjgnet.com/bpg/gerinfo/242>

**STEPS FOR SUBMITTING MANUSCRIPTS**

<https://www.wjgnet.com/bpg/gerinfo/239>

**ONLINE SUBMISSION**

<https://www.f6publishing.com>



## Bone cement implantation syndrome during hip replacement in a patient with pemphigus and Parkinson's disease: A case report

Wei Zhou, Wen-Jing Zhang, Guo-Qing Zhao, Kai Li

**ORCID number:** Wei Zhou 0000-0003-3511-5927; Wen-Jing Zhang 0000-0001-7493-4488; Guo-Qing Zhao 0000-0002-9724-281X; Kai Li 0000-0002-9342-8836.

**Author contributions:** Zhou W collected the patient's clinical data and contributed to literature review; Li K reviewed the literature and drafted the manuscript; Zhang WJ contributed to manuscript revision; Zhao GQ made critical revisions related to important intellectual content of the manuscript; all authors read and approved the final manuscript.

### Informed consent statement:

Informed written consent was obtained from the patient for publication of this report and any accompanying images.

### Conflict-of-interest statement:

There is no conflict of interest for all authors.

### CARE Checklist (2016) statement:

The authors have read the CARE Checklist (2016), and the manuscript was prepared and revised according to the CARE Checklist (2016).

**Open-Access:** This article is an open-access article that was selected by an in-house editor and fully peer-reviewed by external reviewers. It is distributed in

**Wei Zhou,** Department of Anesthesiology, Tongde Hospital of Zhejiang Province, Hangzhou 310012, Zhejiang Province, China

**Wen-Jing Zhang, Guo-Qing Zhao, Kai Li,** Department of Anesthesiology, China Japan Union Hospital of Jilin University, Changchun 130021, Jilin Province, China

**Corresponding author:** Kai Li, MD, PhD, Doctor, Department of Anesthesiology, China Japan Union Hospital of Jilin University, No. 126 Xiantai Avenue, Changchun 130021, Jilin Province, China. [likai@jlu.edu.cn](mailto:likai@jlu.edu.cn)

## Abstract

### BACKGROUND

Bone cement implantation syndrome (BCIS) is characterized by hypotension, arrhythmia, diffuse pulmonary microvascular embolism, shock, cardiac arrest, any combination of these factors, or even death following bone cement implantation.

### CASE SUMMARY

An 80-year-old patient with pemphigus and Parkinson's disease underwent total hip replacement under spinal subarachnoid block and developed acute pulmonary embolism after bone cement implantation. The patient received mask mechanical ventilation with a continuous intravenous infusion of adrenaline (2 µg/mL) at a rate of 30 mL/h. Subsequently, the symptoms of BCIS were markedly alleviated, and the infusion rate of adrenaline was gradually reduced until the infusion was completely stopped 45 min later. The patient was then transferred to the Department of Orthopedics, and anticoagulation therapy began at 12 h postoperatively. No other complications were observed.

### CONCLUSION

This is a rare case of BCIS in a high-risk patient with pemphigus and Parkinson's disease.

**Key Words:** Bone cement implantation syndrome; Pemphigus; Parkinson's disease; Pulmonary embolism; Case report

©The Author(s) 2021. Published by Baishideng Publishing Group Inc. All rights reserved.



accordance with the Creative Commons Attribution NonCommercial (CC BY-NC 4.0) license, which permits others to distribute, remix, adapt, build upon this work non-commercially, and license their derivative works on different terms, provided the original work is properly cited and the use is non-commercial. See: <http://creativecommons.org/licenses/by-nc/4.0/>

**Manuscript source:** Unsolicited manuscript

**Specialty type:** Medicine, research and experimental

**Country/Territory of origin:** China

**Peer-review report's scientific quality classification**

Grade A (Excellent): 0  
Grade B (Very good): B  
Grade C (Good): 0  
Grade D (Fair): 0  
Grade E (Poor): 0

**Received:** October 4, 2020

**Peer-review started:** October 4, 2020

**First decision:** December 30, 2020

**Revised:** January 22, 2021

**Accepted:** March 3, 2021

**Article in press:** March 3, 2021

**Published online:** May 16, 2021

**P-Reviewer:** Labusca L

**S-Editor:** Fan JR

**L-Editor:** Wang TQ

**P-Editor:** Ma YJ



**Core Tip:** Bone cement implantation syndrome (BCIS) is an important cause of death and disability during the perioperative period of total hip replacement. The present patient with pemphigus and Parkinson's disease had a higher risk of BCIS than the general population due to pathophysiological changes and current medications. Therefore, the choice of anesthetic method for such patients must take full account of their current conditions. In addition, vital signs must be closely monitored intraoperatively to prevent the occurrence of BCIS.

**Citation:** Zhou W, Zhang WJ, Zhao GQ, Li K. Bone cement implantation syndrome during hip replacement in a patient with pemphigus and Parkinson's disease: A case report. *World J Clin Cases* 2021; 9(14): 3342-3349

**URL:** <https://www.wjgnet.com/2307-8960/full/v9/i14/3342.htm>

**DOI:** <https://dx.doi.org/10.12998/wjcc.v9.i14.3342>

## INTRODUCTION

Pemphigus is an autoimmune blistering disease in which autoantibodies attack the non-chromosomal group of epithelial cells, which leads to damage of the cell-cell adhesion; the first-line treatment for pemphigus is still immunosuppressant drugs such as corticosteroids[1]. There is no anesthetic protocol established for patients with pemphigus. However, for older adults with concurrent diseases affecting multiple organs, the anesthetic protocol should be minimally invasive, simple, effective, and easy to control.

Bone cement implantation syndrome (BCIS) is a common medical condition in which the bone marrow cavity is seriously injured by compression and fixation with bone cement, and a chemical reaction takes place in the closed space filled with bone cement. Under high temperature and pressure, the bone marrow enters the blood circulation. The presence of lipid droplets larger than 20  $\mu\text{m}$  is sufficient to cause pulmonary embolism[2]. Proposed severity classification of BCIS is classified as following: Grade 1, moderate hypoxia ( $\text{SpO}_2 < 94\%$ ) or hypotension [fall in systolic blood pressure (SBP)  $> 20\%$ ]; grade 2, severe hypoxia ( $\text{SpO}_2 < 88\%$ ) or hypotension (fall in SBP  $> 40\%$ ) or unexpected loss of consciousness; and grade 3, cardiovascular collapse requiring cardiopulmonary resuscitation. Because it is impossible to draw each meaningful hypotension and oxygen desaturation, the true incidence of BCIS, especially the lesser degrees, is not systematically collected or published, probably under-estimated[3].

Herein, we report the case of a high-risk older adult patient with a rare combination of pemphigus and Parkinson's disease who had suspected pulmonary embolism due to BCIS during total hip replacement.

## CASE PRESENTATION

### Chief complaints

An 80-year-old man was hospitalized due to pain in the right hip joint with restricted mobility.

### History of present illness

The patient's symptoms started after trauma 3 d ago.

### History of past illness

The patient had a history of pemphigus for 3 years, for which he was taking oral prednisone acetate (one 5 mg tablet daily). He also had a history of Parkinson's disease for over 10 years, for which he had not received any specific treatment.

### Physical examination

Physical examination findings were: height 170 cm and weight 42 kg; severe tremoring of both hands; extensive erosion and purulent scabs on the chest, abdomen, and all four limbs, but with a better integrity of the skin on the back; and scattered moist rales

in both lungs. The degree of mouth opening was two fingers wide, with erosion and bloody scabs in the mouth and oral mucosa, and a Mallampati grade of III. There was neither pain or stiffness nor swelling or redness below the knees.

### **Laboratory examinations**

Auxiliary examination showed that the coagulation function was normal. Biochemical liver test showed that aspartate aminotransferase was 77.73 IU/L, alanine aminotransferase was 66.21 IU/L, and albumin was 26.88 g/L. Arterial blood gas analysis findings were: pH 7.52, partial pressure of oxygen 51 mmHg, and partial pressure of carbon dioxide 42 mmHg.

### **Imaging examinations**

Cerebral computed tomography revealed bilateral multiple lacunar infarcts, leukoaraiosis, and encephalatrophy. Chest computed tomography showed scattered inflammatory lesions in both lungs, with mild bilateral pleural effusion, and mild pericardial effusion. Echocardiography showed widening of the ascending aorta, reduced diastolic left ventricular function, mild mitral and aortic regurgitation, and an ejection fraction of 57%. Vascular color Doppler ultrasound revealed acute-stage intramuscular venous thrombosis in the right calf.

---

## **FINAL DIAGNOSIS**

The patient was diagnosed with a fracture of the right femoral neck, intramuscular venous thrombosis in the right calf (acute stage), Parkinson's disease, pemphigus, type I respiratory failure, grade 1 hypertension (high risk), and cachexia syndrome.

---

## **TREATMENT**

The patient was scheduled for total hip replacement under combined epidural/spinal anesthesia; no preoperative anticoagulation therapy was given to reduce the risk of intraspinal hematoma.

**Figure 1** shows an image of the patient during treatment. The patient received mask oxygen therapy and non-invasive blood pressure (BP) monitoring, which showed a BP of 118/76 mmHg, heart rate (HR) of 88 bpm, and SpO<sub>2</sub> of 96%. Venous access was established only in the left elbow due to extensive skin ulceration, and hydroxyethyl starch was rapidly infused at a dose of 8 mL/kg. The patient was placed in the supine position and underwent urethral catheterization. Puncture was performed at the L2-L3 intervertebral space in the left lateral position, and 16 mg of 0.5% isobaric ropivacaine was injected into the subarachnoid space for spinal anesthesia. An indwelling epidural catheter was placed with a length of 3 cm on the cephalic side. The patient was cooperative during the above-mentioned procedures and made no complaint of discomfort.

Five minutes after the administration of spinal anesthesia, analgesia was confirmed at the T10 level and the surgery began. The vital signs were stable initially, and the bone cement was implanted 30 min later, shortly after precautionary pulse lavage of the medullary cavity. However, at 1 min post-implantation, the patient experienced chest tightness and agitation, and had a BP of 59/36 mmHg, HR of 75 bpm, and SpO<sub>2</sub> of 94%. Fluid replacement and intravenous injection of noradrenaline (NA) 8 µg were performed immediately; at this time, the BP was 74/43 mmHg, HR was 85 bpm, and SpO<sub>2</sub> was 94%. With mask mechanical ventilation, duplicated 1 mL of NA (8 µg/mL) was intravenously injected four times, resulting in a BP of 74-79/41-49 mmHg, HR of 80-83 bpm, and SpO<sub>2</sub> of 95%-97%. However, the patient still reported chest tightness and agitation. Pulmonary embolism was suspected, and so 2 mL of adrenaline (2 µg/mL) was injected intravenously, resulting in a BP of 91/55 mmHg, HR of 82 bpm, and SpO<sub>2</sub> of 99%. After another intravenous injection of 1 mL of adrenaline, the BP was 100/48 mmHg. Adrenaline (2 µg/mL) was continuously infused at 30 mL/h, and the infusion rate was gradually decreased. The vital signs stabilized and the patient reported no further discomfort. The surgery was completed 30 min later, the epidural catheter was removed, and the patient was transferred to the resuscitation room. The adrenaline infusion was completely stopped 45 min later, at which time the BP was 98/59 mmHg, HR was 74 bpm, and SpO<sub>2</sub> was 95%. **Figure 2** shows the intraoperative vital signs and the timeline of interventions performed.



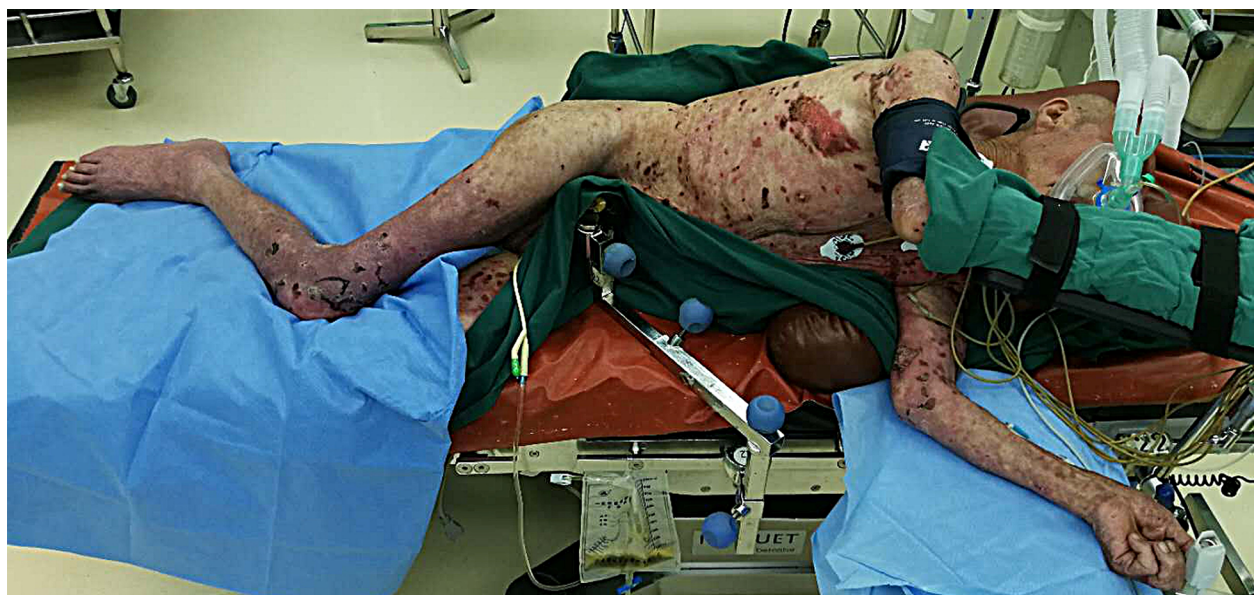

Figure 1 Image of the patient during treatment.

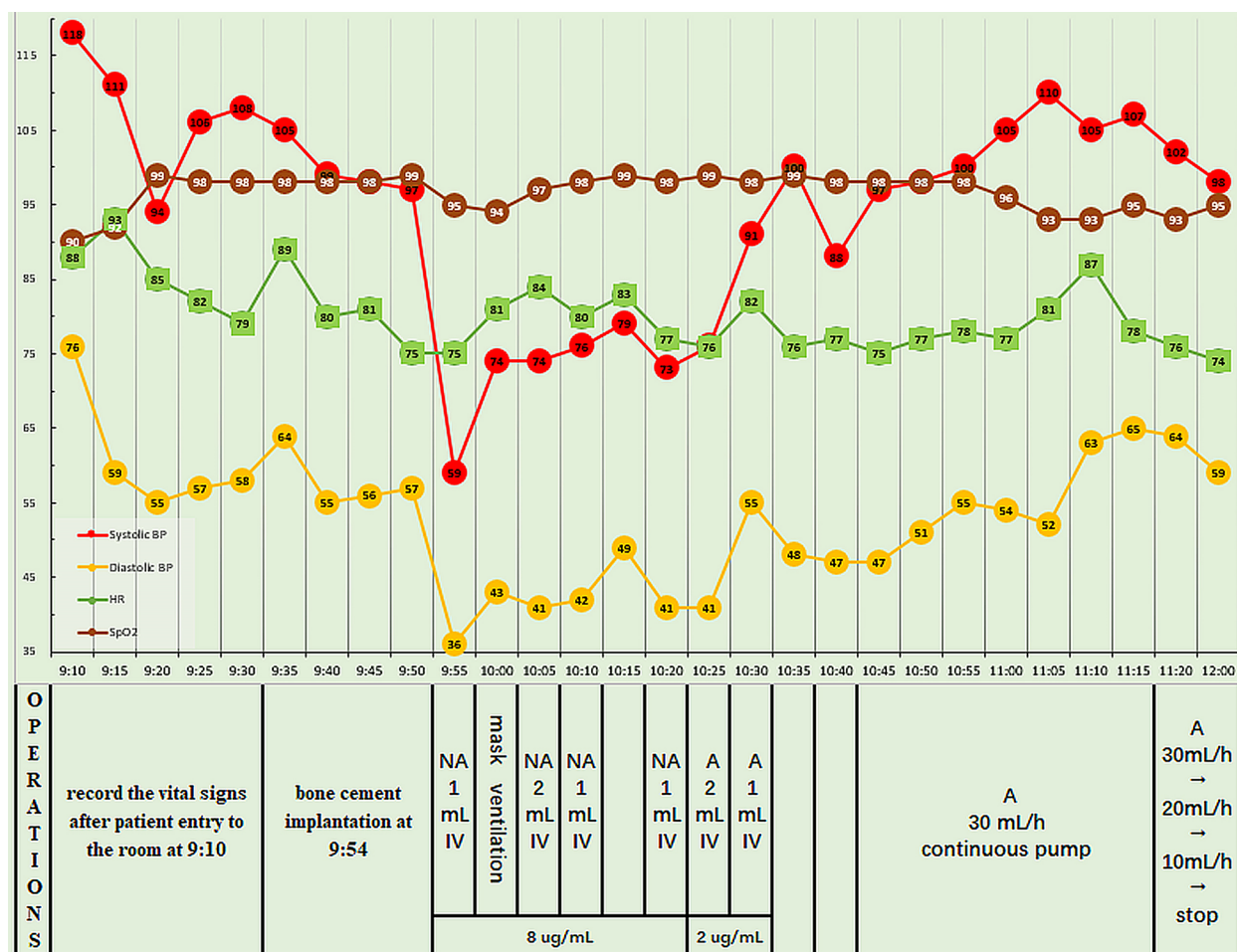


Figure 2 Intraoperative vital signs and timeline of interventions. NA: Noradrenaline; A: Adrenaline; BP: Blood pressure; HR: Heart rate.

## OUTCOME AND FOLLOW-UP

The patient was then transferred to the regular nursing floor of Orthopedics Department, and anticoagulation therapy was initiated 12 h postoperatively. No major complications occurred during 2 d of postoperative follow-up, and the patient was discharged 5 d postoperatively.

## DISCUSSION

BCIS is characterized by hypotension, arrhythmia, diffuse pulmonary microvascular embolism, shock, cardiac arrest, any combination of these conditions, or even death after implantation. The incidence of BCIS is about 65%, and those with BCIS have an incidence of cardiac arrest of 0.5%-10%, and a mortality rate of 0.6%-1.0%[4]. There are several mechanisms proposed for the development of BCIS. The serious mechanical injury in the bone marrow cavity associated with compression and fixation, together with a series of chemical reactions occurring in the confined space caused by bone cement, is the possible explanations. Under high temperature and high pressure, the bone marrow enters the circulation in a retrograde fashion, and pulmonary embolism can result from a lipid droplet with a diameter greater than 20  $\mu\text{m}$ [2]. The bone cement monomers that have entered the bloodstream act on the calcium channels in the vascular smooth muscle, dilating peripheral vessels and producing myocardial toxicity[5]. The cells damaged by the bone cement monomers release proteolytic enzymes that dissolve the cells and tissues; other consequences include increased platelet activity, thrombosis development, and aggravation of the inflammatory response[6]. The main lipid mediators of BCIS are endocannabinoids, including anandamide and 2-arachidonoylglycerol; these neurotransmitters are extremely strong vasodilators, which can cause hypotension[7]. The physiological consequences of embolization are considered to be the result of both a mechanical effect and mediator release, which provokes increased pulmonary vascular tone[4].

The diagnosis of BCIS is made based on the following criteria: (1) During the process of bone cement implantation, the patient presents with signs of sudden pulmonary embolism syndrome, including hypoxemia, pulmonary edema, transient hypotension or a marked reduction in BP, transient bradycardia, and even severe cardiac arrest; (2) Hemodynamic monitoring shows increased pulmonary artery pressure and pulmonary vessel resistance; and (3) Thrombi may be seen on transesophageal echocardiography, but these are not always detected. Therefore, the key to BCIS diagnosis is a high degree of clinical suspicion and vigilance[8].

The clinical manifestations of BCIS are as follows[2]: (1) An early, rapid, and large decrease in transient BP. The most marked decrease in BP occurs 3-5 min after implantation, mainly due to a decrease in diastolic BP. The BP can generally be recovered after 10 min. Some patients show a marked drop in BP, while the HR increases substantially after the decrease in BP. Some patients with BCIS experience bradycardia of a longer duration; (2) Electrocardiography shows an arrhythmia characterized by premature beats and ST-T changes; (3) Most patients have varying symptoms such as nausea, vomiting, dizziness, headache, and loss of consciousness; (4)  $\text{SpO}_2$  and  $\text{SaO}_2$  decrease, causing shortness of breath; and (5) When acute pulmonary edema occurs, patients have pink frothy phlegm, and wet rales are auscultated bilaterally. In the present case, chest tightness and agitation occurred abruptly during bone cement implantation 30 min after the administration of spinal anesthesia. While noradrenaline was ineffective, the continuous adrenaline infusion was beneficial; this was probably because the symptoms were less correlated to vasodilation than to shedding of intramuscular venous thrombi, pulmonary embolism, myocardial suppression, long-term use of methylprednisolone acetate, poor baseline condition (cachexia syndrome), and difficulty in redressing. The abovementioned manifestations basically accord with the clinical characteristics of BCIS, and so BCIS was suspected. The risk factors for BCIS include advanced age, poor preoperative physiological function reserve, and impaired cardiopulmonary function. Independent risk factors affecting the development of BCIS are a high American Society of Anesthesiologists (ASA) grade, chronic obstructive pulmonary disease, diuretic administration, and warfarin treatment[9]. In this case, the patient suffered from Parkinson's disease without systematic treatment, which can lead to excessive muscle tension and lack of movement. At the same time, due to the poor basic state, the patient was bedridden, leading to muscle atrophy, which may be a high risk of BCIS. Thus, the present patient was at high risk of BCIS due to an ASA grade of III,

advanced age, pemphigus, Parkinson's disease, cachexia syndrome, and other multisystem diseases.

Pemphigus is an autoimmune blistering disease that usually results in multiple oral and general erosions with flaccid bullae and positivity for Nikolsky's sign. However, the pathogenesis of pemphigus remains unclear, and immunosuppressant drugs such as corticosteroids still represent the first-line treatment, despite the potential for serious adverse effects[1]. A previous review found no recommended anesthetic protocol for pemphigus[10]. Local anesthesia is the first choice, and should be performed under strictly sterile conditions to avoid secondary infection arising from lesion exfoliation. However, local puncture and infiltration anesthesia cannot be performed for bullous skin lesions. Opioids used during general anesthesia may lead to pruritus and aggravate the progression of pemphigus. Moreover, it is best to avoid tracheal intubation to prevent damage to the vulnerable larynx[11]. A case report of anesthetic management for emergency laparotomy in a patient with pemphigus emphasized that touch or injury of the patient must be minimized during monitoring equipment installation, intravenous injection, and airway intervention, as the performance of these procedures may cause further blistering[12]. Moreover, local anesthesia should be avoided if possible before deep vein puncture and arterial intubation. After the preparatory work is done, no tapes should be used to fix the tubes, which should instead be sutured to the skin to avoid creating blisters. Clinicians should avoid using monitoring equipment that causes skin friction, such as electrocardiogram electrodes or BP cuffs. If tracheal intubation cannot be avoided, small-sized tubes should be used. Furthermore, the laryngoscope lens and tracheal catheter should be lubricated, and adrenaline in normal saline (1:500000) should be placed in the throat to reduce the bleeding and stimulation caused by tube withdrawal. An appropriate amount of supplemental corticosteroids can help patients with pemphigus to survive the perioperative period without markedly increasing the occurrence of infections and poor wound healing. This is considered a safe and reliable perioperative management strategy for patients with pemphigus who are on long-term oral hormone replacement therapy. In the present patient who underwent total joint replacement (considered moderate surgical stress), cortisol production rates suggest that the glucocorticoid target is about 50 to 75 mg per day of a hydrocortisone equivalent for 1 to 2 d. Thus, the present patient should have received 5 mg of oral prednisone acetate preoperatively, and 50 mg of intravenous hydrocortisone intraoperatively. We suggest the intravenous administration of 60 mg of hydrocortisone (20 mg every 8 h) on postoperative day 1, with a return to the patient's preoperative glucocorticoid dose (enterally or parenterally) on postoperative day 2[13]. Anticoagulation therapy initiated 12 h postoperatively without any difference from routine prevention of polyethylene, based on the comprehensive consideration of the temporary characteristic of BICS, relatively low risk of intramuscular venous thrombosis, and possibility of epidural hematoma[4].

In Parkinson's disease, autonomic neuropathy can lead to a resting tremor, cough, and swallowing difficulty, which increases the risk of respiratory tract infection[14]. Although the incidence of aspiration pneumonia is low in those with Parkinson's disease, aspiration pneumonia is still the leading cause of death in this population[15]. In Parkinson's disease, general anesthesia may be associated with a greater risk of postoperative pneumonia, delirium, and cognitive impact than combined epidural-spinal anesthesia[16]. Furthermore, fasting from food and water may interfere with the effect of oral L-dopa, while residual neuromuscular-blocking drugs and antagonists may mask or aggravate respiratory muscle rigidity, bradykinesia, polysialia, atelectasis, aspiration, and respiratory tract infection. However, few local anesthetics are available for use. It is important to achieve minimal disturbance to brain neurotransmitters, and oral drugs should not be withdrawn. Adrenaline can enhance the  $\beta$ -adrenergic effect of peripheral dopamine, while ephedrine can promote dopamine release; thus, both of these drugs should be avoided in patients with Parkinson's disease.

The present patient was an older adult, had concomitant diseases in multiple systems, as well as pemphigus, Parkinson's disease, an ASA grade of III, and acute intramuscular venous thrombosis, and was on long-term oral medications. He also had difficulty in opening his mouth and oral mucosal ulceration, and was considered high risk for general anesthesia and associated complications; thus, we performed spinal anesthesia rather than general anesthesia. Although the circulation is usually stable during nerve block, the procedures are made more challenging by the use of larger anesthetic doses, multiple puncture sites, and a longer anesthetic duration. A nerve block may be used in combination with shallow general anesthesia. Combined epidural-spinal anesthesia involves fewer puncture sites and easy manipulation, and



has a proven effect, adjustability, longer maintenance of anesthetic effect, and little disturbance to the routine oral medications.

In patients with suspected BCIS, the inspired oxygen concentration should be increased to 100%, and supplementary oxygen should be continued postoperatively[5]. In addition, tracheal intubation and mechanical ventilation should be performed immediately if necessary; when dopamine is not effective, 5-50 µg of adrenaline can be administered to provide the vital organs with sufficient perfusion. Moreover, it is very important to maintain good communication between the surgeon and anesthetist during critical moments. For example, in knee joint replacement surgery, a large number of venous emboli may be released when the tourniquet is released, and so the surgeon should inform the other staff before releasing the tourniquet[17]. In addition, the severity of BCIS can be mitigated by preemptive administration of glucocorticoid, early supplementation of an appropriate amount of colloidal fluid, bone marrow cavity rinsing with low-concentration adrenaline, and an infusion of dopamine 2-8 µg/(kg m).

## CONCLUSION

We have reported a case of suspected pulmonary embolism during total hip replacement in a patient with pemphigus and Parkinson's disease. Pemphigus with concomitant Parkinson's disease is rare, especially in an older adult patient with multisystem disorders. The anesthetic protocol used in such patients should be minimally invasive, simple, effective, and easy to control. These patients are more likely to develop BCIS, and so active invasive arterial monitoring and other comprehensive preventive measures should be adopted. When vasoactive drugs such as ephedrine and dopamine are ineffective, the immediate use of adrenaline may be the best option.

## REFERENCES

- 1 **Vodo D**, Sarig O, Sprecher E. The Genetics of Pemphigus Vulgaris. *Front Med (Lausanne)* 2018; **5**: 226 [PMID: 30155467 DOI: 10.3389/fmed.2018.00226]
- 2 **Gu Y**, Li L, Zhao F, Li K. [Diagnosis and treatment of acute pulmonary fat embolism induced cardiac arrest: an analysis of 1 case]. *Zhonghua Wei Zhong Bing Ji Jiu Yi Xue* 2014; **26**: 759-760 [PMID: 25315954]
- 3 **Dradjat RS**, Pradana AS, Putra DP, Hexa Pandiangan RA, Cendikiawan F, Mustamsir E. Successful management of severe manifestation bone cemented implantation syndrome during hemiarthroplasty surgery in patient with multiple comorbidities: A case report. *Int J Surg Case Rep* 2021; **78**: 331-335 [PMID: 33388512 DOI: 10.1016/j.ijscr.2020.12.076]
- 4 **Donaldson AJ**, Thomson HE, Harper NJ, Kenny NW. Bone cement implantation syndrome. *Br J Anaesth* 2009; **102**: 12-22 [PMID: 19059919 DOI: 10.1093/bja/aen328]
- 5 **Govil P**, Kakar PN, Arora D, Das S, Gupta N, Govil D, Gupta S, Malohtra A. Bone cement implantation syndrome: a report of four cases. *Indian J Anaesth* 2009; **53**: 214-218 [PMID: 20640126]
- 6 **Blinc A**, Bozic M, Vengust R, Stegnar M. Methyl-methacrylate bone cement surface does not promote platelet aggregation or plasma coagulation in vitro. *Thromb Res* 2004; **114**: 179-184 [PMID: 15342214 DOI: 10.1016/j.thromres.2004.05.010]
- 7 **Motobe T**, Hashiguchi T, Uchimura T, Yamakuchi M, Taniguchi N, Komiya S, Maruyama I. Endogenous cannabinoids are candidates for lipid mediators of bone cement implantation syndrome. *Shock* 2004; **21**: 8-12 [PMID: 14676677 DOI: 10.1097/01.SHK.0000094766.36694.49]
- 8 **Singh V**, Bhakta P, Zietak E, Hussain A. Bone cement implantation syndrome: a delayed postoperative presentation. *J Clin Anesth* 2016; **31**: 274-277 [PMID: 27185726 DOI: 10.1016/j.jclinane.2016.01.041]
- 9 **Olsen F**, Kotyra M, Houltz E, Ricksten SE. Bone cement implantation syndrome in cemented hemiarthroplasty for femoral neck fracture: incidence, risk factors, and effect on outcome. *Br J Anaesth* 2014; **113**: 800-806 [PMID: 25031262 DOI: 10.1093/bja/aeu226]
- 10 **Bansal A**, Tewari A, Garg S, Kanwal A. Anesthetic considerations in pemphigus vulgaris: Case series and review of literature. *Saudi J Anaesth* 2012; **6**: 165-168 [PMID: 22754445 DOI: 10.4103/1658-354X.97032]
- 11 **Vasilou A**, Nikolopoulos TP, Manolopoulos L, Yiotakis J. Laryngeal pemphigus without skin manifestations and review of the literature. *Eur Arch Otorhinolaryngol* 2007; **264**: 509-512 [PMID: 17111102 DOI: 10.1007/s00405-006-0208-6]
- 12 **Mahalingam TG**, Kathirvel S, Sodhi P. Anaesthetic management of a patient with pemphigus vulgaris for emergency laparotomy. *Anaesthesia* 2000; **55**: 160-162 [PMID: 10651679 DOI: 10.1054/anaes.2000.35445]

- 10.1046/j.1365-2044.2000.055002160.x]
- 13 **Salem M**, Tainsh RE Jr, Bromberg J, Loriaux DL, Chernow B. Perioperative glucocorticoid coverage. A reassessment 42 years after emergence of a problem. *Ann Surg* 1994; **219**: 416-425 [PMID: 8161268 DOI: 10.1097/0000658-199404000-00013]
- 14 **Shaikh SI**, Verma H. Parkinson's disease and anaesthesia. *Indian J Anaesth* 2011; **55**: 228-234 [PMID: 21808393 DOI: 10.4103/0019-5049.82658]
- 15 **Lee JH**, Lee KW, Kim SB, Lee SJ, Chun SM, Jung SM. The Functional Dysphagia Scale Is a Useful Tool for Predicting Aspiration Pneumonia in Patients With Parkinson Disease. *Ann Rehabil Med* 2016; **40**: 440-446 [PMID: 27446780 DOI: 10.5535/arm.2016.40.3.440]
- 16 **Shanthanna H**. Stiff man syndrome and anaesthetic considerations: successful management using combined spinal epidural anaesthesia. *J Anaesthesiol Clin Pharmacol* 2010; **26**: 547-548 [PMID: 21547190]
- 17 **Schwarzkopf E**, Sachdev R, Flynn J, Boddapati V, Padilla RE, Prince DE. Occurrence, risk factors, and outcomes of bone cement implantation syndrome after hemi and total hip arthroplasty in cancer patients. *J Surg Oncol* 2019; **120**: 1008-1015 [PMID: 31432531 DOI: 10.1002/jso.25675]



Published by **Baishideng Publishing Group Inc**  
7041 Koll Center Parkway, Suite 160, Pleasanton, CA 94566, USA

**Telephone:** +1-925-3991568

**E-mail:** [bpgoffice@wjgnet.com](mailto:bpgoffice@wjgnet.com)

**Help Desk:** <https://www.f6publishing.com/helpdesk>

<https://www.wjgnet.com>

