

World Journal of *Clinical Cases*

World J Clin Cases 2021 May 16; 9(14): 3227-3486



Contents

Thrice Monthly Volume 9 Number 14 May 16, 2021

MINIREVIEWS

- 3227** Non-invasive physical therapy as salvage measure for ischemic skin flap: A literature review
Zheng YH, Yin LQ, Xu HK, Gong X
- 3238** Prediction models for development of hepatocellular carcinoma in chronic hepatitis B patients
Guo J, Gao XS

ORIGINAL ARTICLE

Retrospective Cohort Study

- 3252** Burden of atrial fibrillation in patients with rheumatic diseases
Khan MZ, Patel K, Patel KA, Doshi R, Shah V, Adalja D, Waqar Z, Franklin S, Gupta N, Gul MH, Jesani S, Kutalek S, Figueredo V

Retrospective Study

- 3265** Observation of the effect of one-to-one education on high-risk cases of diabetic foot
Fu XJ, Hu SD, Peng YF, Zhou LY, Shu T, Song DD
- 3273** Pediatric Wilson disease presenting as acute liver failure: Prognostic indices
Fang WY, Abuduxikuer K, Shi P, Qiu YL, Zhao J, Li YC, Zhang XY, Wang NL, Xie XB, Lu Y, Knisely AS, Wang JS

Observational Study

- 3287** Positive psychological intervention for anxiety, depression and coping in subjects addicted to online games
Gao XJ, Sun JJ, Xiang M

SYSTEMATIC REVIEWS

- 3294** Cluster headache due to structural lesions: A systematic review of published cases
Long RJ, Zhu YS, Wang AP

META-ANALYSIS

- 3308** Comparison of smear cytology with liquid-based cytology in pancreatic lesions: A systematic review and meta-analysis
Zhang XH, Ma SY, Liu N, Wei ZC, Gao X, Hao YJ, Liu YX, Cai YQ, Wang JH

CASE REPORT

- 3320** Bronchial glomus tumor with calcification: A case report
Zhang Y, Zhang QP, Ji YQ, Xu J

- 3327** Acute flaccid paralysis and neurogenic respiratory failure associated with enterovirus D68 infection in children: Report of two cases
Zhang Y, Wang SY, Guo DZ, Pan SY, Lv Y
- 3334** Skeletal muscle metastases of hepatocellular carcinoma: A case report and literature review
Song Q, Sun XF, Wu XL, Dong Y, Wang L
- 3342** Bone cement implantation syndrome during hip replacement in a patient with pemphigus and Parkinson's disease: A case report
Zhou W, Zhang WJ, Zhao GQ, Li K
- 3350** Novel intergenic *KIF5B-MET* fusion variant in a patient with gastric cancer: A case report
Wu ZW, Sha Y, Chen Q, Hou J, Sun Y, Lu WK, Chen J, Yu LJ
- 3356** Recurrent perimesencephalic nonaneurysmal subarachnoid hemorrhage within a short period of time: A case report
Li J, Fang X, Yu FC, Du B
- 3365** Incremental value of three-dimensional and contrast echocardiography in the evaluation of endocardial fibroelastosis and multiple cardiovascular thrombi: A case report
Sun LJ, Li Y, Qiao W, Yu JH, Ren WD
- 3372** Floating elbow combining ipsilateral distal multiple segmental forearm fractures: A case report
Huang GH, Tang JA, Yang TY, Liu Y
- 3379** Acute cholangitis detected ectopic ampulla of Vater in the antrum incidentally: A case report
Lee HL, Fu CK
- 3385** Almitrine for COVID-19 critically ill patients – a vascular therapy for a pulmonary vascular disease: Three case reports
Huette P, Abou Arab O, Jounieaux V, Guilbart M, Belhout M, Haye G, Dupont H, Beyls C, Mahjoub Y
- 3394** Tenosynovial giant cell tumor involving the cervical spine: A case report
Zhu JH, Li M, Liang Y, Wu JH
- 3403** Primary bone anaplastic lymphoma kinase positive anaplastic large-cell lymphoma: A case report and review of the literature
Zheng W, Yin QQ, Hui TC, Wu WH, Wu QQ, Huang HJ, Chen MJ, Yan R, Huang YC, Pan HY
- 3411** Acute spontaneous thoracic epidural hematoma associated with intraspinal lymphangioma: A case report
Chia KJ, Lin LH, Sung MT, Su TM, Huang JF, Lee HL, Sung WW, Lee TH
- 3418** Change in neoadjuvant chemotherapy could alter the prognosis of patients with pancreatic adenocarcinoma: A case report
Meyer A, Carvalho BJ, Medeiros KA, Pipek LZ, Nascimento FS, Suzuki MO, Munhoz JV, Iuamoto LR, Carneiro-D'Albuquerque LA, Andraus W
- 3424** Laparoscopic cholecystectomy for gangrenous cholecystitis in around nineties: Two case reports
Inoue H, Ochiai T, Kubo H, Yamamoto Y, Morimura R, Ikoma H, Otsuji E

- 3432** Radiological insights of ectopic thyroid in the porta hepatis: A case report and review of the literature
Chooah O, Ding J, Fei JL, Xu FY, Yue T, Pu CL, Hu HJ
- 3442** Successful treatment of infantile hepatitis B with lamivudine: A case report
Zhang YT, Liu J, Pan XB, Gao YD, Hu YF, Lin L, Cheng HJ, Chen GY
- 3449** Pure large cell neuroendocrine carcinoma originating from the endometrium: A case report
Du R, Jiang F, Wang ZY, Kang YQ, Wang XY, Du Y
- 3458** Diabetic mastopathy in an elderly woman misdiagnosed as breast cancer: A case report and review of the literature
Chen XX, Shao SJ, Wan H
- 3466** Cronkhite-Canada syndrome with steroid dependency: A case report
Jiang D, Tang GD, Lai MY, Huang ZN, Liang ZH
- 3472** Extremely rare case of necrotizing gastritis in a patient with autoimmune hepatitis: A case report
Moon SK, Yoo JJ, Kim SG, Kim YS
- 3478** Paget's disease of bone: Report of 11 cases
Miao XY, Wang XL, Lyu ZH, Ba JM, Pei Y, Dou JT, Gu WJ, Du J, Guo QH, Chen K, Mu YM

ABOUT COVER

Editorial Board Member of *World Journal of Clinical Cases*, Nicola Montemurro, MD, PhD, Assistant Professor, Consultant Physician-Scientist, Neurosurgeon, Surgeon, Surgical Oncologist, Department of Translational Research and New Technologies in Medicine and Surgery, University of Pisa, Pisa 56126, Italy. nicola.montemurro@unipi.it

AIMS AND SCOPE

The primary aim of *World Journal of Clinical Cases* (WJCC, *World J Clin Cases*) is to provide scholars and readers from various fields of clinical medicine with a platform to publish high-quality clinical research articles and communicate their research findings online.

WJCC mainly publishes articles reporting research results and findings obtained in the field of clinical medicine and covering a wide range of topics, including case control studies, retrospective cohort studies, retrospective studies, clinical trials studies, observational studies, prospective studies, randomized controlled trials, randomized clinical trials, systematic reviews, meta-analysis, and case reports.

INDEXING/ABSTRACTING

The WJCC is now indexed in Science Citation Index Expanded (also known as SciSearch®), Journal Citation Reports/Science Edition, Scopus, PubMed, and PubMed Central. The 2020 Edition of Journal Citation Reports® cites the 2019 impact factor (IF) for WJCC as 1.013; IF without journal self cites: 0.991; Ranking: 120 among 165 journals in medicine, general and internal; and Quartile category: Q3. The WJCC's CiteScore for 2019 is 0.3 and Scopus CiteScore rank 2019: General Medicine is 394/529.

RESPONSIBLE EDITORS FOR THIS ISSUE

Production Editor: Jia-Hui Li; Production Department Director: Yun-Jie Ma; Editorial Office Director: Jin-Lei Wang.

NAME OF JOURNAL

World Journal of Clinical Cases

ISSN

ISSN 2307-8960 (online)

LAUNCH DATE

April 16, 2013

FREQUENCY

Thrice Monthly

EDITORS-IN-CHIEF

Dennis A Bloomfield, Sandro Vento, Bao-Gan Peng

EDITORIAL BOARD MEMBERS

<https://www.wjgnet.com/2307-8960/editorialboard.htm>

PUBLICATION DATE

May 16, 2021

COPYRIGHT

© 2021 Baishideng Publishing Group Inc

INSTRUCTIONS TO AUTHORS

<https://www.wjgnet.com/bpg/gerinfo/204>

GUIDELINES FOR ETHICS DOCUMENTS

<https://www.wjgnet.com/bpg/gerinfo/287>

GUIDELINES FOR NON-NATIVE SPEAKERS OF ENGLISH

<https://www.wjgnet.com/bpg/gerinfo/240>

PUBLICATION ETHICS

<https://www.wjgnet.com/bpg/gerinfo/288>

PUBLICATION MISCONDUCT

<https://www.wjgnet.com/bpg/gerinfo/208>

ARTICLE PROCESSING CHARGE

<https://www.wjgnet.com/bpg/gerinfo/242>

STEPS FOR SUBMITTING MANUSCRIPTS

<https://www.wjgnet.com/bpg/gerinfo/239>

ONLINE SUBMISSION

<https://www.f6publishing.com>



Cronkhite-Canada syndrome with steroid dependency: A case report

Dan Jiang, Guo-Du Tang, Ming-Yu Lai, Zhen-Ning Huang, Zhi-Hai Liang

ORCID number: Dan Jiang 0000-0001-5475-4869; Guo-Du Tang 0000-0003-0254-3570; Ming-Yu Lai 0000-0002-1291-696X; Zhen-Ning Huang 0000-0001-8530-3059m; Zhi-Hai Liang 0000-0001-5348-0130.

Author contributions: Jiang D collected basic patient information and imaging data and wrote the main content of the manuscript; Tang GD reviewed the literature and made the diagnosis; Lai MY and Huang ZN were responsible for the analysis and interpretation of data; Liang ZH was responsible for the conception and design of the study and the final approval of the version of the article to be published; All authors have read and approve the final manuscript.

Informed consent statement: Informed written consent was obtained from the patient for publication of this report and any accompanying images.

Conflict-of-interest statement: The authors declare that they have no conflicts of interest.

CARE Checklist (2016) statement: The authors have read the CARE Checklist (2016), and the manuscript was prepared and revised according to the CARE Checklist (2016).

Open-Access: This article is an open-access article that was selected by an in-house editor and

Dan Jiang, Guo-Du Tang, Ming-Yu Lai, Zhen-Ning Huang, Zhi-Hai Liang, Department of Gastroenterology, The First Affiliated Hospital of Guangxi Medical University, Nanning 530021, Guangxi Zhuang Autonomous Region, China

Corresponding author: Zhi-Hai Liang, MD, Professor, Department of Gastroenterology, The First Affiliated Hospital of Guangxi Medical University, No. 6 Shuangyong Road, Nanning 530021, Guangxi Zhuang Autonomous Region, China. lzh@stu.gxmu.edu.cn

Abstract

BACKGROUND

Cronkhite-Canada syndrome (CCS) is a rare nonhereditary disease characterized by chronic diarrhoea, diffuse gastrointestinal polyposis and ectodermal manifestations. The lethality of CCS can be up to 50% if it is untreated or if treatment is delayed or inadequate. More than 35% of the patients do not achieve long-term clinical remission after corticosteroid administration, with relapse occurring during or after the cessation of glucocorticoid use. The optimal strategy of maintenance therapy of this disease is controversial.

CASE SUMMARY

A 47-year-old man presented to the hospital with a 3-mo history of frequent watery diarrhoea, accompanied by macular skin pigmentation that included the palms and soles, and onychodystrophy of the fingernails and toenails. Gastroscopy and colonoscopy revealed numerous polyps in the stomach and colon. After other possibilities were ruled out by a series of examinations, CCS was diagnosed and treated with prednisone. The patient took prednisone for more than 1 year before achieving complete resolution of his symptoms and endoscopic findings. The patient was then given prednisone 5 mg/d for 6 mo of maintenance therapy. With clinical improvement and polyp regression, prednisone was discontinued. Eight mo after the discontinuation of prednisone, the diarrhoea and gastrointestinal polyps relapsed. Therefore, the patient was given the same dose of prednisone, and complete remission was achieved again.

CONCLUSION

It is necessary to extend the duration of prednisone maintenance therapy for CCS. Prednisone is still effective when readministered after relapse. Surveillance endoscopy at intervals of 1 year or less is recommended to assess mucosal disease activity.

Key Words: Cronkhite-Canada syndrome; Endoscopy; Prednisone; Relapse; Maintenance therapy; Case report

fully peer-reviewed by external reviewers. It is distributed in accordance with the Creative Commons Attribution NonCommercial (CC BY-NC 4.0) license, which permits others to distribute, remix, adapt, build upon this work non-commercially, and license their derivative works on different terms, provided the original work is properly cited and the use is non-commercial. See: <http://creativecommons.org/licenses/by-nc/4.0/>

Manuscript source: Unsolicited manuscript

Specialty type: Medicine, research and experimental

Country/Territory of origin: China

Peer-review report's scientific quality classification

Grade A (Excellent): 0
Grade B (Very good): 0
Grade C (Good): 0
Grade D (Fair): 0
Grade E (Poor): 0

Received: December 15, 2020

Peer-review started: December 15, 2020

First decision: January 17, 2021

Revised: January 27, 2021

Accepted: March 15, 2021

Article in press: March 15, 2021

Published online: May 16, 2021

P-Reviewer: de Nucci G

S-Editor: Fan JR

L-Editor: Filipodia

P-Editor: Liu JH



©The Author(s) 2021. Published by Baishideng Publishing Group Inc. All rights reserved.

Core Tip: Cronkhite-Canada syndrome (CCS) is a rare gastrointestinal polyposis syndrome. Here, we report a case of CCS that has been followed for almost 4 years. The patient was treated with prednisone. After he discontinued prednisone, his clinical and endoscopic manifestations relapsed. The patient was given prednisone again, and it was effective in bringing about a second remission. It is necessary to extend the duration of prednisone maintenance therapy for CCS. Surveillance endoscopy at intervals of 1 year or less is recommended to assess mucosal disease activity.

Citation: Jiang D, Tang GD, Lai MY, Huang ZN, Liang ZH. Cronkhite-Canada syndrome with steroid dependency: A case report. *World J Clin Cases* 2021; 9(14): 3466-3471

URL: <https://www.wjgnet.com/2307-8960/full/v9/i14/3466.htm>

DOI: <https://dx.doi.org/10.12998/wjcc.v9.i14.3466>

INTRODUCTION

Cronkhite-Canada syndrome (CCS) is a rare gastrointestinal polyposis syndrome characterized by dermatologic manifestations associated with chronic diarrhoea, malnutrition, and enteric protein wasting resulting from chronic inflammatory changes in the intestinal mucosa[1-3]. Since the disease was first described in 1955, only approximately 500 patients with CCS have been reported worldwide, among which over 70% were from Japan[2,4,5]. Although disease presentation has been well described, there is no consensus on the management of CCS. Its clinical course is characterized by progressive disease with occasional spontaneous remissions and frequent relapses[6]. The lethality of CCS can be up to 50% if it is untreated or if treatment is delayed or inadequate. The 5-year mortality of CCS patients can be as high as 55% secondary to complications[7].

CASE PRESENTATION

Chief complaints

A 47-year-old Chinese man presented to the hospital with frequent watery diarrhoea.

History of present illness

The patient had no history of prior illness and no family history of any similar disease.

History of past illness

The patient's symptoms had started 3 mo prior with frequent watery diarrhoea (4-5 times/d). For nearly a month, there was apparent blood in the diarrhoea and positive faecal occult blood with acid regurgitation, eructation, occasional nausea, and a weight loss of 10 kg within 2 mo. The patient was treated with symptomatic therapies, such as spasmolytics and antibiotics, which were ineffective in alleviating his symptoms.

Personal and family history

The patient had no history of prior illness and no family history of any similar disease.

Physical examination

A physical examination revealed marked alopecia; brownish macular pigmentation of the facial region, palms and soles; and onychodystrophy of the fingernails and toenails (Figure 1).

Laboratory evaluation

The laboratory findings included a positive faecal occult blood showing 0-2 red blood cells/haptoglobin, an albumin concentration of 32.7 g/L (normal range 40-55 g/L), and cytoplasmic antinuclear antibody positivity with a titre of 1:320.

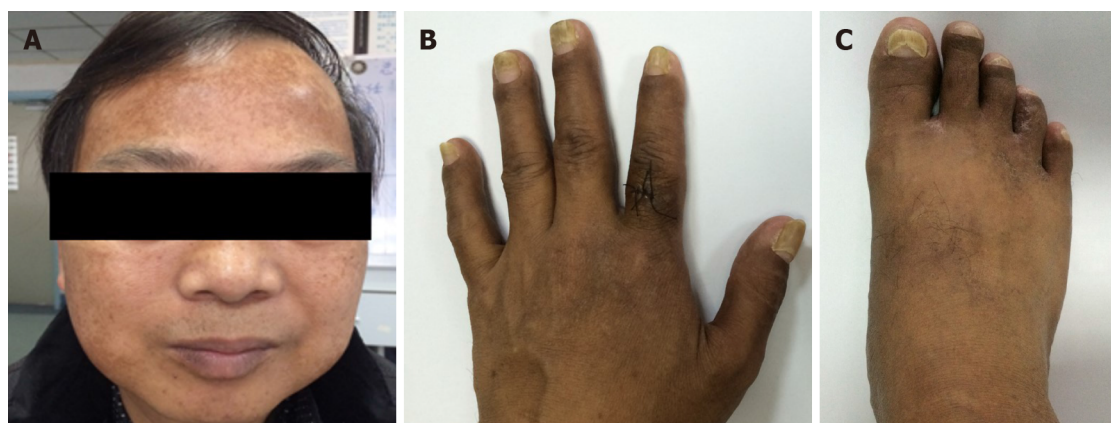


Figure 1 Physical examination findings included alopecia, brown macular pigmentation over the facial region, palms and soles, and onychodystrophy of the fingernails and toenails. A: Facial region; B: Palms; C: Soles.

Imaging evaluation

Gastroscopy revealed multiple polyps in the stomach and duodenum (Figure 2A). Endoscopic ultrasonography revealed diffuse thickening of the gastric mucosa to 8.5 mm (*i.e.* massive enlargement of the mucosa and submucosa), and the polyps originated from the mucosa, which was internally hyperechoic and inhomogeneous (Figure 2B). Colonoscopy revealed numerous polyps occupying the colonic and rectal mucosa (Figure 2C).

Further diagnostic work-up

Histological examination of biopsy specimens obtained from the colon and the stomach was consistent with hyperplastic polyps, and immunoglobulin G 4 staining was negative.

FINAL DIAGNOSIS

The final diagnosis of the present case was CCS.

TREATMENT

Oral administration of prednisone was initiated at 40 mg/d, and the daily steroid dose was varied in a tapered regimen, with a decrease of 5 mg every 4 wk.

OUTCOME AND FOLLOW-UP

After 3 mo of treatment, the gastrointestinal symptoms and ectodermal manifestations began disappearing one-by-one, and gastrointestinal endoscopy showed small, sparsely distributed polyps. After 6 mo of treatment, the patient's skin colour was normal and his nail dystrophy was improved (Figure 3A and B). Gastroscopy and colonoscopy showed that the polyps were significantly reduced in size and number. However, the patient's gastrointestinal manifestations relapsed, including diarrhoea; in response, we slowed the prednisone reduction, subtracting 5 mg from the daily dose only once every 3-6 mo. Until April 2018, the patient took only 5 mg of prednisone a day. After 14 mo of treatment, he was admitted to our hospital again for follow-up. The faecal occult blood test was negative; serum albumin levels had risen to normal. Additionally, the tumour markers were negative. Gastroscopy revealed several polyps with a diameter of 3-4 mm in the gastric antrum and duodenum. Some of the polyps were removed by endoscopic mucosal resection (Figure 3C). Colonoscopy revealed polyp regression (Figure 3D). Beginning in April 2018, the patient was given 5 mg of prednisone/d for 6 mo of maintenance therapy. With clinical improvement and polyp regression, prednisone was discontinued.

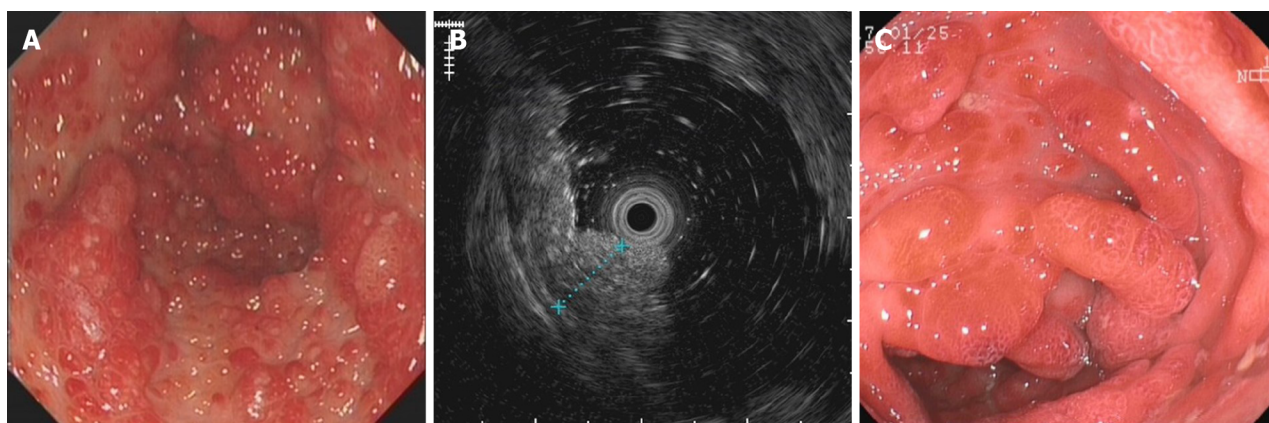


Figure 2 Gastroscopy. A: Gastroscopy revealed multiple polyps in the stomach; B: Endoscopic ultrasonography revealed diffuse thickening of the gastric mucosa of up to 8.5 mm in thickness; C: Colonoscopy revealed numerous polyps occupying the colonic and rectal mucosa.

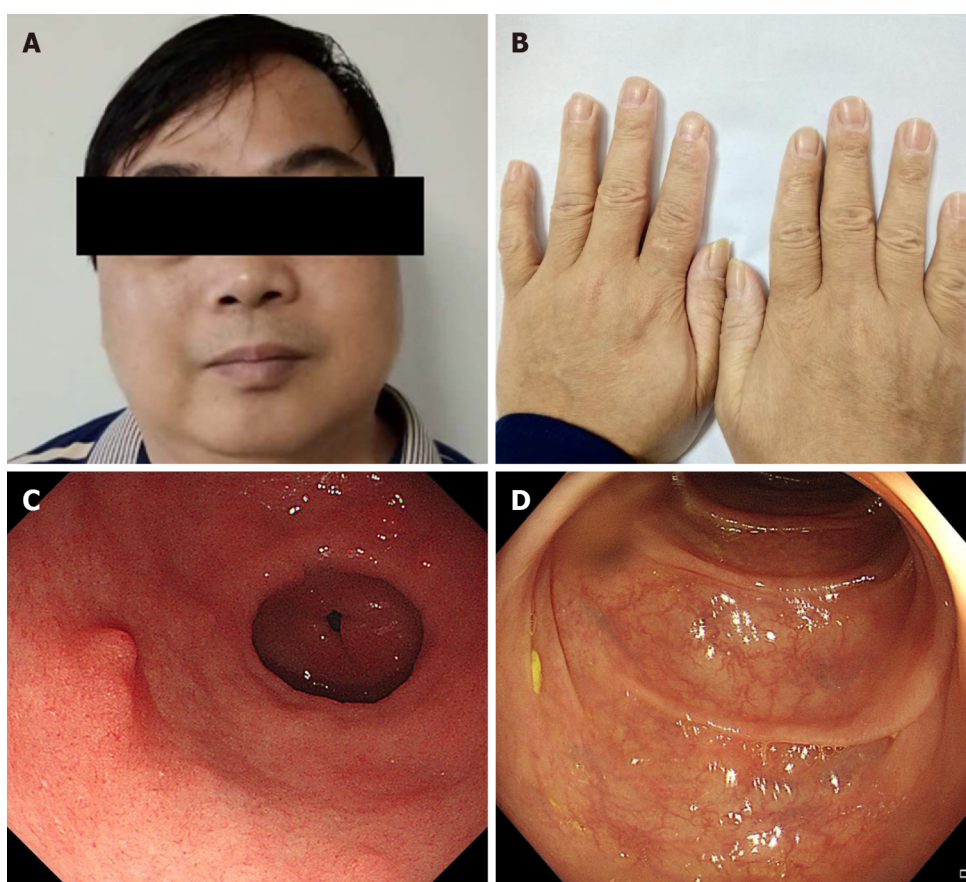


Figure 3 Examination after treatment. A: The patient showed great improvement in his skin pigmentation after 6-8 mo of steroid therapy; B: The patient showed great improvement in his nail dystrophy after 6-8 mo of steroid therapy; C and D: After 14 mo of treatment, gastroscopy revealed several polyps with a diameter of 3-4 mm in the gastric antrum (C), and colonoscopy revealed polyp regression (D).

Eight mo after the discontinuation of prednisone, the patient developed ectodermal manifestations again and was reviewed by gastroscopy, which suggested a relapse of CCS. We began to treat the patient again with the original regimen (*i.e.* a dose of 40 mg prednisone qd po with a decrease of 5 mg every 4 wk). Prednisone was reduced to 10 mg/d and maintained for 6 mo. In October 2020, we reviewed the patient by gastroscopy and colonoscopy, which indicated that the mucosal lesions had disappeared.

DISCUSSION

CCS is a rare disease, and there is no consensus on therapy at present. Treatment for CCS is largely based on anecdotal evidence and traditionally consists of nutritional support, histamine receptor antagonists, steroids, immunosuppression, or *Helicobacter pylori* eradication. A retrospective analysis has confirmed that steroid therapy is the mainstay of medical treatment and that 30-49 mg/d of orally administered prednisolone is optimal for active CCS, suggesting that the prednisolone dose should be slowly tapered only after endoscopic confirmation of the regression of polyposis[2]. The duration of therapy usually required is 6-12 mo. Once a sustained response is achieved, corticosteroids should be slowly tapered and eventually discontinued. Recurrences often respond to corticosteroid retreatment[8]. More than 35% of patients failed to achieve long-term clinical remission after corticosteroid administration, and relapse occurred during or after the cessation of glucocorticoid use. A proportion of patients were prescribed low-dose (5-10 mg/d) corticosteroids or immunosuppressants to counteract the tendency to relapse[5].

As immunological dysregulation is one of the important factors hypothesized to be present in CCS, the long-term use of immunoregulatory drugs or biologics may be useful for active or refractory disease[9]. Steroid-sparing therapies such as cyclosporine A and an antitumor necrosis factor- agent, a combination that has shown promise in a few cases, can be used in steroid-resistant cases to induce or maintain clinical remission. Other case reports described the beneficial response of immunosuppressive therapies including infliximab, sirolimus, tacrolimus, methicillin, and mycophenolate mofetil[2,10-14]. Azathioprine and mesalazine used with steroid maintenance therapy were reported to be associated with sustained clinical remission[3,15-17]. In a study by Mao *et al*[17], the patient was given a dose of 1.25 mg/kg/d azathioprine (previous reports had specified a dose of 2 mg/kg/d). The prednisone dose was tapered after 6 wk of therapy, and azathioprine was initiated. Corticosteroid side effects resolved when the prednisone was tapered, and CCS symptoms remained controlled on azathioprine without adverse effects; the total course of treatment consisted of 6 wk of prednisone and 26 wk of azathioprine. In a study by Schulte *et al*[3], discontinuation of steroid therapy was not possible, and mesalazine (1000 mg tid) was added to prednisolone (10.0 mg/d). The steroid dosage was further reduced over the course of 3 years; when all polyps had disappeared and the steroid therapy was finished, the dosage of mesalazine was reduced in a stepwise fashion. Four years later, the mesalazine was stopped, and more than 14.0 years after the initial diagnosis, the patient was still in complete remission without any treatment.

In conclusion, the mainstay of medical treatment for CCS is steroid therapy. Endoscopic remission and histopathologic remission are the therapeutic goals. A standard dose-adjustment protocol for prednisolone in CCS patients has not been established. Prednisone treatment after relapse in this case is still effective. Treatment should, therefore, be individualized for each patient according to their symptoms and recorded response to previous therapy. In episodically active clinical disease, the frequent use of steroids is necessary to prevent endoscopic relapse. Azathioprine, mesalazine, and other drugs merit consideration as CCS maintenance therapy. Surveillance endoscopy at intervals of 1 year or less is recommended to assess mucosal disease activity.

CONCLUSION

Steroid therapy is the mainstay of medical treatment for CCS. Endoscopic remission and histopathologic remission are the therapeutic goals. In the current case, prednisone treatment was still effective after relapse. Treatment should, therefore, be individualized for each patient according to his or her symptoms and recorded responses to previous therapy. Surveillance endoscopy at intervals of 1 year or less is recommended to assess mucosal disease activity.

REFERENCES

- 1 Slavik T, Montgomery EA. Cronkhite-Canada syndrome six decades on: the many faces of an enigmatic disease. *J Clin Pathol* 2014; 67: 891-897 [PMID: 25004941 DOI: 10.1136/jclinpath-2014-202488]
- 2 Watanabe C, Komoto S, Tomita K, Hokari R, Tanaka M, Hirata I, Hibi T, Kaunitz JD, Miura S.

- Endoscopic and clinical evaluation of treatment and prognosis of Cronkhite-Canada syndrome: a Japanese nationwide survey. *J Gastroenterol* 2016; **51**: 327-336 [PMID: [26216651](#) DOI: [10.1007/s00535-015-1107-7](#)]
- 3 **Schulte S**, Kütting F, Mertens J, Kaufmann T, Drebber U, Nierhoff D, Töx U, Steffen HM. Case report of patient with a Cronkhite-Canada syndrome: sustained remission after treatment with corticosteroids and mesalazine. *BMC Gastroenterol* 2019; **19**: 36 [PMID: [30813906](#) DOI: [10.1186/s12876-019-0944-x](#)]
 - 4 **Zong Y**, Zhao H, Yu L, Ji M, Wu Y, Zhang S. Case report-malignant transformation in Cronkhite-Canada syndrome polyp. *Medicine (Baltimore)* 2017; **96**: e6051 [PMID: [28178153](#) DOI: [10.1097/MD.00000000000006051](#)]
 - 5 **Liu S**, You Y, Ruan G, Zhou L, Chen D, Wu D, Yan X, Zhang S, Zhou W, Li J, Qian J. The Long-Term Clinical and Endoscopic Outcomes of Cronkhite-Canada Syndrome. *Clin Transl Gastroenterol* 2020; **11**: e00167 [PMID: [32352683](#) DOI: [10.14309/ctg.0000000000000167](#)]
 - 6 **Ward E**, Wolfsen HC, Ng C. Medical management of Cronkhite-Canada syndrome. *South Med J* 2002; **95**: 272-274 [PMID: [11846261](#) DOI: [10.1097/00007611-200202000-00025](#)]
 - 7 **Daniel ES**, Ludwig SL, Lewin KJ, Ruprecht RM, Rajacich GM, Schwabe AD. The Cronkhite-Canada Syndrome. An analysis of clinical and pathologic features and therapy in 55 patients. *Medicine (Baltimore)* 1982; **61**: 293-309 [PMID: [7109958](#)]
 - 8 **Ward EM**, Wolfsen HC. Pharmacological management of Cronkhite-Canada syndrome. *Expert Opin Pharmacother* 2003; **4**: 385-389 [PMID: [12614190](#) DOI: [10.1517/14656566.4.3.385](#)]
 - 9 **Bettington M**, Brown IS, Kumarasinghe MP, de Boer B, Bettington A, Rosty C. The challenging diagnosis of Cronkhite-Canada syndrome in the upper gastrointestinal tract: a series of 7 cases with clinical follow-up. *Am J Surg Pathol* 2014; **38**: 215-223 [PMID: [24418855](#) DOI: [10.1097/PAS.0000000000000098](#)]
 - 10 **Ohmiya N**, Nakamura M, Yamamura T, Yamada K, Nagura A, Yoshimura T, Hirooka Y, Matsumoto T, Hirata I, Goto H. Steroid-resistant Cronkhite-Canada syndrome successfully treated by cyclosporine and azathioprine. *J Clin Gastroenterol* 2014; **48**: 463-464 [PMID: [24172181](#) DOI: [10.1097/MCG.0000000000000009](#)]
 - 11 **Yamakawa K**, Yoshino T, Watanabe K, Kawano K, Kurita A, Matsuzaki N, Yuba Y, Yazumi S. Effectiveness of cyclosporine as a treatment for steroid-resistant Cronkhite-Canada syndrome; two case reports. *BMC Gastroenterol* 2016; **16**: 123 [PMID: [27716071](#) DOI: [10.1186/s12876-016-0541-1](#)]
 - 12 **Langevin C**, Chapdelaine H, Picard JM, Poitras P, Leduc R. Sirolimus in Refractory Cronkhite-Canada Syndrome and Focus on Standard Treatment. *J Investig Med High Impact Case Rep* 2018; **6**: 2324709618765893 [PMID: [29619395](#) DOI: [10.1177/2324709618765893](#)]
 - 13 **Taylor SA**, Kelly J, Loomes DE. Cronkhite-Canada Syndrome: Sustained Clinical Response with Anti-TNF Therapy. *Case Rep Med* 2018; **2018**: 9409732 [PMID: [30057620](#) DOI: [10.1155/2018/9409732](#)]
 - 14 **Liu Y**, Zhang L, Yang Y, Peng T. Cronkhite-Canada syndrome: report of a rare case and review of the literature. *J Int Med Res* 2020; **48**: 300060520922427 [PMID: [32459145](#) DOI: [10.1177/0300060520922427](#)]
 - 15 **Takakura M**, Adachi H, Tsuchihashi N, Miyazaki E, Yoshioka Y, Yoshida K. A case of Cronkhite-Canada syndrome markedly improved with mesalazine therapy. *Dig Endosc* 2004; **16**: 74-78 [DOI: [10.1111/j.1443-1661.2004.00306.x](#)]
 - 16 **Flannery CM**, Lunn JA. Cronkhite-Canada Syndrome: an unusual finding of gastro-intestinal adenomatous polyps in a syndrome characterized by hamartomatous polyps. *Gastroenterol Rep (Oxf)* 2015; **3**: 254-257 [PMID: [24982130](#) DOI: [10.1093/gastro/gou041](#)]
 - 17 **Mao EJ**, Hyder SM, DeNucci TD, Fine S. A Successful Steroid-Sparing Approach in Cronkhite-Canada Syndrome. *ACG Case Rep J* 2019; **6**: 1-4 [PMID: [31620498](#) DOI: [10.14309/crj.0000000000000055](#)]



Published by **Baishideng Publishing Group Inc**
7041 Koll Center Parkway, Suite 160, Pleasanton, CA 94566, USA

Telephone: +1-925-3991568

E-mail: bpgoffice@wjgnet.com

Help Desk: <https://www.f6publishing.com/helpdesk>

<https://www.wjgnet.com>

