

World Journal of *Clinical Cases*

World J Clin Cases 2021 May 26; 9(15): 3487-3795



Contents

Thrice Monthly Volume 9 Number 15 May 26, 2021

OPINION REVIEW

- 3487 COVID-19 combined with liver injury: Current challenges and management
Deng ML, Chen YJ, Yang ML, Liu YW, Chen H, Tang XQ, Yang XF

MINIREVIEWS

- 3498 Cholesterol gallstones: Focusing on the role of interstitial Cajal-like cells
Fu BB, Zhao JN, Wu SD, Fan Y
- 3506 Association of hidradenitis suppurativa with Crohn's disease
Zhang M, Chen QD, Xu HX, Xu YM, Chen HJ, Yang BL
- 3517 Surgical treatment of hepatocellular carcinoma in the era of COVID-19 pandemic: A comprehensive review of current recommendations
Fancellu A, Sanna V, Scognamiglio F, Feo CF, Vidili G, Nigri G, Porcu A

ORIGINAL ARTICLE

Retrospective Cohort Study

- 3531 Critical prognostic value of the log odds of negative lymph nodes/tumor size in rectal cancer patients
Xie JB, Pang YS, Li X, Wu XT
- 3546 Effectiveness of adjunctive corticosteroid therapy in patients with severe COVID-19: A retrospective cohort study
Xiong B, He LM, Qin YY, Du H, Zhan Z, Zhou YH, Chen YK, Zhang A

Retrospective Study

- 3559 Multifactor study of efficacy and recurrence in laparoscopic surgery for inguinal hernia
Chen WL, Deng QQ, Xu W, Luo M
- 3567 Ultrasound-guided, direct suprainguinal injection for fascia iliaca block for total hip arthroplasty: A retrospective study
Wang YL, Liu YQ, Ni H, Zhang XL, Ding L, Tong F, Chen HY, Zhang XH, Kong MJ
- 3576 Changes in endoscopic patterns before and during COVID-19 outbreak: Experience at a single tertiary center in Korean
Kim KH, Kim SB, Kim TN

Observational Study

- 3586 Cleansing efficacy and safety of bowel preparation protocol using sodium picosulfate/magnesium citrate considering subjective experiences: An observational study
Liu FX, Wang L, Yan WJ, Zou LC, Cao YA, Lin XC

- 3597** Clinically significant endoscopic findings in patients of dyspepsia with no warning symptoms: A cross-sectional study

Mao LQ, Wang SS, Zhou YL, Chen L, Yu LM, Li M, Lv B

META-ANALYSIS

- 3607** Effect of antifoaming agent on benign colorectal tumors in colonoscopy: A meta-analysis

Zhang H, Gong J, Ma LS, Jiang T, Zhang H

CASE REPORT

- 3623** Subchondral bone as a novel target for regenerative therapy of osteochondritis dissecans: A case report

Zhang SY, Xu HH, Xiao MM, Zhang JJ, Mao Q, He BJ, Tong PJ

- 3631** Progressive familial intrahepatic cholestasis — farnesoid X receptor deficiency due to *NR1H4* mutation: A case report

Czubkowski P, Thompson RJ, Jankowska I, Knisely AS, Finegold M, Parsons P, Cielecka-Kuszyk J, Strautnieks S, Pawłowska J, Bull LN

- 3637** Postoperative pain due to an occult spinal infection: A case report

Kerckhove MFV, Fiere V, Vieira TD, Bahroun S, Szadkowski M, d'Astorg H

- 3644** Combined cesarean delivery and repair of acute aortic dissection at 34 weeks of pregnancy during COVID-19 outbreak: A case report

Liu LW, Luo L, Li L, Li Y, Jin M, Zhu JM

- 3649** Brucellosis of unknown origin with haemophagocytic syndrome: A case report

Tian LH, Dong ZG, Chen XY, Huang LJ, Xiao PP

- 3655** Recalcitrant paradoxical pustular psoriasis induced by infliximab: Two case reports

Xia P, Li YH, Liu Z, Zhang X, Jiang Q, Zhou XY, Su W

- 3662** Needle tract seeding of papillary thyroid carcinoma after fine-needle capillary biopsy: A case report

Shi LH, Zhou L, Lei YJ, Xia L, Xie L

- 3668** Metachronous pulmonary and pancreatic metastases arising from sigmoid colon cancer: A case report

Yang J, Tang YC, Yin N, Liu W, Cao ZF, Li X, Zou X, Zhang ZX, Zhou J

- 3675** Infiltrating ductal breast carcinoma with monoclonal gammopathy of undetermined significance: A case report

Ma Y, Cui S, Yin YJ

- 3680** Roxadustat as treatment for a blood transfusion-dependent maintenance hemodialysis patient: A case report and review of literature

Fei M, Wen XQ, Yu ZL, Kang T, Wu WH, Ou ST

- 3689** Small bowel ulcer bleeding due to suspected clopidogrel use in a patient with clopidogrel resistance: A case report

Lee SH, Ryu DR, Lee SJ, Park SC, Cho BR, Lee SK, Choi SJ, Cho HS

- 3696** Recurrent abdominal pain due to small bowel volvulus after transabdominal preperitoneal hernioplasty: A case report and review of literature
Man Y, Li BS, Zhang X, Huang H, Wang YL
- 3704** Malignant giant cell tumor in the left upper arm soft tissue of an adolescent: A case report
Huang WP, Zhu LN, Li R, Li LM, Gao JB
- 3711** Anesthetic management of bilateral pheochromocytoma resection in Von Hippel-Lindau syndrome: A case report
Wang L, Feng Y, Jiang LY
- 3716** Sarcomatoid carcinoma of the pancreas — a rare tumor with an uncommon presentation and course: A case report and review of literature
Toledo PF, Berger Z, Carreño L, Cardenas G, Castillo J, Orellana O
- 3726** Fulminant amebic colitis in a patient with concomitant cytomegalovirus infection after systemic steroid therapy: A case report
Shijubou N, Sumi T, Kamada K, Sawai T, Yamada Y, Ikeda T, Nakata H, Mori Y, Chiba H
- 3733** Maisonneuve injury with no fibula fracture: A case report
Liu GP, Li JG, Gong X, Li JM
- 3741** Alopecia treatment using minimally manipulated human umbilical cord-derived mesenchymal stem cells: Three case reports and review of literature
Ahn H, Lee SY, Jung WJ, Lee KH
- 3752** Pheochromocytoma in a 49-year-old woman presenting with acute myocardial infarction: A case report
Wu HY, Cao YW, Gao TJ, Fu JL, Liang L
- 3758** Lymphangiomas associated with protein losing enteropathy: A case report
Ding XL, Yin XY, Yu YN, Chen YQ, Fu WW, Liu H
- 3765** *De novo* multiple primary carcinomas in a patient after liver transplantation: A case report
Rao W, Liu FG, Jiang YP, Xie M
- 3773** Contralateral hemopneumothorax after penetrating thoracic trauma: A case report
İşcan M
- 3779** Bilateral posterior scleritis presenting as acute primary angle closure: A case report
Wen C, Duan H
- 3787** Bilateral cerebral infarction in diabetic ketoacidosis and bilateral internal carotid artery occlusion: A case report and review of literature
Chen YC, Tsai SJ

ABOUT COVER

Editorial Board Member of *World Journal of Clinical Cases*, Wei Wang, MD, PhD, Associate Professor, Key Laboratory on Technology for Parasitic Disease Prevention and Control, Jiangsu Institute of Parasitic Diseases, Wuxi 214064, Jiangsu Province, China. wangwei@jipd.com

AIMS AND SCOPE

The primary aim of *World Journal of Clinical Cases* (WJCC, *World J Clin Cases*) is to provide scholars and readers from various fields of clinical medicine with a platform to publish high-quality clinical research articles and communicate their research findings online.

WJCC mainly publishes articles reporting research results and findings obtained in the field of clinical medicine and covering a wide range of topics, including case control studies, retrospective cohort studies, retrospective studies, clinical trials studies, observational studies, prospective studies, randomized controlled trials, randomized clinical trials, systematic reviews, meta-analysis, and case reports.

INDEXING/ABSTRACTING

The WJCC is now indexed in Science Citation Index Expanded (also known as SciSearch®), Journal Citation Reports/Science Edition, Scopus, PubMed, and PubMed Central. The 2020 Edition of Journal Citation Reports® cites the 2019 impact factor (IF) for WJCC as 1.013; IF without journal self cites: 0.991; Ranking: 120 among 165 journals in medicine, general and internal; and Quartile category: Q3. The WJCC's CiteScore for 2019 is 0.3 and Scopus CiteScore rank 2019: General Medicine is 394/529.

RESPONSIBLE EDITORS FOR THIS ISSUE

Production Editor: Ji-Hong Lin; Production Department Director: Xiang Li; Editorial Office Director: Jin-Lai Wang.

NAME OF JOURNAL

World Journal of Clinical Cases

ISSN

ISSN 2307-8960 (online)

LAUNCH DATE

April 16, 2013

FREQUENCY

Thrice Monthly

EDITORS-IN-CHIEF

Dennis A Bloomfield, Sandro Vento, Bao-Gan Peng

EDITORIAL BOARD MEMBERS

<https://www.wjgnet.com/2307-8960/editorialboard.htm>

PUBLICATION DATE

May 26, 2021

COPYRIGHT

© 2021 Baishideng Publishing Group Inc

INSTRUCTIONS TO AUTHORS

<https://www.wjgnet.com/bpg/gerinfo/204>

GUIDELINES FOR ETHICS DOCUMENTS

<https://www.wjgnet.com/bpg/GerInfo/287>

GUIDELINES FOR NON-NATIVE SPEAKERS OF ENGLISH

<https://www.wjgnet.com/bpg/gerinfo/240>

PUBLICATION ETHICS

<https://www.wjgnet.com/bpg/GerInfo/288>

PUBLICATION MISCONDUCT

<https://www.wjgnet.com/bpg/gerinfo/208>

ARTICLE PROCESSING CHARGE

<https://www.wjgnet.com/bpg/gerinfo/242>

STEPS FOR SUBMITTING MANUSCRIPTS

<https://www.wjgnet.com/bpg/GerInfo/239>

ONLINE SUBMISSION

<https://www.f6publishing.com>



Anesthetic management of bilateral pheochromocytoma resection in Von Hippel-Lindau syndrome: A case report

Lu Wang, Yi Feng, Lu-Yang Jiang

ORCID number: Lu Wang 0000-0002-5025-2818; Yi Feng 0000-0002-3952-1351; Lu-Yang Jiang 0000-0002-4341-4444.

Author contributions: Wang L reviewed the records and contributed to manuscript drafting; Feng Y and Jiang LY, the patient's anesthesiologists, reviewed the literature and contributed to manuscript revision; all authors issued final approval for the version to be submitted.

Informed consent statement:

Informed written consent was obtained from the patient for publication of this report and any accompanying images.

Conflict-of-interest statement: The authors declare that they have no conflict of interest.

CARE Checklist (2016) statement:

The authors have read the CARE Checklist (2016), and the manuscript was prepared and revised according to the CARE Checklist (2016).

Open-Access: This article is an open-access article that was selected by an in-house editor and fully peer-reviewed by external reviewers. It is distributed in accordance with the Creative Commons Attribution NonCommercial (CC BY-NC 4.0)

Lu Wang, Yi Feng, Lu-Yang Jiang, Department of Anesthesiology, Peking University People's Hospital, Beijing 100044, China

Corresponding author: Lu-Yang Jiang, MD, Associate Professor, Department of Anesthesiology, Peking University People's Hospital, No. 11 Xizhimen South Street, Xicheng District, Beijing 100044, China. jiangluyang@pkuph.edu.cn

Abstract

BACKGROUND

Von Hippel-Lindau disease (also known as VHL syndrome), is an autosomal dominant inherited disease. We describe a sporadic case of VHL syndrome where bilateral pheochromocytomas were unexpectedly identified. The patient underwent selective laparoscopic resections of the pheochromocytomas, and the anesthetic management during surgery was complex and challenging.

CASE SUMMARY

A 22-year-old man presented to our hospital to seek medical advice for infertility without any other complaints. The results of computed tomography and catecholamine levels in blood and urine demonstrated adrenal gland masses which were diagnosed as pheochromocytomas. Further examination confirmed that the patient also had VHL syndrome. After thorough preparation, the patient underwent selective laparoscopic resection of the pheochromocytomas and was discharged 10 d after surgery. We describe the process of perioperative anesthesia management in this patient undergoing pheochromocytoma resection.

CONCLUSION

This case summaries specific clinical traits and considerations in perioperative anesthesia management for VHL syndrome patients undergoing bilateral pheochromocytoma resection.

Key Words: Von Hippel-Lindau syndrome; Pheochromocytoma; Surgery; Anesthesia; Case report

©The Author(s) 2021. Published by Baishideng Publishing Group Inc. All rights reserved.

license, which permits others to distribute, remix, adapt, build upon this work non-commercially, and license their derivative works on different terms, provided the original work is properly cited and the use is non-commercial. See: <http://creativecommons.org/licenses/by-nc/4.0/>

Manuscript source: Unsolicited manuscript

Specialty type: Anesthesiology

Country/Territory of origin: China

Peer-review report's scientific quality classification

Grade A (Excellent): 0
Grade B (Very good): B
Grade C (Good): 0
Grade D (Fair): 0
Grade E (Poor): 0

Received: December 27, 2020

Peer-review started: December 28, 2020

First decision: January 24, 2021

Revised: February 1, 2021

Accepted: March 18, 2021

Article in press: March 18, 2021

Published online: May 26, 2021

P-Reviewer: Zavras N

S-Editor: Liu M

L-Editor: Webster JR

P-Editor: Yuan YY



Core Tip: Von Hippel-Lindau (VHL) syndrome is a rare autosomal dominant inherited disease, and anesthesia for patients with VHL syndrome undergoing bilateral pheochromocytoma resection involves some unique considerations. This case highlights the process of anesthesia, including preparation, monitoring and perioperative management.

Citation: Wang L, Feng Y, Jiang LY. Anesthetic management of bilateral pheochromocytoma resection in Von Hippel-Lindau syndrome: A case report. *World J Clin Cases* 2021; 9(15): 3711-3715

URL: <https://www.wjgnet.com/2307-8960/full/v9/i15/3711.htm>

DOI: <https://dx.doi.org/10.12998/wjcc.v9.i15.3711>

INTRODUCTION

Von Hippel-Lindau disease (also known as VHL syndrome), is an autosomal dominant inherited disease characterized by carcinomas in multiple organs with an incidence of approximately 1/36000. Its development is related to mutations in the VHL gene (a tumor suppressor gene, 3p25-26)[1]. Accompanying pheochromocytoma can be found in type 2 VHL but not in type 1, which is further classified into three subtypes (2A, 2B and 2C) depending on the risk of renal cell carcinoma or pheochromocytoma only[2]. It is estimated that pheochromocytoma is seen in 10%-20% of patients with VHL syndrome[3]. Pheochromocytoma is a benign tumor; however, when it is resected, extreme changes in blood pressure can occur which require close monitoring, especially in VHL patients with bilateral pheochromocytomas.

CASE PRESENTATION

Chief complaints

A 22-year-old male complained of infertility without any other discomfort.

History of present illness

The couple had been trying to conceive for 2 years.

History of past illness

The patient had an unremarkable medical history.

Personal and family history

Personal and family history showed no specific illnesses.

Physical examination

The patients's physical examination showed no abnormalities. His blood pressure (BP) and heart rate (HR) were 17.3/9.3 mmHg and 80 bpm, respectively.

Laboratory examinations

The levels of catecholamines in blood (norepinephrine 283.1 pg/mL, epinephrine 47.5 pg/mL, dopamine /) and urine (norepinephrine 93 µg/24 h, epinephrine 3 µg/24 h, dopamine 137 µg/24 h) confirmed that the adrenal gland masses were pheochromocytomas.

Imaging examinations

Computed tomography (CT) results indicated the association of multiple lesions: (1) Bilateral adrenal gland mass (Figure 1): The size of the left mass was 4.5 cm × 4.3 cm × 4.5 cm, and the right mass was 2.6 cm × 2.2 m × 3 cm; (2) Cysts in the upper region and a low-density occupying lesion on the left kidney; (3) Cystadenomas of the pancreas; and (4) Space occupying lesion with supply blood on the epididymis.

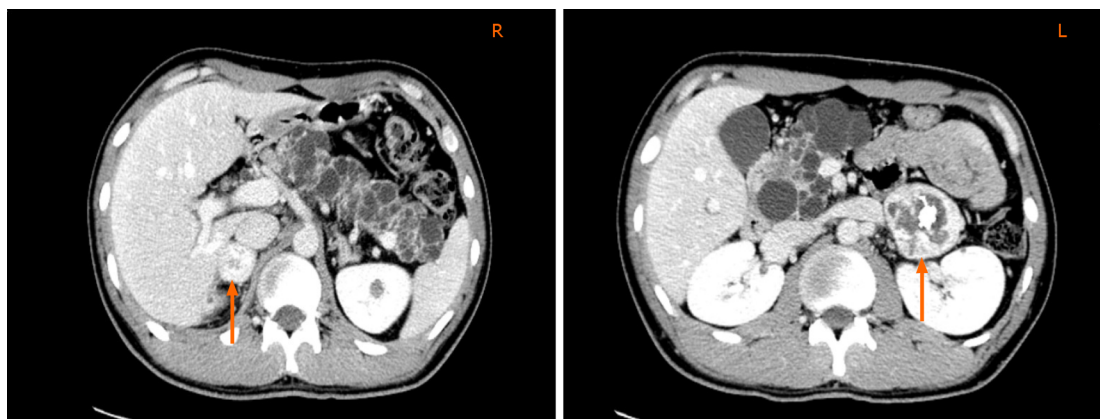


Figure 1 Bilateral adrenal gland masses. Bilateral adrenal gland masses on computed tomography are shown by the blue arrows, “R” and “L” represent the right and left side of the patient.

Further diagnostic work-up

The patient was advised to undergo extensive imaging examinations. Multiple cystic nodules were detected in the thyroid by ultrasound. A single hemangioblastoma in the brainstem was characterized by magnetic resonance imaging, the diameter of which was approximately 5.6 mm along the medulla oblongata, which correlated with the clinical manifestations of Type 2B genotype-phenotype classification in families with VHL syndrome.

FINAL DIAGNOSIS

The patient was diagnosed with VHL syndrome.

TREATMENT

It was decided that bilateral pheochromocytoma resections would be a reasonable treatment option. The pre-operative levels of alanine aminotransferase (ALT) and aspartate aminotransferase (AST) (431 U/L and 189 U/L, respectively) were significantly higher than normal due to massive replication of Hepatitis B Virus (HBV), which suggested poor liver function and did not meet the standards for surgery. Thus, the patient was transferred to the liver disease clinic. Two months later, he was transferred back to the urology ward for surgery following a reduction in ALT and AST (53 U/L and 27 U/L, respectively).

The patient was treated with terazosin 4 mg orally, together with hydroxyethyl starch 500 mL and crystal fluid 1000 mL intravenous infusion each day in preparation for the operation. A week later, he underwent right laparoscopic adrenalectomy. On arrival at the operating room the patient was monitored with electrocardiography, oxygen saturation (SpO₂) by pulse oximetry, BP and a radial artery line for invasive arterial blood pressure (IBP). The initial IBP was 17.3/10.7 kPa, HR was 90 bpm and SpO₂ was 98%. Induction of anesthesia began after preparation of the peripheral vein, with midazolam 2 mg, propofol 160 mg, fentanyl 0.25 mg, cisatracurium 12 mg, and esmolol 80 mg intravenous, a tracheal cannula and right internal jugular vein catheter were placed sequentially. The central venous pressure was 0.5 kPa in the left lateral position before pneumoperitoneum was performed. Anesthesia was maintained by 1% sevoflurane, and intravenous infusion of propofol and remifentanyl. Initial arterial blood gas analysis before surgery was normal. Following preparation and monitoring, we proceeded with the operation. During this process, when the surgeons peeled the tumor and managed its blood supply, as predicted the IBP fluctuated, with a peak of 25.7/12.3 kPa, and then dropped to 12.3/6.7 kPa as ligation of the veins started to drain the tumor. The BP was maintained by dopamine briefly for 20 min. Blood glucose varied from 111 mg/dL to 113 mg/dL during surgery, and fluid infusion of approximately 3600 mL was administered with an equal ratio of crystal and colloid. Hydrocortisone 100 mg was given to prevent an adrenalectomy-related cortisol crisis. After 3 h of surgery, the patient was transferred to the intensive care unit (ICU) and

his BP was 17.2/10.1 kPa and HR was 93 bpm. Pathological diagnosis of the mass was a pheochromocytoma 3.5 cm × 2.5 cm × 2.0 cm in size.

His BP was maintained at 14.7/8.0 kPa after the first operation, routine blood cortisol test was 0.71 µg/dL at 8 AM, 0.65 µg/dL at 4 PM, and 0.47 µg/dL at midnight, Hydrocortisone was suggested at 100 mg during induction of anesthesia and 50 mg at the end of surgery to prevent a cortisol crisis during the second operation. Two weeks later, laparoscopic adrenalectomy on the left side was performed, using the same preoperative preparation and monitoring methods. IBP did not increase but dropped dramatically from 16.0/10.0 kPa to 10.4/6.5 kPa, while HR rose markedly from 80 to 103 bpm during left adrenalectomy. His BP was maintained with vasopressors (dopamine 6 µg/kg/min, norepinephrine 0.06 µg/kg/min) until he was transferred to the ICU. Postoperative laboratory tests showed that blood norepinephrine concentration dropped from 283.1 pg/mL to 124.9 pg/mL, urine 24-h norepinephrine concentration dropped from 93 µg to 24 µg, and dopamine decreased from 137 µg to 77 µg. Pathological diagnosis of the mass confirmed a pheochromocytoma 6 cm × 4 cm × 3.5 cm in size.

OUTCOME AND FOLLOW-UP

The patient was discharged 10 d after surgery with BP at 16.0/10.7 kPa and hydrocortisone 50 mg as replacement therapy. Five years later, he returned with a growing epididymis mass. Pulmonary shadows on his X-ray findings accompanied by the history of hydrocortisone use after surgery suggested tuberculosis, which could not be excluded by CT. As a result, he was advised to undergo systematic treatment for tuberculosis and periodic review to evaluate the progression of VHL syndrome.

DISCUSSION

This patient initially only complained of infertility, but multiple tumors were found on routine examination. On reviewing his family history, it was discovered that his grandfather died from renal cell carcinoma in his 50's, but his parents were alive and had not undergone medical examinations. Central nervous system and visceral lesions were detected including medullary hemangioblastoma, bilateral pheochromocytomas, left renal cyst, cystadenomas of the pancreas, space occupying lesion in the left kidney and in the epididymis, which proved the diagnosis of VHL syndrome.

For patients with VHL syndrome, anesthetic management during pheochromocytoma resection has its own specific characteristics. Firstly, compared with pheochromocytoma patients, those with VHL syndrome are likely to develop pheochromocytomas early, usually between 18 and 30 years old. Pheochromocytomas can be bilateral or multicentric (50%), have a rich supply blood, and secrete high levels of norepinephrine[4], which is very challenging for anesthesiologists. In our patient, the tumors were resected separately in stages, the smaller one was removed first. Before surgery, full drug and fluid preparations were carried out. Thorough monitoring of all types of vasoactive drugs during surgery is important. After resection of one tumor, drug and fluid preparations before the second operation are essential even if BP is normal. We should be aware that hypotension caused by α-receptor blockers can develop due to the low level of corticosteroid after resection of the first pheochromocytoma and prompt supplemental therapy for the next operation is necessary. Caution is required due to hemodynamic fluctuations during the second operation as a result of the impact of changes in catecholamine concentrations after the first operation. Patients with larger and bilateral pheochromocytomas are more likely to develop complications; thus, these patients should be closely monitored in the ICU.

There is a potential risk of medulla oblongata hemangioblastoma rupture in patients with VHL syndrome. Dramatic changes in BP during the operation can change intracranial and intraocular pressure with the risk of vitreous hemorrhage, retinal detachment and cerebral hernia; thus, early detection of intracranial hemorrhage is important[5]. The maintenance of blood and intracranial pressure is critical and requires careful consideration[6].

Thirdly, as morbidity and mortality of patients with VHL syndrome are linked to the progression of hemangioblastoma or renal cell carcinoma[7], if the patient's liver function has been damaged due to HBV, the selection of drugs which do not damage renal and liver function is essential. For those with a family history of VHL syndrome, periodic surveillance to detect tumors early is essential[8]. Research has shown that

pheochromocytoma can act as an indication of VHL syndrome, and bilateral pheochromocytoma mainly occurs due to genetic disease[9,10].

CONCLUSION

In summary, VHL syndrome is an autosomal dominant inherited disease, and due to its specific clinical traits perioperative management is more complex. We present a patient accidentally diagnosed with VHL syndrome and the anesthesia management for bilateral pheochromocytoma resection is discussed. Learning about specific diseases and optimizing each treatment step is crucial for clinicians.

ACKNOWLEDGEMENTS

We would like to thank the patient for allowing us to share details of his diagnosis and treatment.

REFERENCES

- 1 **Chou A**, Toon C, Pickett J, Gill AJ. von Hippel-Lindau syndrome. *Front Horm Res* 2013; **41**: 30-49 [PMID: 23652669 DOI: 10.1159/000345668]
- 2 **Shanbhogue KP**, Hoch M, Fatterpaker G, Chandarana H. von Hippel-Lindau Disease: Review of Genetics and Imaging. *Radiol Clin North Am* 2016; **54**: 409-422 [PMID: 27153780 DOI: 10.1016/j.rcl.2015.12.004]
- 3 **Lonser RR**, Glenn GM, Walther M, Chew EY, Libutti SK, Linehan WM, Oldfield EH. von Hippel-Lindau disease. *Lancet* 2003; **361**: 2059-2067 [PMID: 12814730 DOI: 10.1016/S0140-6736(03)13643-4]
- 4 **Lefebvre M**, Foulkes WD. Pheochromocytoma and paraganglioma syndromes: genetics and management update. *Curr Oncol* 2014; **21**: e8-e17 [PMID: 24523625 DOI: 10.3747/co.21.1579]
- 5 **Ercan M**, Kahraman S, Başgöl E, Aypar U. Anaesthetic management of a patient with von Hippel-Lindau disease: a combination of bilateral pheochromocytoma and spinal cord haemangioblastoma. *Eur J Anaesthesiol* 1996; **13**: 81-83 [PMID: 8829941 DOI: 10.1097/00003643-199601000-00014]
- 6 **Mugawar M**, Rajender Y, Purohit AK, Sastry RA, Sundaram C, Rammurti S. Anesthetic management of von Hippel-Lindau Syndrome for excision of cerebellar hemangioblastoma and pheochromocytoma surgery. *Anesth Analg* 1998; **86**: 673-674 [PMID: 9495437 DOI: 10.1097/0000539-199803000-00045]
- 7 **Pilié PG**, Jonasch E, McCutcheon IE. Key considerations in the treatment of von Hippel-Lindau disease. *Future Oncol* 2016; **12**: 1755-1758 [PMID: 27020706 DOI: 10.2217/fon-2016-0028]
- 8 **Rasmussen A**, Alonso E, Ochoa A, De Biase I, Familiar I, Yescas P, Sosa AL, Rodríguez Y, Chávez M, López-López M, Bidichandani SI. Uptake of genetic testing and long-term tumor surveillance in von Hippel-Lindau disease. *BMC Med Genet* 2010; **11**: 4 [PMID: 20064270 DOI: 10.1186/1471-2350-11-4]
- 9 **Neumann HP**, Berger DP, Sigmund G, Blum U, Schmidt D, Parmer RJ, Volk B, Kirste G. Pheochromocytomas, multiple endocrine neoplasia type 2, and von Hippel-Lindau disease. *N Engl J Med* 1993; **329**: 1531-1538 [PMID: 8105382 DOI: 10.1056/NEJM199311183292103]
- 10 **Kittah NE**, Gruber LM, Bancos I, Hamidi O, Tamhane S, Iñiguez-Ariza N, Babovic-Vuksanovic D, Thompson GB, Lteif A, Young WF, Erickson D. Bilateral pheochromocytoma: Clinical characteristics, treatment and longitudinal follow-up. *Clin Endocrinol (Oxf)* 2020; **93**: 288-295 [PMID: 32410303 DOI: 10.1111/cen.14222]



Published by **Baishideng Publishing Group Inc**
7041 Koll Center Parkway, Suite 160, Pleasanton, CA 94566, USA

Telephone: +1-925-3991568

E-mail: bpgoffice@wjgnet.com

Help Desk: <https://www.f6publishing.com/helpdesk>

<https://www.wjgnet.com>

