

# World Journal of *Clinical Cases*

*World J Clin Cases* 2021 June 6; 9(16): 3796-4115



## Contents

Thrice Monthly Volume 9 Number 16 June 6, 2021

## REVIEW

- 3796 COVID-19 and the digestive system: A comprehensive review  
*Wang MK, Yue HY, Cai J, Zhai YJ, Peng JH, Hui JF, Hou DY, Li WP, Yang JS*

## MINIREVIEWS

- 3814 COVID-19 impact on the liver  
*Baroiu L, Dumitru C, Iancu A, Leşe AC, Drăgănescu M, Baroiu N, Anghel L*
- 3826 Xenogeneic stem cell transplantation: Research progress and clinical prospects  
*Jiang LL, Li H, Liu L*

## ORIGINAL ARTICLE

## Case Control Study

- 3838 Histopathological classification and follow-up analysis of chronic atrophic gastritis  
*Wang YK, Shen L, Yun T, Yang BF, Zhu CY, Wang SN*

## Retrospective Study

- 3848 Effectiveness of sharp recanalization of superior vena cava-right atrium junction occlusion  
*Wu XW, Zhao XY, Li X, Li JX, Liu ZY, Huang Z, Zhang L, Sima CY, Huang Y, Chen L, Zhou S*
- 3858 Management and outcomes of surgical patients with intestinal Behçet's disease and Crohn's disease in southwest China  
*Zeng L, Meng WJ, Wen ZH, Chen YL, Wang YF, Tang CW*
- 3869 Clinical and radiological outcomes of dynamic cervical implant arthroplasty: A 5-year follow-up  
*Zou L, Rong X, Liu XJ, Liu H*

## Observational Study

- 3880 Differential analysis revealing APOC1 to be a diagnostic and prognostic marker for liver metastases of colorectal cancer  
*Shen HY, Wei FZ, Liu Q*

## Randomized Clinical Trial

- 3895 Comparison of white-light endoscopy, optical-enhanced and acetic-acid magnifying endoscopy for detecting gastric intestinal metaplasia: A randomized trial  
*Song YH, Xu LD, Xing MX, Li KK, Xiao XG, Zhang Y, Li L, Xiao YJ, Qu YL, Wu HL*

## CASE REPORT

- 3908** Snapping wrist due to bony prominence and tenosynovitis of the first extensor compartment: A case report  
*Hu CJ, Chow PC, Tzeng IS*
- 3914** Massive retroperitoneal hematoma as an acute complication of retrograde intrarenal surgery: A case report  
*Choi T, Choi J, Min GE, Lee DG*
- 3919** Internal fixation and unicompartmental knee arthroplasty for an elderly patient with patellar fracture and anteromedial osteoarthritis: A case report  
*Nan SK, Li HF, Zhang D, Lin JN, Hou LS*
- 3927** Haemangiomas in the urinary bladder: Two case reports  
*Zhao GC, Ke CX*
- 3936** Endoscopic diagnosis and treatment of an appendiceal mucocele: A case report  
*Wang TT, He JJ, Zhou PH, Chen WW, Chen CW, Liu J*
- 3943** Diagnosis and spontaneous healing of asymptomatic renal allograft extra-renal pseudo-aneurysm: A case report  
*Xu RF, He EH, Yi ZX, Li L, Lin J, Qian LX*
- 3951** Rehabilitation and pharmacotherapy of neuromyelitis optica spectrum disorder: A case report  
*Wang XJ, Xia P, Yang T, Cheng K, Chen AL, Li XP*
- 3960** Undifferentiated intimal sarcoma of the pulmonary artery: A case report  
*Li X, Hong L, Huo XY*
- 3966** Chest pain in a heart transplant recipient: A case report  
*Chen YJ, Tsai CS, Huang TW*
- 3971** Successful management of therapy-refractory pseudoachalasia after Ivor Lewis esophagectomy by bypassing colonic pull-up: A case report  
*Flemming S, Lock JF, Hankir M, Reimer S, Petritsch B, Germer CT, Seyfried F*
- 3979** Old unreduced obturator dislocation of the hip: A case report  
*Li WZ, Wang JJ, Ni JD, Song DY, Ding ML, Huang J, He GX*
- 3988** Laterally spreading tumor-like primary rectal mucosa-associated lymphoid tissue lymphoma: A case report  
*Wei YL, Min CC, Ren LL, Xu S, Chen YQ, Zhang Q, Zhao WJ, Zhang CP, Yin XY*
- 3996** Coronary artery aneurysm combined with myocardial bridge: A case report  
*Ye Z, Dong XF, Yan YM, Luo YK*
- 4001** Thoracoscopic diagnosis of traumatic pericardial rupture with cardiac hernia: A case report  
*Wu YY, He ZL, Lu ZY*

- 4007** Delayed diagnosis and comprehensive treatment of cutaneous tuberculosis: A case report  
*Gao LJ, Huang ZH, Jin QY, Zhang GY, Gao MX, Qian JY, Zhu SX, Yu Y*
- 4016** Rapidly progressing primary pulmonary lymphoma masquerading as lung infectious disease: A case report and review of the literature  
*Jiang JH, Zhang CL, Wu QL, Liu YH, Wang XQ, Wang XL, Fang BM*
- 4024** Asymptomatic carbon dioxide embolism during transoral vestibular thyroidectomy: A case report  
*Tang JX, Wang L, Nian WQ, Tang WY, Xiao JY, Tang XX, Liu HL*
- 4032** Transient immune hepatitis as post-coronavirus disease complication: A case report  
*Drăgănescu AC, Săndulescu O, Bilașco A, Kouris C, Streinu-Cercel A, Luminos M, Streinu-Cercel A*
- 4040** Acute inferior myocardial infarction in a young man with testicular seminoma: A case report  
*Scafa-Udriste A, Popa-Fotea NM, Bataila V, Calmac L, Dorobantu M*
- 4046** Asymptomatic traumatic rupture of an intracranial dermoid cyst: A case report  
*Zhang MH, Feng Q, Zhu HL, Lu H, Ding ZX, Feng B*
- 4052** Parotid mammary analogue secretory carcinoma: A case report and review of literature  
*Min FH, Li J, Tao BQ, Liu HM, Yang ZJ, Chang L, Li YY, Liu YK, Qin YW, Liu WW*
- 4062** Liver injury associated with the use of selective androgen receptor modulators and post-cycle therapy: Two case reports and literature review  
*Koller T, Vrbova P, Meciarova I, Molcan P, Smitka M, Adamcova Selcanova S, Skladany L*
- 4072** Spinal epidural abscess due to coinfection of bacteria and tuberculosis: A case report  
*Kim C, Lee S, Kim J*
- 4081** Rare complication of inflammatory bowel disease-like colitis from glycogen storage disease type 1b and its surgical management: A case report  
*Lui FCW, Lo OSH*
- 4090** Thymosin as a possible therapeutic drug for COVID-19: A case report  
*Zheng QN, Xu MY, Gan FM, Ye SS, Zhao H*
- 4095** Arrhythmogenic right ventricular cardiomyopathy characterized by recurrent syncope during exercise: A case report  
*Wu HY, Cao YW, Gao TJ, Fu JL, Liang L*
- 4104** Delayed pseudoaneurysm formation of the carotid artery following the oral cavity injury in a child: A case report  
*Chung BH, Lee MR, Yang JD, Yu HC, Hong YT, Hwang HP*
- 4110** Atezolizumab-induced anaphylactic shock in a patient with hepatocellular carcinoma undergoing immunotherapy: A case report  
*Bian LF, Zheng C, Shi XL*

**ABOUT COVER**

Editorial Board Member of *World Journal of Clinical Cases*, Gwo-Ping Jong, FCCP, MD, MHSc, PhD, Associate Professor, Department of Public Health, Chung Shan Medical University, Taichung 40201, Taiwan. cgp8009@yahoo.com.tw

**AIMS AND SCOPE**

The primary aim of *World Journal of Clinical Cases* (WJCC, *World J Clin Cases*) is to provide scholars and readers from various fields of clinical medicine with a platform to publish high-quality clinical research articles and communicate their research findings online.

WJCC mainly publishes articles reporting research results and findings obtained in the field of clinical medicine and covering a wide range of topics, including case control studies, retrospective cohort studies, retrospective studies, clinical trials studies, observational studies, prospective studies, randomized controlled trials, randomized clinical trials, systematic reviews, meta-analysis, and case reports.

**INDEXING/ABSTRACTING**

The WJCC is now indexed in Science Citation Index Expanded (also known as SciSearch®), Journal Citation Reports/Science Edition, Scopus, PubMed, and PubMed Central. The 2020 Edition of Journal Citation Reports® cites the 2019 impact factor (IF) for WJCC as 1.013; IF without journal self cites: 0.991; Ranking: 120 among 165 journals in medicine, general and internal; and Quartile category: Q3. The WJCC's CiteScore for 2019 is 0.3 and Scopus CiteScore rank 2019: General Medicine is 394/529.

**RESPONSIBLE EDITORS FOR THIS ISSUE**

Production Editor: Yan-Xia Xing, Production Department Director: Yun-Xiaoqian Wu, Editorial Office Director: Jin-Lai Wang.

**NAME OF JOURNAL**

*World Journal of Clinical Cases*

**ISSN**

ISSN 2307-8960 (online)

**LAUNCH DATE**

April 16, 2013

**FREQUENCY**

Thrice Monthly

**EDITORS-IN-CHIEF**

Dennis A Bloomfield, Sandro Vento, Bao-Gan Peng

**EDITORIAL BOARD MEMBERS**

<https://www.wjgnet.com/2307-8960/editorialboard.htm>

**PUBLICATION DATE**

June 6, 2021

**COPYRIGHT**

© 2021 Baishideng Publishing Group Inc

**INSTRUCTIONS TO AUTHORS**

<https://www.wjgnet.com/bpg/gerinfo/204>

**GUIDELINES FOR ETHICS DOCUMENTS**

<https://www.wjgnet.com/bpg/GerInfo/287>

**GUIDELINES FOR NON-NATIVE SPEAKERS OF ENGLISH**

<https://www.wjgnet.com/bpg/gerinfo/240>

**PUBLICATION ETHICS**

<https://www.wjgnet.com/bpg/GerInfo/288>

**PUBLICATION MISCONDUCT**

<https://www.wjgnet.com/bpg/gerinfo/208>

**ARTICLE PROCESSING CHARGE**

<https://www.wjgnet.com/bpg/gerinfo/242>

**STEPS FOR SUBMITTING MANUSCRIPTS**

<https://www.wjgnet.com/bpg/GerInfo/239>

**ONLINE SUBMISSION**

<https://www.f6publishing.com>

## Successful management of therapy-refractory pseudoachalasia after Ivor Lewis esophagectomy by bypassing colonic pull-up: A case report

Sven Flemming, Johan F Lock, Mohammed Hankir, Stanislaus Reimer, Bernhard Petritsch, Christoph-Thomas Germer, Florian Seyfried

**ORCID number:** Sven Flemming 0000-0002-6304-3169; Johan F Lock 0000-0002-9007-3937; Mohammed Hankir 0000-0001-5218-9683; Stanislaus Reimer 0000-0002-6356-7632; Bernhard Petritsch 0000-0002-9909-1592; Christoph-Thomas Germer 0000-0003-3539-6132; Florian Seyfried 0000-0002-5915-8692.

**Author contributions:** Flemming S, Lock JF, Hankir M (native speaker) and Seyfried F wrote the manuscript; Seyfried F and Reimer S lead overall treatment; Seyfried F and Lock JF performed revisional surgery; Reimer S lead endoscopic treatment; Flemming S and Petritsch B prepared the figures; Germer CT supported infrastructure and organizational issues; all authors read and approved the final manuscript.

**Informed consent statement:** The patient provided informed written consent.

**Conflict-of-interest statement:** The authors declare that they have no competing interests.

**CARE Checklist (2016) statement:** The authors have read the CARE Checklist (2016), and the manuscript was prepared and revised according to the CARE

Sven Flemming, Johan F Lock, Mohammed Hankir, Christoph-Thomas Germer, Florian Seyfried, Department of General, Visceral, Transplantation, Vascular and Pediatric Surgery, University Hospital of Würzburg, Würzburg 97080, Germany

Stanislaus Reimer, Department of Internal Medicine II, Section of Gastroenterology, University Hospital of Würzburg, Würzburg 97080, Germany

Bernhard Petritsch, Department of Diagnostic and Interventional Radiology, University Hospital of Würzburg, Würzburg 97080, Germany

**Corresponding author:** Sven Flemming, MD, Academic Research, Senior Research Fellow, Surgeon, Department of General, Visceral, Transplantation, Vascular and Pediatric Surgery, University Hospital of Würzburg, Oberdürrbacher Str. 6, Würzburg 97080, Germany. [flemming\\_s@ukw.de](mailto:flemming_s@ukw.de)

### Abstract

#### BACKGROUND

Gastric pull-up after esophagectomy is still a demanding surgical procedure and associated with considerable morbidity such as anastomotic leaks, fistulas or stenoses. These complications are usually managed by endoscopy, but in extreme cases multidisciplinary management including reoperations may be necessary. Here, we report managing therapy-refractory pseudoachalasia after Ivor Lewis esophagectomy by bypassing colonic pull-up.

#### CASE SUMMARY

A 70-year-old male with dysphagia and regurgitation after esophagectomy with gastric pull-up reconstruction was transferred to our tertiary hospital. Since endoscopic approaches including balloon dilatation and stenting failed, retrosternal colonic pull-up with Roux-en-Y reconstruction was performed with no subsequent adverse events.

#### CONCLUSION

Secondary colonic pull-up is a demanding but successful surgical procedure in patients suffering from therapy-refractory complaints after esophagectomy with gastric pull-up reconstruction.

Checklist (2016).

**Open-Access:** This article is an open-access article that was selected by an in-house editor and fully peer-reviewed by external reviewers. It is distributed in accordance with the Creative Commons Attribution NonCommercial (CC BY-NC 4.0) license, which permits others to distribute, remix, adapt, build upon this work non-commercially, and license their derivative works on different terms, provided the original work is properly cited and the use is non-commercial. See: <http://creativecommons.org/licenses/by-nc/4.0/>

**Manuscript source:** Unsolicited manuscript

**Specialty type:** Surgery

**Country/Territory of origin:** Germany

**Peer-review report's scientific quality classification**

Grade A (Excellent): 0  
Grade B (Very good): B  
Grade C (Good): 0  
Grade D (Fair): 0  
Grade E (Poor): 0

**Received:** December 21, 2020

**Peer-review started:** December 21, 2020

**First decision:** February 11, 2021

**Revised:** February 26, 2021

**Accepted:** March 24, 2021

**Article in press:** March 24, 2021

**Published online:** June 6, 2021

**P-Reviewer:** Kobayashi S

**S-Editor:** Zhang H

**L-Editor:** A

**P-Editor:** Li JH



**Key Words:** Pseudoachalasia; Ivor Lewis esophagectomy; Dysphagia; Colonic pull-up; Esophageal stenting; Case report

©The Author(s) 2021. Published by Baishideng Publishing Group Inc. All rights reserved.

**Core Tip:** Esophageal surgery with gastric pull-up reconstruction remains the only curative therapy for malignant tumors of the esophagus. Despite significant progress in minimally invasive techniques and improvements in perioperative care/complication management, it is still associated with high rates of morbidity and mortality such as anastomotic leak, fistula and stenosis. One of the most frequent long-term functional complications of esophageal surgery with gastric pull-up is delayed gastric emptying which can be usually treated successfully by endoscopic approaches. However, there are cases with a therapy-refractory complaints where salvage operations are required. Here, we present such a case where an operation with secondary colonic pull-up after oncological esophagectomy with gastric tube reconstruction was performed due to pseudoachalasia caused by an anastomotic stenosis that was refractory to endoscopic interventions.

**Citation:** Flemming S, Lock JF, Hankir M, Reimer S, Petritsch B, Germer CT, Seyfried F. Successful management of therapy-refractory pseudoachalasia after Ivor Lewis esophagectomy by bypassing colonic pull-up: A case report. *World J Clin Cases* 2021; 9(16): 3971-3978

**URL:** <https://www.wjgnet.com/2307-8960/full/v9/i16/3971.htm>

**DOI:** <https://dx.doi.org/10.12998/wjcc.v9.i16.3971>

## INTRODUCTION

Esophageal surgery remains the only curative therapy for malignant tumors of the esophagus/esophagogastric junction. Despite significant progress in minimally invasive techniques and improvements in perioperative care/complication management, it is still associated with high rates of morbidity and mortality. Usually, gastric pull-up procedures are used to restore continuity of the alimentary tract[1]. Furthermore, colonic or jejunal pull-up are usually not performed minimal invasive and necessitate at least three anastomoses to restore gastrointestinal continuity which may enhance the risk for additional postoperative complications[2].

One of the most frequent long-term functional complications of esophageal surgery with gastric pull-up is delayed gastric emptying (DGE) which occurs in up to 50% of patients and is a cause of dysphagia, regurgitation, vomiting and feelings of abdominal fullness[3,4]. The primary treatment options for DGE are endoscopic interventions and prokinetic medication, secondary surgical options include a pyloroplasty and gastrojejunostomy[5]. If DGE persists due to more complex structural and functional damage of the stomach and remnant esophagus colonic or jejunal interposition may become a valuable option as salvage operations.

Here, we present such a case study where a salvage operation with secondary colonic pull-up after oncological esophagectomy with gastric tube reconstruction was performed due to pseudoachalasia caused by an anastomotic stenosis that was refractory to endoscopic interventions.

## CASE PRESENTATION

### Chief complaints

The patient reported unintentional weight loss of 8 kg during the previous 5 mo.

### History of past illness

A 70-year old male patient originally contacted our outpatient clinic in the Section of Gastroenterology at the Department of Internal Medicine in 2015 complaining of dysphagia along with regurgitation and vomiting. Anamnestic information revealed that the patient had an abdominal-thoracic esophagus resection (Ivor-Lewis) with

gastric tube reconstruction due to cancer of the esophagogastric junction 3 years prior in the Ukraine.

### Physical examination

Despite reduced nutritional status, the patient's general health status was good. Physical examination did not show any further abnormalities.

### Imaging examinations

A computed tomography (CT) scan of the thorax and abdomen was initiated to exclude tumor recurrence. In parallel, endoscopic examination was performed which revealed a stenosis of the end-to-end esophago-gastrostomy with a residual lumen of 15 mm (Figure 1). The pre-stenotic esophagus was dilated and exhibited impaired peristalsis along with food retention and stasis esophagitis. The gastric tube also exhibited impaired peristalsis and food retention while the pylorus was tight and only passable when considerable pressure was applied to the endoscope.

---

## FINAL DIAGNOSIS

In summary, the patient suffered from anastomotic stenosis resulting in dysphagia but also from DGE due to pylorospasm and hypomotility of gastric pull-up.

---

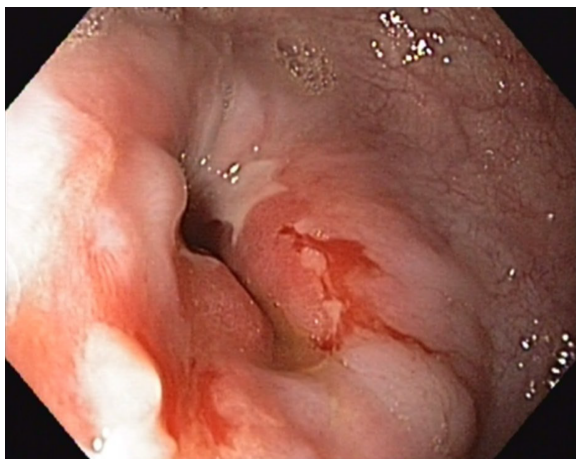
## TREATMENT

Based on the endoscopic findings and patient's symptoms, multiple endoscopic balloon dilatations of the anastomosis and the pylorus were performed resulting in temporary improvement of complaints. However, due to the need for repetition of endoscopic interventions and only temporary relief of symptoms, endoscopic stent insertion was performed but failed due to recurrent stent dislocations. After stent removal, balloon dilatation therapy was reinitiated every 8 wk for almost 3 years. Adjunctive pro-kinetic medical therapy did not confer any clinically relevant improvements.

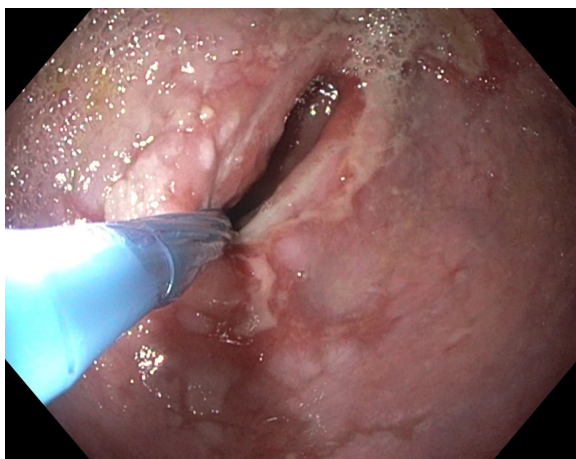
Over the time, the patient reported persistent and even progressively worsening dysphagia. Another CT scan did not reveal tumor recurrence. However, endoscopic examination revealed progressive esophagus dilatation with pre-stenotic bulging and residual lumen of the esophago-gastrostomy with 10mm (Figure 2). The esophagus and gastric tube still exhibited reduced motility and retention of food although the pylorus was now easily passable endoscopically. These endoscopic findings were in line with imaging findings, the progressive complaints and symptoms of the patient and their further weight loss. As a minimally invasive procedure, placement of a jejunal feeding tube for enteral nutrition was considered, but ultimately refused by the patient.

The case was presented to and discussed by the Interdisciplinary Board of Diseases of the Upper Gastrointestinal Tract who unanimously recommended a salvage operation with reconstruction of gastrointestinal continuity by secondary colonic pull-up without resection of the gastric pull-up to avoid thoracotomy. Gastric pyloroplasty or gastro-jejunostomy as therapeutic alternatives were excluded since these two approaches would not address the problem of dysphagia due to anastomotic stenosis of the esophago-gastrostomy.

After a pre-habilitation period with parenteral nutrition, the operation was performed. First, a laparotomy was performed in order to mobilize and transect the transverse and left colon. A sufficient blood supply of the pedicled colon graft was ensured after mobilization. Then, the cervical area was explored and the esophagus was then transected and sealed at the aboral end. The colon could be pulled up to the neck retrosternally in a tension-free manner to create an end-to-side hand-sewn esophago-colostomy (Figure 3). By choosing this approach, an additional thoracotomy was omitted and the gastric tube remained untouched. The gastrointestinal passage was restored by an end-to-side colo-jejunostomy (25 mm circular GIA) and a side-to-side jejuno-jejunostomy (Roux-en-Y reconstruction, 60 mm Endo-GIA) as well as a side-to-side colo-colostomy (60 mm Endo-GIA).



**Figure 1** Endoscopic examination revealed a scar stricture of the esophago-gastrostomy with prestenotic dilatation of the remnant esophagus. Tumor recurrence or anastomotic leakage-induced anastomotic stenosis could not be identified.



**Figure 2** Progressive anastomotic stricture despite recurrent endoscopic balloon dilatations resulted in increased clinical symptoms such as regurgitation and vomiting.

---

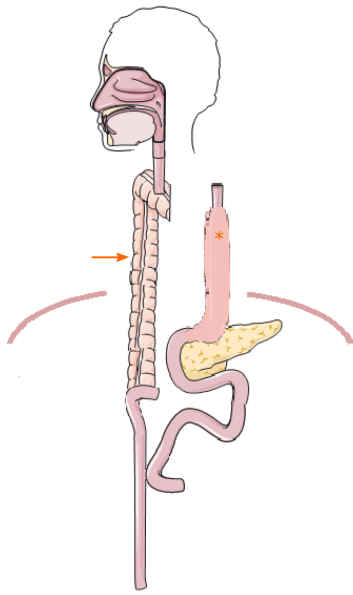
## OUTCOME AND FOLLOW-UP

There were no postoperative complications apart from a pneumonia that required antibiotic therapy for 5 d. Oral food intake could be increased gradually to a complete oral diet. Hence, the initial supportive enteral and parenteral nutrition could be stopped. Endoscopic and radiological re-examination after surgery revealed no abnormalities or signs of anastomotic leakage, retention of food or dilatation of the remnant esophagus (Figure 4). The patient reported no symptoms of dysphagia, regurgitation or vomiting at all time points during the postoperative follow-up. Notably, despite the presence of two abdominal organs in the thoracic region from gastric and colonic pull-up (Figure 5), postoperative cardio-pulmonary function of the patient was not compromised.

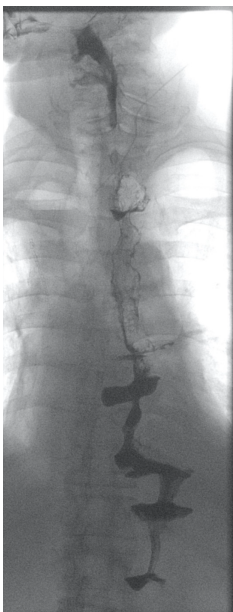
---

## DISCUSSION

The continual development of surgical techniques as well as perioperative management of short-term complications has significantly improved the outcome of patients diagnosed with esophageal cancer[6,7]. However, there are still long-term complications such as DGE, anastomotic strictures and reflux resulting in clinical symptoms including dysphagia, regurgitation and vomiting. Patients suffering from long-term complications usually have a significantly impaired quality of life[6,8,9].



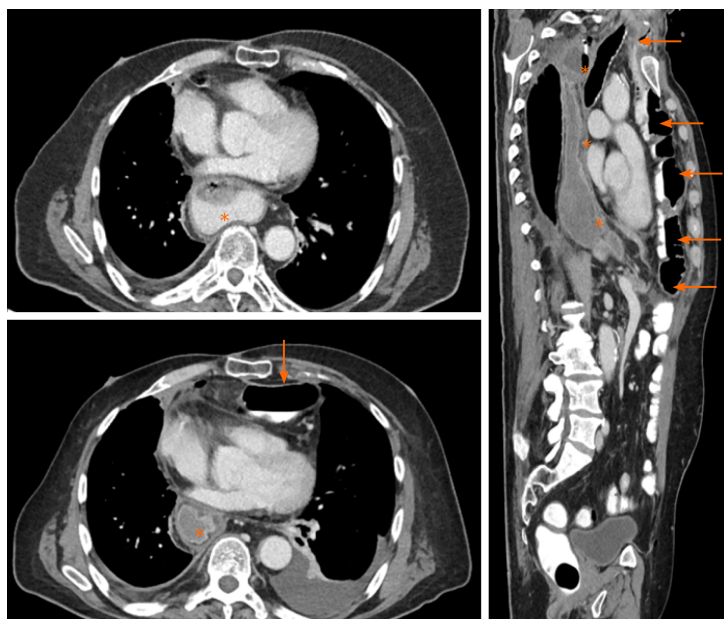
**Figure 3 Schematic illustration of restoring gastrointestinal continuity after colonic pull-up (arrow).** Gastric pull-up (\*) is still localized in the posterior mediastinum after dissection of esophago-gastrostomy. (Figure was created with the support of SMART Servier Medical Art, smart.servier.com).



**Figure 4 Postoperative esophageal barium swallow examination shows a normal gastrointestinal passage without food retention or anastomotic leakage.**

Functional dysphagia mostly occurs after cervical esophageal anastomosis due to insufficient esophageal peristalsis[3]. The main reason for severe postoperative dysphagia is anastomotic stricture. Endoscopic balloon dilatation is usually the therapy of choice[3,10] but tumor recurrence needs to be excluded. Endoscopic balloon angioplasty is also the primary therapeutic approach for DGE that is caused by pylorus dysfunction resulting in early satiety, regurgitation, dysphagia and vomiting. Furthermore, medication which stimulates gastric motility can be used to treat DGE[3,4,8,9].

In this particular case, the patient suffered from DGE due to pylorus dysfunction and reduced motility of the gastric tube. The main problem, however, was an anastomotic stricture caused by scar contracture resulting in dysphagia and a progressive inability to consume food orally. Repetitive endoscopic balloon dilatation, stenting and medication were unsuccessful in the long-term. Stenting of the anastomotic stricture was exceedingly difficult to perform due to the lack of long-



**Figure 5 Postoperative computed tomography images.** Postoperative computed tomography scan demonstrates gastric pull-up (\*) placed in the posterior mediastinum and the retrosternal localized colonic pull-up (arrow) without compromising patient's cardiopulmonary status.

segment anchoring of the stent caused by pre-stenotic esophageal dilatation, which resulted in stent dislocation. Given the therapy-refractory progression of disease, a “re-do” operation was indicated upon insistence of the patient and following appropriate interdisciplinary discussion.

If gastric pull-up has failed, colon interposition is a potential substitute for esophageal replacement[11]. Thus, colon interposition is not only indicated for oncological but also for benign diseases and in situations when salvage surgery becomes mandatory[12-15]. Since pedicled jejunum is limited with respect to its extension length because of poor connection of marginal vessels, super charged pedicled jejunum or free segment interposition are only suitable for full-length esophageal reconstruction requiring microvascular anastomosis and microsurgical techniques[16-18]. Furthermore, jejunal interposition is also associated with short- as well as long-term morbidity[4,16,17,19]. As recommended by Bakshi *et al*[19], we decided to use a colon interposition for the operation due to the characteristics of the colon defined by sufficient length, robust blood supply, and non-dependence of a microvascular anastomosis.

Further questions include which part of the colon and which route for digestive reconstruction should be used. A recent review suggests that the left colon placed retrosternally is the safest technique for colon interposition[20]. These results are supported by a national survey of specialist surgeons in the United Kingdom revealing that the left colon and retrosternal placement was the favored surgical approach[21,22]. An additional alternative of reconstruction would have been local resection of stenotic anastomosis re-anastomosis between the cervical esophagus and the gastric conduit but was withdrawn in this case due to the additional DGE[23].

Since we wanted to leave the gastric pull-up in a position that avoids re-exploration of the posterior mediastinum, we used a retrosternal route for the left colonic interposition as recommended by the most recent evidence. For restoring gastrointestinal continuity, we performed an end-to-side colo-jejunostomy and a side-to-side jejuno-jejunostomy (Roux-en-Y reconstruction) to avoid biliary reflux[24]. As a result of our reconstruction of the gastrointestinal passage, 2 abdominal organs were placed intrathoracically (Figures 3-5). This, however, did not compromise the patient's cardiopulmonary status or physical performance.

## CONCLUSION

Long-term complications after esophagectomy with gastric pull-up can usually be treated by non-surgical approaches such as endoscopic intervention, pro-kinetic medication and gradual oral diet under supervision. However, some patients with

therapy-refractory complaints require surgical salvage treatment. In these cases, the retrosternal left colon interposition is one of the preferred reconstruction methods to improve alimentary satisfaction and quality of life. Since the operation of colon interposition after esophagectomy and patient's follow up are demanding, these procedures should be performed in high volume centers which provide an interdisciplinary team of specialists ensuring the best possible outcome for the patient.

## REFERENCES

- 1 **Butskiy O**, Rahmanian R, White RA, Durham S, Anderson DW, Prisman E. Revisiting the gastric pull-up for pharyngoesophageal reconstruction: A systematic review and meta-analysis of mortality and morbidity. *J Surg Oncol* 2016; **114**: 907-914 [PMID: [27774626](#) DOI: [10.1002/jso.24477](#)]
- 2 **Oki M**, Asato H, Suzuki Y, Umekawa K, Takushima A, Okazaki M, Harii K. Salvage reconstruction of the oesophagus: a retrospective study of 15 cases. *J Plast Reconstr Aesthet Surg* 2010; **63**: 589-597 [PMID: [19303831](#) DOI: [10.1016/j.bjps.2009.01.038](#)]
- 3 **Chen KN**. Managing complications I: leaks, strictures, emptying, reflux, chylothorax. *J Thorac Dis* 2014; **6** Suppl 3: S355-S363 [PMID: [24876942](#) DOI: [10.3978/j.issn.2072-1439.2014.03.36](#)]
- 4 **Irino T**, Tsekrekos A, Coppola A, Scandavini CM, Shetye A, Lundell L, Rouvelas I. Long-term functional outcomes after replacement of the esophagus with gastric, colonic, or jejunal conduits: a systematic literature review. *Dis Esophagus* 2017; **30**: 1-11 [PMID: [28881882](#) DOI: [10.1093/dote/dox083](#)]
- 5 **Petrov RV**, Bakhos CT, Abbas AE, Malik Z, Parkman HP. Endoscopic and Surgical Treatments for Gastroparesis: What to Do and Whom to Treat? *Gastroenterol Clin North Am* 2020; **49**: 539-556 [PMID: [32718569](#) DOI: [10.1016/j.gtc.2020.04.008](#)]
- 6 **Pu S**, Chen H, Zhou C, Yu S, Liao X, Zhu L, He J, Wang B. Major Postoperative Complications in Esophageal Cancer After Minimally Invasive Esophagectomy Compared With Open Esophagectomy: An Updated Meta-analysis. *J Surg Res* 2021; **257**: 554-571 [PMID: [32927322](#) DOI: [10.1016/j.jss.2020.08.011](#)]
- 7 **Mariette C**, Markar SR, Dabakuyo-Yonli TS, Meunier B, Pezet D, Collet D, D'Journo XB, Brigand C, Perniceni T, Carrère N, Mabrut JY, Msika S, Peschard F, Prudhomme M, Bonnetain F, Piessen G; Fédération de Recherche en Chirurgie (FRENCH) and French Eso-Gastric Tumors (FREGAT) Working Group. Hybrid Minimally Invasive Esophagectomy for Esophageal Cancer. *N Engl J Med* 2019; **380**: 152-162 [PMID: [30625052](#) DOI: [10.1056/NEJMoa1805101](#)]
- 8 **Mboumi IW**, Reddy S, Lidor AO. Complications After Esophagectomy. *Surg Clin North Am* 2019; **99**: 501-510 [PMID: [31047038](#) DOI: [10.1016/j.suc.2019.02.011](#)]
- 9 **Xu QL**, Li H, Zhu YJ, Xu G. The treatments and postoperative complications of esophageal cancer: a review. *J Cardiothorac Surg* 2020; **15**: 163 [PMID: [32631428](#) DOI: [10.1186/s13019-020-01202-2](#)]
- 10 **Briel JW**, Tamhankar AP, Hagen JA, DeMeester SR, Johansson J, Choustoulakis E, Peters JH, Bremner CG, DeMeester TR. Prevalence and risk factors for ischemia, leak, and stricture of esophageal anastomosis: gastric pull-up versus colon interposition. *J Am Coll Surg* 2004; **198**: 536-41; discussion 541 [PMID: [15051003](#) DOI: [10.1016/j.jamcollsurg.2003.11.026](#)]
- 11 **Gust L**, Ouattara M, Coosemans W, Nafteux P, Thomas PA, D'Journo XB. European perspective in Thoracic surgery-eso-coloplasty: when and how? *J Thorac Dis* 2016; **8**: S387-S398 [PMID: [27195136](#) DOI: [10.21037/jtd.2016.04.43](#)]
- 12 **Reslinger V**, Tranchart H, D'Annunzio E, Poghosyan T, Quero L, Munoz-Bongrand N, Corte H, Sarfati E, Cattani P, Chirica M. Esophageal reconstruction by colon interposition after esophagectomy for cancer analysis of current indications, operative outcomes, and long-term survival. *J Surg Oncol* 2016; **113**: 159-164 [PMID: [26699417](#) DOI: [10.1002/jso.24118](#)]
- 13 **Kitajima T**, Momose K, Lee S, Haruta S, Shinohara H, Ueno M, Fujii T, Udagawa H. Benign esophageal stricture after thermal injury treated with esophagectomy and ileocolon interposition. *World J Gastroenterol* 2014; **20**: 9205-9209 [PMID: [25083096](#) DOI: [10.3748/wjg.v20.i27.9205](#)]
- 14 **Greene CL**, DeMeester SR, Augustin F, Worrell SG, Oh DS, Hagen JA, DeMeester TR. Long-term quality of life and alimentary satisfaction after esophagectomy with colon interposition. *Ann Thorac Surg* 2014; **98**: 1713-9; discussion 1719 [PMID: [25258155](#) DOI: [10.1016/j.athoracsur.2014.06.088](#)]
- 15 **Chirica M**, Veyrie N, Munoz-Bongrand N, Zohar S, Halimi B, Celerier M, Cattani P, Sarfati E. Late morbidity after colon interposition for corrosive esophageal injury: risk factors, management, and outcome. A 20-years experience. *Ann Surg* 2010; **252**: 271-280 [PMID: [20622655](#) DOI: [10.1097/SLA.0b013e3181e8fd40](#)]
- 16 **Gaur P**, Blackmon SH. Jejunal graft conduits after esophagectomy. *J Thorac Dis* 2014; **6** Suppl 3: S333-S340 [PMID: [24876939](#) DOI: [10.3978/j.issn.2072-1439.2014.05.07](#)]
- 17 **Zhang Z**, Guo Y, Liang C, Feng H, Liu D. Free jejunum interposition as salvage surgery after cervical esophagus injury. *J Thorac Dis* 2016; **8**: E513-E516 [PMID: [27499985](#) DOI: [10.21037/jtd.2016.05.06](#)]
- 18 **Poh M**, Selber JC, Skoracki R, Walsh GL, Yu P. Technical challenges of total esophageal reconstruction using a supercharged jejunal flap. *Ann Surg* 2011; **253**: 1122-1129 [PMID: [21587114](#) DOI: [10.1097/SLA.0b013e318217e875](#)]
- 19 **Bakshi A**, Sugarbaker DJ, Burt BM. Alternative conduits for esophageal replacement. *Ann*

- Cardiothorac Surg* 2017; **6**: 137-143 [PMID: [28447002](#) DOI: [10.21037/acs.2017.03.07](#)]
- 20 **Brown J**, Lewis WG, Foliaki A, Clark GWB, Blackshaw GRJC, Chan DSY. Colonic Interposition After Adult Oesophagectomy: Systematic Review and Meta-analysis of Conduit Choice and Outcome. *J Gastrointest Surg* 2018; **22**: 1104-1111 [PMID: [29520647](#) DOI: [10.1007/s11605-018-3735-8](#)]
- 21 **Fisher RA**, Griffiths EA, Evison F, Mason RC, Zylstra J, Davies AR, Alderson D, Gossage JA. A national audit of colonic interposition for esophageal replacement. *Dis Esophagus* 2017; **30**: 1-10 [PMID: [28375436](#) DOI: [10.1093/dote/dow003](#)]
- 22 **Fisher RA**, Gossage J, Griffiths E. Response to: "Colonic Interposition After Adult Oesophagectomy: Systematic Review and Meta-analysis of Conduit Choice and Outcome". *J Gastrointest Surg* 2018; **22**: 2002 [PMID: [30076590](#) DOI: [10.1007/s11605-018-3909-4](#)]
- 23 **Kinoshita Y**, Udagawa H, Tsutsumi K, Ueno M, Mine S, Ehara K. Surgical repair of refractory strictures of esophagogastric anastomoses caused by leakage following esophagectomy. *Dis Esophagus* 2009; **22**: 427-433 [PMID: [19191859](#) DOI: [10.1111/j.1442-2050.2008.00926.x](#)]
- 24 **Chang A**. Colon Interposition for Staged Esophageal Reconstruction. *Oper Tech Thorac Cardiothorac Surg* 2010; **3**: 231-242 [DOI: [10.1053/j.optechstcvs.2010.08.003](#)]



Published by **Baishideng Publishing Group Inc**  
7041 Koll Center Parkway, Suite 160, Pleasanton, CA 94566, USA

**Telephone:** +1-925-3991568

**E-mail:** [bpgoffice@wjgnet.com](mailto:bpgoffice@wjgnet.com)

**Help Desk:** <https://www.f6publishing.com/helpdesk>

<https://www.wjgnet.com>

