

# World Journal of *Clinical Cases*

*World J Clin Cases* 2021 June 6; 9(16): 3796-4115



## Contents

Thrice Monthly Volume 9 Number 16 June 6, 2021

## REVIEW

- 3796 COVID-19 and the digestive system: A comprehensive review  
*Wang MK, Yue HY, Cai J, Zhai YJ, Peng JH, Hui JF, Hou DY, Li WP, Yang JS*

## MINIREVIEWS

- 3814 COVID-19 impact on the liver  
*Baroiu L, Dumitru C, Iancu A, Leşe AC, Drăgănescu M, Baroiu N, Anghel L*
- 3826 Xenogeneic stem cell transplantation: Research progress and clinical prospects  
*Jiang LL, Li H, Liu L*

## ORIGINAL ARTICLE

## Case Control Study

- 3838 Histopathological classification and follow-up analysis of chronic atrophic gastritis  
*Wang YK, Shen L, Yun T, Yang BF, Zhu CY, Wang SN*

## Retrospective Study

- 3848 Effectiveness of sharp recanalization of superior vena cava-right atrium junction occlusion  
*Wu XW, Zhao XY, Li X, Li JX, Liu ZY, Huang Z, Zhang L, Sima CY, Huang Y, Chen L, Zhou S*
- 3858 Management and outcomes of surgical patients with intestinal Behçet's disease and Crohn's disease in southwest China  
*Zeng L, Meng WJ, Wen ZH, Chen YL, Wang YF, Tang CW*
- 3869 Clinical and radiological outcomes of dynamic cervical implant arthroplasty: A 5-year follow-up  
*Zou L, Rong X, Liu XJ, Liu H*

## Observational Study

- 3880 Differential analysis revealing APOC1 to be a diagnostic and prognostic marker for liver metastases of colorectal cancer  
*Shen HY, Wei FZ, Liu Q*

## Randomized Clinical Trial

- 3895 Comparison of white-light endoscopy, optical-enhanced and acetic-acid magnifying endoscopy for detecting gastric intestinal metaplasia: A randomized trial  
*Song YH, Xu LD, Xing MX, Li KK, Xiao XG, Zhang Y, Li L, Xiao YJ, Qu YL, Wu HL*

## CASE REPORT

- 3908** Snapping wrist due to bony prominence and tenosynovitis of the first extensor compartment: A case report  
*Hu CJ, Chow PC, Tzeng IS*
- 3914** Massive retroperitoneal hematoma as an acute complication of retrograde intrarenal surgery: A case report  
*Choi T, Choi J, Min GE, Lee DG*
- 3919** Internal fixation and unicompartmental knee arthroplasty for an elderly patient with patellar fracture and anteromedial osteoarthritis: A case report  
*Nan SK, Li HF, Zhang D, Lin JN, Hou LS*
- 3927** Haemangiomas in the urinary bladder: Two case reports  
*Zhao GC, Ke CX*
- 3936** Endoscopic diagnosis and treatment of an appendiceal mucocele: A case report  
*Wang TT, He JJ, Zhou PH, Chen WW, Chen CW, Liu J*
- 3943** Diagnosis and spontaneous healing of asymptomatic renal allograft extra-renal pseudo-aneurysm: A case report  
*Xu RF, He EH, Yi ZX, Li L, Lin J, Qian LX*
- 3951** Rehabilitation and pharmacotherapy of neuromyelitis optica spectrum disorder: A case report  
*Wang XJ, Xia P, Yang T, Cheng K, Chen AL, Li XP*
- 3960** Undifferentiated intimal sarcoma of the pulmonary artery: A case report  
*Li X, Hong L, Huo XY*
- 3966** Chest pain in a heart transplant recipient: A case report  
*Chen YJ, Tsai CS, Huang TW*
- 3971** Successful management of therapy-refractory pseudoachalasia after Ivor Lewis esophagectomy by bypassing colonic pull-up: A case report  
*Flemming S, Lock JF, Hankir M, Reimer S, Petritsch B, Germer CT, Seyfried F*
- 3979** Old unreduced obturator dislocation of the hip: A case report  
*Li WZ, Wang JJ, Ni JD, Song DY, Ding ML, Huang J, He GX*
- 3988** Laterally spreading tumor-like primary rectal mucosa-associated lymphoid tissue lymphoma: A case report  
*Wei YL, Min CC, Ren LL, Xu S, Chen YQ, Zhang Q, Zhao WJ, Zhang CP, Yin XY*
- 3996** Coronary artery aneurysm combined with myocardial bridge: A case report  
*Ye Z, Dong XF, Yan YM, Luo YK*
- 4001** Thoracoscopic diagnosis of traumatic pericardial rupture with cardiac hernia: A case report  
*Wu YY, He ZL, Lu ZY*

- 4007** Delayed diagnosis and comprehensive treatment of cutaneous tuberculosis: A case report  
*Gao LJ, Huang ZH, Jin QY, Zhang GY, Gao MX, Qian JY, Zhu SX, Yu Y*
- 4016** Rapidly progressing primary pulmonary lymphoma masquerading as lung infectious disease: A case report and review of the literature  
*Jiang JH, Zhang CL, Wu QL, Liu YH, Wang XQ, Wang XL, Fang BM*
- 4024** Asymptomatic carbon dioxide embolism during transoral vestibular thyroidectomy: A case report  
*Tang JX, Wang L, Nian WQ, Tang WY, Xiao JY, Tang XX, Liu HL*
- 4032** Transient immune hepatitis as post-coronavirus disease complication: A case report  
*Drăgănescu AC, Săndulescu O, Bilașco A, Kouris C, Streinu-Cercel A, Luminos M, Streinu-Cercel A*
- 4040** Acute inferior myocardial infarction in a young man with testicular seminoma: A case report  
*Scafa-Udriste A, Popa-Fotea NM, Bataila V, Calmac L, Dorobantu M*
- 4046** Asymptomatic traumatic rupture of an intracranial dermoid cyst: A case report  
*Zhang MH, Feng Q, Zhu HL, Lu H, Ding ZX, Feng B*
- 4052** Parotid mammary analogue secretory carcinoma: A case report and review of literature  
*Min FH, Li J, Tao BQ, Liu HM, Yang ZJ, Chang L, Li YY, Liu YK, Qin YW, Liu WW*
- 4062** Liver injury associated with the use of selective androgen receptor modulators and post-cycle therapy: Two case reports and literature review  
*Koller T, Vrbova P, Meciarova I, Molcan P, Smitka M, Adamcova Selcanova S, Skladany L*
- 4072** Spinal epidural abscess due to coinfection of bacteria and tuberculosis: A case report  
*Kim C, Lee S, Kim J*
- 4081** Rare complication of inflammatory bowel disease-like colitis from glycogen storage disease type 1b and its surgical management: A case report  
*Lui FCW, Lo OSH*
- 4090** Thymosin as a possible therapeutic drug for COVID-19: A case report  
*Zheng QN, Xu MY, Gan FM, Ye SS, Zhao H*
- 4095** Arrhythmogenic right ventricular cardiomyopathy characterized by recurrent syncope during exercise: A case report  
*Wu HY, Cao YW, Gao TJ, Fu JL, Liang L*
- 4104** Delayed pseudoaneurysm formation of the carotid artery following the oral cavity injury in a child: A case report  
*Chung BH, Lee MR, Yang JD, Yu HC, Hong YT, Hwang HP*
- 4110** Atezolizumab-induced anaphylactic shock in a patient with hepatocellular carcinoma undergoing immunotherapy: A case report  
*Bian LF, Zheng C, Shi XL*

**ABOUT COVER**

Editorial Board Member of *World Journal of Clinical Cases*, Gwo-Ping Jong, FCCP, MD, MHSc, PhD, Associate Professor, Department of Public Health, Chung Shan Medical University, Taichung 40201, Taiwan. cgp8009@yahoo.com.tw

**AIMS AND SCOPE**

The primary aim of *World Journal of Clinical Cases* (WJCC, *World J Clin Cases*) is to provide scholars and readers from various fields of clinical medicine with a platform to publish high-quality clinical research articles and communicate their research findings online.

WJCC mainly publishes articles reporting research results and findings obtained in the field of clinical medicine and covering a wide range of topics, including case control studies, retrospective cohort studies, retrospective studies, clinical trials studies, observational studies, prospective studies, randomized controlled trials, randomized clinical trials, systematic reviews, meta-analysis, and case reports.

**INDEXING/ABSTRACTING**

The WJCC is now indexed in Science Citation Index Expanded (also known as SciSearch®), Journal Citation Reports/Science Edition, Scopus, PubMed, and PubMed Central. The 2020 Edition of Journal Citation Reports® cites the 2019 impact factor (IF) for WJCC as 1.013; IF without journal self cites: 0.991; Ranking: 120 among 165 journals in medicine, general and internal; and Quartile category: Q3. The WJCC's CiteScore for 2019 is 0.3 and Scopus CiteScore rank 2019: General Medicine is 394/529.

**RESPONSIBLE EDITORS FOR THIS ISSUE**

Production Editor: Yan-Xia Xing, Production Department Director: Yun-Xiaoqian Wu, Editorial Office Director: Jin-Lai Wang.

**NAME OF JOURNAL**

*World Journal of Clinical Cases*

**ISSN**

ISSN 2307-8960 (online)

**LAUNCH DATE**

April 16, 2013

**FREQUENCY**

Thrice Monthly

**EDITORS-IN-CHIEF**

Dennis A Bloomfield, Sandro Vento, Bao-Gan Peng

**EDITORIAL BOARD MEMBERS**

<https://www.wjgnet.com/2307-8960/editorialboard.htm>

**PUBLICATION DATE**

June 6, 2021

**COPYRIGHT**

© 2021 Baishideng Publishing Group Inc

**INSTRUCTIONS TO AUTHORS**

<https://www.wjgnet.com/bpg/gerinfo/204>

**GUIDELINES FOR ETHICS DOCUMENTS**

<https://www.wjgnet.com/bpg/GerInfo/287>

**GUIDELINES FOR NON-NATIVE SPEAKERS OF ENGLISH**

<https://www.wjgnet.com/bpg/gerinfo/240>

**PUBLICATION ETHICS**

<https://www.wjgnet.com/bpg/GerInfo/288>

**PUBLICATION MISCONDUCT**

<https://www.wjgnet.com/bpg/gerinfo/208>

**ARTICLE PROCESSING CHARGE**

<https://www.wjgnet.com/bpg/gerinfo/242>

**STEPS FOR SUBMITTING MANUSCRIPTS**

<https://www.wjgnet.com/bpg/GerInfo/239>

**ONLINE SUBMISSION**

<https://www.f6publishing.com>



## Transient immune hepatitis as post-coronavirus disease complication: A case report

Anca Cristina Drăgănescu, Oana Săndulescu, Anuța Bilașco, Camelia Kouris, Anca Streinu-Cercel, Monica Luminos, Adrian Streinu-Cercel

**ORCID number:** Anca Cristina Drăgănescu 0000-0002-4659-1921; Oana Săndulescu 0000-0002-2586-4070; Anuța Bilașco 0000-0002-7911-0426; Camelia Kouris 0000-0002-5775-7501; Anca Streinu-Cercel 0000-0003-2794-6720; Monica Luminos 0000-0002-7140-661X; Adrian Streinu-Cercel 0000-0001-6382-5067.

**Author contributions:** Drăgănescu AC, Săndulescu O, Bilașco A, Kouris C, Streinu-Cercel An, Luminos M, and Streinu-Cercel Ad had equal contributions to the article and were involved in patient management, acquisition, analysis, or interpretation of data for the work; drafted the work or revised it critically for important intellectual content; gave final approval of the version to be published, and agree to be accountable for all aspects of the work.

**Informed consent statement:** Written informed consent was obtained from the patient for the publication of this report and any accompanying images.

**Conflict-of-interest statement:** The authors declare that they have no conflict of interest.

**CARE Checklist (2016) statement:** The authors have read the CARE Checklist (2016), and the

Anca Cristina Drăgănescu, Oana Săndulescu, Anuța Bilașco, Camelia Kouris, Anca Streinu-Cercel, Monica Luminos, Adrian Streinu-Cercel, Infectious Diseases Department, National Institute for Infectious Diseases “Prof. Dr. Matei Balș”, Bucharest 021105, Romania

Oana Săndulescu, Anca Streinu-Cercel, Monica Luminos, Adrian Streinu-Cercel, Infectious Diseases Department, Carol Davila University of Medicine and Pharmacy, Bucharest 021105, Romania

**Corresponding author:** Oana Săndulescu, MD, PhD, Associate Professor, Infectious Diseases Department, National Institute for Infectious Diseases “Prof. Dr. Matei Balș”, Carol Davila University of Medicine and Pharmacy, No. 1 Dr. Calistrat Grozovici Street, Bucharest 021105, Romania. [oana.sandulescu@umfcd.ro](mailto:oana.sandulescu@umfcd.ro)

### Abstract

#### BACKGROUND

We report a case of post-coronavirus disease (COVID) immune hepatitis occurring in a young male with no pre-existing comorbidities.

#### CASE SUMMARY

A previously healthy 21-year-old male patient was admitted to our hospital with mild COVID-19. During the course of in-hospital isolation and monitoring, he developed an alanine aminotransferase (ALT) and aspartate aminotransferase (AST) increase, with the enzymes peaking at day 24 (ALT 15 times the upper normal limit), with preserved liver function. The liver enzyme increase occurred 20 d after the complete clinical remission of COVID-19, and ALT dynamics paralleled the increase in total antibodies against severe acute respiratory syndrome coronavirus 2 (SARS-CoV-2). The case was interpreted as post-COVID immune hepatitis, with extensive laboratory investigations excluding other potential causes. The hepatocytolysis remitted 20 d after the peak ALT, without further intervention, with complete recovery, but the total anti-SARS-CoV-2 antibodies continued to increase the next 5 mo following the acute infection.

#### CONCLUSION

Close attention should also be paid to young patients with mild forms of disease, and a high index of suspicion should be maintained for post-COVID complications.



manuscript was prepared and revised according to the CARE Checklist (2016).

**Open-Access:** This article is an open-access article that was selected by an in-house editor and fully peer-reviewed by external reviewers. It is distributed in accordance with the Creative Commons Attribution NonCommercial (CC BY-NC 4.0) license, which permits others to distribute, remix, adapt, build upon this work non-commercially, and license their derivative works on different terms, provided the original work is properly cited and the use is non-commercial. See: <http://creativecommons.org/licenses/by-nc/4.0/>

**Manuscript source:** Unsolicited manuscript

**Specialty type:** Infectious diseases

**Country/Territory of origin:** Romania

**Peer-review report's scientific quality classification**

Grade A (Excellent): 0  
Grade B (Very good): B, B  
Grade C (Good): C  
Grade D (Fair): D  
Grade E (Poor): 0

**Received:** January 12, 2021

**Peer-review started:** January 12, 2021

**First decision:** February 11, 2021

**Revised:** February 25, 2021

**Accepted:** March 24, 2021

**Article in press:** March 24, 2021

**Published online:** June 6, 2021

**P-Reviewer:** Jin SY, Lipiński P, Vieira A

**S-Editor:** Zhang H

**L-Editor:** A

**P-Editor:** Li JH



**Key Words:** COVID-19; Complications; Liver; Case report

©The Author(s) 2021. Published by Baishideng Publishing Group Inc. All rights reserved.

**Core Tip:** We report an interesting case of post-coronavirus disease immune hepatitis occurring in a young male with no pre-existing comorbidities. The patient acquired the infection from an asymptomatic carrier of severe acute respiratory syndrome coronavirus 2 (SARS-CoV-2). He developed a mild form of disease, but after apparent clinical remission and real-time reverse transcription polymerase chain reaction negative conversion, an important increase in liver enzymes was recorded in parallel with an increasing SARS-CoV-2 antibody titer.

**Citation:** Drăgănescu AC, Săndulescu O, Bilaşco A, Kouris C, Streinu-Cercel A, Luminos M, Streinu-Cercel A. Transient immune hepatitis as post-coronavirus disease complication: A case report. *World J Clin Cases* 2021; 9(16): 4032-4039

**URL:** <https://www.wjgnet.com/2307-8960/full/v9/i16/4032.htm>

**DOI:** <https://dx.doi.org/10.12998/wjcc.v9.i16.4032>

## INTRODUCTION

The emergence of severe acute respiratory syndrome coronavirus 2 (SARS-CoV-2) as a novel pathogen has reshaped our understanding of infectious diseases. While immune-mediated post-infectious complications have been previously described for other pathogens, these remain relatively rare occurrences. With the onset of the coronavirus disease 2019 (COVID-19) pandemic, infectious diseases practitioners and colleagues from related specialties need to maintain a double focus—managing the acute disease per se, while also keeping a heightened attention towards post-COVID complications.

## CASE PRESENTATION

### Chief complaints

We report the case of a previously healthy 21-year-old male patient from Bucharest, Romania, presenting in June 2020, during the first COVID-19 wave in Romania, with a two-day prodrome of fatigability and headache, followed by sudden onset high-grade fever (highest recorded temperature of 39.8 °C) and malaise. Nasopharyngeal and oropharyngeal swabs were collected and the real-time reverse transcription polymerase chain reaction (RT-PCR) results came back positive for SARS-CoV-2. In accordance to the national regulations in June 2020, the patient underwent isolation, treatment and monitoring in the hospital, and remained hospitalized until he met the criteria of clinical remission plus two consecutive negative RT-PCR tests at least 24 h apart.

### History of present illness

The patient had been self-isolating at home for the past two months and a half, and had only left the house for one meeting, 4 d prior to symptom onset. After being confirmed with COVID-19 by RT-PCR, epidemiological tracing revealed that the meeting consisted of indoor close contact, without mask wearing on either side, with one person who had no signs or symptoms of infection at the time of the meeting. Upon evaluation of the contact, she was confirmed by RT-PCT to be an asymptomatic carrier of SARS-CoV-2. According to the national regulations at the time, she was also admitted to the hospital, where she remained completely asymptomatic, and reverted to negative RT-PCR on days 16 and 17 from the initial RT-PCR confirmation.

### Physical examination

Upon hospital admission, our patient underwent a complete evaluation, which revealed pharyngeal erythema at physical exam, normal hematology and biochemistry

laboratory tests (Table 1) and normal computed tomography (CT) of the chest. He received antiviral treatment with umifenovir 200 mg orally every 8 h for 5 d, and thromboprophylaxis with low molecular weight heparin subcutaneously once daily for 14 d. The course of disease was mild, with no occurrence of pneumonia, and all symptoms subsided 4 d after onset; no further symptoms developed throughout the course of the disease.

### Laboratory examinations

While still in the hospital for isolation and monitoring purposes, an increase in liver enzymes was noted, with alanine aminotransferase (ALT) and aspartate aminotransferase (AST) starting to increase around day 14 from symptom onset, reaching a peak of 736 U/L ALT (15 times the upper normal limit) and 290 U/L AST (5 times the upper normal limit) on day 24 (Figure 1). All other liver function tests were normal, and no other changes were seen in other laboratory parameters, including complete blood count, total and direct bilirubin, gamma-glutamyl transferase, fibrinogen, and coagulation markers. The peak ALT was reached at approximately the same time when RT-PCR became negative (on days 22 and 23 since onset).

For the differential diagnosis of the ALT increase, multiple plausible causes of hepatic cytolysis were ruled out (Table 2): drug-induced liver injury was excluded based on the fact that no drugs had been recently administered. Systemic replication of SARS-CoV-2 was ruled out through negative RT-PCR from peripheral blood, which paralleled the negative RT-PCR from nasopharyngeal and oropharyngeal swabs. Another potential hypothesis considered was a COVID-19 cytokine storm that could also affect the liver. However, the timing of the ALT increase was not superposable to a cytokine storm, as the peak ALT occurred on day 24. We also checked the values of inflammatory markers at that time point and the results were within the normal range, and we repeated the chest CT, which was normal, confirming that no pulmonary lesions had been constituted throughout the course of the disease. We also ruled out infections with other hepatotropic viruses, through negative serological tests for hepatitis viruses A, B, C, E, adenovirus, coxsackie virus, echo virus, herpes simplex viruses, Epstein-Barr virus and cytomegalovirus.

## FINAL DIAGNOSIS

The remaining hypothesis, and the final diagnosis in our case, was post-COVID immune hepatitis, which occurred 20 days after the complete clinical remission of COVID-19 and paralleled a rapidly increasing titer of total anti-SARS-CoV-2 antibodies (determined through amplified chemiluminescence on VITROS 3600, Ortho Clinical Diagnosis, United States). Total antibodies appeared as early as day 6 (29.2 S/CO) and rapidly increased to a titer of 166 S/CO on day 23 (Figure 2).

## OUTCOME AND FOLLOW-UP

We continued to monitor the patient closely over the next few days, until the ALT and AST levels started to decrease. Following this decrease, the patient was discharged on day 27, since the clinical remission and RT-PCR negative conversion criteria had been already met, and he continued to be followed-up as outpatient. A normalization of ALT levels was seen 20 d after the ALT peak. However, the titer of SARS-CoV-2 antibodies continued to increase up to 5 mo after the initial infection, reaching a peak of 865 S/CO at day 145 and then gradually decreasing to 657 S/CO at day 193 (6 mo after the initial infection).

## DISCUSSION

This case has a set of particularities. Transmission of disease occurred from an asymptomatic SARS-CoV-2 carrier, which highlights the importance of preventive measures such as continued mask wearing, including in the presence of apparently asymptomatic persons. A recent meta-analysis has reported that the risk of transmission of SARS-CoV-2 infection from asymptomatic carriers is 18.8% with close contact, and that the overall percentage of asymptomatic patients among all those testing positive for SARS-CoV-2 can vary in quite a large range, from 20% to 75%,



**Table 1 Laboratory assessment at hospital admission and throughout follow-up**

Parameter	Day 3	Day 7	Day 11	Day 17	Day 20	Day 24	Day 25	Day 26	Day 27	Day 32	Day 43	Day 69	Day 104	Day 145	Day 193	Day 257
<b>Hematology</b>																
White blood cells (3.6-9.6) $\times 10^3/\mu\text{L}$	4.5	3.9	5.8	7.6		6.6		6.7				5.7	5.7			4.3
Neutrophils (1.4-6.5) $\times 10^3/\mu\text{L}$	1.8	1.7	3.0	3.8		3.4		3.5				3.1	3.3			2.0
Lymphocytes (1.2-3.4) $\times 10^3/\mu\text{L}$	1.8	1.7	2.0	2.7		2.2		2.2				1.7	1.6			1.7
Hemoglobin (12.1-17.2) g/dL	15.6	15.2	15.5	15.8		15.8		15.2				15.0	15.6			14.3
Platelets (200-400) $\times 10^3/\mu\text{L}$	205	<b>188</b>	266	311		265		254				245	255			215
<b>Coagulation</b>																
D-dimers hs (50-230) ng/mL	68	38	<b>10</b>		<b>18</b>	56		30		<b>23</b>	61					
Activated partial thromboplastin time (24-38) s	31.6			33.4	35.4						31.9	32.3				27.2
Prothrombin concentration (80-115) %	<b>75</b>	95	<b>73.9</b>	89	84	90		89	83	86	83	<b>75</b>	<b>72.6</b>			86.9
<b>Biochemistry</b>																
ALT (4-50) U/L	28	<b>64</b>	<b>211</b>	<b>309</b>	<b>349</b>	<b>736</b>	<b>627</b>	<b>592</b>	<b>523</b>	<b>270</b>	46	23	19			13
AST (17-59) U/L	28	50	59	13	<b>94</b>	<b>290</b>	<b>196</b>	<b>148</b>	<b>113</b>	<b>63</b>	28	24	22			18
Total bilirubin (0.2-1.3) mg/dL	0.4	0.4	0.4	0.6	0.5	0.6	0.5	0.5	0.8	0.6	0.6	0.6	0.6			
Direct bilirubin (0.0-0.4) mg/dL	0.1	0.1	0.1	0.1	0.1	0.1	0.1	0.1	0.2	0.2	0.2	0.2	0.2			
GGT (15-85) U/L	29	38		64	81	<b>94</b>	<b>93</b>	<b>92</b>	<b>86</b>	74	46	26	22			<b>14</b>
Alkaline phosphatase (38-126) U/L	58			69		71	65	67	65		69					
Albumin (3.5-5) g/dL	4.7				4.5	4.9			4.6	4.8						
Amylase (30-110) U/L			59			57										
Lipase (23-300) U/L			35			37										
Creatine kinase (55-170) U/L	89	59	46	52	56	62	59	58	54	78						117
Creatine kinase-MB (1-16) U/L	9	6	6	7	4	7	6	10	7	5						9
Fasting plasma glucose (74-106) mg/dL	84	102	97	86	88	98	90		92	84	89	87	96			97
Lactate dehydrogenase (120-246) U/L	189	221	214	<b>252</b>	<b>258</b>	<b>426</b>	<b>378</b>	<b>285</b>	245	<b>260</b>	189	172	162			145

Total proteins (6.3-8.2) g/dL	7.9	8.0	8.2	8.2	7.9	<b>8.7</b>				8.2	<b>8.5</b>	7.8	7.9			7.8
Cholesterol (50-200) mg/dL	150					196										151
HDL-cholesterol (40-60) mg/dL						46										48
Total lipids (400-800) mg/dL						705										482
Triglycerides (15-150) mg/dL	62					<b>174</b>										52
Creatinine (0.7-1.3) mg/dL	0.9	0.8	0.8	0.7	0.8	0.8	<b>0.6</b>	<b>0.6</b>	0.9	0.7	0.7	0.7	0.7			<b>0.6</b>
Urea (15-45) mg/dL	31	27	27	27.5	20	28		28	29	34	34	41	33			35
Sodium (137-145) mmol/L	143	141	142	142	141	139	140		141	141	142	141				143
Potassium (3.6-5.0) mmol/L	4.3	4.4	4.6	4.4	4.4	4.7	4.7		4.8	4.6	4.5	4.3				4.7
Calcium (8.4-10.2) mg/dL	9.3		9.4	9.9	9.7					9.7	10.0	9.9	9.9			9.9
Inflammatory markers																
C-reactive protein (0-3) mg/L	<b>6.20</b>	1.62		0.99								1.75	1.37			0.78
Erythrocyte sedimentation rate mm/h			10								16	8				
Fibrinogen (200-393) mg/dL	250	243	<b>196</b>	227	221	254		246	244	269	260	221				
Ferritin (22-322) ng/mL	149.7		173.8					166.3								
IL-6 (0-9.7) pg/mL	0.453		0.420													
TNF- $\alpha$ (0-1.9) pg/mL	0.0		0.0													
Procalcitonin (0-0.5) ng/mL	0.05		0.05													
Cardiac markers																
Myoglobin (0-99.3) ng/mL	47.4					36.7										
NT-proBNP (0-125) ng/L	5					5										
Troponin I (0-0.16) ng/mL	0.03					0.03										
SARS-CoV-2 antibodies																
Total SARS-CoV-2 Ab (0.00-0.99) S/CO		<b>29.2</b>	<b>62</b>	<b>110</b>	<b>132</b>	<b>166</b>	<b>173</b>	<b>180</b>	<b>188</b>	<b>225</b>	<b>305</b>	<b>498</b>	<b>721</b>	<b>865</b>	<b>654</b>	<b>85.1</b>

Days are counted since symptom onset. Day 3 was the first day of hospital admission (baseline laboratory assessment).

Bold font indicates laboratory values outside of the normal range. SARS-CoV-2: Severe acute respiratory syndrome coronavirus 2; IL-6: Interleukin 6; ALT: Alanine aminotransferase; AST: Aspartate aminotransferase; NT-proBNP: N-terminal pro-B-type natriuretic peptide; TNF- $\alpha$ : Tumor necrosis factor-alpha; HDL: High-density lipoprotein.

depending on the assayed population[1].

Our current case also led to secondary transmission to another member of the household, who was a healthcare worker, working at a COVID-19 unit. At the time when our current case was confirmed by RT-PCR the household member was negative for SARS-CoV-2 by RT-PCR, and approximately 5 d after symptom onset in our case, the household member became symptomatic and also tested positive for SARS-CoV-2 by RT-PCR. In our experience, when wearing appropriate personal protective equipment in the COVID ward, the overall risk of acquiring infection at work might theoretically be lower than that of acquiring infection elsewhere, particularly in the household, where permanent mask wearing is most often not possible.

Furthermore, while elderly patients with associated comorbidities have clearly been characterized as one of the most important groups at risk of severe or complicated COVID-19, our reported case highlights the fact that close attention should also be paid to young patients with mild forms of disease, and a high index of suspicion should be maintained for post-COVID complications, particularly since young patients may develop a strong immune response, potentially associating immune complications.

Hepatocytolysis can be a relatively common feature of COVID-19, but it generally occurs during the acute phase of the infection, with a French cohort study reporting that up to 36.3% of patients had abnormal liver function tests[2], similar to the rates of 31.6%[3] and 37.2%[4] reported from China, with even higher rates (62%) reported from the United States[5]. However, most of these clinical observations come from patients with moderate, severe or critical forms of disease, since this is the patient population that most often requires management in the hospital. Liver cytolysis has also been associated with more extensive lung lesions during the acute phase of COVID-19[3]. However, while the overall prevalence of liver cytolysis in patients with COVID-19 appears to be quite high, reported at 46.9% in a pooled meta-analysis[6], relatively fewer cases display high-grade cytolysis, *i.e.*, only 6.4% of the patients from the French cohort had ALT levels above 5 times the upper normal limit[2]. Because of the fact that in Romania at the time when our case occurred, hospital isolation was mandatory for all patients testing positive for SARS-CoV-2 infection, we were able to detect this biochemistry finding, an ALT level 15 times the upper normal limit in a patient who had had mild COVID. ALT levels above 5 times the upper normal limit in COVID-19 are associated with a poor prognosis, specifically: significantly higher risk of severe lung involvement, intensive care admission, and death[2,6]. This was not the case in our patient, where an even higher ALT level was not associated with worsening of COVID, and it occurred after remission of all clinical signs and symptoms for 20 d.

Residual inflammation has been documented by (<sup>18</sup>F) fluorodeoxyglucose positron emission tomography/CT in patients convalescing post-severe COVID, in organs such as the lungs, mediastinal lymph nodes, liver and spleen, immediately after RT-PCR negative conversion[7]. This residual inflammation could theoretically explain to some extent the pattern of hepatocytolysis seen in our patient, however, our case was a mild form of disease, not severe, and displayed a much higher ALT increase, while in the cited study most patients (6/7) had normal ALT levels at the time when positron emission tomography/computed tomography detected liver inflammation, and only one of the patients had low-grade cytolysis (ALT 1.5 times the upper normal limit)[7].

In the case we have reported, this finding was mostly inconsequential, as it did not associate liver failure, or long-term consequences. However, it is not implausible to speculate that had this type of ALT flare occurred in a patient with pre-existing liver damage, or pre-existing autoimmunity, it could have associated important clinical implications. Therefore, we consider that it is essential to maintain a high index of suspicion for post-COVID complications in all patients, not only those who have had a severe or complicated form of disease.

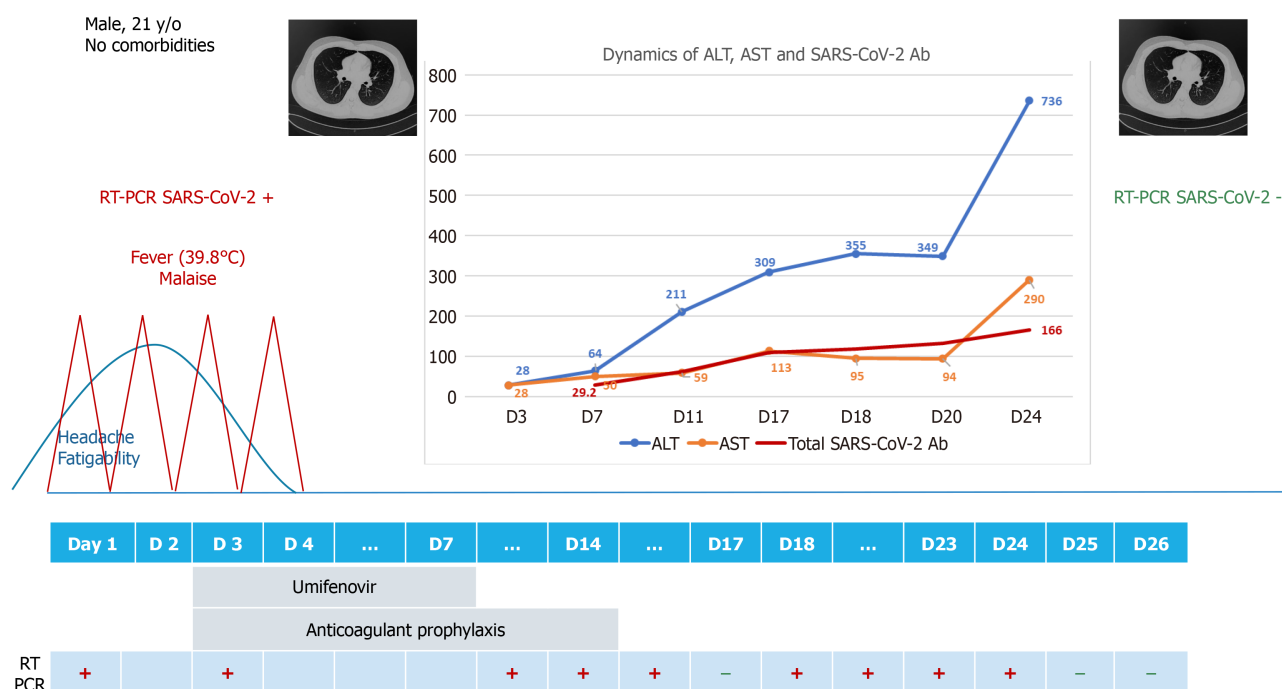
## CONCLUSION

We have reported an interesting case of transient post-COVID immune hepatitis, in a young male patient with no pre-existing comorbidities. Close attention should also be paid to young patients with mild forms of disease, and a high index of suspicion should be maintained for post-COVID complications.

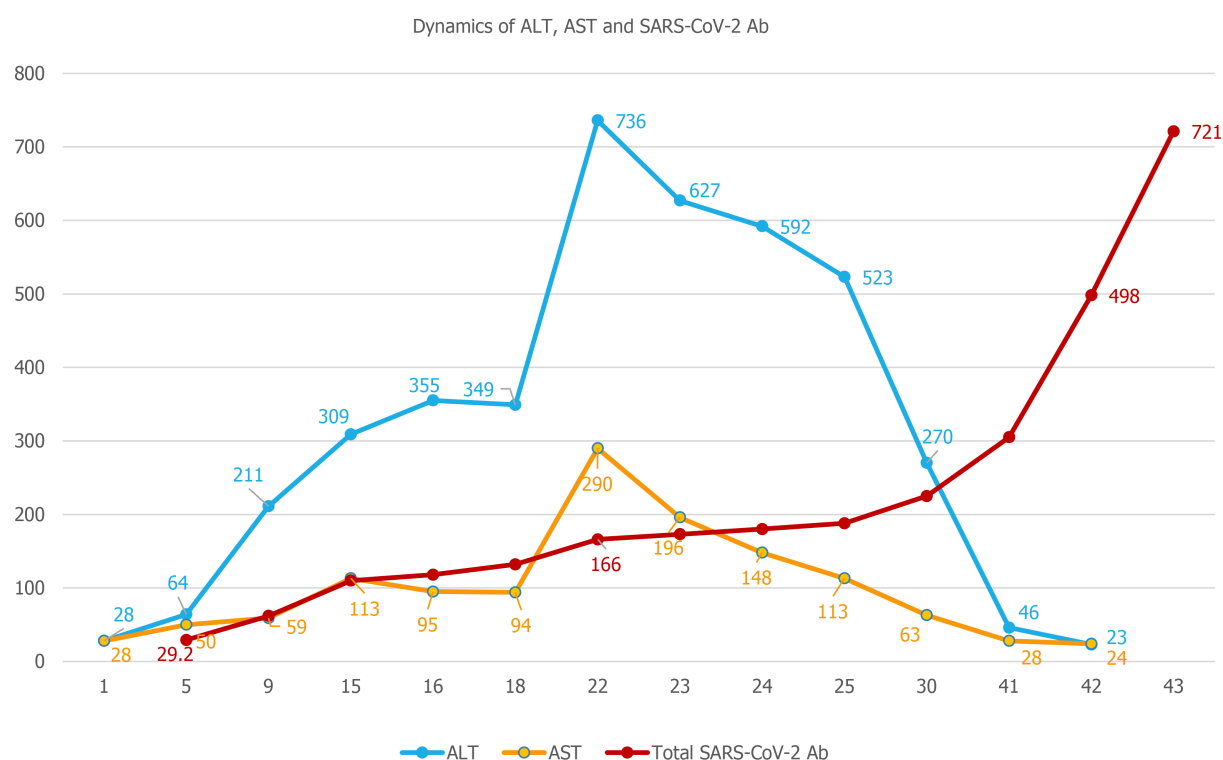
**Table 2 Differential diagnosis of hepatic cytolysis**

Hypothesis	Investigation and result
Drug-induced liver injury	No drugs recently administered
Systemic replication of SARS-CoV-2	Negative SARS-CoV-2 RT-PCR from blood and nasopharyngeal + oropharyngeal swabs
COVID-19 cytokine storm	Timing-day 24 Normal inflammatory markers Normal chest CT at baseline and on day 24
Infections with other hepatotropic viruses	Negative: HAV IgM, HBsAg, HCV Abs, HEV IgM and HEV-RNA, adenovirus IgM, coxsackie virus IgM, echo virus IgM, HSV1+2 IgM, EBV IgM, CMV IgM.
Post-COVID-19 immune hepatitis	Rapidly increasing SARS-CoV-2 antibodies (chemiluminescence)

COVID-19: Coronavirus disease-19; SARS-CoV-2: Severe acute respiratory syndrome coronavirus 2; RT-PCR: Real-time reverse transcription polymerase chain reaction; IL-6: Interleukin 6; CT: Computed tomography; HAV: Hepatitis A virus; HCV Abs: Hepatitis C virus antibodies; HEV: Hepatitis E virus; HSV: Herpes simplex virus; HBsAg: Hepatitis B surface antigen; IgM: Immunoglobulin M; EBV: Epstein-Barr virus; CMV: Cytomegalovirus.



**Figure 1 Patient evolution chart throughout the duration of hospitalization.** ALT: Alanine aminotransferase; AST: Aspartate aminotransferase; SARS-CoV-2: Severe acute respiratory syndrome coronavirus 2; RT-PCR: Real-time reverse transcription polymerase chain reaction.



**Figure 2 Dynamics of alanine aminotransferase, aspartate aminotransferase and severe acute respiratory syndrome coronavirus 2 antibodies.** ALT: Alanine aminotransferase; AST: Aspartate aminotransferase; SARS-CoV-2: Severe acute respiratory syndrome coronavirus 2.

## REFERENCES

- 1 **Yanes-Lane M**, Winters N, Fregonese F, Bastos M, Perlman-Arrow S, Campbell JR, Menzies D. Proportion of asymptomatic infection among COVID-19 positive persons and their transmission potential: A systematic review and meta-analysis. *PLoS One* 2020; **15**: e0241536 [PMID: [33141862](#) DOI: [10.1371/journal.pone.0241536](#)]
- 2 **Chaibi S**, Boussier J, Hajj WE, Abitbol Y, Taieb S, Horaist C, Jouannaud V, Wang P, Piquet J, Maurer C, Lahmek P, Nahon S. Liver function test abnormalities are associated with a poorer prognosis in Covid-19 patients: Results of a French cohort. *Clin Res Hepatol Gastroenterol* 2020; **101556** [PMID: [33139241](#) DOI: [10.1016/j.clinre.2020.10.002](#)]
- 3 **Xie H**, Zhao J, Lian N, Lin S, Xie Q, Zhuo H. Clinical characteristics of non-ICU hospitalized patients with coronavirus disease 2019 and liver injury: A retrospective study. *Liver Int* 2020; **40**: 1321-1326 [PMID: [32239591](#) DOI: [10.1111/liv.14449](#)]
- 4 **Fan Z**, Chen L, Li J, Cheng X, Yang J, Tian C, Zhang Y, Huang S, Liu Z, Cheng J. Clinical Features of COVID-19-Related Liver Functional Abnormality. *Clin Gastroenterol Hepatol* 2020; **18**: 1561-1566 [PMID: [32283325](#) DOI: [10.1016/j.cgh.2020.04.002](#)]
- 5 **Hajifathalian K**, Krisko T, Mehta A, Kumar S, Schwartz R, Fortune B, Sharaiha RZ; WCM-GI research group\*. Gastrointestinal and Hepatic Manifestations of 2019 Novel Coronavirus Disease in a Large Cohort of Infected Patients From New York: Clinical Implications. *Gastroenterology* 2020; **159**: 1137-1140. e2 [PMID: [32389667](#) DOI: [10.1053/j.gastro.2020.05.010](#)]
- 6 **Del Zompo F**, De Siena M, Ianiro G, Gasbarrini A, Pompili M, Ponziani FR. Prevalence of liver injury and correlation with clinical outcomes in patients with COVID-19: systematic review with meta-analysis. *Eur Rev Med Pharmacol Sci* 2020; **24**: 13072-13088 [PMID: [33378061](#) DOI: [10.26355/eurrev\\_202012\\_24215](#)]
- 7 **Bai Y**, Xu J, Chen L, Fu C, Kang Y, Zhang W, Fakhri GE, Gu J, Shao F, Wang M. Inflammatory response in lungs and extrapulmonary sites detected by [ $^{18}$ F] fluorodeoxyglucose PET/CT in convalescing COVID-19 patients tested negative for coronavirus. *Eur J Nucl Med Mol Imaging* 2021 [PMID: [33420914](#) DOI: [10.1007/s00259-020-05083-4](#)]



Published by **Baishideng Publishing Group Inc**  
7041 Koll Center Parkway, Suite 160, Pleasanton, CA 94566, USA

**Telephone:** +1-925-3991568

**E-mail:** [bpgoffice@wjgnet.com](mailto:bpgoffice@wjgnet.com)

**Help Desk:** <https://www.f6publishing.com/helpdesk>

<https://www.wjgnet.com>

