

World Journal of *Clinical Cases*

World J Clin Cases 2021 June 6; 9(16): 3796-4115



Contents

Thrice Monthly Volume 9 Number 16 June 6, 2021

REVIEW

- 3796 COVID-19 and the digestive system: A comprehensive review
Wang MK, Yue HY, Cai J, Zhai YJ, Peng JH, Hui JF, Hou DY, Li WP, Yang JS

MINIREVIEWS

- 3814 COVID-19 impact on the liver
Baroiu L, Dumitru C, Iancu A, Leşe AC, Drăgănescu M, Baroiu N, Anghel L
- 3826 Xenogeneic stem cell transplantation: Research progress and clinical prospects
Jiang LL, Li H, Liu L

ORIGINAL ARTICLE

Case Control Study

- 3838 Histopathological classification and follow-up analysis of chronic atrophic gastritis
Wang YK, Shen L, Yun T, Yang BF, Zhu CY, Wang SN

Retrospective Study

- 3848 Effectiveness of sharp recanalization of superior vena cava-right atrium junction occlusion
Wu XW, Zhao XY, Li X, Li JX, Liu ZY, Huang Z, Zhang L, Sima CY, Huang Y, Chen L, Zhou S
- 3858 Management and outcomes of surgical patients with intestinal Behçet's disease and Crohn's disease in southwest China
Zeng L, Meng WJ, Wen ZH, Chen YL, Wang YF, Tang CW
- 3869 Clinical and radiological outcomes of dynamic cervical implant arthroplasty: A 5-year follow-up
Zou L, Rong X, Liu XJ, Liu H

Observational Study

- 3880 Differential analysis revealing APOC1 to be a diagnostic and prognostic marker for liver metastases of colorectal cancer
Shen HY, Wei FZ, Liu Q

Randomized Clinical Trial

- 3895 Comparison of white-light endoscopy, optical-enhanced and acetic-acid magnifying endoscopy for detecting gastric intestinal metaplasia: A randomized trial
Song YH, Xu LD, Xing MX, Li KK, Xiao XG, Zhang Y, Li L, Xiao YJ, Qu YL, Wu HL

CASE REPORT

- 3908** Snapping wrist due to bony prominence and tenosynovitis of the first extensor compartment: A case report
Hu CJ, Chow PC, Tzeng IS
- 3914** Massive retroperitoneal hematoma as an acute complication of retrograde intrarenal surgery: A case report
Choi T, Choi J, Min GE, Lee DG
- 3919** Internal fixation and unicompartmental knee arthroplasty for an elderly patient with patellar fracture and anteromedial osteoarthritis: A case report
Nan SK, Li HF, Zhang D, Lin JN, Hou LS
- 3927** Haemangiomas in the urinary bladder: Two case reports
Zhao GC, Ke CX
- 3936** Endoscopic diagnosis and treatment of an appendiceal mucocele: A case report
Wang TT, He JJ, Zhou PH, Chen WW, Chen CW, Liu J
- 3943** Diagnosis and spontaneous healing of asymptomatic renal allograft extra-renal pseudo-aneurysm: A case report
Xu RF, He EH, Yi ZX, Li L, Lin J, Qian LX
- 3951** Rehabilitation and pharmacotherapy of neuromyelitis optica spectrum disorder: A case report
Wang XJ, Xia P, Yang T, Cheng K, Chen AL, Li XP
- 3960** Undifferentiated intimal sarcoma of the pulmonary artery: A case report
Li X, Hong L, Huo XY
- 3966** Chest pain in a heart transplant recipient: A case report
Chen YJ, Tsai CS, Huang TW
- 3971** Successful management of therapy-refractory pseudoachalasia after Ivor Lewis esophagectomy by bypassing colonic pull-up: A case report
Flemming S, Lock JF, Hankir M, Reimer S, Petritsch B, Germer CT, Seyfried F
- 3979** Old unreduced obturator dislocation of the hip: A case report
Li WZ, Wang JJ, Ni JD, Song DY, Ding ML, Huang J, He GX
- 3988** Laterally spreading tumor-like primary rectal mucosa-associated lymphoid tissue lymphoma: A case report
Wei YL, Min CC, Ren LL, Xu S, Chen YQ, Zhang Q, Zhao WJ, Zhang CP, Yin XY
- 3996** Coronary artery aneurysm combined with myocardial bridge: A case report
Ye Z, Dong XF, Yan YM, Luo YK
- 4001** Thoracoscopic diagnosis of traumatic pericardial rupture with cardiac hernia: A case report
Wu YY, He ZL, Lu ZY

- 4007** Delayed diagnosis and comprehensive treatment of cutaneous tuberculosis: A case report
Gao LJ, Huang ZH, Jin QY, Zhang GY, Gao MX, Qian JY, Zhu SX, Yu Y
- 4016** Rapidly progressing primary pulmonary lymphoma masquerading as lung infectious disease: A case report and review of the literature
Jiang JH, Zhang CL, Wu QL, Liu YH, Wang XQ, Wang XL, Fang BM
- 4024** Asymptomatic carbon dioxide embolism during transoral vestibular thyroidectomy: A case report
Tang JX, Wang L, Nian WQ, Tang WY, Xiao JY, Tang XX, Liu HL
- 4032** Transient immune hepatitis as post-coronavirus disease complication: A case report
Drăgănescu AC, Săndulescu O, Bilașco A, Kouris C, Streinu-Cercel A, Luminos M, Streinu-Cercel A
- 4040** Acute inferior myocardial infarction in a young man with testicular seminoma: A case report
Scafa-Udriste A, Popa-Fotea NM, Bataila V, Calmac L, Dorobantu M
- 4046** Asymptomatic traumatic rupture of an intracranial dermoid cyst: A case report
Zhang MH, Feng Q, Zhu HL, Lu H, Ding ZX, Feng B
- 4052** Parotid mammary analogue secretory carcinoma: A case report and review of literature
Min FH, Li J, Tao BQ, Liu HM, Yang ZJ, Chang L, Li YY, Liu YK, Qin YW, Liu WW
- 4062** Liver injury associated with the use of selective androgen receptor modulators and post-cycle therapy: Two case reports and literature review
Koller T, Vrbova P, Meciarova I, Molcan P, Smitka M, Adamcova Selcanova S, Skladany L
- 4072** Spinal epidural abscess due to coinfection of bacteria and tuberculosis: A case report
Kim C, Lee S, Kim J
- 4081** Rare complication of inflammatory bowel disease-like colitis from glycogen storage disease type 1b and its surgical management: A case report
Lui FCW, Lo OSH
- 4090** Thymosin as a possible therapeutic drug for COVID-19: A case report
Zheng QN, Xu MY, Gan FM, Ye SS, Zhao H
- 4095** Arrhythmogenic right ventricular cardiomyopathy characterized by recurrent syncope during exercise: A case report
Wu HY, Cao YW, Gao TJ, Fu JL, Liang L
- 4104** Delayed pseudoaneurysm formation of the carotid artery following the oral cavity injury in a child: A case report
Chung BH, Lee MR, Yang JD, Yu HC, Hong YT, Hwang HP
- 4110** Atezolizumab-induced anaphylactic shock in a patient with hepatocellular carcinoma undergoing immunotherapy: A case report
Bian LF, Zheng C, Shi XL

ABOUT COVER

Editorial Board Member of *World Journal of Clinical Cases*, Gwo-Ping Jong, FCCP, MD, MHSc, PhD, Associate Professor, Department of Public Health, Chung Shan Medical University, Taichung 40201, Taiwan. cgp8009@yahoo.com.tw

AIMS AND SCOPE

The primary aim of *World Journal of Clinical Cases* (WJCC, *World J Clin Cases*) is to provide scholars and readers from various fields of clinical medicine with a platform to publish high-quality clinical research articles and communicate their research findings online.

WJCC mainly publishes articles reporting research results and findings obtained in the field of clinical medicine and covering a wide range of topics, including case control studies, retrospective cohort studies, retrospective studies, clinical trials studies, observational studies, prospective studies, randomized controlled trials, randomized clinical trials, systematic reviews, meta-analysis, and case reports.

INDEXING/ABSTRACTING

The WJCC is now indexed in Science Citation Index Expanded (also known as SciSearch®), Journal Citation Reports/Science Edition, Scopus, PubMed, and PubMed Central. The 2020 Edition of Journal Citation Reports® cites the 2019 impact factor (IF) for WJCC as 1.013; IF without journal self cites: 0.991; Ranking: 120 among 165 journals in medicine, general and internal; and Quartile category: Q3. The WJCC's CiteScore for 2019 is 0.3 and Scopus CiteScore rank 2019: General Medicine is 394/529.

RESPONSIBLE EDITORS FOR THIS ISSUE

Production Editor: Yan-Xia Xing, Production Department Director: Yun-Xiaoqian Wu, Editorial Office Director: Jin-Lai Wang.

NAME OF JOURNAL

World Journal of Clinical Cases

ISSN

ISSN 2307-8960 (online)

LAUNCH DATE

April 16, 2013

FREQUENCY

Thrice Monthly

EDITORS-IN-CHIEF

Dennis A Bloomfield, Sandro Vento, Bao-Gan Peng

EDITORIAL BOARD MEMBERS

<https://www.wjgnet.com/2307-8960/editorialboard.htm>

PUBLICATION DATE

June 6, 2021

COPYRIGHT

© 2021 Baishideng Publishing Group Inc

INSTRUCTIONS TO AUTHORS

<https://www.wjgnet.com/bpg/gerinfo/204>

GUIDELINES FOR ETHICS DOCUMENTS

<https://www.wjgnet.com/bpg/GerInfo/287>

GUIDELINES FOR NON-NATIVE SPEAKERS OF ENGLISH

<https://www.wjgnet.com/bpg/gerinfo/240>

PUBLICATION ETHICS

<https://www.wjgnet.com/bpg/GerInfo/288>

PUBLICATION MISCONDUCT

<https://www.wjgnet.com/bpg/gerinfo/208>

ARTICLE PROCESSING CHARGE

<https://www.wjgnet.com/bpg/gerinfo/242>

STEPS FOR SUBMITTING MANUSCRIPTS

<https://www.wjgnet.com/bpg/GerInfo/239>

ONLINE SUBMISSION

<https://www.f6publishing.com>



Rare complication of inflammatory bowel disease-like colitis from glycogen storage disease type 1b and its surgical management: A case report

Frederick Chi-Wai Lui, Oswens Siu-Hung Lo

ORCID number: Frederick Chi-Wai Lui 0000-0003-1809-4124; Oswens Siu-Hung Lo 0000-0002-1472-382X.

Author contributions: Lui FCW was responsible for drafting and revision of the manuscript, review of the literature, photos and tables editing and inpatient care of the patient; Lo OSH was the operating surgeon, responsible for the inpatient care and outpatient follow-up of the patient, and for the drafting and revision of the manuscript for important intellectual content; issued the final approval for the version to be submitted.

Informed consent statement:

Informed written consent was obtained from the patient for publication of this report and any accompanying images.

Conflict-of-interest statement: The authors declare that they have no conflict of interest.

CARE Checklist (2016) statement:

The authors have read the CARE Checklist (2016), and the manuscript was prepared and revised according to the CARE Checklist (2016).

Open-Access: This article is an open-access article that was

Frederick Chi-Wai Lui, Oswens Siu-Hung Lo, Department of Surgery, LKS Faculty of Medicine, The University of Hong Kong, Hong Kong, China

Corresponding author: Oswens Siu-Hung Lo, FRCS (Ed), MBBS, Surgeon, Department of Surgery, LKS Faculty of Medicine, The University of Hong Kong, No. 102 Pokfulam Road, Hong Kong, China. oswens@hku.hk

Abstract

BACKGROUND

Glycogen storage disease (GSD) is an autosomal recessive inborn metabolic disorder. Patients with GSD are prone to hypoglycaemia, hyperlactacidemia and bleeding. GSD type 1b (GSD-1b) patients specifically can develop neutropenia, recurrent bacterial infection and inflammatory bowel disease (IBD). Documentation of the long-term outcomes of surgical management of GSD-1b has been scarce, especially for Asian patients. We herein describe a case of GSD-1b complicated by IBD-like colitis and coloduodenal fistula. The patient was managed successfully with surgical intervention.

CASE SUMMARY

A 20-year-old Chinese lady confirmed by genetic testing to have GSD-1b was initially managed with uncooked cornstarch and granulocyte-colony stimulating factor. With recurrent abdominal symptoms, her condition was treated as clinical "Crohn's disease" with mesalazine, prednisolone and azathioprine conservatively. Colonoscopy showed a tight stricture at the hepatic flexure. Subsequent computerized tomographic colonography revealed a phlegmon at the ileocaecal region with a suspected coloduodenal fistula. Eventually an exploratory laparotomy was performed and severe colitis at the ascending colon with coloduodenal fistula was confirmed. Right hemicolectomy with primary anastomosis and repair of the duodenum were performed. Surgical management of complications from GSD-1b associated IBD-like colitis has rarely been described. First-line treatment would usually be conservative. Surgical intervention like hemicolectomy is mainly reserved for refractory cases.

CONCLUSION

Surgical management of coloduodenal fistula in GSD-1b patients is a feasible and safe option when failed conservative management.

selected by an in-house editor and fully peer-reviewed by external reviewers. It is distributed in accordance with the Creative Commons Attribution NonCommercial (CC BY-NC 4.0) license, which permits others to distribute, remix, adapt, build upon this work non-commercially, and license their derivative works on different terms, provided the original work is properly cited and the use is non-commercial. See: <http://creativecommons.org/licenses/by-nc/4.0/>

Manuscript source: Unsolicited manuscript

Specialty type: Surgery

Country/Territory of origin: China

Peer-review report's scientific quality classification

Grade A (Excellent): 0
Grade B (Very good): 2
Grade C (Good): 0
Grade D (Fair): 0
Grade E (Poor): 0

Received: January 31, 2021

Peer-review started: January 31, 2021

First decision: February 22, 2021

Revised: March 10, 2021

Accepted: March 24, 2021

Article in press: March 24, 2021

Published online: June 6, 2021

P-Reviewer: Wattanasirichaigoon D

S-Editor: Zhang H

L-Editor: A

P-Editor: Yuan YY



Key Words: Glycogen storage disease; Coloduodenal fistula; Inflammatory bowel disease-like colitis; Case report; Perioperative management

©The Author(s) 2021. Published by Baishideng Publishing Group Inc. All rights reserved.

Core Tip: Inflammatory bowel disease-like colitis is associated with a few rare genetic disorders or certain drug use. First-line treatment is usually conservative with nutritional support or steroids. Granulocyte-colony stimulating factor or immunosuppressant may be beneficial. Surgical intervention like hemicolectomy is mainly reserved for refractory cases with intestinal obstruction resistant to medical treatment.

Citation: Lui FCW, Lo OSH. Rare complication of inflammatory bowel disease-like colitis from glycogen storage disease type 1b and its surgical management: A case report. *World J Clin Cases* 2021; 9(16): 4081-4089

URL: <https://www.wjgnet.com/2307-8960/full/v9/i16/4081.htm>

DOI: <https://dx.doi.org/10.12998/wjcc.v9.i16.4081>

INTRODUCTION

Glycogen storage disease (GSD) is an autosomal recessive inborn metabolic disorder featured by the defects in the glucose-6-phosphatase (G6Pase) complex. Due to the deficiency of G6Pase activity in the liver, kidneys and intestine, patients are prone to over accumulation of glycogen in these organs and corresponding hypoglycaemia. Secondary metabolic and biochemical changes include hyperlactacidemia, hyperuricaemia and hyperlipidaemia. Hepatomegaly, short stature, truncal obesity, and bleeding tendency due to platelet dysfunction can also occur. Classical clinical presentations specific to GSD type 1b (GSD-1b) patients include neutropenia, neutrophil dysfunction, recurrent bacterial infection and inflammatory bowel disease (IBD)[1,2]. Documentation of the long-term outcomes of surgical management of GSD-1b, especially in Asian patients, has been scarce. Large studies on the topic are also lacking. We herein describe a case of GSD-1b complicated by IBD-like colitis and coloduodenal fistula. The patient was managed successfully with surgical intervention.

CASE PRESENTATION

Chief complaints

The patient presented to our clinic with recurrent abdominal pain and subtle bowel obstruction.

History of present illness

She presented to our clinic with recurrent abdominal pain, vomiting and passage of loose stool for two years.

History of past illness

The patient, born in mainland China, started developing hepatosplenomegaly, hypoglycaemia and seizure attacks at one month of age. The diagnosis of GSD was suspected in China as blood tests showed lactic acidosis and hyperuricaemia. Her hypoglycemic symptom was managed with frequent meals and dietary modification with uncooked cornstarch (UCCH). During childhood, she developed growth retardation, recurrent abdominal pain and neutropenia [absolute neutrophil count (ANC): $0.95 \times 10^9/L$]. Details of her treatment in early childhood in China was lacking as the patient was grown up in rural areas. No definitive workup or diagnosis for IBD was documented. At age 11, she was confirmed by genetic testing to have GSD-1b and given granulocyte-colony stimulating factor (G-CSF) injections for neutropenia.

She was firstly seen in Hong Kong at age 12 with chronic diarrhea and associated with perianal fissure. Colonoscopy revealed an ulcer near the hepatic flexure and the histology did not show granulomatous changes. Gastrografin follow-through study did not suggest any small bowel pathology but luminal narrowing in the ascending colon (Figure 1). Contrast computerized tomography (CT) of the abdomen and pelvis noted severe inflammatory changes at the ascending colon and terminal ileum, with enlarged pericolic lymph nodes. Therefore, her condition was treated clinically as Crohn's disease with mesalazine, prednisolone and azathioprine. The condition gradually improved and she was followed up at the paediatric metabolic clinic. G-CSF injections were regularly given for her neutropenia. With good compliance with her UCCH diet, she managed to wean off her azathioprine and oral steroid six months later. Follow-up colonoscopy did not show any mucosal lesion while upper endoscopy showed duodenitis only.

Personal and family history

There was no family history of glycogen storage disease or IBD.

Physical examination

Physical examination showed soft abdomen but not distended. She had hepatosplenomegaly and hyperactive bowel sound. Per rectal examination showed no stigmata of IBD.

Laboratory examinations

She had neutropenia (ANC: $1.43 \times 10^9/L$) and hyperuricaemia (465 $\mu\text{mol/L}$). Stool calprotectin was found to be significantly elevated (977 $\mu\text{g/g}$). Magnetic resonance enteroclysis revealed abnormal bowel wall thickening and stricture with hyperenhancement at the ileocaecal region (Figure 2).

Imaging examinations

Colonoscopy showed a colonic stricture beyond the hepatic flexure (Figure 3). Biopsy from the stricture revealed mild colitis without cryptitis, granuloma or viral inclusion. Upper endoscopy demonstrated chronic gastritis and duodenitis. CT colonography demonstrated a suspected fistula tract between the caecum and the second and third parts of the duodenum (Figure 4).

G-CSF, iron supplement and allopurinol were recommended for the flare-up of colitis. Compliance with UCCH diet was emphasized. However, the bowel symptom was partially responsive to conservative treatment and the patient was repeatedly admitted for intestinal obstruction in the subsequent 6 mo. At the end, she agreed for exploratory laparotomy because of progressive abdominal pain and vomiting.

FINAL DIAGNOSIS

GSD-1b disease.

TREATMENT

Exploratory laparotomy was performed *via* a midline incision. A phlegmon was noticed at the ileocaecal region with grossly dilated small bowel adhering to the right colon (Figure 5). The caecum was found lying in the right upper quadrant and a fistulation was seen over the third part of the duodenum. Right hemicolectomy was performed with a side-to-side hand-sewn ileocolic anastomosis. After Kocherization of the duodenum, the fibrotic edge of the duodenal fistula tract was trimmed and then primarily closed with 4/0 monofilament absorbable suture in a two-layer continuous manner.

OUTCOME AND FOLLOW-UP

Postoperatively, total parenteral nutrition was continued, and blood lactate level was closely monitored to avoid hypoglycemia and lactic acidosis respectively. Oral diet was started after a normal Gastrografin meal study one week after the operation. The

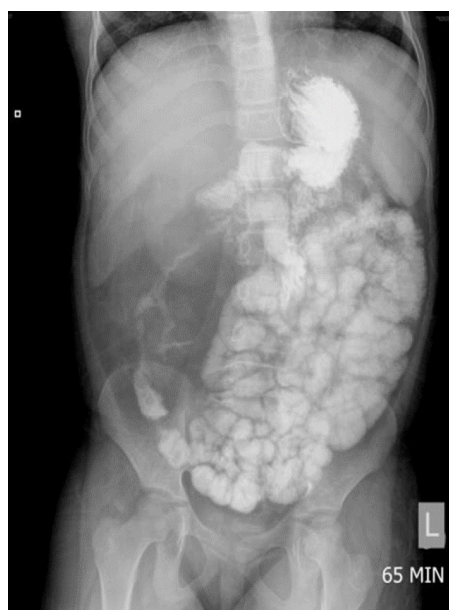

Figure 1 Contrast small bowel follow-through showing stricture right colon.

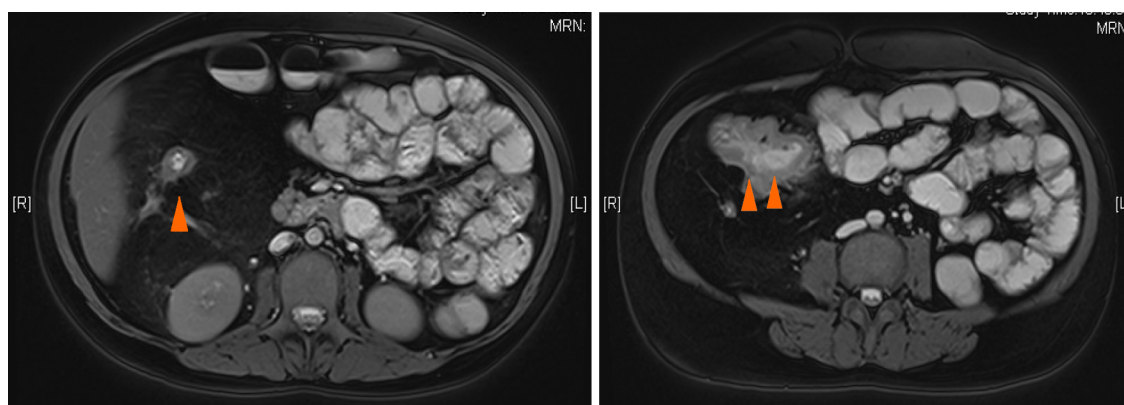


Figure 2 Magnetic resonance enteroclysis showing strictured hepatic flexure (single arrowhead) and thickened ascending colon (double arrowheads).

patient was discharged uneventfully three weeks later. Pathology showed transmural fibrosis with colonic stricture and no malignancy or granuloma. During her follow-up, G-CSF was resumed for her neutropenia and she would be seen at an adult metabolic clinic with expertise in managing patients with inborn errors of metabolism.

DISCUSSION

The medical and surgical management of our patient with a long history of GSD-1b complicated by colitis and resultant coloduodenal fistula was delineated in this review. This is one of the first reported cases in the Asian population with similar pathology.

Classical GSD-1b patients presented at a median age of 4 month, with features including protruding abdomen (83%), growth retardation (25%) and recurrent infection (41%)[3]. Our patient was diagnosed within the first year of life and developed recurrent abdominal pain in primary school years. According to the literature, the average age at first diagnosis of IBD in GSD-1b patients was 8.7 years[2]. As many as 90% of GSD-1b patients with IBD had abdominal pain or intestinal obstructive symptoms, 60% had ileal or colonic stricture, and 50% required surgical resection or endoscopic dilatation.

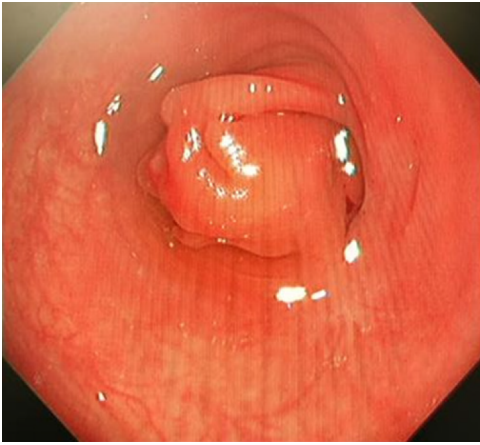


Figure 3 Colonoscopy showing the colonic stricture at hepatic flexure.

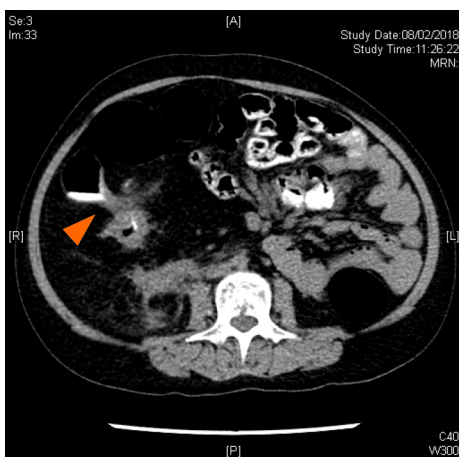


Figure 4 Computerized tomography colonography showing the coloduodenal fistula (arrowhead).

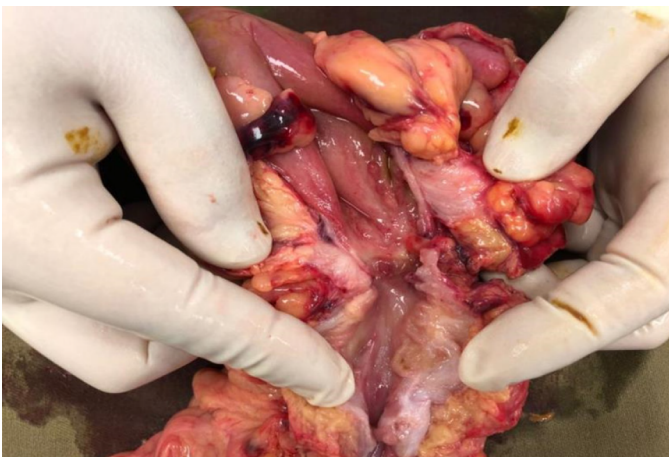


Figure 5 Hemicolectomy specimen showing the colonic stricture causing coloduodenal fistula.

Although there was no definite pathological evidence of Crohn's disease such as granuloma formation or crypt abscess, clinically and biochemically our patient exhibited some typical features of Crohn's disease including relapsing abdominal pain, fever, perianal disease and raised stool calprotectin. A possible differential diagnosis accounting for her symptoms and pathological findings would be chronic IBD-like colitis. IBD-like colitis has been known to be associated with GSD-1b and well described in the literature[4]. It can be associated with features like neutropenia and

circumferential ulcers on colonoscopy. The mean age at onset of bowel symptoms was reported to be 12.3 years. Histopathology usually shows nonspecific inflammation without granulomatous lesions, as in the case of our patient. Neutropenia associated with intestinal mucosal inflammation may contribute to the pathogenesis. Treatment, hence, is usually by high-dose G-CSF and sulfasalazine[5,6]. Volz *et al*[7] gave high-dose G-CSF (30 million IU/d) for five weeks to a young patient with IBD-like colitis and GSD-1b. The neutropenia was successfully corrected, and the C-reactive protein and calprotectin levels were normalized. Repeated colonoscopy, however, revealed progressive stricture and scarring stenosis and the patient eventually required surgical resection. Saltik-Temizel *et al*[8] reported the case of a 3-year-old girl with GSD-1b and IBD-like colitis successfully treated with G-CSF. It has been speculated that raised platelet count is an early marker of IBD-like colitis, but the exact pathogenesis is unclear. The relationship between platelet count and colitis remains uncertain. In our patient, platelet count was not persistently raised (*i.e.*, $117\text{--}538 \times 10^9/\text{L}$).

Xiao[9] recently reported that two patients with GSD-1b and IBD-like colitis were treated conservatively with G-CSF, partial enteral nutrition and mesalazine and no surgical intervention was required. In a retrospective study[10], nine French patients with mild to severe digestive complications from GSD-1b and IBD-associated colitis were treated with a variable combination of G-CSF, cotrimoxazole, corticosteroids, 5-aminosalicylic acid and infliximab without surgical intervention. The authors suggested that the addition of a polymeric formula enriched in anti-inflammatory cytokine transforming growth factor-beta (Modulen IBD®) might have positive effects on metabolic balance and help to improve digestive symptoms.

Reports of the surgical management of patients with GSD-1b complicated by colitis and coloduodenal fistula are rare and mostly case reports[4,11]. For our patient, we performed primary excision of the coloduodenal fistula followed by primary repair of the duodenal defect. Delayed surgical exploration after repeated colitis episodes and adhesion formation had resulted in the distorted anatomy adjacent to her coloduodenal fistula, which imposed technical difficulty during dissection. Intraoperatively, both the second and third parts of the duodenum were involved by the coloduodenal fistula. This finding was consistent with the results in a study by Kamath *et al*[12], who reviewed 22 patients with coloduodenal fistula over a period of 30 years. In these 22 patients, 14 patients had a benign cause either secondary to Crohn's disease or peptic ulcer. Among the 13 patients who had resection, two required a duodenal bypass. The postoperative morbidity rate was 38%. Only one out of the 13 patients had recurrence of fistulation. The second part of duodenum was most involved (64%), followed by the third part (50%) and then the first part (18%). No major postoperative complication was seen in our patient, suggesting that primary duodenal repair is a safe option[13].

As our patient was at risk of hypoglycemia, particular attention was paid to maximize the perioperative glycemic control, including the use of intravenous dextrose and frequent hemastix monitoring. Optimizing glycemic control not only promotes optimal tissue healing but also can minimize wound complications and infection risks.

Our patient was given G-CSF perioperatively and her neutropenia was fully corrected prior to her emergency operation. She required postoperative blood transfusion but experienced no other major morbidities or surgical site infections. In a report, 98% of GSD-1b patients had neutropenia at some time[4]. Filgrastim, an unglycosylated recombinant G-CSF, has been studied and proved to be efficacious in enhancing neutrophil production and promoting regression of IBD[5,14]. High vigilance and thorough precaution are important in perioperative planning for patients with neutropenia[15]. The decision for the best timing of surgery for our patient therefore necessitated a fine balance between the optimization of her infectious risks and the urgency of her clinical symptoms and rate of disease progression.

Apart from GSD-1b, little evidence or description about the surgical management of IBD-like colitis associated with other etiologies is available in the literature. Common causes of IBD-like colitis are listed in Table 1 and a summary of the studies reviewed is delineated in Table 2 below. Dubeau *et al*[16] described the etiology of drug-induced IBD-like colitis and medications for the condition but no details of its surgical management. Specifically, IBD-like colitis was also found to be associated with mycophenolic acid (MPA) use in renal transplant recipients[17]. In patients with MPA-related colitis who underwent colonoscopy, the most frequent histologic pattern was non-specific colitis (31.3%), followed by IBD-like colitis (25%) and then other pathologies. Clinically, MPA-related diarrhea resolved after MPA switch, reduction, or discontinuation without the need for operation. Bolton *et al*[18] recently described a patient with IBD-like colitis secondary to a homozygous variant/mutation in the G6Pase G6PC3 gene. The colitis was refractory to medical therapy. The patient

Table 1 Causes of inflammatory bowel disease-like colitis

Drug-induced [16,17]
Mycophenolic acid
Isotretinoin
Antibiotics
Nonsteroidal antiinflammatory drugs
Oral contraceptives
Etanercept, ipilimumab, and rituximab
Genetic mutations [18,19]
Homozygous variant/mutation in the G6Pase <i>G6PC3</i> gene
Congenital chloride diarrhoea (<i>SLC26A3</i> gene mutation)
Primary immunodeficiencies [20,21]
Antibody deficiency (common variable immunodeficiency, severe combined immunodeficiency, agammaglobulinemia, <i>etc.</i>)
Phagocytes defect (<i>G6PC3</i> deficiency)
Complement deficiency
Immune dysregulation
Immune deficiency + syndromic features
CD4 lymphopenia

G6Pase: Glucose-6-phosphatase.

underwent allogenic stem cell transplantation and saw significant improvement in obstructive symptoms and biochemical parameters. Norsa *et al*[19] described a rare cause of IBD-like colitis, which is congenital chloride diarrhoea, a rare autosomal recessive disease secondary to *SLC26A3* gene mutation. Among the twelve patients with IBD or IBD-like colitis, two were treated with 5-aminosalicylate acid, three with immunosuppressants and six with biologics.

IBD-like colitis associated with primary immunodeficiencies was studied by Akkelle *et al*[20]. Multiple genetic causes including glucose-6-phosphatase catalytic subunit 3 deficiency, common variable immunodeficiency and severe combined immunodeficiency were identified. Twelve patients with primary immunodeficiencies had colitis or enteropathy. One patient with recurrent subtotal intestinal obstruction secondary to inflamed stricture in the hepatic flexure underwent hemicolectomy. Another patient with chronic diarrhea, hypoalbuminemia and intestinal obstruction refractory to conventional immunosuppressive treatment also required operative management. IBD-like colitis can also be an unusual presentation in patients with X-linked agammaglobulinemia due to a reduction of B cells, like the case reported by Kamdar *et al*[21]. Treatment is primarily conservative with steroids and enteral feeding.

CONCLUSION

IBD-like colitis is associated with a few rare genetic disorders or certain drug use. First-line treatment is usually conservative with nutritional support or steroids. G-CSF or immunosuppressants may be beneficial. Surgical intervention like hemicolectomy is mainly reserved for refractory cases with intestinal obstruction resistant to medical treatment.

Table 2 Literature review on surgical management of other inflammatory bowel disease-like colitis

Author, yr	n	Treatment	Results	Discussion
Bolton <i>et al</i> [18], 2020	1	Allogeneic HSCT	HSCT resolves G6PC3-associated immunodeficiency and Crohn's disease phenotype	
Wicker <i>et al</i> [10], 2020	9	G-CSF and cotrimoxazole; polymeric solution enriched in anti-inflammatory cytokine	Modulen IBD®, in addition to G-CSF and anti-biophrophylaxis, improves digestive symptoms	Dietetic treatment improved metabolic balance and clinical symptoms
Norsa <i>et al</i> [19], 2019	12 (2 patients with IBD-like colitis)	ASA; immuno-suppressant and biologics; ileostomy/colectomy	Treatment included a wide range of conservative treatment and ileostomy with variable success	
Xiao[9], 2019	2	PEN, mesalazine, and recombinant human G-CSF	G-CSF increased ANC and improved clinical symptoms	G-CSF lowered the risk of developing IBD-colitis
Akkelle <i>et al</i> [20], 2018	425 (195 with GI symptoms)	Conventional immunosuppressive treatment, hematopoietic stem cell transplantation, hemicolectomy	Twelve patients (aged 9-16) had immunodeficiency associated IBD-like colitis.	Surgery was indicated if immune-therapy failed
de Andrade <i>et al</i> [17], 2014	16	MPA switch, reduction, or discontinuation	IIBD-like colitis found in 25% of patients on MPA who underwent colonoscopy	Symptoms resolved after MPA switch or adjustment without need for surgery
Dubeau, <i>et al</i> [16], 2013			Drugs including isotretinoin, antibiotics, nonsteroidal anti-inflammatory drugs may predispose IBD or IBD-like colitis	Pathogenic mechanisms may include altered immune response or microbiota
Kamdar <i>et al</i> [21], 2011	1	Steroids and enteral feeding	Primarily conservative treatment usually sufficient without need for surgery	

HSCT: Hematopoietic stem cell transplant; ASA: Amino salicylate acid; PEN: Partial enteral nutrition; G-CSF: Granulocyte colony-stimulating factor; MPA: Mycophenolate; IBD: Inflammatory bowel disease.

REFERENCES

- Visser G, Rake JP, Fernandes J, Labrune P, Leonard JV, Moses S, Ullrich K, Smit GP. Neutropenia, neutrophil dysfunction, and inflammatory bowel disease in glycogen storage disease type Ib: results of the European Study on Glycogen Storage Disease type I. *J Pediatr* 2000; **137**: 187-191 [PMID: 10931410 DOI: 10.1067/mpd.2000.105232]
- Dieckgraefe BK, Korzenik JR, Husain A, Dieruf L. Association of glycogen storage disease 1b and Crohn disease: results of a North American survey. *Eur J Pediatr* 2002; **161** Suppl 1: S88-S92 [PMID: 12373579 DOI: 10.1007/s00431-002-1011-z]
- Rake JP, Visser G, Labrune P, Leonard JV, Ullrich K, Smit GP; European Study on Glycogen Storage Disease Type I (ESGSD I). Guidelines for management of glycogen storage disease type I - European Study on Glycogen Storage Disease Type I (ESGSD I). *Eur J Pediatr* 2002; **161** Suppl 1: S112-S119 [PMID: 12373584 DOI: 10.1007/s00431-002-1016-7]
- Yamaguchi T, Ihara K, Matsumoto T, Tsutsumi Y, Nomura A, Ohga S, Hara T. Inflammatory bowel disease-like colitis in glycogen storage disease type 1b. *Inflamm Bowel Dis* 2001; **7**: 128-132 [PMID: 11383585 DOI: 10.1097/00054725-200105000-00008]
- Visser G, Rake JP, Labrune P, Leonard JV, Moses S, Ullrich K, Wendel U, Groenier KH, Smit GP. Granulocyte colony-stimulating factor in glycogen storage disease type 1b. Results of the European Study on Glycogen Storage Disease Type 1. *Eur J Pediatr* 2002; **161** Suppl 1: S83-S87 [PMID: 12373578 DOI: 10.1007/s00431-002-1010-0]
- Alsultan A, Sokol RJ, Lovell MA, Thurman G, Ambruso DR. Long term G-CSF-induced remission of ulcerative colitis-like inflammatory bowel disease in a patient with glycogen storage disease Ib and evaluation of associated neutrophil function. *Pediatr Blood Cancer* 2010; **55**: 1410-1413 [PMID: 20830779 DOI: 10.1002/pbc.22706]
- Volz MS, Nassir M, Treese C, von Winterfeld M, Plöckinger U, Epple HJ, Siegmund B. Inflammatory bowel disease (IBD)-like disease in a case of a 33-year old man with glycogenosis 1b. *BMC Gastroenterol* 2015; **15**: 45 [PMID: 25881301 DOI: 10.1186/s12876-015-0271-9]
- Saltik-Temizel IN, Koçak N, Ozen H, Yüce A, Gürakan F, Demir H. Inflammatory bowel disease-like colitis in a young Turkish child with glycogen storage disease type 1b and elevated platelet count. *Turk J Pediatr* 2005; **47**: 180-182 [PMID: 16052862]
- Xiao Y. Two cases of GSD Ib complicated with Crohn-like colitis. *J Pediatr Gastr Nutr* 2019; **68**: 642
- Wicker C, Roda C, Perry A, Arnoux JB, Brassier A, Castelle M, Servais A, Donadieu J, Bouchereau J, Pigneur B, Labrune P, Ruemmele FM, de Lonlay P. Infectious and digestive complications in glycogen storage disease type 1b: Study of a French cohort. *Mol Genet Metab Rep* 2020; **23**: 100581 [PMID: 32300528 DOI: 10.1016/j.ymgmr.2020.100581]

- 11 **El-Hajj II**, Abdul-Baki H, El-Zahabi LM, Barada KA. Primary coloduodenal fistula in Crohn's disease. *Dig Dis Sci* 2007; **52**: 59-63 [PMID: [17180466](#) DOI: [10.1007/s10620-006-9227-9](#)]
- 12 **Kamath AS**, Iqbal CW, Pham TH, Wolff BG, Chua HK, Donohue JH, Cima RR, Devine RM. Management and outcomes of primary coloduodenal fistulas. *J Gastrointest Surg* 2011; **15**: 1706-1711 [PMID: [21826549](#) DOI: [10.1007/s11605-011-1630-7](#)]
- 13 **Gong J**, Wei Y, Gu L, Li Y, Guo Z, Sun J, Ding C, Zhu W, Li N, Li J. Outcome of Surgery for Coloduodenal Fistula in Crohn's Disease. *J Gastrointest Surg* 2016; **20**: 976-984 [PMID: [26718702](#) DOI: [10.1007/s11605-015-3065-z](#)]
- 14 **Visser G**, Rake JP, Labrune P, Leonard JV, Moses S, Ullrich K, Wendel U, Smit GP; European Study on Glycogen Storage Disease Type I. Consensus guidelines for management of glycogen storage disease type 1b - European Study on Glycogen Storage Disease Type 1. *Eur J Pediatr* 2002; **161** Suppl 1: S120-S123 [PMID: [12373585](#) DOI: [10.1007/s00431-002-1017-6](#)]
- 15 **Jolissaint JS**, Harary M, Saadat LV, Madenci AL, Dieffenbach BV, Al Natour RH, Tavakkoli A. Timing and Outcomes of Abdominal Surgery in Neutropenic Patients. *J Gastrointest Surg* 2019; **23**: 643-650 [PMID: [30659440](#) DOI: [10.1007/s11605-018-04081-0](#)]
- 16 **Dubeau MF**, Iacucci M, Beck PL, Moran GW, Kaplan GG, Ghosh S, Panaccione R. Drug-induced inflammatory bowel disease and IBD-like conditions. *Inflamm Bowel Dis* 2013; **19**: 445-456 [PMID: [22573536](#) DOI: [10.1002/ibd.22990](#)]
- 17 **de Andrade LG**, Rodrigues MA, Romeiro FG, Garcia PD, Contti MM, de Carvalho MF. Clinicopathologic features and outcome of mycophenolate-induced colitis in renal transplant recipients. *Clin Transplant* 2014; **28**: 1244-1248 [PMID: [25142167](#) DOI: [10.1111/ctr.12452](#)]
- 18 **Bolton C**, Burch N, Morgan J, Harrison B, Pandey S, Pagnamenta AT; Oxford IBD cohort investigators, Taylor JC, Taylor JM, Marsh JCW, Potter V, Travis S, Uhlig HH. Remission of Inflammatory Bowel Disease in Glucose-6-Phosphatase 3 Deficiency by Allogeneic Haematopoietic Stem Cell Transplantation. *J Crohns Colitis* 2020; **14**: 142-147 [PMID: [31157858](#) DOI: [10.1093/ecco-jcc/jjz112](#)]
- 19 **Norsa L**, Canani RB, Duclaux-Loras R, Bequet E, Koeglmeier J, Russell R, Uhlig H, Koletzko S, Deflandre J, Neil S, Rodrigues A, Heinz-Erian P, Janecke AR, Lachaux A, Kolho KL and Ruemmele F. Congenital Chloride Diarrhea and Inflammatory Bowel Disease: An Emerging Association. *J Pediatr Gastr Nutr* 2019; **68**: 577
- 20 **Akkelle BS**, Tutar E, Volkan B, Sengul OK, Ozen A, Celikel CA, Ertem D. Gastrointestinal Manifestations in Children with Primary Immunodeficiencies: Single Center: 12 Years Experience. *Dig Dis* 2019; **37**: 45-52 [PMID: [30153682](#) DOI: [10.1159/000492569](#)]
- 21 **Kamdar TA**, Bass L, Chou P and Fuleihan R. Unusual presentation of an IBD-like colitis in X-linked agammaglobulinemia. *Ann Allergy Asthma Immunol* 2011; **107**: A91



Published by **Baishideng Publishing Group Inc**
7041 Koll Center Parkway, Suite 160, Pleasanton, CA 94566, USA

Telephone: +1-925-3991568

E-mail: bpgoffice@wjgnet.com

Help Desk: <https://www.f6publishing.com/helpdesk>

<https://www.wjgnet.com>

