

World Journal of *Clinical Cases*

World J Clin Cases 2021 June 16; 9(17): 4116-4459



Contents

Thrice Monthly Volume 9 Number 17 June 16, 2021

EDITORIAL

- 4116 Is it time to put traditional cold therapy in rehabilitation of soft-tissue injuries out to pasture?
Wang ZR, Ni GX

MINIREVIEWS

- 4123 Health-related quality of life after gastric cancer treatment in Brazil: Narrative review and reflections
Pinheiro RN, Mucci S, Zanatto RM, Picanço Junior OM, Oliveira AF, Lopes Filho GJ
- 4133 Nonalcoholic fatty liver disease and COVID-19: An epidemic that begets pandemic
Ahmed M, Ahmed MH

ORIGINAL ARTICLE

Retrospective Study

- 4143 Why MUC16 mutations lead to a better prognosis: A study based on The Cancer Genome Atlas gastric cancer cohort
Huang YJ, Cao ZF, Wang J, Yang J, Wei YJ, Tang YC, Cheng YX, Zhou J, Zhang ZX
- 4159 Design and development of a new type of phimosis dilatation retractor for children
Yue YW, Chen YW, Deng LP, Zhu HL, Feng JH
- 4166 Primary needle-knife fistulotomy for preventing post-endoscopic retrograde cholangiopancreatography pancreatitis: Importance of the endoscopist's expertise level
Han SY, Baek DH, Kim DU, Park CJ, Park YJ, Lee MW, Song GA

Observational Study

- 4178 Patients with functional bowel disorder have disaccharidase deficiency: A single-center study from Russia
Dbar S, Akhmadullina O, Sabelnikova E, Belostotskiy N, Parfenov A, Bykova S, Bakharev S, Baulo E, Babanova A, Indeykina L, Kuzmina T, Kosacheva T, Spasenov A, Makarova A
- 4188 Self-perceived burden and influencing factors in patients with cervical cancer administered with radiotherapy
Luo T, Xie RZ, Huang YX, Gong XH, Qin HY, Wu YX

SYSTEMATIC REVIEWS

- 4199 COVID-19 in gastroenterology and hepatology: Lessons learned and questions to be answered
Liu S, Tang MM, Du J, Gong ZC, Sun SS

META-ANALYSIS

- 4210 Efficacy of topical *vs* intravenous tranexamic acid in reducing blood loss and promoting wound healing in bone surgery: A systematic review and meta-analysis

Xu JW, Qiang H, Li TL, Wang Y, Wei XX, Li F

CASE REPORT

- 4221 *Ex vivo* liver resection followed by autotransplantation in radical resection of gastric cancer liver metastases: A case report

Wang H, Zhang CC, Ou YJ, Zhang LD

- 4230 Bone marrow inhibition induced by azathioprine in a patient without mutation in the thiopurine S-methyltransferase pathogenic site: A case report

Zhou XS, Lu YY, Gao YF, Shao W, Yao J

- 4238 Eosinophilic gastroenteritis with abdominal pain and ascites: A case report

Tian XQ, Chen X, Chen SL

- 4244 Tunica vaginalis testis metastasis as the first clinical manifestation of pancreatic adenocarcinoma: A case report

Zhang YR, Ma DK, Gao BS, An W, Guo KM

- 4253 “AFGP” bundles for an extremely preterm infant who underwent difficult removal of a peripherally inserted central catheter: A case report

Chen Q, Hu YL, Su SY, Huang X, Li YX

- 4262 Dynamic magnetic resonance imaging features of cavernous hemangioma in the manubrium: A case report

Lin TT, Hsu HH, Lee SC, Peng YJ, Ko KH

- 4268 Diagnosis and treatment of pediatric anaplastic lymphoma kinase-positive large B-cell lymphoma: A case report

Zhang M, Jin L, Duan YL, Yang J, Huang S, Jin M, Zhu GH, Gao C, Liu Y, Zhang N, Zhou CJ, Gao ZF, Zheng QL, Chen D, Zhang YH

- 4279 Stevens-Johnson syndrome and concurrent hand foot syndrome during treatment with capecitabine: A case report

Ahn HR, Lee SK, Youn HJ, Yun SK, Lee IJ

- 4285 Rosai-Dorfman disease with lung involvement in a 10-year-old patient: A case report

Wu GJ, Li BB, Zhu RL, Yang CJ, Chen WY

- 4294 Acute myocardial infarction in twin pregnancy after assisted reproduction: A case report

Dai NN, Zhou R, Zhuo YL, Sun L, Xiao MY, Wu SJ, Yu HX, Li QY

- 4303 Complete recovery of herpes zoster radiculopathy based on electrodiagnostic study: A case report

Kim HS, Jung JW, Jung YJ, Ro YS, Park SB, Lee KH

- 4310** Acute liver failure with thrombotic microangiopathy due to sodium valproate toxicity: A case report
Mei X, Wu HC, Ruan M, Cai LR
- 4318** Lateral epicondyle osteotomy approach for coronal shear fractures of the distal humerus: Report of three cases and review of the literature
Li J, Martin VT, Su ZW, Li DT, Zhai QY, Yu B
- 4327** Pancreatic neuroendocrine carcinoma in a pregnant woman: A case report and review of the literature
Gao LP, Kong GX, Wang X, Ma HM, Ding FF, Li TD
- 4336** Primary primitive neuroectodermal tumor in the pericardium—a focus on imaging findings: A case report
Xu SM, Bai J, Cai JH
- 4342** Minimally invasive surgery for glycogen storage disease combined with inflammatory bowel disease: A case report
Wan J, Zhang ZC, Yang MQ, Sun XM, Yin L, Chen CQ
- 4348** Coronary sinus endocarditis in a hemodialysis patient: A case report and review of literature
Hwang HJ, Kang SW
- 4357** *Clostridium perfringens* bloodstream infection secondary to acute pancreatitis: A case report
Li M, Li N
- 4365** Kidney re-transplantation after living donor graft nephrectomy due to *de novo* chromophobe renal cell carcinoma: A case report
Wang H, Song WL, Cai WJ, Feng G, Fu YX
- 4373** Pelvic lipomatosis with cystitis glandularis managed with cyclooxygenase-2 inhibitor: A case report
Mo LC, Piao SZ, Zheng HH, Hong T, Feng Q, Ke M
- 4381** Prone position combined with high-flow nasal oxygen could benefit spontaneously breathing, severe COVID-19 patients: A case report
Xu DW, Li GL, Zhang JH, He F
- 4388** Primary intratracheal schwannoma misdiagnosed as severe asthma in an adolescent: A case report
Huang HR, Li PQ, Wan YX
- 4395** Prenatal diagnosis of cor triatriatum sinister associated with early pericardial effusion: A case report
Cánovas E, Cazorla E, Alonzo MC, Jara R, Álvarez L, Beric D
- 4400** Pulmonary alveolar proteinosis complicated with tuberculosis: A case report
Bai H, Meng ZR, Ying BW, Chen XR
- 4408** Surgical treatment of four segment lumbar spondylolysis: A case report
Li DM, Peng BG

- 4415** Efficacy of artificial liver support system in severe immune-associated hepatitis caused by camrelizumab: A case report and review of the literature
Tan YW, Chen L, Zhou XB
- 4423** Anti-Yo antibody-positive paraneoplastic cerebellar degeneration in a patient with possible cholangiocarcinoma: A case report and review of the literature
Lou Y, Xu SH, Zhang SR, Shu QF, Liu XL
- 4433** Intraneural ganglion cyst of the lumbosacral plexus mimicking L5 radiculopathy: A case report
Lee JG, Peo H, Cho JH, Kim DH
- 4441** Effectiveness of patient education focusing on circadian pain rhythms: A case report and review of literature
Tanaka Y, Sato G, Imai R, Osumi M, Shigetoh H, Fujii R, Morioka S
- 4453** Schwannoma mimicking pancreatic carcinoma: A case report
Kimura K, Adachi E, Toyohara A, Omori S, Ezaki K, Ihara R, Higashi T, Ohgaki K, Ito S, Maehara SI, Nakamura T, Fushimi F, Maehara Y

ABOUT COVER

Editorial Board Member of *World Journal of Clinical Cases*, Pietro Scicchitano, MD, Professor, Research Scientist, Department of Emergency and Organ Transplantation, School of Medicine, University of Bari, Bari 70124, Italy. piero.sc@hotmail.it

AIMS AND SCOPE

The primary aim of *World Journal of Clinical Cases* (WJCC, *World J Clin Cases*) is to provide scholars and readers from various fields of clinical medicine with a platform to publish high-quality clinical research articles and communicate their research findings online.

WJCC mainly publishes articles reporting research results and findings obtained in the field of clinical medicine and covering a wide range of topics, including case control studies, retrospective cohort studies, retrospective studies, clinical trials studies, observational studies, prospective studies, randomized controlled trials, randomized clinical trials, systematic reviews, meta-analysis, and case reports.

INDEXING/ABSTRACTING

The WJCC is now indexed in Science Citation Index Expanded (also known as SciSearch®), Journal Citation Reports/Science Edition, Scopus, PubMed, and PubMed Central. The 2020 Edition of Journal Citation Reports® cites the 2019 impact factor (IF) for WJCC as 1.013; IF without journal self cites: 0.991; Ranking: 120 among 165 journals in medicine, general and internal; and Quartile category: Q3. The WJCC's CiteScore for 2019 is 0.3 and Scopus CiteScore rank 2019: General Medicine is 394/529.

RESPONSIBLE EDITORS FOR THIS ISSUE

Production Editor: Jia-Hui Li; Production Department Director: Yu-Jie Ma; Editorial Office Director: Jin-Lai Wang.

NAME OF JOURNAL

World Journal of Clinical Cases

ISSN

ISSN 2307-8960 (online)

LAUNCH DATE

April 16, 2013

FREQUENCY

Thrice Monthly

EDITORS-IN-CHIEF

Dennis A Bloomfield, Sandro Vento, Bao-Gan Peng

EDITORIAL BOARD MEMBERS

<https://www.wjgnet.com/2307-8960/editorialboard.htm>

PUBLICATION DATE

June 16, 2021

COPYRIGHT

© 2021 Baishideng Publishing Group Inc

INSTRUCTIONS TO AUTHORS

<https://www.wjgnet.com/bpg/gerinfo/204>

GUIDELINES FOR ETHICS DOCUMENTS

<https://www.wjgnet.com/bpg/GerInfo/287>

GUIDELINES FOR NON-NATIVE SPEAKERS OF ENGLISH

<https://www.wjgnet.com/bpg/gerinfo/240>

PUBLICATION ETHICS

<https://www.wjgnet.com/bpg/GerInfo/288>

PUBLICATION MISCONDUCT

<https://www.wjgnet.com/bpg/gerinfo/208>

ARTICLE PROCESSING CHARGE

<https://www.wjgnet.com/bpg/gerinfo/242>

STEPS FOR SUBMITTING MANUSCRIPTS

<https://www.wjgnet.com/bpg/GerInfo/239>

ONLINE SUBMISSION

<https://www.f6publishing.com>



Pelvic lipomatosis with cystitis glandularis managed with cyclooxygenase-2 inhibitor: A case report

Li-Cai Mo, Song-Zhe Piao, Hai-Hong Zheng, Tao Hong, Qin Feng, Mang Ke

ORCID number: Li-Cai Mo 0000-0002-4272-3210; Song-Zhe Piao 0000-0002-4219-0645; Hai-Hong Zheng 0000-0003-2914-0413; Tao Hong 0000-0001-8574-4911; Qin Feng 0000-0002-2564-7666; Mang Ke 0000-0002-5547-6351.

Author contributions: Piao SZ designed the study; Mo LC and Piao SZ reviewed the literature and drafted the manuscript and contributed equally to this work as co-first authors; Zheng HH performed the histopathological and immunohistochemistry analyses; Hong T participated in the data tracking and analysis; Feng Q was responsible for language revision and reviewed the literature; Ke M revised the manuscript; all authors have read and approved the final manuscript.

Supported by The Grant from the Medical Science and Technology Project of Zhejiang Province, No. 2020KY354.

Informed consent statement: Informed written consent was obtained from the patient for publication of this report and any accompanying images.

Conflict-of-interest statement: The authors declare that they have no competing interests to disclose.

CARE Checklist (2016) statement:

Li-Cai Mo, Song-Zhe Piao, Tao Hong, Qin Feng, Mang Ke, Department of Urology, Taizhou Hospital of Zhejiang Province Affiliated with Wenzhou Medical University, Taizhou 317000, Zhejiang Province, China

Hai-Hong Zheng, Department of Pathology, Taizhou Hospital of Zhejiang Province Affiliated with Wenzhou Medical University, Taizhou 317000, Zhejiang Province, China

Corresponding author: Mang Ke, MD, Doctor, Professor, Department of Urology, Taizhou Hospital of Zhejiang Province Affiliated with Wenzhou Medical University, No. 150 Ximen Street, Taizhou 317000, Zhejiang Province, China. kem@enzemed.com

Abstract

BACKGROUND

Pelvic lipomatosis (PL) is a rare benign condition with characteristic overgrowth of histologically benign fat and invasion and compression of pelvic organs, often leading to non-specific lower urinary tract symptoms (LUTS). Approximately 40% of patients with PL have cystitis glandularis (CG). The cause of PL combined with CG is poorly understood, and there is currently no effective treatment. Refractory CG with upper urinary tract obstruction even requires partial or radical bladder resection.

CASE SUMMARY

In this case, a patient suffering from PL with CG was treated by transurethral resection of bladder tumour (TUR-BT) and oral administration of celecoxib, a selective cyclooxygenase-2 (COX-2) inhibitor. The LUTS were alleviated, and the cystoscopy results improved significantly. Immunohistochemistry showed up-regulated COX-2 expression in the epithelium of TUR-BT samples, suggesting that COX-2 may participate in the pathophysiological process of PL combined with CG.

CONCLUSION

We report for the first time that celecoxib may be an effective treatment strategy for PL combined with refractory CG.

Key Words: Pelvic lipomatosis; Cystitis glandularis; Cyclooxygenase-2; Celecoxib; Lower urinary tract symptoms; Case report

©The Author(s) 2021. Published by Baishideng Publishing Group Inc. All rights reserved.

The authors have read the CARE Checklist (2016), and the manuscript was prepared and revised according to the CARE Checklist (2016).

Open-Access: This article is an open-access article that was selected by an in-house editor and fully peer-reviewed by external reviewers. It is distributed in accordance with the Creative Commons Attribution NonCommercial (CC BY-NC 4.0) license, which permits others to distribute, remix, adapt, build upon this work non-commercially, and license their derivative works on different terms, provided the original work is properly cited and the use is non-commercial. See: <http://creativecommons.org/licenses/by-nc/4.0/>

Manuscript source: Unsolicited manuscript

Specialty type: Urology and nephrology

Country/Territory of origin: China

Peer-review report's scientific quality classification

Grade A (Excellent): 0
Grade B (Very good): B
Grade C (Good): 0
Grade D (Fair): 0
Grade E (Poor): 0

Received: February 4, 2021

Peer-review started: February 4, 2021

First decision: March 7, 2021

Revised: March 10, 2021

Accepted: April 8, 2021

Article in press: April 8, 2021

Published online: June 16, 2021

P-Reviewer: Naswhan AJ

S-Editor: Zhang H

L-Editor: Wang TQ

P-Editor: Ma YJ



Core Tip: Pelvic lipomatosis (PL) is a rare benign condition with characteristic overgrowth of histologically benign fat and invasion and compression of pelvic organs. The cause of PL with cystitis glandularis (CG) is poorly understood, and there is no effective treatment. This paper reports a patient suffering from PL with CG who was treated by transurethral resection of bladder tumour and oral administration of celecoxib. The lower urinary tract symptoms were alleviated, and the cystoscopy results improved significantly. We report for the first time that celecoxib may be an effective treatment strategy for PL combined with refractory CG.

Citation: Mo LC, Piao SZ, Zheng HH, Hong T, Feng Q, Ke M. Pelvic lipomatosis with cystitis glandularis managed with cyclooxygenase-2 inhibitor: A case report. *World J Clin Cases* 2021; 9(17): 4373-4380

URL: <https://www.wjgnet.com/2307-8960/full/v9/i17/4373.htm>

DOI: <https://dx.doi.org/10.12998/wjcc.v9.i17.4373>

INTRODUCTION

Pelvic lipomatosis (PL) is a rare proliferative disease that was first identified by Fogg *et al*[1] early in 1968. Nevertheless, no more than 150 cases have been reported in the English-language literature[2]. PL is characterized by the excessive and diffuse growth of histologically benign fat in the perirectal and perivesicular spaces. It has been reported that more than 75% of PL patients suffer from proliferative cystitis, and an additional 40% of these patients show cystitis glandularis (CG) as a comorbidity[3]. There is currently no effective treatment for PL combined with CG. Approximately 40% of patients may develop obstructive uropathy within 5 years after diagnosis, probably leading to renal failure[4]. Therefore, surgical intervention is often necessary in patients with upper urinary tract obstruction, including ureteral reimplantation, urine drainage (indwelling catheter), and partial or total bladder resection, among others. However, the efficacy of these strategies is not ideal, and the quality of life of patients is seriously affected by the above surgical interventions. A large number of studies have reported that cyclooxygenase-2 (COX-2) is highly expressed in CG tissues[5,6]. Herein, we report the first case of a patient with PL combined with CG who received the COX-2 inhibitor celecoxib in combination with transurethral resection of bladder tumour (TUR-BT), which improved his condition significantly. Additionally, his imaging characteristics were reassessed.

CASE PRESENTATION

Chief complaints

A 49-year-old man complaining of lower urinary tract symptoms (LUTS) with haematuria for 1 year was taken to Taizhou Hospital of Zhejiang Province Affiliated with Wenzhou Medical University, China. The core lower urinary tract symptom score (CLSS) was 11 points.

History of present illness

The patient reported that he had suffered from LUTS and haematuria for 1 year.

History of past illness

The patient had no history of other illness.

Personal and family history

The patient did not smoke or drink, and had no relevant family history.

Physical examination

No positive manifestation was found on prostate examination.

Laboratory examinations

Urine sediment microscopic examination revealed urinary occult blood (ERY) 1+. The results of routine blood test, urine cultures, and renal function tests were normal. Urine cytology revealed no atypical cells.

Imaging examinations

Ultrasound of the urinary system revealed irregular thickening of the bladder triangle where burr-like protrusions were visible and no hydronephrosis (Figure 1A). Contrast-enhanced computed tomography (CT) of the pelvis showed that the bladder wall was thickened, especially the posterior wall and the bladder triangle. Polypoidal growth inside the bladder was noted (Figure 1B). Moreover, no obvious dilatation was found in the kidneys or ureters (Figure 1C). Cystoscopy and biopsy showed bladder lesions in the trigonum vesicae, cervix vesicae, and both sides of the ureteral orifices (Figure 2A and 2B). Histopathological examination suggested CG.

The patient underwent TUR-BT under general anaesthesia with endotracheal intubation. The patient was followed for 3 mo after the first TUR-BT procedure. At this time, the diagnosis of PL was confirmed by CT. The biopsy, unfortunately, had not been performed without the patient's permission. CT of the urinary tract showed that the bladder morphology had changed from an elliptical shape to a pear shape (Figure 1D and F). Additionally, changes from no dilatation of the kidneys or ureters to bilateral dilatation of the renal pelvis, calyces, and ureters was observed and was more obvious in the left upper urinary tract (Figure 1C and E). An increased fat density around the bladder and rectum was noted, as well as compression of the rectum (Figure 1F). The angle between the bladder and seminal vesicle in the axial image (\angle BOS) changed from 49.5° to 89.5° and the diameter of the rectal axial cross-section changed from 2.08 cm to 1.76 cm (Figure 1D and F).

FINAL DIAGNOSIS

Based on the findings of the CT and histopathological examinations, a provisional diagnosis of PL combined with CG was made.

TREATMENT

The patient underwent TUR-BT under general anaesthesia with endotracheal intubation. Besides from the bladder lesions on both sides of the ureteral orifices, the others were completely removed. The bladder lesions on both sides of the ureteral orifices were left *in situ* during the operation, and JJ stents were placed prophylactically. Pathology showed von Brunn nest hyperplasia and goblet cells secreting considerable mucin, consistent with intestinal epithelial CG (Figure 2C).

At the 1-mo follow-up, the JJ stents on both sides were removed. Left renal colic occurred 3 mo after surgery, with abnormally increased renal function indexes (serum creatinine: 1.63 mg/dL; estimated glomerular filtration rate: 49 mL/min/1.73 m²). Cystoscopy indicated the recurrence of CG. We repeated TUR-BT 6 mo after the initial operation, with a similar pathological result, namely, CG. The patient was followed for 3 mo after the second TUR-BT procedure. The CLSS score was 12. The cystoscopy results suggested limited benefit of the above treatment on CG.

Re-examination of renal function revealed that the serum creatinine level was 1.92 mg/dL and the estimated glomerular filtration rate was 40 mL/min/1.73 m². According to cystoscopy results and CT findings, CG was determined to have recurred, with upper urinary tract obstruction on both sides. Therefore, a third TUR-BT procedure and ureteroscopy on both sides were carried out, only revealing the recurrence of CG in the bladder. However, the stricture of the left ureteral orifice made it difficult to insert the flexible ureteroscope (fUR) into the ureter. After using the guide wire to pass through the twisted section of the left ureter, the fUR was placed. Small stones were found in the lower part of the left ureter where a 12/14-Fr ureteral access sheath (UAS) was placed, and three small stones were removed through the UAS using collection basket. There were no obvious abnormalities of the right ureter. One month after the third operation, the JJ stents on both sides were removed together. Postoperatively, the patient was orally given the COX-2 inhibitor celecoxib for 6 mo (200 mg twice daily; Pfizer, United States). Although the indications for celecoxib do not include CG, it can act as an anti-inflammatory agent and postope-

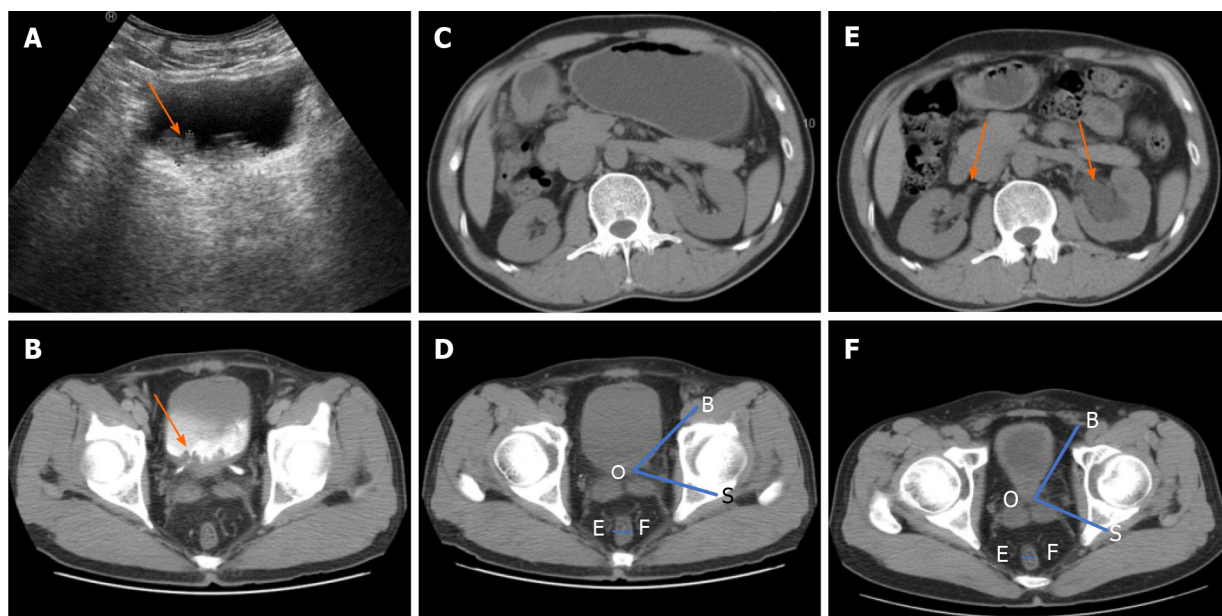


Figure 1 Imaging findings of cystitis glandularis with pelvic lipomatosis. A: Ultrasound examination showed that the mass was located in the triangular region of the bladder, with a burr-like protrusion and irregular thickened wall of the triangular region of the bladder; B: On first admission, computed tomography (CT) of the urinary system suggested thickening of the bladder wall, mainly on the posterior wall and the triangle area, and the mastoid process was observed inside the cavity. Mild to moderate continuous enhancement was noted in the delayed phase; C: Urinary CT scan for the first time revealed no hydronephrosis in the renal pelvis and ureter; D: Angle between the bladder and seminal vesicle (ABS) in the axial cross-section (\angle BOS) and the axial cross-sectional diameter of the rectum (EF) in CT at the first visit. The bladder morphology was elliptical; E: CT was reviewed 3 mo after the second transurethral resection of bladder tumour (TUR-BT). The pelvises, calyces, and ureters on both sides dilated, especially on the left side; F: CT review 3 mo after the second TUR-BT: ABS in the axial cross-section (\angle BOS) became larger and the axial cross-sectional diameter of the rectum (EF) became smaller. The adipose density around the bladder and around the rectum increased, the rectum was compressed, and the bladder shape was inversely pear-shaped.

rative analgesic. The patient was informed about the necessity for and the risk of the off-label use of celecoxib, and his consent was obtained.

OUTCOME AND FOLLOW-UP

The patient was followed at 6 mo and 1 year after the treatment. No CG recurrence was found cystoscopically (Figure 2E and F). The CLSS was decreased significantly at 6 mo and 1 year after treatment (9 and 8 points, respectively) compared to baseline (11 points). At the last follow-up, the patient's clinical manifestations were stable, with no recurrence of CG on cystoscopy. The CLSS was 8 points, haematuria was absent, and the serum creatinine level was stable at 1.63 mg/dL (estimated glomerular filtration rate: 49 mL/min/1.73 m²), although subsequent CT scans revealed PL with obstructive uropathy. We performed a retrospective analysis of the patient's TUR-BT tissue samples, and applied COX-2 antibody to detect the expression level of COX-2 in the CG tissue by immunohistochemistry (Figure 2D). The staining steps were conventional dewaxing and antigen retrieval. Primary antibody (COX-2 monoclonal antibody; Clone No. 3G2B9, Proteintech Group, United States) was added. The next day, we added secondary antibody and incubated the samples for 30 min. Then, we performed DAB staining, hematoxylin counterstaining, and sealing with neutral gum.

DISCUSSION

PL is a rare disease of benign proliferation. Because of the subtle symptoms of early PL, some elderly male patients may be missed, and the incidence may be underestimated[7]. Subsequently, patients with advanced disease are troubled with haematuria, unendurable LUTS, or gastrointestinal symptoms, such as constipation, nausea, lower abdominal pain, or progressively increasing back pain. Severe hydronephrosis and renal insufficiency may have developed in some patients by the time of diagnosis. Approximately 1/3 of patients with PL exhibit hypertension, and some patients exhibit uremia due to renal failure. The patient in the present case

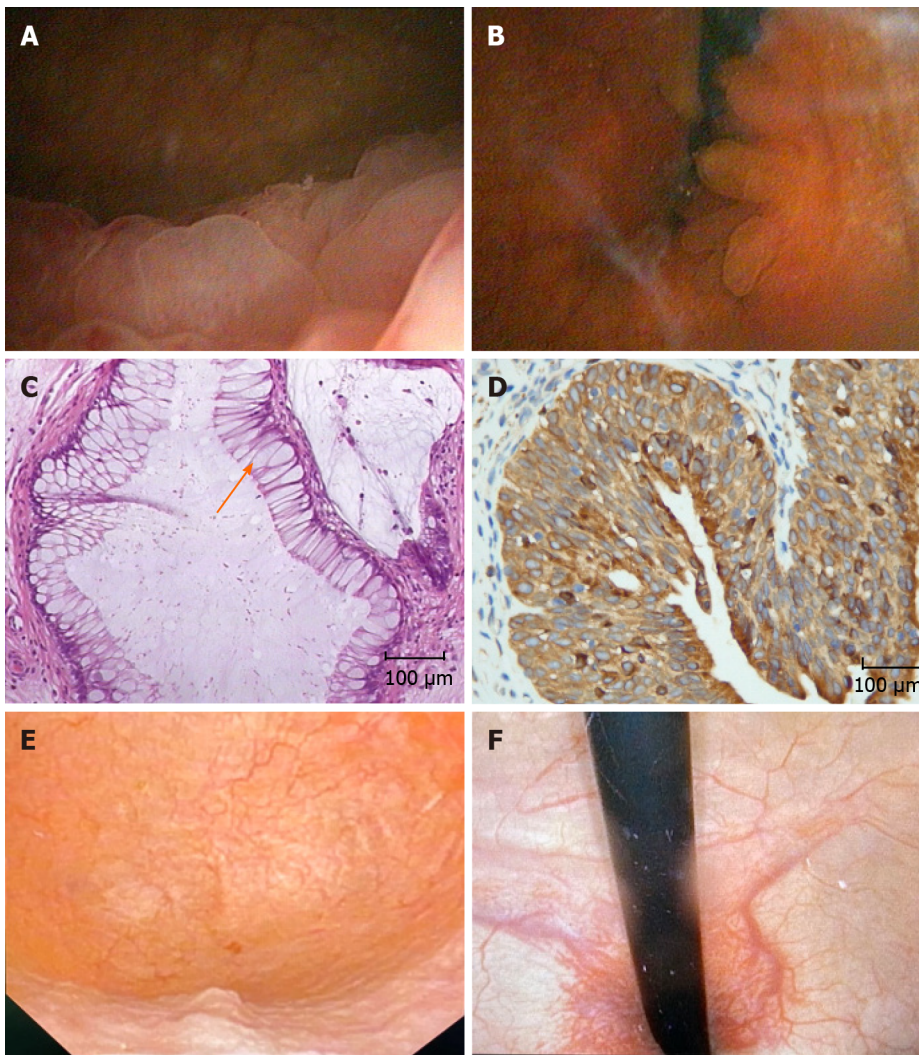


Figure 2 Cystoscopy and pathological results. A and B: Bladder lesions in the trigonum vesicae, cervix vesicae (A), and both sides of ureteral orifices (B) were observed at the first visit; C: The initial histopathological analysis after transurethral resection of bladder tumour showed considerable goblet cells (shown by arrows) in the bladder epithelium; D: Immunohistochemical analysis of cystitis glandularis showed positive expression of cyclooxygenase-2 (COX-2) in the cytoplasm. The pathological results showed that it was intestinal glandular cystitis; E and F: Negative recurrence of bladder tumor was observed cystoscopically after 6-mo application of COX-2 inhibitor.

presented for the first time without significant hypertension but with significant LUTS and gross haematuria. However, there were no abnormalities on CT, indicating that upper urinary tract obstruction may not be specific to early stages of PL. Bilateral hydronephrosis and abnormal renal function were detected at the second admission. The exact cause of CG is still unclear, but the obstruction of lymphatic vessels and veins caused by the compression of adipose tissue against the bladder may be the cause[8]. In this case, postoperative pathology confirmed CG of the intestinal epithelial type. At present, CG is generally divided into typical and intestinal epithelial types, with the latter showing a high tendency for malignancy. Therefore, cystoscopy is particularly important during early follow-up. Although intestinal metaplasia of the bladder is morphologically similar to that of the normal colon mucosa and other organs, the lack of expression of Hep, a marker of midgut epithelial metaplasia in bladder intestinal metaplasia, may indicate the presence of unique intestinal metaplasia pathway in the bladder[9].

There are no typical symptoms of PL. Imaging modalities such as CT may be the first choice for the diagnosis of PL, as opposed to surgery or biopsy[10]. Pelvic CT shows a symmetric increase in fat tissue around the bladder, and a change in bladder shape is important radiologically[10]. Studies have shown that "pear-shaped" and "banana-shaped" bladders are highly specific (100%) in predicting patients with PL, however, with a low sensitivity (40.6%)[10]. Zhang *et al*[11] analysed images from 32 cases of PL and found that the sensitivity and specificity for the diagnosis of PL by the bladder seminal vesicle angle were 62.5% and 100%, respectively, and that the optimal

threshold for diagnosis was 75°. In the previous literature, all patients diagnosed with PL had excretory cystograms or CT that demonstrated a bladder described as "pear-shaped", "banana-shaped", or "inverted teardrop-shaped" (Table 1). In our study, a similar imaging sign was detected, that is, the shape of the bladder was oval at the first visit, and it was pear-shaped on CT 6 mo after surgery. The bladder seminal vesicle angle increased from 49.5° to 89.5°. We speculate that in the early stages of PL, the bladder and sigmoid colorectum maintain a certain degree of tension and can withstand the compression from the excess fat, allowing the bladder to stay in a relatively normal shape. However, as the disease progresses, abnormal fat fills the gap between the lower ureter and the bottom of the bladder, narrowing the ureteral lumen, elongating the inner wall of the ureter, and then causing secondary hydronephrosis or stone formation. In our case, ureteroscopy was also performed because of hydronephrosis in both kidneys, and left lower ureteral stenosis was found along with ureteral calculi during the operation. In addition, all these anatomical changes make intraluminal surgery rather difficult. PL-induced hydronephrosis and ureteral dilatation are usually equal on both sides, but when there is asymmetry, the obstruction on the left side is usually more severe, possibly due to compression of the sigmoid colon[12], as in this case.

The cause of PL is unclear, but multiple studies have shown that PL may be related to obesity[13]. At present, a standard strategy for the treatment of PL needs to be recognized. Long-term oral antibiotics, hormone therapy, and external radiation therapy may be ineffective, and surgical intervention remains controversial[10]. Therefore, it is particularly important to diagnose PL early and slow its progression to hydronephrosis or even uraemia through conservative treatment.

Studies have shown that celecoxib can increase insulin sensitivity on subjects who are overweight or obese[14]. In a study by Hayashi *et al*[15], celecoxib inhibited the growth of tumours in obese mice with prostate cancer. In addition, the intestinal metaplasia in CG is similar to that in the colonic mucosa in terms of morphological changes and the expression of some markers[16]. Long-term oral celecoxib has been shown to prevent recurrence in patients with high-risk adenomas[17]. In addition, several studies have confirmed that COX-2 is overexpressed in CG[5,18]. Takizawa *et al*[6] reported the use of celecoxib to treat glandular cystitis, with certain effects. Our patient was diagnosed with refractory CG with PL and treatments including TUR-BT and long-term antibiotics turned out to be futile. We doubled the dose reported by Nae Takizawa (100 mg of celecoxib daily for treatment), which is also recommended in other inflammatory diseases such as adenoma[17] and bone arthritis[19]. In this patient, we used the CLSS questionnaire, which is a reliable tool for the comprehensive evaluation of LUTS in both sexes, to assess the patient's LUTS[20]. The patient showed a CLSS of 11 points at the first visit, and the CLSS stabilized at 8 points after comprehensive treatment, including oral celecoxib. Additionally, haematuria disappeared, and the serum creatinine level stabilized at 1.63 mg/dL (estimated glomerular filtration rate: 49 mL/min/1.73 m²). In addition, celecoxib improved the cystoscopy results, although subsequent CT scans showed PL with obstructive uropathy.

CONCLUSION

We report for the first time remission in a case of PL with refractory CG after TUR-BT and oral celecoxib. The aetiology of PL combined with intestinal CG is still unclear and needs further study, although it is generally related to chronic inflammation stimulation. COX-2 inhibitors may be a new strategy for the treatment of PL with refractory CG. The take-home messages from the current case include: (1) The early symptoms of PL are subtle and overlooked; (2) CT is very important in addition to cystoscopy; (3) PL patients need to be closely followed, because the condition may cause upper urinary tract obstruction or even renal failure as it progresses, and the surgical treatment effect leaves much to be desired; and (4) COX-2 inhibitors may be a new strategy for the treatment of PL with refractory CG.

Table 1 Pelvic lipomatosis with cystitis glandularis reported in the previous literature

Case (No.)	Age (yr)	Sex	Symptoms	Radiographic findings	Treatment	Outcome	Ref.
1	48	Male	Nocturia	Banana-shaped	Surgical removal of fat	Subjective symptoms improved, radiographic findings not changed	Fogg <i>et al</i> [1], 1968
2	35	Male	Perineal	Teardrop-shaped	Radical cyst prostatectomy	Radiographic findings no recurrence of tumour	Heyns <i>et al</i> [3], 1991
3	47	Male	LUTS	Banana-shaped	Surgical treatment using a bladder-sparing technique	Hydronephrosis not changed	Ge <i>et al</i> [7], 2019
4	49	Male	LUTS	Pear-shaped	TUR-BT and oral administration of celecoxib	Subjective symptoms improved, cystitis glandularis improved, radiographic findings not changed	Our case

LUTS: Lower urinary tract symptoms; TUR-BT: Transurethral resection of bladder tumour.

REFERENCES

- 1 Fogg LB, Smyth JW. Pelvic lipomatosis: a condition simulating pelvic neoplasm. *Radiology* 1968; **90**: 558-564 [PMID: 5642294 DOI: 10.1148/90.3.558]
- 2 Chen Y, Yang Y, Yu W, Xiao Y, Fan Y, Duan J, Tang Y, Jin J, Wang H, Zhu S, Xi Z, Wu S. Urodynamic characteristics of pelvic lipomatosis with glandular cystitis patients correlate with morphologic alterations of the urinary system and disease severity. *Neurourol Urodyn* 2018; **37**: 758-767 [PMID: 28763116 DOI: 10.1002/nau.23343]
- 3 Heyns CF, De Kock ML, Kirsten PH, van Velden DJ. Pelvic lipomatosis associated with cystitis glandularis and adenocarcinoma of the bladder. *J Urol* 1991; **145**: 364-366 [PMID: 1988733 DOI: 10.1016/s0022-5347(17)38342-8]
- 4 Baas W, O'Connor B, El-Zawahry A. Bilateral hydronephrosis and acute kidney injury secondary to pelvis lipomatosis. *Can J Urol* 2018; **25**: 9217-9219 [PMID: 29524979]
- 5 Li A, Zhou J, Lu H, Zuo X, Liu S, Zhang F, Li W, Fang W, Zhang B. Pathological feature and immunoprofile of cystitis glandularis accompanied with upper urinary tract obstruction. *Biomed Res Int* 2014; **2014**: 872170 [PMID: 25136635 DOI: 10.1155/2014/872170]
- 6 Takizawa N, Matsuzaki T, Yamamoto T, Mishima T, Miyasaka C, Tanaka S, Kinoshita H, Uemura Y, Yamada H, Matsuda T. Novel strategy for cystitis glandularis: Oral treatment with cyclooxygenase-2 inhibitor. *Int J Urol* 2016; **23**: 706-708 [PMID: 27238955 DOI: 10.1111/iju.13121]
- 7 Ge L, Tian X, Zhao G, Ma J, Song Y, Yang F, Zhang S, Ma L. Surgical treatment for pelvic lipomatosis using a bladder-sparing technique: A STROBE-compliant study. *Medicine (Baltimore)* 2019; **98**: e16198 [PMID: 31261563 DOI: 10.1097/MD.00000000000016198]
- 8 Barry JM, Bilbao MK, Hodges CV. Pelvic lipomatosis: a rare cause of suprapubic mass. *J Urol* 1973; **109**: 592-594 [PMID: 4695094 DOI: 10.1016/s0022-5347(17)60488-9]
- 9 Ni Y, Zhao S, Yin X, Wang H, Guang Q, Hu G, Yang Y, Jiao S, Shi B. Intravesicular administration of sodium hyaluronate ameliorates the inflammation and cell proliferation of cystitis cystica et glandularis involving interleukin-6/JAK2/Stat3 signaling pathway. *Sci Rep* 2017; **7**: 15892 [PMID: 29162939 DOI: 10.1038/s41598-017-16088-9]
- 10 Klein FA, Smith MJ, Kasenetz I. Pelvic lipomatosis: 35-year experience. *J Urol* 1988; **139**: 998-1001 [PMID: 3361678 DOI: 10.1016/s0022-5347(17)42744-3]
- 11 Zhang Y, Wu S, Xi Z, Wang X, Jiang X. Measuring diagnostic accuracy of imaging parameters in pelvic lipomatosis. *Eur J Radiol* 2012; **81**: 3107-3114 [PMID: 22749803 DOI: 10.1016/j.ejrad.2012.05.031]
- 12 Xu T, Zhao WH, Wang XF, Huang XB, Xu QQ, Yang B, Ye XJ. [Analysis of pelvic lipomatosis and a case report of two brothers]. *Beijing Da Xue Xue Bao Yi Xue Ban* 2007; **39**: 355-360 [PMID: 17657258]
- 13 Morettin LB, Wilson M. Pelvic lipomatosis. *Am J Roentgenol Radium Ther Nucl Med* 1971; **113**: 181-184 [PMID: 5096819 DOI: 10.2214/ajr.113.1.181]
- 14 González-Ortiz M, Pascoe-González S, Esperanzamartínez-Abundis, Kam-Ramos AM, Hernández-Salazar E. Effect of celecoxib, a cyclooxygenase-2-specific inhibitor, on insulin sensitivity, C-reactive protein, homocysteine, and metabolic profile in overweight or obese subjects. *Metab Syndr Relat Disord* 2005; **3**: 95-101 [PMID: 18370716 DOI: 10.1089/met.2005.3.95]
- 15 Hayashi T, Fujita K, Nojima S, Hayashi Y, Nakano K, Ishizuya Y, Wang C, Yamamoto Y, Kinouchi T, Matsuzaki K, Jingushi K, Kato T, Kawashima A, Nagahara A, Ujike T, Uemura M, Pena MDCR, Gordetsky JB, Morii E, Tsujikawa K, Netto GJ, Nonomura N. High-Fat Diet-Induced Inflammation Accelerates Prostate Cancer Growth via IL6 Signaling. *Clin Cancer Res* 2018; **24**: 4309-4318 [PMID: 29776955 DOI: 10.1158/1078-0432.CCR-18-0106]
- 16 Sung MT, Lopez-Beltran A, Eble JN, MacLennan GT, Tan PH, Montironi R, Jones TD, Ulbright

- TM, Blair JE, Cheng L. Divergent pathway of intestinal metaplasia and cystitis glandularis of the urinary bladder. *Mod Pathol* 2006; **19**: 1395-1401 [PMID: [16951671](#) DOI: [10.1038/modpathol.3800670](#)]
- 17 **Thompson PA**, Ashbeck EL, Roe DJ, Fales L, Buckmeier J, Wang F, Bhattacharyya A, Hsu CH, Chow SH, Ahnen DJ, Boland CR, Heigh RI, Fay DE, Hamilton SR, Jacobs ET, Martinez EM, Alberts DS, Lance P. Celecoxib for the Prevention of Colorectal Adenomas: Results of a Suspended Randomized Controlled Trial. *J Natl Cancer Inst* 2016; **108** [PMID: [27530656](#) DOI: [10.1093/jnci/djw151](#)]
- 18 **Li Z**, Ge G, Feng R, Wu D, Shen B, Wang X, Cui Y, Li J, Ju X. Cyclooxygenase-2 and B-cell lymphoma-2 expression in cystitis glandularis and primary vesicle adenocarcinoma. *BMC Urol* 2014; **14**: 2 [PMID: [24387269](#) DOI: [10.1186/1471-2490-14-2](#)]
- 19 **Wittenberg RH**, Schell E, Krehan G, Maeumbaed R, Runge H, Schlüter P, Fashola TO, Thurston HJ, Burger KJ, Trechsel U. First-dose analgesic effect of the cyclo-oxygenase-2 selective inhibitor lumiracoxib in osteoarthritis of the knee: a randomized, double-blind, placebo-controlled comparison with celecoxib [NCT00267215]. *Arthritis Res Ther* 2006; **8**: R35 [PMID: [16469112](#) DOI: [10.1186/ar1854](#)]
- 20 **Homma Y**, Yoshida M, Yamanishi T, Gotoh M. Core Lower Urinary Tract Symptom score (CLSS) questionnaire: a reliable tool in the overall assessment of lower urinary tract symptoms. *Int J Urol* 2008; **15**: 816-820 [PMID: [18657204](#) DOI: [10.1111/j.1442-2042.2008.02121.x](#)]



Published by **Baishideng Publishing Group Inc**
7041 Koll Center Parkway, Suite 160, Pleasanton, CA 94566, USA

Telephone: +1-925-3991568

E-mail: bpgoffice@wjgnet.com

Help Desk: <https://www.f6publishing.com/helpdesk>

<https://www.wjgnet.com>

