

World Journal of *Clinical Cases*

World J Clin Cases 2021 June 26; 9(18): 4460-4880



Contents

Thrice Monthly Volume 9 Number 18 June 26, 2021

OPINION REVIEW

- 4460 Surgery for pancreatic tumors in the midst of COVID-19 pandemic

Kato H, Asano Y, Arakawa S, Ito M, Kawabe N, Shimura M, Hayashi C, Ochi T, Yasuoka H, Higashiguchi T, Kondo Y, Nagata H, Horiguchi A

REVIEW

- 4467 Roles of exosomes in diagnosis and treatment of colorectal cancer

Umwali Y, Yue CB, Gabriel ANA, Zhang Y, Zhang X

MINIREVIEWS

- 4480 Dynamics of host immune responses to SARS-CoV-2

Taherkhani R, Taherkhani S, Farshadpour F

- 4491 Current treatment for hepatitis C virus/human immunodeficiency virus coinfection in adults

Laiwatthanapaisan R, Sirinawasatien A

- 4500 Anti-tumor effect of statin on pancreatic adenocarcinoma: From concept to precision medicine

Huang CT, Liang YJ

- 4506 Roles of vitamin A in the regulation of fatty acid synthesis

Yang FC, Xu F, Wang TN, Chen GX

ORIGINAL ARTICLE

Basic Study

- 4520 Identification of the circRNA-miRNA-mRNA regulatory network and its prognostic effect in colorectal cancer

Yin TF, Zhao DY, Zhou YC, Wang QQ, Yao SK

- 4542 Tetramethylpyrazine inhibits proliferation of colon cancer cells *in vitro*

Li H, Hou YX, Yang Y, He QQ, Gao TH, Zhao XF, Huo ZB, Chen SB, Liu DX

Case Control Study

- 4553 Significance of highly phosphorylated insulin-like growth factor binding protein-1 and cervical length for prediction of preterm delivery in twin pregnancies

Lan RH, Song J, Gong HM, Yang Y, Yang H, Zheng LM

Retrospective Cohort Study

- 4559** Expected outcomes and patients' selection before chemoembolization—"Six-and-Twelve or Pre-TACE-Predict" scores may help clinicians: Real-life French cohorts results

Adhoue X, Larrey E, Anty R, Chevallier P, Penaranda G, Tran A, Bronowicki JP, Raoul JL, Castellani P, Perrier H, Bayle O, Monnet O, Pol B, Bourliere M

Retrospective Study

- 4573** Application of intelligent algorithms in Down syndrome screening during second trimester pregnancy
Zhang HG, Jiang YT, Dai SD, Li L, Hu XN, Liu RZ
- 4585** Evaluation of a five-gene signature associated with stromal infiltration for diffuse large B-cell lymphoma
Nan YY, Zhang WJ, Huang DH, Li QY, Shi Y, Yang T, Liang XP, Xiao CY, Guo BL, Xiang Y
- 4599** Efficacy of combination of localized closure, ethacridine lactate dressing, and phototherapy in treatment of severe extravasation injuries: A case series
Lu YX, Wu Y, Liang PF, Wu RC, Tian LY, Mo HY
- 4607** Observation and measurement of applied anatomical features for thoracic intervertebral foramen puncture on computed tomography images
Wang R, Sun WW, Han Y, Fan XX, Pan XQ, Wang SC, Lu LJ
- 4617** Histological transformation of non-small cell lung cancer: Clinical analysis of nine cases
Jin CB, Yang L
- 4627** Diagnostic value of amygdala volume on structural magnetic resonance imaging in Alzheimer's disease
Wang DW, Ding SL, Bian XL, Zhou SY, Yang H, Wang P
- 4637** Comparison of ocular axis and corneal diameter between entropion and non-entropion eyes in children with congenital glaucoma
Wang Y, Hou ZJ, Wang HZ, Hu M, Li YX, Zhang Z

Observational Study

- 4644** Risk factors for postoperative delayed gastric emptying in ovarian cancer treated with cytoreductive surgery and hyperthermic intraperitoneal chemotherapy
Cui GX, Wang ZJ, Zhao J, Gong P, Zhao SH, Wang XX, Bai WP, Li Y
- 4654** Clinical characteristics, gastrointestinal manifestations and outcomes of COVID-19 patients in Iran; does the location matters?
Mokarram P, Dalivand MM, Pizuorno A, Aligolighasemabadi F, Sadeghdoust M, Sadeghdoust E, Aduli F, Oskrochi G, Brim H, Ashktorab H
- 4668** AWGS2019 vs EWGSOP2 for diagnosing sarcopenia to predict long-term prognosis in Chinese patients with gastric cancer after radical gastrectomy
Wu WY, Dong JJ, Huang XC, Chen ZJ, Chen XL, Dong QT, Bai YY

Prospective Study

- 4681** Clinical outcomes and 5-year follow-up results of keratosis pilaris treated by a high concentration of glycolic acid

Tian Y, Li XX, Zhang JJ, Yun Q, Zhang S, Yu JY, Feng XJ, Xia AT, Kang Y, Huang F, Wan F

Randomized Controlled Trial

- 4690** Tenofovir disoproxil fumarate in Chinese chronic hepatitis B patients: Results of a multicenter, double-blind, double-dummy, clinical trial at 96 weeks

Chen XF, Fan YN, Si CW, Yu YY, Shang J, Yu ZJ, Mao Q, Xie Q, Zhao W, Li J, Gao ZL, Wu SM, Tang H, Cheng J, Chen XY, Zhang WH, Wang H, Xu ZN, Wang L, Dai J, Xu JH

SYSTEMATIC REVIEWS

- 4700** Mesenteric ischemia in COVID-19 patients: A review of current literature

Kerawala AA, Das B, Solangi A

- 4709** Role of theories in school-based diabetes care interventions: A critical review

An RP, Li DY, Xiang XL

CASE REPORT

- 4721** Alport syndrome combined with lupus nephritis in a Chinese family: A case report

Liu HF, Li Q, Peng YQ

- 4728** Botulinum toxin injection for Cockayne syndrome with muscle spasticity over bilateral lower limbs: A case report

Hsu LC, Chiang PY, Lin WP, Guo YH, Hsieh PC, Kuan TS, Lien WC, Lin YC

- 4734** Meigs' syndrome caused by granulosa cell tumor accompanied with intrathoracic lesions: A case report

Wu XJ, Xia HB, Jia BL, Yan GW, Luo W, Zhao Y, Luo XB

- 4741** Primary mesonephric adenocarcinoma of the fallopian tube: A case report

Xie C, Shen YM, Chen QH, Bian C

- 4748** Pancreas-preserving duodenectomy for treatment of a duodenal papillary tumor: A case report

Wu B, Chen SY, Li Y, He Y, Wang XX, Yang XJ

- 4754** Pheochromocytoma with abdominal aortic aneurysm presenting as recurrent dyspnea, hemoptysis, and hypotension: A case report

Zhao HY, Zhao YZ, Jia YM, Mei X, Guo SB

- 4760** Minimally invasive removal of a deep-positioned cannulated screw from the femoral neck: A case report

Yang ZH, Hou FS, Yin YS, Zhao L, Liang X

- 4765** Splenic Kaposi's sarcoma in a human immunodeficiency virus-negative patient: A case report

Zhao CJ, Ma GZ, Wang YJ, Wang JH

- 4772** Neonatal syringocystadenoma papilliferum: A case report
Jiang HJ, Zhang Z, Zhang L, Pu YJ, Zhou N, Shu H
- 4778** Disappeared intralenticular foreign body: A case report
Xue C, Chen Y, Gao YL, Zhang N, Wang Y
- 4783** Femoral neck stress fractures after trampoline exercise: A case report
Nam DC, Hwang SC, Lee EC, Song MG, Yoo JI
- 4789** Collision carcinoma of the rectum involving neuroendocrine carcinoma and adenocarcinoma: A case report
Zhao X, Zhang G, Li CH
- 4797** Therapeutic effect of autologous concentrated growth factor on lower-extremity chronic refractory wounds: A case report
Liu P, Liu Y, Ke CN, Li WS, Liu YM, Xu S
- 4803** Cutaneous myiasis with eosinophilic pleural effusion: A case report
Fan T, Zhang Y, Lv Y, Chang J, Bauer BA, Yang J, Wang CW
- 4810** Severe hematuria due to vesical varices in a patient with portal hypertension: A case report
Wei ZJ, Zhu X, Yu HT, Liang ZJ, Gou X, Chen Y
- 4817** Rare coexistence of multiple manifestations secondary to thalamic hemorrhage: A case report
Yu QW, Ye TF, Qian WJ
- 4823** Anderson-Fabry disease presenting with atrial fibrillation as earlier sign in a young patient: A case report
Kim H, Kang MG, Park HW, Park JR, Hwang JY, Kim K
- 4829** Long-term response to avelumab and management of oligoprogression in Merkel cell carcinoma: A case report
Leão I, Marinho J, Costa T
- 4837** Central pontine myelinolysis mimicking glioma in diabetes: A case report
Shi XY, Cai MT, Shen H, Zhang JX
- 4844** Microscopic transduodenal excision of an ampullary adenoma: A case report and review of the literature
Zheng X, Sun QJ, Zhou B, Jin M, Yan S
- 4852** Growth hormone cocktail improves hepatopulmonary syndrome secondary to hypopituitarism: A case report
Ji W, Nie M, Mao JF, Zhang HB, Wang X, Wu XY
- 4859** Low symptomatic COVID-19 in an elderly patient with follicular lymphoma treated with rituximab-based immunotherapy: A case report
Łęcki S, Wyżgolik K, Nicze M, Georgiew-Nadziakiewicz S, Chudek J, Wdowiak K

- 4866** Adult rhabdomyosarcoma originating in the temporal muscle, invading the skull and meninges: A case report
Wang GH, Shen HP, Chu ZM, Shen J
- 4873** *Listeria monocytogenes* bacteremia in a centenarian and pathogen traceability: A case report
Zhang ZY, Zhang XA, Chen Q, Wang JY, Li Y, Wei ZY, Wang ZC

ABOUT COVER

Editorial Board Member of *World Journal of Clinical Cases*, Shingo Tsujinaka, MD, PhD, Assistant Professor, Senior Lecturer, Surgeon, Department of Surgery, Saitama Medical Center, Jichi Medical University, Saitama 330-8503, Japan. tsujinakas@omiya.jichi.ac.jp

AIMS AND SCOPE

The primary aim of *World Journal of Clinical Cases* (WJCC, *World J Clin Cases*) is to provide scholars and readers from various fields of clinical medicine with a platform to publish high-quality clinical research articles and communicate their research findings online.

WJCC mainly publishes articles reporting research results and findings obtained in the field of clinical medicine and covering a wide range of topics, including case control studies, retrospective cohort studies, retrospective studies, clinical trials studies, observational studies, prospective studies, randomized controlled trials, randomized clinical trials, systematic reviews, meta-analysis, and case reports.

INDEXING/ABSTRACTING

The WJCC is now indexed in Science Citation Index Expanded (also known as SciSearch®), Journal Citation Reports/Science Edition, Scopus, PubMed, and PubMed Central. The 2020 Edition of Journal Citation Reports® cites the 2019 impact factor (IF) for WJCC as 1.013; IF without journal self cites: 0.991; Ranking: 120 among 165 journals in medicine, general and internal; and Quartile category: Q3. The WJCC's CiteScore for 2019 is 0.3 and Scopus CiteScore rank 2019: General Medicine is 394/529.

RESPONSIBLE EDITORS FOR THIS ISSUE

Production Editor: Ji-Hong Lin; Production Department Director: Xiang Li; Editorial Office Director: Jin-Lai Wang.

NAME OF JOURNAL

World Journal of Clinical Cases

ISSN

ISSN 2307-8960 (online)

LAUNCH DATE

April 16, 2013

FREQUENCY

Thrice Monthly

EDITORS-IN-CHIEF

Dennis A Bloomfield, Sandro Vento, Bao-Gan Peng

EDITORIAL BOARD MEMBERS

<https://www.wjnet.com/2307-8960/editorialboard.htm>

PUBLICATION DATE

June 26, 2021

COPYRIGHT

© 2021 Baishideng Publishing Group Inc

INSTRUCTIONS TO AUTHORS

<https://www.wjnet.com/bpg/gerinfo/204>

GUIDELINES FOR ETHICS DOCUMENTS

<https://www.wjnet.com/bpg/GerInfo/287>

GUIDELINES FOR NON-NATIVE SPEAKERS OF ENGLISH

<https://www.wjnet.com/bpg/gerinfo/240>

PUBLICATION ETHICS

<https://www.wjnet.com/bpg/GerInfo/288>

PUBLICATION MISCONDUCT

<https://www.wjnet.com/bpg/gerinfo/208>

ARTICLE PROCESSING CHARGE

<https://www.wjnet.com/bpg/gerinfo/242>

STEPS FOR SUBMITTING MANUSCRIPTS

<https://www.wjnet.com/bpg/GerInfo/239>

ONLINE SUBMISSION

<https://www.f6publishing.com>



Retrospective Study

Histological transformation of non-small cell lung cancer: Clinical analysis of nine cases

Cai-Bao Jin, Ling Yang

ORCID number: Cai-Bao Jin 0000-0003-3544-5774; Ling Yang 0000-0002-5914-9614.

Author contributions: Jin CB performed the research and wrote the paper; Yang L supervised the report.

Institutional review board

statement: This study was reviewed and approved by the Ethics Committee of Hubei Cancer Hospital.

Informed consent statement:

Written informed consent was waived.

Conflict-of-interest statement: We have no financial relationships to disclose.

Data sharing statement: No additional data are available.

Open-Access: This article is an open-access article that was selected by an in-house editor and fully peer-reviewed by external reviewers. It is distributed in accordance with the Creative Commons Attribution NonCommercial (CC BY-NC 4.0) license, which permits others to distribute, remix, adapt, build upon this work non-commercially, and license their derivative works on different terms, provided the

Cai-Bao Jin, Ling Yang, Department of Thoracic Oncology, Hubei Cancer Hospital, Wuhan 430000, Hubei Province, China

Corresponding author: Ling Yang, MD, Chief Doctor, Department of Thoracic Oncology, Hubei Cancer Hospital, No. 116 Zhuodaoquan South Road, Wuhan 430000, Hubei Province, China. 348711624@qq.com

Abstract

BACKGROUND

Histological transformation is one of the numerous mechanisms of acquired resistance to epidermal growth factor receptor tyrosine kinase inhibitors (EGFR-TKIs). Given its rarity, the underlying transformational mechanisms, clinical features, and therapeutic prognoses are only studied through limited case reports.

AIM

To analyze the clinical characteristics and underlying mechanisms in non-small cell lung cancer (SCLC) patients with histological transformation after treatment with EGFR-TKIs.

METHODS

We retrospectively investigated nine patients diagnosed with non-SCLC transforming to SCLC, large-cell neuroendocrine carcinoma (LCNEC), or squamous cell carcinoma on re-biopsy after first- or third-generation EGFR-TKIs.

RESULTS

The median age of nine patients was 60 years. Among them, six patients had the EGFR 19del mutation, one had the L858R mutation, and one had wild-type EGFR. The level of plasma NSE was measured in six patients with SCLC or LCNEC transformation when transformation occurred, and five patients had elevated plasma NSE levels. All patients received standard chemotherapy after transformation with the exception of one patient who received chemotherapy and anlotinib.

CONCLUSION

Tumor re-biopsy should be performed routinely when EGFR-TKI therapy fails in lung cancer patients to avoid ignoring histological transformation and to select a subsequent therapeutic strategy. The transformed tumor retained the original EGFR mutation, indicating that histological transformation represents an

original work is properly cited and the use is non-commercial. See: <http://creativecommons.org/licenses/by-nc/4.0/>

Manuscript source: Unsolicited manuscript

Specialty type: Medicine, research and experimental

Country/Territory of origin: China

Peer-review report's scientific quality classification

Grade A (Excellent): 0
Grade B (Very good): 0
Grade C (Good): C
Grade D (Fair): 0
Grade E (Poor): 0

Received: January 26, 2021

Peer-review started: January 26, 2021

First decision: February 25, 2021

Revised: March 11, 2021

Accepted: April 12, 2021

Article in press: April 12, 2021

Published online: June 26, 2021

P-Reviewer: Pan M

S-Editor: Fan JR

L-Editor: Wang TQ

P-Editor: Wang LL



evolution from the initial tumor.

Key Words: Histological transformation; Epidermal growth factor receptor tyrosine kinase inhibitors; Non-small cell lung cancer; Tumor re-biopsy; Epidermal growth factor receptor mutation

©The Author(s) 2021. Published by Baishideng Publishing Group Inc. All rights reserved.

Core Tip: We retrospectively diagnosed nine cases of non-small cell lung cancer (SCLC) transforming to SCLC, large-cell neuroendocrine carcinoma, or squamous cell carcinoma on re-biopsy after epidermal growth factor receptor tyrosine kinase inhibitors (EGFR-TKIs). Tumor re-biopsy should be performed routinely when EGFR-TKI therapy fails in lung cancer patients to avoid ignoring histological transformation and to select a subsequent therapeutic strategy. The plasma pro-gastrin-releasing peptide and NSE levels could be valuable and significant biomarkers to predict histological transformation. The transformed tumor retained the original EGFR mutation, which indicates that histological transformation represents an evolution from the initial tumor.

Citation: Jin CB, Yang L. Histological transformation of non-small cell lung cancer: Clinical analysis of nine cases. *World J Clin Cases* 2021; 9(18): 4617-4626

URL: <https://www.wjgnet.com/2307-8960/full/v9/i18/4617.htm>

DOI: <https://dx.doi.org/10.12998/wjcc.v9.i18.4617>

INTRODUCTION

Lung cancer is the leading cause of cancer-related death worldwide and is histologically classified into non-small cell lung cancer (NSCLC) and SCLC. Epidermal growth factor receptor tyrosine kinase inhibitors (EGFR-TKIs) are the standard strategy of first-line therapy for EGFR-sensitive mutant patients with advanced or metastatic NSCLC. In a randomized phase III FLAURA study, the median progression-free survival (PFS) and overall survival (OS) of patients administered third-generation TKIs were significantly prolonged compared with those taking first-generation TKIs (18.9 mo *vs* 10.2 mo for PFS and 38.6 mo *vs* 31.8 mo for OS). Currently, the third-generation TKI osimertinib has become the preferred recommended first-line therapeutic strategy.

Although EGFR-TKIs have a favorable and lasting effect, most patients will eventually develop disease progression within 19 mo. Several mechanisms of acquired resistance to EGFR-TKIs have been reported. For first- and second-generation EGFR-TKIs, the most common mechanism is the acquisition of the T790M mutation. The other mechanisms involve alternative pathway activation, such as human epidermal growth factor receptor 2 (HER2) or methionine (MET) amplification, v-raf murine sarcoma viral oncogene homolog B mutation, and histological and phenotypic transformation, such as SCLC transformation and epithelial-mesenchymal transition [1]. For third-generation EGFR-TKIs, in a study in which plasma samples of 38 patients after progression in first-line treatment with osimertinib were collected for next-generation sequencing analysis, the genetic resistance mutations included the following: MET, EGFR, and Kirsten rat sarcoma 2 viral oncogene homolog (KRAS) amplification; PI3K3CA and KRAS mutations; and EGFR C797S mutation. Another researcher also collected and analyzed plasma samples at baseline and during the progression of the FLAURA study. No EGFR T790M mutation was detected under first-line osimertinib therapy. The acquired gene alterations included MET amplification and EGFR C797X mutation. These two studies utilized plasma samples rather than biopsied tissue specimens to study the mechanisms of acquired resistance [2].

Among the mechanisms of acquired resistance to EGFR-TKIs, histological transformation is less common. A number of studies based on case reports have investigated the characteristics and potential mechanisms of transformation to SCLC, large-cell neuroendocrine carcinoma (LCNEC), squamous cell carcinoma (SqCC), and

sarcoma after EGFR-TKIs[3]. Many reports have shown that tumor samples after transformation still retain the original EGFR mutation. In addition, tumor re-biopsy is often replaced by peripheral blood analysis during disease progression, ignoring the presence of transformation.

Here, we report nine cases of NSCLC developing histological transformation after EGFR-TKI therapy.

MATERIALS AND METHODS

Patients

Nine patients with histological transformation were hospitalized at the Department of Thoracic Oncology, Hubei Cancer Hospital (Wuhan, China) from 2014 to 2019. The related clinical data were collected through a retrospective analysis, whereas some data could not be obtained.

EGFR mutation test and immunohistochemistry

The re-biopsy specimens of patients were used to detect the EGFR mutation status through the amplification refractory mutation system in the clinical molecular diagnostic center of our hospital. Pathological diagnosis of biopsy tissues through hematoxylin and eosin and immunohistochemical staining was performed normatively in the pathology department.

RESULTS

Patient information and histological features

Nine patients, including four females and five males, showed histological transformation. Pathological results before and after transformation are presented in [Figure 1](#). Patient information and pathologic features are summarized in [Table 1](#). The median age was 60 years old. Four patients had smoked for a long time prior to diagnosis. Tissue samples were obtained from eight of nine patients through needle biopsy or cytological specimens from pleural effusion with a diagnosis of adenocarcinoma (ADC). The remaining patient was diagnosed with adenosquamous carcinoma after surgical resection. Of all cases, seven transformed to SCLC, one transformed to LCNEC, and one transformed to SqCC.

Clinical information

Initial treatment before TKIs included resection and adjuvant chemotherapy for case 2, chemotherapy and radiotherapy for case 3, palliative chemotherapy for case 5, and multiline chemotherapy and apatinib for case 6.

Of the nine patients in the first biopsy, six (cases 1, 4, 5, 7, 8, and 9) harbored EGFR exon 19 deletion mutations. The EGFR status of cases 2 and 3 was unknown or undetected. In addition, case 6 had wild-type EGFR. Five patients (cases 1, 2, 5, 7, and 9) were treated with icotinib. Three patients (cases 3, 6, and 8) were treated with gefitinib. Case 4 was treated with erlotinib. In addition, case 6 proceeded with osimertinib therapy after progression. Patients 7 and 9 also received osimertinib treatment after the second biopsy as the disease progressed, indicating EGFR exon 20 T790M and exon 19 deletion mutations. The time of TKI treatment, including the first- and third-generation agents, ranged from 11 to 21 mo.

After confirmation of histological transformation, three patients (cases 1, 4, and 5) still had the original EGFR mutation. The EGFR exon 21 L858R mutation was detected in the re-biopsy sample of case 2, whereas case 6 showed no EGFR mutation as previously noted. Unfortunately, cases 2, 7, 8 and 9 did not undergo genetic testing of EGFR.

When SCLC or LCNEC transformation occurred, the serum NSE levels of five patients (cases 2, 4, 5, 8, and 9) were elevated significantly compared with normal baseline levels. Case 6 had normal NSE levels. In addition, NSE levels were not detected in cases 1 and 7.

After transformation to SCLC or LCNEC, cases 5, 6 and 8 were treated with etoposide and cisplatin and showed a stable disease response. Case 9 achieved stable disease with docetaxel and anlotinib treatment. In addition, after the transformation to SqCC, case 3 had disease progression after two cycles of chemotherapy with docetaxel and cisplatin. The follow-up data of the remaining patients after switching to

Table 1 Clinical information, pathologic features, and epidermal growth factor receptor status of nine patients showing histological transformation

| Before transformation onset | | | | | | | | | | Post transformation onset | | | | | | | |
|-----------------------------|-------------|----------------|---------------------------|----------------|-----------------|-------------------------------|-------------------|------------------------|------------------------|---------------------------|------------------------|-----------------|--------------|--|------------------------|----------------------------|-----------------------|
| Case No. | Gender, age | Smoking status | Time of initial diagnosis | Clinical stage | Tumor histology | Sample type, acquisition site | Initial treatment | EGFR mutational status | TKI | TKI line | TKI treatment time (m) | Tumor histology | NSE level | Sample type, acquisition site | EGFR mutational status | Treatment | Response and PFS (mo) |
| 1 | M, 66 | Former | September, 2018 | T4N3M1 | ADC | Biopsy, bone | No | 19del | Iconitib | I | 11 | SCLC | ND | Biopsy, lung | 19del | CTx (etoposide/cisplatin) | ¹ |
| 2 | F, 62 | Never | 2014 | ¹ | ASC | Resection, lung | Surgery, CTx | ¹ | Iconitib | I | 14 | SCLC | Elevated | Biopsy, chest wall | ND | CTx (etoposide/lobaplatin) | ¹ |
| 3 | M, 60 | Former | January, 2016 | T4N3M1 | ADC | Biopsy, lung | CTx, RT | ND | Gefitinib | II | 15 | SqCC | Normal (SCC) | Biopsy, axillary lymph node | 21 L858R | CTx (docetaxel/cisplatin) | PD, 2 |
| 4 | M, 66 | Former | January, 2014 | T1N0M1 | ADC | Cytology, pleural effusion | No | 19del | Erlotinib | I | 21 | SCLC | Elevated | Biopsy, lung | 19del | CTx (etoposide) | ¹ |
| 5 | M, 57 | Never | February, 2017 | T4N2M1 | ADC | Biopsy, lung | CTx | 19del | Iconitib | II | 12 | LCNEC | Elevated | Biopsy, lung | 19del | CTx (etoposide/cisplatin) | SD, 4 |
| 6 ² | M, 60 | Former | July, 2016 | TxN0M1 | ADC | Biopsy, lung | CTx, Apatinib | Wide type | Gefitinib, Osimertinib | VI | 6 + 3 | SCLC | Normal | Biopsy, lung | Wide type | CTx (etoposide/cisplatin) | SD, 3 |
| 7 | F, 42 | Never | December, 2018 | TxN0M1 | ADC | Biopsy, lung | No | 19del → 19del, T790M | Iconitib → Osimertinib | I → II | 3 + 8 | SCLC | ND | Excision biopsy, supraclavicular lymph nodes | ND | CTx (etoposide/cisplatin) | ¹ |
| 8 | F, 65 | Never | May, 2019 | T2N3M1 | ADC | Biopsy, lung | No | 19del | Gefitinib | I | 16 | SCLC | Elevated | Biopsy, lung | ND | CTx (etoposide/cisplatin) | SD |
| 9 | F, 31 | Never | April, 2018 | T4N0M1 | ADC | Biopsy, lung | No | 19del → 19del, T790M | Iconitib → Osimertinib | I → II | 6 + 15 | SCLC | Elevated | Biopsy, supraclavicular lymph node | ND | Docetaxel/anlotinib | SD |

¹No available data.

²Case 6 had been treated with several kinds of chemotherapies such as pemetrexed/cisplatin, docetaxel, gemcitabine/cisplatin, and vinorelbine, and case 9 had been treated with chemotherapy and immunotherapy sequentially in clinical trial before re-biopsy. EGFR: Epidermal growth factor receptor; TKI: Tyrosine kinase inhibitor; ADC: Adenocarcinoma; ASC: Adenosquamous carcinoma; CTx: Chemotherapy; SCLC: Small cell lung cancer; M: Male; F: Female; RT: Radiotherapy; SqCC: Squamous cell carcinoma; LCNEC: Large-cell neuroendocrine carcinoma; SCC: Squamous cell carcinoma antigen; ND: Undetected; PD: Disease progression; SD: Stable disease.

chemotherapy were not obtained.

DISCUSSION

Approximately 80%-85% of lung cancers are NSCLC, among which approximately 50% of Asian patients and 16% of Caucasian patients have EGFR mutations[4,5]. Although considerable improvement has been obtained by EGFR-TKIs for EGFR-sensitive mutations, most patients will inevitably develop acquired resistance. Various mechanisms have been validated, including the EGFR T790M mutation, which accounts for 60% of first- and second-generation EGFR-TKI resistance[6]. Less common mechanisms include MET amplification, HER2 amplification, PIK3CA mutation, histological or phenotypical transformation, and others[7-10]. The most common histological transformation is ADC to SCLC, occurring in 3%-15% of patients [11]. Acquired resistance mechanisms to third-generation TKIs administered as first- or second-line therapy can also be grouped into EGFR-dependent mechanisms, including EGFR C797S and G796 mutations, and EGFR-independent mechanisms, including MET and HER2 amplification and rare histological transformation[12].

In our reported cases, cases 1, 4, 7, 8, and 9 transformed from NSCLC to SCLC after TKI therapy with EGFR mutations, and case 2 with unknown EGFR status also experienced SCLC transformation after EGFR-TKI treatment for 14 mo. Considering that the median progression-free survival of first-generation EGFR-TKIs is approximately 11 mo in treating EGFR-sensitive NSCLC, we hypothesize that case 2 may initially have had EGFR mutations. The potential mechanisms underlying SCLC transformation after TKI treatment remain controversial. On the one hand, some researchers believe that SCLC transformation occurs in NSCLC after EGFR-TKI therapy. It is impossible that SCLC could not progress during EGFR-TKI treatment for 1 year. Previously reported cases revealed that secondary biopsy specimens have the same type of EGFR mutation as the original specimens. In our study, cases 1 and 4 shared the EGFR 19del before and after transformation onset. In addition, SCLC has a lower rate of EGFR mutation than NSCLC[13]. Furthermore, alveolar type II cells may be the common progenitor of ADC and SCLC with EGFR mutations[9]. ADC cells ultimately transdifferentiate into SCLC cells regulated by genetic alterations, such as RB1 and TP53 mutations, under the selective pressure of EGFR-TKIs. On the other hand, some studies have also considered that the primary tumor consists of both ADC and SCLC, which is referred to as mixed SCLC. SCLC cells become dominant when ADC cells are eliminated by EGFR-TKIs[3]. Due to the small biopsy specimens used to confirm the diagnosis, some cases of mixed SCLC cannot be accurately identified during the initial assessment; the incidence of mixed SCLC is 12%-28% in surgical samples[14].

In the present case, case 3 with unknown EGFR status progressed after gefitinib treatment for 15 mo. Gene detection in the re-biopsy tissue revealed the EGFR L858R mutation. We deduce that this patient may have had the same EGFR mutation at diagnosis. Perez-Moreno *et al*[15] summarized the progression of 17 patients with a documented occurrence of SqCC transformation after EGFR-TKI therapy. All these patients and our present case maintained the EGFR mutation detected on ADC at diagnosis. Less than 5% of SqCC patients have EGFR mutations. Thus, it is more likely that SqCC cells arise from ADC cells. Han *et al*[16] constructed a mouse model of transdifferentiation into SqCC from Lkb-1-deficient ADCs. This study also supports the assumption of SqCC transformation under the pressure of EGFR-TKIs. However, we could not completely exclude the hypothesis that adenosquamous carcinoma exists initially and that both components harbor the same EGFR mutation. However, it is a relatively rare subtype accounting for 0.4%-4% of lung carcinomas[17].

LCNEC transformation is extremely rare. Wang *et al*[18] reported that only seven cases have transformed from ADC to LCNEC after EGFR-TKI therapy. Among them, four cases occurred after first-generation TKI treatment, the duration of which was from 10 to 96 mo[19-21]. Six of seven cases maintained the original EGFR mutation after transformation. The other three cases had a transformation after consecutive first- and third-generation TKIs[22]. The times from the beginning of first-generation TKIs to the end of third-generation TKIs were 19 mo, 21 mo, and 49 mo. In our case 5, the ADC patient with the EGFR 19del mutation transformed to LCNEC after 12 mo of icotinib treatment. The lung re-biopsy showed the same mutation. LCNEC is a high-grade neuroendocrine carcinoma with low EGFR mutation rates, the prognosis of which is worse than that of ADC. On the basis of these cases, all the cases had a long duration of TKI treatment, and most cases had the same mutation after acquired

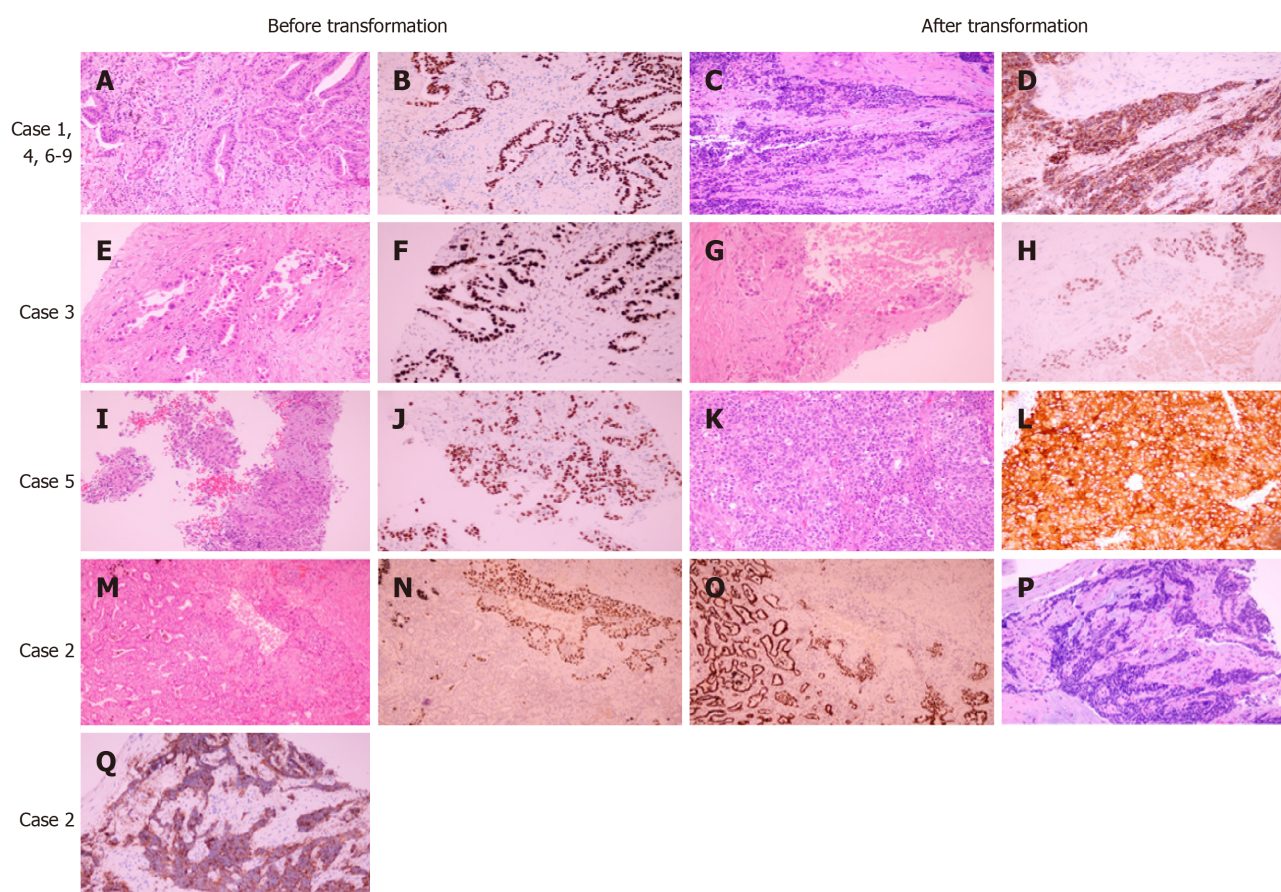


Figure 1 Pathological results of nine patients before and after transformation. A, C, E, G, I, K, M, and P: Hematoxylin and eosin stained sections; B, F, J and O: Positive staining for thyroid transcription factor 1; H and N: Positive staining for P40; D, L and Q: Positive staining for synaptophysin.

resistance. We believe that LCNEC probably transforms from ADC under the effect of EGFR-TKIs.

In our case 6, the patient with EGFR wild-type ADC also transformed to SCC after multiline therapy with gefitinib and osimertinib. This finding indicates that histologic transformation is not unique to tumors harboring EGFR mutations. Only two studies by Ahn *et al*[23] and Gu *et al*[24] reported three cases of EGFR wild-type ADC bearing SCC transformation[23,24]. One case in Ahn *et al*[23]'s study with stage I ADC was diagnosed as SCLC at the time of recurrence after surgery. It is difficult to exclude the possibility of a second primary tumor. Another case in Ahn *et al*[23]'s study experienced a transformation after gefitinib therapy of only 2 mo, indicating primary resistance. This case also suggested that SCC transformation may not exclusively result from TKI treatment. However, in the present case 6, EGFR-TKI therapy was effective, indicating acquired resistance. The transformation of our case is closely related to EGFR-TKIs.

Previous clinical studies have mostly focused on exploring the mechanisms of acquired resistance to osimertinib after first- or second-generation TKIs. In a multicentric retrospective French study of osimertinib in second-line or greater treatment, 9% of patients developed histological transformation in 56 cases with available re-biopsy samples[25]. A recent study showed that histological transformation, mainly SqCC, was identified in 15% of 27 cases with first-line osimertinib therapy[26]. In cases 6, 7 and 9, SCLC transformation occurred after osimertinib as a second-line TKI treatment. The ongoing MELROSE phase 2 trial will evaluate the resistance mechanisms in tumor tissue and liquid biopsy in EGFR mutant NSCLC patients receiving osimertinib as first-line therapy[22].

In general, chemotherapy, such as etoposide plus cisplatin, becomes the standard strategy for patients with SCLC or LCNEC transformation. Roca *et al*[27] performed a systematic analysis of 39 patients who had SCLC transformation. The survival outcome of 16 patients was available, and the median survival after SCLC diagnosis was 6 mo. Another study also retrospectively analyzed the clinical outcomes of 58 patients with EGFR mutant NSCLC undergoing SCLC transformation[28]. The median overall survival since the time of SCLC transformation was 10.9 mo. The median PFS

of patients treated with platinum-etoposide or taxanes was 3.4 mo and 2.7 mo, respectively. In previous research, the median PFS of cisplatin-based therapy for first-line treatment of both limited-stage SCLC and extensive-stage SCLC was approximately 5.5 mo, and the median OS was 9.6 mo[29]. In cases 5 and 6, the PFS from SCC transformation was just 4 and 3 mo, respectively. Therefore, the prognosis after transformation is poor.

When EGFR-mutant NSCLC progresses due to acquired resistance to TKI therapy, it is crucial for re-biopsy to further confirm the mechanisms of resistance to decide subsequent therapeutic schedules. However, in real clinical work in China, the rate of re-biopsy is especially low for various reasons, such as the convenience of peripheral blood detection and rejection of patients. In a Japanese retrospective study, the success rate of re-biopsy was 79.5%[30]. Thus, it is significant to identify and utilize biomarkers to predict which patients will experience histological transformation. Kato *et al*[31] found that plasma pro-gastrin-releasing peptide (ProGRP) levels increased before re-biopsy-confirmed SCLC transformation. Gu *et al*[24] also reported that serum ProGRP and NSE levels were markedly elevated compared with normal levels when SCLC transformation occurred. In addition, many other literature reports have shown a significant increase in NSE levels, indicating SCLC or LCNEC transformation[11,18,32,33]. In our cases, NSE levels were detected in six cases at the time of SCLC transformation. Serum NSE levels of five patients (cases 2, 4, 5, 8, and 9) were elevated, whereas that of case 6 was normal. Therefore, it is meaningful and recommended to monitor plasma ProGRP and NSE levels before invasive re-biopsies for the early prediction of SCLC or LCNEC transformation.

CONCLUSION

In conclusion, we report nine cases of histological transformation after first- or third-generation EGFR-TKIs, which included SCLC, LCNEC, and SqCC transformation. Histological transformation could occur in patients with either wild-type or mutant EGFR. The detected cases in the present report also retained the original EGFR mutation after transformation. This finding indicates that it is a great possibility that tumor cells post transformation transdifferentiate from original tumor cells before transformation. All patients received standard chemotherapy after transformation with a poor prognosis. Plasma ProGRP and NSE levels could represent valuable and significant biomarkers to predict histological transformation. In addition, tumor re-biopsy should be performed routinely when the disease progresses under EGFR-TKI treatment.

ARTICLE HIGHLIGHTS

Research background

Histological transformation is one of the numerous mechanisms of acquired resistance to epidermal growth factor receptor tyrosine kinase inhibitors (EGFR-TKIs). Given its rarity, the underlying transformational mechanisms, clinical features, and therapeutic prognosis are only studied through limited case reports.

Research motivation

The study of non-small cell lung cancer (SCLC) patients with histological transformation after treatment with EGFR-TKIs can improve our understanding of the clinical features and underlying mechanisms in this type of patient. This finding can remind us of the importance of re-biopsy when targeted drug resistance occurs.

Research objectives

The main objective of this study was to analyze the clinical characteristics and underlying mechanisms in non-SCLC (NSCLC) patients with histological transformation after treatment with EGFR-TKIs.

Research methods

We retrospectively investigated nine patients diagnosed with NSCLC transforming to SCLC, large-cell neuroendocrine carcinoma (LCNEC), or squamous cell carcinoma on re-biopsy after first- or third-generation EGFR-TKIs.

Research results

The median age of the nine patients in this study was 60 years old. Among them, six patients had the EGFR 19del mutation, one had the L858R mutation, and one had wild-type EGFR. In six patients with SCLC or LCNEC transformation, plasma NSE levels were detected when transformation occurred, and five patients had elevated plasma NSE levels. All patients received standard chemotherapy after transformation except one patient who received chemotherapy and anlotinib.

Research conclusions

Tumor re-biopsy should be performed routinely when EGFR-TKI therapy fails in lung cancer patients to avoid ignoring histological transformation and to select a subsequent therapeutic strategy. The transformed tumor retained the original EGFR mutation, which indicates that histological transformation represents an evolution from the initial tumor. Plasma pro-gastrin-releasing peptide and NSE levels could represent valuable and significant biomarkers to predict histological transformation.

Research perspectives

Due to the limited cases in this study, it is difficult to draw reliable conclusions. However, our study suggests that the plasma NSE levels potentially represent a valuable biomarker to predict histological transformation, and re-biopsy should be performed to avoid ignoring the occurrence of histological transformation. Furthermore, to a large extent, histological transformation represents an evolution from the initial tumor.

REFERENCES

- 1 **Wu SG**, Shih JY. Management of acquired resistance to EGFR TKI-targeted therapy in advanced non-small cell lung cancer. *Mol Cancer* 2018; **17**: 38 [PMID: 29455650 DOI: 10.1186/s12943-018-0777-1]
- 2 **Bennouna J**, Girard N, Audigier-Valette C, le Thaut A, Gervais R, Masson P, Marcq M, Molinier O, Cortot A, Debieuve D, Cadranel J, Lena H, Moro-Sibilot D, Chouaid C, Mennecier B, Urban T, Sagan C, Perrier L, Barlesi F, Denis MG. Phase II Study Evaluating the Mechanisms of Resistance on Tumor Tissue and Liquid Biopsy in Patients With EGFR-mutated Non-pretreated Advanced Lung Cancer Receiving Osimertinib Until and Beyond Radiologic Progression: The MELROSE Trial. *Clin Lung Cancer* 2020; **21**: e10-e14 [PMID: 31648999 DOI: 10.1016/j.clcc.2019.09.007]
- 3 **Shao Y**, Zhong DS. Histological transformation after acquired resistance to epidermal growth factor tyrosine kinase inhibitors. *Int J Clin Oncol* 2018; **23**: 235-242 [PMID: 29110101 DOI: 10.1007/s10147-017-1211-1]
- 4 **Gridelli C**, Rossi A, Carbone DP, Guarize J, Karachaliou N, Mok T, Petrella F, Spaggiari L, Rosell R. Non-small-cell lung cancer. *Nat Rev Dis Primers* 2015; **1**: 15009 [PMID: 27188576 DOI: 10.1038/nrdp.2015.9]
- 5 **Shi Y**, Au JS, Thongprasert S, Srinivasan S, Tsai CM, Khoa MT, Heeroma K, Itoh Y, Cornelio G, Yang PC. A prospective, molecular epidemiology study of EGFR mutations in Asian patients with advanced non-small-cell lung cancer of adenocarcinoma histology (PIONEER). *J Thorac Oncol* 2014; **9**: 154-162 [PMID: 24419411 DOI: 10.1097/JTO.0000000000000033]
- 6 **Westover D**, Zugazagoitia J, Cho BC, Lovly CM, Paz-Ares L. Mechanisms of acquired resistance to first- and second-generation EGFR tyrosine kinase inhibitors. *Ann Oncol* 2018; **29**: i10-i19 [PMID: 29462254 DOI: 10.1093/annonc/mdx703]
- 7 **Liu S**, Li S, Hai J, Wang X, Chen T, Quinn MM, Gao P, Zhang Y, Ji H, Cross DAE, Wong KK. Targeting *HER2* Aberrations in Non-Small Cell Lung Cancer with Osimertinib. *Clin Cancer Res* 2018; **24**: 2594-2604 [PMID: 29298799 DOI: 10.1158/1078-0432.CCR-17-1875]
- 8 **Ludovini V**, Bianconi F, Pistola L, Chiari R, Minotti V, Colella R, Giuffrida D, Tofanetti FR, Siggillino A, Flacco A, Baldelli E, Iacono D, Mameli MG, Cavaliere A, Crinò L. Phosphoinositide-3-kinase catalytic alpha and KRAS mutations are important predictors of resistance to therapy with epidermal growth factor receptor tyrosine kinase inhibitors in patients with advanced non-small cell lung cancer. *J Thorac Oncol* 2011; **6**: 707-715 [PMID: 21258250 DOI: 10.1097/JTO.0b013e31820a3a6b]
- 9 **Oser MG**, Niederst MJ, Sequist LV, Engelman JA. Transformation from non-small-cell lung cancer to small-cell lung cancer: molecular drivers and cells of origin. *Lancet Oncol* 2015; **16**: e165-e172 [PMID: 25846096 DOI: 10.1016/S1470-2045(14)71180-5]
- 10 **Song KA**, Niederst MJ, Lochmann TL, Hata AN, Kitai H, Ham J, Floros KV, Hicks MA, Hu H, Mulvey HE, Drier Y, Heisey DAR, Hughes MT, Patel NU, Lockerman EL, Garcia A, Gillepsie S, Archibald HL, Gomez-Caraballo M, Nulton TJ, Windle BE, Piotrowska Z, Sahingur SE, Taylor SM, Dozmorov M, Sequist LV, Bernstein B, Ebi H, Engelman JA, Faber AC. Epithelial-to-Mesenchymal Transition Antagonizes Response to Targeted Therapies in Lung Cancer by Suppressing BIM. *Clin Cancer Res* 2018; **24**: 197-208 [PMID: 29051323 DOI: 10.1158/1078-0432.CCR-17-1577]

- 11 **Xie Z**, Gu Y, Lin X, Ouyang M, Qin Y, Zhang J, Liu J, Mai S, Zhou C. Unexpected favorable outcome to etoposide and cisplatin in a small cell lung cancer transformed patient: a case report. *Cancer Biol Ther* 2019; **20**: 1172-1175 [PMID: [31161851](#) DOI: [10.1080/15384047.2019.1617561](#)]
- 12 **Leonetti A**, Sharma S, Minari R, Perego P, Giovannetti E, Tiseo M. Resistance mechanisms to osimertinib in EGFR-mutated non-small cell lung cancer. *Br J Cancer* 2019; **121**: 725-737 [PMID: [31564718](#) DOI: [10.1038/s41416-019-0573-8](#)]
- 13 **El Hussein S**, Khader SN. Transformation of lung adenocarcinoma to small cell lung carcinoma in the setting of tyrosine kinase inhibitor therapy: Cytological approach of a clinically challenging phenomenon. *Diagn Cytopathol* 2019; **47**: 845-850 [PMID: [31017747](#) DOI: [10.1002/dc.24193](#)]
- 14 **de Antonio DG**, Alfageme F, Gámez P, Córdoba M, Varela A; Bronchogenic Carcinoma Cooperative Group of the Spanish Society of Pneumology and Thoracic Surgery (GCCB-S). Results of surgery in small cell carcinoma of the lung. *Lung Cancer* 2006; **52**: 299-304 [PMID: [16567022](#) DOI: [10.1016/j.lungcan.2006.01.012](#)]
- 15 **Perez-Moreno P**, Brambilla E, Thomas R, Soria JC. Squamous cell carcinoma of the lung: molecular subtypes and therapeutic opportunities. *Clin Cancer Res* 2012; **18**: 2443-2451 [PMID: [22407829](#) DOI: [10.1158/1078-0432.CCR-11-2370](#)]
- 16 **Han X**, Li F, Fang Z, Gao Y, Fang R, Yao S, Sun Y, Li L, Zhang W, Ma H, Xiao Q, Ge G, Fang J, Wang H, Zhang L, Wong KK, Chen H, Hou Y, Ji H. Transdifferentiation of lung adenocarcinoma in mice with Lkb1 deficiency to squamous cell carcinoma. *Nat Commun* 2014; **5**: 3261 [PMID: [24531128](#) DOI: [10.1038/ncomms4261](#)]
- 17 **Li C**, Lu H. Adenosquamous carcinoma of the lung. *Onco Targets Ther* 2018; **11**: 4829-4835 [PMID: [30147334](#) DOI: [10.2147/OTT.S164574](#)]
- 18 **Wang H**, Zhang L, Shi X, Zhang X, Si X. Successful treatment with osimertinib and its subsequent resistance mechanism in a patient with non-small-cell lung cancer harboring acquired EGFR T790M mutation after recovery from AC0010-induced interstitial lung disease. *Onco Targets Ther* 2019; **12**: 5545-5549 [PMID: [31371992](#) DOI: [10.2147/OTT.S204689](#)]
- 19 **Kogo M**, Shimizu R, Uehara K, Takahashi Y, Kokubo M, Imai Y, Tomii K. Transformation to large cell neuroendocrine carcinoma as acquired resistance mechanism of EGFR tyrosine kinase inhibitor. *Lung Cancer* 2015; **90**: 364-368 [PMID: [26384434](#) DOI: [10.1016/j.lungcan.2015.09.002](#)]
- 20 **Lim JU**, Woo IS, Jung YH, Byeon JH, Park CK, Kim TJ, Kim HR. Transformation into large-cell neuroendocrine carcinoma associated with acquired resistance to erlotinib in nonsmall cell lung cancer. *Korean J Intern Med* 2014; **29**: 830-833 [PMID: [25378985](#) DOI: [10.3904/kjim.2014.29.6.830](#)]
- 21 **Yanagisawa S**, Morikawa N, Kimura Y, Nagano Y, Murakami K, Tabata T. Large-cell neuroendocrine carcinoma with epidermal growth factor receptor mutation: possible transformation of lung adenocarcinoma. *Respirology* 2012; **17**: 1275-1277 [PMID: [22943430](#) DOI: [10.1111/j.1440-1843.2012.02258.x](#)]
- 22 **Baglivo S**, Ludovini V, Sidoni A, Metro G, Ricciuti B, Siggillino A, Rebonato A, Messina S, Crinò L, Chiari R. Large Cell Neuroendocrine Carcinoma Transformation and EGFR-T790M Mutation as Coexisting Mechanisms of Acquired Resistance to EGFR-TKIs in Lung Cancer. *Mayo Clin Proc* 2017; **92**: 1304-1311 [PMID: [28778263](#) DOI: [10.1016/j.mayocp.2017.03.022](#)]
- 23 **Ahn S**, Hwang SH, Han J, Choi YL, Lee SH, Ahn JS, Park K, Ahn MJ, Park WY. Transformation to Small Cell Lung Cancer of Pulmonary Adenocarcinoma: Clinicopathologic Analysis of Six Cases. *J Pathol Transl Med* 2016; **50**: 258-263 [PMID: [27160687](#) DOI: [10.4132/jptm.2016.04.19](#)]
- 24 **Gu Y**, Zhu X, Cao B, Wu X, Tong X, Shao YW, Liang L. Transformation to small cell lung cancer and activation of KRAS during long-term erlotinib maintenance in a patient with non-small cell lung cancer: A case report. *Oncol Lett* 2019; **17**: 5219-5223 [PMID: [31186738](#) DOI: [10.3892/ol.2019.10196](#)]
- 25 **Mehlman C**, Cadranel J, Rousseau-Bussac G, Lacave R, Pujals A, Girard N, Callens C, Gounant V, Théou-Anton N, Friard S, Trédaniel J, Blons H, Dujon C, Duchemann B, Schischmanoff PO, Chinet T, Giroux Leprieur E. Resistance mechanisms to osimertinib in EGFR-mutated advanced non-small-cell lung cancer: A multicentric retrospective French study. *Lung Cancer* 2019; **137**: 149-156 [PMID: [31600593](#) DOI: [10.1016/j.lungcan.2019.09.019](#)]
- 26 **Schoenfeld AJ**, Chan JM, Kubota D, Sato H, Rizvi H, Daneshbod Y, Chang JC, Paik PK, Offin M, Arcila ME, Davare MA, Shinde U, Pe'er D, Rekhtman N, Kris MG, Somwar R, Riely GJ, Ladanyi M, Yu HA. Tumor Analyses Reveal Squamous Transformation and Off-Target Alterations As Early Resistance Mechanisms to First-line Osimertinib in EGFR-Mutant Lung Cancer. *Clin Cancer Res* 2020; **26**: 2654-2663 [PMID: [31911548](#) DOI: [10.1158/1078-0432.CCR-19-3563](#)]
- 27 **Roca E**, Gurizzan C, Amoroso V, Vermi W, Ferrari V, Berruti A. Outcome of patients with lung adenocarcinoma with transformation to small-cell lung cancer following tyrosine kinase inhibitors treatment: A systematic review and pooled analysis. *Cancer Treat Rev* 2017; **59**: 117-122 [PMID: [28806542](#) DOI: [10.1016/j.ctrv.2017.07.007](#)]
- 28 **Marcoux N**, Gettinger SN, O'Kane G, Arbour KC, Neal JW, Husain H, Evans TL, Brahmer JR, Muzikansky A, Bonomi PD, Del Prete S, Wurtz A, Farago AF, Dias-Santagata D, Mino-Kenudson M, Reckamp KL, Yu HA, Wakelee HA, Shepherd FA, Piotrowska Z, Sequist LV. EGFR-Mutant Adenocarcinomas That Transform to Small-Cell Lung Cancer and Other Neuroendocrine Carcinomas: Clinical Outcomes. *J Clin Oncol* 2019; **37**: 278-285 [PMID: [30550363](#) DOI: [10.1200/JCO.18.01585](#)]
- 29 **Kalemkerian GP**. Small Cell Lung Cancer. *Semin Respir Crit Care Med* 2016; **37**: 783-796 [PMID: [27732999](#) DOI: [10.1055/s-0036-1592116](#)]
- 30 **Nosaki K**, Satouchi M, Kurata T, Yoshida T, Okamoto I, Katakami N, Imamura F, Tanaka K,

- Yamane Y, Yamamoto N, Kato T, Kiura K, Saka H, Yoshioka H, Watanabe K, Mizuno K, Seto T. Re-biopsy status among non-small cell lung cancer patients in Japan: A retrospective study. *Lung Cancer* 2016; **101**: 1-8 [PMID: 27794396 DOI: 10.1016/j.lungcan.2016.07.007]
- 31 **Kato Y**, Tanaka Y, Hino M, Gemma A. ProGRP as early predictive marker of non-small-cell lung cancer to small-cell lung cancer transformation after EGFR-TKI treatment. *Respir Med Case Rep* 2019; **27**: 100837 [PMID: 31016132 DOI: 10.1016/j.rmcr.2019.100837]
- 32 **Fiore M**, Trecca P, Perrone G, Amato M, Righi D, Trodella L, D'Angelillo RM, Ramella S. Histologic transformation to small-cell lung cancer following gefitinib and radiotherapy in a patient with pulmonary adenocarcinoma. *Tumori* 2019; **105**: NP12-NP16 [PMID: 30799776 DOI: 10.1177/0300891619832261]
- 33 **Lu H**, Chen B, Qin J, Xie F, Han N, Huang Z. Transformation to small-cell lung cancer following treatment with icotinib in a patient with lung adenocarcinoma. *Oncol Lett* 2018; **15**: 5799-5802 [PMID: 29552210 DOI: 10.3892/ol.2018.8040]



Published by **Baishideng Publishing Group Inc**
7041 Koll Center Parkway, Suite 160, Pleasanton, CA 94566, USA

Telephone: +1-925-3991568

E-mail: bpgoffice@wjgnet.com

Help Desk: <https://www.f6publishing.com/helpdesk>

<https://www.wjgnet.com>

