

World Journal of *Clinical Cases*

World J Clin Cases 2021 June 26; 9(18): 4460-4880



OPINION REVIEW

- 4460** Surgery for pancreatic tumors in the midst of COVID-19 pandemic

Kato H, Asano Y, Arakawa S, Ito M, Kawabe N, Shimura M, Hayashi C, Ochi T, Yasuoka H, Higashiguchi T, Kondo Y, Nagata H, Horiguchi A

REVIEW

- 4467** Roles of exosomes in diagnosis and treatment of colorectal cancer

Umwali Y, Yue CB, Gabriel ANA, Zhang Y, Zhang X

MINIREVIEWS

- 4480** Dynamics of host immune responses to SARS-CoV-2

Taherkhani R, Taherkhani S, Farshadpour F

- 4491** Current treatment for hepatitis C virus/human immunodeficiency virus coinfection in adults

Laiwatthanapaisan R, Sirinawasatien A

- 4500** Anti-tumor effect of statin on pancreatic adenocarcinoma: From concept to precision medicine

Huang CT, Liang YJ

- 4506** Roles of vitamin A in the regulation of fatty acid synthesis

Yang FC, Xu F, Wang TN, Chen GX

ORIGINAL ARTICLE

Basic Study

- 4520** Identification of the circRNA-miRNA-mRNA regulatory network and its prognostic effect in colorectal cancer

Yin TF, Zhao DY, Zhou YC, Wang QQ, Yao SK

- 4542** Tetramethylpyrazine inhibits proliferation of colon cancer cells *in vitro*

Li H, Hou YX, Yang Y, He QQ, Gao TH, Zhao XF, Huo ZB, Chen SB, Liu DX

Case Control Study

- 4553** Significance of highly phosphorylated insulin-like growth factor binding protein-1 and cervical length for prediction of preterm delivery in twin pregnancies

Lan RH, Song J, Gong HM, Yang Y, Yang H, Zheng LM

Retrospective Cohort Study

- 4559** Expected outcomes and patients' selection before chemoembolization—"Six-and-Twelve or Pre-TACE-Predict" scores may help clinicians: Real-life French cohorts results

Adhoue X, Larrey E, Anty R, Chevallier P, Penaranda G, Tran A, Bronowicki JP, Raoul JL, Castellani P, Perrier H, Bayle O, Monnet O, Pol B, Bourliere M

Retrospective Study

- 4573** Application of intelligent algorithms in Down syndrome screening during second trimester pregnancy
Zhang HG, Jiang YT, Dai SD, Li L, Hu XN, Liu RZ
- 4585** Evaluation of a five-gene signature associated with stromal infiltration for diffuse large B-cell lymphoma
Nan YY, Zhang WJ, Huang DH, Li QY, Shi Y, Yang T, Liang XP, Xiao CY, Guo BL, Xiang Y
- 4599** Efficacy of combination of localized closure, ethacridine lactate dressing, and phototherapy in treatment of severe extravasation injuries: A case series
Lu YX, Wu Y, Liang PF, Wu RC, Tian LY, Mo HY
- 4607** Observation and measurement of applied anatomical features for thoracic intervertebral foramen puncture on computed tomography images
Wang R, Sun WW, Han Y, Fan XX, Pan XQ, Wang SC, Lu LJ
- 4617** Histological transformation of non-small cell lung cancer: Clinical analysis of nine cases
Jin CB, Yang L
- 4627** Diagnostic value of amygdala volume on structural magnetic resonance imaging in Alzheimer's disease
Wang DW, Ding SL, Bian XL, Zhou SY, Yang H, Wang P
- 4637** Comparison of ocular axis and corneal diameter between entropion and non-entropion eyes in children with congenital glaucoma
Wang Y, Hou ZJ, Wang HZ, Hu M, Li YX, Zhang Z

Observational Study

- 4644** Risk factors for postoperative delayed gastric emptying in ovarian cancer treated with cytoreductive surgery and hyperthermic intraperitoneal chemotherapy
Cui GX, Wang ZJ, Zhao J, Gong P, Zhao SH, Wang XX, Bai WP, Li Y
- 4654** Clinical characteristics, gastrointestinal manifestations and outcomes of COVID-19 patients in Iran; does the location matters?
Mokarram P, Dalivand MM, Pizuorno A, Aligolighasemabadi F, Sadeghdoust M, Sadeghdoust E, Aduli F, Oskrochi G, Brim H, Ashktorab H
- 4668** AWGS2019 vs EWGSOP2 for diagnosing sarcopenia to predict long-term prognosis in Chinese patients with gastric cancer after radical gastrectomy
Wu WY, Dong JJ, Huang XC, Chen ZJ, Chen XL, Dong QT, Bai YY

Prospective Study

- 4681** Clinical outcomes and 5-year follow-up results of keratosis pilaris treated by a high concentration of glycolic acid

Tian Y, Li XX, Zhang JJ, Yun Q, Zhang S, Yu JY, Feng XJ, Xia AT, Kang Y, Huang F, Wan F

Randomized Controlled Trial

- 4690** Tenofovir disoproxil fumarate in Chinese chronic hepatitis B patients: Results of a multicenter, double-blind, double-dummy, clinical trial at 96 weeks

Chen XF, Fan YN, Si CW, Yu YY, Shang J, Yu ZJ, Mao Q, Xie Q, Zhao W, Li J, Gao ZL, Wu SM, Tang H, Cheng J, Chen XY, Zhang WH, Wang H, Xu ZN, Wang L, Dai J, Xu JH

SYSTEMATIC REVIEWS

- 4700** Mesenteric ischemia in COVID-19 patients: A review of current literature

Kerawala AA, Das B, Solangi A

- 4709** Role of theories in school-based diabetes care interventions: A critical review

An RP, Li DY, Xiang XL

CASE REPORT

- 4721** Alport syndrome combined with lupus nephritis in a Chinese family: A case report

Liu HF, Li Q, Peng YQ

- 4728** Botulinum toxin injection for Cockayne syndrome with muscle spasticity over bilateral lower limbs: A case report

Hsu LC, Chiang PY, Lin WP, Guo YH, Hsieh PC, Kuan TS, Lien WC, Lin YC

- 4734** Meigs' syndrome caused by granulosa cell tumor accompanied with intrathoracic lesions: A case report

Wu XJ, Xia HB, Jia BL, Yan GW, Luo W, Zhao Y, Luo XB

- 4741** Primary mesonephric adenocarcinoma of the fallopian tube: A case report

Xie C, Shen YM, Chen QH, Bian C

- 4748** Pancreas-preserving duodenectomy for treatment of a duodenal papillary tumor: A case report

Wu B, Chen SY, Li Y, He Y, Wang XX, Yang XJ

- 4754** Pheochromocytoma with abdominal aortic aneurysm presenting as recurrent dyspnea, hemoptysis, and hypotension: A case report

Zhao HY, Zhao YZ, Jia YM, Mei X, Guo SB

- 4760** Minimally invasive removal of a deep-positioned cannulated screw from the femoral neck: A case report

Yang ZH, Hou FS, Yin YS, Zhao L, Liang X

- 4765** Splenic Kaposi's sarcoma in a human immunodeficiency virus-negative patient: A case report

Zhao CJ, Ma GZ, Wang YJ, Wang JH

- 4772** Neonatal syringocystadenoma papilliferum: A case report
Jiang HJ, Zhang Z, Zhang L, Pu YJ, Zhou N, Shu H
- 4778** Disappeared intralenticular foreign body: A case report
Xue C, Chen Y, Gao YL, Zhang N, Wang Y
- 4783** Femoral neck stress fractures after trampoline exercise: A case report
Nam DC, Hwang SC, Lee EC, Song MG, Yoo JI
- 4789** Collision carcinoma of the rectum involving neuroendocrine carcinoma and adenocarcinoma: A case report
Zhao X, Zhang G, Li CH
- 4797** Therapeutic effect of autologous concentrated growth factor on lower-extremity chronic refractory wounds: A case report
Liu P, Liu Y, Ke CN, Li WS, Liu YM, Xu S
- 4803** Cutaneous myiasis with eosinophilic pleural effusion: A case report
Fan T, Zhang Y, Lv Y, Chang J, Bauer BA, Yang J, Wang CW
- 4810** Severe hematuria due to vesical varices in a patient with portal hypertension: A case report
Wei ZJ, Zhu X, Yu HT, Liang ZJ, Gou X, Chen Y
- 4817** Rare coexistence of multiple manifestations secondary to thalamic hemorrhage: A case report
Yu QW, Ye TF, Qian WJ
- 4823** Anderson-Fabry disease presenting with atrial fibrillation as earlier sign in a young patient: A case report
Kim H, Kang MG, Park HW, Park JR, Hwang JY, Kim K
- 4829** Long-term response to avelumab and management of oligoprogression in Merkel cell carcinoma: A case report
Leão I, Marinho J, Costa T
- 4837** Central pontine myelinolysis mimicking glioma in diabetes: A case report
Shi XY, Cai MT, Shen H, Zhang JX
- 4844** Microscopic transduodenal excision of an ampullary adenoma: A case report and review of the literature
Zheng X, Sun QJ, Zhou B, Jin M, Yan S
- 4852** Growth hormone cocktail improves hepatopulmonary syndrome secondary to hypopituitarism: A case report
Ji W, Nie M, Mao JF, Zhang HB, Wang X, Wu XY
- 4859** Low symptomatic COVID-19 in an elderly patient with follicular lymphoma treated with rituximab-based immunotherapy: A case report
Łęcki S, Wyżgolik K, Nicze M, Georgiew-Nadziakiewicz S, Chudek J, Wdowiak K

- 4866** Adult rhabdomyosarcoma originating in the temporal muscle, invading the skull and meninges: A case report

Wang GH, Shen HP, Chu ZM, Shen J

- 4873** *Listeria monocytogenes* bacteremia in a centenarian and pathogen traceability: A case report

Zhang ZY, Zhang XA, Chen Q, Wang JY, Li Y, Wei ZY, Wang ZC

ABOUT COVER

Editorial Board Member of *World Journal of Clinical Cases*, Shingo Tsujinaka, MD, PhD, Assistant Professor, Senior Lecturer, Surgeon, Department of Surgery, Saitama Medical Center, Jichi Medical University, Saitama 330-8503, Japan. tsujinakas@omiya.jichi.ac.jp

AIMS AND SCOPE

The primary aim of *World Journal of Clinical Cases* (WJCC, *World J Clin Cases*) is to provide scholars and readers from various fields of clinical medicine with a platform to publish high-quality clinical research articles and communicate their research findings online.

WJCC mainly publishes articles reporting research results and findings obtained in the field of clinical medicine and covering a wide range of topics, including case control studies, retrospective cohort studies, retrospective studies, clinical trials studies, observational studies, prospective studies, randomized controlled trials, randomized clinical trials, systematic reviews, meta-analysis, and case reports.

INDEXING/ABSTRACTING

The WJCC is now indexed in Science Citation Index Expanded (also known as SciSearch®), Journal Citation Reports/Science Edition, Scopus, PubMed, and PubMed Central. The 2020 Edition of Journal Citation Reports® cites the 2019 impact factor (IF) for WJCC as 1.013; IF without journal self cites: 0.991; Ranking: 120 among 165 journals in medicine, general and internal; and Quartile category: Q3. The WJCC's CiteScore for 2019 is 0.3 and Scopus CiteScore rank 2019: General Medicine is 394/529.

RESPONSIBLE EDITORS FOR THIS ISSUE

Production Editor: Ji-Hong Lin; Production Department Director: Xiang Li; Editorial Office Director: Jin-Lai Wang.

NAME OF JOURNAL

World Journal of Clinical Cases

ISSN

ISSN 2307-8960 (online)

LAUNCH DATE

April 16, 2013

FREQUENCY

Thrice Monthly

EDITORS-IN-CHIEF

Dennis A Bloomfield, Sandro Vento, Bao-Gan Peng

EDITORIAL BOARD MEMBERS

<https://www.wjgnet.com/2307-8960/editorialboard.htm>

PUBLICATION DATE

June 26, 2021

COPYRIGHT

© 2021 Baishideng Publishing Group Inc

INSTRUCTIONS TO AUTHORS

<https://www.wjgnet.com/bpg/gerinfo/204>

GUIDELINES FOR ETHICS DOCUMENTS

<https://www.wjgnet.com/bpg/GerInfo/287>

GUIDELINES FOR NON-NATIVE SPEAKERS OF ENGLISH

<https://www.wjgnet.com/bpg/gerinfo/240>

PUBLICATION ETHICS

<https://www.wjgnet.com/bpg/GerInfo/288>

PUBLICATION MISCONDUCT

<https://www.wjgnet.com/bpg/gerinfo/208>

ARTICLE PROCESSING CHARGE

<https://www.wjgnet.com/bpg/gerinfo/242>

STEPS FOR SUBMITTING MANUSCRIPTS

<https://www.wjgnet.com/bpg/GerInfo/239>

ONLINE SUBMISSION

<https://www.f6publishing.com>

Retrospective Study

Diagnostic value of amygdala volume on structural magnetic resonance imaging in Alzheimer's disease

De-Wei Wang, Shou-Luan Ding, Xian-Li Bian, Shi-Yue Zhou, Hui Yang, Ping Wang

ORCID number: De-Wei Wang 0000-0001-6577-016X; Shou-Luan Ding 0000-0003-2170-2653; Xian-Li Bian 0000-0002-9117-6858; Shi-Yue Zhou 0000-0002-1805-2074; Hui Yang 0000-0003-1368-490X; Ping Wang 0000-0003-2661-5292.

Author contributions: Wang P designed the study; Wang DW wrote the paper; Bian XL, Zhou SY, and Yang H drafted the work and collected the data; Ding SL collected and analyzed the data.

Supported by The Young Talents Fund of the Second Hospital of Shandong University, No. 2018YT16; Rongxiang Regenerative Medicine Foundation of Shandong University, No. 2019SDRX-09.

Institutional review board statement: The study was approved by the Medical Research Ethics Committee of the Second Hospital of Shandong University.

Informed consent statement: All study participants, or their legal guardian, provided informed written consent prior to study enrollment.

Conflict-of-interest statement: The author declares that there is no conflict of interest between them.

Data sharing statement: No

De-Wei Wang, Xian-Li Bian, Hui Yang, Ping Wang, Department of Neurology, The Second Hospital, Cheeloo College of Medicine, Shandong University, Jinan 250033, Shandong Province, China

Shou-Luan Ding, Center for Evidence-Based Medicine, Institute of Medical Sciences, The Second Hospital, Cheeloo College of Medicine, Shandong University, Jinan 250033, Shandong Province, China

Shi-Yue Zhou, Cheeloo College of Medicine, Shandong University, Jinan 250012, Shandong Province, China

Corresponding author: Ping Wang, PhD, Associate Chief Physician, Department of Neurology, The Second Hospital, Cheeloo College of Medicine, Shandong University, No. 247 Beiyuan Street, Jinan 250033, Shandong Province, China. wping0108@163.com

Abstract

BACKGROUND

The main clinical manifestation of Alzheimer's disease (AD) is memory loss, which can be accompanied by neuropsychiatric symptoms at different stages of the disease. Amygdala is closely related to emotion and memory.

AIM

To evaluate the diagnostic value of amygdala on structural magnetic resonance imaging (sMRI) for AD.

METHODS

In this study, 22 patients with AD and 26 controls were enrolled. Their amygdala volumes were measured by sMRI and analyzed using an automatic analysis software.

RESULTS

The bilateral amygdala volumes of AD patients were significantly lower than those of the controls and were positively correlated with the hippocampal volumes. Receiver operating characteristic curve analyses showed that the sensitivity of the left and right amygdala volumes in diagnosing AD was 80.8% and 88.5%, respectively. Subgroup analyses showed that amygdala atrophy was more serious in AD patients with neuropsychiatric symptoms, which mainly included irritability (22.73%), sleep difficulties (22.73%), apathy (18.18%), and

additional data are available.

Open-Access: This article is an open-access article that was selected by an in-house editor and fully peer-reviewed by external reviewers. It is distributed in accordance with the Creative Commons Attribution NonCommercial (CC BY-NC 4.0) license, which permits others to distribute, remix, adapt, build upon this work non-commercially, and license their derivative works on different terms, provided the original work is properly cited and the use is non-commercial. See: <http://creativecommons.org/licenses/by-nc/4.0/>

Manuscript source: Unsolicited manuscript

Specialty type: Clinical Neurology

Country/Territory of origin: China

Peer-review report's scientific quality classification

Grade A (Excellent): 0
Grade B (Very good): B
Grade C (Good): 0
Grade D (Fair): 0
Grade E (Poor): 0

Received: March 2, 2021

Peer-review started: March 2, 2021

First decision: April 4, 2021

Revised: April 6, 2021

Accepted: April 26, 2021

Article in press: April 26, 2021

Published online: June 26, 2021

P-Reviewer: Rakhya P

S-Editor: Wang JL

L-Editor: Filipodia

P-Editor: Liu JH



hallucination (13.64%).

CONCLUSION

Amygdala volumes measured by sMRI can be used to diagnose AD, and amygdala atrophy is more serious in patients with neuropsychiatric symptoms.

Key Words: Alzheimer's disease; Amygdala; Structural magnetic resonance imaging; Neuropsychiatric symptoms

©The Author(s) 2021. Published by Baishideng Publishing Group Inc. All rights reserved.

Core Tip: Amygdala volume measured by structural magnetic resonance imaging can be used for the diagnosis of Alzheimer's disease, and the degree of amygdala atrophy is more severe in patients with neuropsychiatric symptoms.

Citation: Wang DW, Ding SL, Bian XL, Zhou SY, Yang H, Wang P. Diagnostic value of amygdala volume on structural magnetic resonance imaging in Alzheimer's disease. *World J Clin Cases* 2021; 9(18): 4627-4636

URL: <https://www.wjgnet.com/2307-8960/full/v9/i18/4627.htm>

DOI: <https://dx.doi.org/10.12998/wjcc.v9.i18.4627>

INTRODUCTION

Amygdala, a part of the medial temporal lobe, is closely related to emotion and memory, and is one of the key brain regions in the pathogenesis of Alzheimer's disease (AD)[1,2]. Studies have shown that the dysfunction of amygdala plays an important role in the emotional disorder of AD[3,4]. The pathological changes of AD brain such as senile plaque formation, nerve fiber tangle and neuron loss can appear in the amygdala[5-8]. Clinical studies have shown that injury of the amygdala can lead to agitation, irritability, anxiety, and apathy[9-11]. Patients with anxiety disorder, autism, phobia, and post-traumatic stress disorder can have dysfunction of amygdala[12,13]. Medial temporal lobe is the earliest site of brain atrophy in AD[14]. There have been a lot of studies on MRI to evaluate the degree of atrophy of medial temporal lobe, but few studies on amygdala[15,16].

In this study, the amygdala volumes were measured by structural magnetic resonance imaging (sMRI) both in AD patients and controls to evaluate the diagnostic value of amygdala. The correlation between amygdala atrophy and clinical features of AD was also analyzed.

MATERIALS AND METHODS

Participants

Twenty-two patients with AD and twenty-six controls were recruited from the Second Hospital of Shandong University (Shandong, China) between May 2017 and July 2019. The average age of the AD group was 73.9 ± 7.5 years, and the ratio of male to female was 1:1. Among the 22 patients, 4 cases were mild AD, 10 cases were moderate AD, and 8 cases were severe AD (Table 1). The inclusion and exclusion criteria were shown in our published article[17]. The study was approved by the Medical Research Ethics Committee of the Second Hospital of Shandong University and informed consent was obtained from all participants.

Neuropsychological tests

All subjects received a cranial MRI scan and underwent neuropsychological tests including the Chinese version of the Mini Mental State examination[18], the Clinical Dementia Rating (CDR) scale (0: No dementia; 1: Mild dementia; 2: Moderate dementia; and 3: Severe dementia)[19], the Hamilton depression scale, and neuropsychiatric inventory (NPI)[20,21]. The NPI scale was used to evaluate the mental and

Table 1 Demographics characteristics of all participants

Characteristics	AD, <i>n</i> = 22	Control, <i>n</i> = 26	<i>P</i> value
Age (yr)	74.7 ± 8.9	70.8 ± 8.5	0.12 ¹
Gender (female/male)	11/11	14/12	0.79 ²
Education (yr)	5.1 (4.6-11.2)	6.2 (3.1-10.9)	0.85 ³
CDR (0/1/2/3)	0/4/10/8	26/0/0/0	-
MMSE	13.6 ± 8.0	27.8 ± 1.5	< 0.001 ¹
Onset times (yr)	3.8 (2.5-8.5)	-	-

¹*P* values were calculated by Student's *t*-test.

²*P* values were calculated by χ^2 test.

³*P* values were calculated by Mann-Whitney *U* test. *P* < 0.05 was considered statistically significant. AD: Alzheimer's disease; CDR: Clinical Dementia Rating; MMSE: Mini Mental State examination.

behavioral symptoms of all AD patients and the severity of the symptoms was graded. The scale scores included the total scores of patients and psychological distress scores of caregivers. The former was obtained by multiplying the frequency of mental symptoms by the severity[20,21].

Acquisition and processing of images

All subjects received three-dimensional brain volume sequence brain MRI scans. T1-weighted image were analyzed using a set of automated analysis tools, and the steps were described in detail in our previous article[17]. The bilateral amygdala volumes were measured both in AD patients and controls.

Statistical analyses

Categorical variable data are expressed as a frequency and percentage. Numerical data are presented as the mean ± SD or median (interquartile range). Spearman's rank or Pearson correlation coefficient was used for the correlation analyses. Quantitative values were compared using the Student's *t*-test or Mann-Whitney *U* test. One-way analysis of variance or the Kruskal-Wallis test was used to compare the data among three groups. The χ^2 test was used to assess differences in categorical data. Diagnostic values were evaluated by receiver operating characteristic (ROC) curves and the area under the curve (AUC). *P* < 0.05 was considered for a statistically significant difference. Statistical analyses were performed using SPSS Statistics (version 24.0) and GraphPad Prism version 5.0 software.

RESULTS

Amygdala volume

The left amygdala volume of the AD group was 1170.75 ± 402.63 mm³, and that of the control group was 1559.65 ± 289.02 mm³. The right amygdala volume of the AD group was 1342.01 ± 307.68 mm³, and that of the control group was 1629.97 ± 250.24 mm³. Student's *t*-test showed that the bilateral amygdala volume in the AD group was significantly smaller than that in the control group (Figure 1, *P* < 0.01).

Subgroup analysis

The severity of dementia was graded by CDR score (4 mild AD, 10 moderate AD, 8 severe AD). As shown in Figure 2, the bilateral amygdala volume became smaller with the aggravation of dementia, but there was no significant statistical difference among the three subgroups (Figure 2, *P* > 0.05).

Student's *t*-test was used to compare the bilateral volume of the amygdala. There was no significant difference between the left and right amygdala (Figure 3A, *P* > 0.05). Twenty-five women and twenty-three men were recruited in this study. Student's *t*-test was used to observe the difference in amygdala volume between different genders. As shown in Figure 3B and C, there was no significant difference in amygdala volume between the female and male subjects (*P* > 0.05).

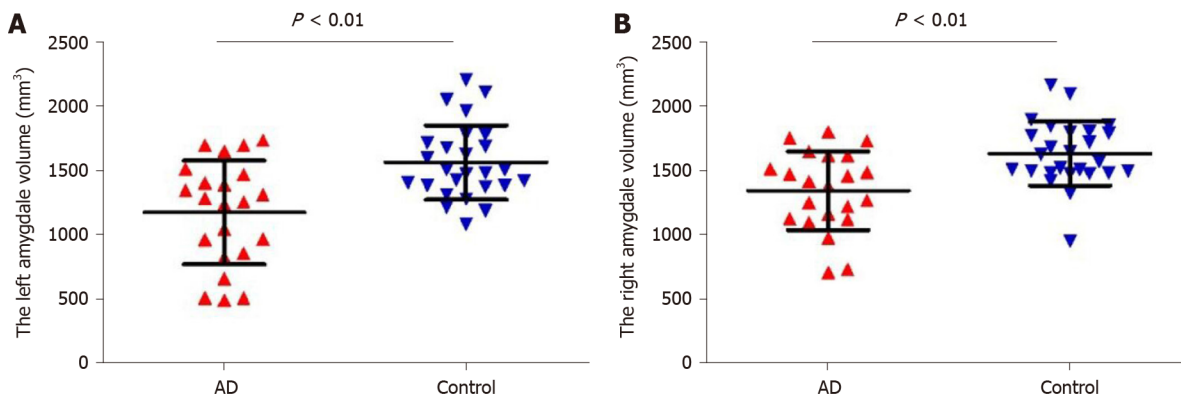


Figure 1 Comparison of amygdala magnetic resonance imaging parameters in two groups. The left and right amygdala volumes of Alzheimer's disease patients were significantly lower than controls. A: Left amygdala volume; B: Right amygdala volume. AD: Alzheimer's disease.

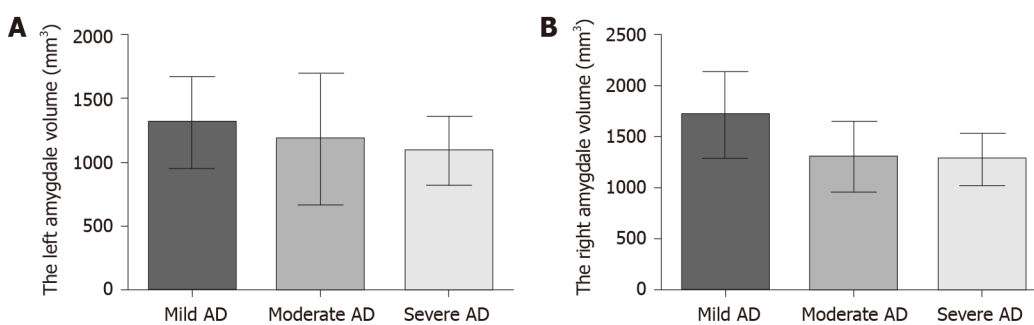


Figure 2 Amygdala volume in different dementia severity. There was no significant difference in the left and right amygdala volume among the three subgroups ($P > 0.05$). A: Left amygdala volume; B: Right amygdala volume. AD: Alzheimer's disease.

Amygdala and neuropsychiatric symptoms

NPI can be used to evaluate the mental symptoms of dementia patients and the psychological distress of caregivers. All AD patients were divided into two groups according to mental symptoms. Thirteen patients had mental symptoms according to NPI scores (Table 2). The volumes of the bilateral amygdala were significantly different between the two groups, and the atrophy of AD patients with mental symptoms was more serious (Figure 4A, $P = 0.0002$; Figure 4B, $P = 0.042$).

As shown in Table 3, 59.1% (13/22) of the AD patients had at least one kind of neuropsychiatric symptom, the most common of which was irritability (22.73%), sleep difficulties (22.73%), apathy (18.18%), and hallucination (13.64%). For mild AD ($n = 4$), one patient (25%) had mental symptoms, manifested as irritability and agitation. Sixty percent (6/10) of moderate AD patients showed abnormal mental behavior, of which irritability and delusion were the most common. Seventy-five percent (6/8) of severe patients had neuropsychiatric symptom, and irritability and delusion were the most common.

Pearson correlation analysis showed that there was no significant correlation between NPI scores and amygdala volumes (Figure 5A and B, $P > 0.05$). In addition, there was no correlation between the psychological distress scores of caregivers and amygdala volumes (Figure 5C and D, $P > 0.05$).

Correlation between amygdala and hippocampal volume

Hippocampal atrophy is a characteristic imaging manifestation of AD, the amygdala attaches to its end, both of them are involved in the pathogenesis of AD. Our previous study measured the volume of hippocampus in all subjects[17]. To further evaluate the relationship between the two brain regions, we analyzed the correlation between the volume of the amygdala and hippocampus.

Pearson correlation analysis showed that there was a significant correlation between left amygdala and hippocampal volumes (Figure 6A, $r = 0.562$, 95%CI: 0.330-0.729, $P < 0.001$). As shown in Figure 6B, there was a significant correlation between the right amygdala volume and hippocampal volume ($r = 0.435$, 95%CI: 0.172-0.640, $P < 0.001$).

Table 2 Neuropsychiatric inventory score and psychological distress scores of caregivers

Case	NPI score, points	Item score, points	Psychological distress scores of caregivers, points
1	27	Hallucination 6, irritability 12, sleep difficulties 9	10
2	24	Hallucination 12, sleep difficulties 12	6
3	14	Agitation 6, irritable 8	6
4	20	Disinhibition 12, sleep difficulties 8	9
5	20	Anxiety 8, indifference 12	6
6	24	Agitation 12, irritable 12	8
7	12	Hallucination 12	5
8	21	Indifference 12, irritable 9	7
9	32	Delusion 12, aggressive 8, sleep difficulties 12	13
10	12	Depression 12	4
11	20	Delusion 12, irritable 8	9
12	18	Indifference 12, sleep difficulties 6	8
13	12	Indifference 12	4

NPI: Neuropsychiatric inventory.

Table 3 Mental symptoms of Alzheimer's disease patients, *n* (%)

Symptoms	Total cases, <i>n</i> = 22	Mild AD, <i>n</i> = 4	Moderate AD, <i>n</i> = 10	Severe AD, <i>n</i> = 8
Irritability	5 (22.73)	1 (25)	2 (20)	2 (25)
Sleep difficulties	5 (22.73)	0	4 (40)	1 (12.5)
Indifference	4 (18.18)	0	3 (30)	1 (12.5)
Hallucination	3 (13.64)	0	2 (20)	1 (12.5)
Agitation	2 (9.09)	1 (25)	1 (10)	0
Delusion	2 (9.09)	0	0	2 (25)
Disinhibition	1 (4.55)	0	0	1 (12.5)
Anxiety	1 (4.55)	0	1 (10)	0
Aggressive	1 (4.55)	0	0	1 (12.5)
Depression	1 (4.55)	0	0	1 (12.5)
At least one of the above symptoms	13 (59.1)	1 (25)	6 (60)	6 (75)

AD: Alzheimer's disease.

ROC curve analysis

To evaluate the potential of amygdala volume serving as a novel biomarker for AD, ROC curves were plotted. The AUC was 0.761 for the left amygdala volume, the sensitivity was 80.8%, the specificity was 63.6%, and the cutoff point was 1358 (Figure 7A, $P = 0.002$). The AUC was 0.771 for the right amygdala volume, the sensitivity was 88.5%, the specificity was 63.6% and the cutoff point was 1472 (Figure 7B, $P = 0.001$).

DISCUSSION

In this study, the amygdala volumes were measured by sMRI and analyzed using a set of automated analysis tools to evaluate the diagnostic value of amygdala for AD. The

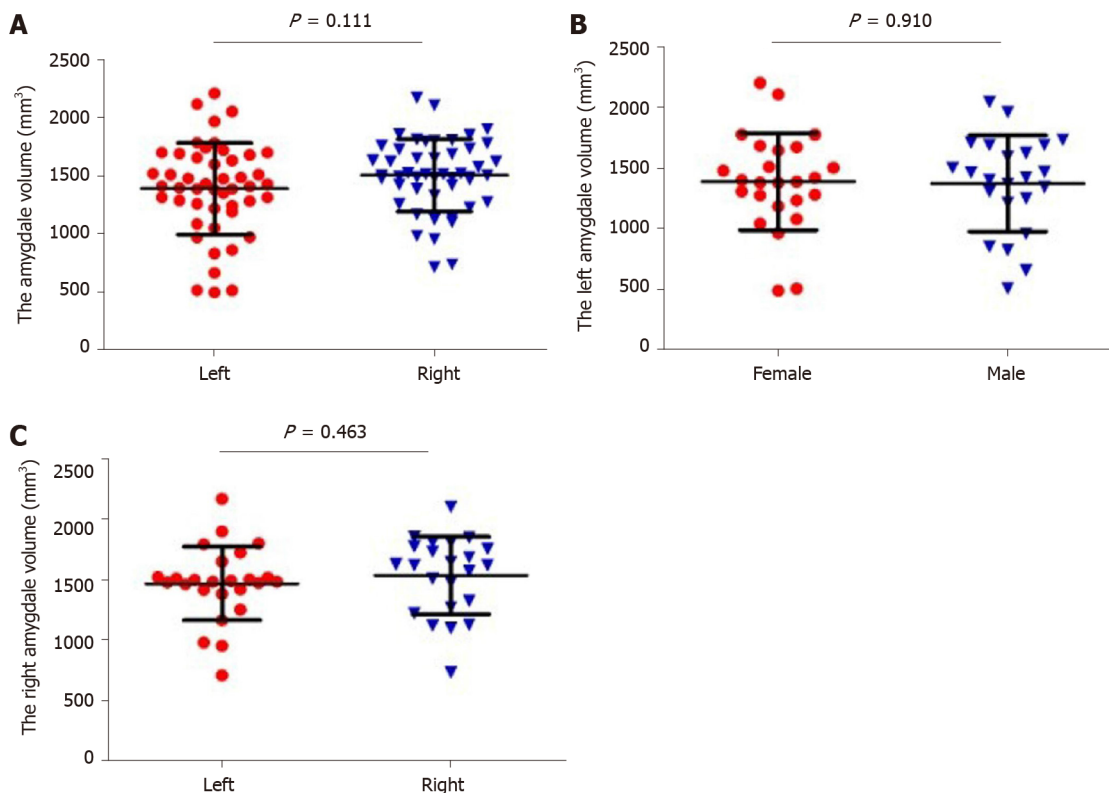


Figure 3 Amygdala volume between different sides and genders. A: There was no significant difference between left and right amygdala ($P > 0.05$); B, C: There was no significant difference in amygdala volume between different genders ($P > 0.05$).

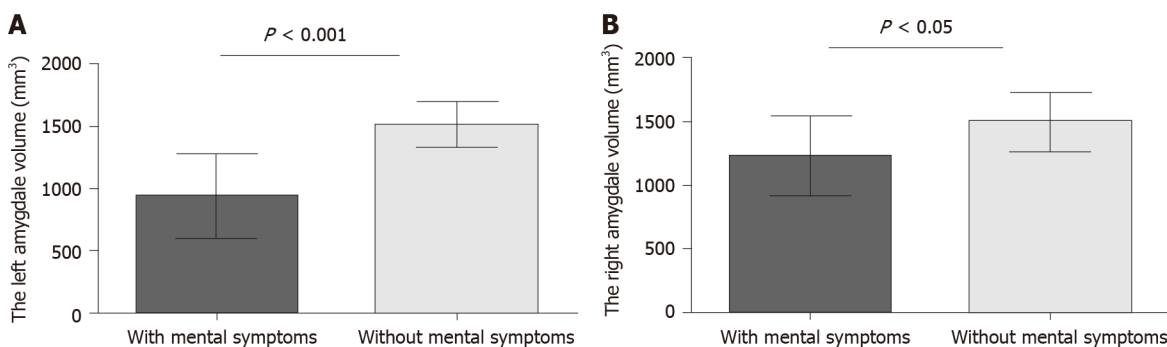


Figure 4 Amygdala volumes between Alzheimer's disease patients with and without mental symptoms. The left and right amygdala volumes of Alzheimer's disease patients with mental symptoms were significantly smaller than patients without mental symptoms. A: Left amygdala volume; B: Right amygdala volume.

results showed that the bilateral amygdala volumes of AD patients were significantly smaller than those of the controls, and were positively correlated with the hippocampal volumes, consistent with previous reports[22,23].

Poulin *et al*[16] found that amygdala atrophy was obvious in early AD and was related to the severity of dementia. Yue *et al*[15] reported that volume of the right amygdala and hippocampus in patients with subjective cognitive decline. However, none of the previous studies evaluated the diagnostic value of amygdala, and there were few studies on the correlation between amygdala atrophy and clinical characteristics. Different from previous studies, we found that the sensitivity of the left and right amygdala volumes in diagnosing AD were 80.8% and 88.5%, respectively, and the cut-off value of the amygdala volume for diagnosis of AD was obtained. Amygdala volume measured by sMRI may be used as a potential imaging marker for the diagnosis of AD. One previous study showed that the degree of amygdala atrophy is correlated with the severity of the dementia[16,24]. We found that the volume of bilateral amygdala became smaller with the aggravation of dementia through subgroup analysis, but there was no significant statistical difference. The reason may

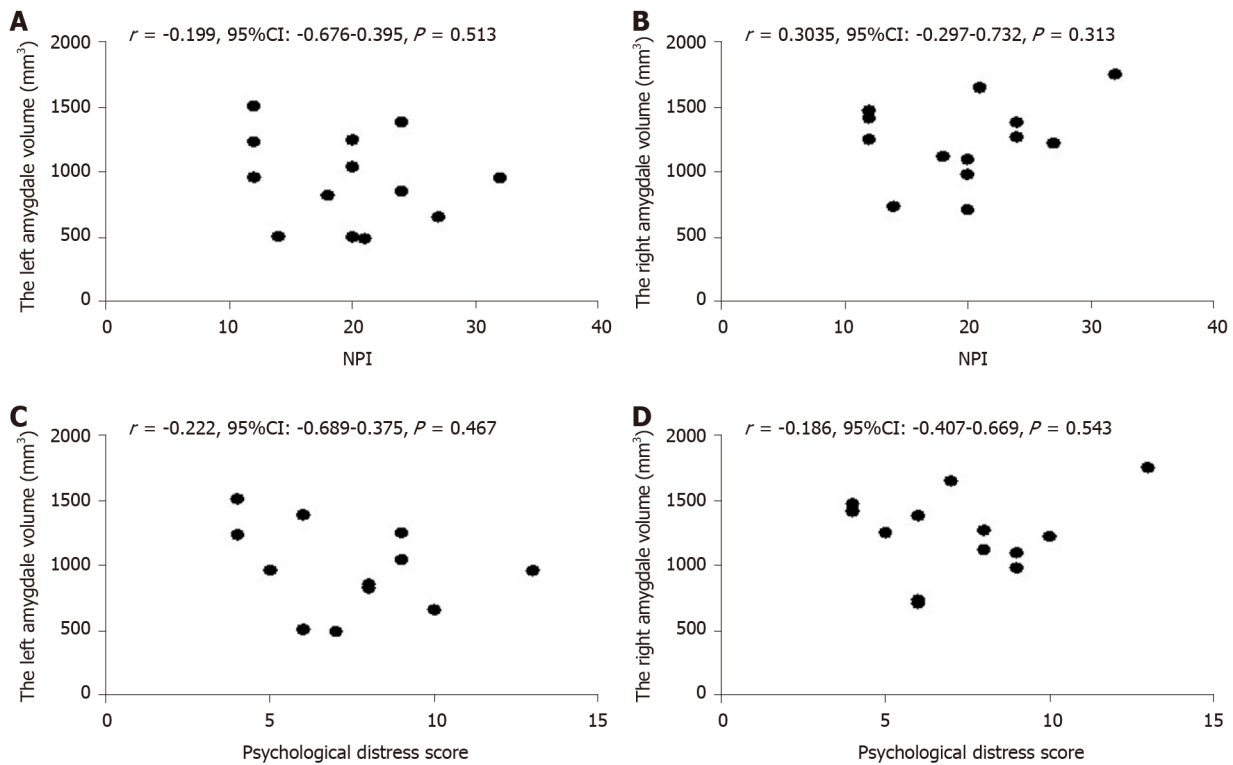


Figure 5 Correlation analyses between neuropsychiatric inventory score and bilateral amygdala. A, B: There was no significant correlation between neuropsychiatric inventory scores and amygdala volumes ($P > 0.05$); C, D: There was no correlation between psychological distress scores of caregivers and amygdala volumes ($P > 0.05$).

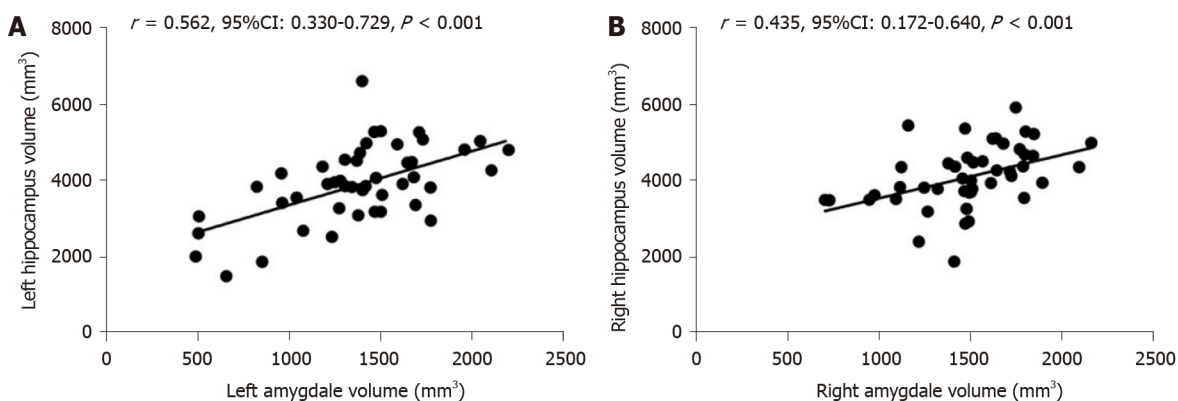


Figure 6 Correlation between amygdala and hippocampus volume. A: There was significant correlation between left amygdala and hippocampal volumes ($P < 0.001$); B: There was a significant correlation between the right amygdala volume and hippocampal volume ($P < 0.001$).

be that the sample size of this study was too small.

The atrophy of the amygdala was more serious in AD patients with mental symptoms in this study, consistent with previous studies[16]. About 80%-90% of patients with AD experience at least one kind of psychobehavioral symptoms, such as anxiety, agitation, irritability, aggression, disinhibition, depression, apathy, which can reduce the quality of life of patients and increase the burden of care[25-28]. The amygdala is attached to the terminal part of the hippocampus and is associated with multiple brain regions to regulate multiple stages of memory formation[1,2]. Some misfolded proteins such as Tau, A β , α -synuclein, and TAR DNA-binding protein 43 are present in the amygdala in neurodegenerative diseases[29]. The decreased functional connectivity among the amygdala, inferior frontal gyrus, and medial prefrontal cortex plays an important role in the development of depression in AD patients[30,31]. Previous research has shown that dysfunction of the amygdala plays an important role in the emotional disorder of AD[6-8]. The injury of amygdala can lead to agitation, irritability, anxiety, and apathy[9,10]. Other studies have indicated

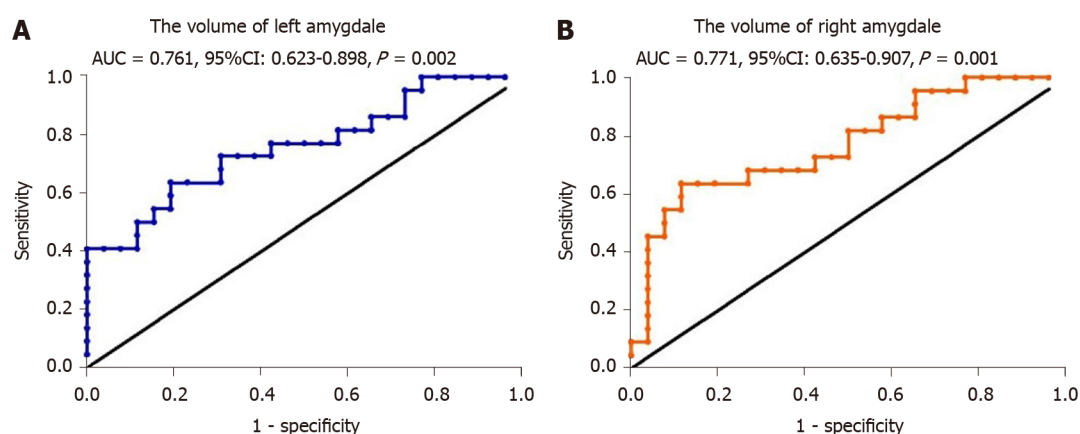


Figure 7 Receiver operating characteristic curve analysis of amygdala volume for diagnosis of Alzheimer's disease. A: Volume of left amygdala; B: Volume of right amygdala. AUC: Area under the curve.

that patients with anxiety disorder, autism, phobia, and post-traumatic stress disorder had dysfunction of amygdala[12,13].

NPI was used to evaluate the severity of mental symptoms of dementia patients and the psychological distress of caregivers in this study. Tanaka *et al*[32] reported a high frequency of apathy, depression, anxiety, and irritability in AD patients. Different from previous studies, we found that 59.1% of AD patients had neuropsychiatric symptoms, the most common of which were irritability, sleep difficulties, apathy, and hallucination. The reason may be that the patients recruited in this study were mostly mild to moderate dementia, leading to a low proportion of mental symptoms. This study also showed that the more serious dementia, the higher the proportion of patients with mental symptoms. This is consistent with previous studies[26].

There were some limitations in this study. Amygdala atrophy has also been seen in other neurodegenerative diseases, such as dementia with Lewy bodies and fronto-temporal dementia[33,34]. It is necessary to compare the amygdala volume in other types of dementia in future in order to improve the specificity of amygdala in the diagnosis of AD.

CONCLUSION

Anyway, the amygdala volumes measured by sMRI can be used for diagnosing of AD and amygdala atrophy was more serious in those with neuropsychiatric symptoms.

ARTICLE HIGHLIGHTS

Research background

Amygdala is closely related to emotion and memory. The dysfunction of amygdala plays an important role in the emotional disorder of Alzheimer's disease (AD). There are few studies evaluating the degree of atrophy of amygdala measured by structural magnetic resonance imaging (sMRI).

Research motivation

The purpose of this study is to evaluate the diagnostic value of amygdala on sMRI for AD.

Research objectives

In this study, the amygdala volumes were measured by sMRI both in AD patients and controls to evaluate the diagnostic value of amygdala. The correlation between amygdala atrophy and clinical features of AD was also analyzed.

Research methods

Twenty-two AD patients and twenty-six controls were enrolled in this study. Their amygdala volumes were measured and analyzed using a set of image analysis

software. All subjects received a cranial MRI scan and underwent neuropsychological tests. The mental and behavioral symptoms of all AD patients and the severity of the symptoms was graded.

Research results

The bilateral amygdala volumes of AD patients were significantly lower than those of the controls. The sensitivity of the left and right amygdala volumes in diagnosing AD was 80.8% and 88.5%, respectively. The amygdala atrophy was more serious in AD patients with neuropsychiatric symptoms including irritability, sleep difficulties, apathy and hallucination.

Research conclusions

In this study, we found that the bilateral amygdala volumes of AD patients were significantly smaller than those of the controls, and were positively correlated with the hippocampal volumes, consistent with previous reports. In addition, the atrophy of the amygdala was more serious in those with neuropsychiatric symptoms. This study confirmed that the amygdala is involved in the mental symptoms of AD.

Research perspectives

It is necessary to compare the amygdala volume in other types of dementia in the future, in order to improve the specificity of amygdala for the diagnosis of AD.

REFERENCES

- 1 **LaBar KS**, Cabeza R. Cognitive neuroscience of emotional memory. *Nat Rev Neurosci* 2006; **7**: 54-64 [PMID: [16371950](#) DOI: [10.1038/nrn1825](#)]
- 2 **Hermans EJ**, Battaglia FP, Atsak P, de Voogd LD, Fernández G, Rooszendaal B. How the amygdala affects emotional memory by altering brain network properties. *Neurobiol Learn Mem* 2014; **112**: 2-16 [PMID: [24583373](#) DOI: [10.1016/j.nlm.2014.02.005](#)]
- 3 **Phelps EA**. Human emotion and memory: interactions of the amygdala and hippocampal complex. *Curr Opin Neurobiol* 2004; **14**: 198-202 [PMID: [15082325](#) DOI: [10.1016/j.conb.2004.03.015](#)]
- 4 **Hamann S**. Cognitive and neural mechanisms of emotional memory. *Trends Cogn Sci* 2001; **5**: 394-400 [PMID: [11520704](#) DOI: [10.1016/s1364-6613\(00\)01707-1](#)]
- 5 **Herzog AG**, Kemper TL. Amygdaloid changes in aging and dementia. *Arch Neurol* 1980; **37**: 625-629 [PMID: [7425886](#) DOI: [10.1001/archneur.1980.00500590049006](#)]
- 6 **Tsuchiya K**, Kosaka K. Neuropathological study of the amygdala in presenile Alzheimer's disease. *J Neurol Sci* 1990; **100**: 165-173 [PMID: [2089133](#) DOI: [10.1016/0022-510x\(90\)90029-m](#)]
- 7 **Scott SA**, DeKosky ST, Scheff SW. Volumetric atrophy of the amygdala in Alzheimer's disease: quantitative serial reconstruction. *Neurology* 1991; **41**: 351-356 [PMID: [2006000](#) DOI: [10.1212/wnl.41.3.351](#)]
- 8 **Scott SA**, DeKosky ST, Sparks DL, Knox CA, Scheff SW. Amygdala cell loss and atrophy in Alzheimer's disease. *Ann Neurol* 1992; **32**: 555-563 [PMID: [1456740](#) DOI: [10.1002/ana.410320412](#)]
- 9 **Davidson RJ**. Anxiety and affective style: role of prefrontal cortex and amygdala. *Biol Psychiatry* 2002; **51**: 68-80 [PMID: [11801232](#) DOI: [10.1016/s0006-3223\(01\)01328-2](#)]
- 10 **Wright CI**, Dickerson BC, Feczko E, Negeira A, Williams D. A functional magnetic resonance imaging study of amygdala responses to human faces in aging and mild Alzheimer's disease. *Biol Psychiatry* 2007; **62**: 1388-1395 [PMID: [17336945](#) DOI: [10.1016/j.biopsych.2006.11.013](#)]
- 11 **Kile SJ**, Ellis WG, Olichney JM, Farias S, DeCarli C. Alzheimer abnormalities of the amygdala with Klüver-Bucy syndrome symptoms: an amygdaloid variant of Alzheimer disease. *Arch Neurol* 2009; **66**: 125-129 [PMID: [19139311](#) DOI: [10.1001/archneur.2008.517](#)]
- 12 **Wassum KM**, Izquierdo A. The basolateral amygdala in reward learning and addiction. *Neurosci Biobehav Rev* 2015; **57**: 271-283 [PMID: [26341938](#) DOI: [10.1016/j.neubiorev.2015.08.017](#)]
- 13 **Nikolenko VN**, Oganessian MV, Rizaeva NA, Kudryashova VA, Nikitina AT, Pavliv MP, Shchedrina MA, Giller DB, Buligin KV, Sinelnikov MY. Amygdala: Neuroanatomical and Morphophysiological Features in Terms of Neurological and Neurodegenerative Diseases. *Brain Sci* 2020; **10** [PMID: [32751957](#) DOI: [10.3390/brainsci10080502](#)]
- 14 **McKhann GM**, Knopman DS, Chertkow H, Hyman BT, Jack CR Jr, Kawas CH, Klunk WE, Koroshetz WJ, Manly JJ, Mayeux R, Mohs RC, Morris JC, Rossor MN, Scheltens P, Carrillo MC, Thies B, Weintraub S, Phelps CH. The diagnosis of dementia due to Alzheimer's disease: recommendations from the National Institute on Aging-Alzheimer's Association workgroups on diagnostic guidelines for Alzheimer's disease. *Alzheimers Dement* 2011; **7**: 263-269 [PMID: [21514250](#) DOI: [10.1016/j.jalz.2011.03.005](#)]
- 15 **Yue L**, Wang T, Wang J, Li G, Li X, Li W, Hu M, Xiao S. Asymmetry of Hippocampus and Amygdala Defect in Subjective Cognitive Decline Among the Community Dwelling Chinese. *Front Psychiatry* 2018; **9**: 226 [PMID: [29942265](#) DOI: [10.3389/fpsy.2018.00226](#)]

- 16 **Poulin SP**, Dautoff R, Morris JC, Barrett LF, Dickerson BC; Alzheimer's Disease Neuroimaging Initiative. Amygdala atrophy is prominent in early Alzheimer's disease and relates to symptom severity. *Psychiatry Res* 2011; **194**: 7-13 [PMID: [21920712](#) DOI: [10.1016/j.psychres.2011.06.014](#)]
- 17 **Wang D**, Wang P, Bian X, Xu S, Zhou Q, Zhang Y, Ding M, Han M, Huang L, Bi J, Jia Y, Xie Z. Elevated plasma levels of exosomal BACE1AS combined with the volume and thickness of the right entorhinal cortex may serve as a biomarker for the detection of Alzheimer's disease. *Mol Med Rep* 2020; **22**: 227-238 [PMID: [32377715](#) DOI: [10.3892/mmr.2020.11118](#)]
- 18 **Yang Z**, Holt HK, Fan JH, Ma L, Liu Y, Chen W, Como P, Zhang L, Qiao YL. Optimal Cutoff Scores for Alzheimer's Disease Using the Chinese Version of Mini-Mental State Examination Among Chinese Population Living in Rural Areas. *Am J Alzheimers Dis Other Dement* 2016; **31**: 650-657 [PMID: [27659393](#) DOI: [10.1177/1533317516662336](#)]
- 19 **Morris JC**. The Clinical Dementia Rating (CDR): current version and scoring rules. *Neurology* 1993; **43**: 2412-2414 [PMID: [8232972](#) DOI: [10.1212/wnl.43.11.2412-a](#)]
- 20 **Tafazzoli A**, Kansal A, Lockwood P, Petrie C, Barsdorf A. The Economic Impact of New Therapeutic Interventions on Neuropsychiatric Inventory (NPI) Symptom Scores in Patients with Alzheimer Disease. *Dement Geriatr Cogn Dis Extra* 2018; **8**: 158-173 [PMID: [29805382](#) DOI: [10.1159/000488140](#)]
- 21 **Hachimori A**. [Neuropsychiatric Inventory (NPI)]. *Nihon Rinsho* 2011; **69** Suppl 8: 439-442 [PMID: [22787830](#)]
- 22 **Lehtovirta M**, Laakso MP, Soininen H, Helisalmi S, Mannermaa A, Helkala EL, Partanen K, Ryyänänen M, Vainio P, Hartikainen P. Volumes of hippocampus, amygdala and frontal lobe in Alzheimer patients with different apolipoprotein E genotypes. *Neuroscience* 1995; **67**: 65-72 [PMID: [7477910](#) DOI: [10.1016/0306-4522\(95\)00014-a](#)]
- 23 **Cavedo E**, Boccardi M, Ganzola R, Canu E, Beltramello A, Caltagirone C, Thompson PM, Frisoni GB. Local amygdala structural differences with 3T MRI in patients with Alzheimer disease. *Neurology* 2011; **76**: 727-733 [PMID: [21339500](#) DOI: [10.1212/WNL.0b013e31820d62d9](#)]
- 24 **LeDoux J**. The amygdala. *Curr Biol* 2007; **17**: R868-R874 [PMID: [17956742](#) DOI: [10.1016/j.cub.2007.08.005](#)]
- 25 **Mao Y**, Fisher DW, Yang S, Keszycki RM, Dong H. Protein-protein interactions underlying the behavioral and psychological symptoms of dementia (BPSD) and Alzheimer's disease. *PLoS One* 2020; **15**: e0226021 [PMID: [31951614](#) DOI: [10.1371/journal.pone.0226021](#)]
- 26 **van der Linde RM**, Denning T, Matthews FE, Brayne C. Grouping of behavioural and psychological symptoms of dementia. *Int J Geriatr Psychiatry* 2014; **29**: 562-568 [PMID: [24677112](#) DOI: [10.1002/gps.4037](#)]
- 27 **Kales HC**, Lyketsos CG, Miller EM, Ballard C. Management of behavioral and psychological symptoms in people with Alzheimer's disease: an international Delphi consensus. *Int Psychogeriatr* 2019; **31**: 83-90 [PMID: [30068400](#) DOI: [10.1017/S1041610218000534](#)]
- 28 **Baquero M**, Martín N. Depressive symptoms in neurodegenerative diseases. *World J Clin Cases* 2015; **3**: 682-693 [PMID: [26301229](#) DOI: [10.12998/wjcc.v3.i8.682](#)]
- 29 **Nelson PT**, Abner EL, Patel E, Anderson S, Wilcock DM, Kryscio RJ, Van Eldik LJ, Jicha GA, Gal Z, Nelson RS, Nelson BG, Gal J, Azam MT, Fardo DW, Cykowski MD. The Amygdala as a Locus of Pathologic Misfolding in Neurodegenerative Diseases. *J Neuropathol Exp Neurol* 2018; **77**: 2-20 [PMID: [29186501](#) DOI: [10.1093/jnen/nlx099](#)]
- 30 **Taylor JP**, Hardy J, Fischbeck KH. Toxic proteins in neurodegenerative disease. *Science* 2002; **296**: 1991-1995 [PMID: [12065827](#) DOI: [10.1126/science.1067122](#)]
- 31 **Hu X**, Song X, Yuan Y, Li E, Liu J, Liu W, Liu Y. Abnormal functional connectivity of the amygdala is associated with depression in Parkinson's disease. *Mov Disord* 2015; **30**: 238-244 [PMID: [25545969](#) DOI: [10.1002/mds.26087](#)]
- 32 **Tanaka H**, Hashimoto M, Fukuhara R, Ishikawa T, Yatabe Y, Kaneda K, Yuuki S, Honda K, Matsuzaki S, Tsuyuguchi A, Hatada Y, Ikeda M. Relationship between dementia severity and behavioural and psychological symptoms in early-onset Alzheimer's disease. *Psychogeriatrics* 2015; **15**: 242-247 [PMID: [25737233](#) DOI: [10.1111/psyg.12108](#)]
- 33 **Horínek D**, Varjassyová A, Hort J. Magnetic resonance analysis of amygdalar volume in Alzheimer's disease. *Curr Opin Psychiatry* 2007; **20**: 273-277 [PMID: [17415082](#) DOI: [10.1097/YCO.0b013e3280ebb613](#)]
- 34 **Barber R**, Ballard C, McKeith IG, Gholkar A, O'Brien JT. MRI volumetric study of dementia with Lewy bodies: a comparison with AD and vascular dementia. *Neurology* 2000; **54**: 1304-1309 [PMID: [10746602](#) DOI: [10.1212/wnl.54.6.1304](#)]



Published by **Baishideng Publishing Group Inc**
7041 Koll Center Parkway, Suite 160, Pleasanton, CA 94566, USA

Telephone: +1-925-3991568

E-mail: bpgoffice@wjgnet.com

Help Desk: <https://www.f6publishing.com/helpdesk>

<https://www.wjgnet.com>

