

# World Journal of *Clinical Cases*

*World J Clin Cases* 2021 June 26; 9(18): 4460-4880



**OPINION REVIEW**

- 4460 Surgery for pancreatic tumors in the midst of COVID-19 pandemic

*Kato H, Asano Y, Arakawa S, Ito M, Kawabe N, Shimura M, Hayashi C, Ochi T, Yasuoka H, Higashiguchi T, Kondo Y, Nagata H, Horiguchi A*

**REVIEW**

- 4467 Roles of exosomes in diagnosis and treatment of colorectal cancer

*Umwali Y, Yue CB, Gabriel ANA, Zhang Y, Zhang X*

**MINIREVIEWS**

- 4480 Dynamics of host immune responses to SARS-CoV-2

*Taherkhani R, Taherkhani S, Farshadpour F*

- 4491 Current treatment for hepatitis C virus/human immunodeficiency virus coinfection in adults

*Laiwatthanapaisan R, Sirinawasatien A*

- 4500 Anti-tumor effect of statin on pancreatic adenocarcinoma: From concept to precision medicine

*Huang CT, Liang YJ*

- 4506 Roles of vitamin A in the regulation of fatty acid synthesis

*Yang FC, Xu F, Wang TN, Chen GX*

**ORIGINAL ARTICLE****Basic Study**

- 4520 Identification of the circRNA-miRNA-mRNA regulatory network and its prognostic effect in colorectal cancer

*Yin TF, Zhao DY, Zhou YC, Wang QQ, Yao SK*

- 4542 Tetramethylpyrazine inhibits proliferation of colon cancer cells *in vitro*

*Li H, Hou YX, Yang Y, He QQ, Gao TH, Zhao XF, Huo ZB, Chen SB, Liu DX*

**Case Control Study**

- 4553 Significance of highly phosphorylated insulin-like growth factor binding protein-1 and cervical length for prediction of preterm delivery in twin pregnancies

*Lan RH, Song J, Gong HM, Yang Y, Yang H, Zheng LM*

**Retrospective Cohort Study**

- 4559** Expected outcomes and patients' selection before chemoembolization—"Six-and-Twelve or Pre-TACE-Predict" scores may help clinicians: Real-life French cohorts results

*Adhoute X, Larrey E, Anty R, Chevallier P, Penaranda G, Tran A, Bronowicki JP, Raoul JL, Castellani P, Perrier H, Bayle O, Monnet O, Pol B, Bourliere M*

**Retrospective Study**

- 4573** Application of intelligent algorithms in Down syndrome screening during second trimester pregnancy  
*Zhang HG, Jiang YT, Dai SD, Li L, Hu XN, Liu RZ*
- 4585** Evaluation of a five-gene signature associated with stromal infiltration for diffuse large B-cell lymphoma  
*Nan YY, Zhang WJ, Huang DH, Li QY, Shi Y, Yang T, Liang XP, Xiao CY, Guo BL, Xiang Y*
- 4599** Efficacy of combination of localized closure, ethacridine lactate dressing, and phototherapy in treatment of severe extravasation injuries: A case series  
*Lu YX, Wu Y, Liang PF, Wu RC, Tian LY, Mo HY*
- 4607** Observation and measurement of applied anatomical features for thoracic intervertebral foramen puncture on computed tomography images  
*Wang R, Sun WW, Han Y, Fan XX, Pan XQ, Wang SC, Lu LJ*
- 4617** Histological transformation of non-small cell lung cancer: Clinical analysis of nine cases  
*Jin CB, Yang L*
- 4627** Diagnostic value of amygdala volume on structural magnetic resonance imaging in Alzheimer's disease  
*Wang DW, Ding SL, Bian XL, Zhou SY, Yang H, Wang P*
- 4637** Comparison of ocular axis and corneal diameter between entropion and non-entropion eyes in children with congenital glaucoma  
*Wang Y, Hou ZJ, Wang HZ, Hu M, Li YX, Zhang Z*

**Observational Study**

- 4644** Risk factors for postoperative delayed gastric emptying in ovarian cancer treated with cytoreductive surgery and hyperthermic intraperitoneal chemotherapy  
*Cui GX, Wang ZJ, Zhao J, Gong P, Zhao SH, Wang XX, Bai WP, Li Y*
- 4654** Clinical characteristics, gastrointestinal manifestations and outcomes of COVID-19 patients in Iran; does the location matters?  
*Mokarram P, Dalivand MM, Pizuorno A, Aligolighasemabadi F, Sadeghdoust M, Sadeghdoust E, Aduli F, Oskrochi G, Brim H, Ashktorab H*
- 4668** AWGS2019 vs EWGSOP2 for diagnosing sarcopenia to predict long-term prognosis in Chinese patients with gastric cancer after radical gastrectomy  
*Wu WY, Dong JJ, Huang XC, Chen ZJ, Chen XL, Dong QT, Bai YY*

**Prospective Study**

- 4681** Clinical outcomes and 5-year follow-up results of keratosis pilaris treated by a high concentration of glycolic acid

*Tian Y, Li XX, Zhang JJ, Yun Q, Zhang S, Yu JY, Feng XJ, Xia AT, Kang Y, Huang F, Wan F*

**Randomized Controlled Trial**

- 4690** Tenofovir disoproxil fumarate in Chinese chronic hepatitis B patients: Results of a multicenter, double-blind, double-dummy, clinical trial at 96 weeks

*Chen XF, Fan YN, Si CW, Yu YY, Shang J, Yu ZJ, Mao Q, Xie Q, Zhao W, Li J, Gao ZL, Wu SM, Tang H, Cheng J, Chen XY, Zhang WH, Wang H, Xu ZN, Wang L, Dai J, Xu JH*

**SYSTEMATIC REVIEWS**

- 4700** Mesenteric ischemia in COVID-19 patients: A review of current literature

*Kerawala AA, Das B, Solangi A*

- 4709** Role of theories in school-based diabetes care interventions: A critical review

*An RP, Li DY, Xiang XL*

**CASE REPORT**

- 4721** Alport syndrome combined with lupus nephritis in a Chinese family: A case report

*Liu HF, Li Q, Peng YQ*

- 4728** Botulinum toxin injection for Cockayne syndrome with muscle spasticity over bilateral lower limbs: A case report

*Hsu LC, Chiang PY, Lin WP, Guo YH, Hsieh PC, Kuan TS, Lien WC, Lin YC*

- 4734** Meigs' syndrome caused by granulosa cell tumor accompanied with intrathoracic lesions: A case report

*Wu XJ, Xia HB, Jia BL, Yan GW, Luo W, Zhao Y, Luo XB*

- 4741** Primary mesonephric adenocarcinoma of the fallopian tube: A case report

*Xie C, Shen YM, Chen QH, Bian C*

- 4748** Pancreas-preserving duodenectomy for treatment of a duodenal papillary tumor: A case report

*Wu B, Chen SY, Li Y, He Y, Wang XX, Yang XJ*

- 4754** Pheochromocytoma with abdominal aortic aneurysm presenting as recurrent dyspnea, hemoptysis, and hypotension: A case report

*Zhao HY, Zhao YZ, Jia YM, Mei X, Guo SB*

- 4760** Minimally invasive removal of a deep-positioned cannulated screw from the femoral neck: A case report

*Yang ZH, Hou FS, Yin YS, Zhao L, Liang X*

- 4765** Splenic Kaposi's sarcoma in a human immunodeficiency virus-negative patient: A case report

*Zhao CJ, Ma GZ, Wang YJ, Wang JH*



- 4772** Neonatal syringocystadenoma papilliferum: A case report  
*Jiang HJ, Zhang Z, Zhang L, Pu YJ, Zhou N, Shu H*
- 4778** Disappeared intralenticular foreign body: A case report  
*Xue C, Chen Y, Gao YL, Zhang N, Wang Y*
- 4783** Femoral neck stress fractures after trampoline exercise: A case report  
*Nam DC, Hwang SC, Lee EC, Song MG, Yoo JI*
- 4789** Collision carcinoma of the rectum involving neuroendocrine carcinoma and adenocarcinoma: A case report  
*Zhao X, Zhang G, Li CH*
- 4797** Therapeutic effect of autologous concentrated growth factor on lower-extremity chronic refractory wounds: A case report  
*Liu P, Liu Y, Ke CN, Li WS, Liu YM, Xu S*
- 4803** Cutaneous myiasis with eosinophilic pleural effusion: A case report  
*Fan T, Zhang Y, Lv Y, Chang J, Bauer BA, Yang J, Wang CW*
- 4810** Severe hematuria due to vesical varices in a patient with portal hypertension: A case report  
*Wei ZJ, Zhu X, Yu HT, Liang ZJ, Gou X, Chen Y*
- 4817** Rare coexistence of multiple manifestations secondary to thalamic hemorrhage: A case report  
*Yu QW, Ye TF, Qian WJ*
- 4823** Anderson-Fabry disease presenting with atrial fibrillation as earlier sign in a young patient: A case report  
*Kim H, Kang MG, Park HW, Park JR, Hwang JY, Kim K*
- 4829** Long-term response to avelumab and management of oligoprogression in Merkel cell carcinoma: A case report  
*Leão I, Marinho J, Costa T*
- 4837** Central pontine myelinolysis mimicking glioma in diabetes: A case report  
*Shi XY, Cai MT, Shen H, Zhang JX*
- 4844** Microscopic transduodenal excision of an ampullary adenoma: A case report and review of the literature  
*Zheng X, Sun QJ, Zhou B, Jin M, Yan S*
- 4852** Growth hormone cocktail improves hepatopulmonary syndrome secondary to hypopituitarism: A case report  
*Ji W, Nie M, Mao JF, Zhang HB, Wang X, Wu XY*
- 4859** Low symptomatic COVID-19 in an elderly patient with follicular lymphoma treated with rituximab-based immunotherapy: A case report  
*Łęcki S, Wyżgolik K, Nicze M, Georgiew-Nadziakiewicz S, Chudek J, Wdowiak K*

- 4866** Adult rhabdomyosarcoma originating in the temporal muscle, invading the skull and meninges: A case report  
*Wang GH, Shen HP, Chu ZM, Shen J*
- 4873** *Listeria monocytogenes* bacteremia in a centenarian and pathogen traceability: A case report  
*Zhang ZY, Zhang XA, Chen Q, Wang JY, Li Y, Wei ZY, Wang ZC*

**ABOUT COVER**

Editorial Board Member of *World Journal of Clinical Cases*, Shingo Tsujinaka, MD, PhD, Assistant Professor, Senior Lecturer, Surgeon, Department of Surgery, Saitama Medical Center, Jichi Medical University, Saitama 330-8503, Japan. tsujinakas@omiya.jichi.ac.jp

**AIMS AND SCOPE**

The primary aim of *World Journal of Clinical Cases* (WJCC, *World J Clin Cases*) is to provide scholars and readers from various fields of clinical medicine with a platform to publish high-quality clinical research articles and communicate their research findings online.

WJCC mainly publishes articles reporting research results and findings obtained in the field of clinical medicine and covering a wide range of topics, including case control studies, retrospective cohort studies, retrospective studies, clinical trials studies, observational studies, prospective studies, randomized controlled trials, randomized clinical trials, systematic reviews, meta-analysis, and case reports.

**INDEXING/ABSTRACTING**

The WJCC is now indexed in Science Citation Index Expanded (also known as SciSearch®), Journal Citation Reports/Science Edition, Scopus, PubMed, and PubMed Central. The 2020 Edition of Journal Citation Reports® cites the 2019 impact factor (IF) for WJCC as 1.013; IF without journal self cites: 0.991; Ranking: 120 among 165 journals in medicine, general and internal; and Quartile category: Q3. The WJCC's CiteScore for 2019 is 0.3 and Scopus CiteScore rank 2019: General Medicine is 394/529.

**RESPONSIBLE EDITORS FOR THIS ISSUE**

Production Editor: Ji-Hong Lin; Production Department Director: Xiang Li; Editorial Office Director: Jin-Lai Wang.

**NAME OF JOURNAL**

*World Journal of Clinical Cases*

**ISSN**

ISSN 2307-8960 (online)

**LAUNCH DATE**

April 16, 2013

**FREQUENCY**

Thrice Monthly

**EDITORS-IN-CHIEF**

Dennis A Bloomfield, Sandro Vento, Bao-Gan Peng

**EDITORIAL BOARD MEMBERS**

<https://www.wjnet.com/2307-8960/editorialboard.htm>

**PUBLICATION DATE**

June 26, 2021

**COPYRIGHT**

© 2021 Baishideng Publishing Group Inc

**INSTRUCTIONS TO AUTHORS**

<https://www.wjnet.com/bpg/gerinfo/204>

**GUIDELINES FOR ETHICS DOCUMENTS**

<https://www.wjnet.com/bpg/GerInfo/287>

**GUIDELINES FOR NON-NATIVE SPEAKERS OF ENGLISH**

<https://www.wjnet.com/bpg/gerinfo/240>

**PUBLICATION ETHICS**

<https://www.wjnet.com/bpg/GerInfo/288>

**PUBLICATION MISCONDUCT**

<https://www.wjnet.com/bpg/gerinfo/208>

**ARTICLE PROCESSING CHARGE**

<https://www.wjnet.com/bpg/gerinfo/242>

**STEPS FOR SUBMITTING MANUSCRIPTS**

<https://www.wjnet.com/bpg/GerInfo/239>

**ONLINE SUBMISSION**

<https://www.f6publishing.com>

# Primary mesonephric adenocarcinoma of the fallopian tube: A case report

Chuan Xie, Yang-Mei Shen, Qiu-He Chen, Ce Bian

**ORCID number:** Chuan Xie 0000-0003-4043-7111; Yang-Mei Shen 0000-0002-2345-5273; Qiu-He Chen 0000-0001-6202-5391; Ce Bian 0000-0002-4593-8559.

**Author contributions:** Xie C performed the data collection and manuscript writing; Shen YM performed the data collection and figure preparation; Chen QH performed the figure preparation; Bian C performed the manuscript writing and editing; all authors have read and approved the manuscript.

**Informed consent statement:** Written consent to publish this information was obtained from the patient.

**Conflict-of-interest statement:** The authors declare no conflict of interest/competing interests in publishing the present manuscript.

**CARE Checklist (2016) statement:** The authors have read the CARE Checklist (2016), and the manuscript was prepared and revised according to the CARE Checklist (2016).

**Open-Access:** This article is an open-access article that was selected by an in-house editor and fully peer-reviewed by external reviewers. It is distributed in accordance with the Creative

**Chuan Xie, Qiu-He Chen, Ce Bian,** Department of Gynecology and Obstetrics, Key Laboratory of Birth Defects and Related Diseases of Women and Children, Ministry of Education, West China Second University Hospital, Sichuan University, Chengdu 610041, Sichuan Province, China

**Yang-Mei Shen,** Department of Pathology, Key Laboratory of Birth Defects and Related Diseases of Women and Children, Ministry of Education, West China Second University Hospital, Sichuan University, Chengdu 610041, Sichuan Province, China

**Corresponding author:** Ce Bian, MD, PhD, Department of Gynecology and Obstetrics, Key Laboratory of Birth Defects and Related Diseases of Women and Children, Ministry of Education, West China Second University Hospital, Sichuan University, No. 20 Section Three, South Renmin Road, Chengdu 610041, Sichuan Province, China. [terrybian@163.com](mailto:terrybian@163.com)

## Abstract

### BACKGROUND

Mesonephric adenocarcinoma (MNAC) is an extremely rare malignancy in the female genital tract. Only a few cases have been reported in the literature, and most of them occurred in the cervix, with extremely rare cases in the uterine body and ovary. MNAC has never been reported to arise in the fallopian tube.

### CASE SUMMARY

A 45-year-old woman was referred to our institution with a history of abdominal pain. Ultrasound revealed a cystic and solid mass in left adnexal region. The patient underwent complete staging surgery when intraoperative pathological examination demonstrated that the mass was malignant. The final histological and immunohistochemical results confirmed the diagnosis of MNAC originating from the fallopian tube. Then she received four cycles of combination chemotherapy with carboplatin plus paclitaxel. The tumor recurred with hepatic metastases 4 mo after initial surgery, and second resection of the tumors in the liver plus partial hepatectomy was performed. She was supplemented with five courses of a new combination chemotherapy with gemcitabine plus carboplatin, and there was no evidence of recurrence within the 22-mo follow-up period after the second surgery.

### CONCLUSION

MNAC originating from the fallopian tube is an extremely rare and high malignancy with a poor prognosis. It can be very aggressive, even at early stage. Little is known about the clinical characteristics, pathological diagnosis,

Commons Attribution NonCommercial (CC BY-NC 4.0) license, which permits others to distribute, remix, adapt, build upon this work non-commercially, and license their derivative works on different terms, provided the original work is properly cited and the use is non-commercial. See: <http://creativecommons.org/licenses/by-nc/4.0/>

**Manuscript source:** Unsolicited manuscript

**Specialty type:** Medicine, research and experimental

**Country/Territory of origin:** China

**Peer-review report's scientific quality classification**

Grade A (Excellent): 0  
Grade B (Very good): B  
Grade C (Good): 0  
Grade D (Fair): 0  
Grade E (Poor): 0

**Received:** October 27, 2020

**Peer-review started:** October 27, 2020

**First decision:** January 17, 2021

**Revised:** April 21, 2021

**Accepted:** April 29, 2021

**Article in press:** April 29, 2021

**Published online:** June 26, 2021

**P-Reviewer:** Tanabe S

**S-Editor:** Fan JR

**L-Editor:** Wang TQ

**P-Editor:** Zhang YL



prognosis, and optimal management strategy of MNAC originating from the fallopian tube. Herein we report the first case of primary MNAC deriving from the fallopian tube.

**Key Words:** Mesonephric adenocarcinoma; Mesonephric-like adenocarcinoma; Fallopian tube; Surgery; Chemotherapy; Case report

©The Author(s) 2021. Published by Baishideng Publishing Group Inc. All rights reserved.

**Core Tip:** We present the first case of primary mesonephric adenocarcinoma (MNAC) deriving from the fallopian tube without sign of relapse or metastasis after second excision of recurrent lesions until now, which demonstrated a satisfactory response to combination chemotherapy of gemcitabine and carboplatin. MNAC originating from the fallopian tube can be very aggressive, even at early stage. Because of its sensitivity to the chemotherapy regimen, it is reasonable that combination chemotherapy of gemcitabine and carboplatin plays an important role in treatment of recurrent MNAC deriving from the fallopian tube. However, further research is needed to determine the effectiveness of this chemotherapy regimen and provide better therapeutic regimen.

**Citation:** Xie C, Shen YM, Chen QH, Bian C. Primary mesonephric adenocarcinoma of the fallopian tube: A case report. *World J Clin Cases* 2021; 9(18): 4741-4747

**URL:** <https://www.wjgnet.com/2307-8960/full/v9/i18/4741.htm>

**DOI:** <https://dx.doi.org/10.12998/wjcc.v9.i18.4741>

## INTRODUCTION

Mesonephric adenocarcinoma (MNAC) has only rarely been reported to occur in the uterine body; however, it has never been reported to arise in the fallopian tube. Ovarian adenocarcinomas that share immunophenotypic, morphologic, and molecular features with MNACs but lack association with mesonephric hyperplasia or remnants have been reported, therefore mesonephric-like adenocarcinomas (MLAs) are recently recommended to describe these neoplasms[1-3]. However, neither MNACs nor MLAs have been reported to arise in the fallopian tube up to now. Here we report the first case of primary fallopian tube MNAC (FT-MNAC) with distant recurrence after complete staging surgery combined with systemic chemotherapy, but there is no evidence of recurrence after the second resection of metastatic lesions followed by a new chemotherapy combination with gemcitabine plus carboplatin till now.

## CASE PRESENTATION

### Chief complaints

A 45-year-old woman presented to our institution with a 3-mo history of lower abdominal pain.

### Physical examination

Vaginal examination revealed a palpable mass about 6 cm in diameter in the left adnexal area, and other physical examinations showed no abnormalities.

### Laboratory examinations

Laboratory examinations including the serum tumor markers were all within normal range.

### Imaging examinations

Transvaginal ultrasound revealed a cystic and solid mass measuring 6.8 cm × 4.6 cm in diameter in left adnexal area.

### ***Surgical treatment and intraoperative findings***

A laparotomy was performed and the intraoperative frozen section revealed a diagnosis of malignancy. Therefore, the patient underwent a complete staging surgery. Intraoperative findings revealed that there was a solid and cystic mass measuring 7 cm in maximum diameter with irregular and friable surface, arising from the left fallopian tube. The capsule of the tumor mass was intact. The left ovary and the right adnexa were normal and not infiltrated by the tumor. No obvious tumor implants were observed in the pelvic and abdominal peritoneum, and other organ surfaces, including the liver, diaphragm, stomach, and omentum.

### ***Postoperative pathology and immunohistochemistry***

Gross examination of the excised specimen showed a mass measuring 7 cm in maximum diameter arising from the left fallopian tube wall. Histologic examination revealed that the tumor originated from the fallopian tube wall and the tumor cell involved the mucosa and serosal membrane of the fallopian tube (Figure 1A and B). Vestiges of mesonephric hyperplasia (Figure 1C) and hyperplasia into cancerous nests (Figure 1D) were histologically found. Immunohistochemical staining revealed that PAX8 expression was strong and diffuse (Figure 2A). The staining for GATA3 was weak and diffuse (Figure 2B) and CD10 revealed cytoplasmic and luminal staining (Figure 2C). The expression of thyroid transcription factor-1 was diffuse and strong (Figure 2D), but the tumors were totally negative for Calretinin (Figure 2E), Wilms' tumour-1 (Figure 2F), estrogen receptor (Figure 3A), progesterone receptor (Figure 3B), and CA125 (Figure 3C). Positive staining for P16 (Figure 3D) and P53 (Figure 3E) was detected. The positive rate of Ki-67 expression was 60%-70% (Figure 3F).

---

## **FINAL DIAGNOSIS**

The final histological and immunohistochemical results confirmed the diagnosis of FT-MNAC. The tumor was staged as International Federation of Gynecology and Obstetrics (FIGO) stage IA.

---

## **TREATMENT**

### ***Chemotherapy after first surgery***

The patient received adjuvant chemotherapy with four courses of paclitaxel (175 mg/m<sup>2</sup>) and carboplatin (300 mg/m<sup>2</sup>) after the first surgery.

### ***Recurrence of the disease and second surgical treatment***

Abdominal computed tomography detected low-density nodules under the liver capsule (Figure 4A and B) 4 mo after initial surgery. Then the second resection of tumors in the liver plus partial hepatectomy (Figure 4C and D) was performed and the postoperative pathological examination indicated that the hepatic tumors were metastatic MNAC.

### ***Chemotherapy after the second surgery***

Five courses of a new combination chemotherapy with carboplatin (300 mg/m<sup>2</sup>) and gemcitabine (1000 mg/m<sup>2</sup>) were administered to the patient.

---

## **OUTCOME AND FOLLOW-UP**

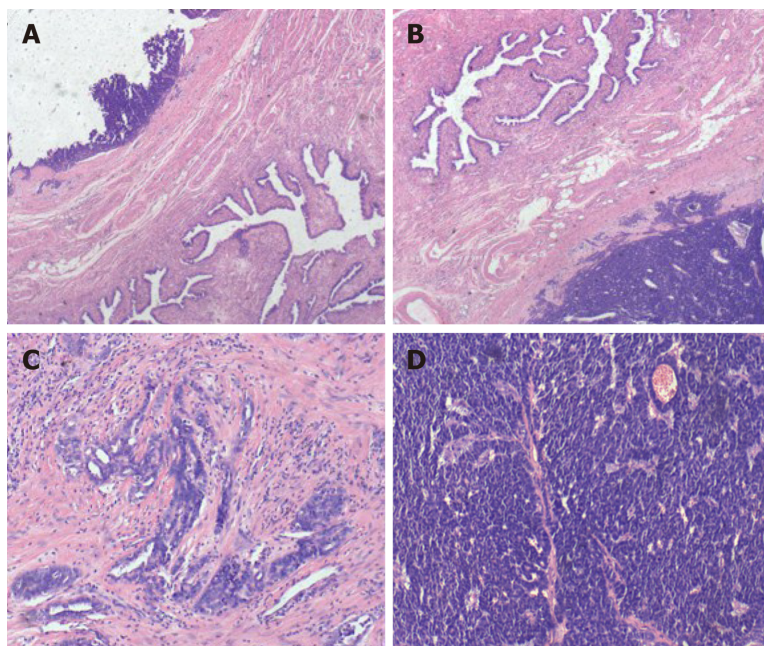
There was no evidence of recurrence within a 22 mo follow-up period after the second surgery.

---

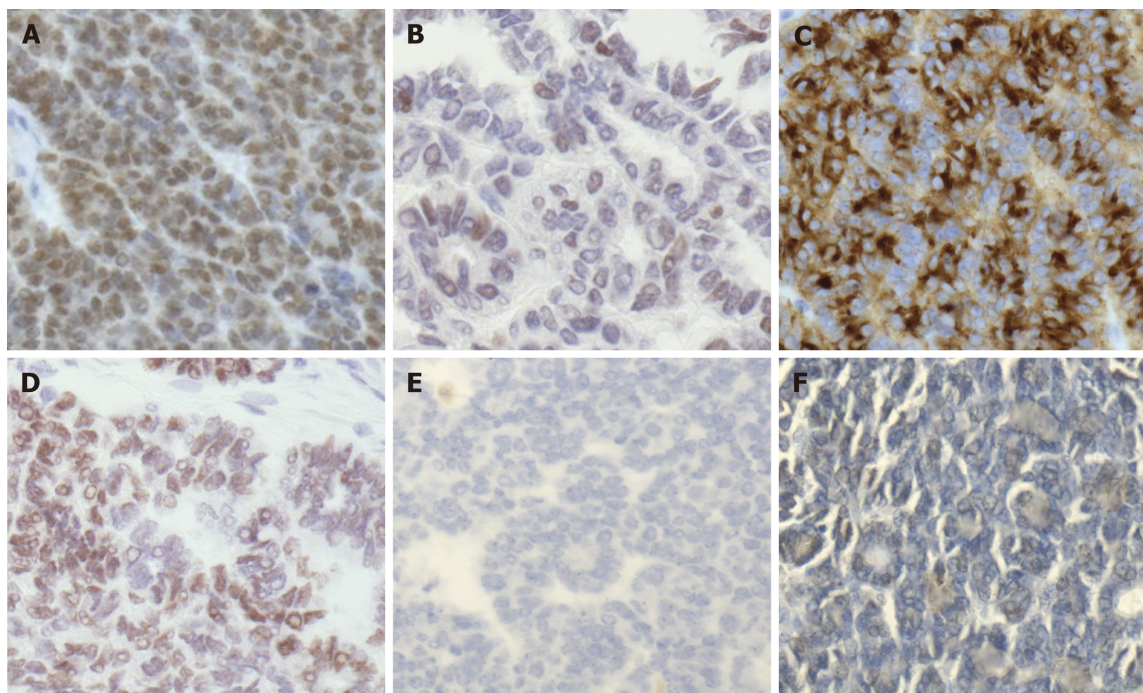
## **DISCUSSION**

MNAC is an extremely rare and highly malignant tumor in the female reproductive system. It is believed to be originated from remnant of the regressed mesonephric duct (also called Wolffian duct)[1,4]. Due to the lack of information on the treatment of this





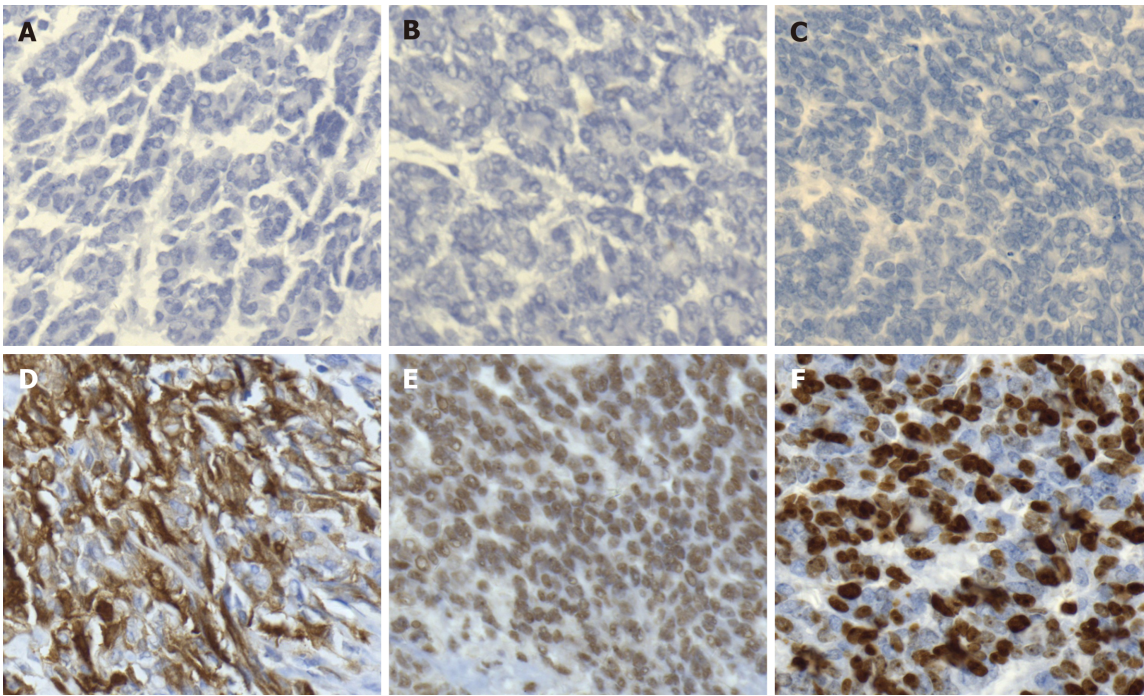
**Figure 1 Histologic features of fallopian tube-mesonephric adenocarcinoma.** A and B: Pathological finding revealed that the tumor originated from the fallopian tube wall and involved the mucosa and serosal membrane of the fallopian tube; C and D: Vestiges of mesonephric hyperplasia (C) and hyperplasia into cancerous nests (D) were histologically found. The histologic patterns of the tumor were mainly solid.



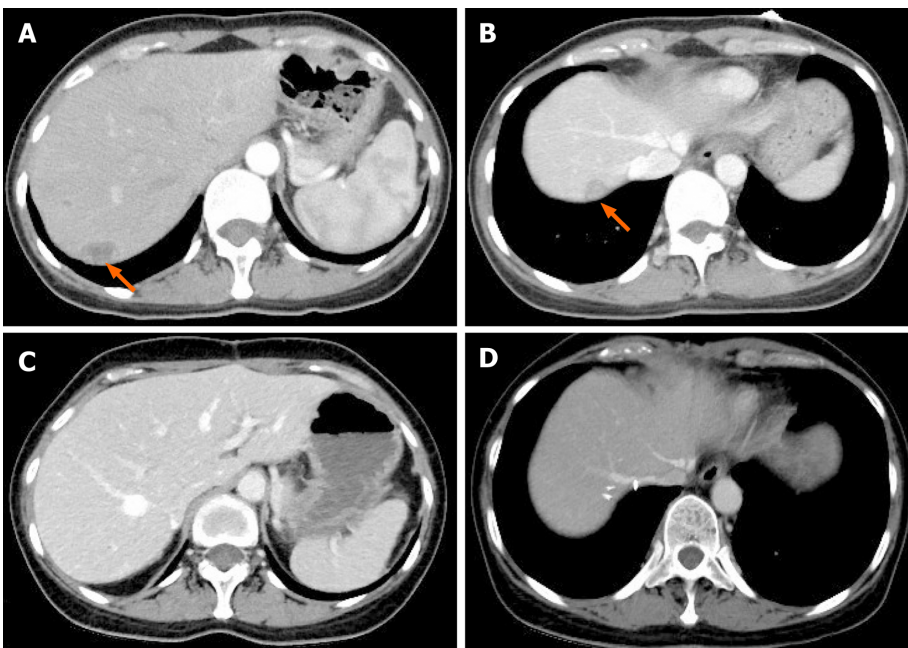
**Figure 2 Immunohistochemical staining of fallopian tube-mesonephric adenocarcinoma.** A: PAX8 expression in this case was strong and diffuse, indicating that the tumor arose from the female genital tract; B: GATA3 positivity is helpful in confirming the diagnosis of mesonephric carcinoma, but the staining may be weak and focal. In the present case, the staining for GATA3 was weak and diffuse; C: CD10 revealed cytoplasmic and luminal staining; D: Immunohistochemical staining for thyroid transcription factor-1 was strong and diffuse; E and F: Immunohistochemistry showed totally negative staining for Calretinin (E) and Wilms' tumour-1 (F).

rare disease, there are currently no established guidelines about standard therapy of FT-MNAC. However, a radical surgery may be the initial choice for localized disease. Comprehensive staging surgery including hysterectomy, bilateral salpingo-oophorectomy, omentectomy, and para-aortic plus pelvic lymphadenectomy was performed in most of the reported MNAC patients. In this case, the woman was a perimenopausal patient who had already given birth, therefore she received complete





**Figure 3 Immunohistochemical staining of fallopian tube-mesonephric adenocarcinoma.** A-C: Immunohistochemistry demonstrated totally negative staining for estrogen receptor (A), progesterone receptor (B), and CA125 (C); D and E: Positive staining for P16 (D) and P53 (E) was detected; F: The positive rate of Ki-67 expression was 60%-70%.



**Figure 4 Computed tomography images of the patient with hepatic recurrence.** A and B: Abdominal computed tomography (CT) scan detected low-density nodules under the liver capsule. The arrows indicate metastatic nodules in the liver, and the diameters of the metastatic lesions ranged from 1.5-2.5 cm; C and D: CT appearances of the liver after second resection of tumors in the liver plus partial hepatectomy.

staging surgery. Initial radical surgery is considered to be the standard treatment, but there is little evidence about the efficacy of the treatment with chemotherapy or radiotherapy after surgery. Because of its high malignancy, postoperative chemotherapy may be an important and necessary adjuvant treatment method for FT-MNAC to prevent or delay tumor recurrence like any other MNAC or fallopian tube cancer.



MNACs can be very aggressive, even at early stage. A review of the literature including 31 cases of MNAC reported that 82% of the patients had FIGO stage IB disease at initial diagnosis, but one third of the patients with FIGO stage I disease developed recurrence even after radical surgery. Distant metastases and local recurrence were frequent findings in this study, and the median time to recurrence was 2.1 years[5]. In another study, a recurrence rate of 32% was reported among patients with FIGO stage I MNAC[6]. Distant metastases at initial diagnosis were found in less than 5% of MNAC cases, but a malignant clinical course has been reported in about 40% of patients[7,8]. In our case, no distant metastasis was detected at the time of initial diagnosis. Although complete staging surgery combined with systemic chemotherapy was performed, the patient still developed tumor recurrence 4 mo after initial surgery, which indicated that FT-MNAC is very aggressive.

There are no specific recommendations about the treatment of recurrent MNAC especially FT-MNAC, due to limited number of reported cases. However, excision of locally recurrent lesions followed by systemic chemotherapy is still the optimal treatment for patients with recurrent MNAC. By the time being, there has been very little research about which chemotherapy regimen is effective for recurrent MNAC. A recent study reported a recurrent MNAC patient with good response to combination chemotherapy of paclitaxel and carboplatin[9]. However, this patient, who had been given chemotherapy with carboplatin plus paclitaxel after initial surgery, rapidly developed a distant relapse. Hence, a new combination chemotherapy with gemcitabine and carboplatin was administered to treat the present patient, and she had no evidence of disease recurrence within a 22 mo follow-up period, indicating that combination chemotherapy with carboplatin plus gemcitabine may be effective for treating FT-MNAC.

## CONCLUSION

We present the first case of primary FT-MNAC without sign of relapse or metastasis after second excision of recurrent lesions until now, which demonstrated a satisfactory response to combination chemotherapy of gemcitabine and carboplatin. FT-MNAC can be very aggressive, even at early stage. Because of its sensitivity to the chemotherapy regimen, it is reasonable that combination chemotherapy of gemcitabine and carboplatin plays an important role in the treatment of recurrent FT-MNAC. However, further research is needed to determine the effectiveness of this chemotherapy regimen and provide better therapeutic regimen.

## REFERENCES

- 1 **Howitt BE**, Nucci MR. Mesonephric proliferations of the female genital tract. *Pathology* 2018; **50**: 141-150 [PMID: [29269124](#) DOI: [10.1016/j.pathol.2017.11.084](#)]
- 2 **McCluggage WG**, Vosmikova H, Laco J. Ovarian Combined Low-grade Serous and Mesonephric-like Adenocarcinoma: Further Evidence for A Mullerian Origin of Mesonephric-like Adenocarcinoma. *Int J Gynecol Pathol* 2020; **39**: 84-92 [PMID: [30575604](#) DOI: [10.1097/PGP.0000000000000573](#)]
- 3 **McFarland M**, Quick CM, McCluggage WG. Hormone receptor-negative, thyroid transcription factor 1-positive uterine and ovarian adenocarcinomas: report of a series of mesonephric-like adenocarcinomas. *Histopathology* 2016; **68**: 1013-1020 [PMID: [26484981](#) DOI: [10.1111/his.12895](#)]
- 4 **Pors J**, Cheng A, Leo JM, Kinloch MA, Gilks B, Hoang L. A Comparison of GATA3, TTF1, CD10, and Calretinin in Identifying Mesonephric and Mesonephric-like Carcinomas of the Gynecologic Tract. *Am J Surg Pathol* 2018; **42**: 1596-1606 [PMID: [30148742](#) DOI: [10.1097/PAS.0000000000001142](#)]
- 5 **Yap OW**, Hendrickson MR, Teng NN, Kapp DS. Mesonephric adenocarcinoma of the cervix: a case report and review of the literature. *Gynecol Oncol* 2006; **103**: 1155-1158 [PMID: [17023031](#) DOI: [10.1016/j.ygyno.2006.08.031](#)]
- 6 **Dierickx A**, Göker M, Braems G, Tummers P, Van den Broecke R. Mesonephric adenocarcinoma of the cervix: Case report and literature review. *Gynecol Oncol Rep* 2016; **17**: 7-11 [PMID: [27354991](#) DOI: [10.1016/j.gore.2016.05.002](#)]
- 7 **Montalvo N**, Redrobán L, Galarza D. Mesonephric adenocarcinoma of the cervix: a case report with a three-year follow-up, lung metastases, and next-generation sequencing analysis. *Diagn Pathol* 2019; **14**: 71 [PMID: [31266530](#) DOI: [10.1186/s13000-019-0847-8](#)]
- 8 **Na K**, Kim HS. Clinicopathologic and Molecular Characteristics of Mesonephric Adenocarcinoma Arising From the Uterine Body. *Am J Surg Pathol* 2019; **43**: 12-25 [PMID: [29189288](#) DOI: [10.1097/PAS.0000000000000991](#)]
- 9 **Montagut C**, Mármol M, Rey V, Ordi J, Pahissa J, Roviroso A, Gascón P, Mellado B. Activity of chemotherapy with carboplatin plus paclitaxel in a recurrent mesonephric adenocarcinoma of the

uterine corpus. *Gynecol Oncol* 2003; **90**: 458-461 [PMID: 12893219 DOI: 10.1016/s0090-8258(03)00228-2]



Published by **Baishideng Publishing Group Inc**  
7041 Koll Center Parkway, Suite 160, Pleasanton, CA 94566, USA

**Telephone:** +1-925-3991568

**E-mail:** [bpgoffice@wjgnet.com](mailto:bpgoffice@wjgnet.com)

**Help Desk:** <https://www.f6publishing.com/helpdesk>

<https://www.wjgnet.com>

