

World Journal of *Clinical Cases*

World J Clin Cases 2021 June 26; 9(18): 4460-4880



Contents

Thrice Monthly Volume 9 Number 18 June 26, 2021

OPINION REVIEW

- 4460 Surgery for pancreatic tumors in the midst of COVID-19 pandemic

Kato H, Asano Y, Arakawa S, Ito M, Kawabe N, Shimura M, Hayashi C, Ochi T, Yasuoka H, Higashiguchi T, Kondo Y, Nagata H, Horiguchi A

REVIEW

- 4467 Roles of exosomes in diagnosis and treatment of colorectal cancer

Umwali Y, Yue CB, Gabriel ANA, Zhang Y, Zhang X

MINIREVIEWS

- 4480 Dynamics of host immune responses to SARS-CoV-2

Taherkhani R, Taherkhani S, Farshadpour F

- 4491 Current treatment for hepatitis C virus/human immunodeficiency virus coinfection in adults

Laiwatthanapaisan R, Sirinawastien A

- 4500 Anti-tumor effect of statin on pancreatic adenocarcinoma: From concept to precision medicine

Huang CT, Liang YJ

- 4506 Roles of vitamin A in the regulation of fatty acid synthesis

Yang FC, Xu F, Wang TN, Chen GX

ORIGINAL ARTICLE

Basic Study

- 4520 Identification of the circRNA-miRNA-mRNA regulatory network and its prognostic effect in colorectal cancer

Yin TF, Zhao DY, Zhou YC, Wang QQ, Yao SK

- 4542 Tetramethylpyrazine inhibits proliferation of colon cancer cells *in vitro*

Li H, Hou YX, Yang Y, He QQ, Gao TH, Zhao XF, Huo ZB, Chen SB, Liu DX

Case Control Study

- 4553 Significance of highly phosphorylated insulin-like growth factor binding protein-1 and cervical length for prediction of preterm delivery in twin pregnancies

Lan RH, Song J, Gong HM, Yang Y, Yang H, Zheng LM

Retrospective Cohort Study

- 4559** Expected outcomes and patients' selection before chemoembolization—"Six-and-Twelve or Pre-TACE-Predict" scores may help clinicians: Real-life French cohorts results

Adhoute X, Larrey E, Anty R, Chevallier P, Penaranda G, Tran A, Bronowicki JP, Raoul JL, Castellani P, Perrier H, Bayle O, Monnet O, Pol B, Bourliere M

Retrospective Study

- 4573** Application of intelligent algorithms in Down syndrome screening during second trimester pregnancy
Zhang HG, Jiang YT, Dai SD, Li L, Hu XN, Liu RZ
- 4585** Evaluation of a five-gene signature associated with stromal infiltration for diffuse large B-cell lymphoma
Nan YY, Zhang WJ, Huang DH, Li QY, Shi Y, Yang T, Liang XP, Xiao CY, Guo BL, Xiang Y
- 4599** Efficacy of combination of localized closure, ethacridine lactate dressing, and phototherapy in treatment of severe extravasation injuries: A case series
Lu YX, Wu Y, Liang PF, Wu RC, Tian LY, Mo HY
- 4607** Observation and measurement of applied anatomical features for thoracic intervertebral foramen puncture on computed tomography images
Wang R, Sun WW, Han Y, Fan XX, Pan XQ, Wang SC, Lu LJ
- 4617** Histological transformation of non-small cell lung cancer: Clinical analysis of nine cases
Jin CB, Yang L
- 4627** Diagnostic value of amygdala volume on structural magnetic resonance imaging in Alzheimer's disease
Wang DW, Ding SL, Bian XL, Zhou SY, Yang H, Wang P
- 4637** Comparison of ocular axis and corneal diameter between entropion and non-entropion eyes in children with congenital glaucoma
Wang Y, Hou ZJ, Wang HZ, Hu M, Li YX, Zhang Z

Observational Study

- 4644** Risk factors for postoperative delayed gastric emptying in ovarian cancer treated with cytoreductive surgery and hyperthermic intraperitoneal chemotherapy
Cui GX, Wang ZJ, Zhao J, Gong P, Zhao SH, Wang XX, Bai WP, Li Y
- 4654** Clinical characteristics, gastrointestinal manifestations and outcomes of COVID-19 patients in Iran; does the location matters?
Mokarram P, Dalivand MM, Pizuorno A, Aligolighasemabadi F, Sadeghdoust M, Sadeghdoust E, Aduli F, Oskrochi G, Brim H, Ashktorab H
- 4668** AWGS2019 vs EWGSOP2 for diagnosing sarcopenia to predict long-term prognosis in Chinese patients with gastric cancer after radical gastrectomy
Wu WY, Dong JJ, Huang XC, Chen ZJ, Chen XL, Dong QT, Bai YY

Prospective Study

- 4681** Clinical outcomes and 5-year follow-up results of keratosis pilaris treated by a high concentration of glycolic acid

Tian Y, Li XX, Zhang JJ, Yun Q, Zhang S, Yu JY, Feng XJ, Xia AT, Kang Y, Huang F, Wan F

Randomized Controlled Trial

- 4690** Tenofovir disoproxil fumarate in Chinese chronic hepatitis B patients: Results of a multicenter, double-blind, double-dummy, clinical trial at 96 weeks

Chen XF, Fan YN, Si CW, Yu YY, Shang J, Yu ZJ, Mao Q, Xie Q, Zhao W, Li J, Gao ZL, Wu SM, Tang H, Cheng J, Chen XY, Zhang WH, Wang H, Xu ZN, Wang L, Dai J, Xu JH

SYSTEMATIC REVIEWS

- 4700** Mesenteric ischemia in COVID-19 patients: A review of current literature

Kerawala AA, Das B, Solangi A

- 4709** Role of theories in school-based diabetes care interventions: A critical review

An RP, Li DY, Xiang XL

CASE REPORT

- 4721** Alport syndrome combined with lupus nephritis in a Chinese family: A case report

Liu HF, Li Q, Peng YQ

- 4728** Botulinum toxin injection for Cockayne syndrome with muscle spasticity over bilateral lower limbs: A case report

Hsu LC, Chiang PY, Lin WP, Guo YH, Hsieh PC, Kuan TS, Lien WC, Lin YC

- 4734** Meigs' syndrome caused by granulosa cell tumor accompanied with intrathoracic lesions: A case report

Wu XJ, Xia HB, Jia BL, Yan GW, Luo W, Zhao Y, Luo XB

- 4741** Primary mesonephric adenocarcinoma of the fallopian tube: A case report

Xie C, Shen YM, Chen QH, Bian C

- 4748** Pancreas-preserving duodenectomy for treatment of a duodenal papillary tumor: A case report

Wu B, Chen SY, Li Y, He Y, Wang XX, Yang XJ

- 4754** Pheochromocytoma with abdominal aortic aneurysm presenting as recurrent dyspnea, hemoptysis, and hypotension: A case report

Zhao HY, Zhao YZ, Jia YM, Mei X, Guo SB

- 4760** Minimally invasive removal of a deep-positioned cannulated screw from the femoral neck: A case report

Yang ZH, Hou FS, Yin YS, Zhao L, Liang X

- 4765** Splenic Kaposi's sarcoma in a human immunodeficiency virus-negative patient: A case report

Zhao CJ, Ma GZ, Wang YJ, Wang JH

- 4772** Neonatal syringocystadenoma papilliferum: A case report
Jiang HJ, Zhang Z, Zhang L, Pu YJ, Zhou N, Shu H
- 4778** Disappeared intralenticular foreign body: A case report
Xue C, Chen Y, Gao YL, Zhang N, Wang Y
- 4783** Femoral neck stress fractures after trampoline exercise: A case report
Nam DC, Hwang SC, Lee EC, Song MG, Yoo JI
- 4789** Collision carcinoma of the rectum involving neuroendocrine carcinoma and adenocarcinoma: A case report
Zhao X, Zhang G, Li CH
- 4797** Therapeutic effect of autologous concentrated growth factor on lower-extremity chronic refractory wounds: A case report
Liu P, Liu Y, Ke CN, Li WS, Liu YM, Xu S
- 4803** Cutaneous myiasis with eosinophilic pleural effusion: A case report
Fan T, Zhang Y, Lv Y, Chang J, Bauer BA, Yang J, Wang CW
- 4810** Severe hematuria due to vesical varices in a patient with portal hypertension: A case report
Wei ZJ, Zhu X, Yu HT, Liang ZJ, Gou X, Chen Y
- 4817** Rare coexistence of multiple manifestations secondary to thalamic hemorrhage: A case report
Yu QW, Ye TF, Qian WJ
- 4823** Anderson-Fabry disease presenting with atrial fibrillation as earlier sign in a young patient: A case report
Kim H, Kang MG, Park HW, Park JR, Hwang JY, Kim K
- 4829** Long-term response to avelumab and management of oligoprogression in Merkel cell carcinoma: A case report
Leão I, Marinho J, Costa T
- 4837** Central pontine myelinolysis mimicking glioma in diabetes: A case report
Shi XY, Cai MT, Shen H, Zhang JX
- 4844** Microscopic transduodenal excision of an ampullary adenoma: A case report and review of the literature
Zheng X, Sun QJ, Zhou B, Jin M, Yan S
- 4852** Growth hormone cocktail improves hepatopulmonary syndrome secondary to hypopituitarism: A case report
Ji W, Nie M, Mao JF, Zhang HB, Wang X, Wu XY
- 4859** Low symptomatic COVID-19 in an elderly patient with follicular lymphoma treated with rituximab-based immunotherapy: A case report
Łęcki S, Wyżgolik K, Nicze M, Georgiew-Nadziakiewicz S, Chudek J, Wdowiak K

- 4866** Adult rhabdomyosarcoma originating in the temporal muscle, invading the skull and meninges: A case report
Wang GH, Shen HP, Chu ZM, Shen J
- 4873** *Listeria monocytogenes* bacteremia in a centenarian and pathogen traceability: A case report
Zhang ZY, Zhang XA, Chen Q, Wang JY, Li Y, Wei ZY, Wang ZC

ABOUT COVER

Editorial Board Member of *World Journal of Clinical Cases*, Shingo Tsujinaka, MD, PhD, Assistant Professor, Senior Lecturer, Surgeon, Department of Surgery, Saitama Medical Center, Jichi Medical University, Saitama 330-8503, Japan. tsujinakas@omiya.jichi.ac.jp

AIMS AND SCOPE

The primary aim of *World Journal of Clinical Cases* (WJCC, *World J Clin Cases*) is to provide scholars and readers from various fields of clinical medicine with a platform to publish high-quality clinical research articles and communicate their research findings online.

WJCC mainly publishes articles reporting research results and findings obtained in the field of clinical medicine and covering a wide range of topics, including case control studies, retrospective cohort studies, retrospective studies, clinical trials studies, observational studies, prospective studies, randomized controlled trials, randomized clinical trials, systematic reviews, meta-analysis, and case reports.

INDEXING/ABSTRACTING

The WJCC is now indexed in Science Citation Index Expanded (also known as SciSearch®), Journal Citation Reports/Science Edition, Scopus, PubMed, and PubMed Central. The 2020 Edition of Journal Citation Reports® cites the 2019 impact factor (IF) for WJCC as 1.013; IF without journal self cites: 0.991; Ranking: 120 among 165 journals in medicine, general and internal; and Quartile category: Q3. The WJCC's CiteScore for 2019 is 0.3 and Scopus CiteScore rank 2019: General Medicine is 394/529.

RESPONSIBLE EDITORS FOR THIS ISSUE

Production Editor: Ji-Hong Lin; Production Department Director: Xiang Li; Editorial Office Director: Jin-Lai Wang.

NAME OF JOURNAL

World Journal of Clinical Cases

ISSN

ISSN 2307-8960 (online)

LAUNCH DATE

April 16, 2013

FREQUENCY

Thrice Monthly

EDITORS-IN-CHIEF

Dennis A Bloomfield, Sandro Vento, Bao-Gan Peng

EDITORIAL BOARD MEMBERS

<https://www.wjnet.com/2307-8960/editorialboard.htm>

PUBLICATION DATE

June 26, 2021

COPYRIGHT

© 2021 Baishideng Publishing Group Inc

INSTRUCTIONS TO AUTHORS

<https://www.wjnet.com/bpg/gerinfo/204>

GUIDELINES FOR ETHICS DOCUMENTS

<https://www.wjnet.com/bpg/GerInfo/287>

GUIDELINES FOR NON-NATIVE SPEAKERS OF ENGLISH

<https://www.wjnet.com/bpg/gerinfo/240>

PUBLICATION ETHICS

<https://www.wjnet.com/bpg/GerInfo/288>

PUBLICATION MISCONDUCT

<https://www.wjnet.com/bpg/gerinfo/208>

ARTICLE PROCESSING CHARGE

<https://www.wjnet.com/bpg/gerinfo/242>

STEPS FOR SUBMITTING MANUSCRIPTS

<https://www.wjnet.com/bpg/GerInfo/239>

ONLINE SUBMISSION

<https://www.f6publishing.com>



Disappeared intralenticular foreign body: A case report

Chao Xue, Ying Chen, Yan-Lin Gao, Nan Zhang, Yan Wang

ORCID number: Chao Xue 0000-0002-7476-5650; Ying Chen 0000-0002-5289-737X; Yan-Lin Gao 0000-0002-0518-1061; Nan Zhang 0000-0002-4708-6863; Yan Wang 0000-0002-1257-6635.

Author contributions: Xue C, Chen Y, Gao YL, and Zhang N are co-first authors of this article; Xue C and Chen Y managed the patient, performed the operation, reviewed the literature, and contributed to manuscript drafting; Gao YL and Zhang N did special eye examinations, reviewed the literature, and contributed to manuscript drafting; Wang Y were responsible for the revision of the manuscript for important intellectual content; all authors issued final approval for the version to be submitted.

Informed consent statement: Informed written consent was obtained from the patient for publication of this report and any accompanying images.

Conflict-of-interest statement: No conflicting relationship exists for any author.

CARE Checklist (2016) statement: The authors have read the CARE Checklist (2016), and the manuscript was prepared and revised according to the CARE Checklist (2016).

Open-Access: This article is an

Chao Xue, Ying Chen, Yan-Lin Gao, Nan Zhang, Yan Wang, Department of Ophthalmology, Tianjin Eye Hospital, Tianjin 300020, China

Corresponding author: Yan Wang, MD, PhD, Professor, Department of Ophthalmology, Tianjin Eye Hospital, No. 4 Gansu Road, Heping District, Tianjin 300020, China.
wangyan7143@vip.sina.com

Abstract

BACKGROUND

Intralenticular foreign body is rarely encountered in ophthalmic practice. In most cases, subsequent traumatic cataract requires cataract surgery for visual rehabilitation.

CASE SUMMARY

A 35-year-old man was injured by iron filings in his left eye. After the injury, the patient tried to draw the object out by himself using a magnet; however, the foreign body (FB) was pushed to the equator of the lens. The FB was removed by a magnet through the anterior chamber accessed through the original capsular wound. Since most of the lens was transparent and only partially opaque after the operation, the lens was kept under close observation. After the surgery, the patient's visual acuity reached 20/20 from 2/20, visual function recovered very well, and local opacity of the lens remained stable.

CONCLUSION

For intralenticular FB in the anterior cortex under the capsule, magnet may be a more advantageous way to remove the object.

Key Words: Intralenticular foreign body; Ocular trauma; Penetrating eye injury; Case report

©The Author(s) 2021. Published by Baishideng Publishing Group Inc. All rights reserved.

Core Tip: Intralenticular foreign body is rarely encountered in ophthalmic practice. In most of these studies, the lens was either preserved without intraocular foreign body removal or removed together with intraocular foreign bodies. The present case report is about successful retrieval of a foreign body from the lens while the lens is preserved, with resultant stable visual function.

open-access article that was selected by an in-house editor and fully peer-reviewed by external reviewers. It is distributed in accordance with the Creative Commons Attribution NonCommercial (CC BY-NC 4.0) license, which permits others to distribute, remix, adapt, build upon this work non-commercially, and license their derivative works on different terms, provided the original work is properly cited and the use is non-commercial. See: <http://creativecommons.org/licenses/by-nc/4.0/>

Manuscript source: Unsolicited manuscript

Specialty type: Ophthalmology

Country/Territory of origin: China

Peer-review report's scientific quality classification

Grade A (Excellent): 0
Grade B (Very good): 0
Grade C (Good): C
Grade D (Fair): 0
Grade E (Poor): 0

Received: January 5, 2021

Peer-review started: January 5, 2021

First decision: March 27, 2021

Revised: April 1, 2021

Accepted: April 23, 2021

Article in press: April 23, 2021

Published online: June 26, 2021

P-Reviewer: Xu X

S-Editor: Gong ZM

L-Editor: Wang TQ

P-Editor: Li JH



Citation: Xue C, Chen Y, Gao YL, Zhang N, Wang Y. Disappeared intralenticular foreign body: A case report. *World J Clin Cases* 2021; 9(18): 4778-4782

URL: <https://www.wjgnet.com/2307-8960/full/v9/i18/4778.htm>

DOI: <https://dx.doi.org/10.12998/wjcc.v9.i18.4778>

INTRODUCTION

Intralenticular foreign body is rarely encountered in ophthalmic practice. It only accounts for approximately 5% to 10% of all intraocular foreign bodies (IOFBs)[1]. In some cases, subsequent traumatic cataract requires cataract surgery for visual rehabilitation[2,3]. Conservative management of intralenticular foreign bodies has also been successful in other patients who have minimal lens opacities and stable visual function [3,4]. In most of these studies, the lens was either preserved without intraocular foreign body removal or removed together with intraocular foreign bodies[5].

However, in clinical practice, the condition is various, and sometimes it is rare and complicated. For rare cases, we should think carefully and try our best to get a good prognosis with optimized treatment. The present case report is about successful retrieval of a foreign body from the lens of the eye of a 35-year-old man, with resultant stable visual function. It was a rare and special case due to the patient's own incorrect treatment. In this case, the lens was preserved while the foreign body was removed.

CASE PRESENTATION

Chief complaints

A 35-year-old man who was injured by iron filings in his left eye visited our emergency room 1 d after the injury. He was admitted to the hospital.

History of present illness

The man was injured by iron filings in his left eye 1 d before visiting our emergency room.

History of past illness

The history of past illness was unremarkable.

Personal and family history

There was nothing special about personal and family history.

Physical examination

On local examination, the visual acuity was 20/20 in the right eye and 2/20 in the left eye. The intraocular pressure was 14 mmHg in the right eye and 13 mmHg in the left eye. Slit-lamp examination of the left eye showed a well-closed full-thickness corneal perforation wound (Figure 1A), an iris hole (Figure 1B, orange arrow), and only a localized lens opacity (Figure 1B, white arrow) at the corresponding positions. There were no cells, flare, or keratic precipitates. Despite dilating the pupil fully, we could not see the foreign body under direct vision. A band of a cloudy area was seen instead extending toward the equator of the lens (Figure 1C, orange arrow). We asked the patient about further events before he reported to us when we came to know about his attempts to remove the object by himself using a magnet. The patient had once successfully removed a foreign body from his arm; on another occasion, therefore, he tried attempting the same for his eye.

The band of the cloudy area towards the equator of the lens made us feel that the foreign body might be lying somewhere behind the iris. Computed tomography (CT) confirmed the presence of the foreign body around the equator of the lens (Figure 1D). An ultrasound biomicroscopic (UBM) examination was performed to check the relative positions of the foreign body and the lens, considering that the cornea wound was well closed (Figure 1E).

Laboratory examinations

Nothing abnormal was showed in the laboratory examinations.

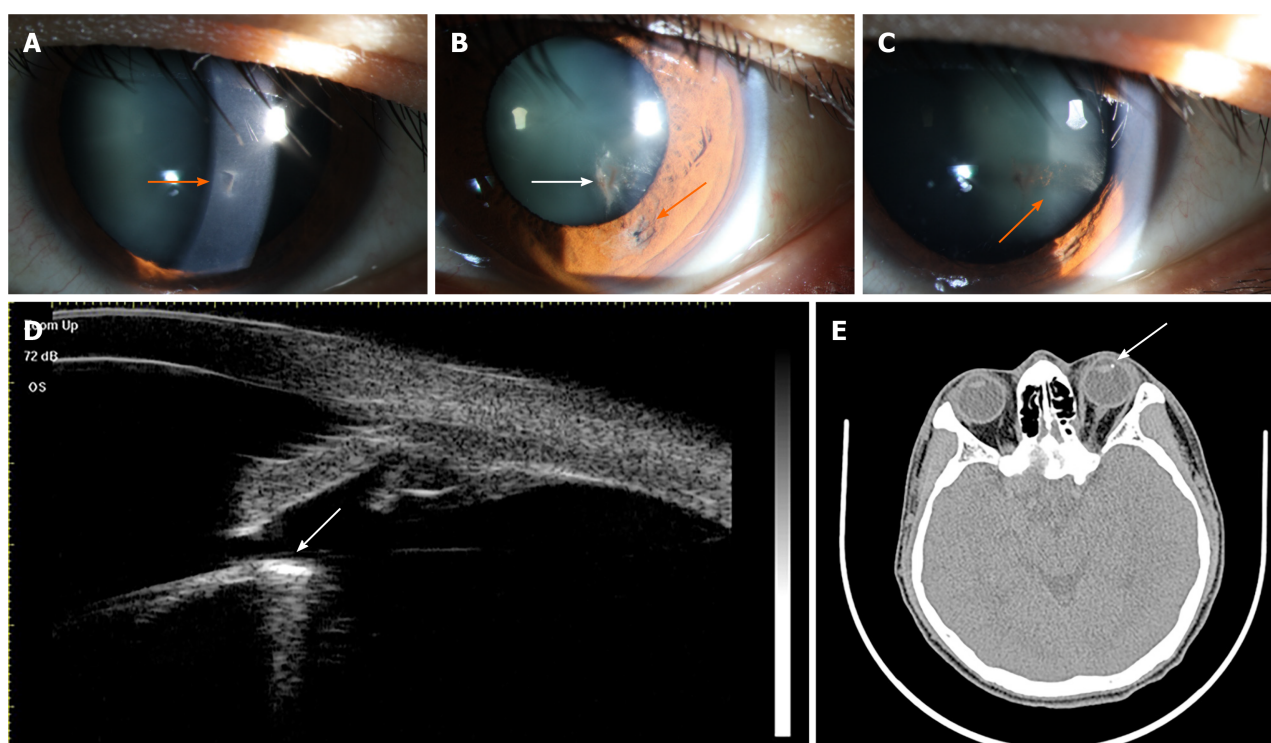


Figure 1 Examination of the injured eye preoperatively. A-C: Anterior segment photographs. Panel A shows a well-closed full-thickness corneal perforation wound (orange arrow), panel B shows an iris hole (orange arrow) and only a localized lens opacity (white arrow) at the corresponding positions, and panel C shows a band of a cloudy area that was seen instead extending toward the equator of the lens (orange arrow); D: Computed tomography showed the relative positions of the foreign body and the lens (white arrow); E: Ultrasound biomicroscope examination confirmed the presence of the foreign body around the equator of the lens (white arrow).

Imaging examinations

CT and UBM was performed to confirm the presence and positions of the foreign body.

FINAL DIAGNOSIS

From the medical history, clinical signs, examinations, and findings in the operation, it was clearly that the final diagnosis was intralenticular foreign body. It was a rare and special case for the patient's attempts to remove the object by himself using a magnet.

TREATMENT

During the procedure, a self-sealing 3.2 mm clear corneal major incision was made at the 11 o'clock position. Then, viscoelastic material was used to fill the anterior chamber. The iris was pushed away, revealing the position of the foreign body at the superficial layer of the lens equator. A magnet was inserted to the anterior chamber through the major corneal incision, and the foreign body was removed through the original capsular wound. Fortunately, the operation was smooth and did not cause any additional laceration of the anterior capsule of the lens after the removal of the object. As most of the lens was transparent and only partially opaque, we decided not to perform any further surgical intervention to the lens, but to observe the progression of traumatic cataract during follow-up.

OUTCOME AND FOLLOW-UP

Postoperative recovery was extremely good. On the 2nd day of the surgery, the visual acuity of the left eye was 20/20, and there was no sign of any cells or flare in the anterior chamber. The lens in the pupil area was transparent, with only local opacity.

One week after the surgery, the best-corrected visual acuity was 20/20 in the left eye, the lens in the pupil area was still transparent, and the local opacity did not expand (Figure 2). One month after the surgery, the best-corrected visual acuity was maintained at 20/20, the lens in the pupil retained transparency, and the local opacity region did not expand more. Three months after the surgery, during a follow-up call, the patient reported excellent visual acuity and did not feel any eye discomfort, indicating no further progression in the opacity.

DISCUSSION

The management of intralenticular foreign body involves an initial assessment of its size, site, material, any potential for infection, and degree of lenticular and other intraocular damage[6]. In this case, the foreign body was of the medium size, and it may cause a higher risk of complication(s) if not be removed. The foreign body embedded in the anterior cortex under the capsule, so a magnet was applied to remove it from the original capsular wound. In younger patients because of the accommodation, age plays a vital factor in the extraction of the lens during removal of the intraocular foreign body[7,8]. In this case, the patient was 35 years old, so we tried out best to retain his lens. Fortunately, the operation did not cause any additional laceration of the anterior capsule of the lens and most of the lens was transparent and only partially opaque; thus, we decided not to extract the lens. The reason for conservative observation was to avoid further damage to the eye, and more importantly, to maintain accommodation of the eye.

Despite a capsular breach, most of the lens was clear and only partial opaque in this case. If the capsular breach is small, the anterior capsule retains its healing capacity. The presence of the subcapsular epithelium makes it heal quickly by rapid epithelial proliferation, restoring its continuity and limiting the free passage of ions and fluid that may progress to the development of cataract formation[9,10].

From examinations and medical history, we could infer that the IOFB passed through the cornea, iris, and anterior capsule of the lens successively, and finally stayed at the superficial layer of the cortex in the middle part of the lens at the time of the primary injury. However, after the patient's attempts to remove the object by himself using a magnet, the IOFB was drawn to the equator of the lens.

The problem encountered in the process of treatment was that the foreign body might enlarge capsular breach, in which situation the development of traumatic cataract might accelerate and the cataract surgery might be necessary in this process. The foreign body was relatively tiny and was at the superficial layer of the lens. We inferred that the force between the magnet and the foreign body might not be strong. Probably, drawing the foreign body from the lens with magnet would not cause additional damage. We were very careful in the process and fortunately the operation was smooth and did not cause any additional laceration of the anterior capsule. The lens could be preserved while the foreign body was removed at the same time.

The critical aspect of this case was the patient's own attempt to retrieve the foreign object using a magnet before he reported to us. This made the case difficult during operation as the object was pushed to the equator of the lens and it may cause additional damage and increase opacity of the lens. Fortunately, with surgery, the patient's visual function recovered well, and local opacity of the lens remained stable without further progress. In summary, patients should not attempt any self-treatment particularly when it involves delicate structures such as the eyes as it might lead to further damage. The clinicians should take all possible considerations to preserve the physiological function when dealing with embedded intraocular foreign bodies. The limitation of this case report was a relatively short follow-up time, however, we can infer a good long-time outcome from the 3-mo follow-up result.

CONCLUSION

In conclusion, for intralenticular foreign body in the anterior cortex under the capsule, magnet may be a more advantageous way to remove the object. It is recommended to keep the lens if only partially opaque and maintain a close follow-up after retrieval of the foreign body, especially in younger patients, to maintain the accommodation of the eye.

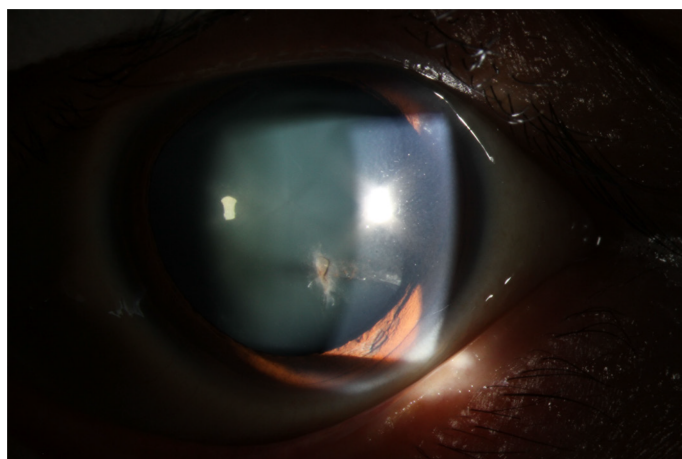


Figure 2 Anterior segment photograph of the injured eye 1 wk after surgery.

REFERENCES

- 1 Coleman DJ, Lucas BC, Rondeau MJ, Chang S. Management of intraocular foreign bodies. *Ophthalmology* 1987; **94**: 1647-1653 [PMID: 3431834 DOI: 10.1016/s0161-6420(87)33239-7]
- 2 Kumar A, Kumar V, Dapling RB. Traumatic cataract and intralenticular foreign body. *Clin Exp Ophthalmol* 2005; **33**: 660-661 [PMID: 16402963 DOI: 10.1111/j.1442-9071.2005.01115.x]
- 3 Dhawahir-Scala FE, Kamal A. Intralenticular foreign body: a D-Day reminder. *Clin Exp Ophthalmol* 2005; **33**: 659-660 [PMID: 16402962 DOI: 10.1111/j.1442-9071.2005.01114.x]
- 4 Lebowitz HA, Couch JM, Thompson JT, Shields JA. Occult foreign body simulating a choroidal melanoma with extrascleral extension. *Retina* 1988; **8**: 141-144 [PMID: 3047824 DOI: 10.1097/00006982-198808020-00011]
- 5 Lin YC, Kuo CL, Chen YM. Intralenticular foreign body: A case report and literature review. *Taiwan J Ophthalmol* 2019; **9**: 53-59 [PMID: 30993070 DOI: 10.4103/tjo.tjo_88_18]
- 6 Reddy SC. Intralenticular metallic foreign body: a case report. *Int J Ophthalmol* 2011; **4**: 326-328 [PMID: 22553673 DOI: 10.3980/j.issn.2222-3959.2011.03.25]
- 7 Cazabon S, Dabbs TR. Intralenticular metallic foreign body. *J Cataract Refract Surg* 2002; **28**: 2233-2234 [PMID: 12498867 DOI: 10.1016/s0886-3350(02)01431-1]
- 8 Loporchio D, Mukkamala L, Gorukanti K, Zarbin M, Langer P, Bhagat N. Intraocular foreign bodies: A review. *Surv Ophthalmol* 2016; **61**: 582-596 [PMID: 26994871 DOI: 10.1016/j.survophthal.2016.03.005]
- 9 Fagerholm PP, Philipson BT. Human traumatic cataract. A quantitative microradiographic and electron microscopic study. *Acta Ophthalmol (Copenh)* 1979; **57**: 20-32 [PMID: 419973 DOI: 10.1111/j.1755-3768.1979.tb06655.x]
- 10 Keeney AH. Intralenticular foreign bodies. *Arch Ophthalmol* 1971; **86**: 499-501 [PMID: 5114442 DOI: 10.1001/archophth.1971.01000010501003]



Published by **Baishideng Publishing Group Inc**
7041 Koll Center Parkway, Suite 160, Pleasanton, CA 94566, USA

Telephone: +1-925-3991568

E-mail: bpgoffice@wjgnet.com

Help Desk: <https://www.f6publishing.com/helpdesk>

<https://www.wjgnet.com>

