

World Journal of *Clinical Cases*

World J Clin Cases 2021 July 6; 9(19): 4881-5351



OPINION REVIEW

- 4881** Fear of missing out: A brief overview of origin, theoretical underpinnings and relationship with mental health
Gupta M, Sharma A

REVIEW

- 4890** Molecular pathways in viral hepatitis-associated liver carcinogenesis: An update
Elpek GO
- 4918** Gastroenterology and liver disease during COVID-19 and in anticipation of post-COVID-19 era: Current practice and future directions
Oikonomou KG, Papamichalis P, Zafeiridis T, Xanthoudaki M, Papapostolou E, Valsamaki A, Bouliaris K, Papamichalis M, Karvouniaris M, Vlachostergios PJ, Skoura AL, Komnos A
- 4939** Enhancing oxygenation of patients with coronavirus disease 2019: Effects on immunity and other health-related conditions
Mohamed A, Alawna M

MINIREVIEWS

- 4959** Clinical potentials of ginseng polysaccharide for treating gestational diabetes mellitus
Zhao XY, Zhang F, Pan W, Yang YF, Jiang XY
- 4969** Remarkable gastrointestinal and liver manifestations of COVID-19: A clinical and radiologic overview
Fang LG, Zhou Q
- 4980** Liver injury in COVID-19: Known and unknown
Zhou F, Xia J, Yuan HX, Sun Y, Zhang Y
- 4990** COVID-19 and gastroenteric manifestations
Chen ZR, Liu J, Liao ZG, Zhou J, Peng HW, Gong F, Hu JF, Zhou Y
- 4998** Role of epithelial-mesenchymal transition in chemoresistance in pancreatic ductal adenocarcinoma
Hu X, Chen W
- 5007** Insights into the virologic and immunologic features of SARS-COV-2
Polat C, Ergunay K

ORIGINAL ARTICLE**Basic Study**

- 5019** SMAC exhibits anti-tumor effects in ECA109 cells by regulating expression of inhibitor of apoptosis protein family

Jiang N, Zhang WQ, Dong H, Hao YT, Zhang LM, Shan L, Yang XD, Peng CL

Case Control Study

- 5028** Efficacy of Solitaire AB stent-release angioplasty in acute middle cerebral artery atherosclerosis obliterative cerebral infarction

Wang XF, Wang M, Li G, Xu XY, Shen W, Liu J, Xiao SS, Zhou JH

Retrospective Study

- 5037** Diagnostic value of different color ultrasound diagnostic method in endometrial lesions

Lin XL, Zhang DS, Ju ZY, Li XM, Zhang YZ

- 5046** Clinical and pathological features and risk factors for primary breast cancer patients

Lei YY, Bai S, Chen QQ, Luo XJ, Li DM

- 5054** Outcomes of high-grade aneurysmal subarachnoid hemorrhage patients treated with coiling and ventricular intracranial pressure monitoring

Wen LL, Zhou XM, Lv SY, Shao J, Wang HD, Zhang X

- 5064** Microwave ablation combined with hepatectomy for treatment of neuroendocrine tumor liver metastases

Zhang JZ, Li S, Zhu WH, Zhang DF

- 5073** Clinical application of individualized total arterial coronary artery bypass grafting in coronary artery surgery

Chen WG, Wang BC, Jiang YR, Wang YY, Lou Y

Observational Study

- 5082** Early diagnosis, treatment, and outcomes of five patients with acute thallium poisoning

Wang TT, Wen B, Yu XN, Ji ZG, Sun YY, Li Y, Zhu SL, Cao YL, Wang M, Jian XD, Wang T

- 5092** Sarcopenia in geriatric patients from the plateau region of Qinghai-Tibet: A cross-sectional study

Pan SQ, Li YM, Li XF, Xiong R

- 5102** Medium-term efficacy of arthroscopic debridement *vs* conservative treatment for knee osteoarthritis of Kellgren-Lawrence grades I-III

Lv B, Huang K, Chen J, Wu ZY, Wang H

Prospective Study

- 5112** Impact of continuous positive airway pressure therapy for nonalcoholic fatty liver disease in patients with obstructive sleep apnea

Hirono H, Watanabe K, Hasegawa K, Kohno M, Terai S, Ohkoshi S

Randomized Controlled Trial

- 5126** Erector spinae plane block at lower thoracic level for analgesia in lumbar spine surgery: A randomized controlled trial
Zhang JJ, Zhang TJ, Qu ZY, Qiu Y, Hua Z

SYSTEMATIC REVIEWS

- 5135** Controversies' clarification regarding ribavirin efficacy in measles and coronaviruses: Comprehensive therapeutic approach strictly tailored to COVID-19 disease stages
Liatsos GD
- 5179** Systematic review and meta-analysis of trans-jugular intrahepatic portosystemic shunt for cirrhotic patients with portal vein thrombosis
Zhang JB, Chen J, Zhou J, Wang XM, Chen S, Chu JG, Liu P, Ye ZD

CASE REPORT

- 5191** Myelodysplastic syndrome transformed into B-lineage acute lymphoblastic leukemia: A case report
Zhu YJ, Ma XY, Hao YL, Guan Y
- 5197** Imaging presentation and postoperative recurrence of peliosis hepatis: A case report
Ren SX, Li PP, Shi HP, Chen JH, Deng ZP, Zhang XE
- 5203** Delayed retroperitoneal hemorrhage during extracorporeal membrane oxygenation in COVID-19 patients: A case report and literature review
Zhang JC, Li T
- 5211** Autologous tenon capsule packing to treat posterior exit wound of penetrating injury: A case report
Yi QY, Wang SS, Gui Q, Chen LS, Li WD
- 5217** Treatment of leiomyomatosis peritonealis disseminata with goserelin acetate: A case report and review of the literature
Yang JW, Hua Y, Xu H, He L, Huo HZ, Zhu CF
- 5226** Homozygous deletion, c. 1114-1116del, in exon 8 of the *CRPPA* gene causes congenital muscular dystrophy in Chinese family: A case report
Yang M, Xing RX
- 5232** Successful diagnosis and treatment of jejunal diverticular haemorrhage by full-thickness enterotomy: A case report
Ma HC, Xiao H, Qu H, Wang ZJ
- 5238** Liver metastasis as the initial clinical manifestation of sublingual gland adenoid cystic carcinoma: A case report
Li XH, Zhang YT, Feng H
- 5245** Severe hyperbilirubinemia in a neonate with hereditary spherocytosis due to a *de novo* ankyrin mutation: A case report
Wang JF, Ma L, Gong XH, Cai C, Sun JJ

- 5252** Long-term outcome of indwelling colon observed seven years after radical resection for rectosigmoid cancer: A case report
Zhuang ZX, Wei MT, Yang XY, Zhang Y, Zhuang W, Wang ZQ
- 5259** Diffuse xanthoma in early esophageal cancer: A case report
Yang XY, Fu KI, Chen YP, Chen ZW, Ding J
- 5266** COVID-19 or treatment associated immunosuppression may trigger hepatitis B virus reactivation: A case report
Wu YF, Yu WJ, Jiang YH, Chen Y, Zhang B, Zhen RB, Zhang JT, Wang YP, Li Q, Xu F, Shi YJ, Li XP
- 5270** Maintenance treatment with infliximab for ulcerative ileitis after intestinal transplantation: A case report
Fujimura T, Yamada Y, Umeyama T, Kudo Y, Kanamori H, Mori T, Shimizu T, Kato M, Kawaida M, Hosoe N, Hasegawa Y, Matsubara K, Shimojima N, Shinoda M, Obara H, Naganuma M, Kitagawa Y, Hoshino K, Kuroda T
- 5280** Infliximab treatment of glycogenosis Ib with Crohn's-like enterocolitis: A case report
Gong YZ, Zhong XM, Zou JZ
- 5287** Hemichorea due to ipsilateral thalamic infarction: A case report
Li ZS, Fang JJ, Xiang XH, Zhao GH
- 5294** Intestinal gangrene secondary to congenital transmesenteric hernia in a child misdiagnosed with gastrointestinal bleeding: A case report
Zheng XX, Wang KP, Xiang CM, Jin C, Zhu PF, Jiang T, Li SH, Lin YZ
- 5302** Collagen VI-related myopathy with scoliosis alone: A case report and literature review
Li JY, Liu SZ, Zheng DF, Zhang YS, Yu M
- 5313** Neuromuscular electrical stimulation for a dysphagic stroke patient with cardiac pacemaker using magnet mode change: A case report
Kim M, Park JK, Lee JY, Kim MJ
- 5319** Four-year-old anti-N-methyl-D-aspartate receptor encephalitis patient with ovarian teratoma: A case report
Xue CY, Dong H, Yang HX, Jiang YW, Yin L
- 5325** Glutamic acid decarboxylase 65-positive autoimmune encephalitis presenting with gelastic seizure, responsive to steroid: A case report
Yang CY, Tsai ST
- 5332** Ectopic opening of the common bile duct into the duodenal bulb with recurrent choledocholithiasis: A case report
Xu H, Li X, Zhu KX, Zhou WC
- 5339** Small bowel obstruction caused by secondary jejunal tumor from renal cell carcinoma: A case report
Bai GC, Mi Y, Song Y, Hao JR, He ZS, Jin J
- 5345** Brugada syndrome associated with out-of-hospital cardiac arrest: A case report
Ni GH, Jiang H, Men L, Wei YY, A D, Ma X

ABOUT COVER

Editorial Board Member of *World Journal of Clinical Cases*, Fan-Bo Meng, MD, PhD, Chief Doctor, Deputy Director, Professor, Department of Cardiology, China-Japan Union Hospital of Jilin University, Changchun 130000, Jilin Province, China. mengfb@jlu.edu.cn

AIMS AND SCOPE

The primary aim of *World Journal of Clinical Cases* (WJCC, *World J Clin Cases*) is to provide scholars and readers from various fields of clinical medicine with a platform to publish high-quality clinical research articles and communicate their research findings online.

WJCC mainly publishes articles reporting research results and findings obtained in the field of clinical medicine and covering a wide range of topics, including case control studies, retrospective cohort studies, retrospective studies, clinical trials studies, observational studies, prospective studies, randomized controlled trials, randomized clinical trials, systematic reviews, meta-analysis, and case reports.

INDEXING/ABSTRACTING

The WJCC is now indexed in Science Citation Index Expanded (also known as SciSearch®), Journal Citation Reports/Science Edition, Scopus, PubMed, and PubMed Central. The 2020 Edition of Journal Citation Reports® cites the 2019 impact factor (IF) for WJCC as 1.013; IF without journal self cites: 0.991; Ranking: 120 among 165 journals in medicine, general and internal; and Quartile category: Q3. The WJCC's CiteScore for 2019 is 0.3 and Scopus CiteScore rank 2019: General Medicine is 394/529.

RESPONSIBLE EDITORS FOR THIS ISSUE

Production Editor: Yan-Xia Xing, Production Department Director: Yun-Xiaoqian Wu, Editorial Office Director: Jin-Li Wang.

NAME OF JOURNAL

World Journal of Clinical Cases

ISSN

ISSN 2307-8960 (online)

LAUNCH DATE

April 16, 2013

FREQUENCY

Thrice Monthly

EDITORS-IN-CHIEF

Dennis A Bloomfield, Sandro Vento, Bao-Gan Peng

EDITORIAL BOARD MEMBERS

<https://www.wjgnet.com/2307-8960/editorialboard.htm>

PUBLICATION DATE

July 6, 2021

COPYRIGHT

© 2021 Baishideng Publishing Group Inc

INSTRUCTIONS TO AUTHORS

<https://www.wjgnet.com/bpg/gerinfo/204>

GUIDELINES FOR ETHICS DOCUMENTS

<https://www.wjgnet.com/bpg/GerInfo/287>

GUIDELINES FOR NON-NATIVE SPEAKERS OF ENGLISH

<https://www.wjgnet.com/bpg/gerinfo/240>

PUBLICATION ETHICS

<https://www.wjgnet.com/bpg/GerInfo/288>

PUBLICATION MISCONDUCT

<https://www.wjgnet.com/bpg/gerinfo/208>

ARTICLE PROCESSING CHARGE

<https://www.wjgnet.com/bpg/gerinfo/242>

STEPS FOR SUBMITTING MANUSCRIPTS

<https://www.wjgnet.com/bpg/GerInfo/239>

ONLINE SUBMISSION

<https://www.f6publishing.com>



Autologous tenon capsule packing to treat posterior exit wound of penetrating injury: A case report

Quan-Yong Yi, Sang-Sang Wang, Qian Gui, Li-Shuang Chen, Wen-Die Li

ORCID number: Quan-Yong Yi 0000-0003-2305-7029; Sang-Sang Wang 0000-0003-2205-7019; Qian Gui 0000-0003-2101-7028; Li-Shuang Chen 0000-0003-2105-6028; Wen-Die Li 0000-0001-6891-2872.

Author contributions: Yi QY drafted the manuscript, collected the data, and reviewed the literature; Wang SS, Chen LS, Gui Q, and Li WD reviewed the literature and collected the data; Yi QY performed the surgery; Yi QY critically reviewed the final manuscript; all authors confirmed and approved the final manuscript.

Informed consent statement: Informed written consent was obtained from the patient for publication of this report and any accompanying images.

Conflict-of-interest statement: All authors declare that they have no conflicts of interest to disclose.

CARE Checklist (2016) statement: The authors have read the CARE Checklist (2016), and the manuscript was prepared and revised according to the CARE Checklist (2016).

Open-Access: This article is an open-access article that was selected by an in-house editor and fully peer-reviewed by external reviewers. It is distributed in

Quan-Yong Yi, Sang-Sang Wang, Qian Gui, Li-Shuang Chen, Wen-Die Li, Department of Ophthalmology, Ningbo Eye Hospital, Ningbo 315040, Zhejiang Province, China

Corresponding author: Quan-Yong Yi, MD, Chief Doctor, Department of Ophthalmology, Ningbo Eye Hospital, No. 855 Bei Ming Chen Road, Ningbo 315040, Zhejiang Province, China. quanyong_yi@163.com

Abstract

BACKGROUND

This study reports a case of autologous tenon capsule packing to treat the posterior exit wound of penetrating injury.

CASE SUMMARY

To treat a 58-year-old male patient with penetrating eyeball injury caused by an iron sheet, we used autologous tenon capsule packing. Two months after removal of the silicone oil, the corrected visual acuity was 0.3, the retina was flat, the tenon capsule graft was in place, the posterior wound closed well, and the intraocular pressure was 15.8 mmHg.

CONCLUSION

Autologous tenon capsule packing to treat the posterior exit wound of penetrating injury is safe and effective.

Key Words: Autologous; Penetrating injury; Case report

©The Author(s) 2021. Published by Baishideng Publishing Group Inc. All rights reserved.

Core Tip: Eyeball penetrating injury refers to an open trauma that may allow the exposure of any vulnerant into the eye from one side, and penetrates the entire eyeball and traverses through the other side of the eyeball. Eyeball penetrating injury wounds are divided into entry wound and exit wound. The laceration at the exit wound is often located at the posterior position and is difficult to suture during the first-stage surgery, and any attempt to a reckless suture may cause even greater damage to the eyeball. Thus, our report describes a newly modified technique involving the use of autologous tenon capsule packing to treat the posterior exit wound of penetrating injury.

accordance with the Creative Commons Attribution NonCommercial (CC BY-NC 4.0) license, which permits others to distribute, remix, adapt, build upon this work non-commercially, and license their derivative works on different terms, provided the original work is properly cited and the use is non-commercial. See: <http://creativecommons.org/licenses/by-nc/4.0/>

Manuscript source: Unsolicited manuscript

Specialty type: Ophthalmology

Country/Territory of origin: China

Peer-review report's scientific quality classification

Grade A (Excellent): 0
Grade B (Very good): B
Grade C (Good): C
Grade D (Fair): 0
Grade E (Poor): 0

Received: December 31, 2020

Peer-review started: December 31, 2020

First decision: March 27, 2021

Revised: April 7, 2021

Accepted: May 7, 2021

Article in press: May 7, 2021

Published online: July 6, 2021

P-Reviewer: Yang J

S-Editor: Zhang H

L-Editor: Wang TQ

P-Editor: Ma YJ



Citation: Yi QY, Wang SS, Gui Q, Chen LS, Li WD. Autologous tenon capsule packing to treat posterior exit wound of penetrating injury: A case report. *World J Clin Cases* 2021; 9(19): 5211-5216

URL: <https://www.wjgnet.com/2307-8960/full/v9/i19/5211.htm>

DOI: <https://dx.doi.org/10.12998/wjcc.v9.i19.5211>

INTRODUCTION

Eyeball penetrating injury refers to an open trauma that may allow the exposure of any vulnerant into the eye from one side, and penetrates the entire eyeball and traverses through the other side of the eyeball. Eyeball penetrating injury wounds are divided into entry wound and exit wound. The laceration at the exit wound is often located at the posterior position and is difficult to suture during the first-stage surgery, and any attempt to a reckless suture may cause even greater damage to the eyeball[1]. We report a case of secondary surgery in which a new modified technique was used to treat the exit wound after penetrating ocular injury.

CASE PRESENTATION

Chief complaints

A 58-year-old male patient presented with decreased vision acuity and pain for 5 h in the right eye after being injured by an iron bullet.

History of present illness

The patient was admitted to our emergency department after being injured by an iron bullet.

History of past illness

The patient was healthy.

Personal and family history

The patient had a disease-free personal and family history.

Physical examination

Ophthalmological examination of the right eye showed decreased naked vision, correct light projection, intraocular pressure of 3.7 mmHg, slight eyelid swelling, mixed congestion in the bulbar conjunctiva, and subconjunctival hemorrhage. An oblique laceration of about 6 mm long was visible in the bulbar conjunctiva at 5:30 o'clock direction and 4 mm away from the corneosclera margin. The cornea was slightly edematous with a large number of blood cells attached in the posterior cornea, and the depth of the anterior chamber was acceptable. The aqueous humor was bloody turbid. The pupil was round with a diameter of 4 mm and the lens was locally opaque. A large amount of vitreous hemorrhage was noticed and the fundus was unclear.

Laboratory examinations

Blood tests showed no obvious abnormality.

Imaging examinations

Orbital computed tomography showed an abnormal morphology of the right eyeball, and a foreign body behind the eyeball (Figure 1).

FINAL DIAGNOSIS

The final diagnosis of the present case was right eye penetrating injury and foreign body in the right eye orbit.

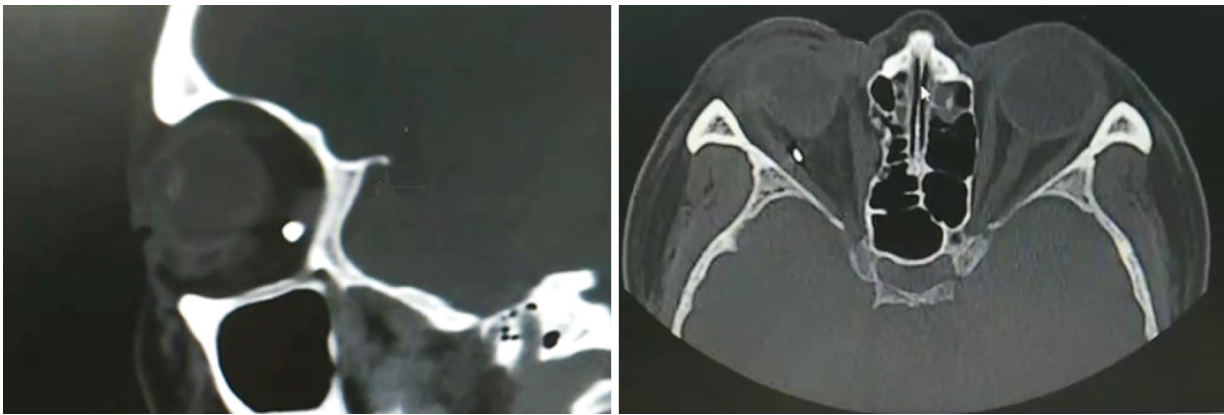


Figure 1 Orbital computed tomography showed a foreign body behind the right eyeball located discontinuously with the posterior wall of the eyeball.

TREATMENT

After emergency admission, the patient underwent right eyeball debridement and suturing with scleral exploration under local anesthesia. During surgery, a 6 mm long full-thickness laceration of the sclera was seen under a conjunctival laceration at 5:30 o'clock direction and 4 mm away from the scleral margin. The scleral laceration was closed with two stitches using 8-0 suture. Because the foreign body was located inside the posterior orbit and was stable in nature, the removal of it was not considered for the time being. Postoperatively, the patient was given general and topical antibiotics and hormonal medications, as well as preventive tetanus antitoxin. During 1 wk postoperatively, the patient's right eye was stable, without intraocular inflammation, elevated intraocular pressure, or intraocular active bleeding (*Figure 2*). One week later, the patient underwent "23G vitrectomy in the right eye" under local anesthesia to remove the vitreous hemorrhage. First, we performed a conventional 23G three channel incision to remove vitreous hemorrhage. It was found that the posterior exit wound of the penetrating injury was located at two pupillary distances (PD) below the temporal region of the macula in the right eye, and a full-thickness spindle hole with a transverse diameter of about one PD was seen in the wall of the eyeball. The conjunctiva was cut from the upper corneoscleral margin, the conjunctiva and fascia were separated, and a fascial flap with an appropriate size was selected, which was trimmed and filled in the hole at the posterior exit wound of the penetrating injury *via* the scleral puncture using intraocular forceps after the conjunctival epithelial tissue was removed. Subsequently, gas-liquid exchange in the vitreous cavity and injection of silicone oil were performed (*Figure 3*). The surgery diagram is shown in *Figure 4*. Postoperatively, the patient was given antibiotics and hormone eye drops.

OUTCOME AND FOLLOW-UP

The patient revisited the hospital at 2 wk, 1 mo, and 5 mo after surgery, and 2 mo after removal of the silicone oil. Ophthalmological examination at 2 wk after surgery revealed that the best corrected visual acuity of the right eye was 0.02, there was silicone oil filling in the vitreous cavity of the right eye and a flattened retina, the tenon capsule graft was in place at the hole of the fundus eyeball wall, and the intraocular pressure was 15.3 mmHg. Optical coherence tomography (OCT) examination showed that the stuffing tissue in the hole was protruded in place, and the surrounding retina was flattened. Ophthalmological examination at 5 mo after surgery showed that the best corrected visual acuity was 0.3, there was silicone oil filling in the vitreous cavity of the right eye and a flattened retina, the tenon capsule graft was in place at the hole of the fundus ocular wall, and the intraocular pressure was 16.1 mmHg. OCT examination showed that the stuffing tissue in the hole was in place and continuous with the surrounding tissue, and the surrounding retina was flat. Ophthalmological examination at 2 mo after removal of the silicone oil showed that the best corrected visual acuity was 0.3, there was a flattened retina, and the tenon capsule graft was in place at the hole of the fundus ocular wall. OCT examination showed that the stuffing tissue in the hole was in place and continuous with the surrounding tissue, the

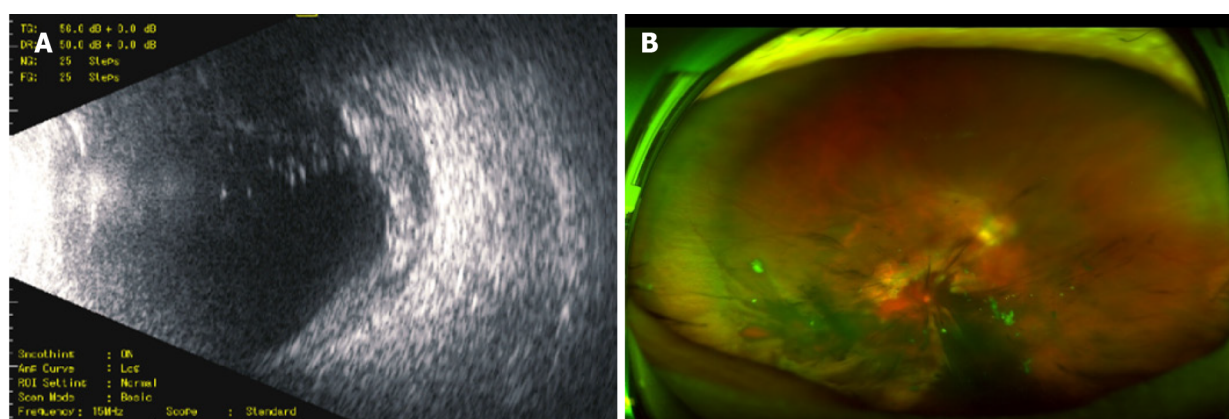


Figure 2 Ultrasound images. A: Ultrasound image of the fundus of the right eye after the first-stage scleral suturing showing opacity of the vitreous body in the right eye, with an abnormal echo of eyeball wall; B: Opel fundus image showing the vitreous hemorrhage with clots in the anterior retina of the posterior pole.

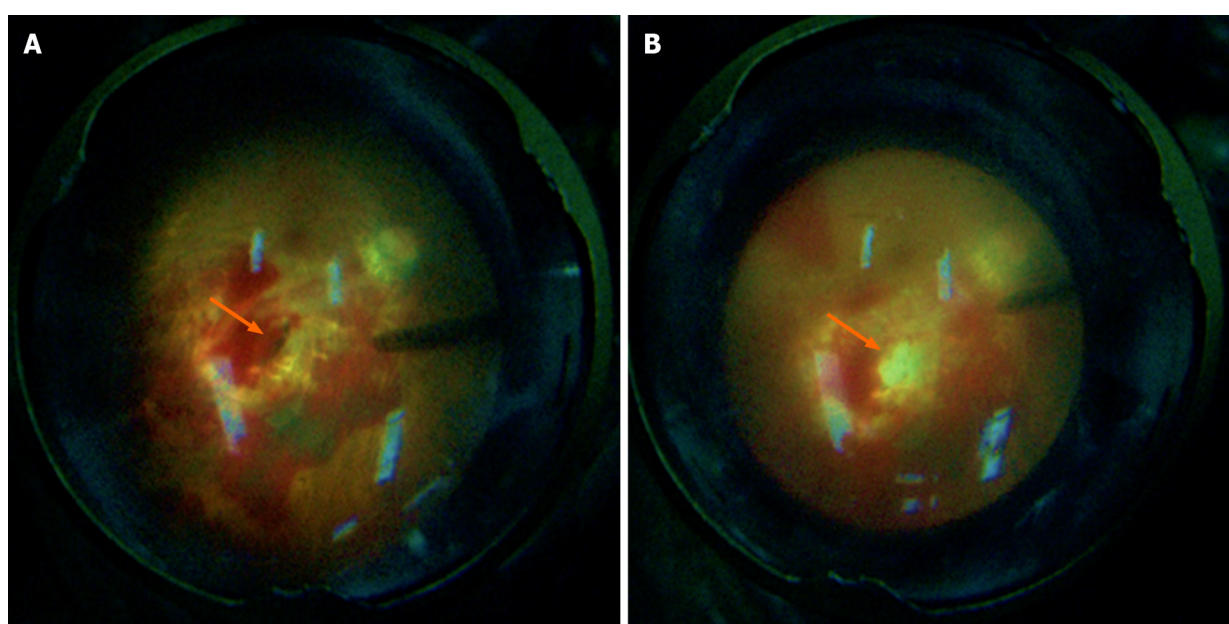


Figure 3 Intraoperative fundus photographs. A: Intraoperative fundus photograph showing a penetrating port with a transverse diameter of about one pupillary distance (PD) seen in the eyeball wall at two PD below the temporal region of the macula in the right eye; B: The autologous fascia was packed in the posterior exit wound, on which the surrounding inner limiting membrane was peeled off, flipped, and covered during the operation.

surrounding retina was flat, and the intraocular pressure was 15.8 mmHg (Figure 5). No complications occurred during or after the surgery.

DISCUSSION

Eyeball penetrating injury refers to an open trauma that may allow the exposure of any vulnerant into the eye from one side, and penetrates the entire eyeball and traverses through the other side of the eyeball. Such extensive injuries accompanied by intraocular or orbital foreign bodies often cause serious damages to the eye tissue, and may predispose to secondary infections, retinal detachment, and optic nerve damage, which leads to difficulty in treatment and a poor prognosis[2].

Clinically, eyeball penetrating injury wounds are divided into entry wound and exit wound. The laceration at the exit wound is often located at the posterior position and is difficult to suture during the first-stage surgery, and any attempt to a reckless suture may cause even greater damage to the eyeball. It was reported that some smaller wounds with stable intraocular pressure can heal by themselves within the time window of second-stage surgery. Moreover, during the second-stage vitreoretinal surgery, these small wounds that can heal by themselves can be quickly filled with

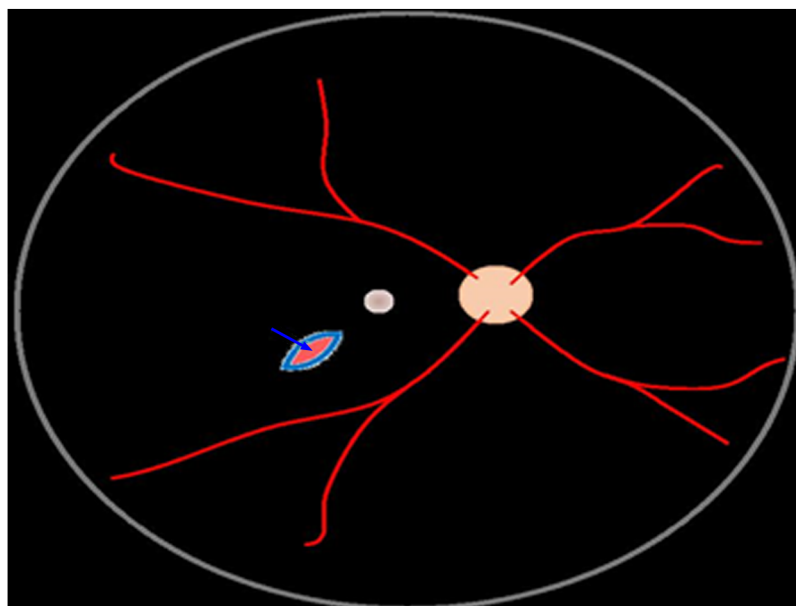


Figure 4 Surgery diagram. Green arrow shows autologous tenon capsule packing in the posterior exit wound.

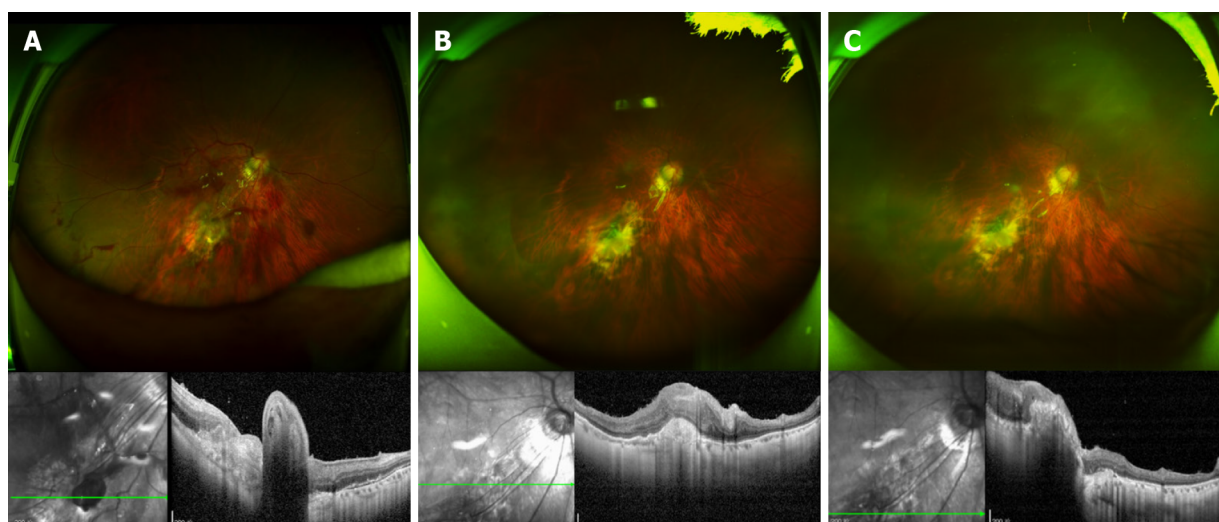


Figure 5 Ophthalmological examination after surgery A: Opkel fundus image and optical coherence tomography (OCT) at 2 wk after surgery. The Opkel fundus image shows that the autophagic fascia was in place in the submacrot temporal laceration of the right eye, with the hole closed and the retina flat. OCT examination showed that the stuffing tissue was protruded in place at the laceration, and the surrounding retina was flattened; B and C: Opkel fundus images and OCT at 5 mo after surgery and 2 mo after removal of the silicone oil. The Opkel fundus image shows that the autophagic fascia was in place in the submacrot temporal laceration of the right eye, with the hole closed and the retina flat. OCT showed that the stuffing tissue in the laceration was in place and connected with the surrounding tissue, and the surrounding retina was flat.

silicone oil after gas-liquid exchange, so as to control the stable intraocular pressure[3, 4]. On the other hand, larger wounds with more extensive damage are managed by filling the posterior exit wound using gelatin sponge. However, studies have shown that gelatin sponge is a synthetic material that may induce an immune response when used as a filler[5,6]. Zhu *et al*[7] have reported to use amnion transplantation to treat and correct the choroidal holes caused by trauma. Similar to gelatin, amnion as a foreign body filler may also potentially induce an immune response[7-9]. Ma *et al*[1] have used autologous tenon capsule transplantation to fill posterior exit wounds caused by penetrating injuries. The main component of the tenon capsule is fibrous tissue, which is similar to scleral tissue and conducive to tissue repair and scar healing. To avoid the chances of rejection reactions and to facilitate the healing process, autologous tenon capsules are used to fill such posterior exit wounds[1]. This method provided impressive results and restored the integrity of the wall of the eyeball, and maintained the intraocular pressure and prevented the leakage of silicone oil or inert

filling gas in the eye.

CONCLUSION

In this case, we used autologous tenon capsule packing to treat the posterior exit wound of penetrating injury, which achieved satisfactory effects. For the case, the posterior perforation port was closed well, without immune reaction and silicone oil overflow. The intraocular pressure remained normal. Over time, the stuffing became flat. It healed and had good continuity with the surrounding eyeball wall. This method provides a reference for the treatment of similar cases, but should be subject to validation with more cases and long-term observation.

REFERENCES

- 1 **Ma J**, Zhang Y, Moe MC, Zhu TP, Yao K. Transocular removal of a retrobulbar foreign body and internal patch of the posterior exit wound with autologous tenon capsule. *Arch Ophthalmol* 2012; **130**: 493-496 [PMID: 22491918 DOI: 10.1001/archophthalmol.2011.1482]
- 2 **Savar A**, Andreoli MT, Kloek CE, Andreoli CM. Enucleation for open globe injury. *Am J Ophthalmol* 2009; **147**: 595-600. e1 [PMID: 19181305 DOI: 10.1016/j.ajo.2008.10.017]
- 3 **Kanu LN**, Jiang Y, Gonzalez AF, Mieler WF. Visual and Anatomic Outcomes in Perforating Ocular Injuries. *J Vitreoretin Dis* 2019; **3**: 428-437 [PMID: 31742242 DOI: 10.1177/2474126419865992]
- 4 **Topping TM**, Abrams GW, Machemer R. Experimental double-perforating injury of the posterior segment in rabbit eyes: the natural history of intraocular proliferation. *Arch Ophthalmol* 1979; **97**: 735-742 [PMID: 426694 DOI: 10.1001/archopht.1979.01020010387024]
- 5 **Black P**. Cerebrospinal fluid leaks following spinal surgery: use of fat grafts for prevention and repair. Technical note. *J Neurosurg* 2002; **96**: 250-252 [PMID: 12450290 DOI: 10.3171/spi.2002.96.2.0250]
- 6 **Luparello C**, Mauro M, Lazzara V, Vazzana M. Collective Locomotion of Human Cells, Wound Healing and Their Control by Extracts and Isolated Compounds from Marine Invertebrates. *Molecules* 2020; **25** [PMID: 32466475 DOI: 10.3390/molecules25112471]
- 7 **Zhu D**, Jin X, Zhou J. Transplantation of amniotic membrane for choroidal hole to treat suprachoroidal silicone oil migration. *Acta Ophthalmol* 2017; **95**: e522-e523 [PMID: 28696567 DOI: 10.1111/aos.13516]
- 8 **Murphy SV**, Skardal A, Nelson RA Jr, Sunnon K, Reid T, Clouse C, Kock ND, Jackson J, Soker S, Atala A. Amnion membrane hydrogel and amnion membrane powder accelerate wound healing in a full thickness porcine skin wound model. *Stem Cells Transl Med* 2020; **9**: 80-92 [PMID: 31328435 DOI: 10.1002/sctm.19-0101]
- 9 **Dewey MJ**, Johnson EM, Slater ST, Milner DJ, Wheeler MB, Harley BAC. Mineralized collagen scaffolds fabricated with amniotic membrane matrix increase osteogenesis under inflammatory conditions. *Regen Biomater* 2020; **7**: 247-258 [PMID: 32523727 DOI: 10.1093/rb/rbaa005]



Published by **Baishideng Publishing Group Inc**
7041 Koll Center Parkway, Suite 160, Pleasanton, CA 94566, USA

Telephone: +1-925-3991568

E-mail: bpgoffice@wjgnet.com

Help Desk: <https://www.f6publishing.com/helpdesk>

<https://www.wjgnet.com>

