

World Journal of *Clinical Cases*

World J Clin Cases 2021 July 6; 9(19): 4881-5351



Contents

Thrice Monthly Volume 9 Number 19 July 6, 2021

OPINION REVIEW

- 4881** Fear of missing out: A brief overview of origin, theoretical underpinnings and relationship with mental health
Gupta M, Sharma A

REVIEW

- 4890** Molecular pathways in viral hepatitis-associated liver carcinogenesis: An update
Elpek GO
- 4918** Gastroenterology and liver disease during COVID-19 and in anticipation of post-COVID-19 era: Current practice and future directions
Oikonomou KG, Papamichalis P, Zafeiridis T, Xanthoudaki M, Papapostolou E, Valsamaki A, Bouliaris K, Papamichalis M, Karvouniaris M, Vlachostergios PJ, Skoura AL, Komnos A
- 4939** Enhancing oxygenation of patients with coronavirus disease 2019: Effects on immunity and other health-related conditions
Mohamed A, Alawna M

MINIREVIEWS

- 4959** Clinical potentials of ginseng polysaccharide for treating gestational diabetes mellitus
Zhao XY, Zhang F, Pan W, Yang YF, Jiang XY
- 4969** Remarkable gastrointestinal and liver manifestations of COVID-19: A clinical and radiologic overview
Fang LG, Zhou Q
- 4980** Liver injury in COVID-19: Known and unknown
Zhou F, Xia J, Yuan HX, Sun Y, Zhang Y
- 4990** COVID-19 and gastroenteric manifestations
Chen ZR, Liu J, Liao ZG, Zhou J, Peng HW, Gong F, Hu JF, Zhou Y
- 4998** Role of epithelial-mesenchymal transition in chemoresistance in pancreatic ductal adenocarcinoma
Hu X, Chen W
- 5007** Insights into the virologic and immunologic features of SARS-COV-2
Polat C, Ergunay K

ORIGINAL ARTICLE

Basic Study

- 5019 SMAC exhibits anti-tumor effects in ECA109 cells by regulating expression of inhibitor of apoptosis protein family

Jiang N, Zhang WQ, Dong H, Hao YT, Zhang LM, Shan L, Yang XD, Peng CL

Case Control Study

- 5028 Efficacy of Solitaire AB stent-release angioplasty in acute middle cerebral artery atherosclerosis obliterative cerebral infarction

Wang XF, Wang M, Li G, Xu XY, Shen W, Liu J, Xiao SS, Zhou JH

Retrospective Study

- 5037 Diagnostic value of different color ultrasound diagnostic method in endometrial lesions

Lin XL, Zhang DS, Ju ZY, Li XM, Zhang YZ

- 5046 Clinical and pathological features and risk factors for primary breast cancer patients

Lei YY, Bai S, Chen QQ, Luo XJ, Li DM

- 5054 Outcomes of high-grade aneurysmal subarachnoid hemorrhage patients treated with coiling and ventricular intracranial pressure monitoring

Wen LL, Zhou XM, Lv SY, Shao J, Wang HD, Zhang X

- 5064 Microwave ablation combined with hepatectomy for treatment of neuroendocrine tumor liver metastases

Zhang JZ, Li S, Zhu WH, Zhang DF

- 5073 Clinical application of individualized total arterial coronary artery bypass grafting in coronary artery surgery

Chen WG, Wang BC, Jiang YR, Wang YY, Lou Y

Observational Study

- 5082 Early diagnosis, treatment, and outcomes of five patients with acute thallium poisoning

Wang TT, Wen B, Yu XN, Ji ZG, Sun YY, Li Y, Zhu SL, Cao YL, Wang M, Jian XD, Wang T

- 5092 Sarcopenia in geriatric patients from the plateau region of Qinghai-Tibet: A cross-sectional study

Pan SQ, Li YM, Li XF, Xiong R

- 5102 Medium-term efficacy of arthroscopic debridement vs conservative treatment for knee osteoarthritis of Kellgren-Lawrence grades I-III

Lv B, Huang K, Chen J, Wu ZY, Wang H

Prospective Study

- 5112 Impact of continuous positive airway pressure therapy for nonalcoholic fatty liver disease in patients with obstructive sleep apnea

Hirono H, Watanabe K, Hasegawa K, Kohno M, Terai S, Ohkoshi S

Randomized Controlled Trial

- 5126** Erector spinae plane block at lower thoracic level for analgesia in lumbar spine surgery: A randomized controlled trial
Zhang JJ, Zhang TJ, Qu ZY, Qiu Y, Hua Z

SYSTEMATIC REVIEWS

- 5135** Controversies' clarification regarding ribavirin efficacy in measles and coronaviruses: Comprehensive therapeutic approach strictly tailored to COVID-19 disease stages
Liatsos GD
- 5179** Systematic review and meta-analysis of trans-jugular intrahepatic portosystemic shunt for cirrhotic patients with portal vein thrombosis
Zhang JB, Chen J, Zhou J, Wang XM, Chen S, Chu JG, Liu P, Ye ZD

CASE REPORT

- 5191** Myelodysplastic syndrome transformed into B-lineage acute lymphoblastic leukemia: A case report
Zhu YJ, Ma XY, Hao YL, Guan Y
- 5197** Imaging presentation and postoperative recurrence of peliosis hepatis: A case report
Ren SX, Li PP, Shi HP, Chen JH, Deng ZP, Zhang XE
- 5203** Delayed retroperitoneal hemorrhage during extracorporeal membrane oxygenation in COVID-19 patients: A case report and literature review
Zhang JC, Li T
- 5211** Autologous tenon capsule packing to treat posterior exit wound of penetrating injury: A case report
Yi QY, Wang SS, Gui Q, Chen LS, Li WD
- 5217** Treatment of leiomyomatosis peritonealis disseminata with goserelin acetate: A case report and review of the literature
Yang JW, Hua Y, Xu H, He L, Huo HZ, Zhu CF
- 5226** Homozygous deletion, c. 1114-1116del, in exon 8 of the *CRPPA* gene causes congenital muscular dystrophy in Chinese family: A case report
Yang M, Xing RX
- 5232** Successful diagnosis and treatment of jejunal diverticular haemorrhage by full-thickness enterotomy: A case report
Ma HC, Xiao H, Qu H, Wang ZJ
- 5238** Liver metastasis as the initial clinical manifestation of sublingual gland adenoid cystic carcinoma: A case report
Li XH, Zhang YT, Feng H
- 5245** Severe hyperbilirubinemia in a neonate with hereditary spherocytosis due to a *de novo* ankyrin mutation: A case report
Wang JF, Ma L, Gong XH, Cai C, Sun JJ

- 5252** Long-term outcome of indwelling colon observed seven years after radical resection for rectosigmoid cancer: A case report
Zhuang ZX, Wei MT, Yang XY, Zhang Y, Zhuang W, Wang ZQ
- 5259** Diffuse xanthoma in early esophageal cancer: A case report
Yang XY, Fu KI, Chen YP, Chen ZW, Ding J
- 5266** COVID-19 or treatment associated immunosuppression may trigger hepatitis B virus reactivation: A case report
Wu YF, Yu WJ, Jiang YH, Chen Y, Zhang B, Zhen RB, Zhang JT, Wang YP, Li Q, Xu F, Shi YJ, Li XP
- 5270** Maintenance treatment with infliximab for ulcerative ileitis after intestinal transplantation: A case report
Fujimura T, Yamada Y, Umeyama T, Kudo Y, Kanamori H, Mori T, Shimizu T, Kato M, Kawaida M, Hosoe N, Hasegawa Y, Matsubara K, Shimojima N, Shinoda M, Obara H, Naganuma M, Kitagawa Y, Hoshino K, Kuroda T
- 5280** Infliximab treatment of glycogenosis Ib with Crohn's-like enterocolitis: A case report
Gong YZ, Zhong XM, Zou JZ
- 5287** Hemichorea due to ipsilateral thalamic infarction: A case report
Li ZS, Fang JJ, Xiang XH, Zhao GH
- 5294** Intestinal gangrene secondary to congenital transmesenteric hernia in a child misdiagnosed with gastrointestinal bleeding: A case report
Zheng XX, Wang KP, Xiang CM, Jin C, Zhu PF, Jiang T, Li SH, Lin YZ
- 5302** Collagen VI-related myopathy with scoliosis alone: A case report and literature review
Li JY, Liu SZ, Zheng DF, Zhang YS, Yu M
- 5313** Neuromuscular electrical stimulation for a dysphagic stroke patient with cardiac pacemaker using magnet mode change: A case report
Kim M, Park JK, Lee JY, Kim MJ
- 5319** Four-year-old anti-N-methyl-D-aspartate receptor encephalitis patient with ovarian teratoma: A case report
Xue CY, Dong H, Yang HX, Jiang YW, Yin L
- 5325** Glutamic acid decarboxylase 65-positive autoimmune encephalitis presenting with gelastic seizure, responsive to steroid: A case report
Yang CY, Tsai ST
- 5332** Ectopic opening of the common bile duct into the duodenal bulb with recurrent choledocholithiasis: A case report
Xu H, Li X, Zhu KX, Zhou WC
- 5339** Small bowel obstruction caused by secondary jejunal tumor from renal cell carcinoma: A case report
Bai GC, Mi Y, Song Y, Hao JR, He ZS, Jin J
- 5345** Brugada syndrome associated with out-of-hospital cardiac arrest: A case report
Ni GH, Jiang H, Men L, Wei YY, A D, Ma X

ABOUT COVER

Editorial Board Member of *World Journal of Clinical Cases*, Fan-Bo Meng, MD, PhD, Chief Doctor, Deputy Director, Professor, Department of Cardiology, China-Japan Union Hospital of Jilin University, Changchun 130000, Jilin Province, China. mengfb@jlu.edu.cn

AIMS AND SCOPE

The primary aim of *World Journal of Clinical Cases* (WJCC, *World J Clin Cases*) is to provide scholars and readers from various fields of clinical medicine with a platform to publish high-quality clinical research articles and communicate their research findings online.

WJCC mainly publishes articles reporting research results and findings obtained in the field of clinical medicine and covering a wide range of topics, including case control studies, retrospective cohort studies, retrospective studies, clinical trials studies, observational studies, prospective studies, randomized controlled trials, randomized clinical trials, systematic reviews, meta-analysis, and case reports.

INDEXING/ABSTRACTING

The WJCC is now indexed in Science Citation Index Expanded (also known as SciSearch®), Journal Citation Reports/Science Edition, Scopus, PubMed, and PubMed Central. The 2020 Edition of Journal Citation Reports® cites the 2019 impact factor (IF) for WJCC as 1.013; IF without journal self cites: 0.991; Ranking: 120 among 165 journals in medicine, general and internal; and Quartile category: Q3. The WJCC's CiteScore for 2019 is 0.3 and Scopus CiteScore rank 2019: General Medicine is 394/529.

RESPONSIBLE EDITORS FOR THIS ISSUE

Production Editor: Yan-Xia Xing, Production Department Director: Yun-Xiaoqian Wu, Editorial Office Director: Jin-Li Wang.

NAME OF JOURNAL

World Journal of Clinical Cases

ISSN

ISSN 2307-8960 (online)

LAUNCH DATE

April 16, 2013

FREQUENCY

Thrice Monthly

EDITORS-IN-CHIEF

Dennis A Bloomfield, Sandro Vento, Bao-Gan Peng

EDITORIAL BOARD MEMBERS

<https://www.wjgnet.com/2307-8960/editorialboard.htm>

PUBLICATION DATE

July 6, 2021

COPYRIGHT

© 2021 Baishideng Publishing Group Inc

INSTRUCTIONS TO AUTHORS

<https://www.wjgnet.com/bpg/gerinfo/204>

GUIDELINES FOR ETHICS DOCUMENTS

<https://www.wjgnet.com/bpg/GerInfo/287>

GUIDELINES FOR NON-NATIVE SPEAKERS OF ENGLISH

<https://www.wjgnet.com/bpg/gerinfo/240>

PUBLICATION ETHICS

<https://www.wjgnet.com/bpg/GerInfo/288>

PUBLICATION MISCONDUCT

<https://www.wjgnet.com/bpg/gerinfo/208>

ARTICLE PROCESSING CHARGE

<https://www.wjgnet.com/bpg/gerinfo/242>

STEPS FOR SUBMITTING MANUSCRIPTS

<https://www.wjgnet.com/bpg/GerInfo/239>

ONLINE SUBMISSION

<https://www.f6publishing.com>



Severe hyperbilirubinemia in a neonate with hereditary spherocytosis due to a *de novo* ankyrin mutation: A case report

Jun-Fang Wang, Li Ma, Xiao-Hui Gong, Cheng Cai, Jing-Jing Sun

ORCID number: Jun-Fang Wang 0000-0003-3328-978X; Li Ma 0000-0003-3212-0704; Xiao-Hui Gong 0000-0001-7956-8608; Cheng Cai 0000-0002-9320-0495; Jing-Jing Sun 0000-0002-7077-4058.

Author contributions: Wang JF interpreted the data and wrote the manuscript; Sun JJ and Cai C collected clinical information and provided genetics counseling; Sun JJ and Ma L provided patient samples and determined the phenotype based on the clinical criteria; Wang JF analyzed the data; Gong XH and Ma L designed the study and revised the manuscript.

Supported by Shanghai Jiao Tong University "Jiao Tong Star" Medical-Industrial Cross-Research Fund, No. YG2019ZDA01; Shanghai Key Clinical Specialty Project, No. shslczdk05705.

Informed consent statement: Informed written consent was obtained from the patient for publication of this report and any accompanying images.

Conflict-of-interest statement: The authors declared no conflicts of interest.

CARE Checklist (2016) statement: The authors have read the CARE Checklist (2016), and the

Jun-Fang Wang, Li Ma, Xiao-Hui Gong, Cheng Cai, Jing-Jing Sun, Department of Neonatology, Shanghai Children's Hospital, Shanghai Jiao Tong University, Shanghai 200062, China

Li Ma, Xiao-Hui Gong, Cheng Cai, Jing-Jing Sun, NHC Key Laboratory of Medical Embryogenesis and Developmental Molecular Biology, Shanghai Key Laboratory of Embryo and Reproduction Engineering, Shanghai 200062, China

Corresponding author: Jing-Jing Sun, MD, Chief Physician, Department of Neonatology, Shanghai Children's Hospital, Shanghai Jiao Tong University, No. 355 Liding Road, Putuo District, Shanghai 200062, China. [sunjj@shchildren.com.cn](mailto:sunj@shchildren.com.cn)

Abstract

BACKGROUND

Hereditary spherocytosis (HS) is a common type of hemolytic anemia caused by a red cell membrane disorder. HS type 1 (HS1) is mostly caused by mutations in ankyrin (ANK1). Newborns with HS1 usually only exhibit anemia and mild jaundice. We herein report a case of HS1 and discuss its clinical characteristics.

CASE SUMMARY

A 2-d-old male full-term newborn was admitted to our hospital with severe, intractable neonatal jaundice. Laboratory investigations showed hemolytic anemia and hyperbilirubinemia and excluded immune-mediated hemolysis. The patient underwent two exchange transfusions and one plasmapheresis resulting in significantly reduced serum bilirubin. Hematologic analyses and genomic DNA sequencing studies were performed. The trio clinical exome sequencing revealed a *de novo* null heterozygous mutation in the patient's ANK1 gene: c.841C > T(p.Arg281Ter). This mutation results in the premature termination of the ANK1 protein.

CONCLUSION

Our case demonstrates that genetic analysis can be an essential method for diagnosing HS when a newborn has severe hyperbilirubinemia.

Key Words: Hereditary spherocytosis; Ankyrin; Neonate; Intractable neonatal jaundice; Case report

©The Author(s) 2021. Published by Baishideng Publishing Group Inc. All rights reserved.

manuscript was prepared and revised according to the CARE Checklist (2016).

Open-Access: This article is an open-access article that was selected by an in-house editor and fully peer-reviewed by external reviewers. It is distributed in accordance with the Creative Commons Attribution NonCommercial (CC BY-NC 4.0) license, which permits others to distribute, remix, adapt, build upon this work non-commercially, and license their derivative works on different terms, provided the original work is properly cited and the use is non-commercial. See: <http://creativecommons.org/licenses/by-nc/4.0/>

Manuscript source: Unsolicited manuscript

Specialty type: Pediatrics

Country/Territory of origin: China

Peer-review report's scientific quality classification

Grade A (Excellent): 0
Grade B (Very good): B
Grade C (Good): 0
Grade D (Fair): 0
Grade E (Poor): 0

Received: January 30, 2021

Peer-review started: January 30, 2021

First decision: May 6, 2021

Revised: May 10, 2021

Accepted: May 19, 2021

Article in press: May 19, 2021

Published online: July 6, 2021

P-Reviewer: Reddy R

S-Editor: Wang JL

L-Editor: Filipodia

P-Editor: Xing YX



Core Tip: Hereditary spherocytosis (HS) is a common type of hemolytic anemia caused by red cell membrane disorder. HS type 1 (HS1) typically results from mutations in ankyrin (*ANK1*). Newborns with HS1 usually only exhibit anemia and mild jaundice. This paper reports on a Chinese neonate who developed severe, intractable neonatal jaundice unrelated to immune-mediated hemolysis. The patient underwent two exchange transfusions and one plasmapheresis, which significantly reduced his extreme hyperbilirubinemia. Using trio clinical exome sequencing, we identified a *de novo* null heterozygous mutation in the patient's *ANK1* gene: c.841C > T(p.Arg281Ter), which resulted in the premature termination of ANK1 protein.

Citation: Wang JF, Ma L, Gong XH, Cai C, Sun JJ. Severe hyperbilirubinemia in a neonate with hereditary spherocytosis due to a *de novo* ankyrin mutation: A case report. *World J Clin Cases* 2021; 9(19): 5245-5251

URL: <https://www.wjgnet.com/2307-8960/full/v9/i19/5245.htm>

DOI: <https://dx.doi.org/10.12998/wjcc.v9.i19.5245>

INTRODUCTION

Hereditary spherocytosis (HS) is the most common monogenic hemolytic anemia disease and is characterized by spherical-shaped erythrocytes in patients' peripheral blood. Approximately 75% of HS cases are inherited in an autosomal dominant manner[1]. The clinical manifestations of HS vary widely, ranging from almost asymptomatic to dependence on blood transfusions or severe life-threatening anemia. HS occurs worldwide, particularly in Northern Europe and North America, where the incidence is 1 in 1000 to 2000 births[2]. In China, the epidemiology of HS is poorly understood. A systematic review from China estimated that the prevalence was 1.27 cases per 100000 people in males and 1.49 cases per 100000 people in females between January 1987 and December 2013[3]. However, only one-third of children are diagnosed with HS in the first year of life[4], and HS is rarely diagnosed in the neonatal period. HS is thought to have a high underdiagnosis rate due to limited clinical recognition during the neonatal period. The clinical manifestations of HS include anemia, jaundice, and splenomegaly. More than two-thirds of neonates with HS have near-normal hemoglobin (Hb) values at birth but then develop a dramatic decrease in Hb levels during the first weeks of life[5]. Physiological jaundice is the most common presenting feature of HS in neonates without any treatments[6], and splenomegaly is rarely detected[5]. The characteristic spherocytes are observed less often in the blood smear of neonates[7].

ANK1 mutations (approximately 50%) are the most common cause of HS type 1 (HS1)[8]. The functional defects of ankyrin protein, located in the red blood cell membrane, lead to the loss of membrane cohesion, a loss of surface area, and an increase in the number of peripheral blood cells[9]. *ANK1* mutations are associated with both dominant and recessive HS and are frequently mutated *de novo*[10]. Using exome sequencing to detect pathogenic mutations in *ANK1* and other genes would allow an early HS diagnosis.

This report describes a unique case of HS1 in a Chinese neonate with extreme hyperbilirubinemia and anemia, which was treated with two exchange transfusions and one plasmapheresis. Using the trio clinical exome sequencing method, we identified a *de novo* *ANK1* null mutant causing HS1. This report will contribute to the understanding and diagnosis of HS in neonates.

CASE PRESENTATION

Chief complaints

The patient was a 2-d-old male newborn admitted to the Department of Neonatology due to severe jaundice.

History of present illness

He was the first child of healthy, non-consanguineous Chinese parents without any

known family history. He was born *via* cesarean delivery at a gestational age of 39⁺6 wk with APGAR scores of 9 at 1 and 5 min after birth. His birth weight was 3125 g (P10-P50), and his length was 48 cm (P10). He developed jaundice within 24 h after birth without apnea, fever, or seizures in the maternity hospital. Laboratory tests revealed serum bilirubin (SBR) of 413.9 $\mu\text{mol/L}$ (direct 21.5) and Hb of 17.9 g/dL. The blood types of both the baby and the mother were B+. Double phototherapy and intravenous infusion of albumin were initiated. However, his bilirubin level did not significantly decrease (413.9 to 395.9 $\mu\text{mol/L}$) despite ongoing double phototherapy, and he was admitted to our neonatal intensive care unit 2 d after birth.

History of past illness

The patient had been hospitalized in a maternity hospital for 2 d.

Personal and family history

He was the first child of healthy, non-consanguineous Chinese parents without any known family history.

Physical examination

Physical examination showed jaundice with neither pallor nor palpable liver and spleen. No other abnormalities on physical examination, such as poor sucking, decreased alertness/lethargy, high-pitched cry, hypertonia of the extensor muscles, and hypotonia, were detected.

Laboratory examinations

The glucose-6-phosphate dehydrogenase deficiency screen and direct Coombs test were negative. Erythrocyte osmotic fragility was negative. Spherocytes were not observed on the blood smear. For the blood routine examination, the hemoglobin level was 13.2 g/dL (normal range, 15-23 g/dL), the mean corpuscular volume was 96.2 fL (normal range, 99-113 fL), the mean corpuscular hemoglobin was 34.9 pg (normal range, 27-32 pg), the mean corpuscular hemoglobin concentration was 36.2 g/dL (normal range, 31.7-33.0 g/dL), the standard deviation of red cell distribution width was 71.3 fL (37-54 fL), and the coefficient variation of red cell volume distribution width was 20.3% (11.0-16.0%). The SBR was 354.8 $\mu\text{mol/L}$ (direct 37), with a reticulocyte of 12.18%.

Imaging examinations

Axial T1-weighted brain magnetic resonance imaging sequence revealed a bilateral, symmetrical, hyperintense signal in the globus pallidus without a mass effect, which suggested kernicterus ([Figure 1B](#)).

FINAL DIAGNOSIS

Genetic analysis revealed a heterozygous null mutation in the patient's *ANK1* gene: c.841C > T(p.Arg281Ter). Sanger sequencing results showed that the heterozygous nonsense mutation was not detected in the patient's parents, indicating a *de novo* mutation ([Figure 2](#)). Combined with the above results, the patient was diagnosed with HS1.

TREATMENT

Considering that this child had a rare but severe hyperbilirubinemia and neglected hemolytic disease, an exchange transfusion was performed *via* a continuous arterio-venous exchange. The SBR began falling, with subsequent measurements of 232.6 $\mu\text{mol/L}$. One day later, the SBR elevated to 469.7 $\mu\text{mol/L}$ (direct 27.6), with Hb of 11.7 g/dL. The second exchange transfusion was performed, and the SBR decreased to 448 $\mu\text{mol/L}$. The next day SBR was elevated to 465 $\mu\text{mol/L}$. After two exchange transfusions without any obvious improvement, therapeutic plasma exchange was provided, which decreased serum bilirubin. The patient experienced a subsequent decrease in total bilirubin from 465 $\mu\text{mol/L}$ to a nadir value of 197.0 $\mu\text{mol/L}$. No significant increase in bilirubin was observed under phototherapy.

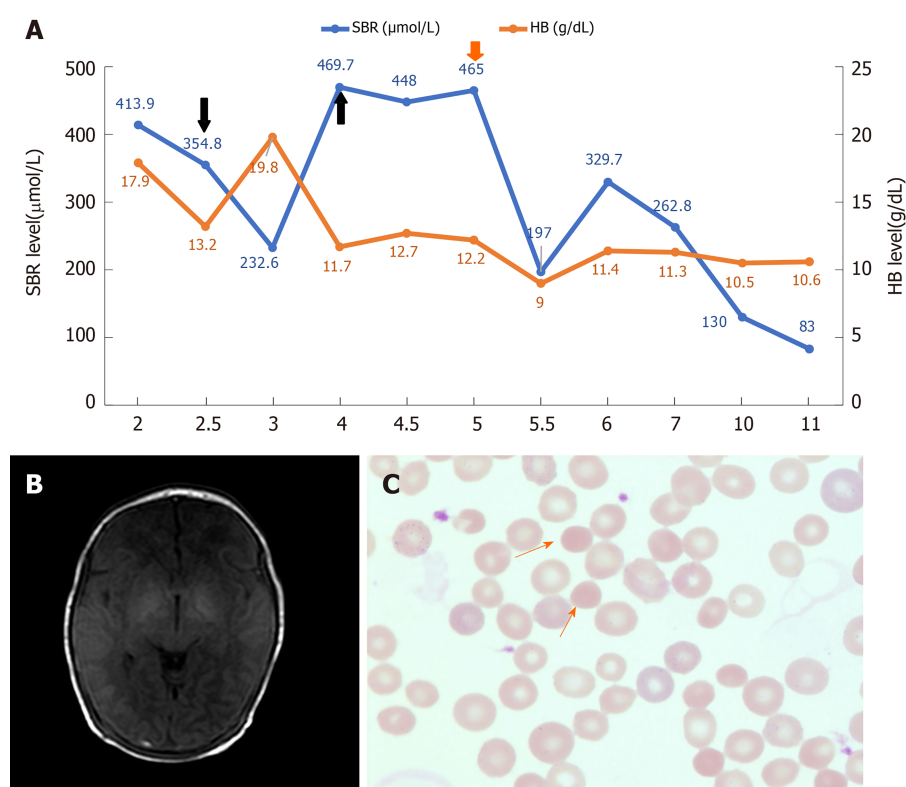


Figure 1 The representative clinical characteristics, imaging findings, and peripheral blood smears results. A: The dynamic changes of serum bilirubin (SBR) (blue) and hemoglobin (HB) (orange) levels during hospitalization. The treatment of exchange transfusion and plasmapheresis are indicated by the black and red arrow respectively. The number on the X axis represents the number of days after birth; B: The imaging finding of axial T1-weighted brain magnetic resonance imaging sequence done at 1 wk after birth; C: Morphology of erythrocytes in the blood smear (Wright-Giemsa stain; magnification, $\times 1000$). The spherocyte is indicated by the orange arrows.

OUTCOME AND FOLLOW-UP

After 4 d without phototherapy, bilirubin fluctuated between 83–130 $\mu\text{mol/L}$, and Hb was stable between 10.5–11.4 g/dL (Figure 1A). The patient did not have any abnormal neurologic manifestations and was discharged after 11 d of hospitalization. This patient has been followed up regularly. The spherocytes were observed on the blood smear at 6 mo of age (Figure 1C). To date, he has shown mild anemia and jaundice, but he has not experienced splenomegaly. No visual, auditory, or extrapyramidal abnormalities have been observed in this patient.

DISCUSSION

In this report, we describe a Chinese male neonate with HS1, resulting in severe hyperbilirubinemia. A *de novo* mutation in exon 9: c.841C > T(p.Arg281Ter) caused the premature termination of peptide translation in exon 9 of *ANK1*, which was found through trio clinical exome sequencing followed by Sanger sequencing.

HS is an inherited membranopathy of red blood cells characterized by phenotypic and genotypic heterogeneity, making it difficult to diagnose during the first year of life [11]. During the perinatal period, the clinical manifestation of HS ranges from severe fetal anemia with hydrops fetalis to no clinical symptoms. HS is characterized by hemolytic anemia, jaundice, splenomegaly, cholelithiasis, and spherocytes, which are observed on the peripheral blood smear. The typical neonatal erythropoiesis response is slow, often making the reticulocyte count relatively low in comparison with anemia. Nevertheless, these symptoms are not typical in the newborn. More than one-half of neonates with HS are anemia-free in the first week of life. Rare cases exhibit splenomegaly, and spherocytes are observed in the blood smear of neonates [7]. Neonate jaundice is the most common and can be the only manifestation of neonatal HS. Our patient's serum total bilirubin was raised higher than 400 $\mu\text{mol/L}$ within 24 h after birth and was prolonged, suggesting a high risk of kernicterus. Afterwards, his brain MRI results showed symmetrical hyperintensity of globus pallidus on T1-weighted

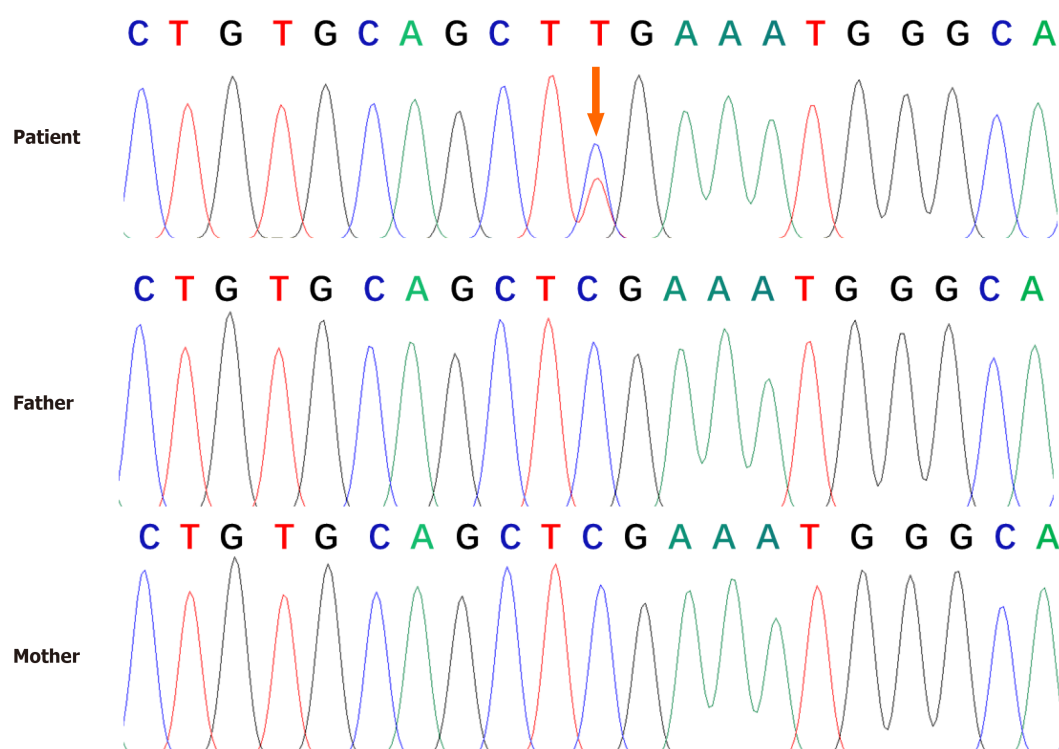


Figure 2 Genomic sequence of the patient. Genetic analysis revealed a heterozygous null mutation in the patient's ankyrin gene [c.841C > T (p. Arg281Ter)]. No genetic mutations were found in his parents. The arrows indicated the mutation site.

sequence. Although the symmetric hyperintensity of globus pallidus on T1-weighted in neonates can be seen in "a transient hyperintensity" or other diseases including cerebral injury, hypoproteinemia, premature delivery, apnea, purulent meningitis, sepsis, *etc.*, the patient did not appear to have any of these illnesses. In our case, he exhibited severe and delayed remission of jaundice and anemia without splenomegaly or spherocytes in the neonatal period. Therefore, we have reason to believe that patients with severe jaundice and anemia in the neonatal period should undergo genetic testing to confirm whether they have HS after excluding the possibility of other hemolytic diseases.

ANK1, located at 8p11.21[12], encodes erythroid ankyrin, and its mutations are the most common causes of HS1. *ANK1* contains 43 exons with a complementary DNA length of 8300 bp. The erythroid ankyrin 1 protein consists of 1880 amino acids with three main structural domains, an N-terminal membrane-binding domain, a central spectrin binding domain, and a C-terminal regulatory domain[13]. All three domains of *ANK1* are key to maintaining the shape of erythrocytes essential for proper function and assembly of the erythrocyte membranous-cytoskeletal network. Mutations in *ANK1* can result in spherocytes with high osmotic fragility observed in most HS patients[14]. *ANK1* mutations, mainly nonsense and frameshift mutations, can significantly affect the function of *ANK1*[15,16]. In this case, a *de novo* mutation at c.841C > T (p. Arg281Ter) in the *ANK1* gene was identified as a nonsense mutation. This mutation led to premature termination of the protein at the spectrin binding domain, thereby forming a truncated protein without normal function, causing an early-onset and severe phenotype.

In the literature, we found a few cases diagnosed with HS1 during the neonatal period and compared their clinical features with our patient (Table 1). Case 2 was a male neonate who developed severe hemolytic anemia 4 wk after his birth and was identified to have a novel *de novo* nonsense E9X: c.25G > T(p.Glu9Ter) mutant in exon 1 of *ANK1*[17]. Case 3 was a 31-wk premature infant who received an RBC transfusion 3 d after birth because of severe anemia and jaundice; this patient was clinically diagnosed with HS1 and carried a *de novo* nonsense mutation (Q109X: c.325C > T(p.Gln109Ter) in exon 4 of *ANK1*[18]. In these cases, the early phenotype can be attributed to the severely impaired protein function by a nonsense mutation. It is worth highlighting a notable difference between our case and the other two cases, both of whom presented with severe anemia as the first manifestation. Our patient presented with intractable pathological neonatal jaundice resistant to phototherapy

Table 1 Clinical features, laboratory investigations, and genetics analysis results of three cases

Patient	Case 1	Case 2	Case 3	Reference
Gender	Male	Male	Male	
Gestational age	39 ⁺⁶ wk	Term infant	31 wk	
Appearance characteristics				
Time to first onset	Within 24 h after birth	4 wk after birth	3 d after birth	
Pallor	-	+	+	
Jaundice	Severe	Moderate	Moderate	
Laboratory examinations				
Hb (g/L)	130	51	80	150-230
MCV (fL)	96.2	75.8	70.8	55.4-60.2
MCHC (g/dL)	36.2	36.0	33.0	31.7-33.0
RET (%)	12.2	13.4	8.2	0.5-1.5
MCHC/MCV (%)	37.6	47.4	46.6	
Erythrocyte osmotic fragility	Negative	Positive	Positive	
Genetics	<i>De novo</i> heterozygous nonsense mutation in exon 9 of <i>ANK1</i> (c.841C > T,p.Arg281Ter)	<i>De novo</i> heterozygous nonsense mutation in exon 1 of <i>ANK1</i> (c.25G > T,p.Glu9Ter)	<i>De novo</i> heterozygous nonsense mutation in exon 4 of <i>ANK1</i> (c.325C > T,p.Gln109Ter)	

Case 1: The patient in our case; Case 2: The patient reported by Gundel *et al*[17]; Case 3: The patient reported by Liu *et al*[18]. Hb: Hemoglobin; MCHC: Mean corpuscular hemoglobin concentration; MCV: Mean corpuscular volume; RET: Reticulocyte.

and exchange transfusion, explaining the different length of retained truncated proteins by other mutations. In short, HS1 caused by nonsense mutations in *ANK1* tends to have an early onset and more severe phenotype. Although there are a few HS1 cases caused by other mutation types of *ANK1* and have a certain degree of clinical phenotype in the neonatal and infancy period, the diagnosis time is often delayed[19,20]. In summary, the physicians should include HS1 in the differential diagnosis in patients who develop severe jaundice or anemia without any known reason in the neonatal period. Moreover, physicians should consider sequencing of relevant genes, especially for *ANK1*, which will provide beneficial help for the timely diagnosis of HS1.

CONCLUSION

In conclusion, we report a Chinese neonate diagnosed as HS1 with severe hyperbilirubinemia caused by the heterozygous null mutation in the *ANK1* gene: c.841C > T(p.Arg281Ter). It is worth noting that early genetic analysis plays an important role in the diagnosis of HS. Prompt treatment and anticipatory guidance are essential to prevent neonates' adverse outcomes with HS, so physicians should be more aware of signs of HS in the newborn period.

ACKNOWLEDGEMENTS

We are thankful for the members of the family for their participation and help in the study.

REFERENCES

- 1 Hao L, Li S, Ma D, Chen S, Zhang B, Xiao D, Zhang J, Jiang N, Jiang S, Ma J. Two novel *ANK1* loss-of-function mutations in Chinese families with hereditary spherocytosis. *J Cell Mol Med* 2019;

- 23: 4454-4463 [PMID: [31016877](#) DOI: [10.1111/jcmm.14343](#)]
- 2 **Da Costa L**, Suner L, Galimand J, Bonnel A, Pascreau T, Couque N, Fenneteau O, Mohandas N; Society of Hematology and Pediatric Immunology (SHIP) group; French Society of Hematology (SFH). Diagnostic tool for red blood cell membrane disorders: Assessment of a new generation ektacytometer. *Blood Cells Mol Dis* 2016; **56**: 9-22 [PMID: [26603718](#) DOI: [10.1016/j.bcmd.2015.09.001](#)]
- 3 **Wang C**, Cui Y, Li Y, Liu X, Han J. A systematic review of hereditary spherocytosis reported in Chinese biomedical journals from 1978 to 2013 and estimation of the prevalence of the disease using a disease model. *Intractable Rare Dis Res* 2015; **4**: 76-81 [PMID: [25984425](#) DOI: [10.5582/irdr.2015.01002](#)]
- 4 **Eber SW**, Gonzalez JM, Lux ML, Scarpa AL, Tse WT, Dornwell M, Herbers J, Kugler W, Ozcan R, Pekrun A, Gallagher PG, Schröter W, Forget BG, Lux SE. Ankyrin-1 mutations are a major cause of dominant and recessive hereditary spherocytosis. *Nat Genet* 1996; **13**: 214-218 [PMID: [8640229](#) DOI: [10.1038/ng0696-214](#)]
- 5 **Delhommeau F**, Cynober T, Schischmanoff PO, Rohrlach P, Delaunay J, Mohandas N, Tchernia G. Natural history of hereditary spherocytosis during the first year of life. *Blood* 2000; **95**: 393-397 [PMID: [10627440](#)]
- 6 **Christensen RD**, Henry E. Hereditary spherocytosis in neonates with hyperbilirubinemia. *Pediatrics* 2010; **125**: 120-125 [PMID: [19948573](#) DOI: [10.1542/peds.2009-0864](#)]
- 7 **Christensen RD**, Yaish HM, Gallagher PG. A pediatrician's practical guide to diagnosing and treating hereditary spherocytosis in neonates. *Pediatrics* 2015; **135**: 1107-1114 [PMID: [26009624](#) DOI: [10.1542/peds.2014-3516](#)]
- 8 **An X**, Mohandas N. Disorders of red cell membrane. *Br J Haematol* 2008; **141**: 367-375 [PMID: [18341630](#) DOI: [10.1111/j.1365-2141.2008.07091.x](#)]
- 9 **Da Costa L**, Galimand J, Fenneteau O, Mohandas N. Hereditary spherocytosis, elliptocytosis, and other red cell membrane disorders. *Blood Rev* 2013; **27**: 167-178 [PMID: [23664421](#) DOI: [10.1016/j.blre.2013.04.003](#)]
- 10 **Miraglia del Giudice E**, Nobili B, Francese M, D'Urso L, Iolascon A, Eber S, Perrotta S. Clinical and molecular evaluation of non-dominant hereditary spherocytosis. *Br J Haematol* 2001; **112**: 42-47 [PMID: [11167781](#) DOI: [10.1046/j.1365-2141.2001.02501.x](#)]
- 11 **Kar R**, Rao S, Srinivas UM, Mishra P, Pati HP. Clinico-hematological profile of hereditary spherocytosis: experience from a tertiary care center in North India. *Hematology* 2009; **14**: 164-167 [PMID: [19490762](#) DOI: [10.1179/102453309X402278](#)]
- 12 **Lambert S**, Yu H, Prechal JT, Lawler J, Ruff P, Speicher D, Cheung MC, Kan YW, Palek J. cDNA sequence for human erythrocyte ankyrin. *Proc Natl Acad Sci U S A* 1990; **87**: 1730-1734 [PMID: [1689849](#) DOI: [10.1073/pnas.87.5.1730](#)]
- 13 **Lux SE**, John KM, Bennett V. Analysis of cDNA for human erythrocyte ankyrin indicates a repeated structure with homology to tissue-differentiation and cell-cycle control proteins. *Nature* 1990; **344**: 36-42 [PMID: [2137557](#) DOI: [10.1038/344036a0](#)]
- 14 **King MJ**, Zanella A. Hereditary red cell membrane disorders and laboratory diagnostic testing. *Int J Lab Hematol* 2013; **35**: 237-243 [PMID: [23480868](#) DOI: [10.1111/ijlh.12070](#)]
- 15 **Gallagher PG**, Forget BG. Hematologically important mutations: spectrin and ankyrin variants in hereditary spherocytosis. *Blood Cells Mol Dis* 1998; **24**: 539-543 [PMID: [9887280](#) DOI: [10.1006/bcmd.1998.0217](#)]
- 16 **Delaunay J**. The molecular basis of hereditary red cell membrane disorders. *Blood Rev* 2007; **21**: 1-20 [PMID: [16730867](#) DOI: [10.1016/j.blre.2006.03.005](#)]
- 17 **Gundel F**, Eber S, Heep A. A new ankyrin mutation (ANK1 EXON E9X) causing severe hereditary spherocytosis in the neonatal period. *Ann Hematol* 2011; **90**: 231-232 [PMID: [20512576](#) DOI: [10.1007/s00277-010-0989-y](#)]
- 18 **Liu S**, Jiang H, Huang LY, Li DZ. A de novo ankyrin mutation (ANK1 Q109X) causing severe hereditary spherocytosis from preterm neonatal period. *Ann Hematol* 2017; **96**: 1067-1068 [PMID: [28280995](#) DOI: [10.1007/s00277-017-2966-1](#)]
- 19 **Huang TL**, Sang BH, Lei QL, Song CY, Lin YB, Lv Y, Yang CH, Li N, Yang YH, Zhang XW, Tian X. A de novo ANK1 mutation associated to hereditary spherocytosis: a case report. *BMC Pediatr* 2019; **19**: 62 [PMID: [30777044](#) DOI: [10.1186/s12887-019-1436-4](#)]
- 20 **Luo Y**, Li Z, Huang L, Tian J, Xiong M, Yang Z. Spectrum of Ankyrin Mutations in Hereditary Spherocytosis: A Case Report and Review of the Literature. *Acta Haematol* 2018; **140**: 77-86 [PMID: [30227413](#) DOI: [10.1159/000492024](#)]



Published by **Baishideng Publishing Group Inc**
7041 Koll Center Parkway, Suite 160, Pleasanton, CA 94566, USA

Telephone: +1-925-3991568

E-mail: bpgoffice@wjgnet.com

Help Desk: <https://www.f6publishing.com/helpdesk>

<https://www.wjgnet.com>

