

World Journal of *Clinical Cases*

World J Clin Cases 2021 July 6; 9(19): 4881-5351



OPINION REVIEW

- 4881** Fear of missing out: A brief overview of origin, theoretical underpinnings and relationship with mental health
Gupta M, Sharma A

REVIEW

- 4890** Molecular pathways in viral hepatitis-associated liver carcinogenesis: An update
Elpek GO
- 4918** Gastroenterology and liver disease during COVID-19 and in anticipation of post-COVID-19 era: Current practice and future directions
Oikonomou KG, Papamichalis P, Zafeiridis T, Xanthoudaki M, Papapostolou E, Valsamaki A, Bouliaris K, Papamichalis M, Karvouniaris M, Vlachostergios PJ, Skoura AL, Komnos A
- 4939** Enhancing oxygenation of patients with coronavirus disease 2019: Effects on immunity and other health-related conditions
Mohamed A, Alawna M

MINIREVIEWS

- 4959** Clinical potentials of ginseng polysaccharide for treating gestational diabetes mellitus
Zhao XY, Zhang F, Pan W, Yang YF, Jiang XY
- 4969** Remarkable gastrointestinal and liver manifestations of COVID-19: A clinical and radiologic overview
Fang LG, Zhou Q
- 4980** Liver injury in COVID-19: Known and unknown
Zhou F, Xia J, Yuan HX, Sun Y, Zhang Y
- 4990** COVID-19 and gastroenteric manifestations
Chen ZR, Liu J, Liao ZG, Zhou J, Peng HW, Gong F, Hu JF, Zhou Y
- 4998** Role of epithelial-mesenchymal transition in chemoresistance in pancreatic ductal adenocarcinoma
Hu X, Chen W
- 5007** Insights into the virologic and immunologic features of SARS-COV-2
Polat C, Ergunay K

ORIGINAL ARTICLE**Basic Study**

- 5019** SMAC exhibits anti-tumor effects in ECA109 cells by regulating expression of inhibitor of apoptosis protein family

Jiang N, Zhang WQ, Dong H, Hao YT, Zhang LM, Shan L, Yang XD, Peng CL

Case Control Study

- 5028** Efficacy of Solitaire AB stent-release angioplasty in acute middle cerebral artery atherosclerosis obliterative cerebral infarction

Wang XF, Wang M, Li G, Xu XY, Shen W, Liu J, Xiao SS, Zhou JH

Retrospective Study

- 5037** Diagnostic value of different color ultrasound diagnostic method in endometrial lesions

Lin XL, Zhang DS, Ju ZY, Li XM, Zhang YZ

- 5046** Clinical and pathological features and risk factors for primary breast cancer patients

Lei YY, Bai S, Chen QQ, Luo XJ, Li DM

- 5054** Outcomes of high-grade aneurysmal subarachnoid hemorrhage patients treated with coiling and ventricular intracranial pressure monitoring

Wen LL, Zhou XM, Lv SY, Shao J, Wang HD, Zhang X

- 5064** Microwave ablation combined with hepatectomy for treatment of neuroendocrine tumor liver metastases

Zhang JZ, Li S, Zhu WH, Zhang DF

- 5073** Clinical application of individualized total arterial coronary artery bypass grafting in coronary artery surgery

Chen WG, Wang BC, Jiang YR, Wang YY, Lou Y

Observational Study

- 5082** Early diagnosis, treatment, and outcomes of five patients with acute thallium poisoning

Wang TT, Wen B, Yu XN, Ji ZG, Sun YY, Li Y, Zhu SL, Cao YL, Wang M, Jian XD, Wang T

- 5092** Sarcopenia in geriatric patients from the plateau region of Qinghai-Tibet: A cross-sectional study

Pan SQ, Li YM, Li XF, Xiong R

- 5102** Medium-term efficacy of arthroscopic debridement *vs* conservative treatment for knee osteoarthritis of Kellgren-Lawrence grades I-III

Lv B, Huang K, Chen J, Wu ZY, Wang H

Prospective Study

- 5112** Impact of continuous positive airway pressure therapy for nonalcoholic fatty liver disease in patients with obstructive sleep apnea

Hirono H, Watanabe K, Hasegawa K, Kohno M, Terai S, Ohkoshi S

Randomized Controlled Trial

- 5126** Erector spinae plane block at lower thoracic level for analgesia in lumbar spine surgery: A randomized controlled trial
Zhang JJ, Zhang TJ, Qu ZY, Qiu Y, Hua Z

SYSTEMATIC REVIEWS

- 5135** Controversies' clarification regarding ribavirin efficacy in measles and coronaviruses: Comprehensive therapeutic approach strictly tailored to COVID-19 disease stages
Liatsos GD
- 5179** Systematic review and meta-analysis of trans-jugular intrahepatic portosystemic shunt for cirrhotic patients with portal vein thrombosis
Zhang JB, Chen J, Zhou J, Wang XM, Chen S, Chu JG, Liu P, Ye ZD

CASE REPORT

- 5191** Myelodysplastic syndrome transformed into B-lineage acute lymphoblastic leukemia: A case report
Zhu YJ, Ma XY, Hao YL, Guan Y
- 5197** Imaging presentation and postoperative recurrence of peliosis hepatis: A case report
Ren SX, Li PP, Shi HP, Chen JH, Deng ZP, Zhang XE
- 5203** Delayed retroperitoneal hemorrhage during extracorporeal membrane oxygenation in COVID-19 patients: A case report and literature review
Zhang JC, Li T
- 5211** Autologous tenon capsule packing to treat posterior exit wound of penetrating injury: A case report
Yi QY, Wang SS, Gui Q, Chen LS, Li WD
- 5217** Treatment of leiomyomatosis peritonealis disseminata with goserelin acetate: A case report and review of the literature
Yang JW, Hua Y, Xu H, He L, Huo HZ, Zhu CF
- 5226** Homozygous deletion, c. 1114-1116del, in exon 8 of the *CRPPA* gene causes congenital muscular dystrophy in Chinese family: A case report
Yang M, Xing RX
- 5232** Successful diagnosis and treatment of jejunal diverticular haemorrhage by full-thickness enterotomy: A case report
Ma HC, Xiao H, Qu H, Wang ZJ
- 5238** Liver metastasis as the initial clinical manifestation of sublingual gland adenoid cystic carcinoma: A case report
Li XH, Zhang YT, Feng H
- 5245** Severe hyperbilirubinemia in a neonate with hereditary spherocytosis due to a *de novo* ankyrin mutation: A case report
Wang JF, Ma L, Gong XH, Cai C, Sun JJ

- 5252** Long-term outcome of indwelling colon observed seven years after radical resection for rectosigmoid cancer: A case report
Zhuang ZX, Wei MT, Yang XY, Zhang Y, Zhuang W, Wang ZQ
- 5259** Diffuse xanthoma in early esophageal cancer: A case report
Yang XY, Fu KI, Chen YP, Chen ZW, Ding J
- 5266** COVID-19 or treatment associated immunosuppression may trigger hepatitis B virus reactivation: A case report
Wu YF, Yu WJ, Jiang YH, Chen Y, Zhang B, Zhen RB, Zhang JT, Wang YP, Li Q, Xu F, Shi YJ, Li XP
- 5270** Maintenance treatment with infliximab for ulcerative ileitis after intestinal transplantation: A case report
Fujimura T, Yamada Y, Umeyama T, Kudo Y, Kanamori H, Mori T, Shimizu T, Kato M, Kawaida M, Hosoe N, Hasegawa Y, Matsubara K, Shimojima N, Shinoda M, Obara H, Naganuma M, Kitagawa Y, Hoshino K, Kuroda T
- 5280** Infliximab treatment of glycogenosis Ib with Crohn's-like enterocolitis: A case report
Gong YZ, Zhong XM, Zou JZ
- 5287** Hemichorea due to ipsilateral thalamic infarction: A case report
Li ZS, Fang JJ, Xiang XH, Zhao GH
- 5294** Intestinal gangrene secondary to congenital transmesenteric hernia in a child misdiagnosed with gastrointestinal bleeding: A case report
Zheng XX, Wang KP, Xiang CM, Jin C, Zhu PF, Jiang T, Li SH, Lin YZ
- 5302** Collagen VI-related myopathy with scoliosis alone: A case report and literature review
Li JY, Liu SZ, Zheng DF, Zhang YS, Yu M
- 5313** Neuromuscular electrical stimulation for a dysphagic stroke patient with cardiac pacemaker using magnet mode change: A case report
Kim M, Park JK, Lee JY, Kim MJ
- 5319** Four-year-old anti-N-methyl-D-aspartate receptor encephalitis patient with ovarian teratoma: A case report
Xue CY, Dong H, Yang HX, Jiang YW, Yin L
- 5325** Glutamic acid decarboxylase 65-positive autoimmune encephalitis presenting with gelastic seizure, responsive to steroid: A case report
Yang CY, Tsai ST
- 5332** Ectopic opening of the common bile duct into the duodenal bulb with recurrent choledocholithiasis: A case report
Xu H, Li X, Zhu KX, Zhou WC
- 5339** Small bowel obstruction caused by secondary jejunal tumor from renal cell carcinoma: A case report
Bai GC, Mi Y, Song Y, Hao JR, He ZS, Jin J
- 5345** Brugada syndrome associated with out-of-hospital cardiac arrest: A case report
Ni GH, Jiang H, Men L, Wei YY, A D, Ma X

ABOUT COVER

Editorial Board Member of *World Journal of Clinical Cases*, Fan-Bo Meng, MD, PhD, Chief Doctor, Deputy Director, Professor, Department of Cardiology, China-Japan Union Hospital of Jilin University, Changchun 130000, Jilin Province, China. mengfb@jlu.edu.cn

AIMS AND SCOPE

The primary aim of *World Journal of Clinical Cases* (WJCC, *World J Clin Cases*) is to provide scholars and readers from various fields of clinical medicine with a platform to publish high-quality clinical research articles and communicate their research findings online.

WJCC mainly publishes articles reporting research results and findings obtained in the field of clinical medicine and covering a wide range of topics, including case control studies, retrospective cohort studies, retrospective studies, clinical trials studies, observational studies, prospective studies, randomized controlled trials, randomized clinical trials, systematic reviews, meta-analysis, and case reports.

INDEXING/ABSTRACTING

The WJCC is now indexed in Science Citation Index Expanded (also known as SciSearch®), Journal Citation Reports/Science Edition, Scopus, PubMed, and PubMed Central. The 2020 Edition of Journal Citation Reports® cites the 2019 impact factor (IF) for WJCC as 1.013; IF without journal self cites: 0.991; Ranking: 120 among 165 journals in medicine, general and internal; and Quartile category: Q3. The WJCC's CiteScore for 2019 is 0.3 and Scopus CiteScore rank 2019: General Medicine is 394/529.

RESPONSIBLE EDITORS FOR THIS ISSUE

Production Editor: Yan-Xia Xing, Production Department Director: Yun-Xiaoqian Wu, Editorial Office Director: Jin-Li Wang.

NAME OF JOURNAL

World Journal of Clinical Cases

ISSN

ISSN 2307-8960 (online)

LAUNCH DATE

April 16, 2013

FREQUENCY

Thrice Monthly

EDITORS-IN-CHIEF

Dennis A Bloomfield, Sandro Vento, Bao-Gan Peng

EDITORIAL BOARD MEMBERS

<https://www.wjgnet.com/2307-8960/editorialboard.htm>

PUBLICATION DATE

July 6, 2021

COPYRIGHT

© 2021 Baishideng Publishing Group Inc

INSTRUCTIONS TO AUTHORS

<https://www.wjgnet.com/bpg/gerinfo/204>

GUIDELINES FOR ETHICS DOCUMENTS

<https://www.wjgnet.com/bpg/GerInfo/287>

GUIDELINES FOR NON-NATIVE SPEAKERS OF ENGLISH

<https://www.wjgnet.com/bpg/gerinfo/240>

PUBLICATION ETHICS

<https://www.wjgnet.com/bpg/GerInfo/288>

PUBLICATION MISCONDUCT

<https://www.wjgnet.com/bpg/gerinfo/208>

ARTICLE PROCESSING CHARGE

<https://www.wjgnet.com/bpg/gerinfo/242>

STEPS FOR SUBMITTING MANUSCRIPTS

<https://www.wjgnet.com/bpg/GerInfo/239>

ONLINE SUBMISSION

<https://www.f6publishing.com>



Maintenance treatment with infliximab for ulcerative ileitis after intestinal transplantation: A case report

Takumi Fujimura, Yohei Yamada, Tomoshige Umeyama, Yumi Kudo, Hiroki Kanamori, Teizaburo Mori, Takahiro Shimizu, Mototoshi Kato, Miho Kawaida, Naoki Hosoe, Yasushi Hasegawa, Kentaro Matsubara, Naoki Shimojima, Masahiro Shinoda, Hideaki Obara, Makoto Naganuma, Yuko Kitagawa, Ken Hoshino, Tatsuo Kuroda

ORCID number: Takumi Fujimura 0000-0002-7078-6542; Yohei Yamada 0000-0001-6059-7660; Tomoshige Umeyama 0000-0001-8263-2068; Yumi Kudo 0000-0002-8706-4028; Hiroki Kanamori 0000-0002-3029-843X; Teizaburo Mori 0000-0002-0056-7344; Takahiro Shimizu 0000-0002-7648-8773; Mototoshi Kato 0000-0002-5076-8558; Miho Kawaida 0000-0003-0353-4246; Naoki Hosoe 0000-0002-4516-5648; Yasushi Hasegawa 0000-0002-4990-0419; Kentaro Matsubara 0000-0002-6438-6040; Naoki Shimojima 0000-0001-5949-260X; Masahiro Shinoda 0000-0002-4315-9244; Hideaki Obara 0000-0001-6740-2715; Makoto Naganuma 0000-0002-4244-3243; Yuko Kitagawa 0000-0001-6469-2155; Ken Hoshino 0000-0002-3021-3029; Tatsuo Kuroda 0000-0001-7183-2830.

Author contributions: Fujimura T wrote and coordinated this manuscript; Yamada Y, Kuroda T, Kitagawa Y, Hoshino K, Hasegawa Y, Matsubara K, Shimojima N, Shinoda M, Obara H, and Naganuma M helped draft the manuscript; Umeyama T, Kudo Y, Kanamori H, Mori T, Shimizu T, Kato M, and Hosoe N helped treatment of the patient and corrected data; Kawaida M performed the pathological analysis; all authors read and

Takumi Fujimura, Department of Pediatric Surgery, National Saitama Hospital, Wako Shi, Saitama 351-0102, Japan

Takumi Fujimura, Yohei Yamada, Tomoshige Umeyama, Yumi Kudo, Hiroki Kanamori, Teizaburo Mori, Takahiro Shimizu, Mototoshi Kato, Naoki Shimojima, Ken Hoshino, Tatsuo Kuroda, Department of Pediatric Surgery, Keio University School of Medicine, Tokyo 160-8582, Japan

Miho Kawaida, Department of Pathology, Keio University School of Medicine, Tokyo 160-8582, Japan

Naoki Hosoe, Center for Diagnostic and Therapeutic Endoscopy, Keio University School of Medicine, Tokyo 160-8582, Japan

Yasushi Hasegawa, Kentaro Matsubara, Masahiro Shinoda, Hideaki Obara, Yuko Kitagawa, Department of Surgery, Keio University School of Medicine, Tokyo 160-8582, Japan

Masahiro Shinoda, Digestive Diseases Center, International University of Health and Welfare, Mita Hospital, Tokyo 108-8329, Japan

Makoto Naganuma, Department of Gastroenterology and Hepatology, Keio University School of Medicine, Tokyo 160-8582, Japan

Corresponding author: Yohei Yamada, FACS, MD, PhD, Assistant Lecturer, Department of Pediatric Surgery, Keio University School of Medicine, 35 Shinanomachi, Shinjuku-ku, Tokyo 160-8582, Japan. yohei.z7@keio.jp

Abstract

BACKGROUND

Evidence has been published on the successful applications of the anti-tumor necrosis factor alpha antibody infliximab, such as induction therapy, salvage treatment for acute cellular rejection, and treatment for chronic ulcerative inflammation, in intestinal transplant recipients. However, the optimal protocol for the effective use of infliximab remains largely undetermined due to scarcity of available clinical data. We report a continuative application of infliximab as maintenance therapy for recurrent chronic ulcerative ileitis in a recipient of isolated intestinal transplantation (ITx).

approved the final manuscript.

Supported by JSPS KAKENHI, No. JP18K16286, and No. JP18K08600.

Informed consent statement:

Consent was obtained from the patient for the publication of this report and any accompanying images.

Conflict-of-interest statement: The authors declare that they have no conflicts of interest.

CARE Checklist (2016) statement:

The authors have read the CARE Checklist (2016), and the manuscript was prepared and revised according to the CARE Checklist (2016).

Open-Access: This article is an open-access article that was selected by an in-house editor and fully peer-reviewed by external reviewers. It is distributed in accordance with the Creative Commons Attribution NonCommercial (CC BY-NC 4.0) license, which permits others to distribute, remix, adapt, build upon this work non-commercially, and license their derivative works on different terms, provided the original work is properly cited and the use is non-commercial. See: <http://creativecommons.org/licenses/by-nc/4.0/>

Manuscript source: Unsolicited manuscript

Specialty type: Medicine, research and experimental

Country/Territory of origin: Japan

Peer-review report's scientific quality classification

Grade A (Excellent): 0
Grade B (Very good): 0
Grade C (Good): C
Grade D (Fair): 0
Grade E (Poor): 0

Received: February 3, 2021

Peer-review started: February 3, 2021

First decision: March 6, 2021

Revised: March 18, 2021

Accepted: May 17, 2021

Article in press: May 17, 2021

CASE SUMMARY

The patient was a 11-year-old boy with intestinal motility disorder classified as a hypogenic type of intestinal dysganglionosis. The patient underwent living-donor related intestinal transplant. His immunosuppression regimen consisted of daclizumab, tacrolimus, and steroids. Although he did not show rejection while on tacrolimus monotherapy, routine screening endoscopy showed several ulcerative lesions in the distal end of the graft 2 years after the intestinal transplant. Endoscopic work up to evaluate the progression of anemia revealed stenosis with ulcerative inflammatory changes and multiple longitudinal ulcers in the graft. Since the endoscopic findings suggested ulcerative lesions in Crohn's disease, infliximab treatment was considered. Treatment with infliximab and a small dose of oral prednisolone afforded successful withdrawal of total parenteral nutrition and maintenance of a well-functioning graft without infectious complications for 5 years since the administration of the first dose of infliximab.

CONCLUSION

Infliximab is effective as maintenance therapy for recurrent chronic ulcerative ileitis in an isolated ITx patient.

Key Words: Intestinal transplantation; Chronic ulcer; Infliximab; Crohn's disease; Tumor necrosis factor alpha; Case report

©The Author(s) 2021. Published by Baishideng Publishing Group Inc. All rights reserved.

Core Tip: Infliximab binds to soluble and transmembrane forms of human tumor necrosis factor alpha (TNF- α). Ulcerative inflammatory changes in the graft under intestinal transplantation (ITx) is an often-encountered finding. However, it does not meet the criteria for so-called rejection and is close to the pathology of Crohn's disease. Studies in Crohn's disease patients revealed that anti-TNF- α therapy provides better outcomes when combined with immunomodulatory agents and that therapeutic drug monitoring might help optimize dosing. Infliximab may be effective as a treatment for ulcerative inflammation in the intestinal graft that does not meet the criteria for acute cellular rejection not improved by immunosuppressant conditioning. The optimal management for recurrent ulcerative inflammation under ITx settings by using anti-TNF- α therapy needs further elucidation.

Citation: Fujimura T, Yamada Y, Umeyama T, Kudo Y, Kanamori H, Mori T, Shimizu T, Kato M, Kawaida M, Hosoe N, Hasegawa Y, Matsubara K, Shimojima N, Shinoda M, Obara H, Naganuma M, Kitagawa Y, Hoshino K, Kuroda T. Maintenance treatment with infliximab for ulcerative ileitis after intestinal transplantation: A case report. *World J Clin Cases* 2021; 9(19): 5270-5279

URL: <https://www.wjgnet.com/2307-8960/full/v9/i19/5270.htm>

DOI: <https://dx.doi.org/10.12998/wjcc.v9.i19.5270>

INTRODUCTION

Tumor necrosis factor alpha (TNF- α) is one of the central cytokines in the pathogenesis of mucosal inflammation in inflammatory bowel disease (IBD) and has been the primary target of biologic therapies. Although TNF is mainly produced by monocytes, macrophages, and T lymphocytes, it is also produced by mast cells, granulocytes, fibroblasts, and several other cell types[1]. TNF is a highly pro-inflammatory cytokine that is involved in key processes in inflammation, including the activation of coagulation and fibrinolytic responses, promotion of the development of the neutrophil-endothelial adhesion necessary for recruitment to inflammation sites[2-4], and promotion of granulomatous inflammation through its role in the recruitment of T lymphocytes, monocytes, and macrophages[5-7].

Infliximab is a chimeric immunoglobulin G1 monoclonal antibody that binds to soluble and transmembrane forms of human TNF- α . It was approved by the United

Published online: July 6, 2021**P-Reviewer:** Quaglio AEV**S-Editor:** Fan JR**L-Editor:** A**P-Editor:** Yuan YY

States Food and Drug Administration in 1998 for Crohn's disease and in 1999 for rheumatoid arthritis. Later, the approval was broadened for the treatment of various autoimmune diseases including diseases in pediatric patients. The advent of anti-TNF- α antibodies has resulted in a paradigm shift in the treatment of IBD. Anti-TNF- α antibodies are thought to have multiple mechanisms of action, including neutralization of TNF- α , reverse signaling, apoptosis, and cytotoxicity[8], and have a predilection and efficiency for distribution into inflamed tissue[9]. Anti-TNF- α antibodies also induce the apoptosis of activated lamina propria T lymphocytes[10], which is contradictory to a proposed pathological mechanism in Crohn's disease, where mucosal T cell proliferation exceeds T cell apoptosis[11]. In addition, anti-TNF- α therapies are capable of inducing antibody-dependent cell-mediated cytotoxicity and complement-dependent cytotoxicity[9].

Advances in treatment for IBD provide an insight into the potential mechanism to control immune responses in intestinal transplantation (ITx). The first case report about the use of infliximab in the ITx setting dates back to 2003[12]. The report describes two adult patients who were successfully treated for cellular rejection refractory to anti-CD3 monoclonal antibody (OKT3) treatment. Since then, 22 published cases related to "intestinal transplant and infliximab" have been found in PubMed. Studies in rodents suggested promising complementary effects of infliximab addition to conventional immunosuppressive regimens not only in terms of alleviation of ischemic reperfusion injury but also attenuation of acute cellular rejection (ACR)[13, 14]. However, despite some promising clinical evidence available from both animal and human studies, little is known about the optimal protocol and safety of infliximab use in the ITx setting. Herein, we report the detailed clinical course with serial serum TNF- α levels of an intestinal transplant recipient for a prolonged period and discuss future prospects of infliximab treatment based on a literature review.

CASE PRESENTATION

Chief complaints

Routine screening endoscopy showed several ulcerative lesions in the distal end of the graft 2 years after ITx. The patient developed anorexia, showed weight loss, and experienced intermittent abdominal pain.

History of present illness

A patient was an 11-year-old boy with intestinal motility disorder classified as a hypogenic type of intestinal dysganglionosis. The patient underwent living-donor related ITx from his father because of a lack of vascular access and growth retardation due to malnutrition. The graft was 110 cm of donor ileum from a point 20 cm proximal to the Bauhin valve. His initial immunosuppression regimen consisted of daclizumab as induction therapy, tacrolimus, and steroids. Daclizumab was continued until 12 wk after ITx as the maintenance treatment. Tacrolimus was started on the day of surgery after reperfusion. It was initially administered in a continuous intravenous manner, before switching to oral administration 2 wk after the transplant. The target trough level was between 20 and 25 ng/mL for the first month, 15-20 ng/mL for the next 2 mo, 10-15 ng/mL for the next 3 mo, and 10 ng/mL thereafter. Despite two episodes of steroid-responsive mild ACR and cytomegalovirus (CMV) infection within the first year after ITx, he was free of rejection on tacrolimus monotherapy.

History of past illness

Hypogenic type of intestinal dysganglionosis.

Personal and family history

There was no relevant family history.

Physical examination

Routine screening endoscopy showed several ulcerative lesions in the distal end of the graft 2 years after ITx. Partial resection of the small intestine including the ulcerative lesions was performed when he underwent revision of the stoma (Bishop-Koop procedure) in preparation for a complete reversal of ileostomy at the age of 13 years. Histological analysis of the ulcerative lesion revealed non-specific inflammatory changes. However, the patient developed anorexia, showed weight loss, and experienced intermittent abdominal pain several months after the previous operation.

These symptoms persisted on and off over several months.

Laboratory examinations

Regular blood tests revealed hypoalbuminemia, a low total cholesterol level, and anemia; the other findings were unremarkable, including C-reactive protein level, erythrocyte sedimentation rate, and white blood cell count.

Imaging examinations

The endoscopic work up to evaluate the progression of anemia revealed stenosis with ulcerative inflammatory changes in the proximal part of the anastomosis and multiple longitudinal ulcers in the graft near the distal anastomosis site (Figure 1A and B). Computed tomography showed thickened intestinal walls with inflamed fat tissue.

Pathological examinations

Mucosal biopsy showed non-specific inflammation of the mucosa, which did not fulfill the criteria of ACR or chronic rejection (CR). C4d staining was negative; the anti-donor human leukocyte antigen antibody was absent in the patient's serum. Polymerase chain reaction performed using the mucosal specimen was negative for CMV and Epstein-Barr virus (EBV).

FINAL DIAGNOSIS

The final diagnosis was suggested to be ulcerative lesions in Crohn's disease.

TREATMENT

Several attempts to dilate the stenotic lesions with a balloon only provided transient relief. Anorexia, pain, and anemia were progressive. Since the endoscopic findings suggested ulcerative lesions in Crohn's disease, infliximab treatment was considered. Before the initiation of infliximab treatment, screening tests for malignancy and latent infections, including tuberculosis and infections with EBV, CMV, and hepatitis B virus, were performed, all of which were negative.

The initial, second, third, and subsequent doses of infliximab were administered on day 0, day 14, day 42, and every 8 wk thereafter, respectively.

OUTCOME AND FOLLOW-UP

The patient's oral intake was restored immediately after the first infusion of infliximab, and abdominal pain alleviated. Endoscopy, which was performed after the administration of the second dose of infliximab, showed mucosal healing of the ulcerative lesions (Figure 1C-E). However, the effect was only transient, the symptoms relapsed, and ulcerative inflammation recurred within several weeks. Furthermore, the effect of infliximab was attenuated; thus, repetitive infusion of infliximab was required in shorter intervals. The dosage was also increased to 7.5 mg/kg, and mycophenolate mofetil (MMF, 20 mg/kg) was added to prevent the production of neutralizing antibodies against infliximab. Later, MMF was switched with 5 mg of prednisolone, which helped reduce the dosage and frequency. Treatment with 5 mg/kg infliximab every 8 wk and 5 mg of oral prednisolone allowed the maintenance of remission for the following 2 years. Since the ulcerative lesion persisted despite symptom relief, another partial resection of the intestinal part with longitudinal ulcerative lesions was performed at the same time as ileostomy reversal 11 years after ITx (when the patient was 22 years old). The serum level of TNF- α and changes in body weight are shown in Figure 2. The trough serum TNF- α levels ranged from 14.8 to 246 pg/mL, which rapidly declined to 0.55-4.17 pg/mL (immediately after each infusion). The resected specimen of the graft revealed no clinical features of ACR or CR (such as submucosal vasculopathy, intimal thickening, or fibrosis) (Figure 3). Endoscopy performed for surveillance 3 mo after the resection showed the recurrence of several ulcerative lesions in the graft, which prompted the resumption of treatment with infliximab (5 mg/kg) followed by symptom-based administration. Currently, the patient is successfully off parenteral nutrition. Infliximab is being administered as needed (average 8-10 wk), and the patient's condition has been stable without any obvious

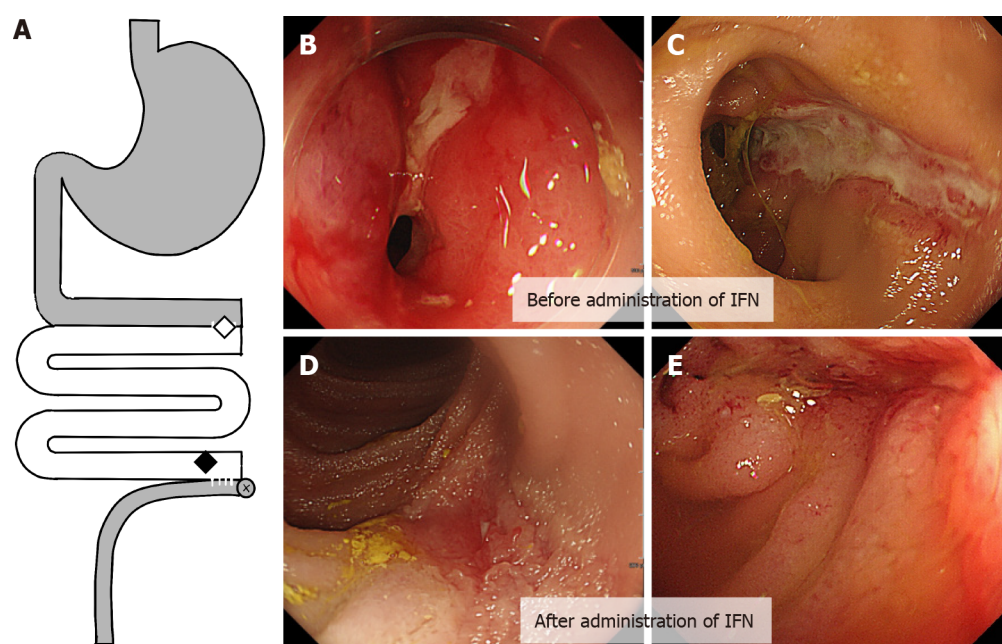


Figure 1 Ulcerative lesion in graft before and after administration infliximab. A: The location of the diseases in the graft; B and C: Stenosis with inflammation in the proximal anastomosis between the graft and the original intestine (B, indicated by a white diamond in A), and a longitudinal ulcerative lesion in the distal end of the graft (C, indicated by a black diamond in A); D and E: Mucosal healing was observed in the distal ulcerative lesion after the administration of two doses of infliximab. IFN: Infliximab.

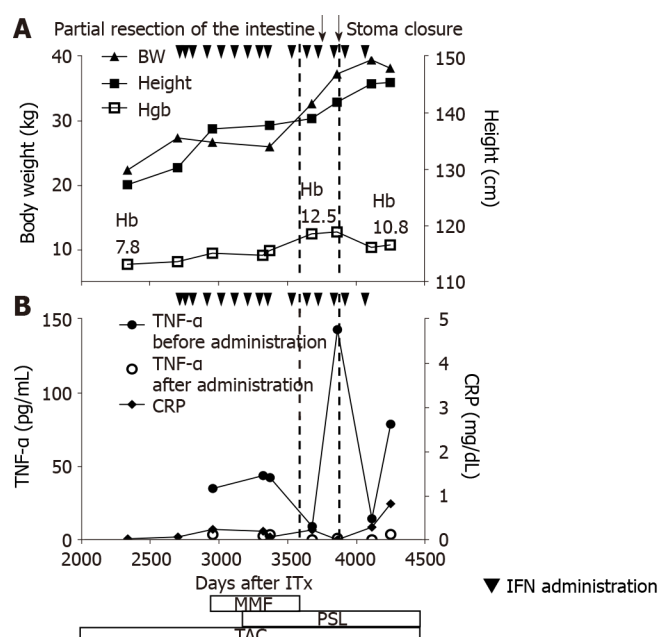


Figure 2 Clinical course during infliximab administration. A: Height and body weight indicating a steady growth, in line with the initiation of infliximab (5 mg/kg). Hemoglobin (g/dL) level rapidly recovered. Following attenuation in the clinical response, the dose was increased to 7.5 mg/kg and immunomodulatory agents were added (mycophenolate mofetil was later switched with oral prednisolone); B: Dots (●) indicate the trough serum tissue necrosis factor alpha level, which declined immediately after each infliximab infusion (indicated by squares). In contrast, almost normal white blood cell counts and C-reactive protein level were observed throughout the course of treatment. Partial resection and stoma reversal were performed (indicated by dotted lines). IFN: Infliximab; MMF: Mycophenolate mofetil; PSL: Prednisolone; TAC: Tacrolimus; Hb: Hemoglobin.

adverse events for 5 years since the first administration infliximab. The test for neutralizing antibodies against infliximab has been negative to date.

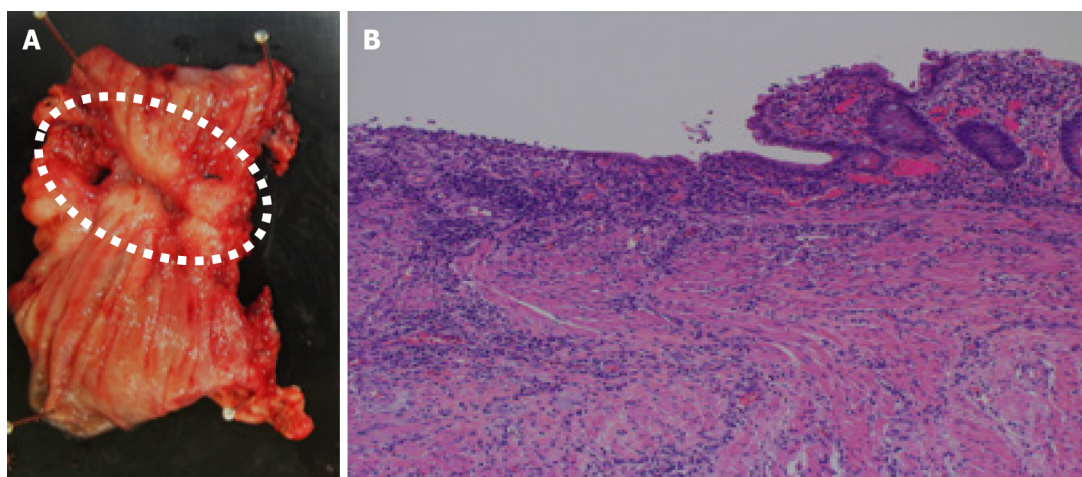


Figure 3 Pathological findings of the ulcerative lesion. A: The resected specimen of the graft showing ulcerative inflammation with fibrotic tissue; B: No signs of chronic rejection are observed.

DISCUSSION

The four major indications of infliximab for ITx can be considered as follows: (1) Induction therapy; (2) Salvage treatment for rejection refractory to treatment with lymphocyte-depleting antibodies [anti-thymocyte globulin (ATG) or OKT3]; (3) Preemptive treatment for steroid-refractory rejection to avoid the use of treatment with lymphocyte-depleting antibodies; and (4) Treatment for ulcerative inflammation not meeting the criteria for rejection. Regarding indication I, some treatment centers use infliximab as part of induction therapy based on results of animal studies[13-15]. However, thus far, clear benefits in human studies remain to be elucidated[16]. The data of 22 ITx patients treated with infliximab due to indications 2, 3, and 4 are summarized in Table 1[17-23]. Ten patients received infliximab after being treated with lymphocyte-depleting antibodies (indication 2), six received infliximab before treatment with lymphocyte-depleting antibodies or did not receive lymphocyte-depleting antibodies (indication 3), and two received infliximab for chronic ulcerative conditions, which did not meet the criteria for ACR (indication 4). No clinical details were available for four patients[24].

Eight out of the 10 patients (dosage: 3 mg/kg to 5 mg/kg) treated for indication 2 achieved complete remission, one was in transient remission and being treated, and one lost the graft. The patient who lost the graft had developed severe exfoliative ACR accompanied by humoral rejection 15 d after transplantation. The graft did not recover even after the administration of seven doses of infliximab along with plasma pheresis and intravenous immunoglobulin (high dose). Although based on only a single case, it can be speculated that infliximab may have a limited effect on humoral rejection. Among the 10 rejection episodes, two occurred early after ITx (1 d and 15 d) and the other eight episodes occurred 6 mo to 5 years after ITx.

Among six patients who received infliximab for indication III, graft recovery was achieved in three patients (dosage: 5 mg/kg) without the need for treatment with lymphocyte-depleting antibodies. Two patients needed ATG/OKT-3 treatment and achieved remission, and one lost the graft without receiving ATG because of underlying CMV disease. Whether earlier treatment with infliximab might have prevented the need for treatment with lymphocyte-depleting antibodies remains unclear, because, unfortunately, data on the interval between the onset of ACR and infliximab administration were unavailable. For now, early application of infliximab in cases of steroid-resistant ACR with an aim to avoid treatment with lymphocyte-depleting antibodies remains controversial and should be prudent because a delay in treatment with ATG might have detrimental effects.

Only three patients, including our current patient, received infliximab for indication 4, known as ulcerative ileitis/anastomositis, which is clearly distinct from ACR. Results of histological analyses were consistent in three individuals, and were characterized as an ulcer with granulation tissue and fibrinoid necrosis on the surface. The events occurred 17, 24, and 72 mo after ITx. Of note, although one patient achieved complete remission after two infusions of infliximab, the other two patients continue to be treated for recurrent ulcerative lesions at the time of submission. One patient received regular treatment every 6 mo[19], and our patient receives the treatment

Table 1 Summary of the literature related to treatment with infliximab for ulcerative lesion after intestinal transplantation

Ref.	Number of patients	Age of the patients at the time of events (yr)	Disease	Baseline immunosuppressive therapy at the time of the event	Indications	Serum TNF- α (pg/mL)	Dose	Number of infusions	Interval after ITx	Outcome	Adverse events and F/u
Fishbein <i>et al</i> [17], 2006	4	N/A	N/A	N/A	Late-onset resistant rejection (no details available)	N/A	N/A	N/A	N/A	Full recovery	N/A
Giovanelli <i>et al</i> [18], 2008	1	11 (m)	Chronic intestinal pseudo-obstruction	Tacrolimus, sirolimus	Steroid-resistant ACR	N/A	N/A	1	18 mo	No response, remission after OKT3 treatment	EBV viremia, graft loss due to chronic rejection in 5 mo
Gerlach <i>et al</i> [19], 2011	9	27-44 (7: m 2: f)	Short bowel syndrome, chronic intestinal pseudo-obstruction	Steroid, tacrolimus, ATG, daclizumab, alemtuzumab, sirolimus, MMF	Late-onset OKT3-resistant ACR (2), early-onset OKT3-resistant ACR, humoral rejection (1), early-onset OKT3-resistant ACR (1), steroid-resistant ACR (3), chronic ulcerative ileitis/anastomosis (2)	Late-onset OKT3-resistant ACR (60-170), steroid-resistant ACR (80-140), chronic ulcerative ileitis (60-114), early-onset OKT3-resistant rejection (100-167)	5 mg/kg	12 \pm 11.3	0-40 mo (18.2 + 14.1 mo)	6/9 sustained remission, 2/9 repeated transient remission, 1/9 graft loss	EBV infection (3), cutaneous mycosis, pneumonia, 6 mo to 10 yr
De Greef <i>et al</i> [20], 2012	2	13 (m), 5 (f)	Microvillous inclusion disease, short bowel syndrome	Tacrolimus monotherapy, rapamycin + daclizumab + steroid	Steroid- and ATG-resistant ACR	N/A	5 mg/kg, 4 mg/kg + 3 mg/kg 2-wk interval	1, 3	5 yr and 6 mo	Complete remission	27/22 mo
Avsar <i>et al</i> [21], 2014	1	52 (f)	Short bowel syndrome	Steroid, tacrolimus, everolimus, daclizumab, MMF	Graft rejection after CMV infection	N/A	5 mg/kg	1	6 mo	No response, graft explantation (no ATG)	Graft loss
Rao <i>et al</i> [22], 2016	1	38 (f)	Crohn's disease	Steroid, tacrolimus	Late-onset steroid- and ATG-resistant ACR	N/A	Adalimumab	< 2	10 mo	Remission with maintenance adalimumab treatment	6 mo
Narang <i>et al</i> [23], 2019	1	20 (f)	Total intestinal aganglionosis + solitary kidney	Steroid, tacrolimus	Late-onset steroid-resistant ACR (moderate to severe), ulcerative ileitis	N/A	5 mg/kg, 10 mg/kg	More than 3	13 yr	No response with 5 mg/kg, remission after ATG, 10 mg/kg induced remission for another ACR episode later	PTLD (remission), 2 yr
Current case, 2020	1	20 (m)	Isolated hypoganglionosis	Tacrolimus	Chronic ulcerative ileitis, anastomosis	14.8-246 pg/mL	5-7.5 mg/kg	> 17	6 yr	Repeated transient remission	5 yr

TNF- α : Tissue necrosis factor alpha; ITx: Intestinal transplantation; ACR: Acute cellular rejection; OKT3: Anti-CD3 monoclonal antibody; EBV: Epstein-Barr virus; ATG: Anti-thymocyte globulin; MMF: Mycophenolate mofetil; CMV: Cytomegalovirus; PTLT: Posttransplant lymphoproliferative disorder; N/A: Not available.

every 8-10 wk as of now. The macroscopic findings and the clinical response induced by infliximab led us to speculate about the potential commonality of immune responses in the transplanted intestine and consider IBD. The first description of such similarity was reported by Fishbein *et al*[25]. They reported that 10% of 30 ITx recipients showed gross features of graft ulceration and a reduction in the number of Paneth cells on histological examination, and required on average 6 wk of infliximab treatment until remission; the success rate was 75%. A subsequent study reported the potential underlying mechanism of NOD2 polymorphism in such inflammatory lesions[25].

The optimal management for recurrent ulcerative inflammation under ITx settings by using anti-TNF- α therapy needs further elucidation. Previous studies in patients with Crohn's disease revealed that anti-TNF- α therapy provides better outcomes when used in combination with immunomodulatory agents and that therapeutic drug monitoring might help optimization of dosing[26]. Our patient received MMF (500 mg) for 6 mo without additional improvement. MMF has since been switched with 5 mg of prednisolone. The dose was once escalated to 7.5 mg/kg based on clinical symptoms. Five years have passed since the patient was first administered infliximab, and treatment has been effective thus far. Options for future treatment include dose escalation or short-interval based on therapeutic drug monitoring, combination treatment with other immunomodulatory agents (such as azathioprine), and switching to other anti-TNF antibodies (such as adalimumab)[23]. With regard to the safety of infliximab addition in highly immunocompromised recipients, EBV viremia and cutaneous mycosis have been reported as adverse events. Studies on the addition of anti-TNF- α treatment for immunosuppression maintenance among other solid-organ transplant recipients, the indications for which mostly included coexistent IBD and rheumatoid arthritis, showed essentially no additional risk of infectious complications and malignancy in liver transplant[27,28] and kidney transplant patients[29]. Nevertheless, as stated in the guideline for Crohn's disease management, a thorough assessment for opportunistic infections and malignancy is necessary among ITx recipients before the initiation of anti-TNF- α therapy.

CONCLUSION

Treatment with infliximab and immunomodulatory agents in addition to conventional immunosuppressive therapy is safe and effective for chronic ulcerative conditions after ITx. Anti-TNF- α therapy should be considered as a powerful option in immunosuppressive treatment strategy against various conditions associated with immunologically challenging ITx.

REFERENCES

- Tracey D, Klareskog L, Sasso EH, Salfeld JG, Tak PP. Tumor necrosis factor antagonist mechanisms of action: a comprehensive review. *Pharmacol Ther* 2008; **117**: 244-279 [PMID: 18155297 DOI: 10.1016/j.pharmthera.2007.10.001]
- Kuijpers TW, Hakker BC, Hart MH, Roos D. Neutrophil migration across monolayers of cytokine-prestimulated endothelial cells: a role for platelet-activating factor and IL-8. *J Cell Biol* 1992; **117**: 565-572 [PMID: 1315317 DOI: 10.1083/jcb.117.3.565]
- Paleolog EM, Delasalle SA, Buurman WA, Feldmann M. Functional activities of receptors for tumor necrosis factor- α on human vascular endothelial cells. *Blood* 1994; **84**: 2578-2590 [PMID: 7919375 DOI: 10.1182/blood.V84.8.2578.bloodjournal8482578]
- Carlos TM, Harlan JM. Leukocyte-endothelial adhesion molecules. *Blood* 1994; **84**: 2068-2101 [PMID: 7522621 DOI: 10.1182/blood.V84.7.2068.bloodjournal8472068]
- Van Deventer SJ. Tumour necrosis factor and Crohn's disease. *Gut* 1997; **40**: 443-448 [PMID: 9176068 DOI: 10.1136/gut.40.4.443]
- Kindler V, Sappino AP, Grau GE, Piguet PF, Vassalli P. The inducing role of tumor necrosis factor in the development of bactericidal granulomas during BCG infection. *Cell* 1989; **56**: 731-740 [PMID: 2647299 DOI: 10.1016/0092-8674(89)90676-4]
- Myatt N, Coghill G, Morrison K, Jones D, Cree IA. Detection of tumour necrosis factor alpha in sarcoidosis and tuberculosis granulomas using in situ hybridisation. *J Clin Pathol* 1994; **47**: 423-426 [PMID: 8027394 DOI: 10.1136/jcp.47.5.423]
- Berns M, Hommes DW. Anti-TNF- α therapies for the treatment of Crohn's disease: the past, present and future. *Expert Opin Investig Drugs* 2016; **25**: 129-143 [PMID: 26616476 DOI: 10.1517/13543784.2016.1126247]
- Mitoma H, Horiuchi T, Tsukamoto H, Ueda N. Molecular mechanisms of action of anti-TNF- α

- agents - Comparison among therapeutic TNF- α antagonists. *Cytokine* 2018; **101**: 56-63 [PMID: 27567553 DOI: 10.1016/j.cyto.2016.08.014]
- 10 **ten Hove T**, van Montfrans C, Peppelenbosch MP, van Deventer SJ. Infliximab treatment induces apoptosis of lamina propria T lymphocytes in Crohn's disease. *Gut* 2002; **50**: 206-211 [PMID: 11788561 DOI: 10.1136/gut.50.2.206]
- 11 **Van den Brande JM**, Koehler TC, Zelinkova Z, Bennink RJ, te Velde AA, ten Cate FJ, van Deventer SJ, Peppelenbosch MP, Hommes DW. Prediction of antitumour necrosis factor clinical efficacy by real-time visualisation of apoptosis in patients with Crohn's disease. *Gut* 2007; **56**: 509-517 [PMID: 17082252 DOI: 10.1136/gut.2006.105379]
- 12 **Pascher A**, Radke C, Dignass A, Schulz RJ, Veltzke-Schlieker W, Adler A, Sauer IM, Platz K, Klupp J, Volk HD, Neuhaus P, Mueller AR. Successful infliximab treatment of steroid and OKT3 refractory acute cellular rejection in two patients after intestinal transplantation. *Transplantation* 2003; **76**: 615-618 [PMID: 12923454 DOI: 10.1097/01.TP.0000072804.41125.82]
- 13 **Pech T**, Fujishiro J, Finger T, Ohsawa I, Praktijnjo M, Abu-Elmagd K, von Websky M, Overhaus M, Kalff JC, Schaefer N. Combination therapy of tacrolimus and infliximab reduces inflammatory response and dysmotility in experimental small bowel transplantation in rats. *Transplantation* 2012; **93**: 249-256 [PMID: 22167049 DOI: 10.1097/TP.0b013e31823e7abb]
- 14 **Gerlach UA**, Atanasov G, Wallenta L, Polenz D, Reutzel-Selke A, Kloepfel M, Jurisch A, Marksteiner M, Loddenkemper C, Neuhaus P, Sawitzki B, Pascher A. Short-term TNF-alpha inhibition reduces short-term and long-term inflammatory changes post-ischemia/reperfusion in rat intestinal transplantation. *Transplantation* 2014; **97**: 732-739 [PMID: 24598936 DOI: 10.1097/TP.0000000000000032]
- 15 **Pech T**, Fujishiro J, Finger T, Ohsawa I, Praktijnjo M, von Websky M, Wehner S, Abu-Elmagd K, Kalff JC, Schaefer N. Perioperative infliximab application has marginal effects on ischemia-reperfusion injury in experimental small bowel transplantation in rats. *Langenbecks Arch Surg* 2012; **397**: 131-140 [PMID: 21960137 DOI: 10.1007/s00423-011-0853-0]
- 16 **Gerlach UA**, Lachmann N, Sawitzki B, Arsenic R, Neuhaus P, Schoenemann C, Pascher A. Clinical relevance of the de novo production of anti-HLA antibodies following intestinal and multivisceral transplantation. *Transpl Int* 2014; **27**: 280-289 [PMID: 24279605 DOI: 10.1111/tri.12250]
- 17 **Fishbein T**, Novitsky G. Innate immunity is altered after intestinal transplantation causing a new inflammatory bowel disease. *Transplantation* 2006; **82**: 372 [DOI: 10.1097/00007890-200607152-00907]
- 18 **Giovanelli M**, Gupte GL, Sharif K, Mayer DA, Mirza DF. Chronic rejection after combined liver and small bowel transplantation in a child with chronic intestinal pseudo-obstruction: a case report. *Transplant Proc* 2008; **40**: 1763-1767 [PMID: 18589190 DOI: 10.1016/j.transproceed.2008.01.066]
- 19 **Gerlach UA**, Koch M, Müller HP, Veltzke-Schlieker W, Neuhaus P, Pascher A. Tumor necrosis factor alpha inhibitors as immunomodulatory antirejection agents after intestinal transplantation. *Am J Transplant* 2011; **11**: 1041-1050 [PMID: 21521472 DOI: 10.1111/j.1600-6143.2011.03497.x]
- 20 **De Greef E**, Avitzur Y, Grant D, De-Angelis M, Ng V, Jones N, Ngan B, Shapiro R, Steinberg R, Gana JC. Infliximab as salvage therapy in paediatric intestinal transplant with steroid- and thymoglobulin-resistant late acute rejection. *J Pediatr Gastroenterol Nutr* 2012; **54**: 565-567 [PMID: 21694633 DOI: 10.1097/MPG.0b013e3182293d73]
- 21 **Avsar Y**, Cicinnati VR, Kabar I, Wolters H, Anthoni C, Schmidt HH, Beckebaum S. Small bowel transplantation complicated by cytomegalovirus tissue invasive disease without viremia. *J Clin Virol* 2014; **60**: 177-180 [PMID: 24703746 DOI: 10.1016/j.jcv.2014.03.005]
- 22 **Rao B**, Jafri SM, Kazimi M, Mullins K, Raoufi M, Segovia MC. A Case Report of Acute Cellular Rejection Following Intestinal Transplantation Managed With Adalimumab. *Transplant Proc* 2016; **48**: 536-538 [PMID: 27109995 DOI: 10.1016/j.transproceed.2015.11.033]
- 23 **Narang A**, Xi D, Mitsinikos T, Genyk Y, Thomas D, Kohli R, Lin CH, Soufi N, Warren M, Merritt R, Yanni G. Severe Late-Onset Acute Cellular Rejection in a Pediatric Patient With Isolated Small Intestinal Transplant Rescued With Aggressive Immunosuppressive Approach: A Case Report. *Transplant Proc* 2019; **51**: 3181-3185 [PMID: 31711586 DOI: 10.1016/j.transproceed.2019.08.012]
- 24 **Matsumoto CS**, Zasloff MA, Fishbein TM. Chronic mucosal inflammation/inflammatory bowel disease-like inflammation after intestinal transplantation: where are we now? *Curr Opin Organ Transplant* 2014; **19**: 276-280 [PMID: 24752065 DOI: 10.1097/MOT.0000000000000077]
- 25 **Fishbein T**, Novitskiy G, Mishra L, Matsumoto C, Kaufman S, Goyal S, Shetty K, Johnson L, Lu A, Wang A, Hu F, Kallakury B, Lough D, Zasloff M. NOD2-expressing bone marrow-derived cells appear to regulate epithelial innate immunity of the transplanted human small intestine. *Gut* 2008; **57**: 323-330 [PMID: 17965060 DOI: 10.1136/gut.2007.133322]
- 26 **Lichtenstein GR**, Loftus EV, Isaacs KL, Regueiro MD, Gerson LB, Sands BE. ACG Clinical Guideline: Management of Crohn's Disease in Adults. *Am J Gastroenterol* 2018; **113**: 481-517 [PMID: 29610508 DOI: 10.1038/ajg.2018.27]
- 27 **Altwegg R**, Combes R, Laharie D, De Ledinghen V, Radenne S, Conti F, Chazouilleres O, Duvoux C, Dumortier J, Leroy V, Treton X, Durand F, Dharancy S, Nachury M, Goutorbe F, Lamblin G, Boivineau L, Peyrin-Biroulet L, Pageaux GP. Effectiveness and safety of anti-TNF therapy for inflammatory bowel disease in liver transplant recipients for primary sclerosing cholangitis: A nationwide case series. *Dig Liver Dis* 2018; **50**: 668-674 [PMID: 29655972 DOI: 10.1016/j.dld.2018.02.014]
- 28 **Westerouen van Meeteren MJ**, Hayee B, Inderson A, van der Meulen AE, Altwegg R, van Hoek B,

- Pageaux GP, Stijnen T, Stein D, Maljaars PWJ. Safety of Anti-TNF Treatment in Liver Transplant Recipients: A Systematic Review and Meta-analysis. *J Crohns Colitis* 2017; **11**: 1146-1151 [PMID: 28482085 DOI: 10.1093/ecco-jcc/jjx057]
- 29 **Quinn CS**, Jorgenson MR, Descourouez JL, Muth BL, Astor BC, Mandelbrot DA. Management of Tumor Necrosis Factor α Inhibitor Therapy After Renal Transplantation: A Comparative Analysis and Associated Outcomes. *Ann Pharmacother* 2019; **53**: 268-275 [PMID: 30234366 DOI: 10.1177/1060028018802814]



Published by **Baishideng Publishing Group Inc**
7041 Koll Center Parkway, Suite 160, Pleasanton, CA 94566, USA

Telephone: +1-925-3991568

E-mail: bpgoffice@wjgnet.com

Help Desk: <https://www.f6publishing.com/helpdesk>

<https://www.wjgnet.com>

