

World Journal of *Clinical Cases*

World J Clin Cases 2021 January 16; 9(2): 291-520



Contents

Thrice Monthly Volume 9 Number 2 January 16, 2021

OPINION REVIEW

- 291 Continuity of cancer care in the era of COVID-19 pandemic: Role of social media in low- and middle-income countries
Yadav SK, Yadav N

REVIEW

- 296 Effect of a fever in viral infections — the ‘Goldilocks’ phenomenon?
Belon L, Skidmore P, Mehra R, Walter E
- 308 Overview of bile acid signaling in the cardiovascular system
Zhang R, Ma WQ, Fu MJ, Li J, Hu CH, Chen Y, Zhou MM, Gao ZJ, He YL

MINIREVIEWS

- 321 Gut microbiota and inflammatory bowel disease: The current status and perspectives
Zheng L, Wen XL

ORIGINAL ARTICLE

Retrospective Cohort Study

- 334 Effective immune-inflammation index for ulcerative colitis and activity assessments
Zhang MH, Wang H, Wang HG, Wen X, Yang XZ

Retrospective Study

- 344 Risk factors associated with acute respiratory distress syndrome in COVID-19 patients outside Wuhan: A double-center retrospective cohort study of 197 cases in Hunan, China
Hu XS, Hu CH, Zhong P, Wen YJ, Chen XY

META-ANALYSIS

- 357 Limb length discrepancy after total knee arthroplasty: A systematic review and meta-analysis
Tripathy SK, Pradhan SS, Varghese P, Purudappa PP, Velagada S, Goyal T, Panda BB, Vanyambadi J

CASE REPORT

- 372 Lateral position intubation followed by endoscopic ultrasound-guided angiotherapy in acute esophageal variceal rupture: A case report
Wen TT, Liu ZL, Zeng M, Zhang Y, Cheng BL, Fang XM
- 379 Perioperative mortality of metastatic spinal disease with unknown primary: A case report and review of literature
Li XM, Jin LB

- 389** Massive gastric bleeding - perforation of pancreatic pseudocyst into the stomach: A case report and review of literature
Jin Z, Xiang YW, Liao QS, Yang XX, Wu HC, Tuo BG, Xie R
- 396** Natural history of inferior mesenteric arteriovenous malformation that led to ischemic colitis: A case report
Kimura Y, Hara T, Nagao R, Nakanishi T, Kawaguchi J, Tagami A, Ikeda T, Araki H, Tsurumi H
- 403** Coil embolization of arterioportal fistula complicated by gastrointestinal bleeding after Caesarian section: A case report
Stepanyan SA, Poghosyan T, Manukyan K, Hakobyan G, Hovhannisyan H, Safaryan H, Baghdasaryan E, Gemilyan M
- 410** Cholecystoduodenal fistula presenting with upper gastrointestinal bleeding: A case report
Park JM, Kang CD, Kim JH, Lee SH, Nam SJ, Park SC, Lee SJ, Lee S
- 416** Rare case of fecal impaction caused by a fecalith originating in a large colonic diverticulum: A case report
Tanabe H, Tanaka K, Goto M, Sato T, Sato K, Fujiya M, Okumura T
- 422** Intravitreal dexamethasone implant — a new treatment for idiopathic posterior scleritis: A case report
Zhao YJ, Zou YL, Lu Y, Tu MJ, You ZP
- 429** Inflammatory myofibroblastic tumor successfully treated with metformin: A case report and review of literature
Liang Y, Gao HX, Tian RC, Wang J, Shan YH, Zhang L, Xie CJ, Li JJ, Xu M, Gu S
- 436** Neonatal isovaleric acidemia in China: A case report and review of literature
Wu F, Fan SJ, Zhou XH
- 445** Malignant solitary fibrous tumor of the greater omentum: A case report and review of literature
Guo YC, Yao LY, Tian ZS, Shi B, Liu Y, Wang YY
- 457** Paratesticular liposarcoma: Two case reports
Zheng QG, Sun ZH, Chen JJ, Li JC, Huang XJ
- 463** Sinistral portal hypertension associated with pancreatic pseudocysts - ultrasonography findings: A case report
Chen BB, Mu PY, Lu JT, Wang G, Zhang R, Huang DD, Shen DH, Jiang TT
- 469** Epstein-Barr virus-associated monomorphic post-transplant lymphoproliferative disorder after pediatric kidney transplantation: A case report
Wang Z, Xu Y, Zhao J, Fu YX
- 476** Postoperative complications of concomitant fat embolism syndrome, pulmonary embolism and tympanic membrane perforation after tibiofibular fracture: A case report
Shao J, Kong DC, Zheng XH, Chen TN, Yang TY
- 482** Double-hit lymphoma (rearrangements of MYC, BCL-2) during pregnancy: A case report
Xie F, Zhang LH, Yue YQ, Gu LL, Wu F

- 489** Is sinusoidal obstructive syndrome a recurrent disease after liver transplantation? A case report
Liu Y, Sun LY, Zhu ZJ, Wei L, Qu W, Zeng ZG
- 496** Portal hypertension exacerbates intrahepatic portosystemic venous shunt and further induces refractory hepatic encephalopathy: A case report
Chang YH, Zhou XL, Jing D, Ni Z, Tang SH
- 502** Repair of a severe palm injury with anterolateral thigh and ilioinguinal flaps: A case report
Gong HY, Sun XG, Lu LJ, Liu PC, Yu X
- 509** Indirect inguinal hernia containing portosystemic shunt vessel: A case report
Yura M, Yo K, Hara A, Hayashi K, Tajima Y, Kaneko Y, Fujisaki H, Hirata A, Takano K, Hongo K, Yoneyama K, Nakagawa M
- 516** Recurrent inverted papilloma coexisted with skull base lymphoma: A case report
Hsu HJ, Huang CC, Chuang MT, Tien CH, Lee JS, Lee PH

ABOUT COVER

Editorial Board Member of *World Journal of Clinical Cases*, Dr. Mukul Vij is Senior Consultant Pathologist and Lab Director at Dr Rela Institute and Medical Center in Chennai, India (since 2018). Having received his MBBS degree from King George Medical College in 2004, Dr. Vij undertook postgraduate training at Sanjay Gandhi Postgraduate Institute of Medical Sciences, receiving his Master's degree in Pathology in 2008 and his PDCC certificate in Renal Pathology in 2009. After 2 years as senior resident, he became Assistant Professor in the Department of Pathology at Christian Medical College, Vellore (2011), moving on to Global Health City as Consultant Pathologist and then Head of the Pathology Department (2013). (L-Editor: Filipodia)

AIMS AND SCOPE

The primary aim of *World Journal of Clinical Cases* (*WJCC*, *World J Clin Cases*) is to provide scholars and readers from various fields of clinical medicine with a platform to publish high-quality clinical research articles and communicate their research findings online.

WJCC mainly publishes articles reporting research results and findings obtained in the field of clinical medicine and covering a wide range of topics, including case control studies, retrospective cohort studies, retrospective studies, clinical trials studies, observational studies, prospective studies, randomized controlled trials, randomized clinical trials, systematic reviews, meta-analysis, and case reports.

INDEXING/ABSTRACTING

The *WJCC* is now indexed in Science Citation Index Expanded (also known as SciSearch®), Journal Citation Reports/Science Edition, PubMed, and PubMed Central. The 2020 Edition of Journal Citation Reports® cites the 2019 impact factor (IF) for *WJCC* as 1.013; IF without journal self cites: 0.991; Ranking: 120 among 165 journals in medicine, general and internal; and Quartile category: Q3.

RESPONSIBLE EDITORS FOR THIS ISSUE

Production Editor: Jia-Hui Li; Production Department Director: Yu-Jie Ma; Editorial Office Director: Jin-Lai Wang.

NAME OF JOURNAL

World Journal of Clinical Cases

ISSN

ISSN 2307-8960 (online)

LAUNCH DATE

April 16, 2013

FREQUENCY

Thrice Monthly

EDITORS-IN-CHIEF

Dennis A Bloomfield, Sandro Vento, Bao-gan Peng

EDITORIAL BOARD MEMBERS

<https://www.wjnet.com/2307-8960/editorialboard.htm>

PUBLICATION DATE

January 16, 2021

COPYRIGHT

© 2021 Baishideng Publishing Group Inc

INSTRUCTIONS TO AUTHORS

<https://www.wjnet.com/bpg/gerinfo/204>

GUIDELINES FOR ETHICS DOCUMENTS

<https://www.wjnet.com/bpg/GerInfo/287>

GUIDELINES FOR NON-NATIVE SPEAKERS OF ENGLISH

<https://www.wjnet.com/bpg/gerinfo/240>

PUBLICATION ETHICS

<https://www.wjnet.com/bpg/GerInfo/288>

PUBLICATION MISCONDUCT

<https://www.wjnet.com/bpg/gerinfo/208>

ARTICLE PROCESSING CHARGE

<https://www.wjnet.com/bpg/gerinfo/242>

STEPS FOR SUBMITTING MANUSCRIPTS

<https://www.wjnet.com/bpg/GerInfo/239>

ONLINE SUBMISSION

<https://www.f6publishing.com>

Natural history of inferior mesenteric arteriovenous malformation that led to ischemic colitis: A case report

Yushi Kimura, Takeshi Hara, Ryotaro Nagao, Takayuki Nakanishi, Junji Kawaguchi, Atsushi Tagami, Tsuneko Ikeda, Hiroshi Araki, Hisashi Tsurumi

ORCID number: Yushi Kimura 0000-0001-5128-3635; Takeshi Hara 0000-0003-1762-9254; Ryotaro Nagao 0000-0002-7998-0050; Takayuki Nakanishi 0000-0002-5560-6267; Junji Kawaguchi 0000-0001-5244-1375; Atsushi Tagami 0000-0002-5007-795X; Tsuneko Ikeda 0000-0002-8259-3158; Hiroshi Araki 0000-0003-3445-5727; Hisashi Tsurumi 0000-0002-9262-5790.

Author contributions: Kimura Y contributed to the diagnosis of the patient, writing of the manuscript, and discussion; Hara T and Tsurumi H contributed to the revised manuscript; Nagao R, Nakanishi T, Kawaguchi J, Tagami A and Araki H contributed to the diagnosis of the patient; Ikeda T contributed to the analysis of the pathology.

Informed consent statement:

Informed consent was obtained from the reported patient.

Conflict-of-interest statement:

The authors declare that they have no conflict of interest.

CARE Checklist (2016) statement:

The authors have read the CARE Checklist (2016), and the manuscript was prepared and revised according to the CARE Checklist (2016).

Yushi Kimura, Ryotaro Nagao, Takayuki Nakanishi, Junji Kawaguchi, Atsushi Tagami, Hiroshi Araki, Department of Gastroenterology, Matsunami General Hospital, Hashima-gun 501-6062, Japan

Takeshi Hara, Hisashi Tsurumi, Department of Hematology, Matsunami General Hospital, Hashima-gun 501-6062, Japan

Tsuneko Ikeda, Department of Pathology, Matsunami General Hospital, Hashima-gun 501-6062, Japan

Corresponding author: Yushi Kimura, MD, Doctor, Department of Gastroenterology, Matsunami General Hospital, 185-1 Dendai, Kasamatsu-cho, Hashima-gun 501-6062, Japan. yushi.kigaruni@mgghg.jp

Abstract

BACKGROUND

Ischemic colitis with inferior mesenteric arteriovenous malformation (AVM) is a rare disease. Although a few reports have been published, no report has described the natural history of idiopathic mesenteric AVM.

CASE SUMMARY

A 50-year-old male was admitted to our hospital due to abdominal pain that had persisted for 3 mo and bloody diarrhea. He had no history of trauma or abdominal surgery. He had undergone two colonoscopies 6 mo and 2 years ago, and they showed only a polyp. He was diagnosed with ischemic colitis with inferior mesenteric AVM following contrast-enhanced abdominal computed tomography (CT) and underwent rectal low anterior resection. He has not had a recurrence of symptoms for 3 years. His history showed that he had undergone non-enhanced abdominal CT 2, 5, and 8 years ago when he had attacks of urinary stones. Retrospectively, dilation of blood vessels around the rectosigmoid colon could have been detected 5 years ago, and these findings gradually became more evident.

CONCLUSION

This is the first report of the natural history of inferior mesenteric AVM.

Key Words: Inferior mesenteric arteriovenous malformation; Ischemic colitis; Natural

Open-Access: This article is an open-access article that was selected by an in-house editor and fully peer-reviewed by external reviewers. It is distributed in accordance with the Creative Commons Attribution NonCommercial (CC BY-NC 4.0) license, which permits others to distribute, remix, adapt, build upon this work non-commercially, and license their derivative works on different terms, provided the original work is properly cited and the use is non-commercial. See: <http://creativecommons.org/licenses/by-nc/4.0/>

Manuscript source: Unsolicited manuscript

Specialty type: Medicine, research and experimental

Country/Territory of origin: Japan

Peer-review report's scientific quality classification

Grade A (Excellent): 0
Grade B (Very good): B
Grade C (Good): 0
Grade D (Fair): 0
Grade E (Poor): 0

Received: July 16, 2020

Peer-review started: July 16, 2020

First decision: November 3, 2020

Revised: November 11, 2020

Accepted: November 21, 2020

Article in press: November 21, 2020

Published online: January 16, 2021

P-Reviewer: Luo HS

S-Editor: Gao CC

L-Editor: A

P-Editor: Liu JH



history; Case report; Arteriovenous malformation

©The Author(s) 2021. Published by Baishideng Publishing Group Inc. All rights reserved.

Core Tip: Ischemic colitis around the rectum is very rare, and thus, we need to diagnose this condition carefully and consider the possibility of inferior mesenteric arteriovenous malformation (AVM). Although a few reports have been published, inferior mesenteric AVM is a rare disease. This is the first report described the natural history of inferior mesenteric AVM.

Citation: Kimura Y, Hara T, Nagao R, Nakanishi T, Kawaguchi J, Tagami A, Ikeda T, Araki H, Tsurumi H. Natural history of inferior mesenteric arteriovenous malformation that led to ischemic colitis: A case report. *World J Clin Cases* 2021; 9(2): 396-402

URL: <https://www.wjgnet.com/2307-8960/full/v9/i2/396.htm>

DOI: <https://dx.doi.org/10.12998/wjcc.v9.i2.396>

INTRODUCTION

Rectum blood flow is supplied from several arteries, including the superior rectal artery (branch of the inferior mesenteric artery), middle rectal artery (branch of the internal iliac artery), and inferior rectal artery (branch of the internal pudendal artery); hence, ischemia of the rectum is very rare^[1]. Arteriovenous malformation (AVM) causes gastrointestinal bleeding^[2] and may also cause ischemic colitis. A few reports of ischemic colitis caused by inferior mesenteric AVM have been published^[4-14]. However, no report has described the natural history of idiopathic AVM. Here we describe a case of ischemic colitis caused by idiopathic inferior mesenteric AVM. We were able to retrospectively observe the dilation of blood vessels around the rectosigmoid colon.

CASE PRESENTATION

Chief complaints

A 50-year-old male presented with intermittent abdominal pain and bloody diarrhea.

History of present illness

He had tenesmus 3 mo before his first admission. One month before presentation, he had bloody diarrhea and lower abdominal pain, which was alleviated by defecation. Five days before admission, these symptoms became worse, and he visited our hospital.

History of past illness

The patient had hypertension, lipidosis, sleep apnea syndrome, and urinary stones. He had no history of trauma or abdominal surgery. He had undergone a colonoscopy 2 years ago because of fecal occult blood, and a colon polyp was detected. No abnormalities were detected in a second colonoscopy performed 6 mo ago. Because of attacks of urinary stones, he had previously undergone non-enhanced abdominal computed tomography (CT).

Personal and family history

His father had cholangiocarcinoma, and his mother had hypertension.

Physical examination

He was afebrile with normal vital signs. Physical examination showed abdominal tenderness in the lower abdominal quadrants without signs of peritoneal irritation. No mass was detected in the abdomen.

Laboratory examinations

His laboratory data were unremarkable except for mild anemia (hemoglobin level, 12.9 g/dL).

Imaging examinations

Non-enhanced abdominal CT showed hypodense thickening of the sigmoid and rectal wall. Colonoscopy revealed diffuse ulcerations, edema, and erythema from the descending colon to the rectum. These mucosal findings were most evident in the upper rectum (Figure 1). Biopsy specimens from the colon showed atrophy of crypts and infiltration of inflammatory cells, which were consistent with ischemic colitis.

Further diagnostic work-up

Stool samples were negative for infectious causes. Cytomegalovirus antigenemia and *Entamoeba histolytica* immunoglobulin M (IgM) antibody were also negative.

First diagnosis and follow-up

After the diagnosis of ischemic colitis, he was treated with fasting and fluid replacement. However, his tenesmus continued, and his abdominal pain and bloody diarrhea improved. He was discharged from the hospital 12 d after admission.

Three weeks after discharge from the hospital, he presented to our clinic with similar abdominal pain. He underwent contrast-enhanced abdominal CT, which showed a nidus of small corkscrew vessels arising from the superior rectal artery (branch of the inferior mesenteric artery) and marked early inferior mesenteric vein enhancement (Figures 2 and 3).

FINAL DIAGNOSIS

Based on contrast-enhanced abdominal CT, inferior mesenteric AVM was diagnosed.

TREATMENT

We performed another colonoscopy, and most findings of colitis showed improvement, but not complete recovery. His abdominal pain was still present, and thus, another treatment was needed.

Rectal low anterior resection was performed 4 mo later. The range of AVM was wide, and thus, embolization could have caused more severe ischemia. The resected specimen showed dilated blood vessels from the superior rectal artery, and the sigmoid colon to the upper rectum wall were thickened and edematous.

Histopathological findings showed dilation of arteries and veins that were close and mixed; these findings were consistent with AVM (Figure 4).

OUTCOME AND FOLLOW-UP

The postoperative period was uneventful, and he has not had a recurrence of bloody diarrhea or abdominal pain for 3 years.

His previous abdominal CTs from 2, 5, and 8 years ago when he had attacks of urinary stones revealed that vessels around the rectosigmoid colon were not evident 8 years ago. However, dilation of blood vessels around the rectosigmoid colon could have been detected 5 years previously (Figure 5).

DISCUSSION

AVMs and arteriovenous fistulas (AVFs) are often grouped together because the clinical courses of these disease entities are similar. AVFs are usually acquired, typically from previous trauma or iatrogenic events with surgery. On the other hand, AVMs are generally congenital or idiopathic. Congenital AVMs are caused by disruptions in vascular morphogenesis that result in persistent embryonic vessels that fail to regress and lead to a direct communication between the arterial and venous systems^[3-6].

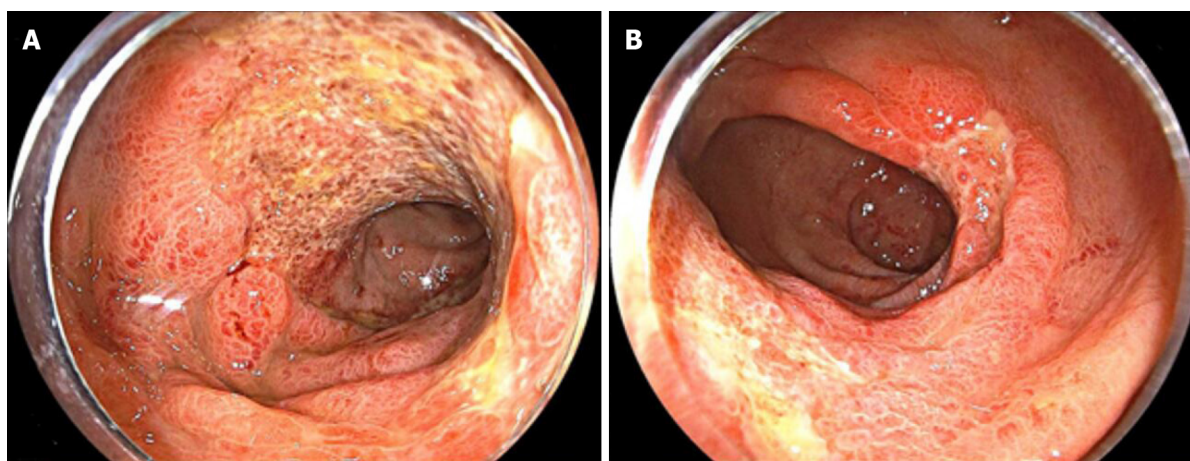


Figure 1 Colonoscopy findings at his first admission. Colonoscopy showed diffuse ulceration, edema, and erythema from the descending colon to the rectum. These mucosal findings were most evident in the rectum above the peritoneal reflection. A: Colon; B: Rectum.

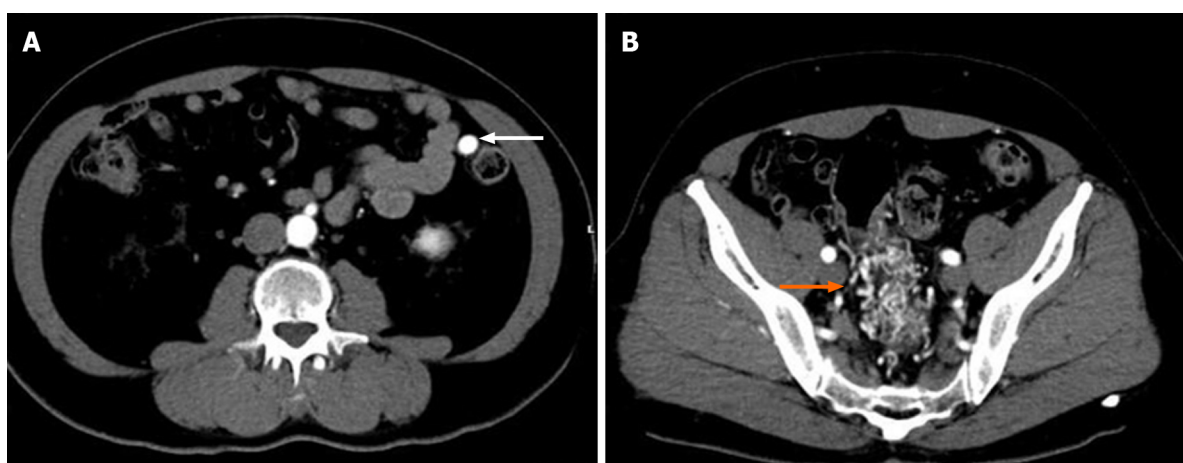


Figure 2 Images from contrast-enhanced abdominal computed tomography. A contrast-enhanced abdominal computed tomography scan showed the nidus of small corkscrew and dilated vessels (orange arrow) and marked early inferior mesenteric vein enhancement (white arrow).

About 200 cases of splanchnic AVFs have been described, mainly between the hepatic, splenic, and superior mesenteric vessels^[10]. Poullos *et al*^[1] reported only 24 cases in the literature of AVMs involving the inferior mesenteric vessels.

We identified 11 cases of ischemic colitis caused by inferior mesenteric AVMs reported in English^[4-14]. All 11 cases were idiopathic AVMs without trauma or abdominal surgery, similar to our case. No report mentioned the natural history of AVMs. Only one case report mentioned that 4 years before ischemic colitis occurred, abdominal CT showed a normal inferior mesenteric artery^[6]. Fortunately, we were able to examine the natural history of idiopathic AVM in our case. Comparing our patient's previous abdominal CT, dilation of blood vessels around the rectosigmoid colon could have been detected 5 years ago. We could not determine if these vessels were arteries or veins, but they seem to have gradually grown (Figure 5). Our patient also underwent two colonoscopies 6 mo and 2 years before his first admission, and they showed only a colon polyp. During this time period, he did not have any abdominal symptoms. These results suggest that some idiopathic AVMs are not congenital, and grow slowly over years. Similar to our case, the median age of patients with idiopathic AVMs was 57 years (range: 36-83 years)^[4-14]. Thus, some acquired factor may have played an important role in the growth of vessels.

Regarding brain AVM, Kim *et al*^[15] described the idiopathic pathogenesis of brain AVM and indicated that even modest injury such as an unremarkable episode of trauma, infection, inflammation, irradiation, or a mechanical stimulus could cause an abnormal dysplastic response and result in brain AVM. The normal response to these injuries includes moderate angiogenesis, endothelial mitogenesis, and vascular stabilization. However, if an underlying structural defect is present, the normal

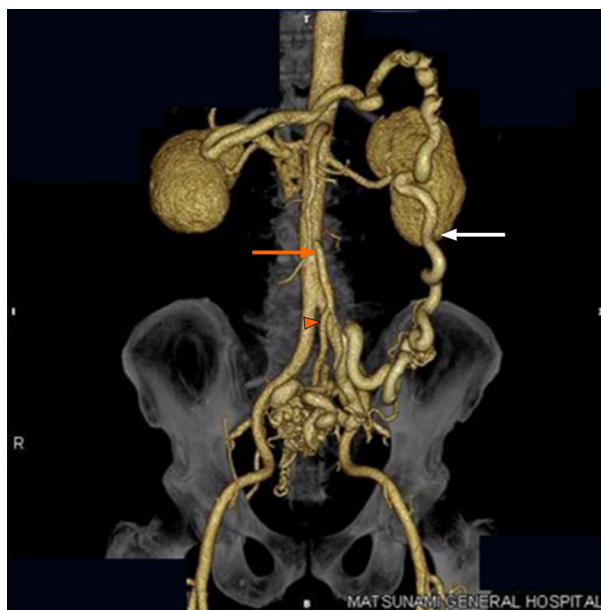


Figure 3 Image from computed tomography angiography. Computed tomography angiography showed the same findings as contrast-enhanced abdominal computed tomography. The image showed the nidus of small corkscrew and dilated vessels arising from the superior rectal artery (orange arrowhead), which is a branch of the inferior mesenteric artery (orange arrow). Dilated inferior mesenteric veins were observed (white arrow).

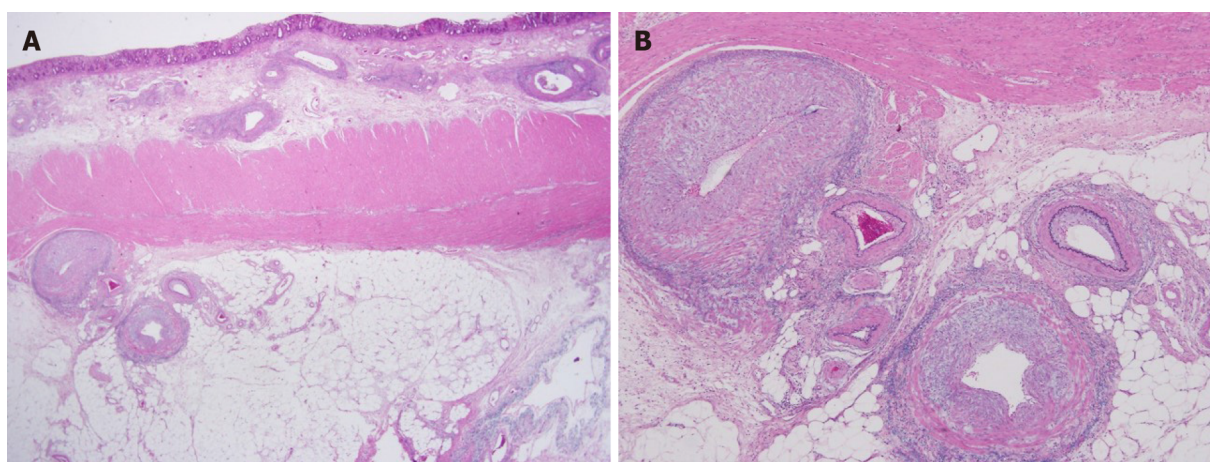


Figure 4 Histopathological findings of the surgical specimen. Histopathological findings showed dilation of arteries and veins, which were close and mixed, consistent with an arteriovenous malformation. A: Victoria blue-hematoxylin-eosin $\times 12.5$; B: Victoria blue-hematoxylin-eosin $\times 40$.

response may shift towards an abnormal dysplastic response and result in brain AVM^[15]. In our current case, he had no history of trauma or abdominal surgery, but he may have had an unremarkable episode of modest injury that could have caused his AVM. Additional factors and/or mechanisms of idiopathic inferior mesenteric AVM are still unclear, and further accumulation of cases is desired.

Diagnosing ischemic colitis caused by AVM is generally difficult. Some cases have been misdiagnosed as ulcerative colitis^[7,8] or diverticulitis^[5,9]. In our case, colonoscopy and non-enhanced abdominal CT did not lead to a correct diagnosis at his first admission. He was diagnosed with AVM following contrast-enhanced abdominal CT 3 wk after discharge from the hospital. Ischemic colitis around the rectum is very rare because the rectum is supplied by several arteries. When we detect ischemic colitis around the rectum, we have to consider this diagnosis carefully, and contrast-enhanced CT should be considered to find an AVM.

Most reported AVM cases are diagnosed by mesenteric angiography, and only two cases were diagnosed only with contrast-enhanced CT^[6,10]. Contrast-enhanced CT and CT angiography are also useful for diagnosis of an inferior mesenteric AVM, and they are non-invasive compared to mesenteric angiography.

Concerning treatment for AVM, we selected surgery and not embolization. We

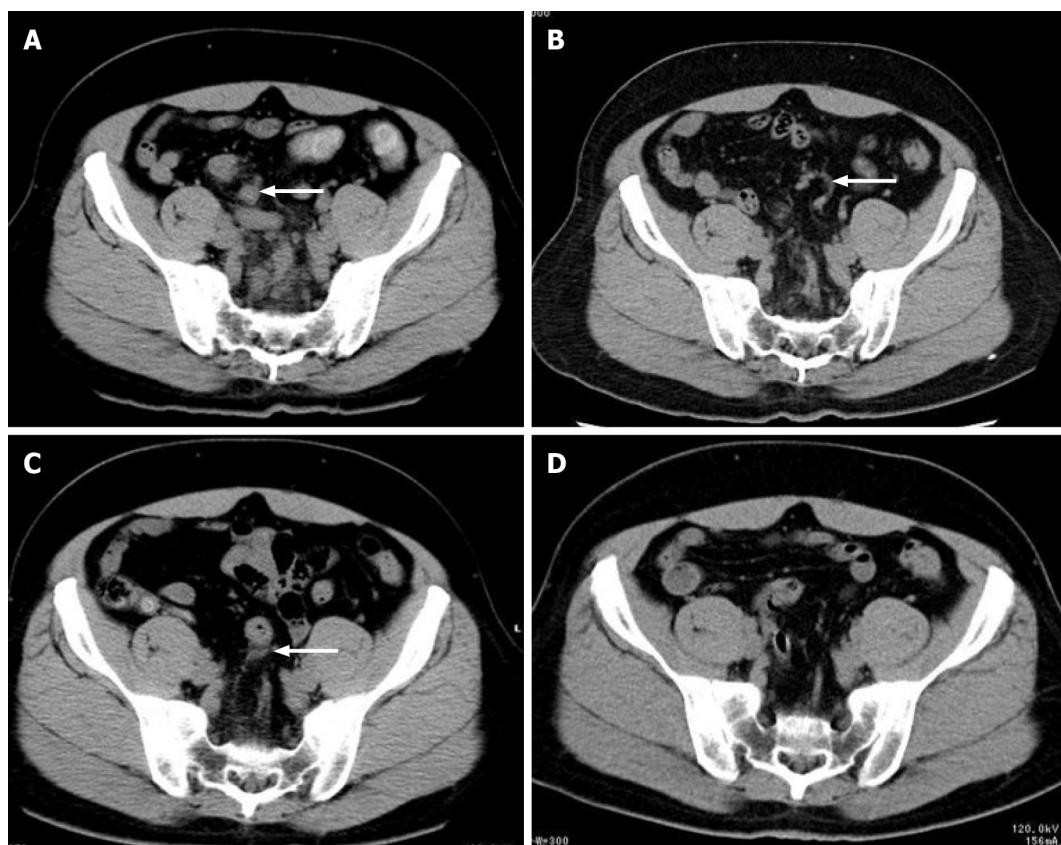


Figure 5 Recent abdominal computed tomography. A-D: Non-enhanced abdominal computed tomography images were taken before admission (A) and 2 years (B), 5 years (C), and 8 years (D) ago. The vessels around the rectosigmoid colon were not evident 8 years ago (D), but dilation of blood vessels around the rectosigmoid colon could have been detected 5 years ago (B and C).

considered that embolization may have exacerbated the ischemia because the range of AVM was widespread. Indeed, in most reported cases, surgical approaches were selected, and only two successful embolization cases were reported^[8,9]. Several cases selected embolization first, followed by exacerbation of ischemia; hence, surgery was finally performed^[4,6,12]. We need to consider how widespread the AVM is when we treat mesenteric AVMs.

CONCLUSION

We revealed the natural history of idiopathic AVM. Ischemic colitis around the rectum is very rare, and thus, we need to diagnose this condition carefully and consider the possibility of AVM. Further accumulation of cases is desired to understand the mechanisms of idiopathic AVM.

REFERENCES

- 1 Washington C, Carmichael JC. Management of ischemic colitis. *Clin Colon Rectal Surg* 2012; **25**: 228-235 [PMID: 24294125 DOI: 10.1055/s-0032-1329534]
- 2 Moore JD, Thompson NW, Appelman HD, Foley D. Arteriovenous malformations of the gastrointestinal tract. *Arch Surg* 1976; **111**: 381-389 [PMID: 1083228 DOI: 10.1001/archsurg.1976.01360220077013]
- 3 Poullos PD, Thompson AC, Holz G, Edelman LA, Jeffrey RB. Ischemic colitis due to a mesenteric arteriovenous malformation in a patient with a connective tissue disorder. *J Radiol Case Rep* 2014; **8**: 9-21 [PMID: 25926912 DOI: 10.3941/jrcr.v8i12.1843]
- 4 Athanasiou A, Michalinos A, Alexandrou A, Georgopoulos S, Felekouras E. Inferior mesenteric arteriovenous fistula: case report and world-literature review. *World J Gastroenterol* 2014; **20**: 8298-8303 [PMID: 25009407 DOI: 10.3748/wjg.v20.i25.8298]
- 5 Metcalf DR, Nivatvongs S, Andrews JC. Ischemic colitis: an unusual case of inferior mesenteric

- arteriovenous fistula causing venous hypertension. Report of a case. *Dis Colon Rectum* 2008; **51**: 1422-1424 [PMID: [18521673](#) DOI: [10.1007/s10350-008-9377-2](#)]
- 6 **Coulier B**, De Wispelaere JF, Bueres I, Pierard F, Deprez FC, Maldague P, van Hoof M, Gielen I. Acute massive congestive ischaemic colitis related to inferior mesenteric arteriovenous malformation. *BJR Case Rep* 2016; **2**: 20150275 [PMID: [30364461](#) DOI: [10.1259/bjrcr.20150275](#)]
- 7 **Strjina V**, Kelley SR. An unusual case of proctosigmoiditis secondary to arteriovenous fistulization. *Turk J Gastroenterol* 2017; **28**: 408-411 [PMID: [28797991](#) DOI: [10.5152/tjg.2017.17253](#)]
- 8 **Doppl WE**, Kuttner D, Stolte M, Breithecker A, Padberg W, Franke FE, Roeb E. Clinical challenges and images in GI. Segmental ischemic colitis owing to vascular malformation of the inferior mesenteric artery. *Gastroenterology* 2007; **133**: 15, 373 [PMID: [17631125](#) DOI: [10.1053/j.gastro.2007.05.038](#)]
- 9 **Justaniah AI**, Molgaard C, Flacke S, Barto A, Iqbal S. Congenital inferior mesenteric arteriovenous malformation presenting with ischemic colitis: endovascular treatment. *J Vasc Interv Radiol* 2013; **24**: 1761-1763 [PMID: [24160837](#) DOI: [10.1016/j.jvir.2013.05.064](#)]
- 10 **Türkvtan A**, Ozdemir Akdur P, Akdoğan M, Cumhuri T, Olçer T, Parlak E. Inferior mesenteric arteriovenous fistula with ischemic colitis: multidetector computed tomographic angiography for diagnosis. *Turk J Gastroenterol* 2009; **20**: 67-70 [PMID: [19330739](#)]
- 11 **Plotkin E**, Assis DN, Boyer JL. Now you see it, now you don't. *Hepatology* 2013; **58**: 446-447 [DOI: [10.1002/hep.26439](#)]
- 12 **Noor M**, Cooper K, Lujan H, Pena C. Arteriovenous malformation of the inferior mesenteric artery presenting as ischemic colitis. *Vasc Med* 2016; **21**: 555-557 [PMID: [27138349](#) DOI: [10.1177/1358863X16645855](#)]
- 13 **Lee S**, Chung J, Ahn B, Lee S, Baek S. Inferior mesenteric arteriovenous fistula. *Ann Surg Treat Res* 2017; **93**: 225-228 [PMID: [29094033](#) DOI: [10.4174/astr.2017.93.4.225](#)]
- 14 **El Muhtaseb MS**, Gorgun E, Liu M. Arteriovenous malformation: a potential cause of ischaemic colitis. *ANZ J Surg* 2013; **83**: 93-94 [PMID: [23350982](#) DOI: [10.1111/j.1445-2197.2012.06322.x](#)]
- 15 **Kim H**, Su H, Weinsheimer S, Pawlikowska L, Young WL. Brain arteriovenous malformation pathogenesis: a response-to-injury paradigm. *Acta Neurochir Suppl* 2011; **111**: 83-92 [PMID: [21725736](#) DOI: [10.1007/978-3-7091-0693-8_14](#)]



Published by **Baishideng Publishing Group Inc**
7041 Koll Center Parkway, Suite 160, Pleasanton, CA 94566, USA

Telephone: +1-925-3991568

E-mail: bpgoffice@wjgnet.com

Help Desk: <https://www.f6publishing.com/helpdesk>

<https://www.wjgnet.com>

