

World Journal of *Clinical Cases*

World J Clin Cases 2021 July 16; 9(20): 5352-5753



Contents

Thrice Monthly Volume 9 Number 20 July 16, 2021

EDITORIAL

- 5352** COVID-19: Considerations about immune suppression and biologicals at the time of SARS-CoV-2 pandemic

Costanzo G, Cordeddu W, Chessa L, Del Giacco S, Firinu D

REVIEW

- 5358** Obesity in people with diabetes in COVID-19 times: Important considerations and precautions to be taken

Alberti A, Schuelter-Trevisol F, Iser Betine PM, Traebert E, Freiburger V, Ventura L, Rezin GT, da Silva BB, Meneghetti Dallacosta F, Grigollo L, Dias P, Fin G, De Jesus JA, Pertille F, Rossoni C, Hur Soares B, Nodari Junior RJ, Comim CM

- 5372** Revisiting delayed appendectomy in patients with acute appendicitis

Li J

MINIREVIEWS

- 5391** Detection of short stature homeobox 2 and RAS-associated domain family 1 subtype A DNA methylation in interventional pulmonology

Wu J, Li P

- 5398** Borderline resectable pancreatic cancer and vascular resections in the era of neoadjuvant therapy

Mikulic D, Mrzljak A

- 5408** Esophageal manifestation in patients with scleroderma

Voulgaris TA, Karamanolis GP

- 5420** Exploration of transmission chain and prevention of the recurrence of coronavirus disease 2019 in Heilongjiang Province due to in-hospital transmission

Chen Q, Gao Y, Wang CS, Kang K, Yu H, Zhao MY, Yu KJ

- 5427** Role of gastrointestinal system on transmission and pathogenesis of SARS-CoV-2

Simsek C, Erul E, Balaban HY

ORIGINAL ARTICLE

Case Control Study

- 5435** Effects of nursing care in fast-track surgery on postoperative pain, psychological state, and patient satisfaction with nursing for glioma

Deng YH, Yang YM, Ruan J, Mu L, Wang SQ

Retrospective Study

- 5442** Risk factors related to postoperative recurrence of dermatofibrosarcoma protuberans: A retrospective study and literature review

Xiong JX, Cai T, Hu L, Chen XL, Huang K, Chen AJ, Wang P

- 5453** Prediction of presence and severity of coronary artery disease using prediction for atherosclerotic cardiovascular disease risk in China scoring system

Hong XL, Chen H, Li Y, Teeroovengadum HD, Fu GS, Zhang WB

- 5462** Effects of angiotensin receptor blockers and angiotensin-converting enzyme inhibitors on COVID-19

Li XL, Li T, Du QC, Yang L, He KL

- 5470** Prognostic factors and its predictive value in patients with metastatic spinal cancer

Gao QP, Yang DZ, Yuan ZB, Guo YX

Clinical Trials Study

- 5479** Prospective, randomized comparison of two supplemental oxygen methods during gastro-scopy with propofol mono-sedation in obese patients

Shao LJZ, Hong FX, Liu FK, Wan L, Xue FS

SYSTEMATIC REVIEWS

- 5490** Herb-induced liver injury: Systematic review and meta-analysis

Ballotin VR, Bigarella LG, Brandão ABM, Balbinot RA, Balbinot SS, Soldera J

META-ANALYSIS

- 5514** Type 2 diabetes mellitus increases liver transplant-free mortality in patients with cirrhosis: A systematic review and meta-analysis

Liu ZJ, Yan YJ, Weng HL, Ding HG

CASE REPORT

- 5526** Duplication of 19q (13.2-13.31) associated with comitant esotropia: A case report

Feng YL, Li ND

- 5535** Multiple left ventricular myxomas combined with severe rheumatic valvular lesions: A case report

Liu SZ, Hong Y, Huang KL, Li XP

- 5540** Complete pathological response in locally advanced non-small-cell lung cancer patient: A case report

Parisi E, Arpa D, Ghigi G, Micheletti S, Neri E, Tontini L, Pieri M, Romeo A

- 5547** Successful reversal of ostomy 13 years after Hartmann procedure in a patient with colon cancer: A case report

Huang W, Chen ZZ, Wei ZQ

- 5556** Delayed papillary muscle rupture after radiofrequency catheter ablation: A case report

Sun ZW, Wu BF, Ying X, Zhang BQ, Yao L, Zheng LR

- 5562** Temporary coronary sinus pacing to improve ventricular dyssynchrony with cardiogenic shock: A case report

Ju TR, Tseng H, Lin HT, Wang AL, Lee CC, Lai YC

- 5568** Hemoglobin Fukuoka caused unexpected hemoglobin A_{1c} results: A case report
Lin XP, Yuan QR, Niu SQ, Jiang X, Wu ZK, Luo ZF
- 5575** Giant androgen-producing adrenocortical carcinoma with atrial flutter: A case report and review of the literature
Costache MF, Arhirii RE, Mogos SJ, Lupascu-Ursulescu C, Litcanu CI, Ciunanghel AI, Cucu C, Ghiciuc CM, Petris AO, Danila N
- 5588** Can kissing cause paraquat poisoning: A case report and review of literature
Ly B, Han DF, Chen J, Zhao HB, Liu XL
- 5594** Spinal dural arteriovenous fistula 8 years after lumbar discectomy surgery: A case report and review of literature
Ouyang Y, Qu Y, Dong RP, Kang MY, Yu T, Cheng XL, Zhao JW
- 5605** Perianal superficial CD34-positive fibroblastic tumor: A case report
Long CY, Wang TL
- 5611** Low-dose clozapine-related seizure: A case report and literature review
Le DS, Su H, Liao ZL, Yu EY
- 5621** Rapid diagnosis of disseminated *Mycobacterium mucogenicum* infection in formalin-fixed, paraffin-embedded specimen using next-generation sequencing: A case report
Liu J, Lei ZY, Pang YH, Huang YX, Xu LJ, Zhu JY, Zheng JX, Yang XH, Lin BL, Gao ZL, Zhuo C
- 5631** Cytomegalovirus colitis induced segmental colonic hypoganglionosis in an immunocompetent patient: A case report
Kim BS, Park SY, Kim DH, Kim NI, Yoon JH, Ju JK, Park CH, Kim HS, Choi SK
- 5637** Primary extra-pancreatic pancreatic-type acinar cell carcinoma in the right perinephric space: A case report and review of literature
Wei YY, Li Y, Shi YJ, Li XT, Sun YS
- 5647** Muscular atrophy and weakness in the lower extremities in Behçet's disease: A case report and review of literature
Kim KW, Cho JH
- 5655** Novel technique of extracorporeal intrauterine morcellation after total laparoscopic hysterectomy: Three emblematic case reports
Macciò A, Sanna E, Lavra F, Calò P, Madeddu C
- 5661** Rare isolated extra-hepatic bile duct injury: A case report
Zhao J, Dang YL, Lin JM, Hu CH, Yu ZY
- 5668** Gelfoam embolization for distal, medium vessel injury during mechanical thrombectomy in acute stroke: A case report
Kang JY, Yi KS, Cha SH, Choi CH, Kim Y, Lee J, Cho BS

- 5675** Oncocytic adrenocortical tumor with uncertain malignant potential in pediatric population: A case report and review of literature
Chen XC, Tang YM, Mao Y, Qin DR
- 5683** Submucosal hematoma with a wide range of lesions, severe condition and atypical clinical symptoms: A case report
Liu L, Shen XJ, Xue LJ, Yao SK, Zhu JY
- 5689** Chorioamnionitis caused by *Serratia marcescens* in a healthcare worker: A case report
Park SY, Kim MJ, Park S, Kim NI, Oh HH, Kim J
- 5695** Endoscopic management of biliary ascariasis: A case report
Wang X, Lv YL, Cui SN, Zhu CH, Li Y, Pan YZ
- 5701** Role of ranulas in early diagnosis of Sjögren's syndrome: A case report
Chen N, Zeng DS, Su YT
- 5709** Sacral chondroblastoma — a rare location, a rare pathology: A case report and review of literature
Zheng BW, Niu HQ, Wang XB, Li J
- 5717** Primary liver actinomycosis in a pediatric patient: A case report and literature review
Liang ZJ, Liang JK, Chen YP, Chen Z, Wang Y
- 5724** Splenosis masquerading as gastric stromal tumor: A case report
Zheng HD, Xu JH, Sun YF
- 5730** Hemorrhagic transformation of ischemic cerebral proliferative angiopathy: A case report
Xia Y, Yu XF, Ma ZJ, Sun ZW
- 5737** Multidisciplinary team therapy for left giant adrenocortical carcinoma: A case report
Zhou Z, Luo HM, Tang J, Xu WJ, Wang BH, Peng XH, Tan H, Liu L, Long XY, Hong YD, Wu XB, Wang JP, Wang BQ, Xie HH, Fang Y, Luo Y, Li R, Wang Y
- 5744** Histopathology and immunophenotyping of late onset cutaneous manifestations of COVID-19 in elderly patients: Three case reports
Mazzitelli M, Dastoli S, Mignogna C, Bennardo L, Lio E, Pelle MC, Trecarichi EM, Pereira BI, Nisticò SP, Torti C

CORRECTION

- 5752** Corrigendum to "Probiotic mixture VSL#3: An overview of basic and clinical studies in chronic diseases"
Sang LX

ABOUT COVER

Editorial Board Member of *World Journal of Clinical Cases*, Fan-Zheng Meng, MD, PhD, Director, Professor, Department of Pediatrics, The First hospital of Jilin University, Changchun 130021, Jilin Province, China. mengfanzheng1972@163.com

AIMS AND SCOPE

The primary aim of *World Journal of Clinical Cases* (WJCC, *World J Clin Cases*) is to provide scholars and readers from various fields of clinical medicine with a platform to publish high-quality clinical research articles and communicate their research findings online.

WJCC mainly publishes articles reporting research results and findings obtained in the field of clinical medicine and covering a wide range of topics, including case control studies, retrospective cohort studies, retrospective studies, clinical trials studies, observational studies, prospective studies, randomized controlled trials, randomized clinical trials, systematic reviews, meta-analysis, and case reports.

INDEXING/ABSTRACTING

The WJCC is now indexed in Science Citation Index Expanded (also known as SciSearch®), Journal Citation Reports/Science Edition, Scopus, PubMed, and PubMed Central. The 2021 Edition of Journal Citation Reports® cites the 2020 impact factor (IF) for WJCC as 1.337; IF without journal self cites: 1.301; 5-year IF: 1.742; Journal Citation Indicator: 0.33; Ranking: 119 among 169 journals in medicine, general and internal; and Quartile category: Q3. The WJCC's CiteScore for 2020 is 0.8 and Scopus CiteScore rank 2020: General Medicine is 493/793.

RESPONSIBLE EDITORS FOR THIS ISSUE

Production Editor: Jia-Hui Li; Production Department Director: Yu-Jie Ma; Editorial Office Director: Jin-Lei Wang.

NAME OF JOURNAL

World Journal of Clinical Cases

ISSN

ISSN 2307-8960 (online)

LAUNCH DATE

April 16, 2013

FREQUENCY

Thrice Monthly

EDITORS-IN-CHIEF

Dennis A Bloomfield, Sandro Vento, Bao-Gan Peng

EDITORIAL BOARD MEMBERS

<https://www.wjgnet.com/2307-8960/editorialboard.htm>

PUBLICATION DATE

July 16, 2021

COPYRIGHT

© 2021 Baishideng Publishing Group Inc

INSTRUCTIONS TO AUTHORS

<https://www.wjgnet.com/bpg/gerinfo/204>

GUIDELINES FOR ETHICS DOCUMENTS

<https://www.wjgnet.com/bpg/GerInfo/287>

GUIDELINES FOR NON-NATIVE SPEAKERS OF ENGLISH

<https://www.wjgnet.com/bpg/gerinfo/240>

PUBLICATION ETHICS

<https://www.wjgnet.com/bpg/GerInfo/288>

PUBLICATION MISCONDUCT

<https://www.wjgnet.com/bpg/gerinfo/208>

ARTICLE PROCESSING CHARGE

<https://www.wjgnet.com/bpg/gerinfo/242>

STEPS FOR SUBMITTING MANUSCRIPTS

<https://www.wjgnet.com/bpg/GerInfo/239>

ONLINE SUBMISSION

<https://www.f6publishing.com>



Successful reversal of ostomy 13 years after Hartmann procedure in a patient with colon cancer: A case report

Wang Huang, Zhen-Zhou Chen, Zheng-Qiang Wei

ORCID number: Wang Huang 0000-0002-5634-1272; Zhen-Zhou Chen 0000-0002-4324-5388; Zheng-Qiang Wei 0000-0002-6499-6033.

Author contributions: Huang W performed the case report and wrote the manuscript; Chen ZZ edited the manuscript; Wei ZQ supervised the work and edited the manuscript.

Supported by Chongqing Key Diseases Research and Application Demonstration Program (Colorectal Cancer Prevention and Treatment Technology Research and Application Demonstration), No. 2019ZX003.

Informed consent statement: The patient provided informed written consent for participation in this study, including sample collection and permission for their use in research.

Conflict-of-interest statement: The authors have no conflicts of interest to declare.

CARE Checklist (2016) statement: The authors have read the CARE Checklist (2016), and the manuscript was prepared and revised according to the CARE Checklist (2016).

Open-Access: This article is an open-access article that was

Wang Huang, Zhen-Zhou Chen, Zheng-Qiang Wei, Department of Gastrointestinal Surgery, The First Affiliated Hospital of Chongqing Medical University, Chongqing 400000, China

Corresponding author: Zheng-Qiang Wei, MD, Doctor, Department of Gastrointestinal Surgery, The First Affiliated Hospital of Chongqing Medical University, No. 1 Youyi Road, Yuanjiagang, Yuzhong District, Chongqing 400000, China. 384535713@qq.com

Abstract

BACKGROUND

The Hartmann procedure is currently recognized as a common, safe, and feasible surgical procedure. However, its reversal rate is low, and the optimal timing for Hartmann reversal surgery is controversial.

CASE SUMMARY

A 65-year-old man came to our hospital with a complaint of an intestinal fistula next to the stoma. The patient had undergone a Hartmann procedure 13 years prior. We performed colonoscopy, computed tomography, and other diagnostics before successfully reversing the stoma.

CONCLUSION

Although the optimal time for Hartmann procedure reversal is controversial, time may ultimately not be a factor in the success of reversal.

Key Words: Hartmann; Hartmann's procedure; Reversal; Time; Complications; Case study; Case report

©The Author(s) 2021. Published by Baishideng Publishing Group Inc. All rights reserved.

Core Tip: First, for acute intestinal obstruction in the left colon or rectum, Hartmann's surgery is a safe and feasible treatment. Second, there is controversy about the time to reversal after Hartmann's procedure. This case is the longest successful reversal in the world.

Citation: Huang W, Chen ZZ, Wei ZQ. Successful reversal of ostomy 13 years after Hartmann procedure in a patient with colon cancer: A case report. *World J Clin Cases* 2021; 9(20): 5547-5555

selected by an in-house editor and fully peer-reviewed by external reviewers. It is distributed in accordance with the Creative Commons Attribution NonCommercial (CC BY-NC 4.0) license, which permits others to distribute, remix, adapt, build upon this work non-commercially, and license their derivative works on different terms, provided the original work is properly cited and the use is non-commercial. See: <http://creativecommons.org/licenses/by-nc/4.0/>

Manuscript source: Unsolicited manuscript

Specialty type: Medicine, research and experimental

Country/Territory of origin: China

Peer-review report's scientific quality classification

Grade A (Excellent): 0
Grade B (Very good): 0
Grade C (Good): 0
Grade D (Fair): 0
Grade E (Poor): 0

Received: November 26, 2020

Peer-review started: November 26, 2020

First decision: May 11, 2021

Revised: May 22, 2021

Accepted: May 25, 2021

Article in press: May 25, 2021

Published online: July 16, 2021

P-Reviewer: Wetwittayakhleng P

S-Editor: Fan JR

L-Editor: Wang TQ

P-Editor: Li X



URL: <https://www.wjgnet.com/2307-8960/full/v9/i20/5547.htm>

DOI: <https://dx.doi.org/10.12998/wjcc.v9.i20.5547>

INTRODUCTION

Currently, colorectal cancer is one of the most common malignant tumors, having the third highest incidence among all malignancies and being the second leading cause of cancer-related mortality. Many colorectal cases are diagnosed as acute onset due to intestinal obstruction and/or perforation. The majority of the reported figures are approximately 30% for such presentation[1]. However, colorectal obstruction accounts for approximately 80% of emergency cases related to colorectal cancer[1]. The most common site of colorectal cancer obstruction is the sigmoid colon, and 75% of such tumors are located in the distal splenic flexure[2].

When colon cancer is complicated by intestinal obstruction, emergency surgery is often required, and Hartmann's procedure[3] (proximal fistula, distal closure) is usually preferred. Currently, the Hartmann procedure is recognized as a common, safe, and feasible surgical method[4]. However, after Hartmann, the long-term stoma state leads to a lower quality of life for the patient, and there are also complications such as parastomal hernia[5], stoma prolapse[6], stoma stenosis[6], and stoma infection [6]. However, due to the locally advanced nature of most colorectal tumors, the possibility of tumor recurrence and metastasis after surgery is relatively high. Therefore, it is necessary to fully evaluate the characteristics of the tumor before considering the reversal surgery. Additionally, Hartmann procedure reversal is extremely difficult due to severe abdominal adhesions, difficulty in finding stumps, and changes in distal disuse, which have caused the time to perform reversal to be delayed. Moreover, the patient's bowel function may be affected after the reversal procedure, so often no such surgery is considered. Currently, the time to reversal after Hartmann's operation is the focus of controversy.

In this case study, we report a patient with a successful fistula reversal 13 years after undergoing Hartmann's procedure.

CASE PRESENTATION

Chief complaints

A 65-year-old man was admitted to our hospital for "discovering a nodule adjacent to the stoma in April that had enlarged for 1 wk, and then ruptured 1 d prior".

History of present illness

Four months ago, the patient accidentally found a small nodule on the right side of the colostomy that was approximately 0.5 cm in size without redness, swelling, or tenderness, and did not go to the doctor. Two months ago, the nodule enlarged, accompanied by redness, swelling, heat, and pain. After oral administration of cefdinir, he improved and did not take antibiotics regularly. One week ago, the patient had an enlarged nodule on the right side of the stoma, accompanied by a mass on the left side of the stoma that was approximately 4 cm × 3 cm in size, with redness, swelling, heat, pain, and a black mass of pus in the middle; intravenous infusion of cefoxitin did not alleviate symptoms. Three days ago, the nodule on the right side of the stoma ruptured, and a fistula of approximately 1.5 cm in size appeared, which caused a large amount of overflowing stool. A day ago, the mass on the left side of the fistula ruptured and released pus, so he went to our hospital.

History of past illness

Thirteen years ago, the patient underwent Hartmann surgery due to a sigmoid colon tumor with acute obstruction. Postoperative pathological diagnosis was stage II sigmoid colon adenocarcinoma (T4N0M0). Due to the patient's own reasons, he did not undergo regular treatment and not reverse the stoma in time. The patient was admitted to our hospital for paraostomy hernia and right inguinal hernia 3 years ago, and underwent tension-free inguinal repair and paraostomy hernia repair *via* an open operation. The abscess was cut for drainage 1 year ago due to a paraostomy abscess.

Physical examination

There was a 10-cm surgical scar (from the Hartmann surgical incision) on the right abdomen, a 15-cm surgical incision scar (paraostomy hernia repair incision) in the middle abdomen, and a 5-cm surgical scar on the right inguinal area. The colostomy port was located in the left lower abdomen. On the right side of the colostomy port, there was an abscess of approximately 5 cm × 5 cm in size. The skin was red, swollen, and hot. A middle ulcer was also found. The place where the mass overflowed with pus was located at the anterior upper pole of the iliac and was approximately 1.5 cm × 1.5 cm, at a depth of approximately about 2 cm, and there was pus outflow. On the left side of the stoma, there was a fistula of approximately 1.5 cm × 1.5 cm in size, located next to the belly button that had much stool overflow. A mass of approximately 5 cm × 3 cm was palpable in the left groin area, which was obvious when standing, soft in quality, and did not protrude into the scrotum.

Laboratory examinations

Routine blood markers and tumor markers were normal, but Calcitonin original was 0.53.

Imaging examinations

Enhanced computed tomography: The right sinus of the stoma was formed, which was the same as the intestinal cavity (orange arrow), and the parastomal hernia can be seen (Figure 1A-C). The left side of the stoma had a suspicious sinus formation (yellow arrow), with surrounding soft tissue swelling (Figure 1D and E) and left inguinal hernia (white arrow). No tumor recurrence was seen (Figure 1F).

Colonoscopy: The proximal bowel (Figure 2A and B) was not significantly abnormal; the distal bowel (Figure 2C and D) was approximately 25 cm, and showed changes from disuse, with a large number of white mucus masses (The white mucus masses were formed by the absorption of water by intestinal fluid secreted by the colon).

Retrograde transanal digestive tract radiography: Front view (Figure 3A and B) and lateral view (Figure 3C and D) showed that the distal bowel was approximately 25 cm, with no bowel stenosis and a smooth bowel mucosa.

FINAL DIAGNOSIS

(1) Colostomy with infection; (2) Parastomal hernia; (3) Intestinal fistula; and (4) Inguinal hernia.

TREATMENT

Although the patient had no fever after admission and the infection index was not high, the patient's local infection was severe, and the left abscess was treated with incision and drainage. According to the results of drug sensitivity, ceftizoxime was given as an anti-inflammatory with nutritional support. With general care, including changing the dressing on the fistula, the patient's infection was gradually controlled and improved.

The patient has a large amount of leakage due to the intestinal fistula, which was a high-flow fistula[7] that seriously affects the patient's quality of life. According to the patient's condition, the following treatment options were available: (1) Stoma displacement and stoma reconstruction; (2) Proximal colostomy to address the abdominal wall where two stomas had formed; (3) Hartmann reversal; and (4) Waiting and observation. After full communication, the patient, the patient's family, and the doctor unanimously decided to perform Hartmann's reversal. The patient underwent laparoscopic exploration under general anesthesia, lysis of intestinal adhesions, partial removal of the parastomal mesh, bowel resection and anastomosis, and abdominal sinus resection. A small incision in the right upper abdomen was first made. During the operation, it was found that abdominal adhesion was serious, no tumor recurrence was found, the distal bowel was located in the left paracolic sulcus (approximately 25 cm in length), and the distal bowel was changed due to disuse with obvious atrophy. There was also a mucus mass in the stump. To ensure a successful anastomosis, a 5-cm intestinal tube was removed from the stump and end-to-end anastomosis was performed. The inflation test was negative, so preventive stoma was not performed.

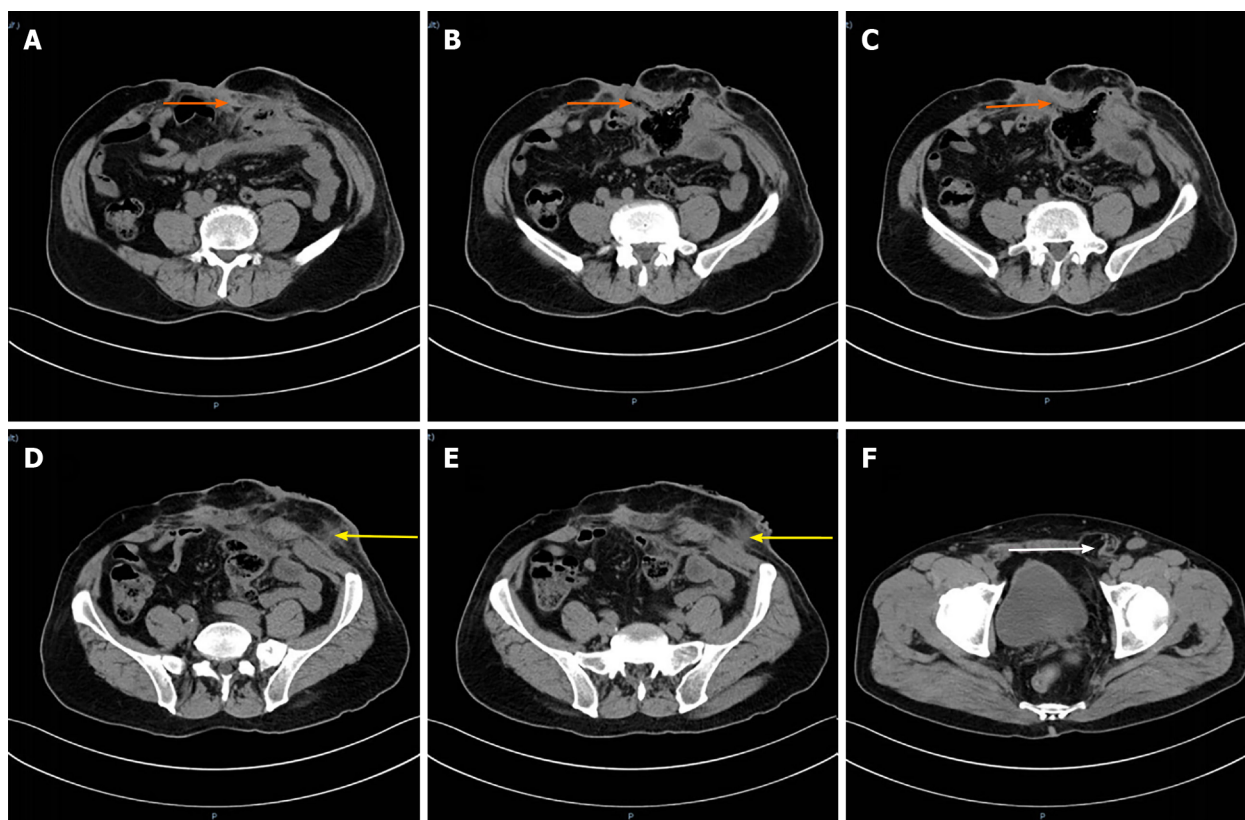


Figure 1 Enhanced computed tomography. A-C: The orange arrow refers to the sinus formed by the intestinal fistula on the right side of the stoma; D and E: The yellow arrow is the suspicious sinus on the left side of the stoma; F: The white arrow is the left inguinal hernia.

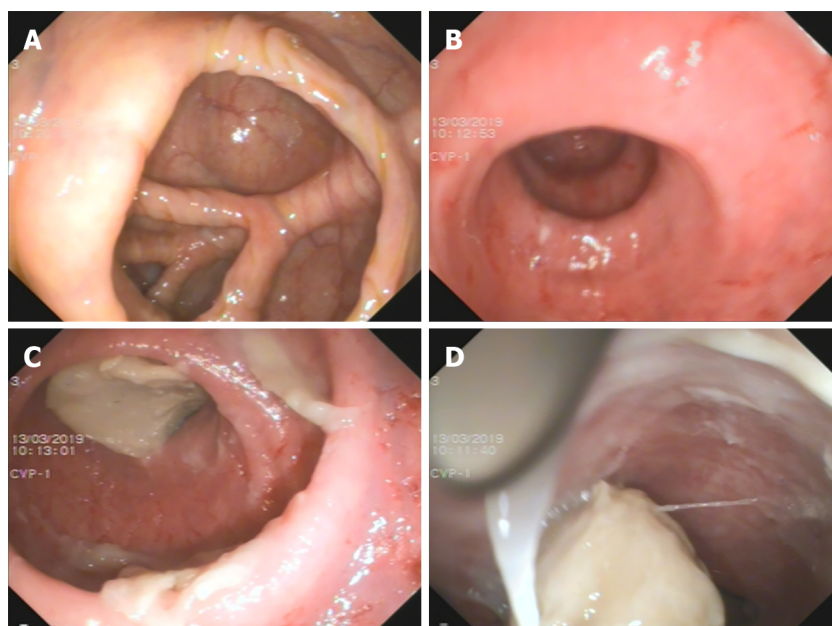


Figure 2 Colonoscopy. A: The ileocecal region; B: The proximal intestine; C and D: The distal intestine.

Intraoperative bleeding was 200 mL, and the operation took 420 min.

After the operation, *Escherichia coli* and *Enterococcus faecium* were cultured in the abdominal drainage fluid of the patient, who had signs of peritonitis. According to the drug sensitivity test, piperacillin sodium and tazobactam sodium 4.5 g every 8 h (total 14 d) were given for anti-inflammatory. An incision infection occurred on the 6th day (Figure 4A), and the dressing was changed. On the 6th day after the operation, he developed exhaust and defecated on the 8th day. After active anti-infection treatment,

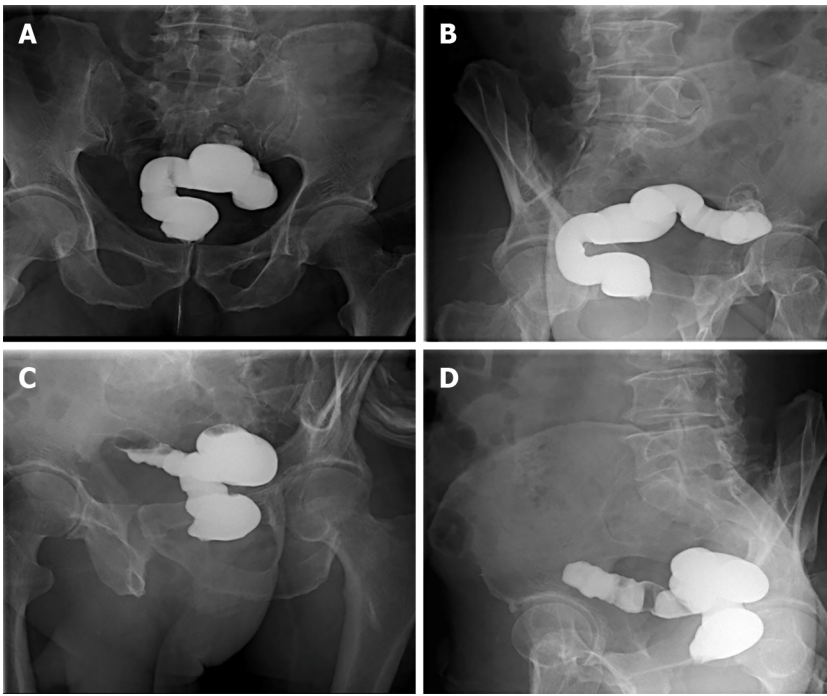


Figure 3 Pelvis films. A and B: Pelvic anterior films; C and D: Pelvic lateral films.

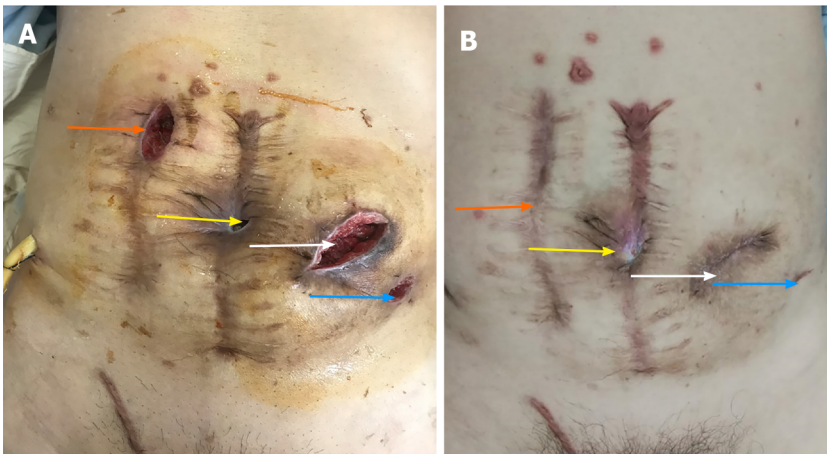


Figure 4 Postoperative wound. A: The wound on the 6th day after surgery. The orange arrow is the small incision, the yellow arrow is the sinus on the right side of the stoma, the white arrow is the original fistula position, and the blue arrow is the left fistula of the stoma; B: The wound 6 mo after the operation. The yellow arrow is the sinus tract on the right side of the stoma, which has not healed, the white arrow is the location of the original stoma, which is an incisional hernia, and the blue arrow is the left fistula of the original stoma.

he was discharged smoothly after the operation.

OUTCOME AND FOLLOW-UP

In the first 6 mo after surgery, regular follow-up visits were made every 3 mo in the outpatient clinic, and the patient's intestinal function was assessed through the Ligament Augmentation and Reconstruction System (LARS) scale. Tumor markers were evaluated every 6 mo after surgery. Colonoscopy and computed tomography (CT) examinations were completed 1 year after surgery. Three months after surgery, bowel movements occurred 4 to 7 times a day, with stool irregularity. The LARS score was 21 points, which is considered mild LARS. Six months after surgery, the patient had a bowel movement once a day, with stool formation. The LARS score was 11 points, meaning no LARS. There were also normal tumor markers and CT prompts for incisional hernia and inguinal hernia formation (Figure 5), abdominal wounds

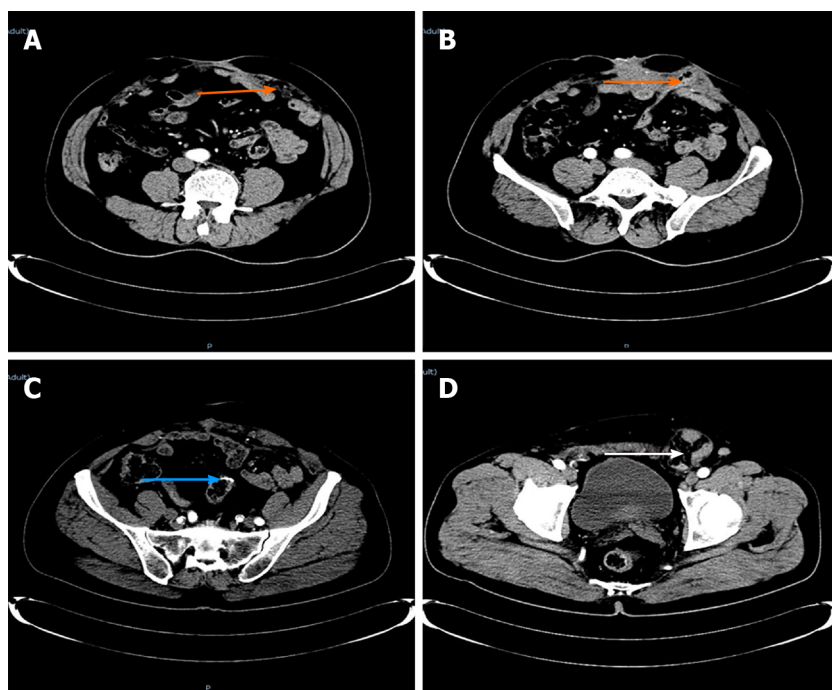


Figure 5 Re-examination at 6 mo showed no tumor recurrence. A and B: The orange arrow is the incisional hernia; C: The blue arrow is the anastomosis; D: The white arrow is the left inguinal hernia, which is larger than before.

(Figure 4B), abdominal wall hernia repair, and inguinal hernia repair. One year after the operation, the patient had a bowel movement once a day, with stool formation. The LARS score remained at 11 points, with no LARS, normal tumor markers, and normal colonoscopy results (Figure 6). Over the past year, the patient's psychological pressure has significantly decreased, as he can travel, visit friends, and have a bright mood, which has improved his quality of life.

DISCUSSION

According to reports in the literature, the incidence of colorectal cancer is increasing annually, with up to 40% of colorectal cancers developing acutely. Among them, most are caused by obstruction. The current common processing methods[3] are: (1) Loop colostomy; (2) Primary resection with end colostomy: Hartmann's procedure; (3) Endoscopic colonic stenting with self-expanding metallic stents; and (4) Primary resection and anastomosis. Currently, Hartmann's procedure is one of the main methods for treating left colorectal cancer with acute intestinal obstruction[2]. In this case, the patient started with acute mechanical obstruction. Since colonic stent implantation was immature in China 13 years ago, doctors chose this safe and feasible method, which not only cured the intestinal obstruction, but was also more successful. The tumor was removed, and the patient had no tumor recurrence after the operation.

The rate of complications after receiving Hartmann's procedure is as high as 51% [8]. Common complications include incision infection, distal rectal stump dysfunction, and parastomal complications. In this case, the patient experienced stoma-related complications such as parastomal hernia[6], parastomal abscess, and intestinal fistula, which seriously affected the patient's quality of life and increased psychological pressure. According to the literature, the rate of parastomal hernia is as high as 58%. Stoma patients have poor mental health, body image, and physical and emotional function[5]. In addition to the above-mentioned complications, the survival rate following Hartmann's operation is lower[9]; but fortunately, the patient in this case achieved R0 resection and no metastasis occurred after the operation.

In this case, the patient underwent Hartmann reversal, which decreased his psychological pressure and allowed him to better integrate into society. It is also because this case had two parastomal hernias and bilateral inguinal hernias on the abdominal wall. The patient's abdomen was weak. If the stoma is displaced or two stomas are performed, the patient will still have stoma-related complications and the abdominal wall will be worse. Therefore, the team chose stoma reversal.

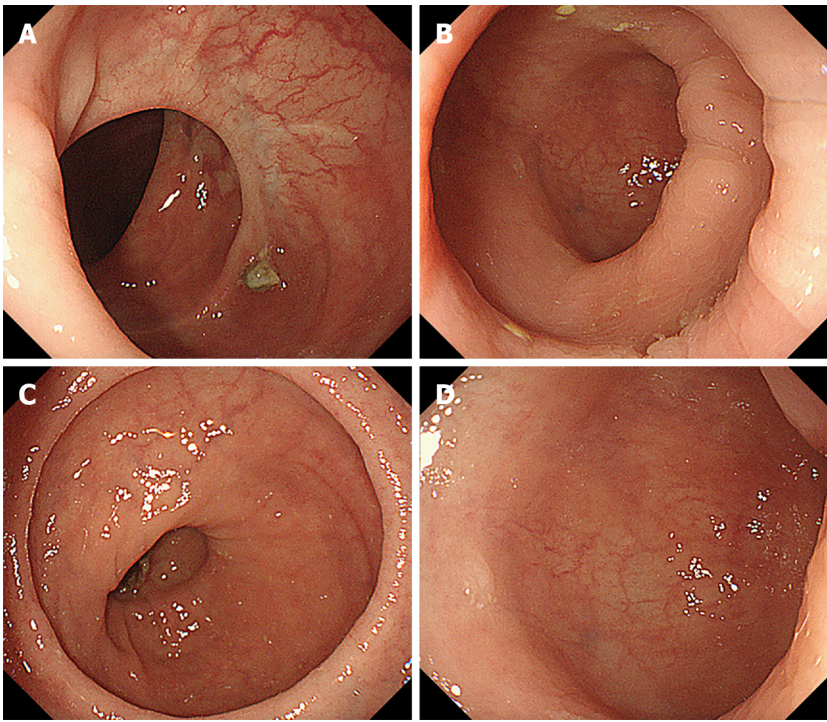


Figure 6 A colonoscopy was performed one year after surgery. A: The proximal end; B and C: The anastomoses; D: The distal end of the anastomosis.

The reversal rate of Hartmann surgery is very low. As reported in the literature, the Hartmann reversal rate is 25.9%-61% [4,10-14], and most of the literature reports are less than 50%. According to the 2015 United States bowel cancer audit report, 95% of patients who received Hartmann surgery still had a stoma 18 mo later. Currently, the intervening time before performing Hartmann reversal is controversial. It has been reported in the literature that the average time interval between Hartmann surgery and Hartmann reversal is 11 mo [4], of which the longest fistula reversal time is 96 mo [4]. The reversal time in this case was 156 mo, much longer than the time reported in the literature.

Previous studies have reported increased rates of complications with increased time to the reversal operation [12,14-16]. They speculated that this was related to atrophy of the distal stump, and it is recommended to reverse it as soon as possible. Others have noted that complications can be reduced by clinical treatment and nutrition support [12,17-20]. Finally, some believe that the length of reversal time does not affect postoperative complications or reversal rate [5,14,21,22]. In this case, the reversal time was 156 mo, which proves that the interval length does not increase the risk of reversal. At the same time, the incidence of complications after Hartmann reversal is quite high. According to reports in the literature, the total incidence of complications after Hartmann reversal is 16.3% (3.6%-50%) [11]. The most common postoperative complication is wound infection, with incidence rates ranging from 5% to 30% (average 12.5%) [12], followed by anastomotic failure, whose incidence rate is 4.2% [22]. In this case, the complication was wound infection, but no serious complications were present such as cardiopulmonary complications, anastomotic leakage, or other related complications.

Technical difficulties for Hartmann reversal include pelvic adhesions [4], chronic pelvic infections [4], difficulty in identifying short rectal stumps [4], and failure of rectal stump anastomosis [11]. Currently, the methods for Hartmann's reversal include: Traditional open surgery, laparoscopic surgery, and transostomy reversal. Studies have shown that using laparoscopic surgery for reversal is more beneficial than using traditional approaches [11]. Additionally, laparoscopic surgery can reduce postoperative pain, aid in early recovery (early exhaust [23]), lower overall morbidity and wound infection rates, and decrease the postoperative intestinal obstruction rate [24]. However, as reported in the literature [25], incisional hernias also appeared in this case.

CONCLUSION

First, for acute intestinal obstruction in the left colon or rectum, Hartmann's surgery is a safe and feasible treatment. Second, there is controversy about the time to reversal after Hartmann's procedure. It is not possible to use conventional experience or treatment methods to make the patient lose the opportunity to reverse the fistula. As in this case, the longer interval did not increase reversal complications; of course, the opinions of the patients and the surgical team should also be integrated. This successful case is a boon for patients after Hartmann's procedure, as it offers more choices.

ACKNOWLEDGEMENTS

We would like to express our gratitude to all those who contributed to the study.

REFERENCES

- 1 **Pisano M**, Zorcolo L, Merli C, Cimbanassi S, Poiasina E, Ceresoli M, Agresta F, Allievi N, Bellanova G, Coccolini F, Coy C, Fugazzola P, Martinez CA, Montori G, Paolillo C, Penachim TJ, Pereira B, Reis T, Restivo A, Rezende-Neto J, Sartelli M, Valentino M, Abu-Zidan FM, Ashkenazi I, Bala M, Chiara O, De' Angelis N, Deidda S, De Simone B, Di Saverio S, Finotti E, Kenji I, Moore E, Wexner S, Biffl W, Coimbra R, Guttadauro A, Leppäniemi A, Maier R, Magnone S, Mefire AC, Peitzmann A, Sakakushev B, Sugrue M, Viale P, Weber D, Kashuk J, Fraga GP, Kluger I, Catena F, Ansaloni L. 2017 WSES guidelines on colon and rectal cancer emergencies: obstruction and perforation. *World J Emerg Surg* 2018; **13**: 36 [PMID: 30123315 DOI: 10.1186/s13017-018-0192-3]
- 2 **Frago R**, Ramirez E, Millan M, Kreisler E, del Valle E, Biondo S. Current management of acute malignant large bowel obstruction: a systematic review. *Am J Surg* 2014; **207**: 127-138 [PMID: 24124659 DOI: 10.1016/j.amjsurg.2013.07.027]
- 3 **Ansaloni L**, Andersson RE, Bazzoli F, Catena F, Cennamo V, Di Saverio S, Fuccio L, Jeekel H, Leppäniemi A, Moore E, Pinna AD, Pisano M, Repici A, Sugarbaker PH, Tuech JJ. Guidelines in the management of obstructing cancer of the left colon: consensus conference of the world society of emergency surgery (WSES) and peritoneum and surgery (PnS) society. *World J Emerg Surg* 2010; **5**: 29 [PMID: 21189148 DOI: 10.1186/1749-7922-5-29]
- 4 **Hallam S**, Mothe BS, Tirumulaju R. Hartmann's procedure, reversal and rate of stoma-free survival. *Ann R Coll Surg Engl* 2018; **100**: 301-307 [PMID: 29484943 DOI: 10.1308/rcsann.2018.0006]
- 5 **Näsvall P**, Dahlstrand U, Löwenmark T, Rutegård J, Gunnarsson U, Strigård K. Quality of life in patients with a permanent stoma after rectal cancer surgery. *Qual Life Res* 2017; **26**: 55-64 [PMID: 27444778 DOI: 10.1007/s11136-016-1367-6]
- 6 **Ambe PC**, Kurz NR, Nitschke C, Odeh SF, Möslin G, Zirngibl H. Intestinal Ostomy. *Dtsch Arztebl Int* 2018; **115**: 182-187 [PMID: 29607805 DOI: 10.3238/arztebl.2018.0182]
- 7 **Kumpf VJ**, de Aguilar-Nascimento JE, Diaz-Pizarro Graf JJ, Hall AM, McKeever L, Steiger E, Winkler MF, Compher CW; FELANPE; American Society for Parenteral and Enteral Nutrition. ASPEN-FELANPE Clinical Guidelines. *JPEN J Parenter Enteral Nutr* 2017; **41**: 104-112 [PMID: 27913762 DOI: 10.1177/0148607116680792]
- 8 **Ermolov AS**, Rudin EP, Novruzov NG, Upyrev AV, Mironov AS. [Complications after Hartman's operation]. *Khirurgiya (Mosk)* 2007; **11**-14 [PMID: 18231090]
- 9 **Biondo S**, Kreisler E, Millan M, Fracalvieri D, Golda T, Martí Ragué J, Salazar R. Differences in patient postoperative and long-term outcomes between obstructive and perforated colonic cancer. *Am J Surg* 2008; **195**: 427-432 [PMID: 18361923 DOI: 10.1016/j.amjsurg.2007.02.027]
- 10 **Horesh N**, Lessing Y, Rudnicki Y, Kent I, Kammar H, Ben-Yaacov A, Dreznik Y, Tulchinsky H, Avital S, Mavor E, Wasserberg N, Kashtan H, Klausner JM, Gutman M, Zmora O. Considerations for Hartmann's reversal and Hartmann's reversal outcomes-a multicenter study. *Int J Colorectal Dis* 2017; **32**: 1577-1582 [PMID: 28879552 DOI: 10.1007/s00384-017-2897-2]
- 11 **van de Wall BJ**, Draaisma WA, Schouten ES, Broeders IA, Consten EC. Conventional and laparoscopic reversal of the Hartmann procedure: a review of literature. *J Gastrointest Surg* 2010; **14**: 743-752 [PMID: 19936852 DOI: 10.1007/s11605-009-1084-3]
- 12 **Banerjee S**, Leather AJ, Rennie JA, Samano N, Gonzalez JG, Papagrigoriadis S. Feasibility and morbidity of reversal of Hartmann's. *Colorectal Dis* 2005; **7**: 454-459 [PMID: 16108881 DOI: 10.1111/j.1463-1318.2005.00862.x]
- 13 **Tokode OM**, Akingboye A, Coker O. Factors affecting reversal following Hartmann's procedure: experience from two district general hospitals in the UK. *Surg Today* 2011; **41**: 79-83 [PMID: 21191695 DOI: 10.1007/s00595-009-4224-1]
- 14 **Roque-Castellano C**, Marchena-Gomez J, Hemmersbach-Miller M, Acosta-Merida A, Rodriguez-Mendez A, Fariña-Castro R, Hernandez-Romero J. Analysis of the factors related to the decision of restoring intestinal continuity after Hartmann's procedure. *Int J Colorectal Dis* 2007; **22**: 1091-1096

- [PMID: [17256137](#) DOI: [10.1007/s00384-007-0272-4](#)]
- 15 **Tan WS**, Lim JF, Tang CL, Eu KW. Reversal of Hartmann's procedure: experience in an Asian population. *Singapore Med J* 2012; **53**: 46-51 [PMID: [22252183](#)]
 - 16 **Schmelzer TM**, Mostafa G, Norton HJ, Newcomb WL, Hope WW, Lincourt AE, Kercher KW, Kuwada TS, Gersin KS, Heniford BT. Reversal of Hartmann's procedure: a high-risk operation? *Surgery* 2007; **142**: 598-606; discussion 606 [PMID: [17950354](#) DOI: [10.1016/j.surg.2007.08.001](#)]
 - 17 **Pearce NW**, Scott SD, Karran SJ. Timing and method of reversal of Hartmann's procedure. *Br J Surg* 1992; **79**: 839-841 [PMID: [1393489](#) DOI: [10.1002/bjs.1800790844](#)]
 - 18 **Keck JO**, Collopy BT, Ryan PJ, Fink R, Mackay JR, Woods RJ. Reversal of Hartmann's procedure: effect of timing and technique on ease and safety. *Dis Colon Rectum* 1994; **37**: 243-248 [PMID: [8137671](#) DOI: [10.1007/BF02048162](#)]
 - 19 **Khan AL**, Ah-See AK, Crofts TJ, Heys SD, Eremin OJ. Reversal of Hartmann's colostomy. *J R Coll Surg Edinb* 1994; **39**: 239
 - 20 **Fleming FJ**, Gillen P. Reversal of Hartmann's procedure following acute diverticulitis: is timing everything? *Int J Colorectal Dis* 2009; **24**: 1219-1225 [PMID: [19499234](#) DOI: [10.1007/s00384-009-0747-6](#)]
 - 21 **Takahashi-Monroy T**, Velasco L, Morales-Olivera JM. [Morbi-mortality of Hartmann's reversal procedure]. *Cir Cir* 2006; **74**: 329-333 [PMID: [17224103](#)]
 - 22 **Guerra F**, Coletta D, Del Basso C, Giuliani G, Patriti A. Conventional Versus Minimally Invasive Hartmann Takedown: A Meta-analysis of the Literature. *World J Surg* 2019; **43**: 1820-1828 [PMID: [30824963](#) DOI: [10.1007/s00268-019-04962-8](#)]
 - 23 **Kwak HD**, Kim J, Kang DW, Baek SJ, Kwak JM, Kim SH. Hartmann's reversal: a comparative study between laparoscopic and open approaches. *ANZ J Surg* 2018; **88**: 450-454 [PMID: [28730630](#) DOI: [10.1111/ans.13979](#)]
 - 24 **Celentano V**, Giglio MC, Bucci L. Laparoscopic vs open Hartmann's reversal: a systematic review and meta-analysis. *Int J Colorectal Dis* 2015; **30**: 1603-1615 [PMID: [26189028](#) DOI: [10.1007/s00384-015-2325-4](#)]
 - 25 **Fiscon V**, Portale G, Mazzeo A, Migliorini G, Frigo F. Laparoscopic reversal of Hartmann's procedure. *Updates Surg* 2014; **66**: 277-281 [PMID: [25262377](#) DOI: [10.1007/s13304-014-0268-x](#)]



Published by **Baishideng Publishing Group Inc**
7041 Koll Center Parkway, Suite 160, Pleasanton, CA 94566, USA

Telephone: +1-925-3991568

E-mail: bpgoffice@wjgnet.com

Help Desk: <https://www.f6publishing.com/helpdesk>

<https://www.wjgnet.com>

