

World Journal of *Clinical Cases*

World J Clin Cases 2021 July 26; 9(21): 5754-6177



Contents

Thrice Monthly Volume 9 Number 21 July 26, 2021

REVIEW

- 5754 Treatment strategies for hepatocellular carcinoma with extrahepatic metastasis
Long HY, Huang TY, Xie XY, Long JT, Liu BX

MINIREVIEWS

- 5769 Prevention of hepatitis B reactivation in patients requiring chemotherapy and immunosuppressive therapy
Shih CA, Chen WC
- 5782 Research status on immunotherapy trials of gastric cancer
Liang C, Wu HM, Yu WM, Chen W
- 5794 Therapeutic plasma exchange for hyperlipidemic pancreatitis: Current evidence and unmet needs
Zheng CB, Zheng ZH, Zheng YP
- 5804 Essentials of thoracic outlet syndrome: A narrative review
Chang MC, Kim DH

ORIGINAL ARTICLE

Case Control Study

- 5812 Soluble programmed death-1 is predictive of hepatitis B surface antigen loss in chronic hepatitis B patients after antiviral treatment
Tan N, Luo H, Kang Q, Pan JL, Cheng R, Xi HL, Chen HY, Han YF, Yang YP, Xu XY

Retrospective Cohort Study

- 5822 Tunneled biopsy is an underutilised, simple, safe and efficient method for tissue acquisition from subepithelial tumours
Koutsoumpas A, Perera R, Melton A, Kuker J, Ghosh T, Braden B

Retrospective Study

- 5830 Macular ganglion cell complex injury in different stages of anterior ischemic optic neuropathy
Zhang W, Sun XQ, Peng XY
- 5840 Value of refined care in patients with acute exacerbation of chronic obstructive pulmonary disease
Na N, Guo SL, Zhang YY, Ye M, Zhang N, Wu GX, Ma LW
- 5850 Facilitators and barriers to colorectal cancer screening in an outpatient setting
Samuel G, Kratzer M, Asagbra O, Kinderwater J, Poola S, Udom J, Lambert K, Mian M, Ali E
- 5860 Development and validation of a prognostic nomogram for colorectal cancer after surgery
Li BW, Ma XY, Lai S, Sun X, Sun MJ, Chang B

Observational Study

- 5873** Potential protein-phenotype correlation in three lipopolysaccharide-responsive beige-like anchor protein-deficient patients

Tang WJ, Hu WH, Huang Y, Wu BB, Peng XM, Zhai XW, Qian XW, Ye ZQ, Xia HJ, Wu J, Shi JR

- 5889** Quantification analysis of pleural line movement for the diagnosis of pneumothorax

Xiao R, Shao Q, Zhao N, Liu F, Qian KJ

Prospective Study

- 5900** Preprocedure ultrasound imaging combined with palpation technique in epidural labor analgesia

Wu JP, Tang YZ, He LL, Zhao WX, An JX, Ni JX

Randomized Controlled Trial

- 5909** Effects of perioperative rosuvastatin on postoperative delirium in elderly patients: A randomized, double-blind, and placebo-controlled trial

Xu XQ, Luo JZ, Li XY, Tang HQ, Lu WH

SYSTEMATIC REVIEWS

- 5921** Pain assessment and management in the newborn: A systematized review

Garcia-Rodriguez MT, Bujan-Bravo S, Seijo-Bestilleiro R, Gonzalez-Martin C

META-ANALYSIS

- 5932** Fatigue prevalence in men treated for prostate cancer: A systematic review and meta-analysis

Luo YH, Yang YW, Wu CF, Wang C, Li WJ, Zhang HC

CASE REPORT

- 5943** Diagnostic discrepancy between colposcopy and vaginoscopy: A case report

Li Q, Zhang HW, Sui L, Hua KQ

- 5948** Contrast enhanced ultrasound in diagnosing liver lesion that spontaneously disappeared: A case report

Wang ZD, Haitham S, Gong JP, Pen ZL

- 5955** COVID-19 patient with an incubation period of 27 d: A case report

Du X, Gao Y, Kang K, Chong Y, Zhang ML, Yang W, Wang CS, Meng XL, Fei DS, Dai QQ, Zhao MY

- 5963** Awake extracorporeal membrane oxygenation support for a critically ill COVID-19 patient: A case report

Zhang JC, Li T

- 5972** Meigs syndrome with pleural effusion as initial manifestation: A case report

Hou YY, Peng L, Zhou M

- 5980** Giant hemangioma of the caudate lobe of the liver with surgical treatment: A case report

Wang XX, Dong BL, Wu B, Chen SY, He Y, Yang XJ

- 5988** Anti-programmed cell death ligand 1-based immunotherapy in recurrent hepatocellular carcinoma with inferior vena cava tumor thrombus and metastasis: Three case reports
Liu SR, Yan Q, Lin HM, Shi GZ, Cao Y, Zeng H, Liu C, Zhang R
- 5999** Minimal deviation adenocarcinoma with elevated CA19-9: A case report
Dong Y, Lv Y, Guo J, Sun L
- 6005** Isolated fungus ball in a single cell of the left ethmoid roof: A case report
Zhou LQ, Li M, Li YQ, Wang YJ
- 6009** Rare case of brucellosis misdiagnosed as prostate carcinoma with lumbar vertebra metastasis: A case report
Yan JF, Zhou HY, Luo SF, Wang X, Yu JD
- 6017** Myeloid sarcoma of the colon as initial presentation in acute promyelocytic leukemia: A case report and review of the literature
Wang L, Cai DL, Lin N
- 6026** Primary follicular lymphoma in the renal pelvis: A rare case report
Shen XZ, Lin C, Liu F
- 6032** Rosai-Dorfman disease in the spleen of a pediatric patient: A case report
Ryu H, Hwang JY, Kim YW, Kim TU, Jang JY, Park SE, Yang EJ, Shin DH
- 6041** Relapsed/refractory classical Hodgkin lymphoma effectively treated with low-dose decitabine plus tislelizumab: A case report
Ding XS, Mi L, Song YQ, Liu WP, Yu H, Lin NJ, Zhu J
- 6049** Disseminated *Fusarium* bloodstream infection in a child with acute myeloid leukemia: A case report
Ning JJ, Li XM, Li SQ
- 6056** Familial hemophagocytic lymphohistiocytosis type 2 in a female Chinese neonate: A case report and review of the literature
Bi SH, Jiang LL, Dai LY, Wang LL, Liu GH, Teng RJ
- 6067** Usefulness of metagenomic next-generation sequencing in adenovirus 7-induced acute respiratory distress syndrome: A case report
Zhang XJ, Zheng JY, Li X, Liang YJ, Zhang ZD
- 6073** Neurogenic orthostatic hypotension with Parkinson's disease as a cause of syncope: A case report
Li Y, Wang M, Liu XL, Ren YF, Zhang WB
- 6081** SATB2-associated syndrome caused by a novel SATB2 mutation in a Chinese boy: A case report and literature review
Zhu YY, Sun GL, Yang ZL
- 6091** Diagnosis and treatment discussion of congenital factor VII deficiency in pregnancy: A case report
Yang Y, Zeng YC, Rumende P, Wang CG, Chen Y

- 6102** Unusual immunohistochemical “null” pattern of four mismatch repair proteins in gastric cancer: A case report
Yue M, Liu JY, Liu YP
- 6110** Generalized periodontitis treated with periodontal, orthodontic, and prosthodontic therapy: A case report
Kaku M, Matsuda S, Kubo T, Shimoe S, Tsuga K, Kurihara H, Tanimoto K
- 6125** Ligamentum flavum hematoma following a traffic accident: A case report
Yu D, Lee W, Chang MC
- 6130** Oral cyclophosphamide-induced posterior reversible encephalopathy syndrome in a patient with ANCA-associated vasculitis: A case report
Kim Y, Kwak J, Jung S, Lee S, Jang HN, Cho HS, Chang SH, Kim HJ
- 6138** Encapsulating peritoneal sclerosis in an AMA-M2 positive patient: A case report
Yin MY, Qian LJ, Xi LT, Yu YX, Shi YQ, Liu L, Xu CF
- 6145** Multidisciplinary diagnostic dilemma in differentiating Madelung’s disease – the value of superb microvascular imaging technique: A case report
Seskute G, Dapkute A, Kausaite D, Strainiene S, Talijunas A, Butrimiene I
- 6155** Complicated course of biliary inflammatory myofibroblastic tumor mimicking hilar cholangiocarcinoma: A case report and literature review
Strainiene S, Sedleckaite K, Jarasunas J, Savlan I, Stanaitis J, Stundiene I, Strainys T, Liakina V, Valantinas J
- 6170** Fruquintinib beneficial in elderly patient with neoplastic pericardial effusion from rectal cancer: A case report
Zhang Y, Zou JY, Xu YY, He JN

ABOUT COVER

Editorial Board Member of *World Journal of Clinical Cases*, Jae Gil Lee, MD, PhD, Professor, Surgeon, Department of Surgery, Yonsei University College of Medicine, Seoul 03722, South Korea. jakii@yuhs.ac

AIMS AND SCOPE

The primary aim of *World Journal of Clinical Cases* (WJCC, *World J Clin Cases*) is to provide scholars and readers from various fields of clinical medicine with a platform to publish high-quality clinical research articles and communicate their research findings online.

WJCC mainly publishes articles reporting research results and findings obtained in the field of clinical medicine and covering a wide range of topics, including case control studies, retrospective cohort studies, retrospective studies, clinical trials studies, observational studies, prospective studies, randomized controlled trials, randomized clinical trials, systematic reviews, meta-analysis, and case reports.

INDEXING/ABSTRACTING

The WJCC is now indexed in Science Citation Index Expanded (also known as SciSearch®), Journal Citation Reports/Science Edition, Scopus, PubMed, and PubMed Central. The 2021 Edition of Journal Citation Reports® cites the 2020 impact factor (IF) for WJCC as 1.337; IF without journal self cites: 1.301; 5-year IF: 1.742; Journal Citation Indicator: 0.33; Ranking: 119 among 169 journals in medicine, general and internal; and Quartile category: Q3. The WJCC's CiteScore for 2020 is 0.8 and Scopus CiteScore rank 2020: General Medicine is 493/793.

RESPONSIBLE EDITORS FOR THIS ISSUE

Production Editor: Ji-Hong Lin; Production Department Director: Xiang Li; Editorial Office Director: Jin-Lai Wang.

NAME OF JOURNAL

World Journal of Clinical Cases

ISSN

ISSN 2307-8960 (online)

LAUNCH DATE

April 16, 2013

FREQUENCY

Thrice Monthly

EDITORS-IN-CHIEF

Dennis A Bloomfield, Sandro Vento, Bao-Gan Peng

EDITORIAL BOARD MEMBERS

<https://www.wjgnet.com/2307-8960/editorialboard.htm>

PUBLICATION DATE

July 26, 2021

COPYRIGHT

© 2021 Baishideng Publishing Group Inc

INSTRUCTIONS TO AUTHORS

<https://www.wjgnet.com/bpg/gerinfo/204>

GUIDELINES FOR ETHICS DOCUMENTS

<https://www.wjgnet.com/bpg/GerInfo/287>

GUIDELINES FOR NON-NATIVE SPEAKERS OF ENGLISH

<https://www.wjgnet.com/bpg/gerinfo/240>

PUBLICATION ETHICS

<https://www.wjgnet.com/bpg/GerInfo/288>

PUBLICATION MISCONDUCT

<https://www.wjgnet.com/bpg/gerinfo/208>

ARTICLE PROCESSING CHARGE

<https://www.wjgnet.com/bpg/gerinfo/242>

STEPS FOR SUBMITTING MANUSCRIPTS

<https://www.wjgnet.com/bpg/GerInfo/239>

ONLINE SUBMISSION

<https://www.f6publishing.com>



Research status on immunotherapy trials of gastric cancer

Chao Liang, Heng-Miao Wu, Wei-Ming Yu, Wei Chen

ORCID number: Chao Liang 0000-0003-0613-1805; Heng-Miao Wu 0000-0002-8670-5727; Wei-Ming Yu 0000-0002-8925-0078; Wei Chen 0000-0002-1919-5994.

Author contributions: Liang C and Wu HM drafted the manuscript; Yu WM and Chen W collected the data and revised the manuscript.

Supported by National Natural Science Funds of Young Scientists of China, No. 81802944; Zhejiang Provincial Public Welfare Technology Application Research Project, No. LGF18H160007; Program of Ningbo Medical Research Center for Digestive System Cancer, No. 2019A21003; Zhejiang Provincial Natural Science Foundation, No. LR20H160001; Zhejiang Provincial Ten Thousand Plan for Young Top Talents to Wei Chen (2018); Training Objects of Health Innovative Talents of Zhejiang Health to Wei Chen (2018); Key Project Co-constructed by Zhejiang Province and Ministry, No. WKJ-ZJ-1916; National Natural Science Foundation of China, No. 81972693, No. 81802383, No. 81972674, No. 81673809, and No. 31900543; Zhejiang Provincial Traditional Chinese Medicine Science and Technology Project, No. 2020ZZ004; and Projects of Lishui Key Research and Development Plan in Zhejiang Province, No. 2017ZDYF12.

Chao Liang, Wei-Ming Yu, Department of General Surgery, Ningbo Medical Center Lihuili Hospital, Ningbo 315040, Zhejiang Province, China

Heng-Miao Wu, Ningbo Medical Center Lihuili Hospital, Ningbo University, Ningbo 315040, Zhejiang Province, China

Wei Chen, Cancer Institute of Integrated Traditional Chinese and Western Medicine, Zhejiang Academy of Traditional Chinese Medicine, Tongde Hospital of Zhejiang Province, Hangzhou 310012, Zhejiang Province, China

Corresponding author: Wei Chen, MD, PhD, Doctor, Professor, Surgeon, Cancer Institute of Integrated Traditional Chinese and Western Medicine, Zhejiang Academy of Traditional Chinese Medicine, Tongde Hospital of Zhejiang Province, No. 234 Gucui Road, Hangzhou 310012, Zhejiang Province, China. viogro@163.com

Abstract

The breakthrough of immune checkpoint inhibitor (ICI) therapy has created extensive opportunities for cancer immunotherapy. Especially, the block of programmed death-1/programmed death ligand 1 (PD-L1) axis using ICIs has become a new therapeutic strategy to treat advanced gastric cancer (GC). However, in the past decade, single-arm and randomized trials for single-drug ICI therapy showed that the therapeutic effect was not satisfactory, including clinical trials for advanced GC. However, after selecting suitable predictive biomarkers and developing a combination of anti-angiogenic targeted drugs and other chemotherapeutic drugs, the objective response rate and progression-free survival of patients with gastric cancer were improved significantly. The United States Food and Drug Administration has approved treatment with pembrolizumab for patients with advanced GC with PD-L1 expression or microsatellite instability-high/mismatch repair deficiency. In this review, the updated data from the latest trial results of combination immunotherapy for GC are presented. Based on the outcome of combination therapy, we discuss its possible molecular mechanism and summarize effective predictive biomarkers. We also discuss possible problems stemming from results of other clinical trials of ICI treatment and propose other directions for ICI therapy.

Key Words: Gastric cancer; Immunotherapy; Clinical trial; Immune checkpoint inhibitor; Neoadjuvant therapy

©The Author(s) 2021. Published by Baishideng Publishing Group Inc. All rights reserved.

Conflict-of-interest statement: The authors have no conflict of interest to declare.

Open-Access: This article is an open-access article that was selected by an in-house editor and fully peer-reviewed by external reviewers. It is distributed in accordance with the Creative Commons Attribution NonCommercial (CC BY-NC 4.0) license, which permits others to distribute, remix, adapt, build upon this work non-commercially, and license their derivative works on different terms, provided the original work is properly cited and the use is non-commercial. See: <http://creativecommons.org/licenses/by-nc/4.0/>

Manuscript source: Unsolicited manuscript

Specialty type: Medicine, research and experimental

Country/Territory of origin: China

Peer-review report's scientific quality classification

Grade A (Excellent): 0
Grade B (Very good): B, B
Grade C (Good): 0
Grade D (Fair): 0
Grade E (Poor): 0

Received: February 10, 2021

Peer-review started: February 10, 2021

First decision: March 30, 2021

Revised: April 13, 2021

Accepted: May 25, 2021

Article in press: May 25, 2021

Published online: July 26, 2021

P-Reviewer: Mao X, Yao K

S-Editor: Fan JR

L-Editor: Wang TQ

P-Editor: Wang LYT



Core Tip: Immune checkpoint inhibitors gigantically expand the methods of immunotherapy and bring a glimmer of hopefulness for patients with advanced gastric cancer (GC). Ongoing clinical trials show that the effect of monotherapy was not satisfactory, while the combination therapy manifested a better response rate. The most recent clinical trial results of GC immunotherapy are reviewed to suggest the reasons and mechanisms of the high response rate. Additionally, we propose the potential problems of these trials and speculate on the benefits of immune checkpoint inhibitors in neoadjuvant therapy.

Citation: Liang C, Wu HM, Yu WM, Chen W. Research status on immunotherapy trials of gastric cancer. *World J Clin Cases* 2021; 9(21): 5782-5793

URL: <https://www.wjgnet.com/2307-8960/full/v9/i21/5782.htm>

DOI: <https://dx.doi.org/10.12998/wjcc.v9.i21.5782>

INTRODUCTION

Gastric cancer (GC) is the fifth most common malignancy diagnosed worldwide and the third dominant cause of death from cancer[1]. The mild symptoms of early GC and lack of awareness of physical examination mean that most patients with GC are diagnosed at advanced stages, frequently presenting infiltration or metastasis. Cytotoxic chemotherapy for advanced GC is a first-line standard of care, which comprises treatment with fluoropyrimidine plus a platinum agent, and the decision on whether to administer a combination comprising trastuzumab depends on the presence of human epidermal growth factor receptor 2 (HER2) gene expression; however, the 5-year survival rate remains poor[2-4].

According to medicine development for oncology in the past decade, immune checkpoint inhibitors (ICIs), such as an anti-cytotoxic T-lymphocyte antigen 4 (CTLA4) monoclonal antibody and anti-programmed death-1/programmed death ligand-1 (PD-1/PD-L1) monoclonal antibodies, represent a significant breakthrough[5,6]. Several studies have demonstrated that PD-L1 is constitutively expressed in various kinds of malignant tumors, including GC[7]. A meta-analysis by Chen *et al*[8] revealed that ICI treatment could enhance moderate survival benefits for patients with advanced gastric or gastroesophageal junction (G/GEJ) cancer. In particular, anti-PD-1/PD-L1 drugs could raise the 12-mo and 18-mo overall survival (OS) rates and manifested a long effective time of the therapeutic response[8]. Meanwhile, the patient's response showed that anti-PD-1/PD-L1 drugs are more efficacious in molecular subtypes that are PD-L1 positive, microsatellite instability (MSI)-high, or Epstein-Barr virus (EBV) positive, or those with a high mutation burden[8]. However, most patients with advanced GC are not sensitive to ICI monotherapies, according to the results of recent randomized trials[9-12], thus for patients with refractory advanced GC, it is critical to select the appropriate combination therapy to improve their responses to anti-PD-1 therapy or other ICIs[13]. Consequently, the development of safe and effective ICI combination strategies and predictive biomarkers has become an urgent requirement to enhance their therapeutic effect in advanced GC.

In this review, the lately reported trials of combined immunotherapy for advanced GC are summarized, focusing on the combination strategies that have a better overall therapeutic effect, analyzing the possible molecules and their mechanisms of action, and exploring their use as predictive biomarkers. The shortcomings of other cancer types in clinical trials are discussed to indicate the potential problem of developing combined immunotherapy for GC. We also discuss whether ICI could be employed as a neoadjuvant therapy.

CURRENT CLINICAL TRIALS OF COMBINATION THERAPY WITH ICI FOR GC

Since the advent of ICI-related drugs, numerous clinical trials are being carried out worldwide. As of September 2018, there were a total of 2250 ongoing clinical trials, of which 1716 trials tested regimens that combined anti-PD1/PD-L1 drugs with other

cancer treatments[14]. In these trials, lung cancer (254 trials), melanoma (139 trials), breast cancer (106 trials), lymphoma (99 trials), and head and neck cancer (72 trials) were the most studied, while research on GC was relatively limited. In this section, we list the latest clinical trial research progress of ICI drugs for advanced GC in the past two years[9,10,15-18] (Table 1). Compared with the results of previous clinical trials of ICI monotherapy, these trials of ICI combinations showed better objective response rates (ORRs) and median progression free survival (PFS) commonly. In the open-label phase 2 trial EPOC1706, patients with advanced GC were given Lenvatinib (a multikinase inhibitor of vascular endothelial growth factor (VEGF) receptors and other receptor tyrosine kinases) plus pembrolizumab as anti-tumor therapy in the first-line or second-line settings[15]. This trial enrolled 29 patients with metastatic or recurrent adenocarcinoma of G/GEJ and measured disease using the Response Evaluation Criteria in Solid Tumors (RECIST) criteria. The primary endpoint of the trial was the ORR by RECIST. The results report showed that 20 [69%, 95% confidence interval (CI): 49-85] of 29 patients had an objective response at data cutoff. This indicated that Lenvatinib plus pembrolizumab has promising anti-tumor activity in patients with advanced GC.

Another non-randomized, multicenter, open-label phase IIb study, KEYNOTE-659, evaluated the efficacy and safety of pembrolizumab in combination with S-1 plus oxaliplatin (SOX) as first-line treatment in Japanese patients with G/GEJ cancer[16]. At data cutoff, 54 patients were evaluated and the median follow-up was 10.1 mo. The ORR and disease control rate by blinded independent central review were 72.2% (95% CI: 58.4-83.5) and 96.3% (95% CI: 87.3-99.5), respectively. Median duration of response, time to response, PFS, and OS were as follows: Not reached, 1.5 mo, 9.4 mo, and not reached. This result demonstrated encouraging efficacy for SOX plus pembrolizumab treatment of advanced G/GEJ cancer.

MOLECULAR MECHANISMS OF COMBINATION THERAPY WITH ICI FOR GC

The EPOC1706 trial of combination therapy trial of ICI and antivasculature targeted therapy indicated that the VEGF pathway can regulate the antitumor immune response to promote better efficacy of ICIs. Previous research proved that tumor-induced angiogenic factors, including VEGF, could stimulate tumor neovascularization and produce functional and structural abnormalities, leading to an increased intratumoral stress response and hindering of the infiltration of effector T cells[19,20]. Anti-tumor cytotoxic T lymphocytes (CTLs) fail to penetrate into the tumor microenvironment (including GC). Other factors, including downregulation of vascular endothelial cell adhesion molecule-1, prevent the migration of effector T cells into the tumor stroma[21]. In addition, the accumulation of myeloid-derived inhibitor cells further suppresses the anti-tumor response of effector T cells[22]. Preventing the maturation of effector T cells and dendritic cells also inhibits the function of CTLs[22]. Therefore, the normalization of tumor blood vessels after anti-VEGFR therapy can reduce the intratumoral pressure, restore anti-CTL infiltration, and enhance the anti-tumor effect of ICI[23,24]. In addition, several types of immunosuppressive cells, including regulatory T cells (Tregs) and tumor-associated macrophages (TAMs), are present in the tumor microenvironment of GC. Previous studies have reported that the activity of Tregs and TAMs depends in part on the VEGF/VEGF receptor (VEGFR) axis, and overexpression of VEGF promotes the recruitment, differentiation, and proliferation of Tregs in tumors[25]. Likewise, tumor-induced angiogenic factors or a hypoxic state can further enhance the function of Tregs and TAMs *via* the VEGF/VEGFR axis, resulting in downregulation of anti-tumor CTL activity[26]. These above-mentioned mechanisms provide a conceivable theoretical basis for the combined therapy of anti-vascular targeted drugs and ICIs (Figure 1). Kato *et al*[27] certified that the antivasculature targeted drug lenvatinib, *via* decreasing TAMs and enhancing the activation of the interferon (IFN) signaling pathway, upregulated the anti-tumor activity of PD-1 inhibitors *in vivo*[27].

In the past decade, researchers have explored the hypothesis that traditional chemotherapy drugs might interact with the immune mechanism. For instance, chemotherapy drugs such as cyclophosphamide, gemcitabine, platinum, and paclitaxel have been reported to improve the antigenicity of tumor cells by increasing the expression of major histocompatibility complex class I molecules[28,29] and enhancing the sensitivity of tumor cells to immune therapy by upregulation of the mannose-6-phosphate receptor (*e.g.*, paclitaxel, cisplatin, and doxorubicin)[30]. Vacchelli *et al*[31]

Table 1 Current clinical trial results of immune checkpoint inhibitors for gastric cancer

Ref.	Trial phase	Cancer type	n	Drug(s) tested	Key outcome	Trial name (NCT)
Kawazoe <i>et al</i> [15], 2020	2	GC	29	Pembrolizumab + lenvatinib	ORR 69% (95%CI: 49-85) mPFS 7.1 mo (95%CI: 5.4-13.7)	EPOC1706 (NCT03609359)
Kawazoe <i>et al</i> [16], 2020	2b	GC/GEJC	54	Pembrolizumab + SOX	ORR 72.2% (95%CI: 58.4-83.5) mPFS 6.9 mo (95%CI: 5.6-8.3)	KEYNOTE-659 (NCT03382600)
Catenacci <i>et al</i> [17], 2020	1b-2	GEJC	92	Margetuximab + pembrolizumab	ORR 18% (95%CI: 11-28) mPFS 2.73 mo	CP-MGAH22-05 (NCT02689284)
Bang <i>et al</i> [9], 2019	2	GC/GEJC	25	Pembrolizumab + SOC	ORR 60.0% (95%CI: 38.7-78.9) mPFS 6.6 mo (95%CI: 5.9-10.6)	KEYNOTE-059 (NCT02335411)
			31	Pembrolizumab	ORR 25.8% (95%CI: 11.9-44.6) mPFS 3.3 mo (95%CI: 2.0-6.0)	
Tabernero <i>et al</i> [10], 2019	3	GC/GEJC	256	Pembrolizumab	ORR 14.5% (95%CI: 10.4-19.4) mPFS 2.0 mo (95%CI: 1.5-2.8)	KEYNOTE-062 (NCT02494583)
			257	Pembrolizumab + SOC	ORR 48.6% (95%CI: 42.4-54.9) mPFS 6.9 mo (95%CI: 5.7-7.3)	
			250	Placebo + SOC	ORR 36.8% (95%CI: 30.8-43.1) mPFS 6.4 mo (95%CI: 5.7-7.0)	
Boku <i>et al</i> [18], 2019	2	G/GEJ	21	Nivolumab + SOX	ORR 57.1% (95%CI: 34.0-78.2) mPFS 9.7 mo (95%CI: 5.8-NR)	ATTRACTION-4 (NCT02746796)
			18	Nivolumab + CapeOX	ORR 76.5% (95%CI: 50.1-93.2) mPFS 10.6 mo (95%CI: 5.6-12.5)	

GC: Gastric cancer; GEJC: Gastroesophageal junction cancer; SOC: Standard of care; SOX: S-1 plus oxaliplatin; CapeOX: Capecitabine plus oxaliplatin; ORR: Objective response rate; mPFS: Median progression-free survival; CI: Confidence interval.

stated that chemotherapy drugs (paclitaxel, doxorubicin, and cisplatin) could activate the immune system *via* direct effects on cytotoxic lymphocytes and the elimination of immunosuppressive cells *via* clinical trial results of certain chemotherapy drugs (paclitaxel, gemcitabine, and 5Fu)[31]. Traditional chemotherapy drugs are able to enhance the patients' antitumor immune response, and ICIs could further eliminate tumor foci that are resistant to chemotherapy, correspondingly. Thus, the combination of ICI and chemotherapeutics for the treatment of advanced refractory tumors presents clinical benefits, and numerous clinical trials seem to have verified this hypothesis (KEYNOTE-659, KEYNOTE-059, and KEYNOTE-062).

Moreover, additional combination treatment options are worth exploring. The combined use of two ICI drug treatments, such as the combination of CTLA4 and PD-1/PD-L1 blocking antibodies, can kill T lymphocytes in the immune initial and effector stages[32]. For example, the Checkmate032 trial aims to assess the efficacy of the combination treatment of nivolumab (anti-PD-1 antibody) and ipilimumab (anti-CTLA4 antibody) in patients with advanced solid tumors, including advanced GC. As a result, the combined scheme of nivolumab (1 mg/kg) + ipilimumab (3 mg/kg) had a sustained antitumor effect in the treatment of advanced GC, thereby prolonging the OS[33,34]. In addition, radiotherapy is certified to cause immunogenic cell death and has a synergistic effect on anti-tumor CTLs[35]. This principle revealed the possibility of the combined application of radiotherapy and ICI, although there has been no corresponding clinical trial for GC at present. In a novel case report, a patient with HER2-negative advanced GC (stage IV, T4N3M1) received 4 mo of treatment with a combination of concurrent SOX regimen chemotherapy, radiotherapy, and ICI immunotherapy, which showed a satisfactory complete response for tumor lesions, even metastatic lesions (almost complete response, disappearance of all target lesions) [36]. This example demonstrated that the continuous exploration and advances of combined immunotherapy will improve the survival benefits of patients with GC significantly.

PREDICTIVE BIOMARKERS FROM CLINICAL TRIALS

The Cancer Genome Atlas has proposed a molecular classification dividing GC into four subtypes: EBV positive (9%), genomically stable (20%), MSI-high (22%), and

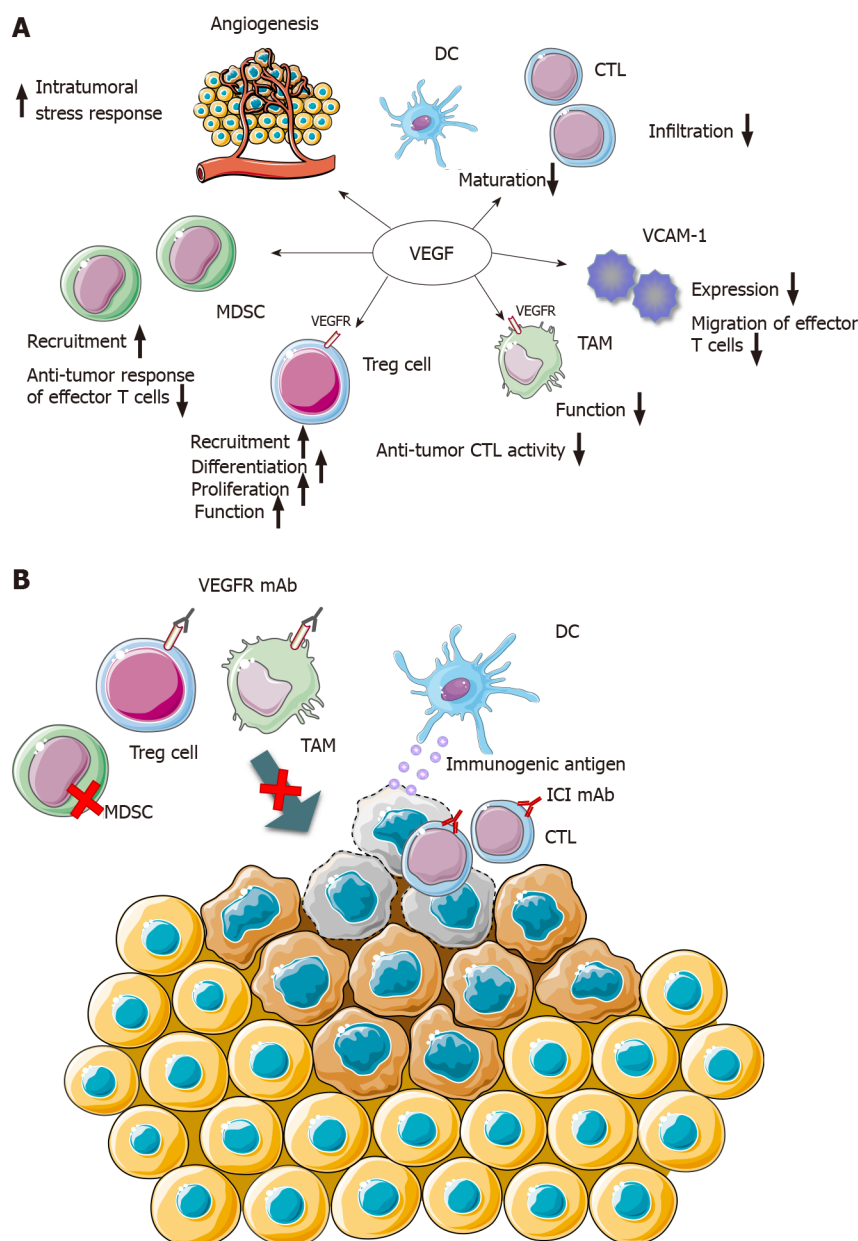


Figure 1 Combined action mechanism of vascular endothelial growth factor monoclonal antibody and immune checkpoint inhibitor monoclonal antibody. A: Impacting on immune-related mechanisms *via* vascular endothelial growth factor (VEGF); B: VEGF receptor (VEGFR) monoclonal antibody (mAb) arouses the normalization of tumor blood vessels, the down-regulation of immunosuppressive cells, and the activity and infiltration of cytotoxic T lymphocytes (CTL). Simultaneously, immune checkpoint inhibitor mAb restores the function of CTL to recognize tumor cells, thereby killing tumor cells and releasing immunogenic antigen. VEGF: Vascular endothelial growth factor; VEGFR: Vascular endothelial growth factor receptor; DC: Dendritic cells; CTL: Cytotoxic T lymphocytes; VCAM-1: Vascular endothelial cell adhesion molecule-1; MDSC: Myeloid-derived suppressor cells; TAM: Tumor-associated macrophages; Treg: Regulatory T; mAb: Monoclonal antibody; ICI: Immune checkpoint inhibitor. Figure 1 was produced with the assistance of Servier Medical Art (<https://smart.servier.com>), which provides free and open pictures.

chromosomal instability (50%)[37]. Among the four molecular subtypes of GC, EBV-positive tumors and MSI-high tumors show better responses to ICIs[38]. The Food and Drug Administration (FDA) has approved treatment with pembrolizumab for patients with PD-L1 positive and MSI-high/DNA mismatch repair deficiency (dMMR) advanced GC in the second- or third-line setting[39,40]. Accordingly, PD-L1 positive and MSI-high/dMMR advanced GC patients are currently the most widely applied for ICI therapy.

PD-L1 expression in tumor cells is determined by immunohistochemistry using formalin-fixed paraffin-embedded sections, and the proportion of PD-L1-stained tumor cells and immune cells is calculated to obtain a clinical prediction score (CPS). The result of KEYNOTE-059 trial shows that patients with PD-L1 positive tumors (CPS ≥ 1) achieved 22.7% ORR and 2.7% complete response *via* anti-PD-1 treatment, compared with 8.6% ORR and 3.4% complete response of patients with PD-L1

negative tumors (CPS < 1)[39]. Another randomized phase III trial, KEYNOTE-062 [10], enrolled 763 patients with HER2-negativity and CPS ≥ 1 . The results showed that 281 (37% of the enrollees) had a CPS score of ≥ 10 . The patients were divided into three groups by their treatment options as initial therapy: Intravenous pembrolizumab, pembrolizumab plus chemotherapy, or chemotherapy plus placebo. The primary endpoint of this trial showed that for patients with HER2-negative, PD-L1-positive (CPS ≥ 1), advanced GC, combination treatment with pembrolizumab plus chemotherapy resulted in a better ORR and PFS compared with traditional chemotherapy. In addition, pembrolizumab resulted in a clinically meaningful OS improvement for patients with high levels of PD-L1 expression (CPS ≥ 10).

Microsatellites are repetitive sequences of small DNA fragments that exist in the genome, and false microsatellites are produced and accumulated during replication, which is called MSI-high status. Mismatched DNA is frequently repaired by the mismatch repair system, and therefore MSI-high status is usually related to dMMR. Once MSI-high/dMMR status occurs in tumor cells, immune mechanism could handle hypermutation generation and the formation of immunogenic neoantigens. Consequently, numerous immune cells accumulate in tumors with MSI-high/dMMR characteristics, and ICIs are more effective for such tumors[41]. In the report of the phase II KEYNOTE-059 trial, the ORR of ICI therapy of advanced GC patients in the MSI high group was significantly higher than that of the non-MSI high group (57.1% *vs* 9.0%). Meanwhile, the authors of KEYNOTE-062 trial presented a directional analysis of 50 patients with MSI-high tumors, indicating that the ORRs of patients treated with pembrolizumab monotherapy and chemotherapy were 57.1% and 36.8%, respectively, and those of patients treated with pembrolizumab plus chemotherapy *vs* chemotherapy was 64.7% *vs* 36.8%[10].

Furthermore, high tumor mutational burden (TMB), EBVpositivity, immune-related gene expression, *IFNG* (IFN- γ) gene activation, and circulating tumor DNA (ctDNA) have been explored as other biomarkers to predict the clinical endpoints of immunotherapy using ICIs[42,43]. TMB represents the total number of mutations in each coding region of a tumor genome, and it has been found that ICI-treated patients with high TMB exhibit a considerable ORR and PFS in multiple cancers[42]. Derks *et al*[38] showed that tumor or tumor infiltrating immune cells with PD-L1 expression are also a general phenomenon in EBV-positive GC, as well as enrichment of an *IFNG* gene expression signature[38]. Interestingly, in the KEYNOTE-059 trial, Fuchs *et al*[39] reported that six patients with EBV-positive tumors achieved a partial or complete remission using pembrolizumab treatment[39], suggesting that EBV-positive tumors show an effective response to ICI treatment. In the same report, the expression profile of 18 immune-related genes [*CCL5*, *CD27*, *CD274* (PD-L1), *CD276* (B7-H3), *CD8A*, *CXCL9*, *CMKLR1*, *CXCR6*, *HLADQA1*, *HLA-DRB1*, *HLAE*, *NKG7*, *IDO1*, *LAG3*, *PDCD1* -*KLG2* (PD-L2), *PSMB10*, *STAT1*, and *TGIT*] illustrated that the statistical score of responders among patients with GC was significantly higher than that of non-responders. Similarly, six IFN- γ -related gene signatures were remarkably associated with the improvement of PFS in ICI-treated patients with GC[43]. Thus, the proposed association with IFN- γ signal transduction and T cell activation of immune-related gene biological signatures, can be used as a biomarker to predict the efficacy of ICI treatment. ctDNA is released into the circulatory system from apoptotic or necrotic tumor cells, and could be used for early diagnosis of some cancers. Moreover, ctDNA mutational burden score is related to the clinical response of patients with GC to pembrolizumab treatment, indicating that ctDNA can be used to screen those patients with GC that are sensitive to ICI treatment[44].

CONSIDERATION OF IMMUNE COMBINATION TRIALS IN OTHER CANCER TYPES

To explore the best schemes of immune combination treatments, it is essential to determine the best endpoints in early phase clinical trials to better opt the correct schemes for confirmatory randomized trials[45]. The development and ratification of single-agent ICIs depended largely on the FDA accelerated approval, and ORR is typically adopted as the primary endpoint in the ICI clinical trials leading to accelerated approval[46]. Table 1 lists these clinical trials that employed ORR as the primary endpoint, and the use of the ORR seemed to prove the excellent effect of ICI treatment. However, traditional clinical trial endpoints, like ORR and PFS, might not be able to predict the long-term survival of patients receiving ICI treatments because the mechanisms of action and reaction patterns for ICI agents differ substantially from

those of conventional chemotherapy. Equally, conventional RECIST criteria might underestimate the benefit from ICI agents[47,48]. For instance, pseudoprogression was initially described in advanced melanoma treated with ipilimumab and was incapable of being assessed by the conventional RECIST criteria[49,50]. Chiou *et al*[50] reported that ORR is correlated insufficiently with PFS and OS in the single-arm and randomized trials of ICI treatment (the *r* correlation coefficients of ORR with 6-mo PFS and 12-mo OS were 0.37 and 0.08, respectively). By contrast, a conspicuous correlation between 6-mo PFS and 12-mo OS was discovered (the *r* correlation coefficient was 0.74)[51]. Thus, in single-arm trials, ICI efficacy analysis by selecting the PFS rate at particular time points (*e.g.*, 6 or 12 mo) might be considered as a better surrogate endpoint than ORR, thereby also improving the evaluation criteria of solid tumors under ICI treatment.

ICI-related trials with multiple primary endpoints require rigorous methods to control the overall type I error rate, yet the generally recognized clinical benefits of ICI therapy in patients with advanced cancer might not be "statistically significant"[46], as demonstrated by the IMvigor211 trial of atezolizumab for the treatment of urothelial carcinoma and the KEYNOTE-240 trial of pembrolizumab for the treatment of advanced hepatocellular carcinoma[52,53]. The demand for volunteers has greatly increased with the development of more and more clinical trials, especially in past few years, and ICI trials have been recruiting patients faster than other interventional oncology trials. However, the recruitment rate has recently declined significantly, from 1.15 patients per site every month in 2014 to 0.35 patients per site every month in 2018, indicating that combination trials may face recruitment challenges in the near future [14]. Furthermore, the low recruitment rate not only affects the progress of clinical trials, but also incurs greater costs. Formulating innovative, efficient, and rational trial schemes to allocate patient volunteers reasonably is required.

PROSPECTS OF ICIS FOR NEOADJUVANT TREATMENT OF GC

Neoadjuvant chemotherapy with FLOT (5-FU, leucovorin, oxaliplatin, and docetaxel) regimen is the standard treatment in the West. In contrast, SOX regimen is the preferred neoadjuvant chemotherapy regimen in the East. The phase II randomized clinical trial NCT03636893 reported 74 patients with locally advanced resectable GC, and the primary outcomes did not show statistically significant differences between neoadjuvant FLOT and SOX regimens[54]. The FLOT and SOX groups showed desired therapeutic effect, yet several hematological grade 3–4 adverse events were observed (29.0% and 16.1%, respectively). It is necessary to explore more treatment methods to expand the scope of medication, and to design the best combined treatment plan for patients to maximize anti-tumor effects and reduce adverse events.

The neoadjuvant treatment of ICI is applied presurgically, playing a pivotal role in radical treatment for tumors, such as anti-CTLA-4 treatment for bladder cancer and melanoma[55,56]. Mechanistically, compared with adjuvant therapy directed only against micrometastatic foci after resection, neoadjuvant ICI makes full use of higher tumor antigen load *in vivo* before surgery, resulting in more tumor-specific T cells being present in the systemic circulation[57]. Anti-PD-L1/anti-PD-1 monoclonal antibody restores the activity of tumor-specific cytotoxic T cells that already exist in the tumor microenvironment and promotes their activation, proliferation, and transfer to micrometastases. Afterwards, the focus of anti-PD-(L)1 activity might be in the tumor draining lymph nodes, where dendritic cells present tumor antigens to T cells, and then these tumor-specific T cells enter the bloodstream and migrate to the tumor sites[57,58]. The aforementioned hypothetical mechanism was verified in a spontaneously metastatic transplantable mouse breast cancer model, showing that survival after neoadjuvant immunotherapy was significantly better than that after adjuvant immunotherapy[59]. Topalian *et al*[57] proposed several potential clinical advantages of neoadjuvant therapy, including preoperative tumor shrinkage and the capability to assess the pathological response as an early surrogate indicator for relapse-free survival and OS, offering sufficient tissue availability therapies for in-depth scientific research to explore mechanism of drug action and predictive biomarkers[57]. Currently, clinical trials of neoadjuvant immunotherapy based on ICIs have started, such as the first trial report of neoadjuvant anti-PD-1 therapy, which is a phase II trial of nivolumab in 21 patients with high-risk (stage I, II, or IIIA) non-small-cell lung cancer, which has indicated that 45% of resected tumors have a major pathological response[60]. However, few clinical trials have been carried out on the application of ICI as neoadjuvant treatment in GC, and only one clinical trial (NCT03064490) is

registered in ClinicalTrials.gov. Jin *et al*[61] submitted a notable case report, in which a patient with PD-L1 positive and MSI-high advanced GC (cT4aN+M0 state) received a single dose of anti-PD-1 therapy in combination with chemotherapy and radical gastrectomy, resulting in a pathological complete response (pT0N0M0)[61]. This case report suggested that a combined ICI scheme might be feasible as neoadjuvant treatment of GC.

CONCLUSION

Through the continuous exploration of clinical trials, the combined scheme of immunotherapy for GC is being implemented. Based on previous feedback, identifying the most valuable predictive biomarkers and trial schemes to promote the further development of clinical trials is required. In terms of prolonging the survival of patients with GC, ICI might possess merit as a neoadjuvant treatment.

REFERENCES

- 1 **Ferlay J**, Soerjomataram I, Dikshit R, Eser S, Mathers C, Rebelo M, Parkin DM, Forman D, Bray F. Cancer incidence and mortality worldwide: sources, methods and major patterns in GLOBOCAN 2012. *Int J Cancer* 2015; **136**: E359-E386 [PMID: [25220842](#) DOI: [10.1002/ijc.29210](#)]
- 2 **Smyth EC**, Verheij M, Allum W, Cunningham D, Cervantes A, Arnold D; ESMO Guidelines Committee. Gastric cancer: ESMO Clinical Practice Guidelines for diagnosis, treatment and follow-up. *Ann Oncol* 2016; **27**: v38-v49 [PMID: [27664260](#) DOI: [10.1093/annonc/mdw350](#)]
- 3 **Bang YJ**, Van Cutsem E, Feyereislova A, Chung HC, Shen L, Sawaki A, Lordick F, Ohtsu A, Omuro Y, Satoh T, Aprile G, Kulikov E, Hill J, Lehle M, Rüschoff J, Kang YK; ToGA Trial Investigators. Trastuzumab in combination with chemotherapy versus chemotherapy alone for treatment of HER2-positive advanced gastric or gastro-oesophageal junction cancer (ToGA): a phase 3, open-label, randomised controlled trial. *Lancet* 2010; **376**: 687-697 [PMID: [20728210](#) DOI: [10.1016/S0140-6736\(10\)61121-X](#)]
- 4 **Japanese Gastric Cancer Association**. Japanese gastric cancer treatment guidelines 2014 (ver. 4). *Gastric Cancer* 2017; **20**: 1-19 [PMID: [27342689](#) DOI: [10.1007/s10120-016-0622-4](#)]
- 5 **Sharma P**, Allison JP. Immune checkpoint targeting in cancer therapy: toward combination strategies with curative potential. *Cell* 2015; **161**: 205-214 [PMID: [25860605](#) DOI: [10.1016/j.cell.2015.03.030](#)]
- 6 **Sharma P**, Allison JP. The future of immune checkpoint therapy. *Science* 2015; **348**: 56-61 [PMID: [25838373](#) DOI: [10.1126/science.aaa8172](#)]
- 7 **Sznol M**, Chen L. Antagonist antibodies to PD-1 and B7-H1 (PD-L1) in the treatment of advanced human cancer--response. *Clin Cancer Res* 2013; **19**: 5542 [PMID: [24048329](#) DOI: [10.1158/1078-0432.CCR-13-2234](#)]
- 8 **Chen C**, Zhang F, Zhou N, Gu YM, Zhang YT, He YD, Wang L, Yang LX, Zhao Y, Li YM. Efficacy and safety of immune checkpoint inhibitors in advanced gastric or gastroesophageal junction cancer: a systematic review and meta-analysis. *Oncoimmunology* 2019; **8**: e1581547 [PMID: [31069144](#) DOI: [10.1080/2162402X.2019.1581547](#)]
- 9 **Bang YJ**, Kang YK, Catenacci DV, Muro K, Fuchs CS, Geva R, Hara H, Golan T, Garrido M, Jalal SI, Borg C, Doi T, Yoon HH, Savage MJ, Wang J, Dalal RP, Shah S, Wainberg ZA, Chung HC. Pembrolizumab alone or in combination with chemotherapy as first-line therapy for patients with advanced gastric or gastroesophageal junction adenocarcinoma: results from the phase II nonrandomized KEYNOTE-059 study. *Gastric Cancer* 2019; **22**: 828-837 [PMID: [30911859](#) DOI: [10.1007/s10120-018-00909-5](#)]
- 10 **Tabernero J**, Van Cutsem E, Bang YJ, Fuchs CS, Wyrwicz L, Lee KW, Kudaba I, Garrido M, Chung HC, Salguero HRC, Mansoor W, Braghiroli M, Goekkurt E, Chao J, Wainberg ZA, Kher U, Shah S, Kang SP, Shitara K. Pembrolizumab with or without chemotherapy vs chemotherapy for advanced gastric or gastroesophageal junction (G/GEJ) adenocarcinoma: The phase III KEYNOTE-062 study. *J Clin Oncol* 2019; **37**: 2 [DOI: [10.1200/JCO.2019.37.18_suppl.LBA4007](#)]
- 11 **Satoh T**, Kang YK, Chao Y, Ryu MH, Kato K, Cheol Chung H, Chen JS, Muro K, Ki Kang W, Yeh KH, Yoshikawa T, Oh SC, Bai LY, Tamura T, Lee KW, Hamamoto Y, Kim JG, Chin K, Oh DY, Minashi K, Cho JY, Tsuda M, Tanimoto M, Chen LT, Boku N. Exploratory subgroup analysis of patients with prior trastuzumab use in the ATTRACTION-2 trial: a randomized phase III clinical trial investigating the efficacy and safety of nivolumab in patients with advanced gastric/gastroesophageal junction cancer. *Gastric Cancer* 2020; **23**: 143-153 [PMID: [31087200](#) DOI: [10.1007/s10120-019-00970-8](#)]
- 12 **Shitara K**, Özgüroğlu M, Bang YJ, Di Bartolomeo M, Mandalà M, Ryu MH, Fornaro L, Olesiński T, Caglevic C, Chung HC, Muro K, Goekkurt E, Mansoor W, McDermott RS, Shacham-Shmueli E, Chen X, Mayo C, Kang SP, Ohtsu A, Fuchs CS; KEYNOTE-061 investigators. Pembrolizumab versus paclitaxel for previously treated, advanced gastric or gastro-oesophageal junction cancer (KEYNOTE-061): a randomised, open-label, controlled, phase 3 trial. *Lancet* 2018; **392**: 123-133

- [PMID: 29880231 DOI: 10.1016/S0140-6736(18)31257-1]
- 13 **Smyth EC**, Nilsson M, Grabsch HI, van Grieken NCT, Lordick F. Gastric cancer. *The Lancet* 2020; **396**: 635-648 [DOI: 10.1016/s0140-6736(20)31288-5]
 - 14 **Tang J**, Yu JX, Hubbard-Lucey VM, Neftelinov ST, Hodge JP, Lin Y. Trial watch: The clinical trial landscape for PD1/PDL1 immune checkpoint inhibitors. *Nat Rev Drug Discov* 2018; **17**: 854-855 [PMID: 30482962 DOI: 10.1038/nrd.2018.210]
 - 15 **Kawazoe A**, Fukuoka S, Nakamura Y, Kuboki Y, Wakabayashi M, Nomura S, Mikamoto Y, Shima H, Fujishiro N, Higuchi T, Sato A, Kuwata T, Shitara K. Lenvatinib plus pembrolizumab in patients with advanced gastric cancer in the first-line or second-line setting (EPOC1706): an open-label, single-arm, phase 2 trial. *Lancet Oncol* 2020; **21**: 1057-1065 [PMID: 32589866 DOI: 10.1016/S1470-2045(20)30271-0]
 - 16 **Kawazoe A**, Yamaguchi K, Yasui H, Negoro Y, Azuma M, Amagai K, Hara H, Baba H, Tsuda M, Hosaka H, Kawakami H, Oshima T, Omuro Y, Machida N, Esaki T, Yoshida K, Nishina T, Komatsu Y, Han SR, Shiratori S, Shitara K. Safety and efficacy of pembrolizumab in combination with S-1 plus oxaliplatin as a first-line treatment in patients with advanced gastric/gastroesophageal junction cancer: Cohort 1 data from the KEYNOTE-659 phase IIb study. *Eur J Cancer* 2020; **129**: 97-106 [PMID: 32145474 DOI: 10.1016/j.ejca.2020.02.002]
 - 17 **Catenacci DVT**, Kang YK, Park H, Uronis HE, Lee KW, Ng MCH, Enzinger PC, Park SH, Gold PJ, Lacy J, Hochster HS, Oh SC, Kim YH, Marrone KA, Kelly RJ, Juergens RA, Kim JG, Bendell JC, Alcindor T, Sym SJ, Song EK, Chee CE, Chao Y, Kim S, Lockhart AC, Knutson KL, Yen J, Franovic A, Nordstrom JL, Li D, Wigginton J, Davidson-Moncada JK, Rosales MK, Bang YJ; CP-MGAH22-5 Study Group. Margetuximab plus pembrolizumab in patients with previously treated, HER2-positive gastro-oesophageal adenocarcinoma (CP-MGAH22-05): a single-arm, phase 1b-2 trial. *Lancet Oncol* 2020; **21**: 1066-1076 [PMID: 32653053 DOI: 10.1016/S1470-2045(20)30326-0]
 - 18 **Boku N**, Ryu MH, Kato K, Chung HC, Minashi K, Lee KW, Cho H, Kang WK, Komatsu Y, Tsuda M, Yamaguchi K, Hara H, Fumita S, Azuma M, Chen LT, Kang YK. Safety and efficacy of nivolumab in combination with S-1/capecitabine plus oxaliplatin in patients with previously untreated, unresectable, advanced, or recurrent gastric/gastroesophageal junction cancer: interim results of a randomized, phase II trial (ATTRACTION-4). *Ann Oncol* 2019; **30**: 250-258 [PMID: 30566590 DOI: 10.1093/annonc/mdy540]
 - 19 **Shrimali RK**, Yu Z, Theoret MR, Chinnasamy D, Restifo NP, Rosenberg SA. Antiangiogenic agents can increase lymphocyte infiltration into tumor and enhance the effectiveness of adoptive immunotherapy of cancer. *Cancer Res* 2010; **70**: 6171-6180 [PMID: 20631075 DOI: 10.1158/0008-5472.CAN-10-0153]
 - 20 **Wallin JJ**, Bendell JC, Funke R, Szoln M, Korski K, Jones S, Hernandez G, Mier J, He X, Hodi FS, Denker M, Leveque V, Cañamero M, Babitski G, Koeppen H, Ziai J, Sharma N, Gaire F, Chen DS, Waterkamp D, Hegde PS, McDermott DF. Atezolizumab in combination with bevacizumab enhances antigen-specific T-cell migration in metastatic renal cell carcinoma. *Nat Commun* 2016; **7**: 12624 [PMID: 27571927 DOI: 10.1038/ncomms12624]
 - 21 **Ott PA**, Hodi FS, Buchbinder EI. Inhibition of Immune Checkpoints and Vascular Endothelial Growth Factor as Combination Therapy for Metastatic Melanoma: An Overview of Rationale, Preclinical Evidence, and Initial Clinical Data. *Front Oncol* 2015; **5**: 202 [PMID: 26442214 DOI: 10.3389/fonc.2015.00202]
 - 22 **Gabrilovich D**, Ishida T, Oyama T, Ran S, Kravtsov V, Nadaf S, Carbone DP. Vascular endothelial growth factor inhibits the development of dendritic cells and dramatically affects the differentiation of multiple hematopoietic lineages in vivo. *Blood* 1998; **92**: 4150-4166 [PMID: 9834220]
 - 23 **Jain RK**. Normalization of tumor vasculature: an emerging concept in antiangiogenic therapy. *Science* 2005; **307**: 58-62 [PMID: 15637262 DOI: 10.1126/science.1104819]
 - 24 **Khan KA**, Kerbel RS. Improving immunotherapy outcomes with anti-angiogenic treatments and vice versa. *Nat Rev Clin Oncol* 2018; **15**: 310-324 [PMID: 29434333 DOI: 10.1038/nrclinonc.2018.9]
 - 25 **Terme M**, Pernot S, Marcheteau E, Sandoval F, Benhamouda N, Colussi O, Dubreuil O, Carpentier AF, Tartour E, Taieb J. VEGFA-VEGFR pathway blockade inhibits tumor-induced regulatory T-cell proliferation in colorectal cancer. *Cancer Res* 2013; **73**: 539-549 [PMID: 23108136 DOI: 10.1158/0008-5472.CAN-12-2325]
 - 26 **Tada Y**, Togashi Y, Kotani D, Kuwata T, Sato E, Kawazoe A, Doi T, Wada H, Nishikawa H, Shitara K. Targeting VEGFR2 with Ramucirumab strongly impacts effector/activated regulatory T cells and CD8⁺ T cells in the tumor microenvironment. *J Immunother Cancer* 2018; **6**: 106 [PMID: 30314524 DOI: 10.1186/s40425-018-0403-1]
 - 27 **Kato Y**, Tabata K, Kimura T, Yachie-Kinoshita A, Ozawa Y, Yamada K, Ito J, Tachino S, Hori Y, Matsuki M, Matsuoka Y, Ghosh S, Kitano H, Nomoto K, Matsui J, Funahashi Y. Lenvatinib plus anti-PD-1 antibody combination treatment activates CD8⁺ T cells through reduction of tumor-associated macrophage and activation of the interferon pathway. *PLoS One* 2019; **14**: e0212513 [PMID: 30811474 DOI: 10.1371/journal.pone.0212513]
 - 28 **Zitvogel L**, Galluzzi L, Smyth MJ, Kroemer G. Mechanism of action of conventional and targeted anticancer therapies: reinstating immunosurveillance. *Immunity* 2013; **39**: 74-88 [PMID: 23890065 DOI: 10.1016/j.immuni.2013.06.014]
 - 29 **Chen G**, Emens LA. Chemoimmunotherapy: reengineering tumor immunity. *Cancer Immunol Immunother* 2013; **62**: 203-216 [PMID: 23389507 DOI: 10.1007/s00262-012-1388-0]
 - 30 **Ramakrishnan R**, Huang C, Cho HI, Lloyd M, Johnson J, Ren X, Altio S, Sullivan D, Weber J,

- Celis E, Gaborilovich DI. Autophagy induced by conventional chemotherapy mediates tumor cell sensitivity to immunotherapy. *Cancer Res* 2012; **72**: 5483-5493 [PMID: [22942258](#) DOI: [10.1158/0008-5472.CAN-12-2236](#)]
- 31 **Vacchelli E**, Aranda F, Eggermont A, Galon J, Sautès-Fridman C, Cremer I, Zitvogel L, Kroemer G, Galluzzi L. *Trial Watch Onco Immunol* 2014; e27878 [DOI: [10.4161/onci.27878](#)]
 - 32 **Wei SC**, Duffy CR, Allison JP. Fundamental Mechanisms of Immune Checkpoint Blockade Therapy. *Cancer Discov* 2018; **8**: 1069-1086 [PMID: [30115704](#) DOI: [10.1158/2159-8290.CD-18-0367](#)]
 - 33 **Janjigian YY**, Bendell JC, Calvo E, Kim JW, Ascierto PA, Sharma P, Ott PA, Bono P, Jaeger D, Evans TRJ, De Braud FG, Chau I, Tschanka M, Harbison CT, Lin CS, Le DT. CheckMate-032: Phase I/II open-label study of safety and activity of nivolumab (nivo) alone or with ipilimumab (ipi) in advanced and metastatic (A/M) gastric cancer (GC). *J Clin Oncol* 2016; **34** [DOI: [10.1200/JCO.2016.34.15_suppl.4010](#)]
 - 34 **Le DT**, Bendell JC, Calvo E, Kim JW, Ascierto PA, Sharma P, Ott PA, Bono P, Jaeger D, Evans TRJ, De Braud FG, Chau I, Christensen O, Harbison C, Lin CS, Janjigian YY. Safety and activity of nivolumab monotherapy in advanced and metastatic (A/M) gastric or gastroesophageal junction cancer (GC/GEC): Results from the CheckMate-032 study. *J Clin Oncol* 2016; **34** [DOI: [10.1200/jco.2016.34.4_suppl.6](#)]
 - 35 **Suzuki Y**, Mimura K, Yoshimoto Y, Watanabe M, Ohkubo Y, Izawa S, Murata K, Fujii H, Nakano T, Kono K. Immunogenic tumor cell death induced by chemoradiotherapy in patients with esophageal squamous cell carcinoma. *Cancer Res* 2012; **72**: 3967-3976 [PMID: [22700877](#) DOI: [10.1158/0008-5472.CAN-12-0851](#)]
 - 36 **Yu S**, Cai L, Lin F, Wu X, Zhang C, Liu X, Li W. Durable Response After Combination Of Concurrent Chemoradiotherapy And Anti-PD-1 Therapy In HER2-Negative Advanced Gastric Adenocarcinoma: A Case Report. *Onco Targets Ther* 2019; **12**: 7691-7698 [PMID: [31571920](#) DOI: [10.2147/OTT.S221436](#)]
 - 37 **Bass AJ**, Thorsson V, Shmulevich I, Reynolds SM, Miller M, Bernard B, Hinoue T, Laird PW, Curtis C, Shen H, Weisenberger DJ, Schultz N, Shen RL, Weinhold N, Keiser DP, Bowlby R, Sipahimalani P, Cherniack AD, Getz G, Liu YC, Noble MS, Pedamallu C, Sougnez C, Taylor-Weiner A, Akbani R, Lee JS, Liu WB, Mills GB, Yang D, Zhang W, Pantazi A, Parfenov M, Gulley M, Piazuelo MB, Schneider BG, Kim J, Boussioutas A, Sheth M, Demchok JA, Rabkin CS, Willis JE, Ng S, Garman K, Beer DG, Pennathur A, Raphael BJ, Wu HT, Odze R, Kim HK, Bowen J, Leraas KM, Lichtenberg TM, Weaver L, McLellan M, Wiznerowicz M, Sakai R, Lawrence MS, Cibulskis K, Lichtenstein L, Fisher S, Gabriel SB, Lander ES, Ding L, Niu BF, Ally A, Balasundaram M, Birol I, Brooks D, Butterfield YSN, Carlsen R, Chu A, Chu J, Chuah E, Chun HJE, Clarke A, Dhalla N, Guin R, Holt RA, Jones SJM, Kasaian K, Lee D, Li HYA, Lim E, Ma Y, Marra MA, Mayo M, Moore RA, Mungall AJ, Mungall KL, Nip KM, Robertson AG, Schein JE, Tam A, Thiessen N, Beroukhi R, Carter SL, Cho J, DiCara D, Frazer S, Gehlenborg N, Heiman DI, Jung J, Lin P, Meyerson M, Ojesina AI, Pedamallu CS, Saksena G, Schumacher SE, Stojanov P, Tabak B, Voet D, Rosenberg M, Zack TI, Zhang HL, Zou LH, Protopopov A, Santoso N, Lee S, Zhang J, Mahadeshwar HS, Tang JB, Ren XJ, Seth S, Yang LX, Xu AW, Song XZ, Xi RB, Bristow CA, Hadjipanayis A, Seidman J, Chin L, Park PJ, Kucherlapati R, Ling SY, Rao A, Weinstein JN, Kim SB, Lu YL, Mills G, Bootwalla MS, Lai PH, Triche T, Van Den Berg DJ, Baylin SB, Herman JG, Murray BA, Askoy BA, Ciriello G, Dresdner G, Gao JJ, Gross B, Jacobsen A, Lee W, Ramirez R, Sander C, Senbabaoglu Y, Sinha R, Sumer SO, Sun YC, Iype L, Kramer RW, Kreisberg R, Rovira H, Tasman N, Haussler D, Stuart JM, Verhaak RGW, Leiserson MDM, Taylor BS, Black AD, Carney JA, Gastier-Foster JM, Helsel C, McAllister C, Ramirez NC, Tabler TR, Wise L, Zmuda E, Penny R, Crain D, Gardner J, Lau K, Curely E, Mallory D, Morris S, Paulauskis J, Shelton T, Shelton C, Sherman M, Benz C, Lee JH, Fedosenko K, Manikhas G, Voronina O, Belyaev D, Dolzhansky O, Rathmell WK, Brzezinski J, Ibbs M, Korski K, Kycler W, Lazniak R, Leporowska E, Mackiewicz A, Murawa D, Murawa P, Spychala A, Suchorska WM, Tatka H, Teresiak M, Abdel-Misih R, Bennett J, Brown J, Iacocca M, Rabeno B, Kwon SY, Kemkes A, Curley E, Alexopoulou I, Engel J, Bartlett J, Albert M, Park DY, Dhir R, Luketich J, Landreneau R, Janjigian YY, Kelsen DP, Cho E, Ladanyi M, Tang L, McCall SJ, Park YS, Cheong JH, Ajani J, Camargo MC, Alonso S, Ayala B, Jensen MA, Pihl T, Raman R, Walton J, Wan YH, Eley G, Shaw KRM, Tarnuzzer R, Wang ZN, Yang LM, Zenklusen JC, Davidsen T, Hutter CM, Sofia HJ, Burton R, Chudamani S, Liu J, Network CGAR. Comprehensive molecular characterization of gastric adenocarcinoma. *Nature* 2014; **513**: 202-209 [DOI: [10.1038/nature13480](#)]
 - 38 **Derks S**, Liao X, Chiaravalli AM, Xu X, Camargo MC, Solcia E, Sessa F, Fleitas T, Freeman GJ, Rodig SJ, Rabkin CS, Bass AJ. Abundant PD-L1 expression in Epstein-Barr Virus-infected gastric cancers. *Oncotarget* 2016; **7**: 32925-32932 [PMID: [27147580](#) DOI: [10.18632/oncotarget.9076](#)]
 - 39 **Fuchs CS**, Doi T, Jang RW, Muro K, Satoh T, Machado M, Sun W, Jalal SI, Shah MA, Metges JP, Garrido M, Golan T, Mandala M, Wainberg ZA, Catenacci DV, Ohtsu A, Shitara K, Geva R, Bleeker J, Ko AH, Ku G, Philip P, Enzinger PC, Bang YJ, Levitan D, Wang J, Rosales M, Dalal RP, Yoon HH. Safety and Efficacy of Pembrolizumab Monotherapy in Patients With Previously Treated Advanced Gastric and Gastroesophageal Junction Cancer: Phase 2 Clinical KEYNOTE-059 Trial. *JAMA Oncol* 2018; **4**: e180013 [PMID: [29543932](#) DOI: [10.1001/jamaoncol.2018.0013](#)]
 - 40 **Le DT**, Uram JN, Wang H, Bartlett BR, Kemberling H, Eyring AD, Skora AD, Luber BS, Azad NS, Laheru D, Biedrzycki B, Donehower RC, Zaheer A, Fisher GA, Crocenzi TS, Lee JJ, Duffy SM, Goldberg RM, de la Chapelle A, Koshiji M, Bhajee F, Huebner T, Hruban RH, Wood LD, Cuka N, Pardoll DM, Papadopoulos N, Kinzler KW, Zhou S, Cornish TC, Taube JM, Anders RA, Eshleman

- JR, Vogelstein B, Diaz LA Jr. PD-1 Blockade in Tumors with Mismatch-Repair Deficiency. *N Engl J Med* 2015; **372**: 2509-2520 [PMID: [26028255](#) DOI: [10.1056/NEJMoa1500596](#)]
- 41 **Kono K**, Nakajima S, Mimura K. Current status of immune checkpoint inhibitors for gastric cancer. *Gastric Cancer* 2020; **23**: 565-578 [PMID: [32468420](#) DOI: [10.1007/s10120-020-01090-4](#)]
- 42 **Yarchoan M**, Hopkins A, Jaffee EM. Tumor Mutational Burden and Response Rate to PD-1 Inhibition. *N Engl J Med* 2017; **377**: 2500-2501 [PMID: [29262275](#) DOI: [10.1056/NEJMc1713444](#)]
- 43 **Ayers M**, Lunceford J, Nebozhyn M, Murphy E, Loboda A, Kaufman DR, Albright A, Cheng JD, Kang SP, Shankaran V, Piha-Paul SA, Yearley J, Seiwert TY, Ribas A, McClanahan TK. IFN- γ -related mRNA profile predicts clinical response to PD-1 blockade. *J Clin Invest* 2017; **127**: 2930-2940 [PMID: [28650338](#) DOI: [10.1172/JCI91190](#)]
- 44 **Kim JW**, Lee HS, Nam KH, Ahn S, Kim JW, Ahn SH, Park DJ, Kim HH, Lee KW. *PIK3CA* mutations are associated with increased tumor aggressiveness and Akt activation in gastric cancer. *Oncotarget* 2017; **8**: 90948-90958 [PMID: [29207615](#) DOI: [10.18632/oncotarget.18770](#)]
- 45 **Upadhaya S**, Neftelino ST, Hodge JP, Oliva C, Campbell JR, Yu JX. Combinations take centre stage in PD1/PDL1 inhibitor clinical trials. *Nat Rev Drug Discov* 2021; **20**: 168-169 [PMID: [33177720](#) DOI: [10.1038/d41573-020-00204-y](#)]
- 46 **Cheng AL**, Hsu C, Chan SL, Choo SP, Kudo M. Challenges of combination therapy with immune checkpoint inhibitors for hepatocellular carcinoma. *J Hepatol* 2020; **72**: 307-319 [PMID: [31954494](#) DOI: [10.1016/j.jhep.2019.09.025](#)]
- 47 **Hodi FS**, Hwu WJ, Kefford R, Weber JS, Daud A, Hamid O, Patnaik A, Ribas A, Robert C, Gangadhar TC, Joshua AM, Hersey P, Dronca R, Joseph R, Hille D, Xue D, Li XN, Kang SP, Ebbinghaus S, Perrone A, Wolchok JD. Evaluation of Immune-Related Response Criteria and RECIST v1.1 in Patients With Advanced Melanoma Treated With Pembrolizumab. *J Clin Oncol* 2016; **34**: 1510-1517 [PMID: [26951310](#) DOI: [10.1200/JCO.2015.64.0391](#)]
- 48 **Bohnsack O**, Hoos A, Ludajic K. Adaptation and modification of the immune related response criteria (IRRC): IrRECIST. *J Clin Oncol* 2014; **32** [DOI: [10.1200/jco.2014.32.15_suppl.e22121](#)]
- 49 **Hodi FS**, O'Day SJ, McDermott DF, Weber RW, Sosman JA, Haanen JB, Gonzalez R, Robert C, Schadendorf D, Hassel JC, Akerley W, van den Eertwegh AJ, Lutzky J, Lorigan P, Vaubel JM, Linette GP, Hogg D, Ottensmeier CH, Lebbé C, Peschel C, Quirt I, Clark JI, Wolchok JD, Weber JS, Tian J, Yellin MJ, Nichol GM, Hoos A, Urban WJ. Improved survival with ipilimumab in patients with metastatic melanoma. *N Engl J Med* 2010; **363**: 711-723 [PMID: [20525992](#) DOI: [10.1056/NEJMoa1003466](#)]
- 50 **Chiou VL**, Burotto M. Pseudoprogression and Immune-Related Response in Solid Tumors. *J Clin Oncol* 2015; **33**: 3541-3543 [PMID: [26261262](#) DOI: [10.1200/JCO.2015.61.6870](#)]
- 51 **Anagnostou V**, Yarchoan M, Hansen AR, Wang H, Verde F, Sharon E, Collyar D, Chow LQM, Forde PM. Immuno-oncology Trial Endpoints: Capturing Clinically Meaningful Activity. *Clin Cancer Res* 2017; **23**: 4959-4969 [PMID: [28864724](#) DOI: [10.1158/1078-0432.CCR-16-3065](#)]
- 52 **Finn RS**, Ryoo B-Y, Merle P, Kudo M, Bouattour M, Lim H-Y, Breder VV, Edeline J, Chao Y, Ogasawara S, Yau T, Garrido M, Chan SL, Knox JJ, Daniele B, Ebbinghaus S, Chen E, Siegel AB, Zhu AX, Cheng A-L. Results of KEYNOTE-240: phase 3 study of pembrolizumab (Pembro) vs best supportive care (BSC) for second line therapy in advanced hepatocellular carcinoma (HCC). *J Clin Oncol* 2019; **37** [DOI: [10.1200/JCO.2019.37.15_suppl.4004](#)]
- 53 **Hung HM**, Wang SJ, O'Neill R. Statistical considerations for testing multiple endpoints in group sequential or adaptive clinical trials. *J Biopharm Stat* 2007; **17**: 1201-1210 [PMID: [18027226](#) DOI: [10.1080/10543400701645405](#)]
- 54 **Sah BK**, Zhang B, Zhang H, Li J, Yuan F, Ma T, Shi M, Xu W, Zhu Z, Liu W, Yan C, Li C, Liu B, Yan M. Neoadjuvant FLOT versus SOX phase II randomized clinical trial for patients with locally advanced gastric cancer. *Nat Commun* 2020; **11**: 6093 [PMID: [33257672](#) DOI: [10.1038/s41467-020-19965-6](#)]
- 55 **Carthon BC**, Wolchok JD, Yuan J, Kamat A, Ng Tang DS, Sun J, Ku G, Troncso P, Logothetis CJ, Allison JP, Sharma P. Preoperative CTLA-4 blockade: tolerability and immune monitoring in the setting of a presurgical clinical trial. *Clin Cancer Res* 2010; **16**: 2861-2871 [PMID: [20460488](#) DOI: [10.1158/1078-0432.CCR-10-0569](#)]
- 56 **Tarhini AA**, Edington H, Butterfield LH, Lin Y, Shuai Y, Tawbi H, Sander C, Yin Y, Holtzman M, Johnson J, Rao UN, Kirkwood JM. Immune monitoring of the circulation and the tumor microenvironment in patients with regionally advanced melanoma receiving neoadjuvant ipilimumab. *PLoS One* 2014; **9**: e87705 [PMID: [24498358](#) DOI: [10.1371/journal.pone.0087705](#)]
- 57 **Topalian SL**, Taube JM, Pardoll DM. Neoadjuvant checkpoint blockade for cancer immunotherapy. *Science* 2020; **367** [PMID: [32001626](#) DOI: [10.1126/science.aax0182](#)]
- 58 **Salmon H**, Idoyaga J, Rahman A, Leboeuf M, Remark R, Jordan S, Casanova-Acebes M, Khudoynazarova M, Agudo J, Tung N, Chakarov S, Rivera C, Hogstad B, Bosenberg M, Hashimoto D, Gnjatich S, Bhardwaj N, Palucka AK, Brown BD, Brody J, Ginhoux F, Merad M. Expansion and Activation of CD103(+) Dendritic Cell Progenitors at the Tumor Site Enhances Tumor Responses to Therapeutic PD-L1 and BRAF Inhibition. *Immunity* 2016; **44**: 924-938 [PMID: [27096321](#) DOI: [10.1016/j.immuni.2016.03.012](#)]
- 59 **Liu J**, Blake SJ, Yong MC, Harjunpää H, Ngiew SF, Takeda K, Young A, O'Donnell JS, Allen S, Smyth MJ, Teng MW. Improved Efficacy of Neoadjuvant Compared to Adjuvant Immunotherapy to Eradicate Metastatic Disease. *Cancer Discov* 2016; **6**: 1382-1399 [PMID: [27663893](#) DOI: [10.1158/2159-8290.CD-16-0577](#)]

- 60 **Forde PM**, Chaft JE, Smith KN, Anagnostou V, Cottrell TR, Hellmann MD, Zahurak M, Yang SC, Jones DR, Broderick S, Battafarano RJ, Velez MJ, Rekhtman N, Olah Z, Naidoo J, Marrone KA, Verde F, Guo H, Zhang J, Caushi JX, Chan HY, Sidhom JW, Scharpf RB, White J, Gabrielson E, Wang H, Rosner GL, Rusch V, Wolchok JD, Merghoub T, Taube JM, Velculescu VE, Topalian SL, Brahmer JR, Pardoll DM. Neoadjuvant PD-1 Blockade in Resectable Lung Cancer. *N Engl J Med* 2018; **378**: 1976-1986 [PMID: [29658848](#) DOI: [10.1056/NEJMoa1716078](#)]
- 61 **Jin H**, Li P, Mao C, Zhu K, Chen H, Gao Y, Yu J. Pathological Complete Response After a Single Dose of Anti-PD-1 Therapy in Combination with Chemotherapy as a First-Line Setting in an Unresectable Locally Advanced Gastric Cancer with PD-L1 Positive and Microsatellite Instability. *Onco Targets Ther* 2020; **13**: 1751-1756 [PMID: [32161470](#) DOI: [10.2147/OTT.S243298](#)]



Published by **Baishideng Publishing Group Inc**
7041 Koll Center Parkway, Suite 160, Pleasanton, CA 94566, USA

Telephone: +1-925-3991568

E-mail: bpgoffice@wjgnet.com

Help Desk: <https://www.f6publishing.com/helpdesk>

<https://www.wjgnet.com>

